

Stress Echocardiography Expert Consensus Statement—Executive Summary

European Association of Echocardiography (EAE) (a registered branch of the ESC)

Rosa Sicari^{1*}, Petros Nihoyannopoulos², Arturo Evangelista³, Jaroslav Kasprzak⁴, Patrizio Lancellotti⁵, Don Poldermans⁶, Jens-Uwe Voigt⁷, and Jose Luis Zamorano⁸ on behalf of the European Association of Echocardiography

¹Institute of Clinical Physiology, Pisa, Italy; ²Hammersmith Hospital, NHLI, Imperial College, London, UK; ³Hospital Vall d'Hebron, Barcelona, Spain; ⁴Department of Cardiology, Medical University of Lodz, Lodz, Poland; ⁵Department of Cardiology, University Hospital Sart Tilman, Liège, Belgium; ⁶Erasmus Medical Center, Rotterdam, The Netherlands; ⁷Catholic University, Leuven, Belgium; and ⁸Instituto Cardiovascular, Hospital Clínico San Carlos, Madrid, Spain

Online publish-ahead-of-print 11 November 2008

Stress echocardiography is the combination of echocardiography with a physical, pharmacological, or electrical stress. The diagnostic endpoint for the detection of myocardial ischaemia is the induction of a transient worsening in regional function during stress. Stress echocardiography provides similar diagnostic and prognostic accuracy to radionuclide stress perfusion imaging, but at a substantially lower cost, without environmental impact, and with no biohazards for the patient and the physician.

Among different stresses of comparable diagnostic and prognostic accuracy, semisupine exercise is the most used, dobutamine the best test for viability, and dipyridamole the safest and simplest pharmacological stress and the most suitable for combined wall motion coronary flow reserve assessment. The additional clinical benefit of myocardial perfusion contrast echocardiography and myocardial velocity imaging has been inconsistent to date, whereas the possibility of performing coronary flow reserve evaluation of the left anterior descending coronary artery by transthoracic Doppler echocardiography adds another potentially important dimension to stress echocardiography. New emerging fields of application taking advantage of the versatility of the technique are Doppler stress echo in valvular heart disease and in dilated cardiomyopathy. In spite of its dependence on the operator's training, stress echocardiography is today the best (most cost-effective and risk-effective) possible imaging choice to achieve the still elusive target of sustainable cardiac imaging in the field of non-invasive diagnosis of coronary artery disease.

Stress echo: a historical and socio-economic perspective

In 1935, Tennant and Wiggers¹ demonstrated that coronary occlusion immediately resulted in instantaneous abnormality of wall motion. A large body of evidence^{2–5} recognized for the first time that transient dys-synergy was an early, sensitive, specific marker of transient ischaemia, clearly more accurate than ECG changes and pain. In European clinical practice,^{6–10} stress echo has been embedded in the legal and cultural framework of existing European laws and medical imaging referral guidelines. The radiation used for medical examinations and tests is the greatest man-made source of radiation exposure.¹¹ Small individual risks of each test performed with ionizing radiation multiplied by a billion examinations become significant population risks. For this reason, in Europe, both the law¹¹ and the referral guidelines for medical imaging¹² recommend a justified, optimized, and responsible use of testing with ionizing radiation. European Commission referral guidelines were released in 2001 in application of the Euratom Directive, and explicitly state that a non-ionizing technique must be used whenever it will give information grossly comparable with an ionizing investigation. For instance, 'because MRI does not use ionizing radiation, MRI should be preferred when both CT and MRI would provide similar information and when both are available'.¹² In this perspective of the medical, as well as socio-economic and biological impact of medical imaging, it is imperative to increase all efforts to improve appropriateness¹³

* Corresponding author. Tel: +39 0503152397, Fax: +39 0503152374, E-mail: rosas@ifc.cnr.it

and minimize the radiation burden of stress imaging for the population and the individual patient.¹⁴ The imperative of sustainability of medical imaging is likely to become increasingly important in the near future, also from a US perspective.^{15,16} In the quest for sustainability, stress echocardiography has unsurpassed assets of low cost, absence of environmental impact, and lack of biological effects for both the patient¹⁷ and the operator compared with equally accurate, but less sustainable, competing techniques.¹⁸

Pathophysiological mechanisms

Stress echocardiography is the combination of 2D echocardiography with a physical, pharmacological, or electrical stress.¹⁹ The diagnostic endpoint for the detection of myocardial ischaemia is the induction of a transient change in regional function during stress. The stress echo sign of ischaemia is a stress-induced worsening of function in a region contracting normally at baseline. The stress echo sign of myocardial viability is a stress-induced improvement of function during low levels of stress in a region that is abnormal at rest. A transient regional imbalance between oxygen demand and supply usually results in myocardial ischaemia, the signs and symptoms of which can be used as a diagnostic tool. Myocardial ischaemia results in a typical 'cascade' of events in which the various markers are hierarchically ranked in a well-defined time sequence.²⁰ Flow heterogeneity, especially between the subendocardial and subepicardial perfusion, is the forerunner of ischaemia, followed by metabolic changes, alteration in regional mechanical function, and only at a later stage by electrocardiographic changes, global left ventricular (LV) dysfunction, and pain. The pathophysiological concept of the ischaemic cascade is translated clinically into a gradient of sensitivity of different available clinical markers of ischaemia, with chest pain being the least and regional malperfusion the most sensitive. This is the conceptual basis of the undisputed advantages of imaging techniques, such as perfusion imaging or stress echocardiography over electrocardiogram (ECG) for the non-invasive detection of coronary artery disease.²¹ The reduction of coronary reserve is the common pathophysiological mechanism. Regardless of the stress used and the morphological substrate, ischaemia tends to propagate centrifugally with respect to the ventricular cavity;^{21,22} it involves primarily the subendocardial layer, whereas the subepicardial layer is affected only at a later stage if the ischaemia persists. In fact, extravascular pressure is higher in the subendocardial than in the subepicardial layer; this provokes a higher metabolic demand (wall tension being among the main determinants of myocardial oxygen consumption) and an increased resistance to flow. In the absence of coronary artery disease, coronary flow reserve (CFR) can be reduced in microvascular disease (e.g. in syndrome X) or LV hypertrophy (e.g. arterial hypertension). In this condition, angina with ST-segment depression can occur with regional perfusion changes, typically in the absence of any regional wall motion abnormalities during stress. Wall motion abnormalities are more specific than CFR and/or perfusion changes for the diagnosis of coronary artery disease.^{23–28}

Key point: wall motion and perfusion (or CFR) changes are highly accurate, and more accurate than ECG

changes, for detection and location of underlying coronary artery disease. However, wall motion is more specific and requires ischaemia; perfusion changes are more sensitive and may occur in the absence of true ischaemia.

Ischaemic stressors

The three most common stressors are exercise, dobutamine, and dipyridamole (Figures 1 and 2). Exercise is the prototype of demand-driven ischaemic stress and the most widely used. However, out of five patients, one cannot exercise, one exercises submaximally, and one has an uninterpretable ECG. Thus, the use of an exercise-independent approach allows the diagnostic domain of a stress test laboratory to be expanded.^{29,30} Pharmacological stressors minimize factors such as hyperventilation, tachycardia, hypercontraction of normal walls, and excessive chest wall movement, which render the ultrasonic examination difficult during exercise. All these factors degrade image quality and—in stress echo—worse image quality dramatically leads to higher interobserver variability and lower diagnostic accuracy. Dipyridamole (or adenosine) and dobutamine act on different receptor populations: dobutamine stimulates adrenoreceptors whereas dipyridamole (which accumulates endogenous adenosine) stimulates adenosine receptors.³¹ They induce ischaemia through different haemodynamic mechanisms: dobutamine primarily increases myocardial oxygen demand³² and dipyridamole (or adenosine) mainly decreases subendocardial flow supply³³ (Table 1). In the presence of coronary atherosclerosis, appropriate arteriolar dilation can paradoxically exert detrimental effects on regional myocardial layers or regions already well perfused in resting conditions at the expense of regions or layers with a precarious flow balance in resting conditions. In 'vertical steal', the anatomical requisite is the presence of an epicardial coronary artery stenosis and the subepicardium 'steals' blood from the subendocardial layers. The mechanism underlying vertical steal is a fall in perfusion pressure across the stenosis. In the presence of a coronary stenosis, the administration of a coronary vasodilator causes a drop in post-stenotic pressure and, therefore, a critical drop in subendocardial perfusion pressure, which in turn provokes a decrease in absolute subendocardial flow, even with subepicardial overperfusion.

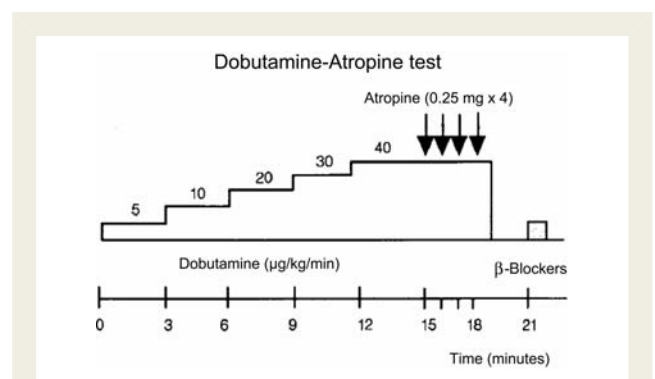


Figure 1 State-of-the-art protocol for dobutamine stress echocardiography.

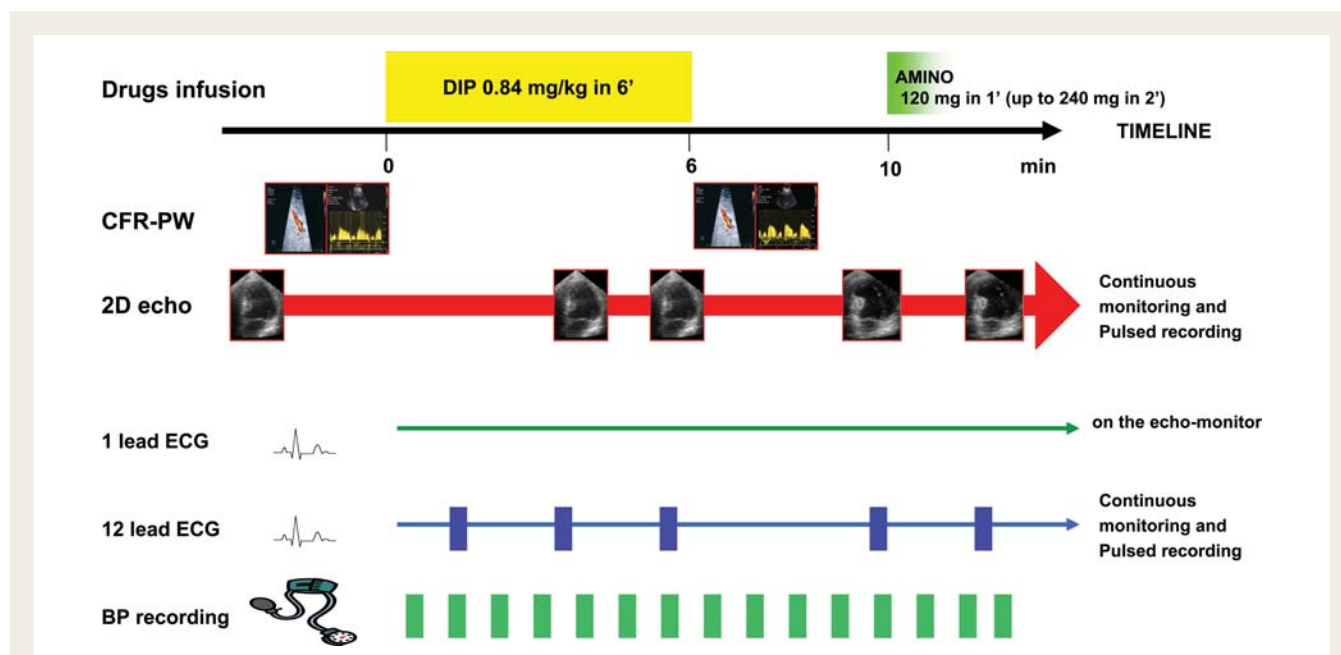


Figure 2 State-of-the art protocol for dipyridamole stress echocardiography.

Table 1 Pharmacological stresses

	Vasodilator	Dobutamine
Receptor targets	A ₂ adenosine	α1; β1; β2 adrenoreceptors
Haemodynamic mechanisms	Reduces supply	Increases supply
Physiological targets	Coronary arterioles	Myocardium
Cellular targets	Smooth muscle cells	Myocytes
Antidote	Aminophylline	β-Blockers
Stress	Dipyridamole (adenosine)	Dobutamine
Contraindications	Asthma, bradyarrhythmias	Tachyarrhythmias, hypertension

Regional thickening is closely related to subendocardial rather than transmural flow, and this explains the regional asynergy with ischaemia, despite regionally increased transmural flow. Since endocardial oxygen demands are greater than epicardial demands, the resistance vessels of the endocardium are more dilated than those of the subepicardium, ultimately resulting in selective subendocardial hypoperfusion. 'Horizontal steal' requires the presence of collateral circulation between two vascular beds, with the victim of the steal being the myocardium fed by the more stenotic vessel. The arteriolar vasodilatory reserve must be preserved, at least partially, in the donor vessel and abolished in the vessel receiving collateral flow. After vasodilation, the flow in the collateral circulation is reduced in comparison with resting conditions. Despite the different pathophysiological mechanism,

Table 2 Stress echocardiography in four equations

Rest	+	Stress	=	Diagnosis
Normokinesis	+	Normo- to hyperkinesis	=	Normal
Normokinesis	+	Hypokinesis, akinesis, dyskinesis	=	Ischaemia
Akinesis	+	Hypokinesis, normokinesis	=	Viable
Akinesis to dyskinesis	+	Akinesis to dyskinesis	=	Necrosis

ischaemia induction when appropriately high doses with state-of-the-art protocols are used, dipyridamole and dobutamine tests show a similar diagnostic accuracy.³⁴⁻³⁷

Key point: exercise, dobutamine, and vasodilators (at appropriately high doses) are equally potent ischaemic stressors for inducing wall abnormalities in the presence of a critical epicardial coronary artery stenosis. Dobutamine and exercise mainly act through increased myocardial oxygen demand, and dipyridamole and adenosine through reduced subendocardial flow supply subsequent to inappropriate arteriolar vasodilation and steal phenomena.

Diagnostic criteria

All stress echocardiographic diagnoses can be easily summarized into equations centred on regional wall function describing the fundamental response patterns as normal, ischaemic, viable, and

necrotic myocardium. In the normal response, a segment is normokinetic at rest and normal or hyperkinetic during stress. In the ischaemic response, a segment worsens its function during stress from normokinesis to hypokinesis, akinesis, or dyskinesis (usually at least two adjacent segments are required for test positivity) (Table 2). In the necrotic response, a segment with resting dysfunction remains fixed during stress. In the viability response, a segment with resting dysfunction may show either a sustained improvement during stress, indicating a non-jeopardized myocardium (stunned), or improve during early stress with subsequent deterioration at peak (biphasic response). This response would indicate a jeopardized region (hibernating myocardium) often improving after revascularization.^{19,38} A resting akinesis which becomes dyskinesis during stress usually reflects a purely passive, mechanical consequence of increased intraventricular pressure developed by normally contracting walls, and should not be considered a true active ischaemia.³⁹

As with most imaging techniques, patient-dependent factors can limit image quality in stress echocardiography, which can adversely affect accuracy. Obesity and lung disease, for example, may lead to poor acoustic windows in ~10% of patients. Harmonic imaging and ultrasound contrast agents for LV opacification are now recommended to enhance endocardial border detection. Given that the interpretation of contractile function is subjective, improved image quality can reduce inter-reader variability.

Key point: all stress echo responses follow four basic patterns: normal (rest = stress = normal function); ischaemia (rest = normal; stress = abnormal); necrotic (rest = stress = abnormal); and viability (rest = abnormal; stress = normal or biphasic). Clear endocardial definition is crucial for optimal interpretation and it is recommended that harmonic imaging, when available, be routinely used for optimal endocardial border detection. Contrast-enhanced endocardial border detection could be used when suboptimal imaging is present.

Diagnostic accuracy

Exercise,^{23,40–50} high-dose dobutamine,^{51–55} and high-dose (accelerated or with atropine) dipyridamole^{29,35,36,46,52,56,57} have not only similar accuracies, but also similar sensitivities.^{35,36,58} (Tables 3 and 4). Familiarity with all forms of stress is an index of the quality of the echo lab. In this way, indications in the individual patient can be optimized, thereby avoiding the relative and absolute contraindications of each test. For instance, a patient with severe hypertension and/or a history of significant atrial or ventricular arrhythmias can more reasonably undergo the dipyridamole stress test which, unlike dobutamine, has no arrhythmogenic or hypertensive effect. In contrast, a patient with severe conduction disturbances or advanced asthmatic disease should undergo the dobutamine stress test, since adenosine has a negative chronotropic and dromotropic effect, as well as a documented bronchoconstrictor activity. Patients either taking xanthine medication or under the effect of caffeine contained in drinks (tea, coffee, and cola) should undergo the dobutamine test. Both dipyridamole and dobutamine have overall tolerance and feasibility. The choice of one test over the other depends on patient characteristics, local drug cost, and the

Table 3 Dipyridamole-stress vs dobutamine-stress echocardiography for detection of coronary artery disease

	Sn (%) ^a , n		Sn 1 v (%) ^b , n		Sn multiv (%) ^c , n		Sp (%) ^d , n		Acc (%) ^e , n	
	Dip	Dob	Dip	Dob	Dip	Dob	Dip	Dob	Dip	Dob
Salustri et al., 1992	82, 23/28	79, 22/28	50, 5/10	40, 4/10	72, 13/18	67, 12/18	89, 16/18	78, 14/18	85, 39/46	72, 36/46
Pingitore et al., 1996	82, 75/92	84, 77/92	71, 29/41	78, 32/41	91, 46/51	87, 44/51	94, 17/18	89, 15/18	84, 92/110	84, 92/110
San Roman et al., 1996	81, 54/66	78, 52/66	68, 22/32	75, 24/32	94, 32/34	82, 28/34	94, 34/36	88, 32/36	86, 88/102	82, 82/102
Loimaala et al., 1999	93, 41/44	95, 42/44	92, 24/26	92, 24/26	94, 17/18	100, 18/18	75, 12/16	63, 10/16	87, 53/60	88, 52/60
Nedejicovic et al., 2006	96, 66/69	93, 64/69	95, 54/57	95, 54/57	100, 12/12	100, 12/12	92, 44/48	92, 44/48	91, 107/117	94, 110/117
Total	87, 259/299	86, 257/299	81, 134/166	83, 138/166	90, 120/133	86, 114/133	90, 123/136	84, 115/136	87, 379/435	85, 372/435

Table 4 Dipyridamole (DIP) stress vs exercise (EXE) stress echocardiography for detection of coronary artery disease

Authors, year	Sensitivity			Specificity			Accuracy			Feasibility		
	Single vessel			Multivessel			Global					
	DIP	EXE	DIP	EXE	DIP	EXE	DIP	EXE	DIP	EXE	DIP	EXE
Picano et al., 1987	6/13 (46%)	8/13 (62%)	12/12 (100%)	11/12 (92%)	18/25 (72%)	19/25 (76%)	15/15 (100%)	13/15 (87%)	33/40 (83%)	32/40 (80%)	55/55 (100%)	40/55 (73%)
Deutsch et al., 1994	19/30 (63%)	20/30 (67%)	18/21 (86%)	18/21 (86%)	37/51 (73%)	38/51 (75%)	13/15 (87%)	12/15 (80%)	50/66 (76%)	50/66 (76%)	74/80 (95%)	66/80 (84%)
Marangelli et al., 1994	4/16 (25%)	13/16 (81%)	11/19 (58%)	18/19 (95%)	15/35 (43%)	31/35 (89%)	23/25 (92%)	22/25 (88%)	38/60 (63%)	53/60 (88%)	80/82 (92%)	84/100 (84%)
Beleslin et al., 1994	78/108 (72%)	95/108 (88%)	10/11 (91%)	10/11 (91%)	88/119 (74%)	105/119 (88%)	16/17 (94%)	14/17 (82%)	105/136 (77%)	118/136 (87%)		
Dagianti et al., 1995	3/10 (30%)	7/10 (70%)	10/15 (70%)	12/15 (80%)	13/25 (52%)	19/25 (76%)	34/35 (97%)	33/35 (94%)	47/60 (78%)	52/60 (87%)	60/60 (100%)	57/60 (95%)
Bjornstad et al., 1995					21/31 (68%)	26/31 (84%)	6/6 (100%)	4/6 (67%)	27/37 (73%)	30/37 (81%)		
Schroder et al., 1996					50/65 (77%)	35/65 (53%)	8/9 (89%)	8/9 (89%)	58/74 (78%)	43/74 (58%)	119/121 (98%)	74/83 (89%)
Loimaala et al., 1999	24/26 (92%)	23/26 (88%)	17/18 (94%)	17/18 (94%)	41/44 (93%)	40/44 (91%)	12/16 (75%)	7/16 (44%)	53/60 (88%)	47/60 (78%)	388/398 (97%)	321/398 (81%)
Total	134/203 (66%)	166/203 (72%)	78/96 (81%)	86/96 (90%)	283/395 (72%)	313/395 (79%)	127/138 (92%)	113/138 (82%)	411/533 (77%)	425/533 (80%)	388/398 (97%)	321/398 (81%)

physician's preference. It is important for all stress echocardiography laboratories to become familiar with all stresses in order to achieve a flexible and versatile diagnostic approach that enables the best stress to be tailored to individual patient needs. Antianginal medical therapy (in particular, β -blocking agents) significantly affects the diagnostic accuracy of all forms of stress; therefore, it is recommended, whenever possible, to withhold medical therapy at the time of testing to avoid a false-negative result.

Key point: physical or pharmacological (inotropic or vasodilator) stress echocardiography have comparable diagnostic accuracies. The choice of one test over the other will depend on relative contraindications. Large volume laboratories should be fully acquainted with all the three main forms of stress in order to apply the test in all patients. In the presence of a submaximal first-line stress for limiting side effects, the second choice should be applied, since submaximal (physical or pharmacological) stresses have suboptimal diagnostic value.

Prognostic value of inducible myocardial ischaemia

The presence (or absence) of inducible wall motion abnormalities separates patients with different prognoses. Information has been obtained from data banks of thousands of patients—also with multicentre design—for exercise,^{59–75} dobutamine,^{76–80} and dipyridamole.^{81–85} A normal stress echocardiogram yields an annual risk of 0.4–0.9% based on a total of 9000 patients,⁷⁵ the same as for a normal stress myocardial perfusion scan. Thus in patients with suspected coronary artery disease, a normal stress echocardiogram implies excellent prognosis, and coronary angiography can safely be avoided. The positive and the negative response can be further stratified with interactions with clinical parameters (diabetes, renal dysfunction, and therapy at the time of test), resting echo (global LV function), and additive stress echo parameters (LV cavity dilatation, CFR, and previous revascularization). The established prognostic stress echo parameters with their relative event rates are shown in *Tables 5* and *6*.

Table 5 Stress echo risk titration of a positive test

One-year risk (hard events)	Intermediate (1–3% year)	High (>10% year)
Dose/workload	High	Low
Resting EF	>50%	<40%
Anti-ischaemic therapy	Off	On
Coronary territory	LCx/RCA	LAD
Peak WMSI	Low	High
Recovery	Fast	Slow
Positivity or baseline dys-synergy	Homozonal	Heterozonal
CFR	>2.0	<2.0

CFR, coronary flow reserve; EF, ejection fraction; LAD, left anterior descending artery; LCx, left circumflex; RCA, right coronary artery; WMSI, wall motion score index.

Table 6 Stress echo risk titration of a negative test

One-year risk (hard events)	Very low (<0.5% year)	Low (1–3% year)
Stress	Maximal	Submaximal
Resting EF	>50%	<40%
Anti-ischaemic therapy	Off	On
CFR	>2.0	<2.0

CFR, coronary flow reserve; EF, ejection fraction.

Key point: physical or pharmacological (inotropic or vasodilator) stress echocardiography have a comparable prognostic power of stratification. The most extensive evidence is available with dipyridamole, dobutamine, and exercise tests. A normal baseline and stress echocardiogram gives an annual risk for death of 0.4–0.9%, the same as for a normal stress myocardial perfusion scan. Thus, in patients with suspected coronary artery disease, a normal stress echocardiogram implies an excellent prognosis, and coronary angiography can safely be avoided.

Indications and prognostic value of myocardial viability assessment

By far the widest experience is available with low-dose dobutamine stress echocardiography,^{6,7,86–88} the preferred stressor for assessing myocardial viability. However, it is also possible to assess the presence of myocardial viability using low-dose dipyridamole, low-level exercise, or enoximone.^{89–94} In the setting of ischaemia, loss of myocardial contractile function may be due to myocardial necrosis, stunning, or hibernation. Whereas myocardial necrosis usually alludes to irreversible myocardial dysfunction, stunning and hibernation reflect reversibility of myocardial function. Revascularization of chronically, but reversibly, dysfunctional myocardium, often referred to as hibernating or viable, has emerged as an important alternative in the treatment of heart failure secondary to coronary artery disease. Observational studies have indeed suggested that patients with ischaemic LV dysfunction and a significant amount of viable myocardium [at least five segments or a wall motion score index (WMSI) >0.25]^{95–104} have lower perioperative mortality, greater improvements in regional and global LV function, fewer heart failure symptoms, and improved long-term survival after revascularization than patients with large areas of non-viable myocardium.

Key point: dobutamine stress echocardiography is by far the most widely used method for assessing viable myocardium. This is highly recommended in patients with LV dysfunction who may benefit from coronary revascularization. When dobutamine is contraindicated or not well tolerated, several other stresses (low-level exercise, adenosine, dipyridamole, and enoximone) can be used to elicit a regional inotropic reserve in viable myocardium.

Table 7 Life-threatening complications in single-centre experience (>1000 patients), multicentre studies (EDIC) and multicentre registries for dobutamine stress echocardiography

Author, year	Patients	Complication(s)
Single institution experience		
Mertes <i>et al.</i> , 1993	1118	None ^a
Pellikka <i>et al.</i> , 1995	1000	1 AMI, 4 VT, 1 prol ischaemia
Zahn <i>et al.</i> , 1996	1000	1 VF, 1 LVF, 1 seizure
Secknus and Marwick, 1997	3011	5 VT, 1 AMI, 1 prol ischaemia, 1 hypo
Elhendy <i>et al.</i> , 1998	1164	7 VT
Bremer <i>et al.</i> , 1998	1035	1 VF, 1 VT
Poldermans <i>et al.</i> , 1994	1734	3 VF, 13 VT, 6 hypo
Mathias <i>et al.</i> , 1999	4033	1 VF, 8 VT, 1 MI; 5 atropine intoxications
Multicentre registry		
Picano <i>et al.</i> (EDIC), 1994	2949	2 VF, 2 VT, 2 AMI, 1 prol ischaemia, 1 hypo
Pezzano <i>et al.</i> (RITED), 1994	3041	2 VF, 1 asystole
Beckmann <i>et al.</i> , 1999	9354	324 (2 VF)
Varga <i>et al.</i> , 2006	35 103	63 (5 deaths)
Total	64 542	461

^aNo life-threatening complications reported; however, minor and self-limiting adverse effects were documented.

AMI, acute myocardial infarction; MI, myocardial infarction; prol, prolonged; hypo, hypokinetic; VF, ventricular fibrillation; VT, ventricular tachycardia.

Safety of pharmacological stress echocardiography

Minor, but limiting, side effects preclude the achievement of maximal pharmacological stress in <10% of patients with dobutamine⁹ and <5% in patients with dipyridamole stress.^{105–119} The most frequent minor and major complications during stress echo and their frequencies are shown in Tables 7–9. The data emphasize some obvious, albeit sometimes neglected, points. First, pharmacological stress tests should always be performed with an attending physician present. Secondly, every test carries a definite, albeit minor risk. Thirdly, not all stress tests carry the same risk of major adverse reactions, and dobutamine stress testing may be more dangerous than other forms of pharmacological stress, such as those produced by dipyridamole or adenosine. These conclusions come convergently from multicentre trials, meta-analyses of published literature, and the Registry of Complications based on prospective data acquisition (German Registry) and retrospective data retrieval. Physical stress with exercise is probably safer than pharmacological testing.^{118,119}

Key point: exercise is safer than pharmacological stress. Among pharmacological stresses, dipyridamole is safer than dobutamine. Both the doctor and the patient

should be aware of the rate of complications—and the rate of complications (derived from literature and from the lab experience) should be spelled out in the informed consent.

Indication for stress echo

Indications for stress echocardiography can also be grouped in very broad categories:

- (i) coronary artery disease diagnosis;
- (ii) prognosis and risk stratification in patients with established diagnosis (e.g. after myocardial infarction);

Table 8 Life-threatening complications in multicentre studies (EPIC) and multicentre registries for dipyridamole stress echocardiography

Author, year	Patients	Complications
Multicentre registry		
Picano et al., 1992	10 451	1 cardiac death, 1 asystole, 2 AMI, 1 pulmonary oedema, 1 sustained VT
Varga et al., 2006	24 599	19 (1 death)
Total	35 050	25

AMI, acute myocardial infarction; VT, ventricular tachycardia.

Table 9 Safety profile of pharmacological stress echocardiography

	Dobutamine	Dipyridamole
% submaximal tests	10%	5%
Side effects	1/300 exams	1/1000
VT, VF	++	+
High grade AV block	+	++
Death	1/5000	1/10000

AV, arteriovenous; VF, ventricular fibrillation; VT, ventricular tachycardia.

- (iii) pre-operative risk assessment;
- (iv) evaluation for cardiac aetiology of exertional dyspnoea;
- (v) evaluation after revascularization;
- (vi) ischaemia location;¹²⁰
- (vii) evaluation of heart valve stenosis severity.

As a rule, the less informative the exercise ECG test is, the stricter the indication for stress echocardiography will be.

The five main specific indications for stress echocardiography can be summarized as follows:

- (i) patients in whom the exercise stress test is contraindicated (e.g. patients with severe arterial hypertension);
- (ii) patients in whom the exercise stress test is not feasible (e.g. those with intermittent claudication);
- (iii) patients in whom the exercise stress test was non-diagnostic or yielded ambiguous results;
- (iv) left bundle branch block or significant resting ECG changes that makes any ECG interpretation during stress difficult;
- (v) submaximal stress ECG.

Stress echocardiography yields the greatest incremental diagnostic and prognostic value in patients in whom exercise electrocardiography is non-diagnostic, ambiguous, or inconclusive. Pharmacological stress echocardiography is the choice for patients in whom exercise is not feasible or contraindicated. The results of physical and pharmacological stress echo should be used in both inpatients and outpatients as 'a gatekeeper' to coronary angiography. In fact, for any given coronary anatomy, the prognostic benefit of recanalization is much higher with documented ischaemia on stress testing. Patients with stress echo positivity, especially those with a 'high-risk' positivity pattern (occurring at low dose or workload, with slow recovery and/or antidote resistance, with akinesis or dyskinesis of more than five segments of the left ventricle), should be referred to coronary angiography. In Table 10, several clinical targets of stress echocardiography are reported.

Key point: stress echocardiography should not be used as a first-line imaging technique for diagnostic and prognostic purposes in patients with known or suspected coronary artery disease, but only when the exercise ECG stress test is either non-diagnostic or non-interpretable (e.g. for left bundle branch block or pacemaker). The less informative

Table 10 Clinical targets: coronary artery disease, dilated cardiomyopathy, valvular disease, and pulmonary hypertension

Clinical condition	Pathophysiological target	Stress of choice	Echo variable
Coronary artery disease	Myocardial ischaemia	Ex, Dob, Dip	WM
Dilated cardiomyopathy	Contractile reserve	Dob (Ex, Dip)	WM
Diabetes, hypertension, HCM	Coronary flow reserve	Dip (Dob, Ex)	PW LAD
Transmitral gradient	Increase in cardiac output	Ex, Dob	PW mitral
Transaortic gradient	Increase in cardiac output	Ex, Dob	CW aortic
Pulmonary hypertension	Pulmonary congestion/vasoconstriction	Ex	CW TR

CW, continuous wave Doppler; DC, dilated cardiomyopathy; Dip, dipyridamole; Dob, dobutamine; Ex, exercise; HCM, hypertrophic cardiomyopathy; LAD, left anterior descending coronary artery; PW, pulsed wave Doppler; TR, tricuspid regurgitation; WM, wall motion;

and/or interpretable exercise electrocardiography is, the higher is the level of appropriateness to stress echocardiography. No new technology application to stress echocardiography is routinely recommended.

New technologies applied to stress echocardiography

The state-of-the-art diagnosis of ischaemia in stress echocardiography remains the eyeballing interpretation of regional wall motion in black and white cine loops. New quantitative techniques can objectify regional myocardial function assessment and, thus, have the potential to reduce observer dependence and to shorten learning curves.¹²¹ Doppler- and speckle tracking-based myocardial velocity and deformation measurements have been proposed, and shown to detect ischaemia and to predict patient outcome.^{121,122} Data noise and time-consuming analysis are issues that still need to be solved in Doppler-based approaches. Speckle tracking- and 3D echocardiography-derived data have currently insufficient temporal resolution for the high heart rates of a bicycle or dobutamine stress test.

Comparison with competing techniques: cost and risk assessment

Given the many factors affecting the value of diagnostic accuracy, reliable information on the relative value of different tests can only be gained by studying an adequate number of patients in head-to-head comparison under the same conditions. When compared with standard exercise electrocardiography testing, stress echocardiography has an advantage in terms of sensitivity and a particularly impressive advantage in terms of specificity. In recent guidelines, the advantages of stress echocardiography over perfusion scintigraphy include higher specificity, greater versatility, greater convenience, and lower cost.¹²³ The advantages of stress perfusion imaging include a higher technical success rate, higher sensitivity (especially for single-vessel disease involving the left circumflex), better accuracy when multiple resting LV wall motion abnormalities are present, and a more extensive database for the evaluation of prognosis.^{124,125} The ESC Guidelines on stable angina conclude that 'On the whole, stress echo and stress perfusion scintigraphy, whether using exercise or pharmacological stress (inotropic or vasodilator), have very similar applications. The choice as to which is employed depends largely on local facilities and expertise'.¹²⁰ Cardiac magnetic resonance (CMR) is the latest technique to enter the field of cardiac imaging.^{126–130} The advantages of the technique are related to the absence of ionizing radiation, at the price of higher costs and lower availability when compared with echocardiography. Despite the high costs, the time of image acquisition, safety profile, and low availability make CMR an excellent option only when stress echocardiography is inconclusive or not feasible.¹³ The high cost of stress imaging procedures warrants some financial justification, and three arguments have been proposed.

First, a negative stress imaging test implies such a low risk of an event that revascularization could not be justified on prognostic grounds. Secondly, compared with simple stress testing, the use of imaging tests in particular situations has been shown to reduce downstream costs (both diagnostic and therapeutic). Thirdly, several studies have shown that in comparison with coronary angiography (where the detection of coronary stenoses seems to lead inexorably to coronary intervention), decision-making based on functional testing is associated with similar outcomes at lower levels of downstream cost. On the basis of this large body of evidence assessing the comparable accuracy of stress echo and perfusion scintigraphy, the choice of one test over the other will depend on the overall biological risk related to the use of radiations. This is recommended by the executive European Law (1997) and the European Commission Medical Imaging Guidelines (2001). EU Medical Imaging Guidelines and the European law (Euratom directive 97/43) state that a radiological (and medico-nuclear) examination can be performed only 'when it cannot be replaced by other techniques that do not employ ionising radiation' and it should always be justified (article 3: 'if an exposure cannot be justified it should be prohibited'). At patient level, the effective dose of a single nuclear cardiology stress imaging scan ranges from 10 to 27 mSv (with dual isotope imaging protocol). The corresponding equivalent dose exposure is 500 chest X-rays (sestamibi), 1200 chest X-rays (thallium), and 1300 chest X-rays (dual isotope protocol). According to the latest and most authoritative estimates of BEIR VII, the estimated risk of cancer for a middle-aged patient ranges from 1 in 1000 (for a sestamibi) to 1 in 400 (for a dual isotope scan). Therefore, in an integrated risk–benefit balance, stress echo has shown advantages when compared with imaging techniques such as scintigraphy.^{13,17,131}

Key point: stress echocardiography should be preferred due to its lower cost, wider availability, and—most importantly—for its radiation-free nature. Stress scintigraphy offers similar information to stress echocardiography, but with a radiation burden equivalent to between 600 and 1300 chest X-rays for every single stress scintigraphy. This poses a significant biological risk both for the individual and for society, since small individual risks multiplied by millions of stress tests per year become a significant population burden.

For the complete document refer to: Sicari R, Nihoyannopoulos P, Evangelista A, Kasprzak J, Lancellotti P, Poldermans D, Voigt JU, Zamorano JL; European Association of Echocardiography. Stress echocardiography expert consensus statement: European Association of Echocardiography (EAE) (a registered branch of the ESC). *Eur J Echocardiogr* 2008;**9**:415–437.

References

1. Tennant R, Wiggers CJ. The effects of coronary occlusion on myocardial contraction. *Am J Physiol* 1935;**112**:351–361
2. Theroux P, Franklin D, Ross J Jr, Lemper WS. Regional myocardial function during acute coronary artery occlusion and its modification by pharmacologic agents in the dog. *Circ Res* 1974;**34**:896–908.
3. Kerber RE, Abboud FM. Echocardiographic detection of regional myocardial infarction. An experimental study. *Circulation* 1973;**47**:997–1005.
4. Sugishita Y, Koseki S, Matsuda M, Tamura T, Yamaguchi I, Ito I. Dissociation between regional myocardial dysfunction and ECG changes during myocardial

- ischaemia induced by exercise in patients with angina pectoris. *Am Heart J* 1983; **106**:1–8.
5. Distante A, Rovai D, Picano E, Moscarelli E, Palombo C, Morales MA, Michelassi C, L'Abbate A. Transient changes in left ventricular mechanics during attacks of Prinzmetal's angina: an M-mode echocardiographic study. *Am Heart J* 1984; **107**:465–470.
 6. Picano E, Distante A, Masini M, Morales MA, Lattanzi F, L'Abbate A. Dipyridamole-echocardiography test in effort angina pectoris. *Am J Cardiol* 1985; **56**:452–456.
 7. Pierard LA, De Landsheere CM, Berthe C, Rigo P, Kulbertus HE. Identification of viable myocardium by echocardiography during dobutamine infusion in patients with myocardial infarction after thrombolytic therapy: comparison with positron emission tomography. *J Am Coll Cardiol* 1990; **15**:1021–1031.
 8. Wann LS, Faris JV, Childress RH, Dillon JC, Weyman AE, Feigenbaum H. Exercise cross-sectional echocardiography in ischaemic heart disease. *Circulation* 1979; **60**:1300–1308.
 9. Picano E, Mathias W Jr, Pingitore A, Bigi R, Previtoli M. Safety and tolerability of dobutamine-atropine stress echocardiography: a prospective, multicentre study. Echo Dobutamine International Cooperative Study Group. *Lancet* 1994; **344**:1190–1192.
 10. Picano E, Sicari R, Landi P, Cortigiani L, Bigi R, Coletta C, Galati A, Heyman J, Mattioli R, Previtoli M, Mathias W Jr, Dodi C, Minardi G, Lowenstein J, Seveso G, Pingitore A, Salustri A, Raciti M. Prognostic value of myocardial viability in medically treated patients with global left ventricular dysfunction early after an acute uncomplicated myocardial infarction: a dobutamine stress echocardiographic study. *Circulation* 1998; **98**:1078–1084.
 11. Council Directive 97/43/Euratom of 30 June 1997 on health protection of individuals against the dangers of ionising radiation in relation to medical exposure, and repealing Directive 84/466/Euratom. *Official Journal L* 180, 09/07/1997 P. 0022–0027.
 12. European Commission Referral Guidelines for imaging. *Rad Protect* 2001; **118**: 1–125. Available at: <http://europa.eu.int/comm/environment/radprot/118/rp-118-en.pdf> (accessed 28 July 2007).
 13. Picano E. Sustainability of medical imaging. *BMJ* 2004; **328**:578–580.
 14. Picano E, Pasanisi E, Brown J, Marwick TH. A gatekeeper for the gatekeeper; inappropriate referrals to stress echocardiography. *Am Heart J* 2007; **154**: 126–132.
 15. Amis ES Jr, Butler PF, Applegate KE, Birnbaum SB, Brateman LF, Hevezi JM, Mettler FA, Morin RL, Pentecost MJ, Smith GG, Strauss KJ, Zeman RK. American College of Radiology white paper on radiation dose in medicine. *J Am Coll Radiol* 2007; **4**:272–284.
 16. Gibbons RJ. Leading the elephant out of the corner: the future of health care: presidential address at the American Heart Association 2006 scientific sessions. *Circulation* 2007; **115**:2221–2230.
 17. Picano E. Informed consent in radiological and nuclear medicine examinations. How to escape from a communication inferno. 2004; **329**:578–580.
 18. Picano E. Stress echocardiography: a historical perspective. *Am J Med* 2003; **114**: 126–130.
 19. Picano E. *Stress Echocardiography*, 4th edn. Heidelberg: Springer Verlag; 2003.
 20. Picano E. Dipyridamole-echocardiography test: historical background and physiologic basis. *Eur Heart J* 1989; **10**:365–376.
 21. Ross J Jr. Mechanisms of regional ischaemia and antianginal drug action during exercise. *Prog Cardiovasc Dis* 1989; **31**:455–466.
 22. Gallagher KP, Matsuzaki M, Koziol JA, Kemper WS, Ross J Jr. Regional myocardial perfusion and wall thickening during ischaemia in conscious dogs. *Am J Physiol* 1984; **247**:H727–H738.
 23. Picano E, Lattanzi F, Masini M, Distante A, L'Abbate A. Usefulness of a high-dose dipyridamole-echocardiography test for diagnosis of syndrome X. *Am J Cardiol* 1987; **60**:508–512.
 24. Kaski JC, Rosano GM, Collins P, Nihoyannopoulos P, Maseri A, Poole-Wilson PA. Cardiac syndrome X: clinical characteristics and left ventricular function. Long-term follow-up study. *J Am Coll Cardiol* 1995; **25**: 807–814.
 25. Palinkas A, Toth E, Amyot R, Rigo F, Venneri L, Picano E. The value of ECG and echocardiography during stress testing for identifying systemic endothelial dysfunction and epicardial artery stenosis. *Eur Heart J* 2002; **23**:1587–1595.
 26. Camici PG, Gistri R, Lorenzoni R, Sorace O, Michelassi C, Bongiorno MG, Salvadori PA, L'Abbate A. Coronary reserve and exercise ECG in patients with chest pain and normal coronary angiograms. *Circulation* 1992; **86**:179–186.
 27. Nihoyannopoulos P, Kaski J-C, Crake T, Maseri A. Absence of myocardial dysfunction during stress in patients with syndrome X. *J Am Coll Cardiol* 1991; **18**: 1463–1470.
 28. Picano E, Palinkas A, Amyot R. Diagnosis of myocardial ischaemia in hypertensive patients. *J Hypertens* 2001; **19**:1177–1183.
 29. Picano E, Lattanzi F, Masini M, Distante A, L'Abbate A. High dose dipyridamole echocardiography test in effort angina pectoris. *J Am Coll Cardiol* 1986; **8**: 848–854.
 30. Berthe C, Pierard LA, Hiernaux M, Trotteur G, Lempereur P, Carlier J, Kulbertus HE. Predicting the extent and location of coronary artery disease in acute myocardial infarction by echocardiography during dobutamine infusion. *Am J Cardiol* 1986; **58**:1167–1172.
 31. Mazeika P, Nihoyannopoulos P, Joshi J, Oakley CM. Evaluation of dipyridamole-Doppler echocardiography for detection of myocardial ischaemia and coronary artery disease. *Am J Cardiol* 1991; **68**:478–484.
 32. Geleijnse ML, Fioretti PM, Roelandt JR. Methodology, feasibility, safety and diagnostic accuracy of dobutamine stress echocardiography. *J Am Coll Cardiol* 1997; **30**:595–606.
 33. Picano E. Stress echocardiography. From pathophysiologic toy to diagnostic tool. *Circulation* 1992; **85**:1604–1612.
 34. Pingitore A, Picano E, Colosso MQ, Reisenhofer B, Gigli G, Lucarini AR, Petix N, Previtoli M, Bigi R, Chiaranda G, Minardi G, de Alcantara M, Lowenstein J, Sclavo MG, Palmieri C, Galati A, Seveso G, Heyman J, Mathias W Jr, Casazza F, Sicari R, Raciti M, Landi P, Marzilli M. The atropine factor in pharmacologic stress echocardiography. Echo Persantine (EPIC) and Echo Dobutamine International Cooperative (EDIC) Study Groups. *J Am Coll Cardiol* 1996; **27**: 1164–1170.
 35. Picano E, Bedetti G, Varga A, Cseh E. The comparable diagnostic accuracies of dobutamine-stress and dipyridamole-stress echocardiographies: a meta-analysis. *Coron Artery Dis* 2000; **11**:151–159.
 36. Picano E, Molinaro S, Pasanisi E. The diagnostic accuracy of pharmacological stress echocardiography for the assessment of coronary artery disease: a meta-analysis. *Cardiovasc Ultrasound* 2008; **6**:30.
 37. Heijenbroek-Kal MH, Fleischmann KE, Hunink MG. Stress echocardiography, stress single-photon-emission computed tomography and electron beam computed tomography for the assessment of coronary artery disease: a meta-analysis of diagnostic performance. *Am Heart J* 2007; **154**:415–423.
 38. Senior R, Lahiri A. Enhanced detection of myocardial ischaemia by stress dobutamine echocardiography utilizing the 'biphasic' response of wall thickening during low and high dose dobutamine infusion. *J Am Coll Cardiol* 1995; **26**:26–32.
 39. Arnese M, Fioretti PM, Cornel JH, Postma-Tjoa J, Reijs AE, Roelandt JR. Akinesis becoming dyskinesis during high dose dobutamine stress echocardiography: a marker of myocardial ischaemia or a mechanical phenomenon? *Am J Cardiol* 1994; **73**:896–899.
 40. Deutsch HJ, Schenkel C, Klaer R, Curtius JM. Comparison of ergometer and dipyridamole echocardiography in patients with suspected coronary heart disease. *Z Kardiol* 1994; **83**:446–453.
 41. Marangelli V, Iliceto S, Piccinni G, De Martino G, Sorgente L, Rizzon P. Detection of coronary artery disease by digital stress echocardiography: comparison of exercise, transesophageal atrial pacing and dipyridamole echocardiography. *J Am Coll Cardiol* 1994; **24**:117–124.
 42. Beleslin BD, Ostojic M, Stepanovic J, Djordjevic-Dikic A, Stojkovic S, Nedeljkovic M, Stankovic G, Petrasinovic Z, Gojkovic L, Vasiljevic-Pokrajcic Z. Stress echocardiography in the detection of myocardial ischaemia. Head-to-head comparison of exercise, dobutamine, and dipyridamole tests. *Circulation* 1994; **90**: 1168–1176.
 43. Dagianti A, Penco M, Agati L, Sciomer S, Dagianti A, Rosanio S, Fedele F. Stress echocardiography: comparison of exercise, dipyridamole and dobutamine in detecting and predicting the extent of coronary artery disease. *J Am Coll Cardiol* 1995; **26**:18–25.
 44. Bjornstad K, Aakhus S, Hatle L. Comparison of digital dipyridamole stress echocardiography and upright bicycle stress echocardiography for identification of coronary artery stenosis. *Cardiology* 1995; **86**:514–520.
 45. Schroder K, Voller H, Dingerkus H, Munzberg H, Dissmann R, Linderer T, Schultheiss HP. Comparison of the diagnostic potential of four echocardiographic stress tests shortly after acute myocardial infarction: submaximal exercise, transesophageal atrial pacing, dipyridamole, and dobutamine-atropine. *Am J Cardiol* 1996; **77**:909–914.
 46. Loimaala A, Groundstroem K, Pasanen M, Oja P, Vuori I. Comparison of bicycle, heavy isometric, dipyridamole-atropine and dobutamine stress echocardiography for diagnosis of myocardial ischaemia. *Am J Cardiol* 1999; **84**:1396–1400.
 47. Armstrong WF, O'Donnell J, Ryan T, Feigenbaum H. Effect of prior myocardial infarction and extent and location of coronary artery disease on accuracy of exercise echocardiography. *J Am Coll Cardiol* 1987; **10**:531–538.
 48. Crouse LJ, Harbrecht JJ, Vacek JL, Rosamond TL, Kramer PH. Exercise echocardiography as a screening test for coronary artery disease and correlation with coronary angiography. *Am J Cardiol* 1991; **67**:1213–1218.
 49. Quinones MA, Verani MS, Haichin RM, Mahmarian JJ, Suarez J, Zoghbi WA. Exercise echocardiography versus thallium-201 single-photon emission computed

- tomography in evaluation of coronary artery disease: analysis of 292 patients. *Circulation* 1992;**85**:1026–1031.
50. Marwick TH, Nemec JJ, Pashkow FJ, Stewart WJ, Salcedo EE. Accuracy and limitations of exercise echocardiography in a routine clinical setting. *J Am Coll Cardiol* 1992;**19**:74–81.
 51. McNeill AJ, Fioretti PM, el-Said SM, Salustri A, Forster T, Roelandt JR. Enhanced sensitivity for detection of coronary artery disease by addition of atropine to dobutamine stress echocardiography. *Am J Cardiol* 1992;**70**:41–46.
 52. Salustri A, Fioretti PM, McNeill AJ, Pozzoli MM, Roelandt JR. Pharmacological stress echocardiography in the diagnosis of coronary artery disease and myocardial ischaemia: a comparison between dobutamine and dipyridamole. *Eur Heart J* 1992;**13**:1356–1362.
 53. Mazeika PK, Nadazdin A, Oakley CM. Dobutamine stress echocardiography for detection and assessment of coronary artery disease. *J Am Coll Cardiol* 1992;**19**:1203–1211.
 54. Segar DS, Brown SE, Sawada SG, Ryan T, Feigenbaum H. Dobutamine stress echocardiography: correlation with coronary lesion severity as determined by quantitative angiography. *J Am Coll Cardiol* 1992;**19**:1197–1202.
 55. Marcovitz P, Armstrong WF. Accuracy of dobutamine stress echocardiography in detecting coronary artery disease. *Am J Cardiol* 1992;**69**:1269–1272.
 56. San Roman JA, Vilacosta I, Castillo JA, Rollan MJ, Peral V, Sanchez-Harguindey L, Fernandez-Aviles F. Dipyridamole and dobutamine-atropine stress echocardiography in the diagnosis of coronary artery disease. Comparison with exercise stress test, analysis of agreement, and impact of antianginal treatment. *Chest* 1996;**110**:1248–1254.
 57. Nedeljkovic I, Ostojic M, Beleslin B, Djordjevic-Dikic A, Stepanovic J, Nedeljkovic M, Stojkovic S, Stankovic G, Saponjski J, Petrasinovic Z, Giga V, Mitrovic P. Comparison of exercise, dobutamine-atropine and dipyridamole-atropine stress echocardiography in detecting coronary artery disease. *Cardiovasc Ultrasound* 2006;**4**:22.
 58. Dal Porto R, Faletta F, Picano E, Pirelli S, Moreo A, Varga A. Safety, feasibility, and diagnostic accuracy of accelerated high-dose dipyridamole stress echocardiography. *Am J Cardiol* 2001;**87**:520–524.
 59. Sawada SG, Ryan T, Conley M, Corya BC, Feigenbaum H, Armstrong W. Prognostic value of a normal exercise echocardiogram. *Am Heart J* 1990;**120**:49–55.
 60. Elhendy A, Shub C, McCully RB, Mahoney DW, Burger KN, Pellikka PA. Exercise echocardiography for the prognostic stratification of patients with low pretest probability of coronary artery disease. *Am J Med* 2001;**111**:18–23.
 61. Marwick TH, Case C, Vasey C, Allen S, Short L, Thomas JD. Prediction of mortality by exercise echocardiography: a strategy for combination with the Duke treadmill score. *Circulation* 2001;**103**:2566–2571.
 62. Arruda-Olson AM, Juracan EM, Mahoney DW, McCully RB, Roger VL, Pellikka PA. Prognostic value of exercise echocardiography in 5,798 patients: is there a gender difference? *J Am Coll Cardiol* 2002;**39**:625–631.
 63. McCully RB, Roger VL, Mahoney DW, Burger KN, Click RL, Seward JB, Pellikka PA. Outcome after abnormal exercise echocardiography for patients with good exercise capacity: prognostic importance of the extent and severity of exercise-related left ventricular dysfunction. *J Am Coll Cardiol* 2002;**39**:1345–1352.
 64. Jaarsma W, Visser C, Funke Kupper A. Usefulness of two-dimensional exercise echocardiography shortly after myocardial infarction. *Am J Cardiol* 1986;**57**:86–90.
 65. Applegate RJ, Dell'Italia LJ, Crawford MH. Usefulness of two dimensional echocardiography during low-level exercise testing early after uncomplicated myocardial infarction. *Am J Cardiol* 1987;**60**:10–14.
 66. Ryan T, Armstrong WF, O'Donnell JA, Feigenbaum H. Risk stratification following acute myocardial infarction during exercise two-dimensional echocardiography. *Am Heart J* 1987;**114**:1305–1316.
 67. Quintana M, Lindvall K, Ryden L, Brolund F. Prognostic value of predischARGE exercise stress echocardiography after acute myocardial infarction. *Am J Cardiol* 1995;**76**:1115–1121.
 68. Hoque A, Maaieh M, Longaker RA, Stoddard MF. Exercise echocardiography and thallium-201 single-photon emission computed tomography stress test for 5- and 10-year prognosis of mortality and specific cardiac events. *J Am Soc Echocardiogr* 2002;**15**:1326–1334.
 69. Elhendy A, Mahoney DW, Khandheria BK, Paterick TE, Burger KN, Pellikka PA. Prognostic significance of the location of wall motion abnormalities during exercise echocardiography. *J Am Coll Cardiol* 2002;**40**:1623–1629.
 70. Mazur W, Rivera JM, Khoury AF, Basu AG, Perez-Verdia A, Marks GF, Chang SM, Olmos L, Quiñones MA, Zoghbi WA. Prognostic value of exercise echocardiography: validation of a new risk index combining echocardiographic, treadmill, and exercise electrocardiographic parameters. *J Am Soc Echocardiogr* 2003;**16**:318–325.
 71. Marwick TH, Case C, Short L, Thomas JD. Prediction of mortality in patients without angina: use of an exercise score and exercise echocardiography. *Eur Heart J* 2003;**24**:1223–1230.
 72. Peteiro J, Monserrat L, Vazquez E, Perez R, Garrido I, Vazquez N, Castro-Beiras A. Comparison of exercise echocardiography to exercise electrocardiographic testing added to echocardiography at rest for risk stratification after uncomplicated acute myocardial infarction. *Am J Cardiol* 2003;**92**:373–376.
 73. Elhendy A, Mahoney DW, Burger KN, McCully RB, Pellikka PA. Prognostic value of exercise echocardiography in patients with classic angina pectoris. *Am J Cardiol* 2004;**94**:559–563.
 74. Garrido IP, Peteiro J, García-Lara J, Montserrat L, Aldama G, Vázquez-Rodríguez JM, Alvarez N, Castro-Beiras A. Prognostic value of exercise echocardiography in patients with diabetes mellitus and known or suspected coronary artery disease. *Am J Cardiol* 2005;**96**:9–12.
 75. Metz LD, Beattie M, Hom R, Redberg RF, Grady D, Fleischmann KE. The prognostic value of normal exercise myocardial perfusion imaging and exercise echocardiography: a meta-analysis. *J Am Coll Cardiol* 2007;**49**:227–237.
 76. Mazeika PK, Nadazdin A, Oakley CM. Prognostic value of dobutamine echocardiography in patients with high pretest likelihood of coronary artery disease. *Am J Cardiol* 1993;**71**:33–39.
 77. Poldermans D, Fioretti PM, Boersma E, Cornel JH, Borst F, Vermeulen EG, Arnese M, el-Hendy A, Roelandt JR. Dobutamine-atropine stress echocardiography and clinical data for predicting late cardiac events in patients with suspected coronary artery disease. *Am J Med* 1994;**97**:119–125.
 78. Marwick TH, Case C, Sawada S, Rimmerman C, Brennenman P, Kovacs R, Short L, Lauer M. Prediction of mortality using dobutamine echocardiography. *J Am Coll Cardiol* 2001;**37**:754–760.
 79. Sicari R, Pasanisi E, Venneri L, Landi P, Cortigiani L, Picano E. Echo Persantine International Cooperative (EPIC) Study Group; Echo Dobutamine International Cooperative (EDIC) Study Group. Stress echo results predict mortality: a large scale multicenter prospective international study. *J Am Coll Cardiol* 2003;**41**:589–595.
 80. Carlos ME, Smart SC, Wynsen JC, Sagar KB. Dobutamine stress echocardiography for risk stratification after myocardial infarction. *Circulation* 1997;**18**:1402–1410.
 81. Picano E, Severi S, Michelassi C, Lattanzi F, Masini M, Orsini E, Distante A, L'Abbate A. Prognostic importance of dipyridamole-echocardiography test in coronary artery disease. *Circulation* 1989;**80**:450–457.
 82. Severi S, Picano E, Michelassi C, Lattanzi F, Landi P, Distante A, L'Abbate A. Diagnostic and prognostic value of dipyridamole echocardiography in patients with suspected coronary artery disease. Comparison with exercise electrocardiography. *Circulation* 1994;**89**:1160–1173.
 83. Picano E, Landi P, Bolognese L, Chiarelli G, Chiarella F, Seveso G, Scavo MG, Gandolfo N, Previtali M, Orlandini A. Prognostic value of dipyridamole echocardiography early after uncomplicated myocardial infarction: a large-scale, multicenter trial. The EPIC Study Group. *Am J Med* 1993;**95**:608–618.
 84. van Daele ME, McNeill AJ, Fioretti PM, Salustri A, Pozzoli MM, el-Said ES, Reijs AE, McFalls EO, Slagboom T, Roelandt JR. Prognostic value of dipyridamole sestamibi single-photon emission computed tomography and dipyridamole stress echocardiography for new cardiac events after an uncomplicated myocardial infarction. *J Am Soc Echocardiogr* 1994;**7**:370–380.
 85. Neskovic AN, Popovic AD, Babic R, Marinkovic J, Obradovic V. Positive high-dose dipyridamole echocardiography test after acute myocardial infarction is an excellent predictor of cardiac events. *Am Heart J* 1995;**129**:31–39.
 86. Smart SC, Sawada S, Ryan T, Segar D, Atherton L, Berkovitz K, Bourdillon PD, Feigenbaum H. Low-dose dobutamine echocardiography detects reversible dysfunction after thrombolytic therapy of acute myocardial infarction. *Circulation* 1993;**88**:405–415.
 87. Bax JJ, Cornel JH, Visser FC, Fioretti PM, van Lingen A, Reijs AE, Boersma E, Teule GJ, Visser CA. Prediction of recovery of myocardial dysfunction after revascularization. Comparison of fluorine-18 fluorodeoxyglucose/thallium-201 SPECT, thallium-201 stress-reinjection SPECT and dobutamine echocardiography. *J Am Coll Cardiol* 1996;**28**:558–564.
 88. Bax JJ, Poldermans D, Elhendy A, Boersma E, Rahimtoola SH. Sensitivity, specificity, and predictive accuracies of various noninvasive techniques for detecting hibernating myocardium. *Curr Probl Cardiol* 2001;**26**:147–186.
 89. Picano E, Marzullo P, Gigli G, Reisenhofer B, Parodi O, Distante A, L'Abbate A. Identification of viable myocardium by dipyridamole-induced improvement in regional left ventricular function assessed by echocardiography in myocardial infarction and comparison with thallium scintigraphy at rest. *Am J Cardiol* 1992;**70**:703–710.
 90. Varga A, Ostojic M, Djordjevic-Dikic A, Sicari R, Pingitore A, Nedeljkovic I, Picano E. Infra-low dose dipyridamole test. A novel dose regimen for selective assessment of myocardial viability by vasodilator stress echocardiography. *Eur Heart J* 1996;**17**:629–634.

91. Varga A, Picano E, Cortigiani L, Petix N, Margaria F, Magaia O, Heyman J, Bigi R, Mathias W Jr, Gigli G, Landi P, Raciti M, Pingitore A, Sicari R. Combined low dose dipyridamole–dobutamine stress echocardiography to identify myocardial viability. *J Am Coll Cardiol* 1996;**27**:1422–1428.
92. Hoffer EP, Dewe W, Celentano C, Pierard LA. Low-level exercise echocardiography detects contractile reserve and predicts reversible dysfunction after acute myocardial infarction: comparison with low-dose dobutamine echocardiography. *J Am Coll Cardiol* 1999;**34**:989–997.
93. Lu C, Carlino M, Fragasso G, Maisano F, Margonato A, Cappelletti A, Chierchia SL. Enoximone echocardiography for predicting recovery of left ventricular dysfunction after revascularization: a novel test for detecting myocardial viability. *Circulation* 2000;**101**:1255–1260.
94. Ghio S, Constantin C, Raineri C, Fontana A, Klersy C, Campana C, Tavazzi L. Enoximone echocardiography: a novel test to evaluate left ventricular contractile reserve in patients with heart failure on chronic betablocker therapy. *Cardiovasc Ultrasound* 2003;**1**:13.
95. Williams MJ, Odbashian J, Lauer MS, Thomas JD, Marwick TH. Prognostic value of dobutamine echocardiography in patients with left ventricular dysfunction. *J Am Coll Cardiol* 1996;**27**:132–139.
96. Bax JJ, Poldermans D, Elhendy A, Cornel JH, Boersma E, Rambaldi R, Roelandt JR, Fioretti PM. Improvement of left ventricular ejection fraction, heart failure symptoms and prognosis after revascularization in patients with chronic coronary artery disease and viable myocardium detected by dobutamine stress echocardiography. *J Am Coll Cardiol* 1999;**34**:163–169.
97. Meluzin J, Cerný J, Frélich M, Stetka F, Spinarová L, Popelová J, Stipal R. Prognostic value of the amount of dysfunctional but viable myocardium in revascularized patients with coronary artery disease and left ventricular dysfunction. *J Am Coll Cardiol* 1998;**32**:912–920.
98. Marwick TH, Zuchowski C, Lauer MS, Secknus MA, Williams J, Lytle BW. Functional status and quality of life in patients with heart failure undergoing coronary bypass surgery after assessment of myocardial viability. *J Am Coll Cardiol* 1999;**33**:750–758.
99. Chaudry FA, Tauke JT, Alessandrini RS, Vardi G, Parker MA, Bonow RO. Prognostic implications of myocardial contractile reserve in patients with coronary artery disease and left ventricular dysfunction. *J Am Coll Cardiol* 1999;**34**:730–738.
100. Sicari R, Ripoli A, Picano E, Borges AC, Varga A, Mathias W, Cortigiani L, Bigi R, Heyman J, Polimeno S, Silvestri O, Gimenez V, Caso P, Severino S, Djordjevic-Dikic A, Ostojic M, Baldi C, Seveso G, Petix N; VIDA (Viability Identification with Dipyridamole Administration) Study Group. The prognostic value of myocardial viability recognized by low dose dipyridamole echocardiography in patients with chronic ischaemic left ventricular dysfunction. *Eur Heart J* 2001;**22**:837–844.
101. Sicari R, Picano E, Cortigiani L, Borges AC, Varga A, Palagi C, Bigi R, Rossini R, Pasanisi E; VIDA (Viability Identification with Dobutamine Administration) Study Group. Prognostic value of myocardial viability recognized by low-dose dobutamine echocardiography in chronic ischaemic left ventricular dysfunction. *Am J Cardiol* 2003;**92**:1263–1266.
102. Senior R, Kaul S, Lahiri A. Myocardial viability on echocardiography predicts long-term survival after revascularization in patients with ischaemic congestive heart failure. *J Am Coll Cardiol* 1999;**33**:1848–1854.
103. Allman KC, Shaw LJ, Hachamovitch R, Udelson JE. Myocardial viability testing and impact of revascularization on prognosis inpatients with coronary artery disease and left ventricular dysfunction: a meta-analysis. *J Am Coll Cardiol* 2002;**39**:1151–1158.
104. Rizzello V, Poldermans D, Schinkel AF, Biagini E, Boersma E, Elhendy A, Sozzi FB, Maat A, Crea F, Roelandt JR, Bax JJ. Long term prognostic value of myocardial viability and ischaemia during dobutamine stress echocardiography in patients with ischaemic cardiomyopathy undergoing coronary revascularisation. *Heart* 2006;**92**:239–244.
105. Picano E, Marini C, Pirelli S, Maffei S, Bolognese L, Chiriatti G, Chiarella F, Orlandini A, Seveso G, Colosso MQ. Safety of intravenous high-dose dipyridamole echocardiography. The Echo-Persantine International Cooperative Study Group. *Am J Cardiol* 1992;**70**:252–258.
106. Lette J, Tatum JL, Fraser S, Miller DD, Waters DD, Heller G, Stanton EB, Bom HS, Leppo J, Nattel S. Safety of dipyridamole testing in 73,806 patients: the Multicenter Dipyridamole Safety Study. *J Nucl Cardiol* 1995;**2**:3–17.
107. Mertes H, Sawada SG, Ryan T, Segar DS, Kovacs R, Foltz J, Feigenbaum H. Symptoms, adverse effects, and complications associated with dobutamine stress echocardiography. Experience in 1118 patients. *Circulation* 1993;**88**:15–19.
108. Pellikka PA, Roger VL, Oh JK, Miller FA, Seward JB, Tajik AJ. Stress echocardiography. Part II. Dobutamine stress echocardiography: techniques, implementation, clinical applications, and correlations. *Mayo Clin Proc* 1995;**70**:16–27.
109. Zahn R, Lotter R, Nohl H, Schiele R, Bergmeier C, Zander M, Seidl K, Senges J. [Feasibility and safety of dobutamine stress echocardiography: experiences with 1,000 studies]. *Z Kardiol* 1996;**85**:28–34.
110. Secknus MA, Marwick TH. Evolution of dobutamine echocardiography protocols and indications: safety and side effects in 3,011 studies over 5 years. *J Am Coll Cardiol* 1997;**29**:1234–1240.
111. Elhendy A, van Domburg RT, Poldermans D, Bax JJ, Nierop PR, Geleijnse ML, Roelandt JR. Safety and feasibility of dobutamine–atropine stress echocardiography for the diagnosis of coronary artery disease in diabetic patients unable to perform an exercise stress test. *Diabetes Care* 1998;**21**:1797–1802.
112. Bremer ML, Monahan KH, Stussy VL, Miller FA Jr, Seward JB, Pellikka PA. Safety of dobutamine stress echocardiography supervised by registered nurse sonographers. *J Am Soc Echocardiogr* 1998;**11**:601–605.
113. Poldermans D, Fioretti PM, Boersma E, Forster T, van Urk H, Cornel JH, Arnese M, Roelandt RT. Safety of dobutamine–atropine stress echocardiography in patients with suspected or proven coronary artery disease. *Am J Cardiol* 1994;**73**:456–459.
114. Mathias W Jr, Arruda A, Santos FC, Arruda AL, Mattos E, Osório A, Campos O, Gil M, Andrade JL, Carvalho AC. Safety of dobutamine–atropine stress echocardiography: a prospective experience of 4,033 consecutive studies. *J Am Soc Echocardiogr* 1999;**12**:785–791.
115. Pezzano A, Gentile F, Mantero A, Morabito A, Ravizza P. RITED (Registro Italiano Test Eco-Dobutamina): side effects and complications of echodobutamine stress test in 3041 examinations. *G Ital Cardiol* 1998;**28**:102–111.
116. Beckmann SH, Haug G. National Registry 1995–1998 on 150,000 stress echo examinations: side effects and complications in 60,448 examinations of the registry 1997–1998. *Circulation* 1999;**100**:3401.
117. Rodríguez García MA, Iglesias-Garriz I, Corral Fernández F, Garrote Coloma C, Alonso-Orcajo N. [Evaluation of the safety of stress echocardiography in Spain and Portugal]. *Rev Esp Cardiol* 2001;**54**:941–948.
118. Lattanzi F, Picano E, Adamo E, Varga A. Dobutamine stress echocardiography: safety in diagnosing coronary artery disease. *Drug Saf* 2000;**22**:251–262.
119. Varga A, Garcia MA, Picano E. International Stress Echo Complication Registry. Safety of stress echocardiography (from the International Stress Echo Complication Registry). *Am J Cardiol* 2006;**98**:541–543.
120. Fox K, Garcia MA, Ardissino D, Buszman P, Camici PG, Crea F, Daly C, De Backer G, Hjelm Dahl P, Lopez-Sendon J, Marco J, Morais J, Pepper J, Sechtem U, Simoons M, Thygesen K, Priori SG, Blanc JJ, Budaj A, Camm J, Dean V, Deckers J, Dickstein K, Lekakis J, McGrover K, Metra M, Morais J, Osterspery A, Tamargo J, Zamorano JL; Task Force on the Management of Stable Angina Pectoris of the European Society of Cardiology; ESC Committee for Practice Guidelines (CPG). Guidelines on the management of stable angina pectoris: executive summary. The Task Force on the Management of Stable Angina Pectoris of the European Society of Cardiology. *Eur Heart J* 2006;**27**:1341–1381.
121. Bjork Ingul C, Stoylen A, Stordahl SA, Wiseth R, Burgess M, Marwick TH. Automated analysis of myocardial deformation at dobutamine stress echocardiography. An angiographic validation. *J Am Coll Cardiol* 2007;**49**:1651–1659.
122. Reant P, Labrousse L, Lafitte S, Bordachar P, Pillois X, Tariosse L, Bonoron-Adele S, Padois P, Deville C, Roudaut R, Dos Santos P. Experimental validation of circumferential, longitudinal, and radial 2-dimensional strain during dobutamine stress echocardiography in ischemic conditions. *J Am Coll Cardiol* 2008;**51**:149–157.
123. Gibbons RJ, Abrams J, Chatterjee K, Daley J, Deedwania PC, Douglas JS, Ferguson TB Jr, Fihn SD, Fraker TD Jr, Gardin JM, O'Rourke RA, Pasternak RC, Williams SV, Gibbons RJ, Alpert JS, Antman EM, Hiratzka LF, Fuster V, Faxon DP, Gregoratos G, Jacobs AK, Smith SC Jr; American College of Cardiology; American Heart Association Task Force on Practice Guidelines. Committee on the Management of Patients With Chronic Stable Angina. ACC/AHA 2002 guideline update for the management of patients with chronic stable angina: a report of the American College of Cardiology/American Heart Association Task Force on Practice Guidelines (Committee to Update the 1999 Guidelines for the management of Patients with Chronic Stable Angina. *Circulation* 2003;**107**:149–158.
124. Geleijnse ML, Elhendy A. Can stress echocardiography compete with perfusion scintigraphy in the detection of coronary artery disease and cardiac risk assessment? *Eur J Echocardiogr* 2000;**1**:12–21.
125. Kim WY, Dianas PG, Stuber M, Flamm SD, Plein S, Nagel E, Langerak SE, Weber OM, Pedersen EM, Schmidt M, Botnar RM, Manning WJ. Coronary magnetic resonance angiography for the detection of coronary stenoses. *N Engl J Med* 2001;**345**:1863–1869.
126. Kim RJ, Wu E, Rafael A, Chen EL, Parker MA, Simonetti O, Klocke FJ, Bonow RO, Judd RM. The use of contrast-enhanced magnetic resonance imaging to identify reversible myocardial dysfunction. *N Engl J Med* 2000;**343**:1445–1453.

127. Nagel E, Lehmkuhl HB, Bocksch W, Klein C, Vogel U, Frantz E, Ellmer A, Dreyse S, Fleck E. Noninvasive diagnosis of ischaemia-induced wall motion abnormalities with the use of high-dose dobutamine stress MRI: comparison with dobutamine stress echocardiography. *Circulation* 1999;**99**:763–770.
128. Pingitore A, Lombardi M, Scattini B, De Marchi D, Aquaro GD, Positano V, Picano E. Head to head comparison between perfusion and function during accelerated high-dose dipyridamole magnetic resonance stress for the detection of coronary artery disease. *Am J Cardiol* 2008;**101**:8–14.
129. Paetsch I, Jahnke C, Fleck E, Nagel E. Current clinical applications of stress wall motion analysis with cardiac magnetic resonance imaging. *Eur J Echocardiogr* 2005;**6**:317–326.
130. Sicari R, Pingitore A, Aquaro G, Pasanisi E, Lombardi M, Picano E. Cardiac functional stress imaging: a sequential approach with stress echo and cardiovascular magnetic resonance. *Cardiovascular Ultrasound* 2007;**5**:47.
131. Picano E, Vano E, Semelka R, Regulla D. The American College of Radiology white paper on radiation dose in medicine: deep impact on the practice of cardiovascular imaging. *Cardiovasc Ultrasound* 2007;**5**:37.