

Studies on the Pathophysiology of Diabetic Retinopathy

The Blood-Retinal Barrier in Diabetes

JOSÉ G. CUNHA-VAZ

SUMMARY

A review of the pathologic picture of diabetic retinopathy shows that available clinical methods of examination demonstrate the alteration of the blood-retinal barrier (leakage), microaneurysms, capillary closure, preferential channels, preretinal neovascularization and gross extravascular lesions. All of these changes may be shown by fluorescein angiography. The value of this method, however, is fundamentally related to the morphologic demonstration of these lesions and not their quantification. Quantitative evaluation of retinal involvement in diabetes is needed in order to delineate more clearly its natural history, criteria for prognosis, and effect of treatment.

Vitreous fluorophotometry, a quantitative and sensitive method of evaluating the permeability of the blood-retinal barrier, has opened new perspectives for the evaluation of retinal involvement in diabetes. Vitreous fluorophotometry has shown that a disturbance of the blood-retinal barrier, possibly functional, appears in diabetic eyes before any lesion is clinically visible in the fundus, and that there is a close correlation between the severity of the vascular lesions and higher vitreous fluorophotometry readings. Recent studies also indicate an interesting correlation with metabolic control, particularly, glycosylated hemoglobin levels and insulin treatment.

Finally, on the basis of these findings a working hypothesis for the pathogenesis of diabetic retinopathy is presented. *DIABETES* 32 (Suppl. 2):20-27, 1983.

Blindness from diabetic retinopathy is responsible for 12% of new blindness at all ages and for 20% of new blindness between the ages of 45 and 74.¹ It remains one of the most challenging problems facing ophthalmologic research. My involvement in diabetic retinopathy research started when working in London with Norman Ashton in 1963. Since then, and following our initial studies on the pathology of diabetic retinopathy and blood-retinal barrier, the same line of research was maintained for

20 yr. This study is a general review of this research. By reviewing the major steps and examining the research as a whole a better insight into our present understanding of diabetic retinopathy can be gained.

PATHOLOGY

Diabetic retinopathy is basically a microangiopathy, usually detected by the appearance of retinal microaneurysms at the posterior pole. In London I had the opportunity of carefully reviewing a large number of diabetic retinas that had been prepared by injection methods and retinal digestion.

In the early stages of retinopathy, when lesions are minimal and limited to the small vessels, the characteristic pathologic findings^{2,3} included endothelial proliferation of the capillaries associated with the venous side of the circulation (Figure 1), apparent endothelial swelling in the capillaries of the arterial side, and signs of irregularly distributed pericyte damage. Microaneurysms were present. Capillary closure, in the arterial side, was found only when there were already a number of microaneurysms, suggesting its later development in the disease process. Earlier changes were observed in the cell populations of the retinal capillaries and veins. The topography of the endothelial cell lesions was characteristic: endothelial proliferation on the venous side versus endothelial cell swelling and degeneration on the arterial side.

I believe that the damage in the pericytes is secondary and associated with endothelial changes. The apparent preferential involvement of pericytes in diabetes is most likely due to their special location in the vessel wall. This has been borne out by experimental studies and observations under the electron microscope (Figure 2). We concluded that the damaged endothelial cells can be easily replaced by sliding of the neighboring endothelial cells. This must occur rapidly for the circulation to remain active, whereas damaged retinal

From the Departments of Ophthalmology, University of Coimbra, Portugal, and the University of Illinois Eye and Ear Infirmary, Chicago, Illinois. Address reprint requests to Dr. José G. Cunha-Vaz, Clinica Oftalmologica, Hospitais da Universidade, 3000 Coimbra, Portugal.




FIGURE 1. Diabetic retina showing endothelial proliferation and microaneurysms on the venous side of the circulation. Digest preparation (PAS + H, magnification $\times 85$).

pericytes cannot be replaced and remain trapped inside the basement membrane.⁴

Thickening of the basement membrane, accepted for a long time as a dominant feature of the microangiopathy of diabetes mellitus, also appeared to be a relatively late development in the diabetic retina, probably associated with the plasma leakage and endothelial cell damage.⁵

In summary, in diabetic retinopathy the changes appear initially to be confined to the small vessels in the form of endothelial cell proliferation and rare microaneurysms on the venous side, with signs of impending cellular degeneration in a few vascular branches on the arterial side. These initial lesions are focal and located preferentially at the posterior pole.

As the disease progresses, the capillaries on the arterial side of the retinal circulation show increased cell loss and closure, while on the venous side there is a simultaneous increase in the number of microaneurysms. As the areas of capillary closure enlarge, they are traversed by a few dilated capillaries that appear to act as arteriovenous shunts, receiving the blood diverted from the surrounding closed capillary net.

The next question was, are these lesions specific for diabetes? Examination of other vascular retinopathies showed that all the lesions observed in the diabetic retinas were shared by a wide variety of apparently unrelated diseases, emphasizing the importance of local factors. Our observations showed that the characteristic features of diabetic retinopathy were present in other vascular retinopathies and differed only in frequency and distribution.

These observations pointed to the likelihood of the existence of "special circumstances" in the retinas, be they structural or functional, which limit the scope of their response to

disease and explain why a great variety of pathologic stimuli causes the development of the same lesions.⁶

At this time we looked for reasons to explain the preferential involvement of the venous side of the circulation in the initial stages of the retinal changes in diabetes, and performed our first studies with histamine. Histamine had been shown to increase vascular permeability on the venous side.⁷ To our surprise no increase in permeability of the retinal vessels was observed and our attention was called to the possibility of the existence in the retina of a blood-retinal barrier similar to the well-known blood-brain barrier. It was possible that the blood-retinal barrier could be one of the "special circumstances."

In our initial studies, the blood-retinal barrier was found in the endothelial membrane of the retinal vessels,⁸ and we demonstrated the presence of extensive tight junctions that completely sealed the interendothelial spaces,⁹ further emphasizing the primary role of the endothelial cell in the makeup of this barrier.

The retinal endothelial cells also differed functionally from endothelial cells of most vessels of the body, a contrast further emphasized by the demonstration in the retinal vessels of active transport activity.¹⁰ This discovery had particular significance. For the first time endothelial cells were shown to possess active transport mechanisms and to regulate actively the exchange of substances across the vessels' walls. The endothelial cells of the retinal vessels appeared to deserve special attention.

The pathologic picture of diabetic retinopathy and other vascular retinopathies revealed the important role of the endothelial cell while at the same time, we discovered that the endothelial cell of the retinal vessels was specially differentiated with highly developed functional activity.

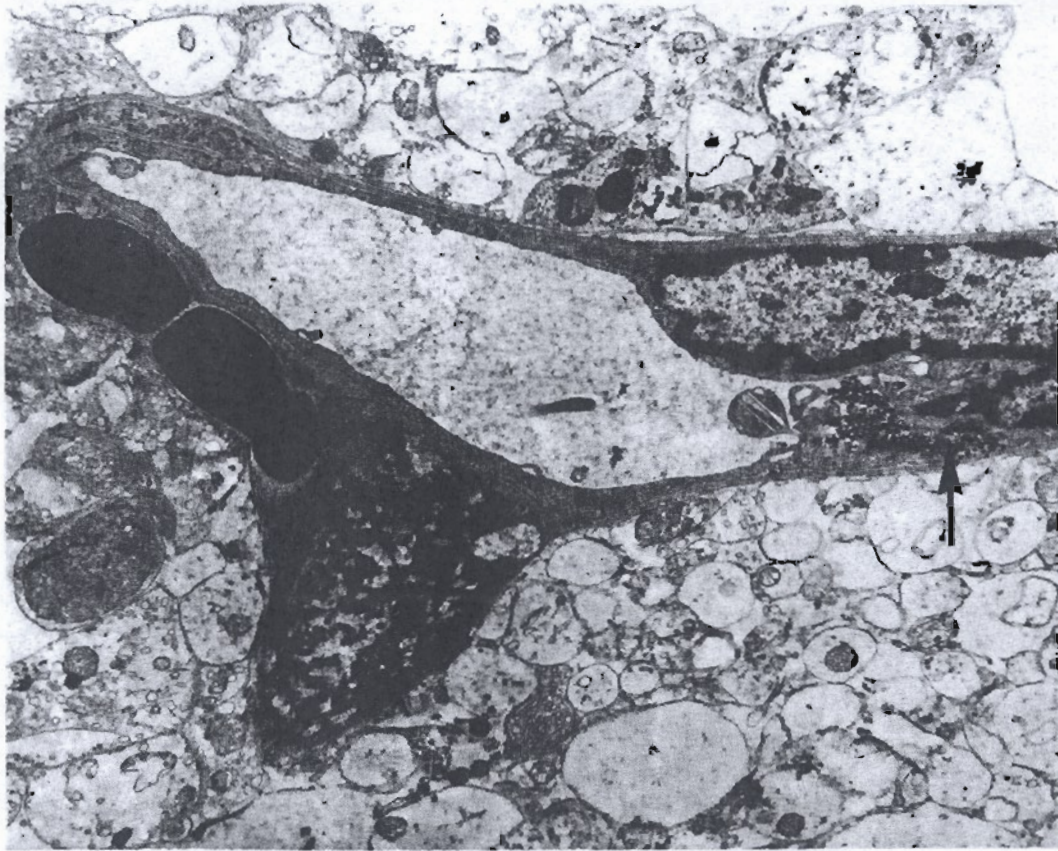


FIGURE 2. Small vessel from the ischemic retina of a rat, 1 h after an intravenous injection of colloidal carbon. There is a gap in the endothelial cytoplasm through which carbon particles reach the basement membrane (arrow). The pericyte is damaged, and red cells, fibrin, and carbon particles are seen in one pericyte lodge. Stained with uranyl acetate followed by lead citrate. EM $\times 7400$.

A study of the experimental pathology resulting from endothelial cell damage and alteration of the blood-retinal barrier appeared to be the next logical step. An attempt was made to examine the consequences to the retina of an experimental breakdown of the blood-retinal barrier. We investigated various methods and chose to elevate the intraocular pressure to different appropriate levels in order to obtain either a situation of total ischemia of the retina or a condition of venous stasis with marked slowing of the blood circulation.¹¹ Carbon and trypan blue, relatively large molecules, were used as indicators of the blood-retinal barrier breakdown. The changes were examined under the electron microscope using carbon and thorium dioxide particles. The study clearly showed that the breakdown of the blood-retinal barrier was caused by endothelial damage (Figure 2). The animals were submitted to single episodes of retinal ischemia or venous stasis and left to survive for different periods of time. The retinas were examined by injection methods, trypsin digestion, and a variety of histologic techniques.²

The resulting vascular lesions appeared to be markedly similar independent of the circulatory disturbance involved, ischemia or venous stasis, and to consist of a series of lesions with a particular distribution: endothelial proliferation and aneurysmal dilations in the venous side of the circulation, capillary closure in the arterial side, and preferential channels appearing as a late development.¹¹

In conclusion, the vascular changes that resulted from an experimental breakdown of the blood-retinal barrier followed a general pattern that had much in common with the vascular lesions found in human diabetic retinas. The fact that the experimental lesions appeared as a direct result of endothelial damage and were independent of the type of circulatory disturbance reinforced the idea that the pathologic changes of diabetic retinopathy and other vascular retinopathies may result from an insult to the retinal endothelial cell or blood-retinal barrier.

Meanwhile, the importance of an alteration of the blood-retinal barrier in the development of diabetic retinopathy received emphasis with the advent of fluorescein angiography. In 1967 Norton and Gutman,¹² studying diabetic patients with fluorescein angiography, called attention to the frequent finding of abnormal fluorescein leakage as one of the earliest retinal alterations. Subsequent studies have confirmed their report.

Up to this point our studies had suggested an important role of an alteration of the blood-retinal barrier in the development of the retinopathy of diabetes; however, a number of major questions, including the following, remained unanswered.

1. What causes the retinopathy? Does the initial and basic lesion reside in the cells of the small vessel walls or are the vascular alterations secondary to changes in the neural tissue of the retina?




FIGURE 3. Prototype of the new vitreous fluorophotometer (Fluorotron Master, Coherent Radiation, Coherent Medical Division, Palo Alto, California).

2. What is the role played by the diabetic metabolic deviation in the development of the retinopathy?

3. What functional alterations precede the pathologic changes?

4. Does control of the diabetic state really modify the course of retinopathy?

We determined it necessary at this point to go one step beyond the morphologic findings previously described and probe the earlier stages of the disease, when changes may still be reversible and functional in character.

DEVELOPMENT OF VITREOUS FLUOROPHOTOMETRY

Demonstration of breakdown of blood-retinal barrier in the diabetic retina in the preretinopathy stage. Experimental studies published in 1967 using fluorophotometry¹⁰ allowed us to determine the distribution of fluorescein within

axial regions of the vitreous body of the living animal. Measurements of the vitreous gradient immediately in front of the retina give a value for the flux of the dye across its surface and allow a quantitative evaluation of the permeability of the blood-retinal barrier. These studies contributed significantly to our understanding of intraocular fluid dynamics and fluorescein angiography. Fluorophotometric examination of the blood-retinal barrier appeared to be a promising field for clinical and experimental research.

The first report on vitreous fluorophotometry,¹³ which appeared in 1975, opened a new area of research by demonstrating early breakdown of the blood-retinal barrier in diabetes mellitus. Vitreous fluorophotometry has since proven to be a sensitive technique for measuring the permeability of the blood-retinal barrier. With it, alteration of the blood-retinal barrier can be identified and accurately quantified.

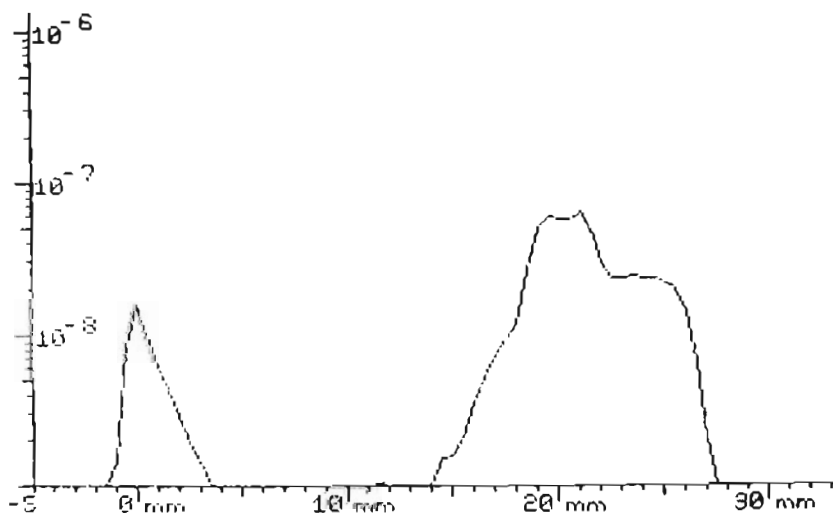


FIGURE 4. Vitreous fluorophotometry scan performed in a normal volunteer 1 h after the intravenous injection of fluorescein.

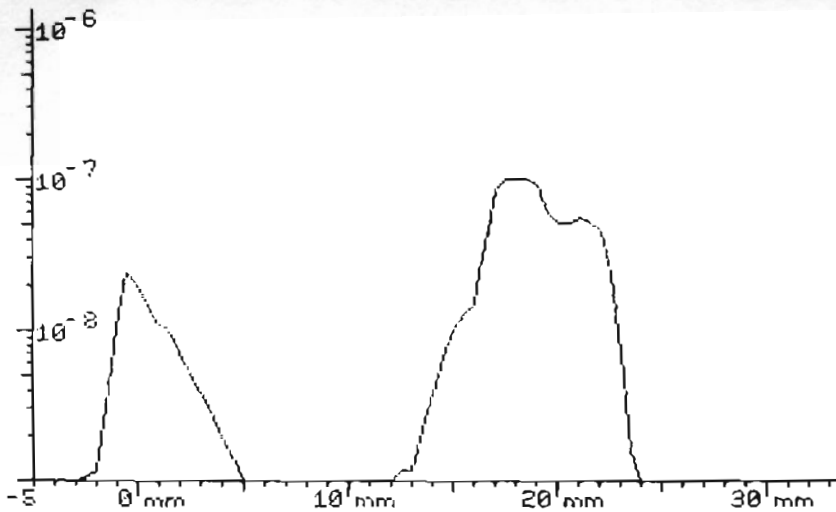


FIGURE 5. Vitreous fluorophotometry scan performed in a diabetic patient with no retinopathy 1 h after the intravenous injection of fluorescein.

In our initial report, the application of vitreous fluorophotometry to a series of diabetic patients with apparently "normal" fundi revealed the presence of a significant breakdown of the blood-retinal barrier in the early stages of retinal involvement in diabetes. The disturbance of the barrier, as evidenced by vitreous fluorophotometry, appears before microaneurysms or capillary closure can be demonstrated by fluorescein angiography. In the past few years, accuracy of the method has been improved (Figure 3), and new protocols with normalization to blood fluorescein levels have been introduced.¹⁴⁻¹⁶ Our results have been confirmed and extended by a number of studies¹⁷⁻²⁰ in both insulin-dependent and non-insulin-dependent diabetic patients.

The early breakdown of the blood-retinal barrier, which occurs in diabetes in the preretinopathy stage (Figures 4, 5, 6, and 7), may represent a structural change of the barrier or result from an inhibition of the active transport of organic anions. One report suggests an alteration of the interendothelial junctions.²¹ This could reflect disordered endothelial proliferation, an alteration consistently observed in human diabetic retinas. However, experimental studies done with rats with streptozotocin-induced diabetes²² showed marked slowing of the rate of clearance of fluorescein from

the vitreous, and rapid reversal of this abnormality after insulin administration, suggesting a functional inhibition of the transport mechanisms. The alteration of the blood-retinal barrier in diabetic animals first reported by Waltman et al.²³ has since been confirmed in streptozotocin-induced diabetes, and in pancreatectomized animals, in studies carried out on different species.^{22,24-26} In a recent study²⁷ we have been able to examine by electron microscopy the alteration of the blood-retinal barrier of two diabetic rhesus monkeys. One animal was diabetic for 11 yr, its diabetes induced by streptozotocin, and the other was diabetic for 5 yr, having had a pancreatectomy. Both animals had abnormal leakage by vitreous fluorophotometry but had no evidence of retinopathy by fundus examination and fluorescein angiography. By light and electron microscopy, degenerative changes were noted in the retinal pigment epithelium, particularly in the macular region. Horseradish peroxidase infiltrated the cytoplasm of some of the retinal pigment epithelium cells. Focal leakage was also noted in the retinal vasculature. This leakage was observed mainly in the retinal veins. The alteration of the blood-retinal barrier, one of the earliest changes in the retina in diabetes, may be due not only to an alteration of the endothelial cells, but also of the retinal pigment epi-

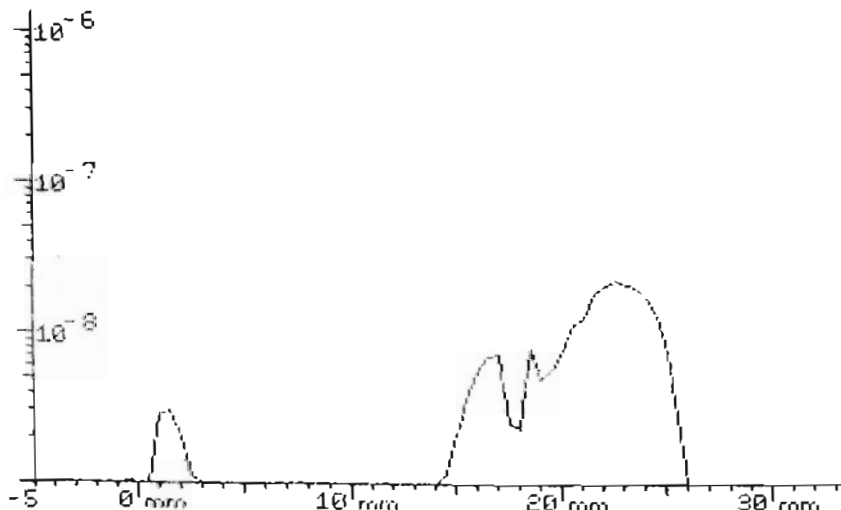


FIGURE 6. Corrected fluorescein concentration in the vitreous in the normal eye represented in Figure 4. Natural fluorescence, lens, and choroid-retina tailing have been removed.

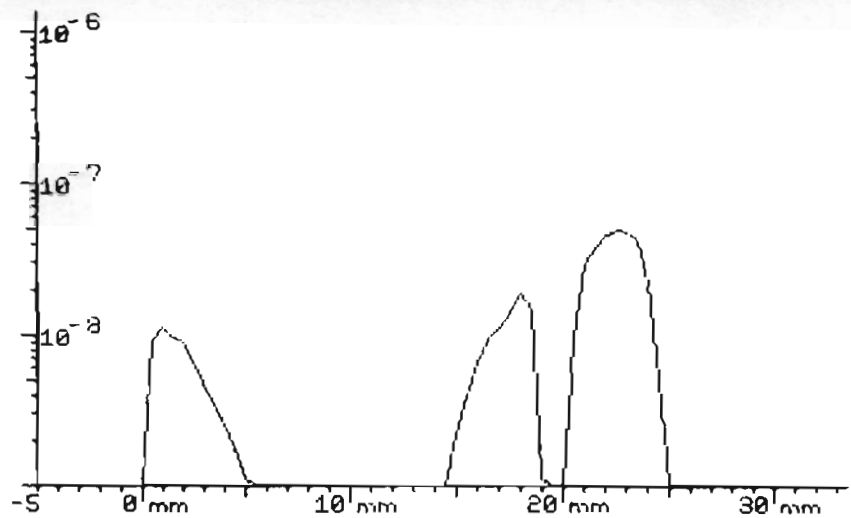


FIGURE 7. Corrected fluorescein concentration in the vitreous in the diabetic eye with no retinopathy represented in Figure 5. Natural fluorescence, lens, and choroid-retina tailing have been removed.

thelium. The relative importance of the alteration of these cellular structures, the mechanisms involved in their damage, and the causal relationship of the diabetic metabolic deviation to these cellular changes in the retina are just a few of the lines of inquiry that need to be followed.

ALTERATION OF THE BLOOD-RETINAL BARRIER AND DEVELOPMENT OF RETINAL LESIONS

Increased permeability of the blood-retinal barrier precedes retinal edema and appears to be responsible for basement membrane thickening, the formation of microaneurysms, and the development of exudates. Retinal hemorrhages are also a result of gross disruption of the blood-retinal barrier. All of these alterations are characteristic features of the pathologic picture of diabetic retinopathy.

In the only longitudinal study already published,²⁸ my co-workers and I followed 25 diabetic patients, who initially had

no clinically visible retinal lesions, by vitreous fluorophotometry for up to 30 mo. Three examinations by vitreous fluorophotometry were performed at approximately 1-yr intervals. This study showed a direct association between progressive increase in vitreal fluorescein levels and development of retinal lesions. Our results also suggested that when a certain level of vitreal fluorescein is reached, retinopathy is almost always present. There have been some conflicting reports regarding correlations between severity of retinopathy and high vitreous fluorophotometry readings. Kernell et al.¹⁹ confirmed our findings, but Waltman et al.^{17,18} could not detect a clear relationship.

Presently it appears that vitreous fluorophotometry correlates with progression of the retinopathy.²⁹ It may also have prognostic value. Rapidly increasing leakage detectable by vitreous fluorophotometry levels suggests deterioration of the retina.

TABLE 1
Comparison of HbA_{1c} variations and changes in vitreous fluorophotometry values

Patient	HbA _{1c} decrease (>0.5%)		HbA _{1c} (±0.5%)		HbA _{1c} increase (>0.5%)	
	HbA _{1c}	VF	HbA _{1c}	VF	HbA _{1c}	VF
1	-2.8	-2.5	—	—	—	—
2	—	—	—	—	+2.1	+1.7
3	—	—	—	—	+3.9	+1.2
4	-4.9	-0.8	—	—	—	—
5	—	—	—	—	+1.2	-0.2
6	—	—	-0.4	+0.9	—	—
7	-4.9	-0.1	—	—	—	—
8	—	—	—	—	+1.2	+2.9
9	—	—	+0.5	-0.2	—	—
10	—	—	-0.2	+0.6	—	—
11	-3.0	-0.8	—	—	—	—
12	-1.4	-0.6	—	—	—	—
13	—	—	0.0	0.0	—	—
14	-2.1	+0.3	—	—	—	—
15	-1.0	+0.0	—	—	—	—
16	—	—	—	—	+1.4	+2.2
17	—	—	—	—	+2.5	+1.9
18	—	—	—	—	+4.4	+0.3
Mean	-2.87	-0.64	-0.025	0.32	2.38	1.42
± SD	±1.55	±0.92	±0.38	±0.51	±1.30	±1.08

ALTERATION OF THE BLOOD-RETINAL BARRIER AND METABOLIC CONTROL

Our initial follow-up study, reported in 1978,²⁶ revealed a statistically significant correlation between vitreous fluorophotometry values and both degree of metabolic control and duration of diabetes. These findings suggested that relatively good metabolic control retards the evolution of the retinopathy by stabilizing the alteration of the blood-retinal barrier. This has been confirmed by a variety of studies^{19,30} and has opened new perspectives for the preventive treatment of diabetic retinopathy. The studies have attempted to correlate vitreous fluorophotometry values with glycosylated hemoglobin levels (index of metabolic control) or improvement of diabetic metabolic control by insulin treatment.

ALTERATION OF THE BLOOD-RETINAL BARRIER AND GLYCOSYLATED HEMOGLOBIN LEVELS

It is generally accepted that the measurement of HbA_{1c} (glycosylated hemoglobin) in diabetic patients may provide a useful index of diabetic control. In our studies no statistically significant correlation could be found between higher vitreous fluorophotometry values and elevated HbA_{1c} levels. However, when the patients were grouped according to duration of diabetes or using a value of HbA_{1c} of 10% as indicative of poor metabolic control, there was some evidence suggesting that in patients without retinopathy the patients under worst metabolic control have leakier retinas.¹⁴ In a more recent study, a series of insulin-dependent diabetic patients was examined at 6-mo intervals and the variations in HbA_{1c} compared with changes in vitreous fluorophotometry values (Table 1). A correlation was observed, again suggesting that the progression in the alteration of the blood-retinal barrier may be directly influenced by the quality of metabolic control.³¹ These studies, however, need further investigation before final conclusions can be drawn.

ALTERATION OF THE BLOOD-RETINAL BARRIER AND INSULIN TREATMENT

Experimental studies applying vitreous fluorophotometry to rats with streptozotocin-induced diabetes have shown that increased permeability of the blood-retinal barrier is an early change that can be reversed by insulin treatment.²³ We have confirmed and extended these observations using kinetic vitreous fluorophotometry. We showed that not only is there a primary leak in the blood-retinal barrier but also a decreased rate of exit of fluorescein from the vitreous in diabetes, and both these alterations of the barrier function are reversed by insulin treatment.²²

While Waltman et al. concluded that normalization of blood glucose levels by insulin administration was followed by recovery of the blood-retinal barrier permeability,²³ our studies suggested that recovery of barrier function, as examined by kinetic vitreous fluorophotometry, may depend not so much on blood glucose levels but on insulin availability.²²

Examination of a series of dogs with spontaneous diabetes has further confirmed the influence of metabolic control on vitreous fluorophotometry values. It was observed that normal dogs of the same age and race showed vitreous fluorophotometry values in the order of 0.7×10^{-8} g/ml, and diabetic dogs under relatively good metabolic control had values of 0.2×10^{-8} g/ml. Values as high as 4.0×10^{-8} g/

ml were recorded in the same diabetic dogs when insulin was stopped for a period of 4 days.

In another study, vitreous fluorophotometry was performed in normal and diabetic rhesus monkeys with a duration of treatment up to 12 yr to evaluate the function of the blood-retinal barrier.²⁶ Diabetes was induced either by streptozotocin or pancreatectomy. Vitreous fluorophotometry values did not differ between 11 control and 10 streptozotocin monkeys not requiring exogenous insulin to prevent ketosis (14 ± 3 and 12 ± 4 mg/ml; $X \pm SD$), but increased significantly in 10 streptozotocin and 6 pancreatectomized rhesus monkeys that were insulin-dependent (22 ± 8 and 27 ± 5 mg/ml). Vitreous fluorophotometry values correlated significantly with serum glucose and glucose tolerance but not with duration of diabetes. Again, this study suggests a direct relationship between insulin availability and blood-retinal barrier.

For some time we have been performing vitreous fluorophotometry in diabetic patients hospitalized to optimally regulate their insulin requirements. In observations made to date, it appears that tight metabolic control, particularly involving more frequent insulin injections, can indeed reverse the alteration of the blood-retinal barrier. Our results, however, are still preliminary, because we have had the opportunity to study only a few cases.

Our observations are, however, in agreement with a growing body of evidence initiated by the report of Waltman et al.³⁰ and recently confirmed by other workers^{19,20} that increased availability of insulin, either through more frequent injections or through the use of insulin infusion systems, may ameliorate the breakdown of the blood-retinal barrier that occurs in the retina of diabetics.

Vitreous fluorophotometry, by measuring the alteration of the blood-retinal barrier, appears to be particularly useful in the study of retinal involvement in diabetes, identifying and measuring the earlier alterations of the barrier. The study of correlations between the diabetic metabolic deviation and the blood-retinal barrier changes is expected to contribute significantly to our understanding of diabetic retinopathy, making it reasonable to expect that diabetic retinopathy may be preventable in the not too distant future.

PATHOPHYSIOLOGY OF DIABETIC RETINOPATHY

The studies outlined above have provided a basis for a working hypothesis of the pathogenesis of diabetic retinopathy. This retinal microangiopathy appears to start with reversible alteration of the blood-retinal barrier at the level of the endothelial membrane of the small retinal vessels. A preceding alteration of the retinal pigment epithelium, or of the retinal neuronal tissue cannot, however, be ruled out at this time. The initial changes in the capillary cell population include endothelial proliferation on the venous side and generalized pericyte damage, and are possibly related to the capillary-venous dilation. Basement membrane thickening associated with the endothelial damage might be responsible for the capillary closure and subsequent shunt formation. Local factors appear to be responsible for the entire evolution of the retinopathy, once the process has been triggered by the changes in the blood-retinal barrier.

The evidence for a direct relationship between the initial alteration of the blood-retinal barrier and diabetic control

offers good support for the view that two distinct processes take part in the pathogenesis of diabetic retinopathy.¹⁴ There is a generalized disorder of the circulation or small blood vessels of still unknown cause that is specific to diabetes and metabolically determined. This generalized disorder affects preferentially the specific endothelial cells of the retina. Second, there are local responses specific to the retina conditioned by its vascular peculiarities and the patient's age, which, once initiated, are largely self-perpetuating.

Human and experimental studies confirm that an alteration of the blood-retinal barrier may be the necessary link between these processes. It remains to be discovered how this endothelial membrane dysfunction occurs in diabetes. Future research should consider the following proposed means by which the diabetic metabolic disturbance may alter the blood-retinal barrier: saturation of the transport mechanism of the barrier cells by increased drainage of metabolites in conditions of abnormal retinal metabolism induced by the diabetic disease; alteration of the transport processes by focal hypoxia, either histotoxic or by an altered ratio between delivery and needs in oxygen, as defended by Ditzel and Standl;³² barrier dysfunction associated with opening of the interendothelial junctions directly due to hyperglycemia or another factor originating in the altered metabolism of diabetes, induced by biochemical or biophysical means such as osmotic influences.²¹ The study of the blood-retinal barrier and of its alteration in diabetes must be kept in the forefront of any research directed to solve the problem of diabetic retinopathy.

REFERENCES

- Kahn, H. A., and Hiller, R.: Blindness caused by diabetic retinopathy. *Am. J. Ophthalmol.* 1974; 78:58-67.
- Cunha-Vaz, J. G.: Aspectos da fisiopatologia vascular da retina. Imprensa de Coimbra, Coimbra, 1967.
- Cunha-Vaz, J. G.: Diabetic retinopathy. Human and experimental studies. *Trans. Ophthalmol. Soc. UK* 1972; 92:111-24.
- Cunha-Vaz, J. G.: The microcirculation and pathology of the diabetic retina. In *Microcirculation*. Effros, R. M., Schmid-Schonbein, H., and Ditzel, J., Eds. New York, Academic Press, 1981:206.
- Ashton, N.: Vascular basement membrane changes in diabetic retinopathy. *Br. J. Ophthalmol.* 1974; 58:344.
- Ashton, N.: The blood-retinal barrier and vasogial relationships in retinal disease. *Trans. Ophthalmol. Soc. UK* 1975; 85:199.
- Ashton, N., and Cunha-Vaz, J. G.: Effect of histamine on the permeability of the ocular vessels. *Arch. Ophthalmol.* 1965; 73:211.
- Cunha-Vaz, J. G., Shakib, M., and Ashton, N.: Studies on the permeability of the blood-retinal barrier. I. On the existence, development and site of a blood-retinal barrier. *Br. J. Ophthalmol.* 1966; 50:441.
- Shakib, M., and Cunha-Vaz, J. G.: Studies on the permeability of the blood-retinal barrier. IV. Role of the junctional complexes of the retinal vessels on the permeability of the blood-retinal barrier. *Exp. Eye Res.* 1966; 5:229.
- Cunha-Vaz, J. G., and Maurice, D. M.: The active transport of the fluorescein by the retinal vessels and retina. *J. Physiol.* 1967; 191:467.
- Cunha-Vaz, J. G.: Studies on the permeability of the blood-retinal barrier. III. Breakdown of the blood-retinal barrier by circulatory disturbances. *Br. J. Ophthalmol.* 1966; 50:505.
- Norton, E. W., and Gutman, F.: Fluorescein angiography of the retina in diabetes mellitus. In *Vascular Complications of Diabetes Mellitus: With Special Emphasis in Microangiopathy of the Eye*. Kimura, S., and Caygill, W., Eds. St. Louis, Mosby, 1967:120.
- Cunha-Vaz, J. G., Abreu, J. R. F., Campos, A. J., and Figo, G.: Early breakdown of the blood-retinal barrier in diabetes. *Br. J. Ophthalmol.* 1975; 59:649.
- Cunha-Vaz, J. G., Goldberg, M. F., Vygantas, C., and Noth, J.: Early detection of retinal involvement in diabetes by vitreous fluorophotometry. *Ophthalmology* 1979; 86:264.
- Cunha-Vaz, J. G., Zeimer, R., Wony, W., and Kiani, R.: Kinetic vitreous fluorophotometry in normals and non-insulin dependent diabetics. *Ophthalmology* 1982; 89:751-56.
- Blair, N., Zeimer, R., Rusin, M., and Cunha-Vaz, J. G.: Outward transport of fluorescein from the vitreous in normal human subjects. In press. *Arch. Ophthalmol.* 1982.
- Waltman, S. R., Krupin, T., Kilo, C., and Becker, B.: Vitreous fluorophotometry in adult-onset diabetes mellitus. *Am. J. Ophthalmol.* 1979; 88:342.
- Krupin, T., Waltman, S. R., Santiago, J., Ratzan, S., Kilo, C., and Becker, B.: Vitreous fluorophotometry in juvenile-onset diabetes mellitus. *Arch. Ophthalmol.* 1978; 96:812.
- Kernell, A., Larsson, Y., Ludvigsson, J., and Tenland, T.: Vitreous fluorophotometry in juvenile diabetes. *Acta Endocrinol.* 1980; 94 (Suppl. 238):67-74.
- Steno Study Group: Effect of 6 months of strict metabolic control eye and kidney function in insulin-dependent diabetics with background retinopathy. *Lancet* 1982; 4:8264-70.
- Wallow, I. H., and Engerman, R. L.: Permeability and patency of retinal blood vessels in experimental diabetes. *Invest. Ophthalmol.* 1977; 16:447-61.
- Jones, C. W., Cunha-Vaz, J. G., Zweig, K. O., and Stein, M. A.: Kinetic vitreous fluorophotometry in experimental diabetes. *Arch. Ophthalmol.* 1979; 97:1941.
- Waltman, S. R., Krupin, T., Hanish, S., Oestrich, C., and Becker, B.: Alteration of the blood-retinal barrier in experimental diabetes mellitus. *Arch. Ophthalmol.* 1978; 96:878.
- Krupin, T., Waltman, S. R., Scharp, D. W., Oestrich, C., Seldman, S. D., Becker, B., Ballinger, W. F., and Lacy, P.: Ocular fluorophotometry in streptozotocin diabetes mellitus in the rat. Effect of pancreatic islet isografts. *Invest. Ophthalmol. Vis. Sci.* 1979; 18:1185.
- Kernell, A.: Influence of metabolic control on the blood-retinal barrier in streptozotocin diabetic rats. *Actas I. International Symposium on Ocular Fluorophotometry, Paris, 1982*. In press.
- Jones, C. W., Cunha-Vaz, J. G., Zeimer, R., Rusin, M., Vygantas, C., and Jonasson, O.: Vitreous fluorophotometry in the normal and diabetic rhesus monkey. In press. *Invest. Ophthalmol. Vis. Sci.* 1982.
- Tso, M. O., Cunha-Vaz, J. G., Blair, N., Jones, C., Suviazdis, F., and Jonasson, O.: Disruption of blood-retinal barrier in diabetic primates. In press. *Invest. Ophthalmol. Vis. Sci.* 1982.
- Cunha-Vaz, J. G., Fonseca, J. R., Abreu, J. R., and Ruas, M. A.: Follow-up study by vitreous fluorophotometry of early retinal involvement in diabetes. *Am. J. Ophthalmol.* 1978; 86:467.
- Cunha-Vaz, J. G., Fonseca, J. R., and Abreu, J. R.: Vitreous fluorophotometry and retinal blood flow studies in proliferative retinopathy. *Albrecht von Graefes Arch. Klin. Exp. Ophthalmol.* 1978; 207:71.
- Waltman, S. R., Santiago, J. R., Krupin, T. R., Singer, P., and Becker, B.: Vitreous fluorophotometry and blood-sugar control in diabetes. *Lancet* 1979; 2:1068.
- Cunha-Vaz, J. G., Rosenthal, I., Weiss, E., and Blair, N.: Vitreous fluorophotometry and metabolic control in insulin-dependent juvenile-onset diabetic patients. *Actas XXIV. Int. Cong. Ophthalmol.* 1982. In press.
- Ditzel, J., and Standl, E.: The problem of tissue oxygenation in diabetes mellitus. I. Its relation to the early functional changes in the microcirculation of diabetic subjects. *Acta Med. Scand.* 1975; 578 (Suppl.):49.