

STUDIES ON THE PROTECTIVE EFFECT OF *RICINUS COMMUNIS* LEAVES EXTRACT ON CARBON TETRACHLORIDE HEPATOTOXICITY IN ALBINO RATS

Evan Prince Sabina^{a*}, MahaboobKhan Rasool^a, Lazar Mathew^a, Parameswari^b,

^aSchool of Bio Sciences and Technology, VIT University, Vellore - 632 014, India.

^bPost graduate Department of Biochemistry, Bharathi Women's College, Chennai-108, India

Summary

Ricinus communis Linn. (Euphorbiaceae) is a soft wooded tree widely prevalent throughout tropics regions of the world which have a warm temperature. In the Indian system of medicine, the leaves, roots and seed oil of this plant have been used for the treatment of inflammation and liver disorders for a long time. In the present study, the protective effects of ethanol extract of *Ricinus communis* L. leaves on carbon tetrachloride (CCl₄)-induced liver damage were investigated in rats. Results were compared those for silymarin, a standard hepatoprotective drug. It was found that an increase in the activities of serum transaminases and the level of liver lipid peroxidation, protein, glycogen and the activities of acid and alkaline phosphatase in liver induced by CCl₄ were significantly inhibited by treatment with *Ricinus communis* ethanol extract (250/500mg/kg/b.wt). In addition, the depletion of glutathione level and adenosine triphosphatase activity observed in the CCl₄-induced rat liver were effectively prevented by treatment with *Ricinus communis* ethanol extract (250/500mg/kg b.wt). Histopathological examination further confirmed the hepatoprotective activity of *Ricinus communis* ethanol extract when compared with the CCl₄-induced control rats. In conclusion, these results indicate that the ethanol extract of *Ricinus communis* ethanol extract exhibits hepatoprotective action.

Keywords: *Ricinus communis*; CCl₄; Serum transaminases; Lipid peroxidation; Hepatoprotective effect

***Corresponding author: Dr. E.P. Sabina Ph.D.**

School of Bio Sciences and Technology, VIT University, Vellore-632104, Tamil Nadu, India E-mail: eps674@gmail.com

Introduction

The hepatitis associated with liver cirrhosis has become one of the most prevalent diseases in the world, which can be induced by virus, alcohol or other toxic chemicals [1]. Carbon tetrachloride, an established hepatotoxin, induces toxicity in rats which closely resembles human cirrhosis [2]. Experimentally, liver diseases have been shown to be produced by the administration of carbon tetrachloride (CCl₄), thioacetamide, paracetamol, etc. CCl₄-induced hepatotoxicity model is frequently used for the investigation of hepatoprotective effect of drugs and plant extracts on experimental animals. CCl₄ hepatotoxicity depends on the reductive dehalogenation of CCl₄ catalyzed by Cyt P450 in the liver cell endoplasmic reticulum leading to the generation of an unstable complex of CCl₃ radical. This trichloromethyl radical reacts rapidly with O₂ to yield trichloromethyl peroxy radical which is reported as a highly reactive species. This free radical attacks microsomal lipids leading to their peroxidation and also covalently binds to microsomal lipids and proteins ultimately initiating a site of secondary biochemical processes which is the ultimate cause of pathological consequences of CCl₄ metabolism [3]. Despite extensive research in the medicine, no drug in the modern system of medicine can be claimed to be effective to cure liver disorders, which in many times become fatal, however, the search for new medicines is still going on [4,5]. Therefore, many remedies of folk tradition from plant origins are evaluated for its possible antioxidant and hepatoprotective effects against different chemical-induced liver damage in experimental animals.

Ricinus communis Linn. (Euphorbiaceae) is a soft wooded tree widely prevalent throughout tropics regions of the world which have a warm temperature [6]. In the Indian system of medicine, the leaves, roots and seed oil of this plant have been used for the treatment of inflammation and liver disorders for a long time [7]. They have been found to be hepatoprotective against galactosamine-induced hepatic damage [8], hypoglycemic [9], laxative [10], diuretic [11] and antibacterial effects [12]. The leaves of *Ricinus communis* found to contain flavanoids like kaempferol-3-O-beta-D-rutinoside and kaempferol-3-O-beta-D-xylopyranoid and tannins [13,14]. However, scientific studies on its utility in damaged liver are few and the aim of the present study was to confirm the hepatoprotective effect of *Ricinus communis* extract against CCl₄-induced hepatic injury in rats. In addition, its hepatoprotective effect was compared to the effect of silymarin which is known to be effective against CCl₄-or acetaminophen-induced liver damages [15].

Experimental

Animals

Male albino rats of Wistar strain (140±10g b.w.) were obtained from the Tamil Nadu Veterinary College, Chennai, India. They were acclimatized for a week in a light and temperature-controlled room with a 12 hr dark-light cycle and fed with commercial pelleted feed (Water 8.9%, Protein 25.4%, Lipid 4.4%, Carbohydrate 50.3%, Ash 6.9%, and Crude fiber 4.1%) from Hindustan Lever Ltd. (Mumbai, India) and water was made freely available. The animals used in this study were treated and cared for in accordance with the guidelines recommended by the Committee for the Purpose of Control and

Supervision of Experiments on Animals (CPCSEA), Government of India, Ministry of Culture, Chennai, India. Experimental protocol was approved by the departmental ethical committee.

Preparation of the extract

Fresh leaves of *Ricinus communis* were collected from rural areas around Chennai, India, and it was authenticated by Chief Botanist, VIT University, Vellore, India. The leaves were dried at the room temperature. The dried and powdered leaves of *Ricinus communis* (1 kg) were extracted with 80% ethanol at room temperature for 24 hrs. It was then filtered and the filtrate was evaporated and dried in a vacuum dessicator. The percentage yield of the dried extract was 15% from the initial raw material. This dried extract and a reference drug, silymarin, Micro Labs, Tamil Nadu, India were dissolved in water and administered to the animals by oral intubation method respectively.

Experimental design

In this study, all group of rats except group I and group VI (negative control) received CCl₄ once only. The animals were divided into six groups of six animals each and were treated as follows:

- Group I : normal control (vehicle olive oil only)
- Group II: CCl₄ (3ml/kg/b.wt intraperitonially in olive oil (1:1, v/v), single administration).
- Group III: CCl₄ + *Ricinus communis* ethanol extract (250mg/kg/b.wt, p. o. for five days).
- Group IV: CCl₄ + *Ricinus communis* ethanol extract (500mg/kg/b.wt, p. o. for five days).
- Group V: CCl₄ + silymarin (50mg/kg/b.wt, p. o. for five days).
- Group VI: negative control (*Ricinus communis* ethanol extract 500mg/kg/b.wt, p. o. for five days).

At the end of the experimental period, all the animals were sacrificed under ether anesthesia. Blood and liver samples were collected. The blood was allowed to clot for 30 min; serum was separated by centrifuging at 37^oc which was used for biochemical estimations.

Assessment of hepatoprotective activity

The activities of serum glutamate pyruvate transaminase (SGPT) and serum glutamate oxaloacetate transaminase (SGOT) were assayed by the method of Reitman and Frankel [16]. Estimation of activities of alkaline phosphatase (ALP), acid phosphatase (ACP) by the method of King [17], and total ATPases [18], protein [19], and glycogen content [20], lipid peroxide [21] and glutathione level [22] were also carried out in liver tissue to assess the damage caused by CCl₄.

Histopathological studies

Immediately after sacrifice, a portion of the liver was fixed in 10% formalin. The washed tissue was dehydrated in descending grades of isopropanol and finally cleared in xylene. The tissue was then embedded in molten paraffin wax and cut into 5 μm thick sections in a rotary microtome.

The sections were then stained with haematoxylin and were studied for histopathological changes, i.e. necrosis, fatty changes and lymphocyte infiltration. Histological damages were scored as follows: 0; absent; +: mild; ++: moderate; +++: severe.

Statistical analysis

The results were expressed as mean \pm S.D. and statistical analysis was performed using ANOVA to determine significant differences between the groups, followed by Student's Newman-Keul's test. $P < 0.05$ was the implied significance.

Results

Administration of CCl_4 to rats caused a significant elevation in serum aspartate, and alanine aminotransmainases (Table 1). However, the elevated SGOT and SGPT activity observed in CCl_4 -treated rats was found to be significantly decreased by prior administration of *Ricinus communis* ethanol extract.

Alterations in the activities of acid phosphatase, alkaline phosphatase, adenosine triphosphatase, glycogen and protein content, lipid peroxidation and glutathione level of liver after single exposure to CCl_4 were expressed in Table 2. Reduced glutathione and enhanced lipid peroxide level were seen in the CCl_4 -treated group, whereas the drug treated groups showed a significant rise in glutathione level with the reduction in lipid peroxidation level, when compared to the CCl_4 -treated group. In CCl_4 -treated rats, the activities of acid phosphatase and alkaline phosphatase were found to be increased, whereas a decreased glycogen and protein content and adenosine triphosphatase activity was observed when compared to the normal control groups. Administration of *Ricinus communis* ethanol extract to the CCl_4 -treated rats modulates the above alterations to near normal levels.

As shown in **Figure 1A-F and Table 3**, liver sections from the control group (**Fig.1A**) and *Ricinus communis* ethanol extract (500 mg/kg. b.wt) alone treated rats (**Fig 1F**) showed normal lobular architecture and normal hepatic cells. The liver section from animals given CCl_4 showed increased cytoplasmic staining and infiltration of mono nuclear cells around the portal triad and in the lobule (**Fig. 1B**). The histological pattern of the liver of the CCl_4 -induced rats treated with *Ricinus communis* ethanol extract (**Fig.1C and Fig. 1D**) and silymarin (**Fig.1E**) showed marked improvement and return to normal architecture respectively.

Table1: Activities of aspartate transaminase (AST) and alanine transaminase (ALT) in serum of normal and experimental rats.

Parameters (IU/L)	Group –I (Control)	Group –II(CCl ₄ -induced)	Group –III (CCl ₄ -induced + <i>Ricinus communis</i> extract 250mg/kg/b.wt)	Group -IV(CCl ₄ -induced + <i>Ricinus communis</i> extract 500mg/kg/b.wt)	Group-V(CCl ₄ -induced + silymarin 50mg/kg/b.wt)	Group -VI(<i>Ricinus communis</i> extract 500mg/kg/b.wt)
Serum AST	44.4 ± 5.77	237.0± 4.64 a*	60± 5.21 b*	55± 5.21 b*	54.9± 5.2 b*	46.3± 3.94
Serum ALT	55.0 ± 7.94	120.4 ± 21.85 a*	65.2± 6.91 b*	60.5± 6.91 b*	59.5 ± 7.64 b*	57.2 ±6.75

The values are expressed as mean ± S.D. Each group consists of six animals

Comparisons were made as follows: a: Group II (CCl₄-induced) vs. Group I (control)

b: Group II vs. Group III (CCl₄-induced +*Ricinus communis* extract 250mg/kg/b.wt),
Group IV (CCl₄-induced +*Ricinus communis* extract 500mg/kg/b.wt)
Group-V (CCl₄-induced + silymarin 50mg/kg/b.wt)

The symbol represents the statistical significance at: *P<0.05.

Table 2: Effect of *Ricinus communis* extract on CCl₄-induced liver damage in rats

Parameters	Group -I(Control)	Group -II(CCl ₄ -induced)	Group -III(CCl ₄ -induced + <i>Ricinus communis</i> extract 250mg/kg/b.wt)	Group -IV(CCl ₄ -induced + <i>Ricinus communis</i> extract 500mg/kg/b.wt)	Group -V(CCl ₄ -induced + silymarin 50mg/kg/b.wt)	Group -VI (<i>Ricinus communis</i> extract 500mg/kg/b.wt)
ALP (μ moles of phenol / min/ mg protein)	9.56± 0.33	24.81± 1.02a*	9.35± 0.55 b*	10.0± 1.01 b*	11.2 ±1.5 b*	10.4± 1.05
ACP (μ moles of phenol / min/ mg of protein)	5.12± 0.32	9.37± 0.56 a*	6.32± 0.45 b*	6.21± 0.39 b*	5.8 ±0.41 b*	5.4 ±0.37
Total ATPase (mg Pi/100g/min)	2.9± 0.12	1.35± 0.10 a*	2.6 ±0.09 b*	2.1 ±0.22 b*	2.45± 0.19 b*	2.32± 0.15
Glycogen (mg/100g)	11.00± 1.26	7.50 ±0.51 a*	10.00± 0.63 b*	10.33 ±1.03 b*	10.50 ±0.83 b*	9.83± 1.32
Protein (mg/100 g)	185.1± 19.2	155.2 ±10.9 a*	190.5± 14.25b*	192.5± 18.9 b*	189.2± 18.5 b*	191.2 18.2
Lipid peroxidation (nmol MDA/mg protein)	164.82 ±8.15	237.33± 9.11 a*	172.28± 7,89 b*	186.66± 16.32 b*	169.21± 11.63 b*	166.83± 5.84
Glutathione (μmol/g)	9.57 ± 0.17	7.52 ± 0.44 a*	9.82± 0.19 b*	9.90± 0.21 b*	8.90 ± 0.16 b*	9.01± 0.17

The values are expressed as mean ± S.D.

Each group consists of six animals

Comparisons were made as follows: a: Group II (CCl₄-induced) vs. Group I (control)

b: Group II vs. Group III (CCl₄-induced +*Ricinus communis* extract 250mg/kg/b.wt),

Group IV (CCl₄-induced +*Ricinus communis* extract 500mg/kg/b.wt)

Group-V(CCl₄-induced + silymarin 50mg/kg/b.wt)

The symbol represents the stastical significance at: *P<0.05.

Table 3: Effect of the *Ricinus communis* ethanol extract on histopathological damages induced by CCl₄ injection in rats

Microscopic observation	Necrosis	Fatty changes	Infiltration of lymphocyte
Control	0	0	0
CCl ₄ (3ml/kg/b.wt, i.p.)	+++	+++	+++
CCl ₄ (3ml/kg/b.wt, i.p.) + <i>Ricinus communis</i> ethanol extract (250mg/kg/b.wt, p. o)	++	++	++
CCl ₄ (3ml/kg/b.wt, i.p.) + <i>Ricinus communis</i> ethanol extract (500mg/kg/b.wt, p. o)	+	+	+
CCl ₄ (3ml/kg/b.wt, i.p.) + silymarin (50mg/kg/b.wt, p. o.)	+	0	+
Negative control (<i>Ricinus communis</i> ethanol extract 500mg/kg/b.wt, p. o)	+	0	+

0; absent; +: mild; ++: moderate; +++: severe; rats were injected (i.p.) with *Ricinus communis* ethanol extract for five days after the injection of CCl₄ (3ml/kg/b.wt, i.p.). Histopathological damages were assessed as explained under materials and methods.

Fig.1 Photomicrographies of paraffin-embedded rat liver

Fig. 1A Normal Architecture of the liver cell was seen in olive oil alone treated (normal) rats

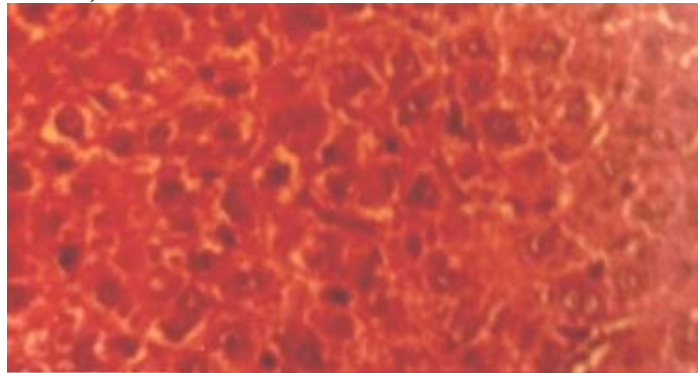


Fig. 1B Few hepatocytes showing increased cytoplasmic staining and infiltration of mono nuclear cells around the portal triad and in the lobule were observed in liver of CCl₄-induced rats

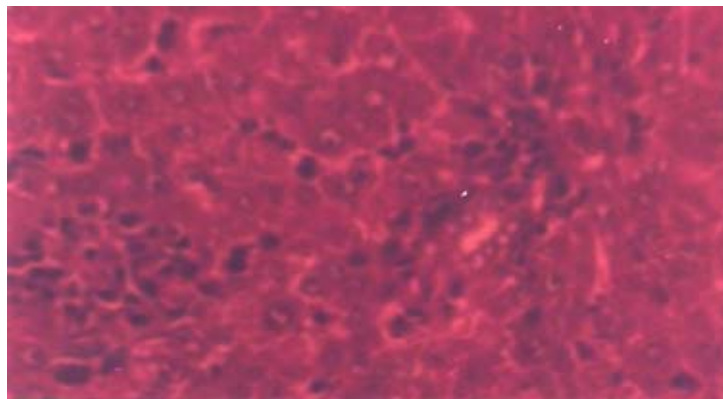


Fig 1C. Liver showing minimal inflammatory cellular filtration was observed in *Ricinus communis* ethanol extract (250 mg/kg b.wt) treated CCl₄-induced rats.

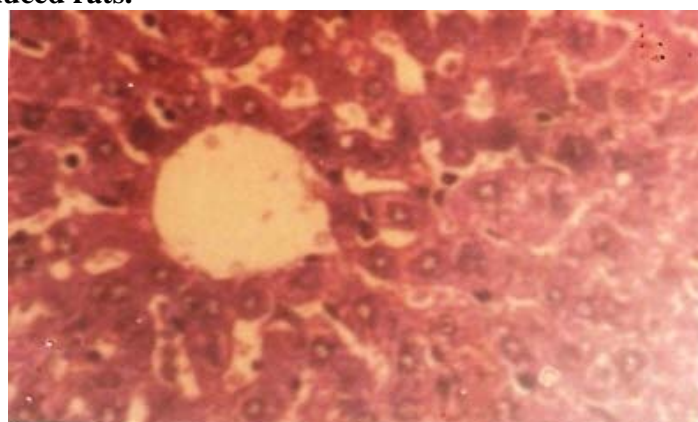


Fig. 1D Liver showing marked improvement to normal architecture was observed in *Ricinus communis* ethanol extract (500 mg/kg b.wt) treated CCl₄-induced rats.

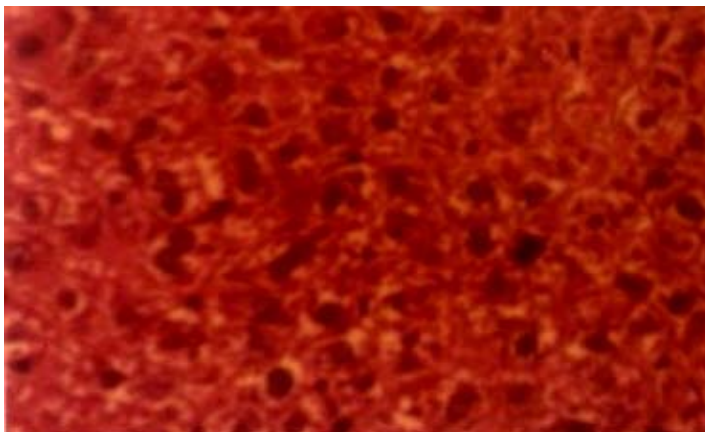


Fig. 1E Liver returned to almost normal architecture was observed in silymarin (50 mg/kg b.wt) treated CCl₄-induced rats.

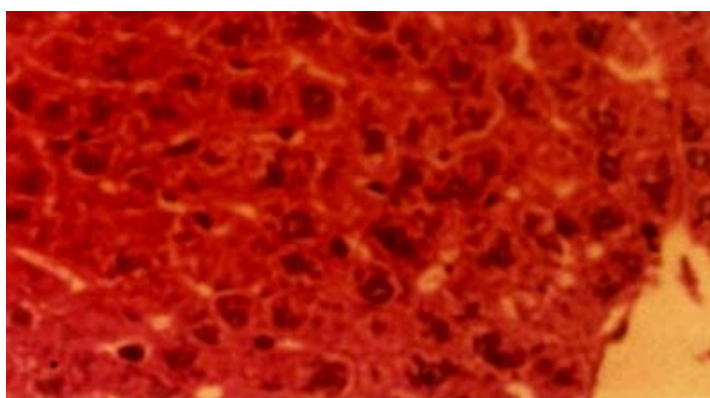



Fig. 1F Normal Architecture of the liver cell was seen in *Ricinus communis* ethanol extract (500mg/kg b.wt) alone treated rats



Discussion

CCl₄-induced hepatic injury is often used as a model for hepatoprotective drug screening and the extent of the hepatic damage is assessed by the level of release cytoplasmic transaminases (SGOT and SGPT) in circulation [23]. The present study revealed a significant increase in the activities of SGOT and SGPT in serum (Table 1) and elevated acid and alkaline phosphatases (ALP) (Table 2) in liver on exposure to CCl₄, indicating considerable hepatocellular injury. Administration of *Ricinus communis* ethanol extract at two different dose levels attenuated the increased levels of marker enzymes, observed in CCl₄-induced rats. The hepatoprotective effect of the *Ricinus communis* ethanol extract was further supported by the limited extent of histological changes (Fig. 1), in *Ricinus communis* treated CCl₄-induced rats. This is in agreement with the commonly accepted view that serum levels of transaminases return to normal with healing of hepatic parenchyma and the regeneration of hepatocytes [24].

CCl₄ is believed to be metabolized by microsomal cytochrome P450 in the liver to a highly reactive trichloromethyl free radical, which can start a chain of reactive free radical formation resulting in peroxidation of lipids and damage to proteins and cell components [5]. The level of lipid peroxide is a measure of membrane damage and alterations in structure and function of cellular membranes. Glutathione protect cells against electrophilic attacks provided by xenobiotics such as free radicals and peroxides. The elevation of MDA levels, which is one of the end products of lipid peroxidation in the liver tissue, and reduction of hepatic GSH levels are important indicators in CCl₄-intoxicated rats [25]. In this study, enhanced liver lipid peroxidation and reduced glutathione level were seen in Group II CCl₄ treated rats (Table 2). However, *Ricinus communis* extract treatment, prevented glutathione depletion with reduction in lipid peroxidation level in CCl₄-induced rats when compared to CCl₄-treated control group. The *Ricinus communis* extract with the potentiality to scavenge the free radicals contains flavanoids and tannins. Flavanoids and tannins have been reported to have anti-peroxidative effects [26]. Moreover recently *Ricinus communis* root extract was also found to have free radical scavenging activity [27]. Thus, this finding suggests that the *Ricinus communis* extract was effective in bringing about functional improvement of hepatocytes.

The decreased hepatic glycogen content, and adenosine triphosphatase activity observed in CCl₄ induced rats (Table 2) in our study agrees with previous reports [28]. Glycogen is the main source of energy in the liver [29], so the reduced glycogen content observed in CCl₄ induced rats may be due to excess requirement of energy in liver. CCl₄ intoxication is capable of initiating cell injury and cellular sites for free radical generation include mitochondria, endoplasmic reticulum and plasma membrane. A significant fall in the activity of adenosine triphosphatase observed in CCl₄ induced rats may be due to the structural and functional disorganization of mitochondria assembly. Upon *Ricinus communis* extract treatment to CCl₄ induced rats, the above said changes were found to be restored significantly when compared to CCl₄ induced rats. The ability of a hepatoprotective drug to reduce the injurious effects or to preserve the normal hepatic physiological mechanisms, which have been disturbed by a hepatotoxin, is the index of its protective effects [30]. It is reported earlier that fresh leaves and aqueous extract of *Ricinus communis* offered protection against CCl₄-induced hepatic damage in albino rats

[31]. In our study, our results demonstrated that the possible hepatoprotective mechanisms of the ethanol extract of *Ricinus communis* leaves on CCl₄-induced hepatic damage in rats. Histopathological examinations also show that *Ricinus communis* ethanol extract (250/500mg/kg/b.wt) at both levels of dosage offer hepatoprotection. In addition, this plant extract up to an oral dose of 1g/kg was found to be devoid of any lethal effects and no apparent behavioral change was observed.

Conclusions

In conclusion, the present study has demonstrated that the ethanolic extract of *Ricinus communis* has hepatoprotective effect against CCl₄-induced hepatotoxicity in rats. The beneficial effect of the *Ricinus communis* ethanol extract may be due to the presence of some flavanoids that may have membrane stabilizing and antiperoxidative effects. Thus, this result suggests that the flavanoids and tannins present in the *Ricinus communis* ethanol extract might efficiently increase the regenerative and reparative capacity of the liver. Although *Ricinus communis* ethanol extract has comparable hepatoprotective effect with silymarin in our study, clarification of the hepatoprotective mechanism and the active components of the *Ricinus communis* extract need further investigation.

References

1. Wang N, Li P, Wang Y, Peng W, Wu Z, Tan S, Liang S, Shen X, Su WW. Hepatoprotective effect of *Hypericum japonicum* extract and its fractions. J Ethanopharmacol. 2008;116: 1-6.
2. Al-Shabanah OA, Alam K, Nagi MN, Al-Rikabi AC, Al-Bekairi AM. Protective effect of aminoguanidine, a nitric oxide synthetase inhibitor against CCl₄- induced hepatotoxicity in mice. Life Sci 2000; 66: 265-270.
3. Olantunde Farombi E. Mechanisms for the hepatoprotective action of kolaviron: studies on hepatic enzymes, microsomal lipids and lipid peroxidation in carbontetra chloride-treated rats. Pharmacol Res 2000; 42: 75-80.
4. Agarwal M, Srivastava VK, Saxena KK, Kumar A. Hepatoprotective activity of Beta vulgaris against CCL₄-induced hepatic injury in rats. Fitoterapia 2006;77: 91-93.
5. Jamshidzadeh A, Fereidooni F, Salehi Z, Niknahad H. Hepatoprotective activity of *Gundelia tourenfortii* J Ethanopharmacol 2005;101: 233-237.
6. Ivan A, Chemical constituents, traditional and modern uses. In: Medicinal Plants of the World. Ross Humana Press Inc., Totowa, NJ, 1998. pp. 375-395
7. Kiritikar KR, Basu BA. Indian Medicinal Plants 1991; 3: 2274-2277.
8. Visen P, Shukla B, Patnaik G, Tripathi S, Kulshreshtha D, Srimal R, Dhawan B. Hepatoprotective activity of *Ricinus communis* leaves. Intl J Pharmacog 1992; 30: 241-250.
9. Dhar ML, Dhar MM, Dhawan BN, Mehrotra BN, Ray C. Screening of Indian plants for biological activity. Part I. Indian J Exp Biol 1968;6: 232-247.
10. Capasso F, Mascolo N, Izzo AA, Gaginella TS. Dissociation of castor oil induced diarrhea and intestinal mucosal injury in rat: effect of NG-nitro-L-arginine methyl ester. Br J Pharmacol 1994;113: 1127-1130.

11. Abraham Z, Bhakuni SD, Garg HS, Goel AK, Meharotra BN, Patnaik GK. Screening of Indian plants for biological activity. Part XII. Indian J Exp Biol 1986; 24: 48-68.
12. Verpoorte R, Dihal PP. Medicinal plants of the Surinam. IV. Antimicrobial activity of some medicinal plants. J Ethanopharmacol 1987;21: 315-318.
13. Kang SS, Cordell A, Soejarto DD, Fong HHS. Alkaloids and flavanoids from *Ricinus communis*. J Nat Prod 1985;48: 155-156.
14. Khogali A, Barakat S, Abou-Zeid H. Isolation and identification of the phenolics from *Ricinus communis* L. Delta J Sci 1992;16: 198-211.
15. Chrungoo VJ, Singh K, Singh J. Silymarin mediated differential modulation of toxicity induced by carbontetra chloride, paracetamol and D-galactosamine in freshly isolated rat hepatocytes. Indian J Exp Biol 1997;35: 611-617.
16. Reitman S, Frankel S. A colorimetric method for the determination of serum glutamic oxaloacetic and glutamic pyruvic transaminases. Am J Clin Pathol 1957; 28: 56-63.
17. King J. The hydrolases-acid and alkaline phosphatases, In: Van D, editor. Practical clinical enzymology. Nostrand Company Limited, London, (1958) pp.191-208.
18. Seth PK, Tangari KK. Biochemical effects of newer salicylic acid congenesis. J Pharm. Pharmacol 1966;18: 831-833.
19. Lowry OH, Rosebrough NJ, Farr AI, Randall RJ. Protein measurement with the folin phenol reagent. J Biol Chem. 1951;193: 265-275.
20. Hassid WZ, Abraham S. Chemical procedures for analysis of polysaccharides. Methods Enzymol 1957; 3: 34-50.
21. Ohkawa H, Ohishi N, Yagi K. Assay for lipid peroxides in animal tissues by thiobarbituric acid reaction, Anal. Biochem. 1997; 95: 351-358.
22. Griffith OW. Determination of glutathione and glutathione disulfide using glutathione reductase and 2-vinylpyridine, Anal. Biochem. 1980;106: 207-212
23. Janbaz KH, Saeed SA, Gilani AH. Protective effect of rutin on paracetamol and CCl₄ induced hepatotoxicity in rodents. Fitoterapia 2002;73(78):557-63
24. Thabrew M, Joice P, Rajatissa W. A comparative study of the efficacy of *Pavetta indica* and *Osbeckia octandra* in the treatment of liver dysfunction. Planta Medica 1987;53: 239-241
25. Souza MF, Rao VSN, Siliveira ER. Inhibition of lipid peroxidation by ternatin, a tetramethoxyflavone from *Egletes viscosa* L. Phytomedicine 1997;4: 25-29.
26. Yokozawa T, Chen CP, Dong E, Tanaka T, Nonaka GI, Nishioka I. Study on the inhibitory effect of tannins and flavanoids against the 1, 1-diphenyl-2-picrylhydrazyl radical. Biochem Pharmacol 1998;56: 213-222.
27. Ilavarasan R, Mallika M, Venkataraman S. Anti-inflammatory and free radical scavenging activity of *Ricinus communis* root extract. J Ethanopharmacol 2006;103: 478-480.
28. Jadon A, Bhadauria M, Shukla S. Protective effect of *Terminalia bellerica* Roxb. and gallic acid against carbon tetrachloride induced damage in albino rats. J Ethanopharmacol 2007;109, 214-218.
29. Krehenbuhl S, Weber Jr FL, Brans E. Decreased hepatic glycogen content and accelerated response to starvation in rats with carbon tetrachloride induced cirrhosis. Hepatology 1991;14: 1189-1195.
30. Yadav NP, Dixit VK. Hepatoprotective activity of leaves of *Kalanchoe pinnata* Pers. J Ethanopharmacol 2003; 86: 197-202.
31. Natu MV, Agarwal S, Agarwal SL, Agarwal S. Protective effect of *Ricinus communis* leaves in experimental liver injury. Ind. J. Pharmac 1977; 9 (4): 265-268.