

STUDY OF TWO CASES OF CUTANEOUS AND SUBCUTANEOUS NOCARDIOSIS

A. R. KHOSRAVI, AND M. EMAMI

From the Department of Medical Mycology and Parasitology, School of Public Health, Tehran University of Medical Sciences, Tehran, Islamic Republic of Iran.

ABSTRACT

Presence of fungal agents in lesions of two patients in Tehran was studied. One of them had clinical symptoms of mycetoma in his foot, and the other had a skin infection in his arm. Examination of the lesions indicated *Nocardia asteroides*. These patients did not show any evidence of nocardia infection in other parts of the body. Negative results were obtained from the cultures of blood and sputum.

MJIRI, Vol.5, No. 3 & 4, 169-172, 1991

INTRODUCTION

Nocardiosis is a fungal infection which is either a subacute or chronic pulmonary infection or a cutaneous and subcutaneous granulomatosis. It is caused by various species of *Nocardia*, especially *N. asteroides*, but also may be caused by *N. brasiliensis* and *N. caviae*.^{2,13,16}

The *Nocardia* genus are soil saprophytes that reside on vegetable debris, thorns, sticks, and so forth, and rarely as saprophyte in the skin or in the upper pulmonary airways without causing clinical symptoms, but these organisms are not a part of body normal flora.^{3,4,10,12} In the reviewed cases, the male to female ratio is given as 2:1 or 3:1.^{11,12,15}

CASE REPORTS

CASE 1

A 24-year-old man residing in Tehran presented with left leg enlargement and inflammation and had many fistulas and sinuses. From them pus and grains were excised. His foot was tumored and painful. In his right leg ulcerative lesions were also seen. The patient was injured three years before the onset of the clinical symptoms. Therefore the history of trauma and developing ulcers in both legs was present (Fig. 1).

CASE 2

A 38-year-old man residing in Tehran presented with skin lesions in his arm in the form of abscess,

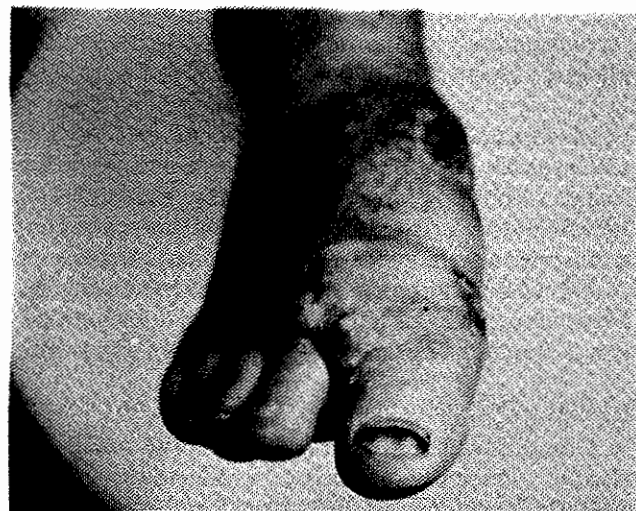


Fig. 1. Process of tumor-like inflammation on the foot that has softened and ruptured.

cellulitis and ulcer. Two years before the appearance of the clinical symptoms, the patient had trauma and ulcer in his arm (Fig. 2).

MATERIALS AND METHODS

A: Specimen preparation

First, the site of lesions of the first patient was cleansed with 70° alcohol until it became devoid of pus or saprophytes. Its pores and abscesses were pressed with sterilized gauze to empty their contents (pus, gra-




Fig. 2. The ulcer appearance leading to skin lesions in patient's arm.

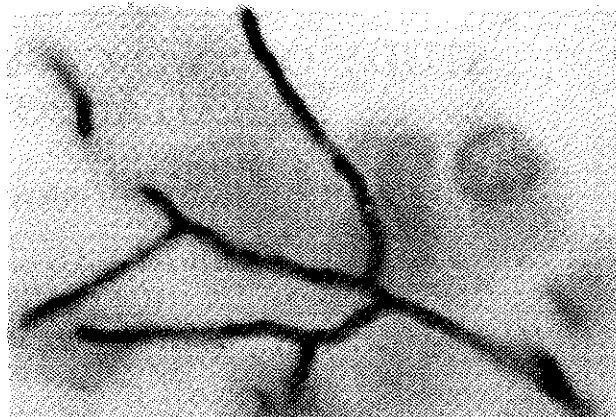


Fig. 3. Branched filaments in *Nocardia asteroides*.

nules and blood). Fistulas and abscesses which were not opened, first were disinfected with iodide alcohol and then with 70° alcohol, and then were opened with a sterile scalpel. The content was taken out into a plate containing some sterile saline, and was washed several times with the same saline until the granules became free of blood and pus. Secretions and pus from of the second patient's hand were also collected in a sterilized plate.

B: Direct examination

Granules, secretions and pus obtained from the lesions of both patients were directly examined with 10% KOH, and narrow, hyaline and branched filaments with a diameter of less than 1 micron were seen.

After preparation and staining of smears using the kinyoun carbol fuchsin technique, its acid-fast property was seen by using the blue and red colors (Figure 3).

C: Culture

Granules which were crushed in sterile saline and also pus and secretions which were collected separately from both patients, were cultured in two series in sabouraud's agar containing chloramphenicol and cyclohexamide, blood agar, brain heart agar and Lowenstein Jensen.

The first series of cultures were kept at laboratory temperature (25°C), and the second series were kept at 37°C. After eight days, the granular, folded, chalky formed, and humid earth-smelling colonies were grown (Figure 4).

For these colonies, slide culture and staining by kinyoun method was performed. Differentiate tests, sugar assimilation (galactose, mannitol and inositol), casein, terosine, starch and urea were carried out. The agent was identified as *N. asteroides*.

DISCUSSION

By contact with the infectious agents which are a part of saprophytes present in soil, nocardia infection is developed.^{2,4,10} In many cases, infection is produced by *N. asteroides*.¹² The first case report of nocardiosis caused by *N. asteroides* was presented by Eppinger in 1890,^{3,4,10} but in Iran, the first case of the generalized nocardiosis was reported by Askari, et al.¹⁸

In many cases, there are predisposing factors such as leukemia, lymphoma, treatment with steroids, cytotoxins, and probably extreme treatment with antibiotics. But in subjects who do not have such factors, this infection can also be observed.

From the 500-1000 cases of nocardiosis which are identified annually, 80% are observed in subjects who have immune deficiency.²

Patients with cutaneous nocardiosis usually have a previous history of trauma or contact with soil. Cutaneous lesions may be found in the form of cellulitis, pustules, pyoderma, or a cutaneous lymphatic syndrome which is similar to sporotrichosis.^{13,14}

The lymphatic syndrome is usually caused by *N. brasiliensis*. Healthy hosts who develop cutaneous infection recover comparatively quickly, either spontaneously or with a short course of treatment by sulphonamides.

Cutaneous draining sinuses and abscesses may be caused by extension of nocardiosis present in internal organs.^{13,14} Patient no. 2, who had cutaneous lesions in his right arm had a history of trauma and wounds in the lesion site. In the examination of arm secretions, narrow, hyaline and branched filaments with a diameter of less than one micron were observed. In the culture medium, chalky form colonies had grown. After physiological tests, *Nocardia asteroides* was iden-




Fig. 4. The granular, folded, and chalky form of *Nocardia asteroides* colony.

tified. Blood and sputum culture tests of *Nocardia* were negative. Therefore, in this patient, the organism causing the infection was transported locally to the skin by the pathway of cutaneous wound, causing the cutaneous nocardiosis.

Subcutaneous nocardiosis infection is a actinomycotic mycetoma infection which is a chronic purulent disease and causes granulomatosis. This infection may be caused by the infectious agent inoculation. Seven genera of aerobic actinomycetes which cause actinomycotic mycetoma have been identified.

Three of these are related to nocardiosis which are: *N. brasiliensis*, *N. asteroides*, and *N. caviae*. The other genera are related to *Streptomyces somaliensis* and *S. paraguangensis*.

Infectious agents which are present in soil and plants may be transferred to the body via wounds and scratches.^{7,9} Locally, these agents gradually form small cutaneous masses. These lesions which are found on the skin surface are opened, and form sinuses. When they empty their contents (pus and granules), these sinuses will be closed, but other pores are opened.

Granules have different colors which differentiates mycetoma from similar diseases such as yaws and

sporotrichosis. Mycetoma usually occurs on one foot or hand and less commonly on shoulders, head, and other parts. This chronic infection is slowly developed and produces many abscesses which are opened through pores to empty their contents. Infectious agents can invade bones and connective tissues, and produce fibrosis and bone deformity, and cause organ masses.¹⁷

In different parts of the world such as Sudan, Mexico, and India, mycetoma is a widely distributed disease.^{5,6,8} Research work in Iran showed the presence of this disease in north Iran (near the coasts of the Caspian sea), and also in the provinces of Khoozestan (Ahwaz), Zanjan (Qazvin), Azarbayjan, Farse (Shiraz), Esfahan, and Khurasan.^{1,18}

Many mycetoma cases are observed in ages between 30-50 years. In the first patient, a history of trauma and wound in the lesion site were present. The inoculation of the organism, with respect to the appearance of the clinical symptoms, may be correlated with the occurrence of the wound. The disease took long to develop. After the preparation of smears from pus and granules the acid-fast filaments were observed. In culture media which are used for *N. asteroides* this organism was grown. Cultures of sputum and blood were negative for *Nocardia*.

It is important to note that eumycetes cause a mycetoma named eumycotic mycetoma in which the clinical symptoms are completely similar to that of actinomycotic mycetoma. According to the previous statements, mycetoma is caused by different organisms, in which the treatment of these two different forms of mycetoma are different.

Therefore, identification of the type of mycetoma as well as observation of clinical symptoms is important for initiating treatment.^{9,13}

REFERENCES

1. Asgari M, Alilou M: Mycetoma in Iran. The first report of eight cases with mycological studies. *Ann Soc Belge Med Trop* 52 (451): 287-306, 1972.
2. Beaman BI, Burnside J, Edwards B, et al: *Nocardia* infection in the United States. *J Infect Dis* 134-289, 1976.
3. Emmons CW: The significance of saprophytism in the epidemiology of the mycosis. *Trans NY Acad Sci* 157-166, 1959.
4. Gordon RE, Hagen WA: A study of some acid-fast actinomycetes from soil with special reference to pathogenicity from animals. *J Infect Dis* 59: 200-206, 1939.
5. Green WO, Adams TE: Mycetoma in the United States. *AM J Clin Pathol* 42: 75-91, 1964.
6. Indira PV, Sirsi M: Studies on maduramycosis. *Indian J Med Res* 56: 1265, 1965.
7. Lavalle P: Agents of mycetoma in Dalldorf. *Fungi and fungus disease*. Springfield, Il. Charles. C. Thomas, 50-65, 1962.
8. Lynch B: Mycetoma in the Sudan. *Ann R Coll Surg Eng* 35: 319-340, 1964.
9. Mahgoub ES: Medical management of mycetoma. *Bull WHO* 54: 303-310, 1976.

Cutaneous Nocardiosis

10. McClung NM: Isolation of *Nocardia asteroides* from soils. *Mycologia* 52: 154-156, 1961.
11. Mycrowitz RL: The Pathology of Opportunistic Infections with Pathogenetic, Diagnostic and Clinical Correlations. New York: Raven Press, 77-82, 1983.
12. Rippon W: The pathogenic fungi and the pathogenic actinomycetes In: Medical Mycology. Second edition, Philadelphia: W.B. Saunders, 51-67, 1988.
13. Satterwhite TK, Wallac RJ: Primary cutaneous nocardiosis. *JAMA* 242 (4): 333-336, 1979.
14. Smego RA, Gallis HA: the clinical spectrum of *Nocardia brasiliensis* infection in the United States. *Rev Infect Dis* 6 (2): 164-180, 1984.
15. Stevens DA: Clinical and clinical laboratory aspects of nocardial infection. *J Hyg Camb* 91: 377-383, 1934.
16. Vistica CA, Beaman BL: Pathogenic and virulence characterization of colonial mutants of *Nocardia asteroides* guh-2. *Can J Microbiol* 29: 1126-1135, 1983.
17. Wilkinson DS, et al: Textbook of Dermatology. Blackwell, 929-932, 1985.
18. Askari M, et al: Nocardiasis, first case report of its generalized form in Iran. *Journal of Tehran School of Medicine* 29 (6): 237, 1971.
19. The Geography of Endemic Diseases of Iran. Health College Publications and Health Research Institute 39, 1971.