

She had undergone an electromyography, which showed reduced motor conduction velocity, reduced compound motor action potential amplitudes and absent sensory nerve action potentials.

DISCUSSION

This disorder is a progressive sensorimotor neuropathy. The sympathetic autonomic dysfunction is considered the cause of the majority of the clinical manifestations^{4,5}:

- Episodes of dysautonomic crises, characterized by nausea, vomiting and symptoms of sympathetic storm (irritability, tachycardia, hypertension, facial flushing, bronchorrhea and diminished oral coordination leading to swallowing and speech dysfunction);
- Additional autonomic symptoms include orthostatic hypotension, excessive salivation, gastrointestinal motility dysfunction, bladder dysfunction, decreased or absent

tearing, pupil dilation, hypohidrosis, episodic hyperhidrosis and blotchy skin;

- Glomerulo sclerosis and chronic kidney disease unrelated to autonomic dysfunction;
- Neuropathic symptoms: loss of reflexes, hypotonia, decreased perception of pain and temperature;
- Additional clinical features: short stature, kyphoscoliosis, smooth tongue (no fungiform papillae), vomiting, recurrent aspiration, multiple skin scars, dysarthria, mental deficiencies, and emotional lability.

Linkage studies map to a candidate region on chromosome 9q31. Genetic evaluation is considered sensitive and specific for the diagnosis of HSAN3. Furthermore, it's the only specific diagnostic test currently available.

No particular treatment for familial dysautonomia has yet been described. Supportive care and symptomatic therapies are the main stay of management. The prognosis is poor.

References

1. Klebanoff MA, Neff JM. Familial dysautonomia associated with recurrent osteomyelitis in a non-Jewish girl. *J Pediatr* 1980; 96:75-77.
2. Levine SL, Manniello RL, Farrell PM. Familial dysautonomia: unusual presentation in an infant of non-Jewish ancestry. *J Pediatr* 1977; 90:79-81.
3. Mehta K. Familial dysautonomia in a Hindu boy. *Am J Dis Child* 1978;132:719.
4. Riley CM, Day RL. Central autonomic dysfunction with defective lacrimation; report of five cases. *Pediatrics* 1949;3:468-78.
5. Axelrod FB. Familial dysautonomia. *Muscle Nerve* 2004; 29:352-363.

Subcostal schwannoma in pregnancy

Schwannoma subcostal na gravidez

Júverson Alves Terra Júnior¹, Edmilson Rodrigo Daneze², Guilherme Azevedo Terra³, Renata Margarida Etchebehere⁴, Aldo Benjamim Rodrigues Barbosa⁵, Sílvia Azevedo Terra^{6*}

¹MD, Professor of Surgery, Department of Surgery, Federal University of Triângulo Mineiro (UFTM), Uberaba MG, Brazil;

²Veterinarian, Faculdade Doutor Francisco Maeda (FAFRAM/FE), Ituverava SP, Brazil;

³Medical Student, Department of Surgery, Federal University of Triângulo Mineiro (UFTM), Uberaba MG, Brazil;

⁴PhD, Professor of Pathology, Department of Pathology, Federal University of Triângulo Mineiro (UFTM), Uberaba MG, Brazil;

⁵MD, Radiologist, Department of Radiology, Santa Casa de Misericórdia de Ituverava, Ituverava SP, Brazil;

⁶PhD, Professor of Pathology, Department of Pathology, Federal University of Triângulo Mineiro (UFTM), Uberaba MG, Brazil.

*in memoriam.

Correspondence: Júverson Alves Terra Júnior; Department of Surgery, Federal University of Triângulo Mineiro (UFTM); Avenida Frei Paulino 30; 38025-180 Uberaba MG - Brasil; E-mail: juverson@terra.com.br

Conflict of interest: There is no conflict of interest to declare.

Received 04 May 2012; Received in final form 11 May 2012; Accepted 18 May 2012

The schwannoma is a supporting cells tumor of peripheral nervous system, characterized by the formation of grayish, firm, circumscribed and usually solitary masses, which is located close to the roots of cranial and spinal nerves. Most of them have a benign character¹.

CASE REPORT

A 27-year-old Caucasian female, with pregnancy at term, who was subjected to routine ultrasound, which observed the presence of hyperechoic lesion at the left hypochondrium

along the costal margin, in intimate contact with the abdominal wall. The surgical evaluation detected the presence of a hardened, fixed, painless lesion, which became more prominent after effort maneuver. Clinical follow-up was kept until delivery.

One month postpartum, the patient was submitted to computed tomography (CT) scan, which observed an hypodense lesion, closely related to the 20th left rib, measuring 8x4 cm, in close contact with the diaphragm (Fig 1A). After preoperative evaluation, left lombotomy was performed, which found the neoplasm related to the left subcostal nerve. The lesion was completely excised and submitted to anatomopathological analysis (Fig 1B). The patient recovered satisfactorily after the surgery.

DISCUSSION

Schwannoma is a rare neoplasm involving the spinal cord and its roots, being responsible for 27% of the spinal tumours. It can affect children and adults², usually between the third and fifth decades of life with equal incidence on both sexes³.

The pregnancy has no significant effect on the incidence and behaviour of gliomas. However, pregnancy appears to increase its growth. About 70% of gliomas have progesterone receptors and 30% have estrogen receptors. Unfortunately, there is lack of documented reports on accelerated cancer growth during pregnancy.

The occurrence of schwannomas during pregnancy rests on the hypothesis of a possible hormonal influence on the growth of a subset of Schwann cells, due to the presence of progesterone receptors. Progesterone levels increase during pregnancy, which may explain their accelerated growth.

Physiological changes during pregnancy may mask the symptoms, as clinical manifestations depend on the size of the mass and on its anatomical location⁴. Our patient did not report pain even after effort maneuver, which made the lesion prominent.

In symptomatic cases located in the chest wall, the most frequently reported symptoms are nonproductive cough, dyspnea, backache, and dysphagia, depending on the anatomic site involved³.

Clinical follow-up until delivery was chosen as the lesion had no apparent risks for the mother and for the fetus. Once malignancy is extremely rare in these neoplasms, surgical excision is indicated. There was no indication of radiotherapy, due to the neoplasm slow growth rate and its nonresponse to this treatment, besides the possibility of miscarriage and birth defects.

The anatomopathological analysis related hardened consistency lesion, fixed, limited and well-defined, with cystic formation and content with mucous aspect (Fig 1B).

The histopathological analysis observed two characteristic growth patterns, with fusiform tumoral cells arranged in palisades, forming the Verocay bodies^{1,3}, with elongated cell shape and regular oval nuclei, both positive for S-100 protein on the immunohistochemical.

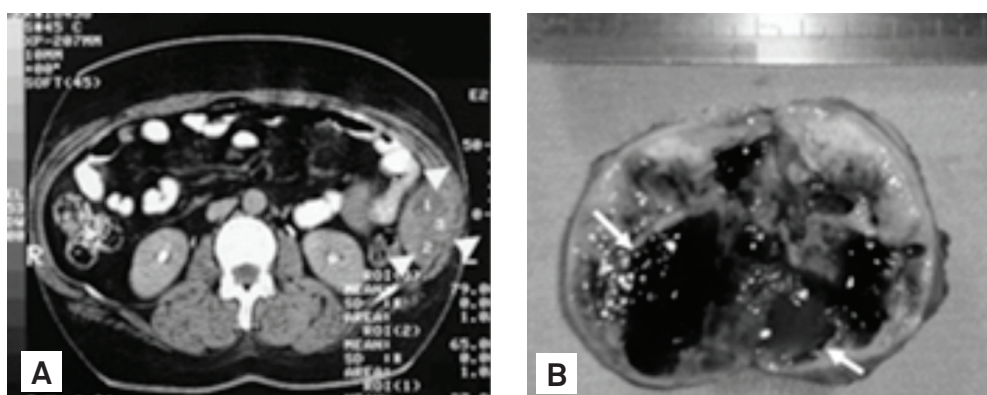


Fig1. Subcostal schwannoma. (A) Computed tomography scan slice showing oval lesion (arrowheads) with definite and regular edges with broad base in the abdominal wall of the left flank; (B) The cut surface containing cystic areas with mucous content (arrows).

References

1. Rodriguez CA, Munhoz AHN, Zampier JA, Silva APG, Fustes OH. Schwannoma benigno do nervo intercostal simulando neoplasia de pulmão. *Arq Neuropsiquiatr* 2004;62:1100-1103.
2. McClenathan JH, Bloom RJ. Peripheral tumors of the intercostal nerves. *Ann ThoracSurg* 2004;78:713-714.
3. Henn LA, Gonzaga RV, Crestani J, Cerski MR. Schwannoma intercostal simulando neoplasia pulmonar. *Rev Ass Med Brasil* 1998;44:146-148.
4. Sakuray H, Hada M, Mitsui T, Ashizawa I. Extratoracic neurilenoma of the lateral chest wall mimicking a subcutaneous tumor: report of a case. *Ann Thoracic Cardiovasc Surg* 2006;12:133-136.