



**Case Report**

**Successful Outcomes of Severe COVID-19 in Patient with Chronic Lymphocytic Leukemia: Diagnostic Challenges in Immunocompromised Hosts**

Alexandre E. Malek<sup>1\*</sup>, Cristina Gutierrez<sup>2\*</sup>, Victor E. Mulanovich<sup>1</sup>, Joshua Botdorf<sup>2</sup>, Roy F. Chemaly<sup>1</sup>, Shivan Shah<sup>1</sup>, Brandi M. McCall<sup>2</sup>, Judd T. Melancon<sup>2</sup>, Kelly K. McConn<sup>1</sup>, Jovan Borjan<sup>3</sup>, Issam I. Raad<sup>1</sup>, Jan A. Burger<sup>4</sup>, Guillermo Garcia-Manero<sup>4</sup> and Javier A. Adachi<sup>1</sup>.

<sup>1</sup> Department of Infectious Diseases, Infection Control and Employee Health. The University of Texas MD Anderson Cancer Center, 1515 Holcombe Blvd., Houston, TX 77030, USA.

<sup>2</sup> Department of Critical Care Department; The University of Texas MD Anderson Cancer Center, 1515 Holcombe Blvd., Houston, TX 77030, USA.

<sup>3</sup> Division of Pharmacy; The University of Texas MD Anderson Cancer Center, 1515 Holcombe Blvd., Houston, TX 77030, USA.

<sup>4</sup> Department of Leukemia; The University of Texas MD Anderson Cancer Center, 1515 Holcombe Blvd., Houston, TX 77030, USA.

\* Alexandre E. Malek and Cristina Gutierrez are first Co-authors.

**Competing interests:** The authors declare no conflict of Interest.

**Abstract.** The emergence and spread of 2019 novel coronavirus have led to an unprecedented public health crisis around the globe, threatening the lives of millions of people. We report a severe case of COVID-19 in a patient with chronic lymphocytic leukemia and describe primarily the clinical presentation and the challenges encountered in the COVID-19 diagnosis, treatment, and specimens sampling pitfalls. This case highlights the importance of a comprehensive diagnostic approach of pneumonia in immunocompromised hosts, including timely and safe bronchoscopy, because of the broad differential diagnosis, more challenging with the current outbreak of COVID-19.

**Keywords:** COVID-19; Chronic lymphocytic leukemia; Cancer patients; ARDS.

**Citation:** Malek A.E., Gutierrez C., Mulanovich V.E., Botdorf J., Chemaly R.F., Shah S., McCall B.M., Melancon J.T., McConn K.K., Borjan J., Raad I.I., Burger J.A., Garcia-Manero G., Adachi J.A. Successful Outcomes of Severe COVID-19 in Patient with Chronic Lymphocytic Leukemia: Diagnostic Challenges in Immunocompromised Hosts. *Mediterr J Hematol Infect Dis* 2020, 12(1): e2020044, DOI: <http://dx.doi.org/10.4084/MJHID.2020.044>

**Published:** July 1, 2020

**Received:** May 13, 2020

**Accepted:** June 15, 2020

This is an Open Access article distributed under the terms of the Creative Commons Attribution License (<https://creativecommons.org/licenses/by-nc/4.0>), which permits unrestricted use, distribution, and reproduction in any medium, provided the original work is properly cited.

Correspondence to: Javier A. Adachi. Department of Infectious Diseases, Infection Control and Employee Health; The University of Texas MD Anderson Cancer Center, 1515 Holcombe Blvd., Houston, TX 77030, USA. E-mail: [jaadachi@mdanderson.org](mailto:jaadachi@mdanderson.org)

**Introduction.** What began as a cluster of pneumonia cases in Wuhan, China, in December 2019 is now known as the worldwide pandemic of the novel coronavirus disease 2019, coined COVID-19.<sup>1</sup> The first case of COVID-19 in the United States was on January 20, 2020, and as of May 4, 2020, more than 3.6 million infections have been reported globally, accounting for a death toll of more than 252,000 persons.<sup>1,2</sup> This disease

is caused by the severe acute respiratory syndrome coronavirus 2 (SARS-CoV-2), and a subpopulation may present with extrapulmonary symptoms nausea, vomiting, abdominal pain and diarrhea,<sup>3</sup> leading to a potential delay in diagnosis.

While currently, around 15 million people are living with cancer,<sup>4</sup> little is known about the burden of COVID-19 in cancer patients who are at increased risk

of worse outcomes.<sup>5</sup> Here we present a case of severe COVID-19 in a patient with chronic lymphocytic leukemia (CLL) who initially evaded a timely diagnosis, but she successfully recovered after 17 days of intubation.

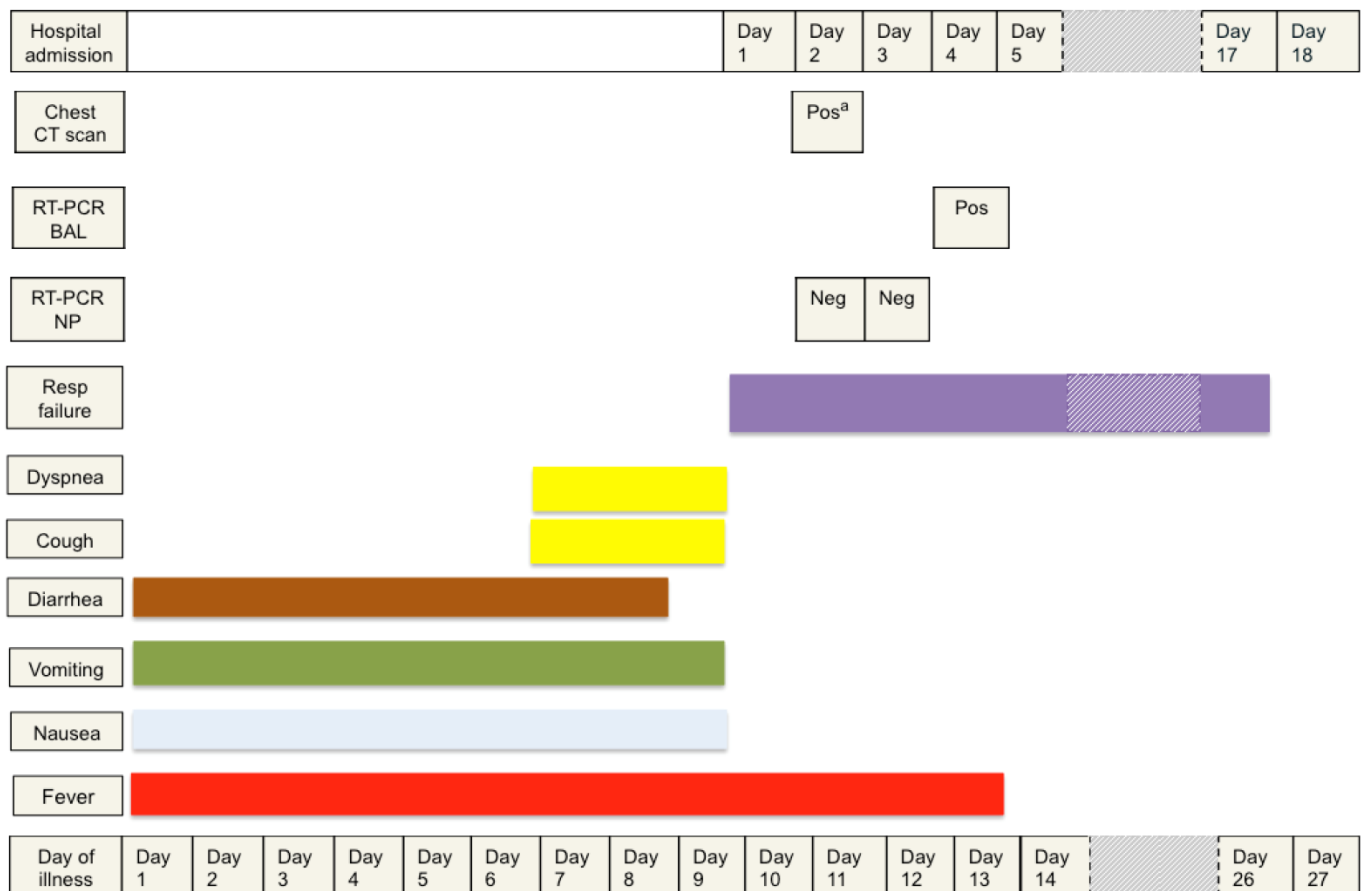
**Case Presentation.** A 41-year-old morbidly obese female with a diagnosis of B-cell type CLL, RAI stage 0, with 13q deletion and mutated immunoglobulin heavy chain, on active surveillance without chemotherapy, presented to an urgent care facility for four days of nausea, vomiting, and diarrhea with a low-grade fever of 100.8 °F (38.2 °C). She was treated with intravenous (IV) fluids and anti-emetics and discharged home with the presumptive diagnosis of acute gastroenteritis. Over the following week, her gastrointestinal (GI) symptoms improved but did not resolve fully.

Ten days after symptoms onset, she presented to the Emergency Department (ED) with two days of dry cough, shortness of breath, myalgias, and persistent fevers of 102 °F (38.9°C). The signs and symptoms are outlined in **Figure 1**. She denied recent international or domestic travel or contact with known or suspected COVID-19 cases. In the ED, she was hypoxic with SpO2 85% on 6 L/min nasal cannula. She was placed on a non-rebreather mask (15 L/min of oxygen) and was

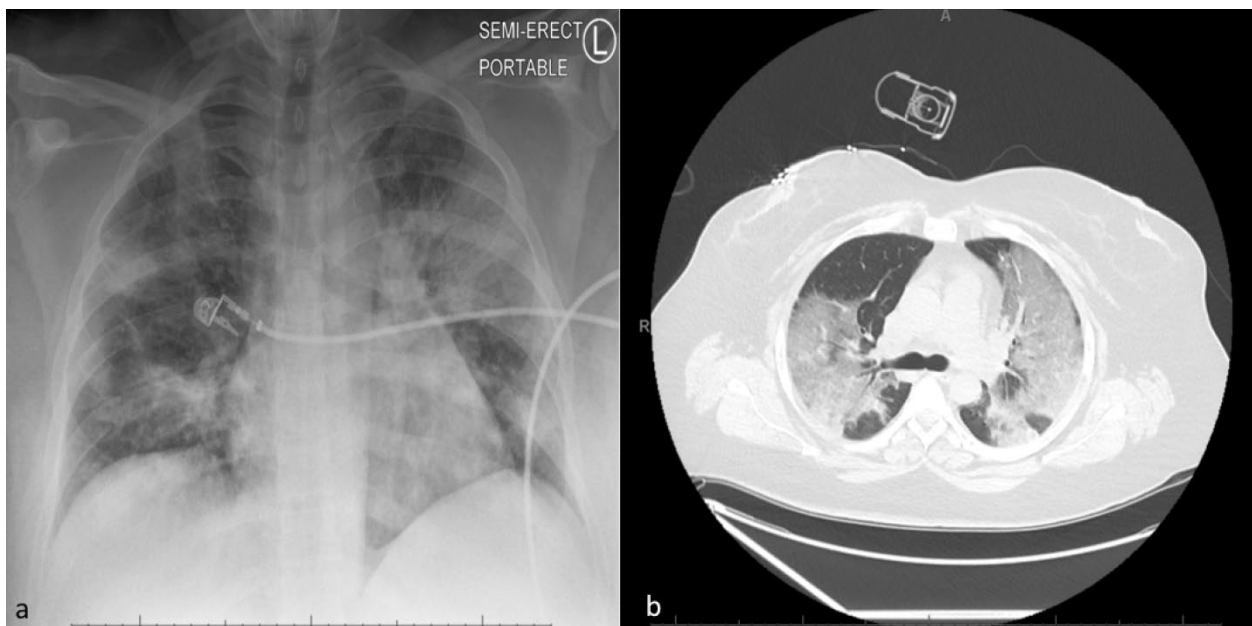
later electively intubated and placed on mechanical ventilation with a lung-protective strategy. Empiric therapy with cefepime 2 g IV Q 12 hours, linezolid 600 mg IV Q 12h and doxycycline were initiated. A posteroanterior chest radiograph showed bilateral diffuse lung opacities (**Figure 2, panel a**).

Her laboratory studies were notable for: white blood cell count 11,700 /µl with 61% neutrophils and 35% lymphocytes, a relative lymphocytopenia in the setting of CLL. Troponin level <6 ng/L and total immunoglobulin G, 839 mg/dL. The remaining laboratory results are summarized in **Table 1**. A nasopharyngeal (NP) swab specimen was negative for common respiratory viruses. This specimen was collected in accordance with the Centers for Disease Control and Prevention and was negative for reverse transcriptase (rRT)-polymerase-chain-reaction (PCR) for SARS-CoV-2.

A chest computed tomography (CT) scan was performed on hospital day (HD) 2 and showed bilobar multi-segmental ground-glass opacities (GGO) located both centrally and peripherally (**Figure 2, panel b**). Despite negative testing, COVID-19 pneumonia was highly suspected. A second NP swab specimen for SARS-CoV-2 was performed and reported negative. Blood cultures, serum *Aspergillus* antigen, βeta-(1,3)-d-



**Figure 1:** Symptoms, signs, PCR testing, chest computed tomography scan imaging according to day of illness and day of hospitalization. Abbreviation: BAL: bronchoalveolar lavage; CT: computed tomography; Pos: positive; NP: nasopharyngeal; Neg: negative; RT-PCR: reverse transcriptase-polymerase chain reaction. <sup>a</sup>Typical features of COVID-19, including peripheral, bilateral ground-glass opacities with visible intralobular lines (crazy-paving), and consolidation.



**Figure 2. Panel a:** Posteroanterior chest radiograph, (illness day 10, hospital day 1), showing bilateral lungs opacities and infiltrates. **Panel b:** A chest computed tomography scan, (illness day 11, hospital day 2), revealing a bilateral multi-segmental ground glass and consolidative opacities (centrally and mainly peripherally).

glucan, and urine legionella antigen were all negative.

In view of the second negative COVID testing, and the patient's risk factors for opportunistic infections, a bronchoscopy with bronchoalveolar lavage (BAL) was performed. Precautions to avoid generating aerosolized particles were taken, such as the use of personal protective aerosolized equipment (PAPR) and paralyzing the patient during the procedure. The BAL specimen was negative for aspergillus antigen, *pneumocystis jirovecii* PCR, cytomegalovirus PCR, bacterial and fungal cultures. However, the BAL rRT-PCR for SARS-CoV-2 was positive on HD 4. The treatment was transitioned to hydroxychloroquine 400 mg twice daily for two doses, then 200 mg twice daily combined with azithromycin 500 mg first dose, then 250 mg once daily for a total of 5 days. Additionally, two doses of tocilizumab of 8 mg/kg every 12 hours were administered on HD 4 with one infusion of immunoglobulins (30 g). The patient developed acute respiratory distress syndrome (ARDS), and she was dependent on mechanical ventilation thereafter. On HD12, a short course of high dose intravenous methylprednisolone 1 mg/kg per day was administered and which resulted in a gradual improvement of the patient's respiratory status. Five days after the initiation of corticosteroids (HD17), the patient was successfully extubated. Before discharge, a repeat SARS-CoV-2 PCR from NP specimen remained negative. She responded well to skilled occupational therapy exercises and, on HD 28, she was discharged home on room air, with stable conditions, and without sequelae. After one month of discharge, serologic testing for COVID-19 (Viracor Eurofins) showed positive IgG, 56.6 Units (normal range,  $\leq 9.0$  Units).

**Discussion.** To our knowledge, this is a unique case of severe COVID-19 in a patient with CLL that illustrates several aspects of this novel infection that are not yet fully understood, and the PCR testing including specimen collection as sensitivity and specificity of the test may vary in accordance to affected organs. Of note, four cases of mild COVID-19 cases in CLL patients have been reported,<sup>6</sup> and no standardized COVID-19 treatment in patients with hematological malignancies is available.

Our patient initially reported GI symptoms in the absence of respiratory symptoms, which did not develop until a week into the illness. The GI manifestations of COVID-19 have been described in 2 to 10% in cases series and an observational study (N=1099) reported the presence of nausea or vomiting (5.0%) and diarrhea (3.8%) in infected patients.<sup>7</sup> However, other studies showed that up to 11% of patients had on admission at least one GI symptom, and around 50% of patients developed GI symptoms during the hospitalization.<sup>8,9</sup> Early nonspecific symptoms of COVID-19 can lead to diagnostic difficulty in distinguishing between other common infectious diseases.

The SARS-CoV-2 has been detected in nasopharyngeal, oropharyngeal, sputum, and BAL specimens in COVID-19. BAL samples are the most accurate but involve dedicated personnel and invasive procedures for the collection.<sup>10</sup> NP swab is the recommended test for suspected COVID-19 as it is safe and well-tolerated by patients.<sup>11-13</sup> However, false negatives (20-40% in NP swab) can occur due to viral load variability throughout stages of the disease, or due to poor technique and this could result in missed diagnosis.<sup>13-16</sup> The positivity of PCR varies depending

**Table 1.** Clinical Laboratory Results.

Parameters	Reference Range	One month prior of illness	Illness Day 4 Urgent Care visit	Illness Day 10 Hospital Day 1	Illness Day 12 Hospital Day 3	Illness Day 14 Hospital Day 5	Illness Day 15 Hospital Day 6	Illness Day 27 Hospital Day 18
White-cell count (per ul)	3800-11,000	25400	12800	11700	8700	11900	26200	371000
Absolute neutrophil count (per ul)	1900-7400	7620	4990	7200	4970	6610	8650	9650
Absolute lymphocyte count (per ul)	1000-3900	16,260	7300	4160	3350	4670	15,200	24490
Platelet count (per ul)	150,000-400,000	240,000	161,000	231,000	188,000	242,000	376,000	268,000
Hematocrit (%)	39.0-50.0	38.4	41.5	34.9	27.4	27.6	29.6	34.0
Sodium (mmol/liter)	136-145	139	136	130	136	138	135	137
Carbon dioxide (mmol/liter)	20-31	27	21	22	22	21	22	29
Blood urea nitrogen (mg/dl)	6-23	12	11	10	4	10	13	22
Creatinine (mg/dl)	0.51-0.95	0.69	0.87	0.92	0.52	0.48	0.45	0.36
Alanine aminotransferase (U/L)	10-49	25	42	64	36	25	28	35
Aspartate aminotransferase (U/L)	<33	15	26	96	33	25	36	20
Alkaline phosphatase (U/L)	35-104	91	95	60	45	56	79	50
Total bilirubin (mg/dl)	<=1.2	0.4	0.3	0.9	0.6	0.3	0.3	1.0
Albumin (g/dl)	3.5-5.2	4.4	4.2	3.4	2.5	2.4	2.7	3.8
C-reactive protein mg/l	<3	-	-	143	172	204	177	0.41
Procalcitonin (ng/ml)	<0.05	-	-	0.56	-	-	-	0.06
Fibrinogen (mg/dl)	214-503	-	-	743	615	766	816	211
D-Dimer (mcg/ml)	0.10-0.50	-	-	0.85	0.77	-	1.7	1.92
Lactate dehydrogenase (U/L)	135-214	171	-	646	461	424	440	347
Prothrombin time (sec)	12.2-14.6	-	-	14.7	16.4	16.3	15.6	15.0
International normalized ratio	0.9-1.1	-	-	1.18	1.36	1.35	1.23	1.20
Creatinine kinase (U/L)	20-180	-	-	219	-	-	-	-
Ferritin (ng/mL)	13-150	-	-	1,101	663	596	705	189
Interleukin-6 (pg/ml)	0-5	-	-	-	122	60	366	64

on the specimens, with higher positive rates on BAL (93%) and sputum (72%) when compared to nasopharyngeal swabs (63%).<sup>10</sup> Despite these findings, in suspected COVID-19 cases, the use of bronchoscopy has been limited, and not recommended routinely, due to the risk it poses to medical staff.<sup>17,18</sup> However, in immunocompromised patients, the diagnosis of COVID-19 can be obscured by other etiologies such as CMV and PJP pneumonia. In such cases, protocols within the institutions on how to perform bronchoscopies safely should be in place; some considerations might include performing BAL immediately after endotracheal intubation. Moreover, as evidenced in this case, highly suspected COVID-19 cases should lead to discussions to safely pursue a diagnosis while also being able to rule out other common causes of respiratory failure in cancer patients.

A chest CT scan has a high sensitivity for COVID-

19 and may be considered as a primary tool for COVID-19 detection in highly epidemic areas.<sup>19</sup> Given the lack of clear data regarding the sensitivity of rRT-PCR NP swab in patients with GI manifestations early on in the disease, further study is needed to assess the impact of early chest CT scan on COVID-19-related outcomes.

**Conclusions.** This case highlights the importance of clinicians relying on indirect markers of COVID-19, such as characteristic clinical, radiographic and laboratory findings in patients seeking medical care. Improved understanding of the variety of clinical manifestation is critical for prompting appropriate specimen collection, timely diagnosis, and treatment initiation. It remains uncertain whether the combination of anti-IL-6, corticosteroids, and immunoglobulins could work synergistically in patients with chronic lymphocytic leukemia with severe COVID-19 and

ARDS. Further studies are needed to define the optimal treatment of COVID-19 in cancer patients as early

treatment will likely prevent further complications and improve outcomes.

## References:

1. [https://www.who.int/docs/default-source/coronaviruse/situation-reports/20200414-sitrep-85-covid-19.pdf?sfvrsn=7b8629bb\\_4](https://www.who.int/docs/default-source/coronaviruse/situation-reports/20200414-sitrep-85-covid-19.pdf?sfvrsn=7b8629bb_4)
2. Holshue ML, DeBolt C, Lindquist S, Lofy KH, Wiesman J, Bruce H, et al. First case of 2019 novel coronavirus in the United States. *N Engl J Med*. 2020; <https://doi.org/10.1056/NEJMoa2001191> PMID:32004427 PMCid:PMC7092802
3. Gu J, Han B, Wang J. COVID-19: Gastrointestinal manifestations and potential fecal-oral transmission. *Gastroenterology*. 2020; <https://doi.org/10.1053/j.gastro.2020.02.054> PMID:32142785 PMCid:PMC7130192
4. Howlader N, Noone AM, Krapcho M, Miller D, Brest A, Yu M, Ruhl J, Tatalovich Z, Mariotto A, Lewis DR, Chen HS, Feuer EJ, Cronin KA (eds). SEER Cancer Statistics Review, 1975-2016, National Cancer Institute. Bethesda, [https://seer.cancer.gov/csr/1975\\_2\\_A\\_2019](https://seer.cancer.gov/csr/1975_2_A_2019). No Title.
5. Liang W, Guan W, Chen W, Chen R, Wang W, Li J, Xu K, et al. Cancer patients in SARS-CoV-2 infection: a nationwide analysis in China. *The Lancet Oncology*. 2020. [https://doi.org/10.1016/S1470-2045\(20\)30096-6](https://doi.org/10.1016/S1470-2045(20)30096-6)
6. Baumann T, Delgado J, Montserrat E. CLL and COVID-19 at the Hospital Clinic of Barcelona: an interim report. *Leukemia*. 2020; <https://doi.org/10.1038/s41375-020-0870-5> PMID:32433507 PMCid:PMC7237061
7. W.-J. G, Z.-Y. N, Y. H, W.-H. L, C.-Q. O, J.-X. H, et al. Clinical Characteristics of Coronavirus Disease 2019 in China. *N Engl J Med*. 2020;
8. Lin L, Jiang X, Zhang Z, Huang S, Zhang Z, Fang Z, et al. Gastrointestinal symptoms of 95 cases with SARS-CoV-2 infection. *Gut*. 2020; <https://doi.org/10.1136/gutjnl-2020-321013> PMID:32241899
9. Jin X, Lian JS, Hu JH, Gao J, Zheng L, Zhang YM, et al. Epidemiological, clinical and virological characteristics of 74 cases of coronavirus-infected disease 2019 (COVID-19) with gastrointestinal symptoms. *Gut*. 2020;
10. Wang W, Xu Y, Gao R, Lu R, Han K, Wu G, et al. Detection of SARS-CoV-2 in Different Types of Clinical Specimens. *JAMA - Journal of the American Medical Association*. 2020. <https://doi.org/10.1001/jama.2020.3786>
11. <https://www.cdc.gov/coronavirus/2019-nCoV/lab/guidelines-clinical-specimens.html>
12. Wang D, Hu B, Hu C, Zhu F, Liu X, Zhang J, et al. Clinical Characteristics of 138 Hospitalized Patients with 2019 Novel Coronavirus-Infected Pneumonia in Wuhan, China. *JAMA - J Am Med Assoc*. 2020; <https://doi.org/10.1001/jama.2020.1585> PMID:32031570 PMCid:PMC7042881
13. Yu F, Yan L, Wang N, Yang S, Wang L, Tang Y, et al. Quantitative Detection and Viral Load Analysis of SARS-CoV-2 in Infected Patients. *Clin Infect Dis*. 2020; <https://doi.org/10.1093/cid/ciaa345> PMID:32221523 PMCid:PMC7184442
14. Long C, Xu H, Shen Q, Zhang X, Fan B, Wang C et al. Diagnosis of the Coronavirus disease (COVID-19): rRT-PCR or CT? *Eur J Radiol*. 2020;25:126. <https://doi.org/10.1016/j.ejrad.2020.108961> PMID:32229322 PMCid:PMC7102545
15. Li Y, Yao L, Li J, Chen L, Song Y, Cai Z, et al. Stability Issues of RT-PCR Testing of SARS-CoV-2 for Hospitalized Patients Clinically Diagnosed with COVID-19. *J Med Virol*. 2020; <https://doi.org/10.1002/jmv.25786> PMID:32219885 PMCid:PMC7228231
16. Li D, Wang D, Dong J, Wang N, Huang H, Xu H, et al. False-negative results of real-time reverse-transcriptase polymerase chain reaction for severe acute respiratory syndrome coronavirus 2: Role of deep-learning-based ct diagnosis and insights from two cases. *Korean J Radiol*. 2020; <https://doi.org/10.3348/kjr.2020.0146> PMID:32174053 PMCid:PMC7082661
17. Bouadma L, Lescure FX, Lucet JC, Yazdanpanah Y, Timsit JF. Severe SARS-CoV-2 infections: practical considerations and management strategy for intensivists. *Intensive Care Med*. 2020; <https://doi.org/10.1007/s00134-020-05967-x> PMID:32103284 PMCid:PMC7079839
18. Wahidi MM, Lamb C, Murgu S, Musani A, Shojaaee S, Sachdeva A, et al. American Association for Bronchology and Interventional Pulmonology (AABIP) Statement on the Use of Bronchoscopy and Respiratory Specimen Collection in Patients with Suspected or Confirmed COVID-19 Infection. *J Bronchology Interv Pulmonol*. 2020; <https://doi.org/10.1097/LBR.0000000000000681> PMID:32195687 PMCid:PMC7141581
19. Ai T, Yang Z, Hou H, Zhan C, Chen C, Lv W, et al. Correlation of Chest CT and RT-PCR Testing in Coronavirus Disease 2019 (COVID-19) in China: A Report of 1014 Cases. *Radiology*. 2020; <https://doi.org/10.1148/radiol.2020200642> PMID:32101510 PMCid:PMC7233399