

Successful Xenografts of Second Trimester Human Fetal Brain and Retinal Tissue in the Anterior Chamber of the Eye of Adult Immunosuppressed Rats

Leon G. Epstein^{1,2,3}, Therese A. Cvetkovich², Eliot Lazar⁴, Ky Dehlinger¹, Kirk Dzenko¹, Coca del Cerro⁴ and Manuel del Cerro⁴

University of Rochester School of Medicine

*Departments of Neurology¹, Pediatrics², Microbiology and Immunology³, and Neurobiology and Anatomy⁴
Rochester NY, USA*

SUMMARY

Successful xenografting of first trimester human fetal CNS tissue and retina has been reported in the literature. We wished to test the feasibility of using the anterior chamber of the rat eye to support the development of more mature human fetal xenografts. Here we report on the successful outcome of human brain and retinal transplants. Adult host rats immunosuppressed with cyclosporin A accepted these xenografts and supported their further development. Periodic examination of the host eyes using a direct ophthalmoscope or an ophthalmic slit lamp permitted direct visual monitoring of the health and growth of the transplants. Histologically it was possible to identify neuronal, macroglial, and microglial (macrophage) cell types within the grafts. Mitotic activity and histogenetic differentiation took place. Blood vessels filled with hematic cells were commonly present within the grafts. The walls of these vessels prevented the leakage of horseradish peroxidase, suggesting the presence of a functional brain-blood barrier in the graft. These results indicate that it is possible to use a small animal model to study normal and

pathological phenomena on late fetal human neural tissues. Our group has already taken advantage of the model to achieve HIV infectivity of fetal human brain outside the human body.

INTRODUCTION

The use of the anterior chamber as a transplantation site was first attempted by van Dooremaal /1/, who in 1873 described experiments in which the rabbit anterior chamber was used to lodge cells from human labial mucosa and other rather unlikely explants. This technique preceded the advent of tissue culture methods and later served as an adjunct to other means of observing growth of explanted cells and tissues in an isolated setting /2/. Subsequent studies utilized explanted fetal retina in the study of retinal plasticity in this immune privileged site and found allo- and xeno-transplantation to be quite feasible /2-7/.

In addition, extensive research has been conducted in the area of syngeneic and xenogeneic grafting of CNS tissue, especially in the study of mechanisms of human brain development /8-11/. Olson *et al.* grafted several areas of 8-11 week gestation human fetal brain and spinal cord into the anterior chamber of nude mice, nude rats, and rats immunosuppressed with cyclosporin A /8/. Under these conditions, first trimester human cerebellar and cerebral cortex, and hippocampus and spinal cord xenografts appear to develop histologically according to a human time-table /9-11/.

Reprint address:

Manuel del Cerro, M.D.
University of Rochester
Department of Neurobiology and Anatomy
Box 603
601 Elmwood Avenue
Rochester, NY, USA

Among the objectives of our laboratories are to develop animal models for viral infections of human neural tissue and to obtain functional retinal transplants. To achieve these objectives, the use of late, more mature, fetal tissue is desirable. Herein we describe successful xenografts of second trimester human brain and retinal tissue into the rat anterior chamber.

METHODS

Host animals

The hosts for this study were 100-120 day old male Sprague-Dawley rats (Charles-River) of 200-350 gram body weight that were pathogen free. The animals were housed in sterilized microisolator cages in a cubicle used for these studies only. They were maintained on an immunosuppressive regime utilizing cyclosporin A. We determined that optimal results were obtained with a dose of 6 mg/kg i.m. one day prior to transplantation, followed by a maintenance dose of 5.0-6.0 mg/kg i.m. daily, adjusting the dose according to blood levels and serial weights. This resulted in cyclosporin A blood levels of 1000-1500 ng/ml using both monoclonal and polyclonal antibody detection assays.

Donor tissues

Procurement of fetal tissues from elective therapeutic abortions was in strict accordance with scientific and ethical guidelines of the NIH and the University of Rochester. Consent for the use of fetal tissues in research was obtained by the obstetrician from the mother, although specific research projects were not designated. The tissue used could not be identified by name, hence confidentiality was assured.

After vacuum extraction, the gestational age of the tissue was confirmed, using heel-to-toe measurements in comparison with standardized charts. Brain or retinal tissue from fetuses between 12 and 19 weeks gestation was used for

these studies. The number of animals that received transplanted tissue at each gestational age were distributed as follows: 12 weeks gestation (n = 24), 13 weeks gestation (n = 9), 14 weeks gestation (n = 11), 15 weeks gestation (n = 7), 17 weeks gestation (n = 16), and 19 weeks gestation (n = 10).

Large fragments of neural tissue were identified and collected in human plasma. The intact retina or brain regions of interest were separated under a dissecting microscope with the tissue submerged in fresh human plasma and mechanically dissociated into small (<0.5 mm³) fragments using curved iris scissors. The brain region routinely used was telencephalon, including both the ventricular and cortical surfaces, which includes proliferating neuronal and glial precursors (Fig. 1).

Surgical procedure

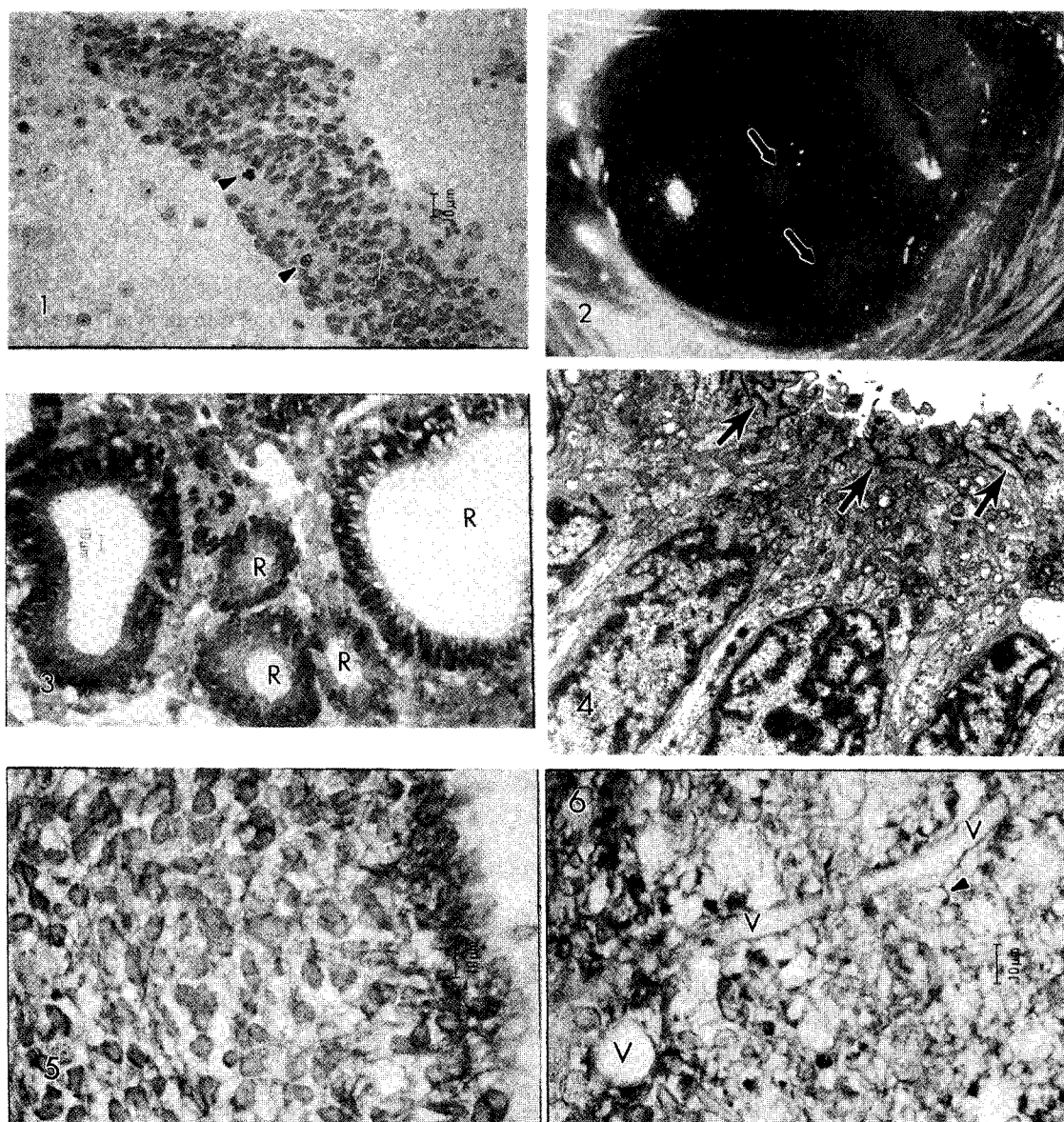
Small fragments of human fetal brain tissue were backloaded into a 50 μ l Hamilton syringe. Following general and topical anesthesia, 10 μ l of fetal tissue suspension was injected into the anterior chamber via a 27 gauge butterfly needle using direct observation under the dissecting microscope. Excess fluid was allowed to egress by partial removal of the injecting needle. The puncture sites were clean and self-sealing.

The progress of the transplants and the status of the eyes' anterior chambers were periodically monitored through the transparent cornea using direct ophthalmoscopy or under a stereomicroscope or slit lamp with photographs taken as necessary. All surgical procedures were carried out in accordance with the NIH Guide for the Care and Use of Animals in Research.

Histological and immunohistochemical studies

Animals were anesthetized with a lethal dose of pentobarbital at selected intervals after transplantation ranging from 2 to 35 days. Following enucleation, each eye containing a xenograft was fixed in either 4% paraformaldehyde for 2 hours

Abbreviations: Central nervous system, CNS; Horseradish peroxidase, HRP; Human Immunodeficiency Virus Type 1, (HIV-1); Acquired Immunodeficiency Syndrome, AIDS



- Fig. 1:** Light micrograph of 14.5 gestational weeks human telencephalon. The sample contains a cluster of subventricular cells, some of which are undergoing mitosis (arrowheads), the rest of the tissue is formed by more mature neural cells and an extensive neuropil.
- Fig. 2:** Macrophotograph of a rat eye bearing a 14.5 weeks gestational age human retinal xenograft 30 days post-transplantation. The graft has developed into two masses of tissue (arrows), one peripheral and one more centrally located. The central mass is connected to the dilated pupillary border by a thin tissue strand.
- Fig. 3:** Light micrograph of the retinal xenograft illustrated in Fig. 2. At 60 post-transplantation days, the graft has grown and differentiated into multiple rosettes (R). The photoreceptor cells forming the rosettes project immature inner segments into the lumina.
- Fig. 4:** Electron micrograph of the luminal surface of a rosette formed by a 14.5 week human retina. The closely packed immature photoreceptor cells have formed junctional complexes in their apical portions (arrows) similar to those present in the normal outer limiting membrane of the normal retina.
- Fig. 5:** Light micrograph of a section of 14.5 weeks gestational age human telencephalon reacted with an antibody to the neuronal marker PGP 9.5. At 7 post-transplantational days, numerous cell bodies and slender processes show a positive reaction.
- Fig. 6:** Light micrograph of the same explant as in Fig. 5 but reacted with antibody to the astroglial marker GFAP. A number of cells scattered throughout the tissue show positive reaction. In addition, there is a fine band of positive reacted cytoplasm around a small blood vessel (V). An arrowhead points to a stained cytoplasmic process abutting onto the vascular wall.

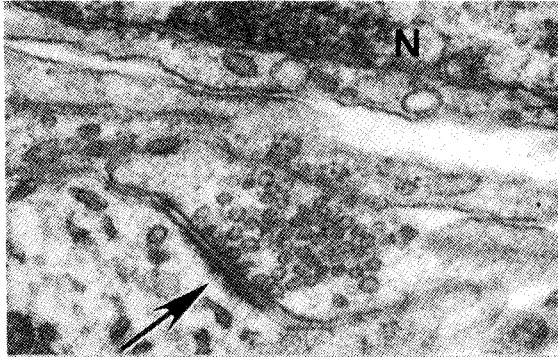


Fig. 7: Electron micrograph depicting an area of neuropil, and part of the body of a neuroblast in the upper right corner of the picture. A synaptic contact is indicated by the arrow. The nucleus of the neuroblast (N) is surrounded by a thin rim of cytoplasm. Human fetal brain xenograft, 12.5 weeks gestational age. Six days survival time. 49,000x.

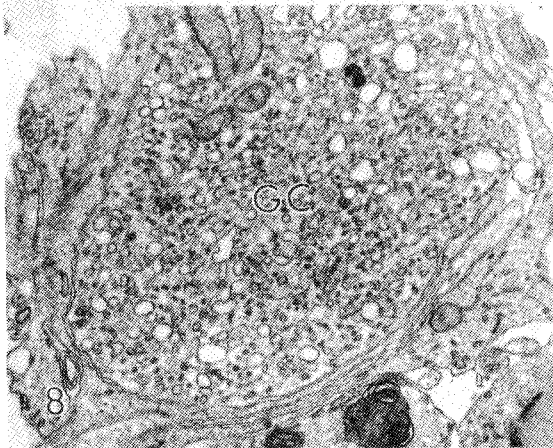


Fig. 8: Electron micrograph depicting a growth cone filled with vesicles and some mitochondria, and located in the neuropil of the same xenograft as in Fig. 7. 20,000 x.

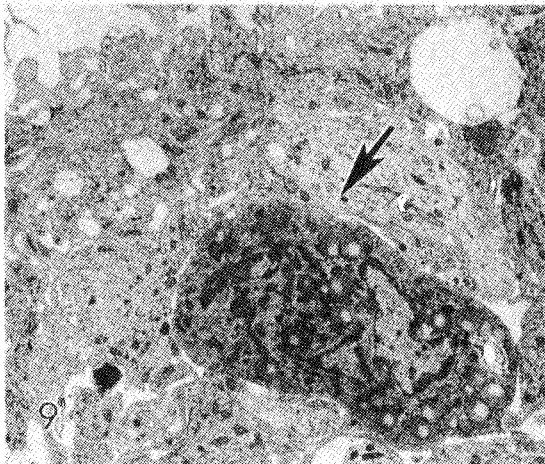


Fig. 9: A reactive macrophage (arrow) in the neuropil of the same specimen depicted in Figs. 7 and 8. The cell cytoplasm contains numerous secondary lysosomes. These cells appear to be the counterparts of the microglial elements identified under the light microscope. 5,700 x.

at 4°C for paraffin embedding, or in 2% glutaraldehyde in a 0.1 M cacodylate buffer (pH 7.2-7.4) for plastic embedding. Immunohistochemical studies were performed with avidin-biotin kits (Vector ABC) using modifications of the procedure of Hse *et al.* /12/. Primary antibodies used included anti-glial fibrillary acidic protein (bovine GFAP, DACO), and anti-PGP 9.5 (Ultraclone Limited) /13/ to identify astrocytes and neurons respectively. Biotinylated lectin *Ricinus communis* Agglutinin-1 (RCA-1-lectin, Vector) /14/, was used to identify microglia.

Horseradish peroxidase marker studies

To test whether vascularized xenografts develop an intact blood-brain barrier, two rats with xenografts established two weeks earlier were injected via the femoral vein with horseradish peroxidase (HRP, Sigma Type VI, 25 µg/100 g body weight) with minor modifications of the protocol of Hirano /15/. After 30 minutes, the animals were perfused with 2% paraformaldehyde/2% glutaraldehyde in a 0.1 M cacodylate buffer (pH 7.2-7.4). Tissue sections were treated with H₂O₂ and diamino-benzidine to expose the peroxidase marker, and prepared for ultrastructural examination as previously reported /2/.

RESULTS

Xenograft survival

The overall success rate in establishing viable xenografts into rat eyes was 82% (63/77). A successful xenograft was defined as such by the presence of a healthy appearing graft at one week post-transplantation. In all cases enucleation was performed while the animals harbored healthy transplants. The longest survival was 60 days. However, in many experiments, the animals were killed prior to this point to assess histogenetic development of the transplant. Grafts placed in animals without immunosuppression regressed after seven to ten days.

Bi-weekly ophthalmological examination revealed that healthy neural tissue grafts enlarged to form spherical or oblong masses, 1 to 2.5 mm in

size, with well defined limits and a characteristic pearlish white glow present on the surfaces (Fig. 2).

Light and electron microscopical observations

Light microscopical study of plastic embedded sections from grafted eyes confirmed and expanded the *in vivo* observations. Almost invariably the grafts grew attached to either the anterior iridal or the posterior corneal surfaces, with some larger grafts bridging both structures. Blood vessels were seen frequently. They appeared to be vascular outgrowths linking the graft to the host iridal vessels. The growth process continued within the grafts, as evidenced by the definite increase in total mass as well as by the presence of mitotic cells. The brain tissue grafts showed neuroblasts characterized by finely dispersed nuclear chromatin, one or two prominent nucleoli, and some cytoplasmic processes arising from the cell soma. A meshwork of these processes formed a neuropil separating neuronal cells from each other. Retinal grafts (Figs. 3 and 4) were characterized by the presence of conspicuous photoreceptor rosettes, with relatively large central lumina. Neural cells reminiscent of those in the inner nuclear layer of the normal retina were arranged outside the rosettes. Immunohistochemical studies identified PGP 9.5 positive neurons (Fig. 5) and GFAP positive astroglia (Fig. 6); also a few RCA-1 positive "microglia" cells were seen. It was usual to find an absence of inflammatory cells in the host anterior chamber, a finding in agreement with the clear ocular media observed during the *in vivo* examinations.

Electron microscopical analysis of the grafts revealed the presence of synaptic contacts (Fig. 7) and growth cones /16/ (Fig. 8). Presence of the latter offers a further suggestion that neurogenesis continues with the grafts. Ultrastructural identification of neuroblasts, or young neurons, with relatively large nuclei and scant cytoplasm was possible at this level (Fig. 7). Although astroglial cells and a discontinuous glial ensheathment of the blood vessels were seen under the light microscope, unambiguous identification of astroglial cell bodies was not possible. In contrast it was possible to identify the electron microscopical

correlates of active microglial cells in the form of macrophages containing abundant secondary lysosomes in their cytoplasm (Fig. 9).

Studies of the blood-graft barrier

After the injection of horseradish peroxidase, the tracer penetrated other tissues but not the vascularized xenograft, suggesting that a functional blood-brain barrier was formed within the transplanted human neural tissue (data not shown).

DISCUSSION

We have demonstrated that second trimester human fetal brain explants (12-19 weeks gestation) can survive in the anterior chamber of adult immunosuppressed rats. Other investigators have studied xenografts of first-trimester human CNS /8-11/ and retina, sometimes with post-transplantation survivals as long as 200 days /17/. However, little has been reported on transplantation of older human fetal neural tissue, and the consensus has been that these older explants fail to thrive. Further studies are needed to determine the reasons behind the successful outcome of our grafts. Nonetheless, it is of interest to compare the results obtained and to discuss the opportunities offered by explants of different gestational ages.

The first issue emerging from comparisons between the fate of first versus second trimester xenografts deals with tissue survival. The evidence available suggests that the general rule in neural transplantation that earlier fetal material fares better than its more developed counterparts may not be without exceptions. Comparison between the outcome of CNS xenografts of different ages, performed by different investigators, are hampered by possible variations in sample selection and handling. In the case of retinal grafts, however, it is possible to make closer correlations since the experimental differences tend to be narrower. Here the survival of second trimester samples appears to be at least as good as that seen with first trimester. Aramant *et al.* report survival of 28 out of 52 grafts, and only 6 of those surviving were deemed appropriate for extensive histological

evaluation /17/. Our retinal series has survived at a better rate, not only in the anterior chamber as reported here, but also in the subretinal space (del Cerro *et al.*, in preparation). A factor here may be the need for shorter survivals required to obtain similar maturational stages when the explant is obtained at a more advanced gestational age. An example of the ability to use shorter survivals is in the study of synaptic development and photoreceptor formation in retinal human xenografts, since these developmental events take place during mid-gestation /18/. A shorter host survival, in turn, represents an abbreviated exposure of the graft to possible deleterious effects of the immunosuppressive regimen. Both Aramant *et al.* and we have resorted to cyclosporin A treatment to prevent rejection of the xenografts. However, we have found that close monitoring of blood cyclosporin levels is essential to define the narrow gap between the induction of cyclosporin toxicity in the host on one hand, and insufficient immunosuppression leading to graft demise on the other. Prolonged survival of these xenografts required blood cyclosporin A levels in the range of 1000-1500 ng/ml, a level higher than previously suggested /19/. Bickford-Wimer *et al.* showed improved brain explant survivability in athymic nude rats over rats immunosuppressed with cyclosporin A /10/. It may be that the higher levels achieved via the parenteral route, with concomitant evidence of toxicity through close monitoring of cyclosporin A levels, allowed for better immunosuppression. A less than optimal host environment under these conditions may be one of the reasons for Aramant's *et al.*'s observation that in their series, grafts of the same total age (i.e., gestational age plus survival time) showed dissimilar maturation development. Furthermore, brain regions are more accurately identifiable when obtained from older specimens, and fetal tissue of ages 12-18 weeks are those most generally available for research. Finally, we expect to examine the issue of vulnerability of fetal brain to a viral infection which may occur only at late time points during gestation.

Study of the human CNS has always been difficult due to its inaccessibility. Studies of the viruses with tropism for the human CNS have been limited by the lack of a model in which intact human

neural tissue can be exposed to infectious virus, virus infected cells, or putative neurotoxic factors. Human immunodeficiency virus type 1 (HIV-1) in particular, is highly species specific, and is known to exhibit important biological differences when studied *in vitro* as compared to *in vivo* /20/. HIV-1 invades the CNS of children and adults and is thought to be responsible for the progressive encephalopathy /21, 22/, and for the underlying neuropathological changes observed in children with AIDS /23/. Transplantation of human CNS tissue into a small animal provides an excellent system in which to study normal development and pathological conditions. In addition, use of the anterior chamber offers a unique advantage in that survival and growth of the xenograft can be visually monitored without invasive procedures. Preliminary studies using this model have demonstrated that the grafts can be infected with cell free virus and HIV-1 laden macrophages /24/. Future investigations using these xenografts should prove useful in elucidating the pathogenesis of CNS infection with HIV-1 and other neurotropic viruses, particularly in the developing nervous system. Furthermore, this model may have a broader application for the screening of antiviral and other therapeutic agents which target the CNS.

A corollary of the previous discussion is that second-trimester xenografts in the anterior chamber may prove to be the optimal model for the study of anatomical, physiological, and pathological phenomena associated with more advanced human gestation stages.



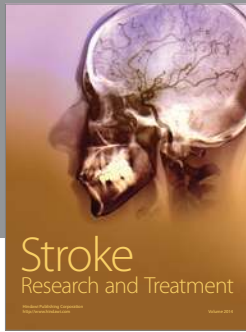

ACKNOWLEDGEMENTS

These studies were supported by PHS grants EY 09217, and A132305. Some of the instrumentation used in this work was acquired through private gifts to the laboratory of Dr. del Cerro. We thank Mary Morgenstern and Robert White for exceptional technical expertise and Corrinne Garland for assistance in preparing the manuscript.

REFERENCES

1. van Dooremaal JC. De ontwikkeling van levende veefsels op vreemden boden geent. *Onderz physiol Lab Rijksuniv. Utrechtsche Loogeschool 1873*; 3: 277-290.
2. del Cerro M. Retinal transplants. In: Osborne N, Chader J, eds, *Progress in Retinal Research*. Vol. 9. Oxford: Pergamon Press, 1989; 230-272.
3. Royo PE, Quay WB. Retinal transplantation from fetal to maternal mammalian eye. *Growth 1959*; 23: 313-336.
4. del Cerro M, Gash DM, Rao GN, Notter MF, Weigand SJ, Gupta M. Intraocular retinal transplants. *Invest Ophthalmol Vis Sci 1984*; 25: 62 (abstr.).
5. del Cerro M, Gash DM, Rao GN, Notter MF, Weigand SJ, Gupta M. Intraocular retinal transplants. *Invest Ophthalmol Vis Sci 1985*; 26: 1182-1185.
6. del Cerro M, Gash DM, Rao GN, Notter MF, Wiegand SJ, Sathi S, del Cerro C. Retinal transplants into the anterior chamber of the rat eye. *Neuroscience 1987*; 21: 707-724.
7. Medawar PB. Immunity to homologous grafted skin. III. The fate of skin homografts transplanted to the brain, to subcutaneous tissue, and to the anterior chamber of the eye. *Br J Exp Pathol 1984*; 29: 58-69.
8. Olson L, Stromberg I, Bygdeman M, Henschen A, Hoffer B, Granholm L, Almqvist P, Dahl D, Oertel W, Seiger A. Human fetal cortices and spinal cord transplanted to the anterior chamber of immunodeficient nude rats: Immunohistochemical studies. *Prog Brain Res 1988*; 78: 583-590.
9. Henschen AF, Stromberg I, Bygdeman M, Dahl D, Hoffer B, Seiger A, Olson I. Human fetal spinal cord xenografts survive in the eye of athymic nude rat hosts. *Exp Brain Res 1989*; 75(2): 317-326.
10. Bickford-Wimer P, Granholm AC, Bygdeman M, Hoffer B, Olson L, Seiger A, Stromberg I. Human fetal cerebellar and cortical tissue transplanted to the anterior eye chamber of athymic rats: Electrophysiological and structural studies. *Proc Natl Acad Sci USA 1987*; 84(16): 5957-5961.
11. Granholm A-C, Eriksdotter-Nilsson M, Stromberg I, Steig P, Seiger A, Bygdeman M, Geffard M, Oertel W, Dahl D, Olsen L, Hoffer B, Freedman R. Morphological and electrophysiological studies of human hippocampal transplants in the anterior eye chamber of athymic nude rats. *Exp Neurol 1989*; 104: 162-171.
12. Hsu S-M, Raine L, Fanger H. A comparative study of the peroxidase-antiperoxidase method and an avidin-biotin complex method for studying polypeptide hormones with radioimmuno-assay antibodies. *Am J Clin Pathol 1981*; 75: 734-738.
13. Kent C, Clark P. The immunolocalisation of the neuroendovine specific protein PG P9 during neurogenesis in the rat. *Dev Brain Res 1991*; 58: 147-150.
14. Mannoji H, Yeger H, Becker LE. A specific histochemical marker (lectin *Ricinus communis* agglutinin-1) for normal human microglia, and application to

- routine histopathology. *Acta Neuropathologica* 1986; 71: 341-343.
15. Hirano A, Dembitzer HM, Becker NH, Levine S, Zimmerman HM. Fine structural alterations of the blood-brain barrier in experimental allergic encephalomyelitis. *J Neuropath Exp Neurol* 1970; 29: 432-440.
 16. del Cerro M, Snider RS. Studies in the developing cerebellum. Ultrastructure of growth cones. *J Comp Neurol* 1968; 133: 341-362.
 17. Aramant RM, Seiler B, Ehinger A, Bergstrom B, Gustavi R, Brundin AR, Adolf. Transplantation of human embryonic retina to adult retina. *Restorat Neurol Neurosci* 1990; 2: 9-22.
 18. Spira AW, Hollenberg MJ. Human retinal development: Ultrastructure of the inner retinal layers. *Dev Biol* 1973; 31: 1-21.
 19. Leimenstoll G, Jessen H, Engemann R, Neidermayer W. Cyclosporin A blood levels in rats after different modes of administration. In: Theide A, ed, *Microsurgical Models in Rats for Transplantation Research*. Berlin - Heidelberg: Springer-Verlag, 1985; 291-294.
 20. Narayan O, Clements JE. Biology and pathogenesis of lentiviruses. *J Gen Virol* 1989; 70: 1617-1639.
 21. Epstein LG, Sharer LR, Oleske JM, et al. Neurologic manifestation of HIV infection in children. *Pediatrics* 1986; 78: 678-687.
 22. Michaels J, Sharer LR, Epstein LG. Human immunodeficiency virus type-1 (HIV-1) infection of the nervous system: A review. *Immunodeficiency Rev* 1988; 1: 71-104.
 23. Sharer LR, Epstein LG, Cho E-S, et al. Pathologic features of AIDS encephalopathy in children: Evidence for LAV/HTLV-III infection of brain. *Hum Pathol* 1986; 17: 271-284.
 24. Cvetkovich TA, Lazar E, Blumberg BM, Saito Y, Eskin TA, Reichman R, Baram DA, del Cerro C, Gendelman HE, del Cerro M, Epstein LG. Human Immunodeficiency Virus Type 1 (HIV-1) infection of neural xenografts. *Proc Natl Acad Sci USA* 1992; 11: 5162-5166.



Hindawi

Submit your manuscripts at
<http://www.hindawi.com>

