

Sudden neck movement and cervical artery dissection

John W. Norris, Vadim Beletsky, Zurab G. Nadareishvili, on behalf of the Canadian Stroke Consortium

Two recent deaths from artery dissection following neck manipulation by chiropractors have focused media and medical attention on the relation between sudden neck movement and cervical artery dissection. Although the first case of carotid artery dissection due to chiropractic neck manipulation was described over 50 years ago,¹ the frequency of carotid and vertebral artery dissection as a cause of stroke has only been recognized in the last decade. Since then, there have been many publications and case reports on this topic. In a recent Canadian survey, dissection of the cervical arteries was one of the most common causes of stroke in patients less than 45 years of age.²

During the past year the Canadian Stroke Consortium, a national network of stroke physicians, has been prospectively collecting detailed information on cases of dissection of the cervical arteries. Seventy-four patients have been studied so far: their age range was 16–87 years (mean 44 years), 60% were male, and there was a predominance of vertebrobasilar artery dissections compared with carotid artery dissections (72% v. 28%). Most (81%) of the dissections were associated with sudden neck movement, ranging from therapeutic neck manipulation to a vigorous game of volleyball, but some occurred during mild exertion such as lifting a pet dog or during a bout of coughing.

The vertebral artery is extremely vulnerable to torsion

injury because it winds around the atlas to enter the skull: any abrupt rotation may stretch the artery and tear the delicate intima. Thrombosis formed over this vascular injury may subsequently be dislodged and may embolize to the brain. This is probably the most frequent cause of stroke in these patients and produces a characteristic angiographic appearance sometimes with “false” aneurysms (Fig. 1).³ Less frequently, the vessel may be occluded by a collar of hematoma forming in the vessel wall at the site of the dissection.

Angiographic evidence of injury to the vertebral artery is nearly always at the C1–2 level. The carotid artery, lying freely in the soft tissues of the neck, is more mobile and less vulnerable but is tethered adjacent to C2, so that dissections may occur 1–2 cm distal to the bifurcation (Fig. 2). This is in contrast to the site of atherosclerotic lesions, which are most frequently close to the origin of the internal carotid artery.

The resulting stroke follows the typical clinical pattern of its arterial territory: carotid artery dissections cause hemiparesis, hemisensory loss and other cerebral hemispheric features such as aphasia, whereas vertebrobasilar artery dissections may result in ataxia and quadriparesis. However, sudden and often severe neck or occipital pain is the hallmark of dissection (in 74% of our cases), and its on-

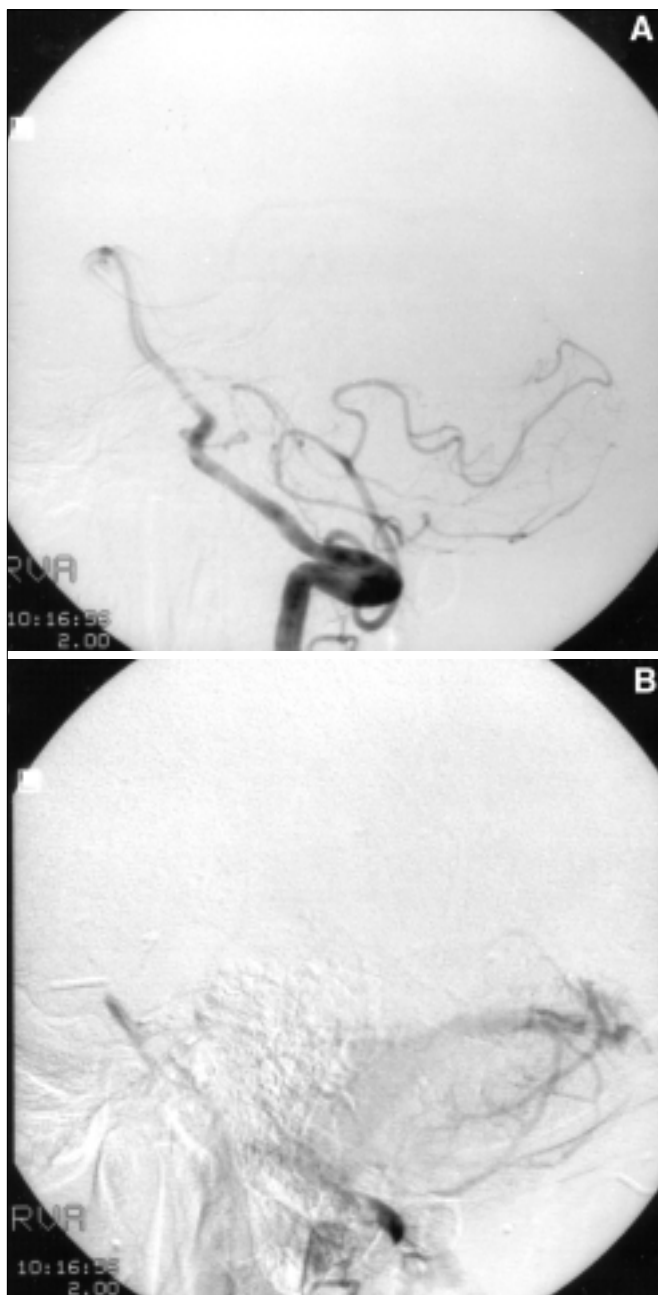


Fig. 1: Angiograms showing traumatic dissection of right vertebral artery at C1 level (A) following fall with hyperextension of head. Contrast is still visible in pseudoaneurysm (B), which remains potential source of embolism.

set is a useful index of the actual moment of dissection. Horner's syndrome ipsilateral to the carotid lesion occurred frequently in our series (in 25% of cases) owing to the local involvement of sympathetic nerves around the carotid artery. This is sometimes the only sign that dissection has occurred; in many cases, dissections may go unnoticed and presumably resolve spontaneously.⁴

There is a broad spectrum of injuries responsible for artery dissections. Direct trauma to the neck, as in injuries

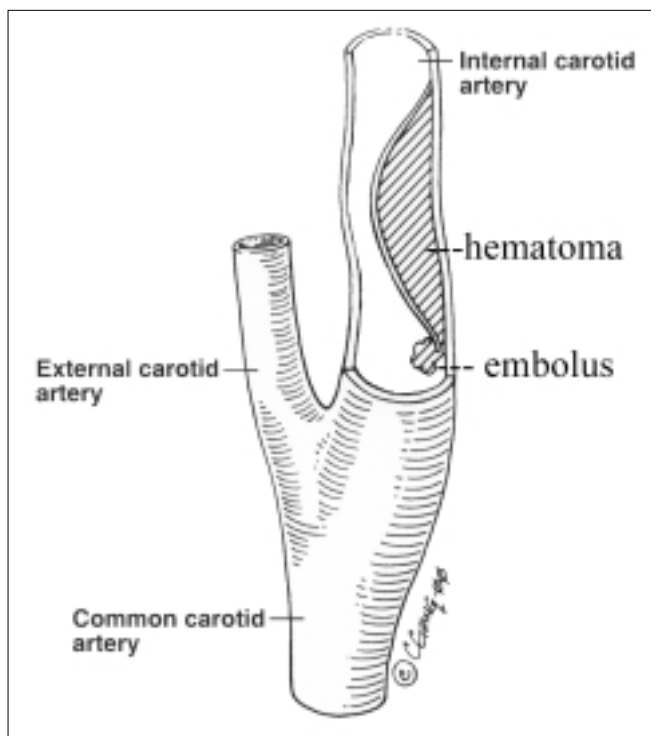


Fig. 2: Schematic representation of arterial dissection above carotid bulb, showing both potential hemodynamic and embolic causes of central ischemic lesions.

from motor vehicle accidents, was distinctly rare in our series (in only 2 cases), and only 19% (14/74) were "spontaneous," with neither head movement nor external trauma to the neck as the cause. In most cases, there was a precipitating event: either neck manipulation or sudden head movement for example during violent coughing or dental examination.

The diagnosis of dissection must be confirmed by means of vascular imaging and should be performed urgently because dissections may recanalize within a few days. Magnetic resonance angiography is now almost as accurate as catheter angiography; ultrasonography remains of limited value especially with stenosis of less than 50%.⁵

Neck pain is a reliable symptom of the onset of dissection, followed a variable time later by neurological deficits caused by blood splitting the arterial wall following the intimal tear. Cervical artery dissection is a significant cause of carotidynia. These otherwise asymptomatic lesions will heal when left alone, but if there is vigorous neck movement or manipulation at a later date, a loosely adherent clot may dislodge and embolize to the brain. Goldstein and colleagues⁶ described a young adult whose carotid artery was found to have areas of previous, recurrent dissections as well as an acute lesion necessitating excision of a pseudoaneurysm. Although there was no angiographic evidence of an arterial anomaly, microscopic examination revealed underlying fibromuscular dysplasia, which suggested that such arterial anomalies may be a more frequent cause of stroke than has been realized. (This case of "spontaneous" carotid

artery dissection was preceded by severe coughing, a known traumatic trigger.)

Whether spontaneous dissection can occur is doubtful. Much depends on the patient's history, and retrospective analyses do not provide the same quality of data available in prospective surveys. Virtually all published data on this topic are retrospective, with the inevitable and implicit biases related to inadequate documentation and dependence on patient recall. In addition, there is a natural reluctance on the part of medical personnel involved in therapeutic neck manipulation to report adverse events, so that the incidence of this complication is probably underreported. Our data, although collected prospectively, are still often deficient, especially for patients with inadequate language communication due to aphasia. It is also likely that many cases of stroke resulting from dissection are overlooked, because many physicians are unaware of the minor events that may induce a dissection.

Although most patients in our series had a stroke within 24 hours after the dissection, some strokes occurred several weeks after the onset of neck pain. There are 2 autopsied cases of fatal vertebral artery dissection following motor vehicle accidents in which stroke occurred 7 weeks and 2 months after the accident.^{7,8} This clearly has important medicolegal implications.

Stroke resulting from neck manipulation occurred in 28% (21/74) of our cases. Neck manipulation as a therapeutic strategy for head and neck pain is common and may be effective. In a recent literature review a chiropractic group in the United States estimated that 6% of patients with headache consulted alternative health care providers (mostly chiropractors) following the failure of conventional medical treatment.⁹ However, neck manipulation should probably be avoided in patients with recent acute neck pain, especially if it follows closely upon an accidental injury, because a fragile clot formed over an otherwise asymptomatic arterial tear is easily dislodged by abrupt head movement, especially rotation. Most patients undergoing therapeutic neck manipulation will have no ill effects, but there is no doubt that chiropractic neck manipulation can result in dissection of the carotid or vertebral arteries leading to stroke. Until a high-risk group can be identified, chiropractors should inform all patients of possible serious complications before neck manipulation. This is already emphasized in their current training programs.

Finally, physicians should be made aware of this potential complication, and all patients with suspected ischemic stroke should be questioned on hospital admission about recent head or neck injuries or neck manipulation.

Suspected cases of cervical artery dissection can be reported to the Canadian Stroke Consortium Headquarters (tel 416 480-4287, fax 416 480-5753).

Dr. Norris is Professor of Neurology and Drs. Beletsky and Nadareishvili are Research Fellows, Stroke Research Unit, Sunnybrook & Women's College Health Sciences Centre, Toronto, Ont.

Participating investigators: Canadian Stroke Consortium (CSC) collaborators: Drs. Neville Bayer, Toronto, Ont.; Sandra Black, Toronto, Ont.; André Bellavance, Greenfield Park, Que.; Alastair Buchan, Calgary, Alta.; Anthony Costantino, Abbotsford, BC; Robert Duke, Hamilton, Ont.; George Elleker, Edmonton, Alta.; Marek Gawel, Toronto, Ont.; Vladimir Hachinski, London, Ont.; Michael Hill, Calgary, Alta.; Jack Jhamandas, Edmonton, Alta.; Frank Kemble, Victoria, BC; Edwin Klimek, St. Catharines, Ont.; Ariane Mackey, Quebec City, Que.; Vance Makin, Vancouver, BC; Jeffrey Minuk, Montreal, Que.; James Perry, Toronto, Ont.; Marc Petitclerc, Quebec City, Que.; Stephen Phillips, Halifax, NS; Peter Seland, Kelowna, BC; Ashfaq Shuaib, Edmonton, Alta.; Denis Simard, Quebec City, Que.; Andrew Woolfenden, Vancouver, BC. Non-CSC collaborators: Drs. Werner Becker, Calgary, Alta.; Irvine Heinrichs, Calgary, Alta.; Kenneth Makus, Edmonton, Alta.; Stephen McKenzie, Toronto, Ont.; Robert Nelson, Ottawa, Ont.; Lise Prescott, Montreal, Que.; Antonio Tamayo, London, Ont.; Judith Tokar, St. Catharines, Ont.; Douglas Zochodne, Calgary, Alta.

Competing interests: None declared.

References

1. Pratt-Thomas HR, Berger KE. Cerebellar and spinal injuries after chiropractic manipulation. *JAMA* 1947;133:600-3.
2. Chan MT, Nadareishvili ZG, Norris JW. Diagnostic strategies in young patients with ischemic stroke in Canada. *Can J Neurol Sci* 2000;27:120-4.
3. Fisher M. *Clinical atlas of cerebrovascular disorders*. Boston: Wolfe; 1994. ch. 5, p. 6.
4. Leira EC, Bendixen BH, Kardon RH, Adams HP Jr. Brief, transient Horner's syndrome can be the hallmark of a carotid artery dissection. *Neurology* 1998;50:289-90.
5. Sturzenegger M, Mattle HP, Rivoir A, Baumgartner RW. Ultrasound findings in carotid artery dissection: analysis of 43 patients. *Neurology* 1995;45:691-8.
6. Goldstein LB, Gray L, Hulette CM. Stroke due to recurrent ipsilateral carotid artery dissection in a young adult. *Stroke* 1995;26:480-3.
7. Auer RN, Krcek J, Butt JC. Delayed symptoms and death after minor head trauma with occult vertebral artery injury. *J Neurol Neurosurg Psychiatry* 1994;57:500-2.
8. Viktrup L, Knudsen GM, Hansen SH. Delayed onset of fatal basilar thrombotic embolus after whiplash injury. *Stroke* 1995;26:2194-6.
9. Hurwitz EL, Aker PD, Adams AH, Meeker WC, Shekelle PG. Manipulation and mobilization of the cervical spine. *Spine* 1996;21(15):1746-60.

Correspondence to: Canadian Stroke Consortium Headquarters, Rm. C408, Sunnybrook & Women's College Health Sciences Centre, 2075 Bayview Ave., Toronto ON M4N 3M5; fax 416 480-6032

Online discussion forums for CMA members

Seek an opinion, share an insight or wax poetic with fellow members of the CMA at www.cma.ca/discussion_groups