

Supernumerary teeth: A review of the literature and four case reports

Mark A. Scheiner, BDS^c*

Wayne J. Sampson, BDS, MDS[†]

Abstract

A review of the literature relating to supernumerary teeth is presented along with four case reports to illustrate some possible presentations, diagnostic features, and treatment options.

Key words: Supernumerary teeth, supplemental teeth.

(Received for publication August 1995. Revised January 1996. Accepted February 1996.)

Introduction

Supernumerary teeth may be defined as any teeth or tooth substance in excess of the usual configuration of twenty deciduous, and thirty-two permanent teeth.¹ Such a surplus can also be accompanied by a deficit of other teeth. For example, thirty-two permanent teeth may be present with five lower incisors and only three lower premolars. Supernumerary teeth may occur singly, multiply, unilaterally or bilaterally, and in one or both jaws.

Cases involving one or two supernumerary teeth most commonly involve the anterior maxilla, followed by the mandibular premolar region.² When multiple supernumerary teeth are present (>five), the most common site affected is the mandibular premolar region.³ Single supernumeraries occur in 76 to 86 per cent of cases, double supernumeraries in 12 to 23 per cent of cases, and multiple supernumeraries in less than 1 per cent of cases.⁴

A slight difference in the relative frequency of different supernumerary teeth is reported in the literature. Luten's study⁵ suggests in order of decreasing frequency: upper lateral incisors (50 per cent), mesiodens (36 per cent), upper central incisors (11 per cent), followed by bicuspid (3 per cent). Shapira

and Kuflinec⁶ state the order of decreasing frequency as being: upper central incisors, molars (especially upper molars), premolars, followed by lateral incisors and canines. Classification of supernumerary teeth may be on the basis of position or form.² Positional variations include mesiodens, paramolars, distomolars and parapremolars. Variations in form consist of conical types, tuberculate types, supplemental teeth and odontomes. Supernumerary teeth may, therefore, vary from a simple odontome, through a conical or tuberculate tooth to a supplemental tooth which closely resembles a normal tooth. Also, the site and number of supernumeraries can vary greatly.

Supernumerary teeth are less common in the deciduous dentition with a reported incidence of 0.3 per cent to 1.7 per cent of the population.⁷ Possible explanations for the less frequent reporting of deciduous supernumerary teeth include less detection by parents, as the spacing frequently encountered in the deciduous dentition may be utilized to allow the supernumerary tooth or teeth to erupt with reasonable alignment. Also, many children have an initial dental examination following eruption of the permanent anterior teeth so anterior deciduous supernumerary teeth which have erupted and exfoliated normally would not be detected.⁷

The prevalence of supernumerary teeth varies between 0.1 and 3.6 per cent of the populations studied.³ Methodology for detection and the population studied could account for the range of prevalence cited. Luten⁵ studied the prevalence of supernumerary teeth in the primary and permanent dentitions of 1558 children and found a prevalence of 2 per cent. The methodology included the use of bitewing and periapical radiographs for detection.

A recent study of 2338 randomly selected panoramic radiographs of intact dentitions of Australian subjects aged seven to twenty years, found 2.3 per cent with supernumeraries (Fuss and Sampson, unpublished data). Of those with

*Orthodontic Registrar, Department of Dentistry, The University of Adelaide.

†Professor of Orthodontics, Department of Dentistry, The University of Adelaide.

supernumeraries, 68.6 per cent had single, 20.3 per cent had double, and 11.1 per cent had multiple supernumeraries. The supernumeraries were most frequently located in the maxillary incisor region (64.3 per cent) with mesiodens accounting for 32.4 per cent of such presentations. In decreasing order of frequency came supernumeraries in the maxillary third molar region (29.6 per cent), mandibular third molar region (7.0 per cent), mandibular premolar region (7 per cent), mandibular incisor region (4.2 per cent), and maxillary premolar region (4.2 per cent). Supernumeraries were encountered more frequently in males than females in a ratio of 2:1.

Sexual dimorphism is reported by most authors^{2,5,8} with males being more commonly affected. Mitchell² suggested no difference with the sex distribution in cases with deciduous supernumeraries, but a 2:1 ratio in favour of males in cases exhibiting permanent supernumerary teeth. Hogstrum and Andersson⁹ also reported a 2:1 ratio of sex distribution while Luten⁵ found a sex distribution of 1.3:1. A study of supernumerary teeth in Asian school children found a greater male to female distribution of 5.5:1 for Japanese, and 6.5:1 for Hong Kong children.⁴

Multiple supernumerary teeth are more common when a syndrome is involved. Yusuf³ suggests that it may be rare to find multiple supernumerary teeth without an associated syndrome. Common syndromes showing multiple supernumerary teeth along with other conditions include Gardiner's syndrome, cleidocranial dysostosis, and cleft lip and palate. Acton⁸ advises checking for evidence of syndromal involvement in all cases exhibiting multiple supernumerary teeth. A careful check for a family history of supernumerary teeth could point to the presence of a genetically determined syndrome.

As inferred above, the aetiology of supernumerary teeth may be partly genetic as supernumerary teeth are more commonly found in relatives of affected individuals than the general population; however the inheritance pattern does not follow Mendelian principles.² Environmental factors must also be considered in the aetiology of supernumerary teeth, as Shapira and Kufninec⁶ propose hyperproductivity of the dental lamina and dichotomy of tooth germs as aetiological factors, which have been supported by *in vitro* experiments. They also suggest the phylogenetic process of atavism, syndromes, and the late development of some supernumerary teeth or a 'post permanent' dentition may also be aetiological factors.

Becker, Bimstein and Shteyer¹⁰ reported a case of multiple, anterior and posterior, maxillary and mandibular supernumerary teeth which were detected in a 12-year-old. The supernumeraries were in the canine-premolar regions and developed after removal of a maxillary midline supernumerary tooth

at the age of eight years. This may be an example of post permanent dentition development. Paramolars and parapremolars would also seem to fit a model of post permanent dentition development consistent with continued dental lamina activity.

Effects of supernumerary teeth on the developing dentition vary. There may be no effect with the supernumerary tooth or teeth discovered either as a chance radiographic finding or following their eruption. Crowding may be evident due to an increased number of erupted teeth. Failure of eruption of adjacent permanent teeth is the most frequent occurrence and occurs in 30 to 60 per cent of cases.^{2,11} The supernumerary or adjacent teeth may be displaced and ectopic eruption of either is not uncommon. Supernumerary teeth may also cause diastemata, root resorption of adjacent teeth, malformation of adjacent teeth such as dilaceration, and loss of vitality of adjacent teeth.⁹

Case reports

The following four cases were referred to the Orthodontic Clinic, Adelaide Dental Hospital for orthodontic assessment and treatment and represent some of the possible presentations of supernumerary teeth. They include a case where there was an obvious excess in the number of teeth erupted, one where lack of eruption of a permanent tooth was the obvious feature, one where the supernumerary teeth were found by chance as part of a comprehensive orthodontic examination, and one of interest in that no treatment was sought or suggested until adult age with consequent complications.

Case 1

An 11-year-old female presented with a chief complaint of delayed eruption of a lower permanent tooth. Medical and family histories were non-contributory. Examination revealed a Class I mixed dentition with a well aligned upper arch and irregularity of the lower arch associated with an unerupted lower central incisor (Fig. 1a).

Radiographic examination showed tooth 41 to be unerupted, lingually positioned and associated with two supernumeraries that were also lingually placed (Fig. 1b, c).

Both supernumeraries were extracted and the incisal tip of tooth 41 was exposed. Orthodontic treatment comprised bracketing of 42-32 and a sectional arch wire to erupt tooth 41 and align the lower incisors. This mixed dentition treatment was uneventful and the patient is now under regular review regarding future fixed orthodontic treatment. Note the dilaceration of 42 root (Fig. 1d) post treatment.

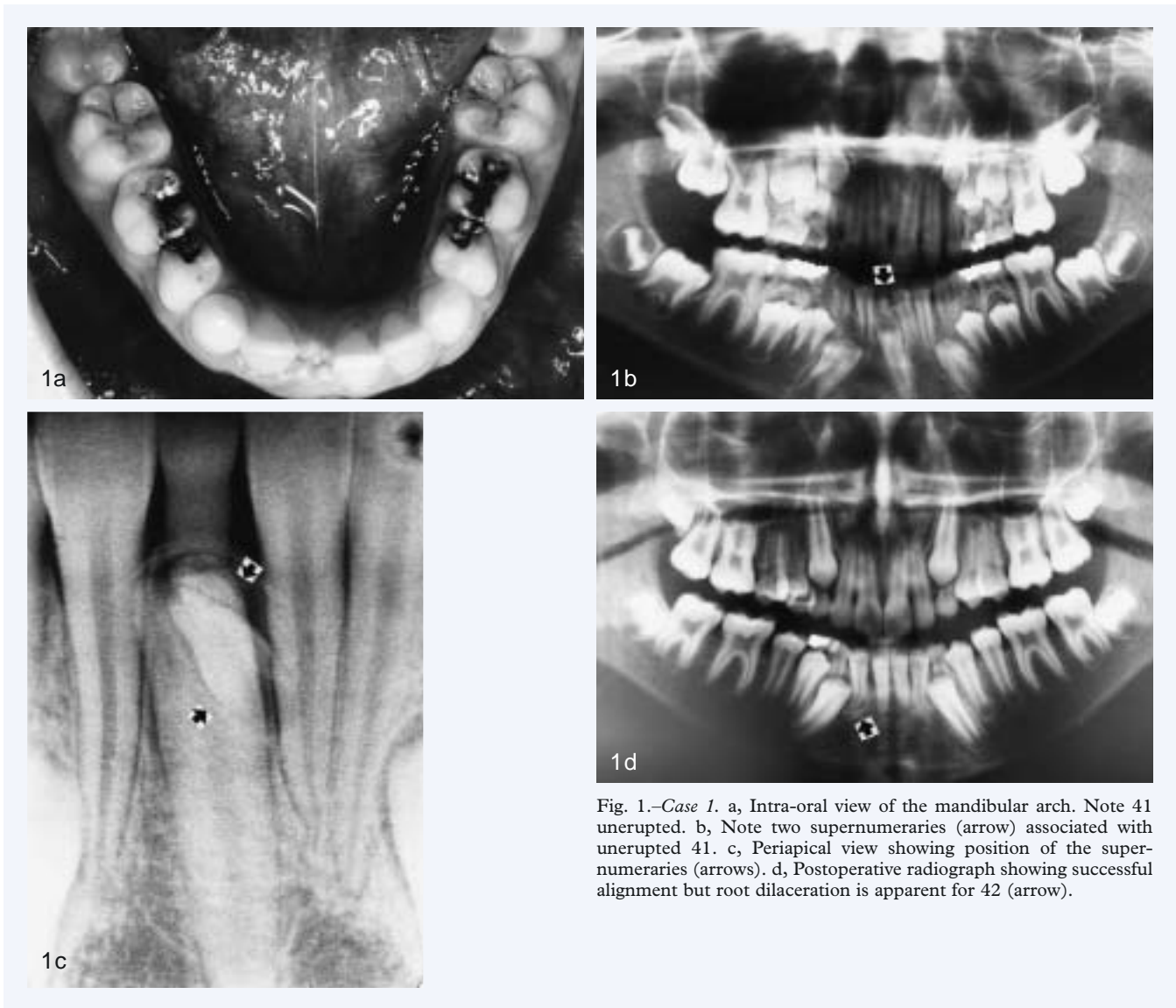


Fig. 1.—Case 1. a, Intra-oral view of the mandibular arch. Note 41 unerupted. b, Note two supernumeraries (arrow) associated with unerupted 41. c, Periapical view showing position of the supernumeraries (arrows). d, Postoperative radiograph showing successful alignment but root dilaceration is apparent for 42 (arrow).

Case 2

An 11-year-old male presented with a chief complaint of an extra front tooth. Medical and family histories were unremarkable. Examination revealed a mild Class II molar relationship in the mixed dentition with a well aligned lower arch and increased overbite and overjet. A supplemental central incisor and lateral incisor on opposite sides of the maxillary arch were evident (Fig. 2a).

Radiographic examination revealed the supernumeraries to be truly supplemental as all three upper central incisors displayed identical morphology as did the three lateral incisors (Fig. 2b).

Treatment involved extraction of the most distal upper right lateral incisor, the most distal and displaced upper central incisor, and placement of upper and lower bands on first molars and brackets on incisors to reduce the overbite and overjet caused by the excess tooth substance. The early treatment goals were achieved without complication and the patient is under regular review.

Case 3

A 16-year-old male presented with a chief complaint relating to aesthetic concerns regarding his crooked teeth. Medical and family histories were not significant. Examination revealed a Class I malocclusion with moderate to severe upper and lower incisor crowding. Also noted were supernumerary teeth erupting buccal to the upper second permanent molars (Fig. 3a).

Radiographic examination revealed the presence of two conical supernumerary paramolars per upper quadrant (Fig. 3b).

Treatment involved the extraction of upper and lower first premolar teeth to relieve the crowding, extraction of the supernumerary teeth and upper and lower full arch banding to correct the malocclusion.

Case 4

An eight-year-old female presented with displaced upper anterior teeth. Medical and family histories

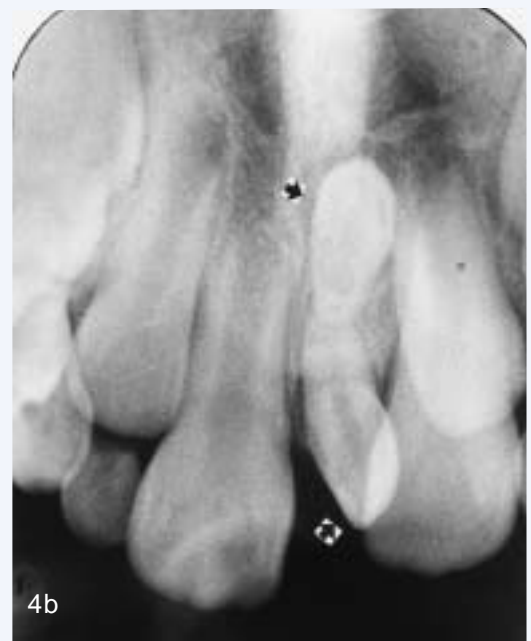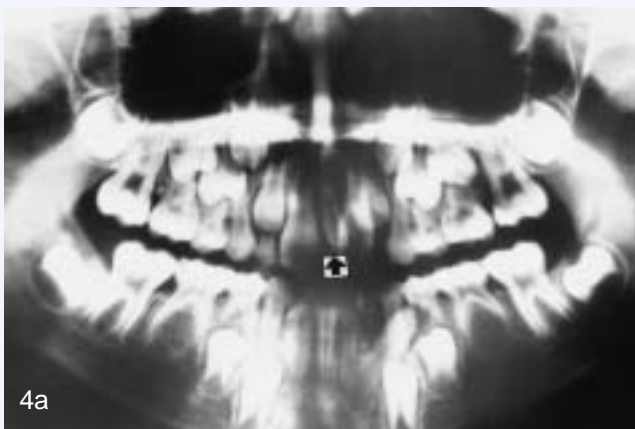
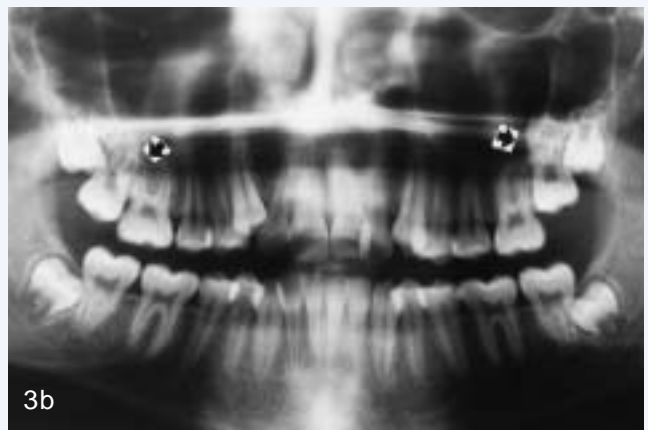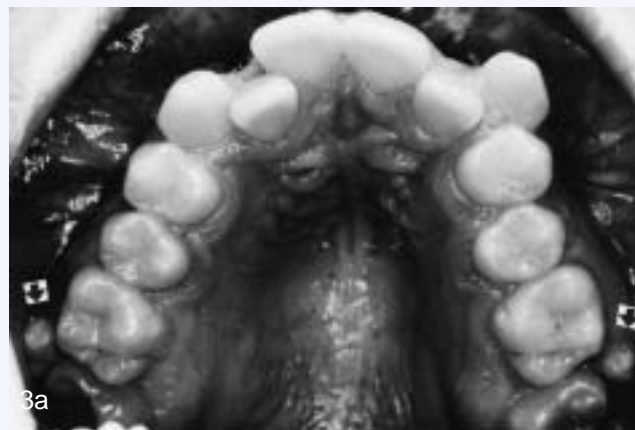
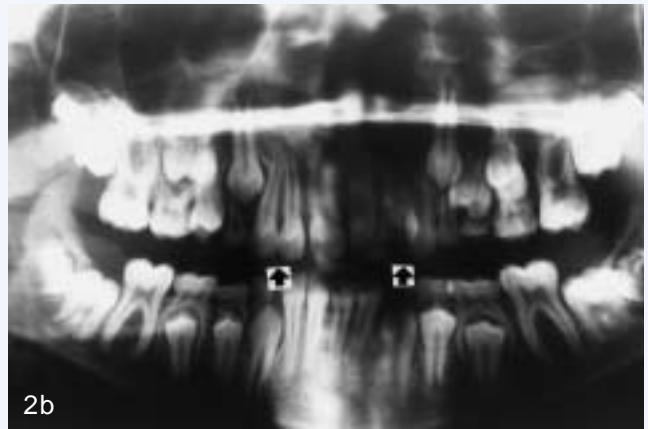


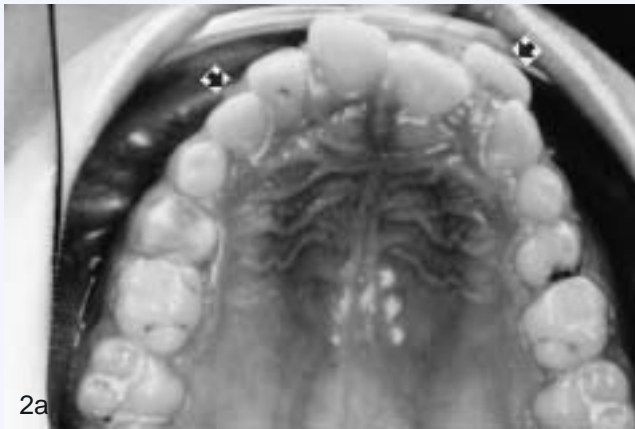Fig. 2.—Case 2. a (top left), Intra-oral view of the maxillary arch. Note supplemental lateral incisor in the right quadrant (arrow) and supplemental central incisor in the left quadrant (arrow). b (top right), Supplemental teeth (arrows) showing identical morphology to permanent lateral and central incisors respectively.

Fig. 3.—Case 3. a (centre left), Intra-oral view of the maxillary arch. Note supernumerary teeth erupting buccal to upper right and left second permanent molars (arrows). b (centre right), Two supernumerary teeth per quadrant associated with upper right and left second permanent molars (arrows). It would be easy to overlook these supernumeraries had they not been clinically emergent.

Fig. 4.—Case 4. a (bottom left), Panoramic radiograph showing supernumeraries between 11 and 21 (arrows) and agenesis of 35 and 45. Note transposing 32. b (bottom right), Periapical radiograph of the supernumeraries (arrows) indicating rudimentary forms and divergent eruption paths.

were unremarkable. Examination revealed a Class I dental pattern compensating for a Class II skeletal facial pattern with upper and lower anterior dental arch crowding.

Radiographic examination revealed two rudimentary-type mesiodens supernumeraries and agenesis of 35 and 45 (Fig. 4a, b). The developing transposition of 32 was also noted.

Treatment was instituted to extract the supernumeraries and 72, 73 and 83 to facilitate alignment and reduce the severity of transposition of 32; the need for early banding to be reviewed four months postoperative.

Discussion

The cases described above represent a small sample of the possible presentations for cases involving supernumerary teeth. It is essential to enumerate and identify the teeth present clinically and radiographically before a definitive diagnosis and treatment plan can be formulated.

Not all situations lend themselves to ideal treatment results. Timing of interceptive treatment should be as soon as possible following clinical detection of an abnormal eruption pattern. It has been suggested that a tooth delayed in its eruption by more than six months with respect to its antimere should be radiographically investigated. A panoramic radiograph is a most useful screening radiograph in such situations as it shows all areas of the maxilla and mandible.

Mitchell and Bennett¹² have suggested that different types of supernumeraries have been associated with different effects on the adjacent dentition. Foster and Taylor¹³ examined this relationship and found tuberculate types more commonly produced delayed eruption, whereas conical types more commonly produced displacement of the adjacent dentition.

Controversy exists regarding the optimal treatment of delayed eruption due to supernumerary involvement. The options include removal of the supernumerary only, removal of the supernumerary and orthodontic treatment to re-establish sufficient space for the delayed tooth, with or without surgical exposure of the unerupted tooth at the time of supernumerary tooth removal.

Taylor¹⁴ described a case where a geminated maxillary lateral incisor was seen as unaesthetic. Treatment involved removal of the large, notched, geminated tooth and autogenous transplantation of a supplemental lateral incisor from the opposite maxillary quadrant. In this case, the surplus tooth material was utilized to replace a malformed tooth. The case report highlighted the need for careful diagnosis and treatment planning as in some

situations the surplus tooth tissue may be utilized advantageously.

Spontaneous eruption following supernumerary removal is suggested to be in the range of 54 per cent¹⁵ to 75 per cent.¹⁶ DiBiase¹⁶ suggests that most teeth experiencing delayed eruption will spontaneously erupt within 18 months of supernumerary removal alone, providing the delayed tooth is not excessively displaced.

Mitchell and Bennett¹² studied spontaneous eruption following supernumerary removal only. Ninety-six patients with 120 teeth exhibiting delayed eruption were studied. They found that 78 per cent spontaneously erupted with a median time for eruption of 16 months. Only 14 per cent required a second operation to expose the delayed tooth and this procedure was performed at a median time of 30 months following supernumerary removal. If adequate space was available, or was created early, the median time for spontaneous eruption was reduced.

Timing of surgical removal of supernumerary teeth has also been contentious. Hogstrum and Andersson⁸ suggested two alternatives exist. The first option involves removal of the supernumerary as soon as it has been diagnosed. This could create dental phobia problems for a young child and has been said to cause devitalization or deformation of adjacent teeth. Secondly, the supernumerary could be left until root development of the adjacent teeth is complete. The potential disadvantages associated with this deferred surgical plan include; loss of eruptive force of adjacent teeth, loss of space and crowding of the affected arch, and possible midline shifts. In their study 23 children aged less than 11 years and 17 aged greater than 11 years at the time of supernumerary removal, Hogstrum and Andersson⁸ found no evidence of root resorption, loss of vitality or disturbance of root development during the three-year follow-up period. Obviously the position, size and nature of the supernumerary and the level of co-operation of the patient will influence the surgical difficulty and each case should be individually assessed.

From the evidence available it would seem prudent to treat by removal of the supernumerary only in cases where adequate space is available for the adjacent permanent tooth to erupt. The space should be monitored to ensure that it does not close, and the delayed tooth should be given approximately 18 months to spontaneously erupt. In cases where the delayed tooth is displaced, or where further early orthodontic treatment is indicated, concomitant exposure and orthodontic traction may be considered. In young patients who are unlikely to cope well with a second operation, initial exposure and orthodontic traction at the time of supernumerary removal may be advisable, particularly when incisors are involved.

References

1. Schulze C. Developmental abnormalities of the teeth and jaws. In: Gorlin RJ, Goldman HM, eds. Thoma's oral pathology. St Louis: CV Mosby, 1970:112-22.
2. Mitchell L. Supernumerary teeth. Dent Update 1989;16:65-9.
3. Yusof WZ. Non-syndromal multiple supernumerary teeth: literature review. J Can Dent Assoc 1990;56:147-9.
4. So LLY. Unusual supernumerary teeth. Angle Orthod 1990;60:289-92.
5. Luten JR, Jr. The prevalence of supernumerary teeth in primary and mixed dentitions. J Dent Child 1967;34:48-9.
6. Shapira Y, Kufinec MM. Multiple supernumerary teeth: report of two cases. Am J Dent 1989;2:28-30.
7. Taylor GS. Characteristics of supernumerary teeth in the primary and permanent dentitions. Dent Pract Dent Rec 1972;22:203-8.
8. Acton CHC. Multiple supernumerary teeth and possible implications. Aust Dent J 1987;32:48-9.
9. Hogstrum A, Andersson L. Complications related to surgical removal of anterior supernumerary teeth in children. J Dent Child 1987;54:341-3.
10. Becker A, Bimstein E, Shteyer A. Interdisciplinary treatment of multiple unerupted supernumerary teeth: a case report. Am J Orthod 1982;81:417-22.
11. Nik-Hussein NN. Anterior maxillary supernumerary teeth: a clinical and radiographic study. Aust Orthod J 1990;11:247-50.
12. Mitchell L, Bennett TG. Supernumerary teeth causing delayed eruption – a retrospective study. Br J Orthod 1992;19:41-6.
13. Foster TD, Taylor GS. Characteristics of supernumerary teeth in the upper incisor region. Dent Pract 1969;20:8-12.
14. Taylor GS. Autotransplant replacement of a geminated incisor by a supplemental lateral incisor. Br J Orthod 1979;6:195-8.
15. Witsenberg B, Boering G. Eruption of impacted permanent incisors after removal of supernumerary teeth. J Oral Surg 1981;10:423-31.
16. DiBiase D. The effects of variations in tooth morphology and position on eruption. Dent Pract 1971;22:95-108.

Address for correspondence/reprints:

Professor W. J. Sampson,
Orthodontic Unit,
Department of Dentistry,
The University of Adelaide,
Adelaide, South Australia 5005.