

# Supraselective intra-arterial chemotherapy: evaluation of treatment-related complications in advanced retinoblastoma

Lejla Mutapcic Vajzovic<sup>1</sup>  
Timothy G Murray<sup>1</sup>  
Mohammad A Aziz-Sultan<sup>2</sup>  
Amy C Scheffler<sup>1</sup>  
Stacey Quintero Wolfe<sup>2</sup>  
Ditte Hess<sup>1</sup>  
Cristina E Fernandes<sup>3</sup>  
Sander R Dubovy<sup>1,4</sup>

<sup>1</sup>Bascom Palmer Eye Institute, University of Miami Miller School of Medicine, Miami, FL, USA;

<sup>2</sup>Department of Neurological Surgery, University of Miami/Jackson Memorial Hospital, Miami, FL, USA; <sup>3</sup>Department of Pediatrics, University of Miami Miller School of Medicine, Miami, FL, USA; <sup>4</sup>Florida Lions Oculopathology Laboratory, Miami, FL, USA

**Purpose:** The purpose of this study is to report the complication profile and safety evaluation of supraselective intra-arterial melphalan chemotherapy in children undergoing treatment with advanced retinoblastoma.

**Methods:** Twelve eyes of 10 children with advanced retinoblastoma (Reese-Ellsworth Group Vb or International Classification Group D) were treated with supraselective intra-ocular artery infusion of melphalan. Eleven eyes of nine children had previously failed traditional management with systemic chemotherapy and laser ablation and underwent intra-ocular artery infusion of melphalan as an alternative to enucleation. Serial ophthalmic examinations, retinal photography, and ultrasonographic imaging were used to evaluate treatment regime.

**Results:** Ophthalmic artery cannulation was successfully performed in 12 eyes of 10 patients (total 16 times). Striking regression of tumor, subretinal and vitreous seeds were seen early in each case. No severe systemic side effects occurred. Grade III neutropenia was seen in one patient. No transfusions were required. Three patients developed a vitreous hemorrhage obscuring tumor visualization. One patient developed periocular edema associated with inferior rectus muscle inflammation per orbital MRI. This same patient had scattered intraretinal hemorrhages and peripapillary cotton wool spots consistent with a Purtscher's-like retinopathy that resolved spontaneously. At the 6-month follow-up examination, nine eyes had no evidence of tumor progression, whereas three eyes were enucleated for tumor progression. In each enucleated case, viable tumor was identified on histopathologic examination.

**Conclusions:** Ophthalmic intra-arterial infusion with melphalan is an excellent globe-conserving treatment option in advanced retinoblastoma cases with minimal systemic side effects. Local toxicities include microemboli to the retina and choroid (1/12, 8%), vitreous hemorrhage (3/12, 25%), and myositis (1/12, 8%). Enucleation remained a definitive treatment for tumor progression in 3 of 12 eyes in this small case series with limited follow-up. Further studies are necessary to establish the role of supraselective intra-arterial melphalan chemotherapy for children with retinoblastoma.

**Keywords:** retinoblastoma, intra-arterial chemotherapy, melphalan

## Introduction

Retinoblastoma is the most common intraocular tumor in childhood, occurring in ~1 in 15,000 live births, with 300 newly diagnosed children each year in the United States.<sup>1,2</sup> Historically, treatment for children with advanced retinoblastoma involved enucleation and external beam radiation therapy that has significant complications including midfacial disfigurement and secondary primary malignancies.<sup>3-5</sup> For over a decade, treatment has been focused on globe-preserving techniques including systemic chemotherapy and a combination of focal consolidative therapy including brachyther-

Correspondence: Timothy G Murray  
Bascom Palmer Eye Institute, University of Miami Miller School of Medicine, PO Box 016880, Miami, FL 33101, USA  
Tel +1 305 326 6166  
Fax +1 305 326 6417  
Email tmurray@med.miami.edu

apy, laser photocoagulation, cryotherapy, or thermotherapy. Although this treatment approach has resulted in significant improvement in survival rates, up to 99% in the developed world, systemic chemotherapy frequently leads to serious toxic side effects including myelosuppression, infection, and the need for blood transfusion in up to 75% of cases.<sup>6-8</sup> As a result, newer treatment approaches have involved localized delivery of chemotherapy to minimize systemic side effects of chemotherapy and have included periocular injection of carboplatin and intra-ophthalmic artery infusion of the chemotherapeutic drug melphalan.<sup>9,10</sup> However, recently concerns have been raised regarding periocular carboplatin with reports of severe localized side effects, such as extraocular motility changes, optic nerve toxicity, and periorbital fat necrosis with enophthalmia.<sup>10-12</sup> Intra-arterial injection of melphalan in retinoblastoma patients has been reported by Yamane et al, Abramson et al, and our group.<sup>13-17</sup> Herein, we summarize the treatment of 12 eyes of 10 children with advanced intraocular retinoblastoma (Reese-Ellsworth Group Vb or International Classification Group D, who would generally undergo enucleation) with intra-ophthalmic artery infusion of melphalan.

## Materials and methods

Under general anesthesia, the femoral artery cannulation was performed with a sterile 21-gauge micropuncture. A heparin bolus (60 units/kg IV) was administered to anticoagulate the patient. Additional heparin boluses were given based on hourly measurement of activated clotting time (ACT) with a goal of ACT between 200 and 250 sec. Under fluoroscopic X-ray guidance, a 4-French (F) guide catheter was maneuvered over a wire through the aortic arch into the ipsilateral external and internal carotid arteries (ICA) through which digital subtracted angiography was performed to assess vascular supply to the orbit. A Marathon microcatheter (EV3, Irvine, CA, USA) was then advanced over a Mirage microguide wire (EV3, Irvine, CA, USA) and into the ostium of the ophthalmic artery where a selective ophthalmic artery angiography was performed. The desired dose of melphalan was diluted in 30 cc of normal saline and infused by pulse injection over 30 min. Ophthalmic artery and ipsilateral ICA angiography were repeated to rule out any inadvertent thromboembolic episodes. All patients tolerated the procedure.

Ophthalmic evaluations under anesthesia were performed approximately every 4 weeks after intra-arterial chemotherapy was completed and consisted of external and anterior segment examination for any evidence of iris neovascularization, hyphema, or hypopyon, indirect ophthalmoscopy with 360° of scleral depression, Ret Cam

digital fundus photography (Massie Industries, Dublin, CA, USA) documenting all lesions, and B-scan ultrasonography (10 MHz). Between evaluations under anesthesia, the pediatric oncologist performed systemic evaluation including an interval history and complete blood counts.

## Results

This report summarizes our initial experience with intra-ophthalmic artery infusion of the chemotherapeutic agent melphalan in 12 eyes of 10 children, all diagnosed with Reese-Ellsworth Group Vb or International Classification Group D retinoblastoma (unilateral 6, bilateral 4) (Table 1). Nine patients were previously treated with systemic chemotherapy in a combination with laser photocoagulation. Systemic chemotherapy included carboplatin, vincristine, etoposide, and/or cyclosporine for nine cycles except for one patient who received 11 cycles. At the subsequent exams and as tumor progression was noted, seven patients were treated with periocular injections of carboplatin and one patient in addition had external beam radiation. Only patient #10 received intra-arterial melphalan and laser photocoagulation as the primary treatment, while the other nine patients received intra-arterial melphalan and laser photocoagulation as salvage therapy in the setting of disease progression after systemic chemotherapy and focal therapy.

All attempts at supraselective intra-arterial drug delivery were successful. There were 16 separate infusions in 10 patients. Eight patients had unilateral and two patients had bilateral infusions. Four patients received repeat melphalan infusion at higher doses due to initial incomplete tumor response. The mean follow-up was 5.5 months and the median was 5.0 months. At the 5-month follow-up examination, nine eyes had no evidence of tumor progression. Three eyes required enucleation. The indications for enucleation were vitreous hemorrhage obscuring visualization of tumor, peripapillary tumor with concern for optic nerve invasion, and continued tumor progression. In each enucleated case, viable tumor was identified on histopathologic examination. These findings have been described elsewhere.<sup>15</sup>

Overall, 76.5% of tumors responded to therapy avoiding enucleation. Of the responders, 54% responded to single dose of melphalan. Representative cases before and after treatment are illustrated (Figures 1-3).

There were no severe systemic complications including fevers, infections, red blood cell or platelet transfusions, stroke or death. Grade III neutropenia was seen in one patient at 1 week. Scrotal hematoma at the femoral artery puncture site was noted in patient #9. Vitreous hemorrhage was

**Table 1** Data on the first 12 eyes of 10 patients with retinoblastoma treated with intra-arterial melphalan

Pt no.	Age at Dx (years)	Laterality	R-E group	ICRB group	Previous tx	Age at first IAM (months)	Eye(s) tx	Dose (mg) with each Dx	F/U interval since IAM (months)	Complications after Dx		
										Enucleation	VH	Other
1	3	U	Vb	D	Yes	34	OS	3, 7.5	6	Yes	Yes	
2	3	U	Vb	D	Yes	59	OS	5	5	No	No	
3	2	B	Vb	D	Yes	21	OU	OD 5, 7.5; OS 3	5	OD Yes; OS No	No	Grade III neutropenia
4	2	B	Vb	D	Yes	25	OU	OD 2; OS 2, 7.5	7	No	Yes	
5	1	B	OD II; OS Vb	D	Yes	17	OS	3	6	No	Yes	
6	3	B	Vb	D	Yes	33	OS	3	6	No	No	
7	2	U	Vb	D	Yes	20	OD	3, 7.5	5	No	No	
8	4	U	Vb	D	Yes	46	OD	5	5	No	No	
9	8	U	Vb	D	Yes	95	OS	5	5	No	No	Scrotal hematoma, periorbital edema
10	7	U	Vb	D	No	83	OD	7.5	5	No	No	Inferior rectus inflammation, Purtscher's-like retinopathy

**Abbreviations:** B, bilateral retinoblastoma; Dx, diagnosis; F/U, follow-up; IAM, intra-ophthalmic artery infusion of melphalan; ICRB, international classification of retinoblastoma group; OD, right eye; OS, left eye; OU, both eyes; Pt, patient; R-E, Reese-Ellsworth; U, unilateral retinoblastoma; VH, vitreous hemorrhage.

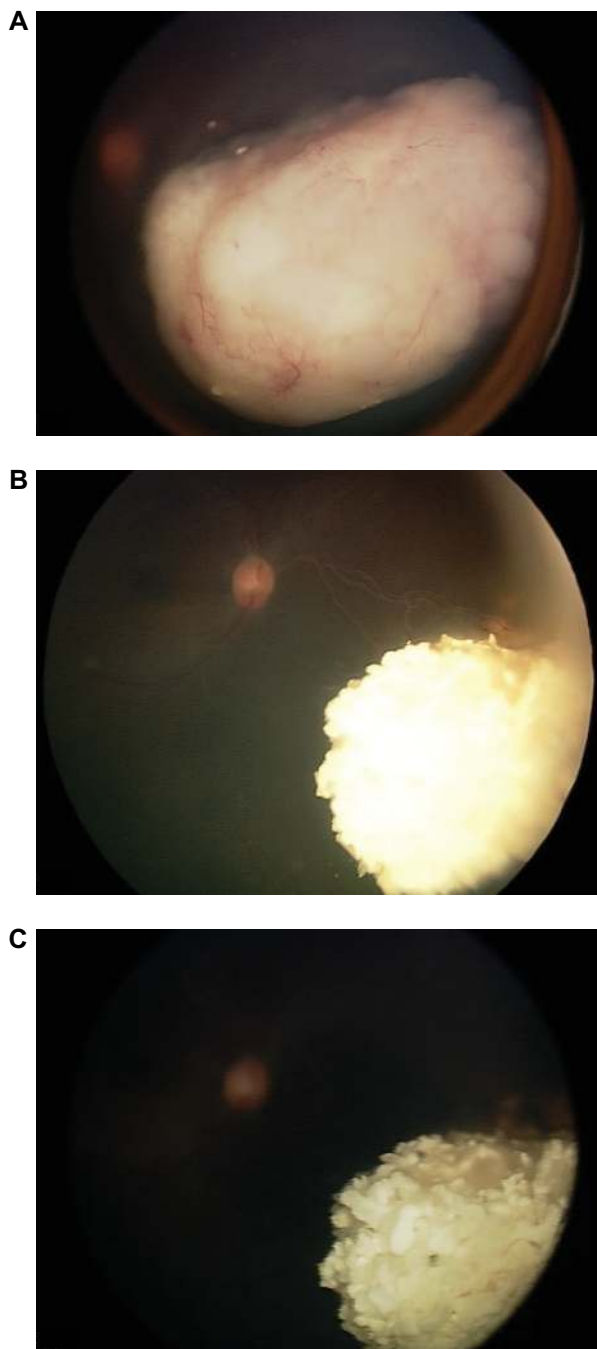
noted in three eyes on initial follow-up after intra-arterial melphalan infusion and was self-limiting in cases #4 and #5. Patient #10 developed periocular swelling, and an MRI of orbits showed inferior rectus muscle inflammation. Dilated fundusoscopic examination showed Purtscher's-like retinopathy with peripapillary cotton wool spots and scattered intraretinal hemorrhages in the treated eye most likely due to an embolic event. These findings resolved spontaneously on close follow-up (Figure 3).

## Discussion

This report describes our experiences with supraselective ophthalmic artery infusion with chemotherapy for patients with advanced intraocular retinoblastoma unresponsive to systemic chemotherapy and focal treatment.

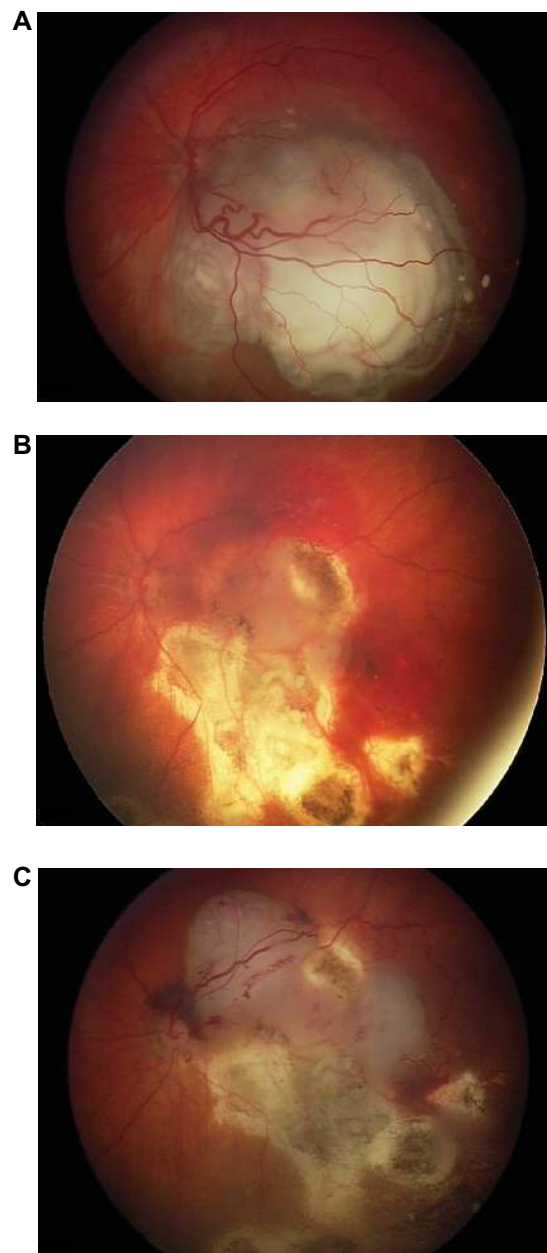
Recently, local treatments including periocular administration of carboplatin, and intra-arterial infusion of melphalan have been suggested as alternative modalities to systemic chemotherapy, especially in eyes with advanced disease (Reese-Ellsworth Group IV and V or International Classification Group D). Responses have been demonstrated with periocular carboplatin; however, severe local side effects have been reported including extraocular motility changes, optic nerve toxicity (necrosis/atrophy), and periorbital fat necrosis.<sup>10-12</sup> Intra-arterial infusion of melphalan has been reported, as noted, in a small case series by Abramson et al.<sup>14</sup> In Japan, clinicians have been investigating intracarotid infusion of chemotherapy for the past 15 years. They have successfully infused melphalan into the cervical ICA while occluding the distal internal carotid just past ophthalmic artery bifurcation in 97.5% of 563 treatments.<sup>13</sup> Many of these eyes also received external beam radiation therapy and intravitreal melphalan making it difficult to draw efficacy conclusions. In the United States, Abramson and associates reported good outcomes after selective intra-ophthalmic artery infusion of melphalan in a phase I/II clinical trial. They enrolled 10 patients and were able to successfully cannulate ophthalmic artery in nine patients. Of these treated patients, eight had visual stabilization or improvement. All patients had poor electroretinogram profiles at baseline, and these were unchanged after treatment. Enucleation was avoided in seven patients. No severe local or systemic side effects were reported in this trial.<sup>14,18</sup>

At our institution, we have treated 12 eyes of 10 patients with selective intra-arterial melphalan at varying doses. All cases had advanced retinoblastoma Reese-Ellsworth Group Vb or International Classification Group D, and all but one patient had received and failed multiagent chemore-



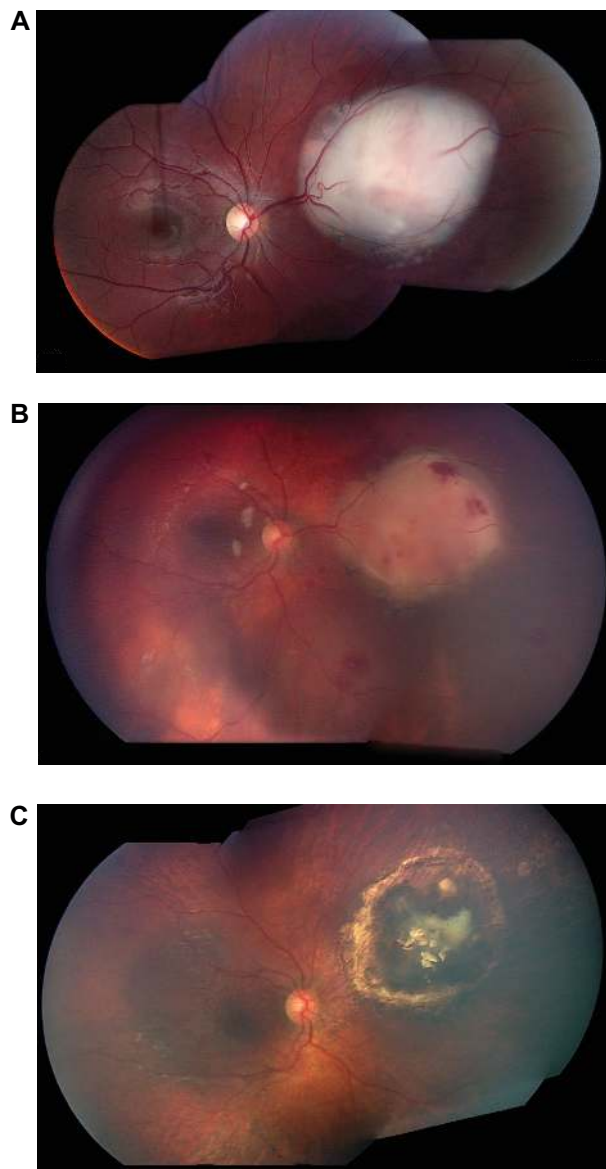
**Figure 1** Patient #8 diagnosed with unilateral advanced Reese-Ellsworth Group Vb or International Classification Group D retinoblastoma previously treated with systemic chemoreduction and focal consolidative treatment, then periocular carboplatin injections without tumor regression. As a salvage therapy, intra-arterial melphalan infusion at 5 mg was performed, which lead to tumor regression. **A)** At presentation. **B)** After systemic chemoreduction and focal laser photocoagulation. **C)** Five months after a single infusion of melphalan at 5-mg dose.

duction therapy combined with laser photocoagulation. In addition, one patient was treated with external beam radiation without success. In 11 eyes, the decision was made to proceed with intra-arterial melphalan combined with focal laser photocoagulation as a salvage treatment option before



**Figure 2** Patient #1 presented with Reese-Ellsworth Group Vb or International Classification Group D retinoblastoma initially treated with systemic multiagent chemoreduction (carboplatin, vincristine, etoposide, and cyclosporine) with focal laser photocoagulation and subsequently with six periocular carboplatin injections. Even with this aggressive treatment, the tumor continued to progress. The patient then underwent intra-arterial melphalan infusion as salvage therapy at the 3-mg dose and then at the 7.5-mg dose. Subsequently, the patient developed a vitreous hemorrhage obscuring tumor visualization. Echographic evaluation demonstrated tumor progression, and the patient underwent definitive therapy with enucleation. **A)** At presentation. **B)** Before first melphalan infusion (3-mg dose). **C)** Before second melphalan infusion (7.5 mg).

standard enucleation. At a 3–4 week follow-up interval after intra-arterial melphalan treatment, a marked response with regression of retinal tumor, subretinal/vitreous seeds was noted in all patients. One eye in our series was treated with intra-arterial melphalan as a primary treatment



**Figure 3** Patient #10 treated primarily with single, high dose (7.5 mg) intra-arterial infusion of melphalan. **A)** Before treatment. **B)** One week after treatment. **C)** Five months after treatment. In this case, intra-arterial melphalan treatment resulted in complete resolution of the tumor by 1 month posttreatment and no evidence of progression at 5 months. At 1-week follow-up, the patient developed periorbital swelling, and an MRI of orbits was obtained showing inferior rectus muscle inflammation. On dilated funduscopic examination, peripapillary cotton wool spots and scattered intraretinal hemorrhages were noted consistent with Purtscher's-like retinopathy in the treated eye. On follow-up examinations, these findings resolved spontaneously.

modality combined with laser photocoagulation with the goal of avoiding long-term systemic chemotherapy and its associated morbidity. In this case, intra-arterial melphalan treatment resulted in complete resolution of the tumor by 1 month posttreatment and no evidence of progression at 5 months (Figure 3). To date, 3 of the 12 eyes (25%) treated with intra-arterial melphalan have been enucleated for suspected tumor recurrence. These were eyes that

previously had undergone extended chemoreduction, laser photocoagulation, and periocular carboplatin injections. On histopathologic examination of enucleated eyes, viable tumor was noted in all three cases.<sup>15</sup>

Although intra-arterial infusion of melphalan has shown promising results, we have noted several local side effects. These side effects included vitreous hemorrhage in three patients and Purtscher's-like retinopathy secondary to an embolic event as well as inferior rectus inflammation in another patient. In two of three patients, vitreous hemorrhage was self-limited, and tumor regression was achieved. The third patient with vitreous hemorrhage underwent enucleation for tumor progression. The Purtscher's-like retinopathy findings in the latter patient resolved spontaneously, and complete tumor regression was noted at last follow-up. No severe systemic complications were identified during posttreatment period including fever, nausea, vomiting, alopecia, bone marrow suppression, sepsis, or any other condition requiring hospitalization.

In our experience, intra-arterial infusion of melphalan has been successful in achieving effective tumor reduction in advanced retinoblastoma cases primarily as globe-salvage therapy after failure of systemic chemotherapy combined with focal therapy. This alternative globe-preserving treatment has dramatically decreased enucleation rate at our institution. It should be noted that this approach requires consolidation with focal therapy, such as laser, after completion of intra-arterial chemotherapy. Clinicians offering this treatment modality should be aware of short-term potential local adverse effects, such as vitreous hemorrhage and Purtscher's-like retinopathy as well as lack of tumor response. Larger patient series are needed to establish the role of supraselective intra-arterial melphalan chemotherapy for children with retinoblastoma. Collaborative series among large institutions are currently in development with the Children's Oncology Group and these series will greatly advance the rate at which we can learn more about this exciting therapy since retinoblastoma is a rare disease.

## Disclosure

The authors report no conflicts of interest in this work.

## References

1. Abramson DH. Retinoblastoma incidence in the United States. *Arch Ophthalmol.* 1990;108(11):1514.
2. Tamboli A, Podgor MJ, Horm JW. The incidence of retinoblastoma in the United States: 1974 through 1985. *Arch Ophthalmol.* 1990; 108:128–132.
3. Cassady JR, Sagerman RH, Tretter P, Ellsworth RM. Radiation therapy in retinoblastoma. An analysis of 230 cases. *Radiology.* 1969;93: 405–409.

4. Desjardins L, Haye C, Schlienger P, Laurent M, Zucker JM, Bouguila H. Second non-ocular tumours in survivors of bilateral retinoblastoma. A 30-year follow-up. *Ophthalmic Paediatr Genet.* 1991;12(3):145–148.
5. Marees T, Moll AC, Imhof SM, de Boer MR, Ringens PJ, van Leeuwen FE. Risk of second malignancies in survivors of retinoblastoma: more than 40 years of follow-up. *J Natl Cancer Inst.* 2008;100(24):1743–1745.
6. Shields JA, Shields CL, Meadows AT. Chemoreduction in the management of retinoblastoma. *Am J Ophthalmol.* 2005;140(3):505–506.
7. Benz MS, Scott IU, Murray TG, Kramer D, Toledano S. Complications of systemic chemotherapy as treatment of retinoblastoma. *Arch Ophthalmol.* 2000;118:577–578.
8. Abramson DH. Retinoblastoma in the 20th century: past success and future challenges the Weisenfeld lecture. *Invest Ophthalmol Vis Sci.* 2005;46(8):2683–2691.
9. Abramson DH, Scheffler AC. Update on retinoblastoma. *Retina.* 2004;24:828–848.
10. Mulvihill A, Budning A, Jay V, et al. Ocular motility changes after sub-tenon carboplatin chemotherapy for retinoblastoma. *Arch Ophthalmol.* 2003;121:1120–1124.
11. Kiratli H, Kocabeyoglu S, Bilgic S. Severe pseudo-preseptal cellulitis following sub-tenon's carboplatin injection for intraocular retinoblastoma. *J AAPOS.* 2007;11(4):404–405.
12. Schmack I, Hubbard GB, Kang SJ, Aaberg TM Jr, Grossniklaus HE. Ischemic necrosis and atrophy of the optic nerve after periocular carboplatin injection for intraocular retinoblastoma. *Am J Ophthalmol.* 2006;142(2):310–315.
13. Yamane T, Kaneko A, Mohri M. The technique of ophthalmic arterial infusion therapy for patients with intraocular retinoblastoma. *Int J Clin Oncol.* 2004;9(2):69–73.
14. Abramson DH, Dunkel IJ, Brodie SE, Kim JW, Gobin YP. A phase I/II study of direct intraarterial (ophthalmic artery) chemotherapy with melphalan for intraocular retinoblastoma initial results. *Ophthalmology.* 2008;115:1398–1404,1404.e1391.
15. Vajzovic LM, Murray TG, Aziz-Sultan MA, et al. Clinicopathologic review of enucleated eyes after intra-arterial chemotherapy with melphalan for advanced retinoblastoma. *Arch Ophthalmol.* 2010;128(12):1619–1623.
16. Aziz HA, Boutrid H, Murray TG, et al. Supraselective injection of intraarterial melphalan as the primary treatment for late presentation unilateral multifocal stage Vb retinoblastoma. *Retina.* 2010;30 Suppl 4:S63–S65.
17. Boutrid H, Wolfe SQ, Murray TG, et al. Bilateral orbital vasculature alterations after systemic chemotherapy and external beam radiation therapy treatment of advanced retinoblastoma: implications for intraarterial chemotherapy management. *Retin Cases Brief Rep.* 2010 Jan 15.
18. Brodie SE, Pierre Gobin Y, Dunkel IJ, Kim JW, Abramson DH. Persistence of retinal function after selective ophthalmic artery chemotherapy infusion for retinoblastoma. *Doc Ophthalmol.* 2009;119(1):13–22.

## Clinical Ophthalmology

### Publish your work in this journal

Clinical Ophthalmology is an international, peer-reviewed journal covering all subspecialties within ophthalmology. Key topics include: Optometry; Visual science; Pharmacology and drug therapy in eye diseases; Basic Sciences; Primary and Secondary eye care; Patient Safety and Quality of Care Improvements. This journal is indexed on

Submit your manuscript here: <http://www.dovepress.com/clinical-ophthalmology-journal>

Dovepress

PubMed Central and CAS, and is the official journal of The Society of Clinical Ophthalmology (SCO). The manuscript management system is completely online and includes a very quick and fair peer-review system, which is all easy to use. Visit <http://www.dovepress.com/testimonials.php> to read real quotes from published authors.