

Surgery of Intracerebral Hemorrhage

24

Regunath Kandasamy, Zamzuri Idris,
and Jafri Malin Abdullah

24.1 Introduction

Spontaneous intracerebral hemorrhage (ICH) due to uncontrolled hypertension is a common clinical entity that affects up to four million people annually [1]. Hemodynamic injury to perforating end arteries (100–400 μm) results in pathological lesions such as lipohyalinosis, fibrinoid necrosis, and Charcot-Bouchard microaneurysm which may predispose to rupture. Common locations where these hemorrhages may occur include the basal ganglia, pons, thalamus, cerebellum, or subcortical white matter (lobar) [2].

Despite numerous multicenter trials, debate still exists on the indication for surgery as well as exact benefits of this treatment modality. Advancement in technology has also provided a number of minimally invasive methods such as endoscopic and stereotactic aspiration for evacuation of clots. The superiority of any one of these methods over the others has still not been completely established.

In the course of training, a young neurosurgeon should be well versed in the basic surgical principles of managing a patient who presents with neurological symptoms due to an intracere-

bral hemorrhage. Despite the increasing popularity of minimally invasive methods, craniotomy remains a fairly safe and standardized method of clot removal and hemostasis under direct visualization. In cases of hemorrhage with significant perilesional edema, the option of removal of the bone flap may help relieve life-threatening brain shifts and elevation in intracranial pressure.

24.2 Rationale for Surgery

Surgical evacuation of the ICH is aimed at reducing mass effect caused by the clot. This in turn reduces intracranial pressure and prevents life-threatening brain shifts from occurring. The removal of clot also reduces biochemical as well as inflammatory processes that are initiated by toxic blood products.

At present the AHA consensus guidelines suggest that cerebellar hemorrhages >3 cm and supratentorial superficial lobar hemorrhages of >30 cc in volume will benefit from surgical evacuation [3]. Additionally, in our center, we practice the evacuation of superficial (within 1 cm from cortical surface) basal ganglia hemorrhages with significant mass effect in young (age <50 years) viable (GCS > 8) patients suffering from this condition.

Prior to proceeding with clot evacuation, it is imperative to rule out other etiological conditions which may result in intracerebral hemorrhage

R. Kandasamy · Z. Idris · J. M. Abdullah (✉)
Department of Neurosciences, Centre for
Neurosciences Services and Research, School of
Medical Sciences, Universiti Sains Malaysia Health
Campus, Kota Bharu, Kelantan, Malaysia

including aneurysms, vascular malformations, tumor with bleeds, or coagulopathy.

24.3 Signs and Symptoms

Clinical features attributed to an ICH can be divided into general symptoms related to the mass effect of the lesion as well as focal symptoms in relation to the anatomical area of the brain affected. Onset is usually sudden and progression of symptoms typically occurs in minutes to hours. The generalized effects of an ICH are due to dural stretching as well as elevation in intracranial pressure. Initial symptoms include headaches, nausea, vomiting, and blurred vision. Worsening brain shifts can result in deterioration in consciousness, abnormal breathing patterns, as well as motor posturing all related to impending herniation.

Focal symptoms as mentioned depend on the site of the bleeding. Lobar hemorrhages have symptoms related to the affected lobe including seizures, hemiparesis, visual field deficits, aphasia, or impaired higher cortical function. In the basal ganglia, a small clot may not manifest with overt neurological deficits. However, extension of the lesion to the thalamus or internal capsule may often result in hemiparesis or hemisensory loss and visual deficits.

Clots in the brain stem region result in cranial nerve impairment. Depending on which nerve is involved, the location of the bleed can often be predicted. Early onset of deterioration in consciousness with flexor or extensor motor posturing occurs when a brain stem bleed disrupts the reticular activating system as well as descending extrapyramidal tracts. Cerebellar hemorrhages on the other hand result in dizziness and vomiting and ataxia. If the clot size is large enough, consciousness may also be impaired due to direct compression of the brain stem.

About a third of patients with ICH will develop secondary intraventricular hemorrhage. In these cases, patients may also develop generalized symptoms due to hydrocephalus causing elevations in intracranial pressure.

A small percentage of patients remain asymptomatic particularly when the hemorrhage vol-

ume is small. Often, the only abnormal findings in this group of patients may be a sudden elevation in blood pressure despite being compliant to their regular medications.

24.4 Investigations

On initial assessment, patients suspected with ICH usually undergo a computed tomographic (CT) evaluation of their brain. When reviewing such a scan, it is important to take note of the following points:

1. Site of lesion and extension.
2. Dimension and volume ($A \times B \times C/2$).
3. Presence of mass effect, midline shift, as well as hydrocephalus.
4. Atypical features warranting further definitive investigation (*calcifications, perilesional edema incongruent with lesion or in terms of onset of clot development, tortuous vessels, subarachnoid hemorrhage, atypical location*).

If the patient's clinical or radiological features necessitate, further investigations should be performed prior to proceeding with intended surgery. Angiography or CT angiography can be performed to rule out vascular malformation or aneurysm rupture. MRI can be performed if a tumor with bleed is suspected. The surgical strategy and timing for surgery for these conditions may differ from that of a simple ICH, and one runs the risk of uncontrollable intraoperative bleeding or other serious complications if these conditions are not identified and addressed according to their respective treatment protocols.

Alternatively, a CT with contrast maybe performed as a preliminary evaluation. Keep in mind that despite the requirement for complete investigation to rule out the underlying cause for a bleed, it should not occur at the expense of the patient particularly in instances when life-threatening mass effect and herniation are in progress.

MRI with diffusion tensor imaging maybe useful to map out the location of the important motor and sensory fibers in relation to the clot to minimize intraoperative injury. This modality

however is often inappropriate for patients with acutely expanding hematomas due to the long duration required to perform this investigation.

Aside from the standard battery of radiological investigations, routine blood investigations such as blood counts, renal profile, coagulation profile, as well blood glucose are essential. It is particularly important that issues such as coagulopathy or thrombocytopenia are duly addressed. Patients with hypertensive ICH usually have a number of coexistent medical problems which may further complicate management. Failure to address these conditions may result in a non-favorable outcome in patients especially those undergoing surgery.

24.5 Preoperative Preparation

Having obtained informed consent from the next of kin, attention should be focused on blood pressure (BP) control, cross-matched blood availability, correction of coagulopathy, and withholding of any drugs which may worsen bleeding (antiplatelet, Coumadin derivatives, etc.). Patients with supratentorial particularly lobar ICH undergoing surgery are usually loaded with an antiepileptic agent due to potential cortical transgression. Antibiotic prophylaxis is also indicated during the time of induction of general anesthesia.

24.6 Steps of Surgery

Preoperative planning of the surgical approach is the key to success in any surgical procedure. It is important to review the preop images carefully in all three surgical planes before deciding on the best approach to use.

Points to consider include exact location and extent of the clot, proximity to eloquent brain regions, and usage of the shortest path with least injury to vital cortical areas. In patients with a lobar hemorrhage in the frontotemporal or basal ganglia region, a frontotemporal craniotomy will usually give adequate access to allow evacuation

of the clot. As for parietal or parieto-occipital clots, a more posteriorly placed craniotomy may be more appropriate. Cerebellar hemorrhages can be accessed using a midline or paramedian posterior fossa craniotomy.

To illustrate this point, we will use the clinical case of a typical basal ganglia hemorrhage as shown below.

24.6.1 Case Illustration

A 36-year-old male patient with a history of hypertension presented with sudden-onset weakness over the right side of his body with progressive deterioration in consciousness. He was admitted with GCS (Glasgow Coma Scale) of E2 V3 M5 = 10/15. His BP was recorded as 220/110 on admission. An urgent CT brain was performed as shown below (Fig. 24.1).

The CT scan revealed the presence of a large left-sided basal ganglia hemorrhage causing significant midline shift. The clot had extended to within 1 cm from the surface of the cortex. CT angiography did not reveal any underlying vascular etiology for this bleed. Patient underwent a frontotemporal craniotomy and evacuation of his clots. Following craniotomy and dural opening, one may use one of the three routes to reach the clot. The three routes include either trans-sylvian or via the prefrontal or superior temporal gyri (Fig. 24.2). The choice of the routes would depend on the characteristics of the clot as well clinical condition. The trans-sylvian method is an advantage because only the insular cortex is transgressed during surgery compared to the frontal or temporal cortex where more neurological deficits may occur. Sylvian fissure splitting and dissection can be time consuming in inexperienced hands and difficult in cases where brain swelling is apparent. In this patient given the degree of brain edema, a clot evacuation using the prefrontal cortex was opted for. Due to poor clinical state on admission and intraoperative finding of brain swelling, it was opted to not replace his bone flap after surgery.

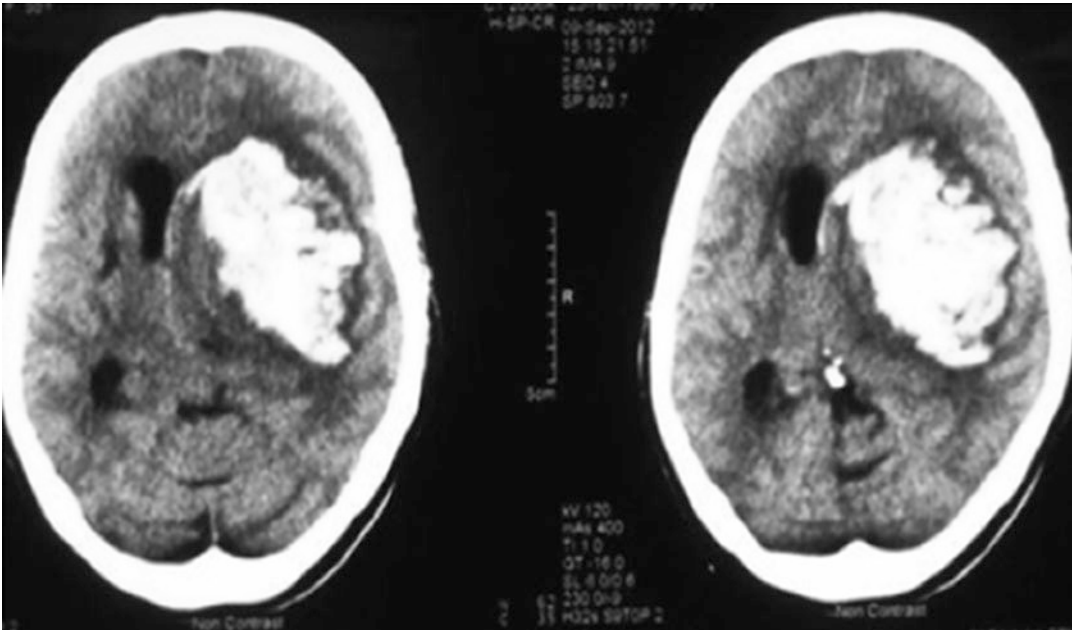
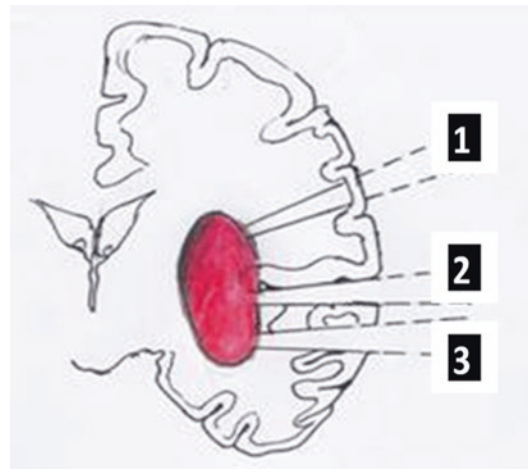


Fig. 24.1 Axial CT brain of the patient

Fig. 24.2 Diagrammatic representation of the surgical corridors that can be utilized for clot evacuation: (1) via the prefrontal cortex, (2) via the Sylvian fissure, and (3) via the superior temporal gyrus



24.6.2 Positioning and Skin Incision

In supratentorial clot evacuation, patients are placed supine with their heads, elevated about 30°, and rotated away from the side of the clot. The patient's head can be fixed in a rigid fixation device (Mayfield clamp) or supported on a horse-shoe. Always ensure that the neck is not excessively flexed as this may impair venous outflow from the head (Fig. 24.3).

For clots, predominantly in the frontal region, a hemi-coronal skin incision behind the hairline is usually adequate for exposure. An inverted question mark-shaped incision is however advised when attempting to remove a large ICH. It would allow adequate access to the region of interest without hindrance due to brain swelling.

24.6.3 Flap Elevation and Craniotomy

The skin flap is secured with Raney clips, and the flap raised in two layers to create a mobile fascial flap for later dural closure. The craniotomy is fashioned around three to four entry burr holes and the bone flap is elevated. Once the flap has been elevated, secure hemostasis from dural vessels and perform peripheral tenting (Figs. 24.4 and 24.5).

24.6.4 Dural Opening

The opening of the dura can be performed in a cruciate manner or as a “U”-shaped flap. A size “11” blade or metzenbaum scissors can be used for this. Ensure that the underlying surface of the brain is lined with patties after initial durotomy to avoid

possible cortical injury during extension of the dural flap. If the brain is very swollen, an osmotic diuretic may be used or CSF diversion performed if intraventricular hemorrhage or hydrocephalus is present on preoperative imaging.

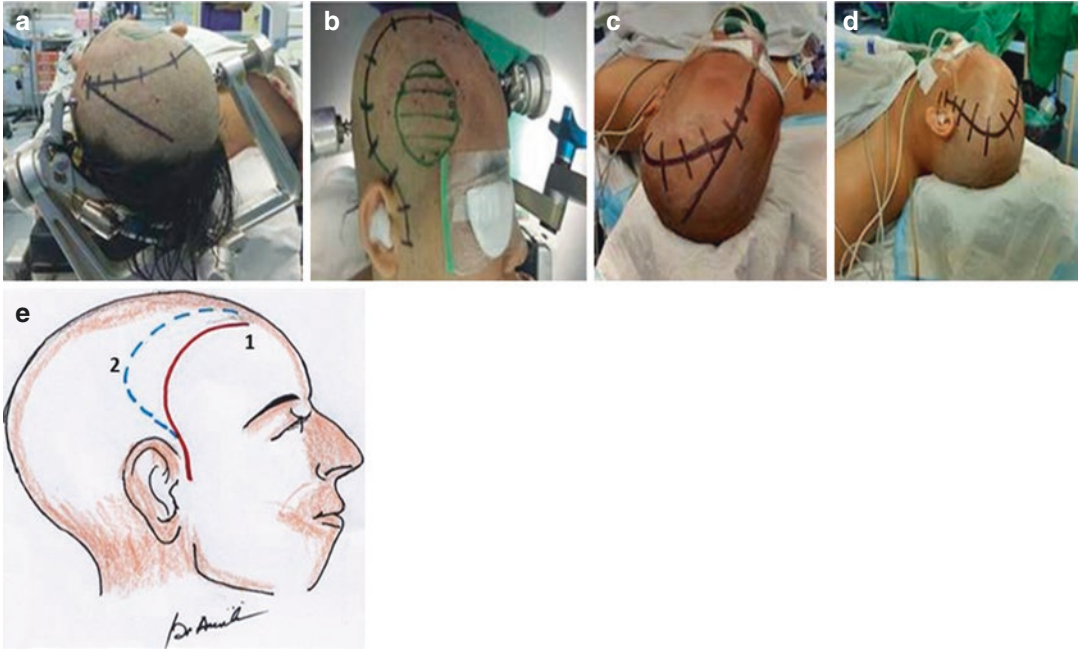


Fig. 24.3 (a, b) Patient with a frontal lobar hemorrhage with head fixed in a Mayfield device and skin incision fashioned in a question mark shape. (c, d) Head placement on a horseshoe clamp for a left basal ganglia hemor-

rhage evacuation. (e) Diagrammatic representations of (1) frontotemporal and (2) question mark incisions that can be used for this surgery

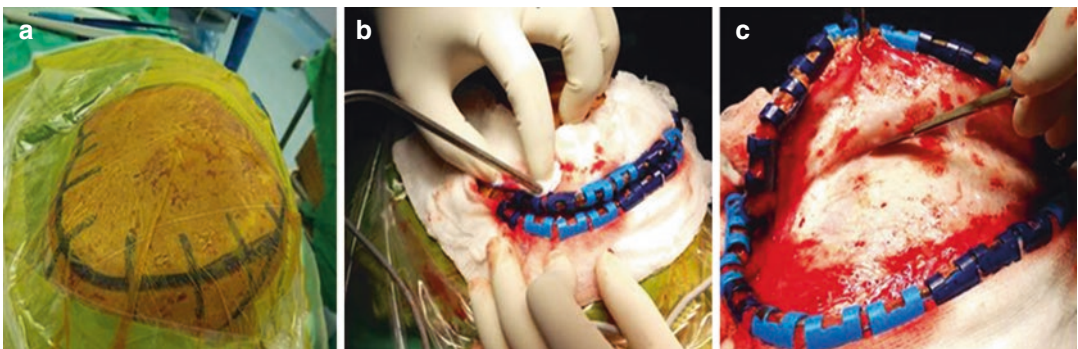

Fig. 24.4 (a–c) Skin flap is marked, draped, and subsequently elevated. Skin edges are secured using Raney clips, and elevation of flap is performed as shown

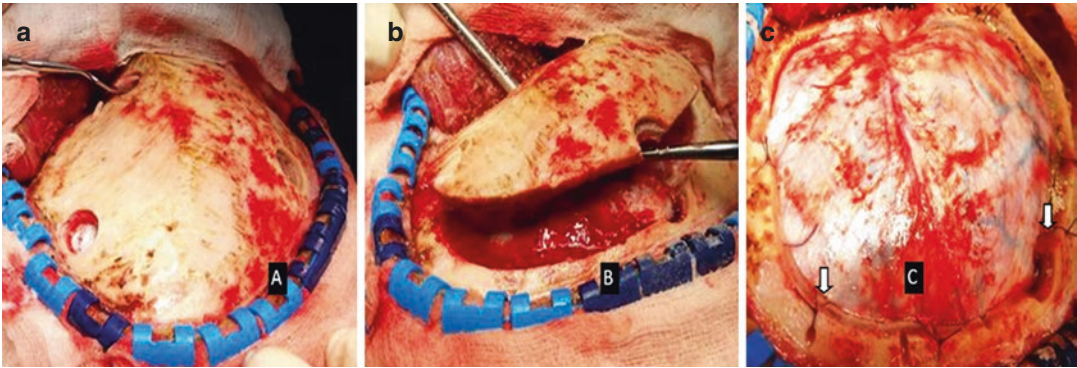


Fig. 24.5 (a) Three burr hole are made starting with one over the MacCarty keyhole followed by the temporal region just posterior to the zygomatic root as well over the frontal region anterior to the coronal suture. The dural adhesion to the bone should be released using a blunt dis-

sector prior to cutting the bone flap. (b) The flap is elevated while freeing the dural attachment to the bone. (c) After elevating the flap, hemostasis is secured by waxing the bone edges and applying tenting sutures peripherally (*white arrow*)

24.6.5 Corticotomy

The decision on how to approach the clot is an important one in view of the morbidity that may result from injury to eloquent brain regions. For basal ganglia clot, we advise an approach via the prefrontal or superior temporal gyrus cortex to minimize disruption of eloquent brain areas (Fig. 24.6). Alternatively, a trans-sylvian approach might be utilized to access a deep-seated clot if brain swelling is not very apparent. Prior to attempted corticotomy, it is wise to use a brain needle to confirm the localization of the clot and subsequently use the tract created by the needle to reach the lesion. This will prevent misadventures due to improper localization that may occur in inexperienced hands. Alternatively, intraoperative ultrasonography may also be used for clot localization. Often, superficial clots may themselves have extended and breached the cortical surface, and in these cases, one should utilize the pre-created path of the clot for evacuation. Once clot location has been confirmed, the operating microscope should be utilized for clot evacuation (Fig. 24.7).

24.6.6 Clot Evacuation

Clots can be removed using gentle suction with irrigation. A teardrop suction device at a

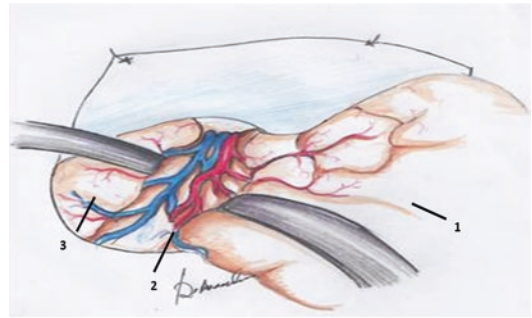


Fig. 24.6 Sites for Corticotomy depending on the surgical approach used: (1) via the prefrontal cortex, (2) via the Sylvian fissure, and (3) via the superior temporal gyrus

setting of 100 Kpa is usually very helpful in this setting. It is imperative that clots are removed patiently and slowly in a spiral movement to prevent injury to the surrounding brain. Initially, the liquefied portion of clot can be easily removed. The harder portions may need to be dissected off adjacent the parenchyma prior to successful removal. Dislodged larger clots may be removed using a biopsy of grasping forces. Once the clot has been removed, the raw edges of the brain are usually visible. The aim of this surgery is to remove as much clot as possible to relieve the mass effect. With this in mind, we personally endeavour to remove as much clot that is safely possible due to the fact that aside from direct

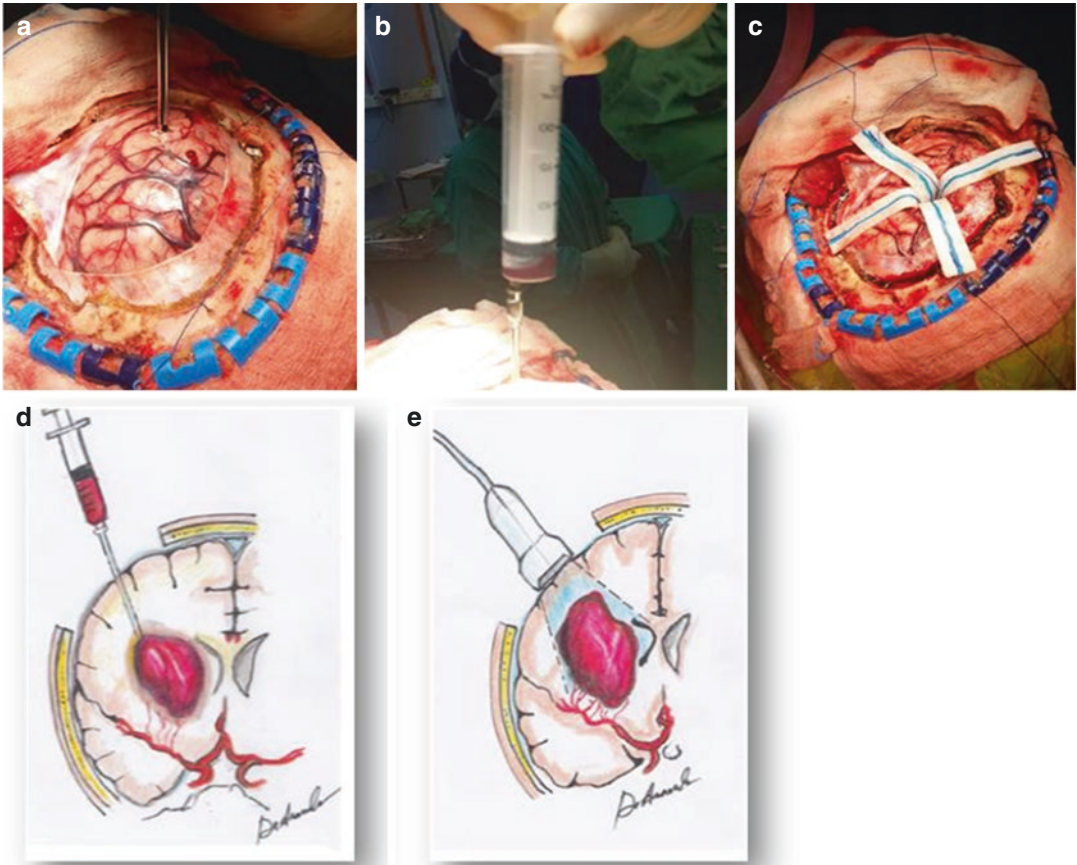


Fig. 24.7 (a, b) Localization of clots using a brain needle and aspiration. (c) Once located, the corticectomy is performed following the trajectory of the needle to the clot.

(d, e) Diagrammatic representation of clot localization using a brain needle or an intraoperative ultrasound probe

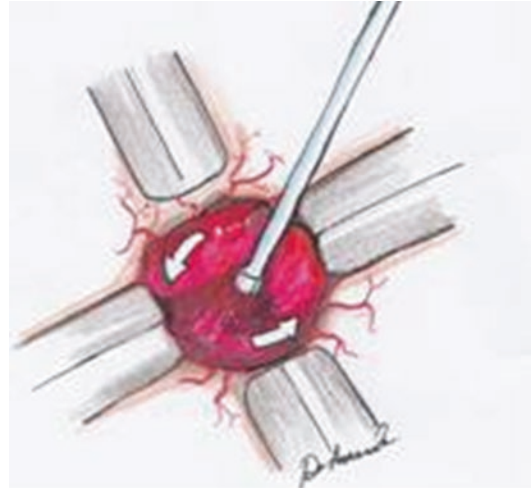
mass effect, blood product left in the brain may also be responsible for pro-inflammatory chemical responses that result in persistent brain edema (Fig. 24.8).

24.6.7 Hemostasis

Following clot removal, the authors find that the extent of oozing within the cavity usually significantly reduces. Utilizing cotton pledgets or cotton balls, the cavity can be packed and irrigated with warm saline to stop minimal oozes and to identify overt bleeding vessels. Bleeding sites are best identified and secured

by moving from the periphery and walls of the cavity to the base in a systematic manner. It is usually necessary to cauterize the actively bleeding stumps of the end arteries in hypertensive hemorrhages. The cavity is then lined with a mechanical hemostatic agents such as “Surgicel or Fibrillar.” Finally, the cavity is again irrigated with warm saline to confirm hemostasis. It is wise to confirm, at this point, the patient’s BP reading to ensure that it is not too low. BP can be transiently increased to identify bleeding points; however, this should be performed with great caution, and not excessively lest significant re-hemorrhage occurs.

Fig. 24.8 Methods of suctioning and clot aspiration in a spiral manner



24.6.8 Closure and Bone Flap Replacement

Dural closure can be performed primarily or using durofasciaoplasty. A continuous suturing method is advocated to achieve a watertight closure. The bone flap is then replaced and secured in place. Skin and soft tissue are closed in layers in a routine fashion. In cases where brain swelling may be significant, replacement of the bone flap may not always be advisable. Performing a craniectomy together with clot evacuation has been noted in some series to improve outcome in patients with putaminal hemorrhage in a subset of patients who exhibit brain swelling [4]. Pure decompression alone however without clot evacuation has been found to have limited benefits. In performing a craniectomy, the surgeon should be aware that the size of the bony defect should be large enough to achieve adequate decompression. The middle fossa flow should be removed to ensure that the incisura and brain stem are relieved from pressure. To achieve this, a large skin incision may be required, and it is the reason that we advocate using a question mark incision in cases where brain swelling might be anticipated.

24.7 Surgeon Plan to Handle the Complication

As with any neurosurgical procedure, evacuation of ICH can be complicated by a spectrum of problems. Specific to this procedure, the important complications include the following:

24.7.1 Intraoperative Brain Swelling

Brain swelling may be encountered at different stages of the surgery. The strategy of management differs slightly in each circumstance. The occurrence of brain swelling at the outset of dural opening can often be predicted based on features such as delayed presentation, poor GCS scores, large clot volume, and significant midline shift. Even in patients with moderate-sized clots on imaging, intraoperative brain swelling is still possible due to clot expansion during the interim period of going to the operation room and induction of anesthesia. One common cause for expansion relates to poorly controlled BP. Thus, it is very important to ensure that the patient's BP is constantly monitored and adequately controlled. If a significant deterioration of the patient's GCS

occurs prior to transfer to the OR, a CT scan can be performed to elucidate the extent of expansion or if hydrocephalus has developed (*but not at the expense of timely surgical intervention*). In cases like these, the surgical strategy should also include decompression and/or CSF diversion aside from clot evacuation.

If brain swelling is encountered during or after clot evacuation, firstly ensure that hemodynamic parameters such as BP and PCO₂ are normal. Additionally, CSF diversion can also be performed if a search of the clot cavity post evacuation reveals no evidence of a new clot formation.

24.7.2 Re-accumulation of Clots

After clot evacuation, rebleeding with recollection may occur immediately or in a delayed manner. If it occurs intraoperatively, it may be heralded by brain swelling, and the surgeon can usually reexplore the clot cavity and evacuate it. In the postoperative period, re-accumulation of clots is often associated with elevations in blood pressure which were not adequately addressed. They may come to attention during routine postoperative CT scanning or due to deterioration in the patient's conscious level after initial recovery. If needed, then a repeat surgery may be required to remove the new clot.

24.7.3 Hydrocephalus

In patients with intraventricular extension of their ICH, hydrocephalus may occur early or late depending on the extent and location of blood in the ventricular system. Patients with hydrocephalus at the outset should get early CSF diversion. Alternatively, the hydrocephalus may manifest as brain swelling intraoperatively or in the postoperative period during patient recovery. A patient who develops a subgaleal CSF collection or leak should be investigated to rule out underlying hydrocephalus. Permanent CSF diversion is usually not necessary for a majority of patients, and

these can be managed using temporary diversion methods.

24.7.4 Injury to Parenchyma During Clot Evacuation

It is advised that a microscope be used for clot evacuation to enable clear differentiation between the clot and adjacent brain. Gentle suction and irrigation are to be used during clot evacuation. If any large vessels are seen during surgery, cover them with a thin layer of hemostatic material and patties to avoid inadvertent injury during clot removal.

24.8 Expert Opinion to Avoid Complications

- Review all investigations prior to surgery.
- Plan surgical approach based on CT imaging.
- Anticipate brain swelling and plan early measures to alleviate it.
- Plan skin flap, keeping in mind the need for a larger bone flap in some patients.
- Localize clot using a brain needle.
- Gentle clot evacuation assisted by microscope.
- Check operative field to ensure hemostasis prior to closure.
- Maintain judicious blood pressure control in postoperative period.

Do not forget hydrocephalus as a cause for delayed duration or operative wound CSF leak.

24.9 Postoperative Care and Follow-Up

Following surgery, patients should be monitored in an intensive care setting with hourly assessment of vital signs and neurological status. Careful attention to BP readings is vital to prevent postoperative re-accumulation of clots. If patients have significant brain swelling intraop-

eratively, postoperative sedation and weaning after repeat CT scanning are advisable.

References

1. Van Asch CJ, Luitse MJ, Rinkel GJ, van der Tweel I, Algra A, Klijn CJ. Incidence, case fatality, and functional outcome of intracerebral haemorrhage over time, according to age, sex, and ethnic origin: a systematic review and meta-analysis. *Lancet Neurol.* 2010;9:167–76.
2. Siddique SM, Mendelow AD. Surgical treatment of intracerebral haemorrhage. *Br Med Bull.* 2000;56:444–56.
3. Morgenstern LB, Hemphill JC, Anderson C, et al. Guidelines for the management of spontaneous intracerebral hemorrhage: a guideline for healthcare professionals from the American Heart Association/American Stroke Association. *Stroke.* 2010;41:2108–29.
4. Hayes SB, Benveniste RJ, Morcos JJ, Aziz-Sultan MA, Elhammady MS. Retrospective comparison of craniotomy and decompressive craniectomy for surgical evacuation of nontraumatic, supratentorial intracerebral hemorrhage. *Neurosurg Focus.* 2013;34:E3.

Open Access This chapter is licensed under the terms of the Creative Commons Attribution 4.0 International License (<http://creativecommons.org/licenses/by/4.0/>), which permits use, sharing, adaptation, distribution and reproduction in any medium or format, as long as you give appropriate credit to the original author(s) and the source, provide a link to the Creative Commons license and indicate if changes were made.

The images or other third party material in this chapter are included in the chapter's Creative Commons license, unless indicated otherwise in a credit line to the material. If material is not included in the chapter's Creative Commons license and your intended use is not permitted by statutory regulation or exceeds the permitted use, you will need to obtain permission directly from the copyright holder.

