

# We are IntechOpen, the world's leading publisher of Open Access books Built by scientists, for scientists

5,900

Open access books available

145,000

International authors and editors

180M

Downloads

Our authors are among the

154

Countries delivered to

TOP 1%

most cited scientists

12.2%

Contributors from top 500 universities



WEB OF SCIENCE™

Selection of our books indexed in the Book Citation Index  
in Web of Science™ Core Collection (BKCI)

Interested in publishing with us?  
Contact [book.department@intechopen.com](mailto:book.department@intechopen.com)

Numbers displayed above are based on latest data collected.  
For more information visit [www.intechopen.com](http://www.intechopen.com)



# Surgical Prevention of Arm Lymphedema in Breast Cancer Treatment

Corradino Campisi, Corrado C. Campisi and Francesco Boccardo  
*Department of Surgery – Unit of Lymphatic Surgery,  
S. Martino Hospital, University of Genoa,  
Italy*

## 1. Introduction

Disruption of the axillary nodes and closure of arm lymphatics can explain the significantly high risk of early and late lymphatic complications after axillary dissection, especially the most serious complication that is arm lymphedema which occurs in about 25% (ranging from 13 to 52%) of patients. Sentinel lymph node (SLN) biopsy has reduced the severity of swelling to nearly 6% (from 2 to 7%) and, in case of positive SLN, complete axillary dissection (AD) is still required. That is why ARM method was developed aiming at identifying and preserve lymphatics draining the arm. It consists in injecting intradermally and subcutaneously a small quantity (1-2 ml) of blue dye at the medial surface of the arm which helps in locating the draining arm lymphatic pathways. ARM technique allowed to find variable clinical anatomical conditions from what was already generally known, that is the most common location of arm lymphatics below and around the axillary vein. In about one-third of the cases, blue lymphatics can be found till 3-4 cm below the vein, site where SLN can easily be located, justifying the occurrence of lymphedema after only SLN biopsy. ARM procedure showed that blue nodes were almost always placed at the lateral part of the axilla, under the vein and above the second intercostals brachial nerve. Leaving in place lymph nodes related to arm lymphatic drainage would decrease the risk of arm lymphedema, but not retrieving all nodes, the main risk is to leave metastatic disease in the axilla. Conversely, arm lymphatic pathways when they enter the axilla, cannot be site of breast tumoral disease and their preservation would certainly bring about a significant decrease of lymphedema occurrence rate (1-4).

## 2. Lymphangiogenesis and other local changes

Another important aspect to point out is that, in the axilla, new lymphatic vessel formation (lymphangiogenesis) occurs in response to the ligation of lymphatic vessels involved in lymph node retrieval. Lymphangiogenesis and lymphatic hypertension were demonstrated experimentally in case of lymphatic drainage obstruction. And, in response to lymphatic hypertension, lympho-venous shunts open and provide alternative lymphatic pathways when the main ones are obstructed. These mechanisms represent an adaptive response to lymphatic hypertension but are not enough to restore normal flow parameters. Furthermore, chronic obstruction to lymph flow progressively leads to a reduced lymphatic

contractility, lymphatic thrombosis and fibrotic changes, at a different degree according to variable constitutional predisposition (5-9)

### 3. Surgical preventive procedures

Recent advances in the treatment of breast cancer, specifically as concerns the prevention of lymphatic complications following sentinel lymph node biopsy and axillary dissection brought to the proposal of a new technique to primarily prevent lymphedema by microsurgical lymphatic-venous anastomoses. ARM technique allows to identify arm lymphatics and lymph nodes which can therefore be preserved even though there is the risk to leave undetected metastatic disease in the axilla. But, it is almost impossible to preserve efferent lymphatics from the blue nodes because they join the common axillary nodal basin draining the breast. Thus, not preserving efferent lymphatics makes practically impossible to preserve arm lymphatic flow. So, on the basis of our wide experience in the treatment of lymphedema by microsurgical lymphatic-venous anastomoses (LVA), we thought to perform LVA immediately after finishing nodal axillary excision. The surgical technique proposed for patients with operable breast cancer requiring an axillary dissection consisted in carrying out LVA between arm lymphatics identified by injecting blue dye in the arm and an axillary vein branch simultaneously (Lymphatic Microsurgical Preventive Healing Approach - LY.M.P.H.A.) (10). It is almost always possible to find blue lymphatics and also to find a vein branch long enough to be connected to arm lymphatics which are usually locate very laterally.

Patients are followed up both clinically by volumetric assessment and by lymphangioscintigraphy performed before surgery and after 18 months. Blue nodes in relation to lymphatic arm drainage can be identified in almost all patients after blue dye injection at the arm. All blue nodes must be resected and 2 to 4 main afferent lymphatics from the arm can be prepared and used for anastomoses. Lymphatics are introduced inside the vein cut-end by a U-shaped stitch. Other few stitches are given to fix the lymphatic adventitia to the vein wall. The operation takes only 15-20 minutes averagely, since both lymphatics and the vein are prepared during nodal dissection. LVA proved not only to prevent lymphedema but also to reduce early lymphatic complications (i.e. lymphorrhea, lymphocele) thanks to the reduced regional intralymphatic pressure. Drain tubes can be removed after about 7-10 days at the utmost. Post-op lymphangioscintigraphy allowed to demonstrate the patency of microvascular anastomoses after over 1 year and half from operation.

### 4. Clinical experience

#### *Study design*

Among forty-nine consecutive women from March 2008 to September 2009 addressed to complete AD, performed by surgeons of the same Breast Unit, who used the same technique, 46 were randomly divided in two groups, the other 3 were not analyzed because refused to perform lymphoscintigraphy (LS) pre-operatively. Twenty-three underwent LYMPHA technique, performed by a surgeon skilled in lymphatic microsurgery, for the prevention of arm lymphedema (LYMPHA group - LG). The other 23 patients had no preventive surgical approach (control group - CG). No wrapping neither compression therapy was used in any of the patients of both groups.

The average age was 57 years (range 39-80 years). In order to be included in this prospective study, patients with unilateral breast cancer had to be addressed to complete AD due to clinically or ultrasonographic positive axillary lymph nodes or positive SLN. Exclusion criteria were cases in whom only SLN biopsy technique was performed and SLNs were negative.

In the LYMPHA group (LG), 16 patients there were lymph nodal metastasis and therefore lymphatic venous anastomosis were performed during the primary surgery together with breast cancer treatment, sentinel lymph node biopsy, intraoperative frozen sections (showing the metastasis) and axillary dissection (AD). In other 7 patients there were no lymph nodal metastasis demonstrated by intraoperative frozen sections and therefore LYMPHA technique was planned after finding micrometastasis by following immunohistochemical investigations. Thus, in this last group of patients we could perform LYMPHA during the complete lymph nodal dissection in the second time surgery.

#### *Operating technique*

Patients signed a specific consent form indicating the kind of operation, possible risks, and complications to participate or not in the LYMPHA procedure. The blue dye (Lymphazurin) was injected in the volar surface of the upper third of the arm in a quantity of about 1-2 ml intradermally, subcutaneously and under muscular fascia. Usually after 5-10 minutes it is already possible to visualize arm blue lymphatics. Axillary nodal dissection was performed usually starting far from the upper lateral part of the axilla which was removed nearly at the end of the dissection in order not to damage the lymphatic pathways coming from the arm. These lymphatics were temporally clipped near their afference to the nodal capsule and thus prepared for anastomosis.

During lymph nodal dissection also one or two collateral branches of the axillary vein are prepared with a length suitable for reaching the lymphatic vessels. The microsurgical technique of lymphatic venous anastomosis has already been described (11). The vein was averagely 2 mm in diameter and lymphatics about half mm. the number of lymphatics anastomosed varied from 2 to 4. The technique is the "sleeve" procedure: lymphatics are put into the vein cut-end. A collateral of the axillary vein is used for anastomoses. In some cases a big gap inbetween the vein and the lymphatics can be found, but in these cases it is usually enough to better dissect the vein and above all the lymphatics from the surrounding tissues. In case it is necessary one of the subscapular or thoraco-dorsal veins which are usually long enough can also be used. A particular attention must be paid in placing the drain tube in order not to damage the anastomosis (Fig.1). Lymphatic-venous anastomoses take only 15-20 minutes to be performed and in our study were performed by a surgeon skilled in lymphatic microsurgery. There is no increased rate of blood loss, wound infection and seromas compared to standard ALND (Fig. 2).

#### *Clinical and lymphoscintigraphic assessment*

All patients of the two groups were preoperatively studied clinically by volume measurements (using the formula of a truncated cone according to Kuhnke method) (10) and by lymphoscintigraphy. Lymphedema, was defined as a difference in excess volume of at least 100 ml compared to preoperative VOL measurements. The follow up included volumetry at 1, 3, 6, 12 and 18 months postoperatively in both groups.

Lymphoscintigraphy was carried out in 21 cases in the LG and in 20 cases of the CG after 18 months postoperatively (Fig. 3).

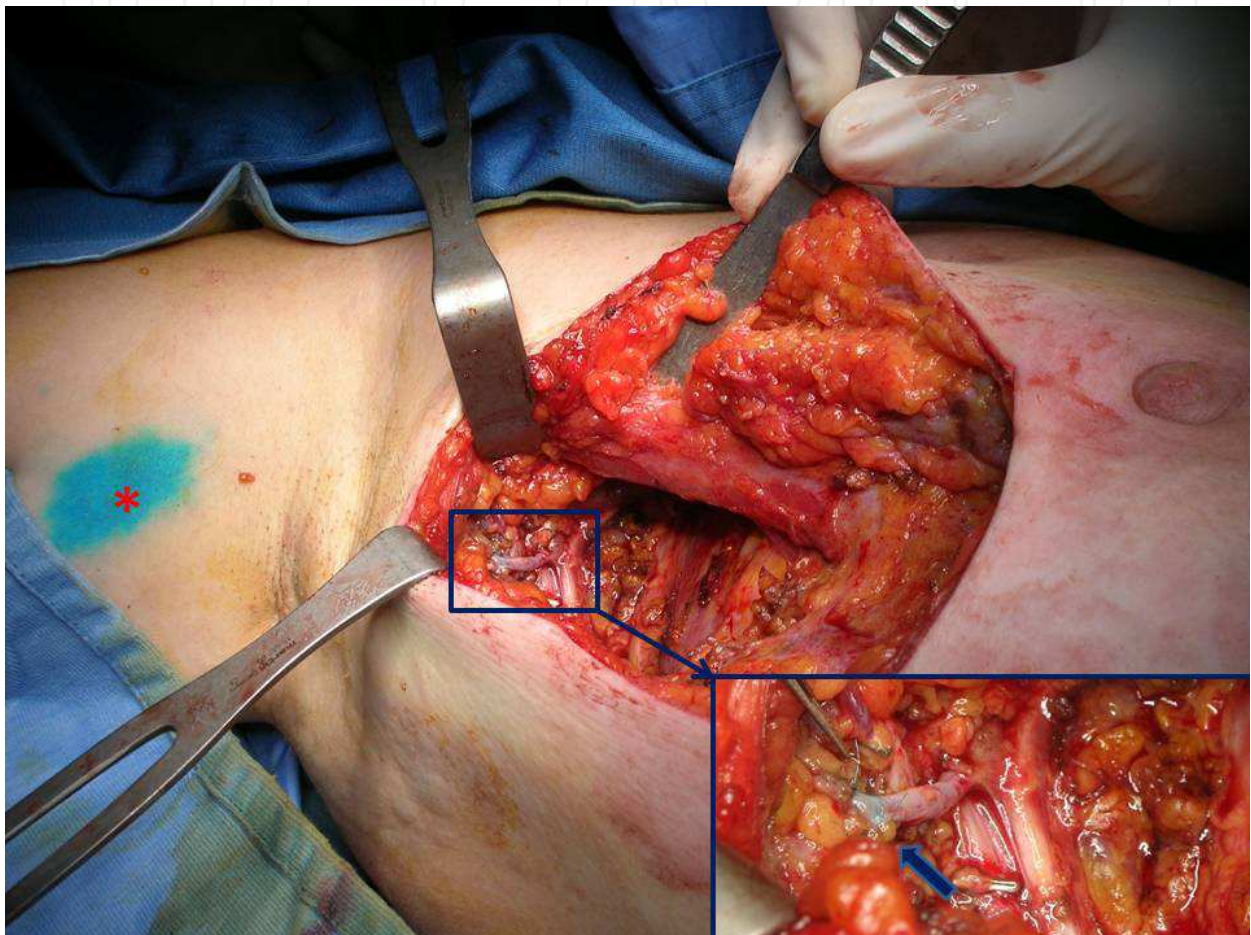


Fig. 1. Lymphatic-venous-anastomoses (rectangle) to prevent arm lymphedema (LYMPHA). Note the blue dye (\*) injected at the upper third of the volar surface of the arm to visualise arm lymphatics. The patency of lymphatic-venous anastomosis is proved by the passage of the blue dye into the vein branch (arrow).

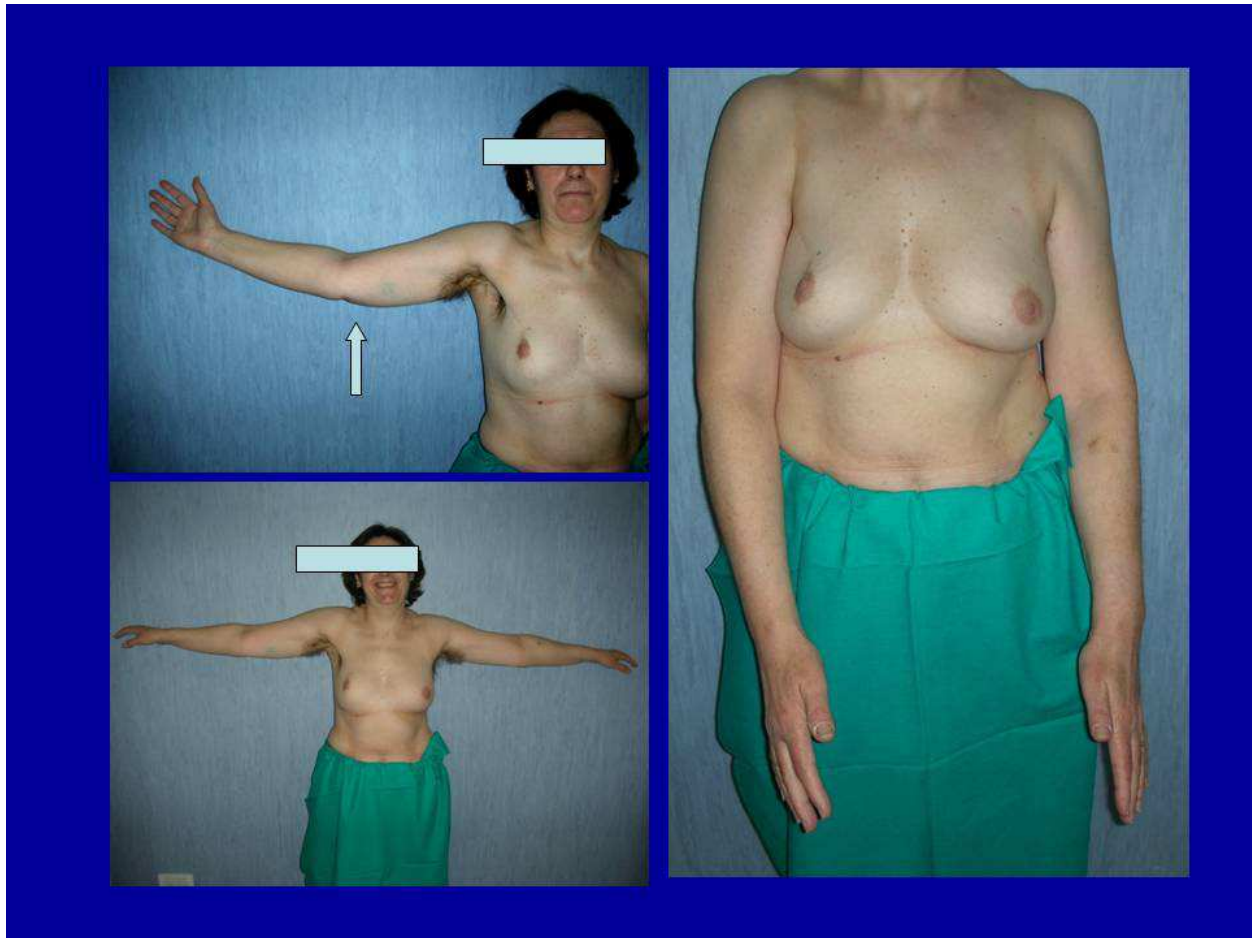


Fig. 2. Patient who underwent axillary lymphnodal dissection and primary surgical prevention of secondary lymphedema by LYMPHA procedure.

#### *Statistical analysis*

Non-parametric tests were used to explore the variable relationships between groups and between timing. The comparison between groups of quantitative variables age, BMI, Preop LS, lymphonodes retrieved, metastatic lymphonodes (MLS LN) and volume at baseline was performed using Wilcoxon test. Nominal baseline variables surgical procedure, radiotherapy and presence of cellulitis were compared using Chi square or Fisher's Exact Test.

The comparison of difference between baseline and volume after 1, 3, 6, 12 and 18 months from operation in LG and CG was performed using Wilcoxon test (between groups) and matched pair test (between timing). The volume difference between baseline and different timing in LG and CG was represented by box plots showing 10°, 25°, 75° and 90° percentiles. Number of patients with lymphedema, defined as a difference in excess volume of at least 100 ml, at 18 months in PG and CG were compared using 2-sided Fischer's Exact Test.

#### *Results*

Lymphedema appeared in 1 patient in the LG after 6 months from the operation (4,34 %) and persisted till 18 months later. It occurred in a patient who underwent radiotherapy and became stable with time without any inflammatory complications. In the CG lymphedema occurred in 7 patients (30,43 %) and appeared mostly after 3 months from operation.

Beginning from month 3, the proportion of patients with lymphedema was statistically higher in CG (p-value=0.047). Table 1 summarizes baseline characteristics of all participants, according to treatment group. There were no significant differences between the two groups in the baseline values of measures of demographic and anthropometric data, in disease characteristics and in type of surgery, and in the proportion of women who undertook to radiotherapy and had a cellulitis. In Figure 4, volume difference between baseline and different timing in LG and CG is represented by box plots showing 10°, 25°, 75° and 90° percentiles.

When compared with previous volume measure, no significant difference in the arm volume were observed in LG during follow-up, while the arm volume in CG showed a significant increase after 1 (mean difference 11.61 ml, S.E. 3.87, p-value<0.01) , 3 (mean difference 22.82 ml, S.E. 5.9, p-value<0.01) and 6 months (mean difference 31.56 ml, S.E. 5.78, p-value<0.01) from operation. No significant changes in arm volume were observed at month 12 and 18, in comparison with data registered at month 6 and 12, respectively, in CG. Significant higher volume with respect to baseline after 1, 3, 6, 12 and 18 months from operation (every timing p-value<0.01) was detected in CG in comparison with LG.

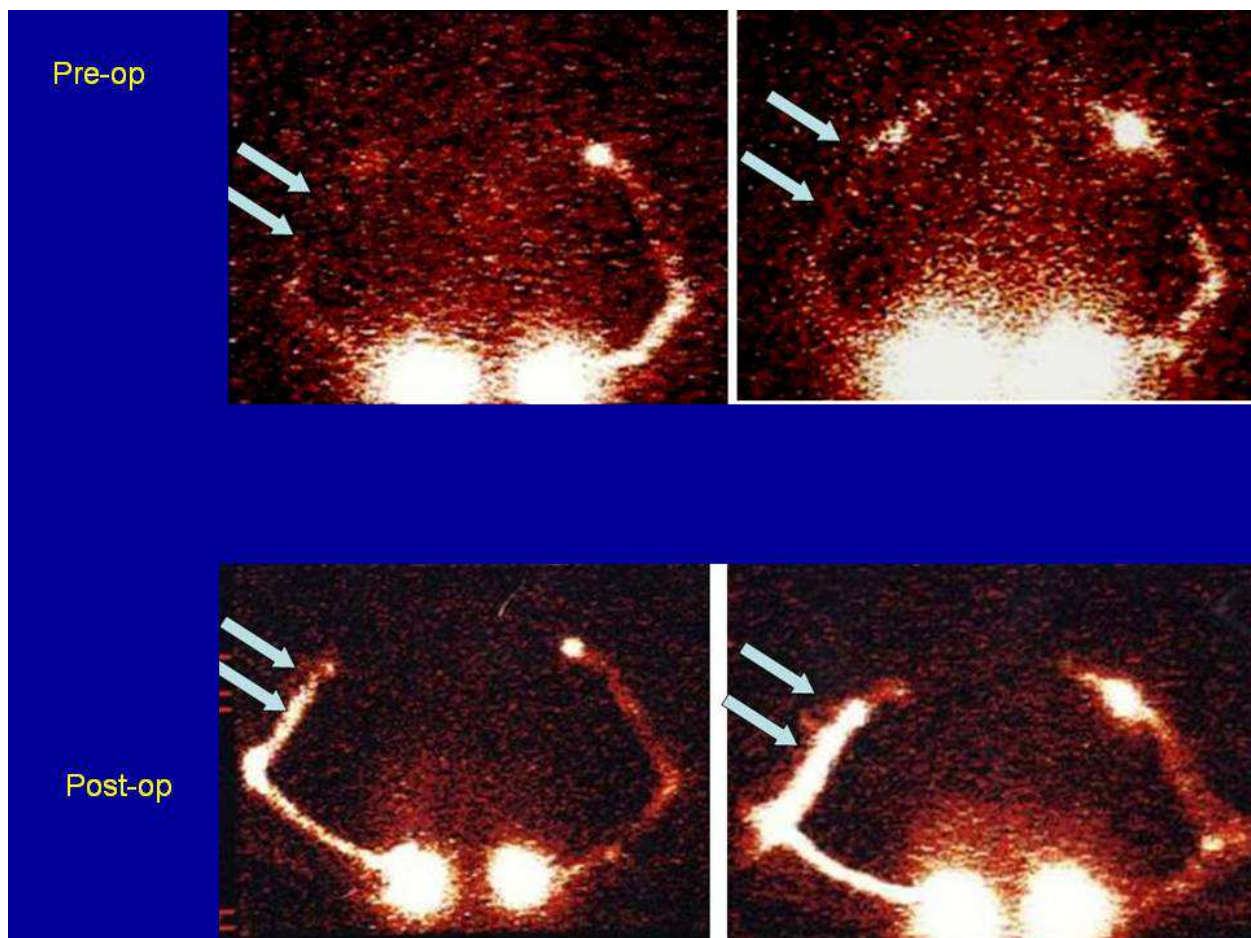


Fig. 3. Lymphoscintigraphic patterns before and after axillary lymphnodal dissection associated with LYMPHA technique.

Duplex scan allowed to exclude a venous pathology in all patients. LS allowed to confirm the lymphostatic nature of the edema. To quantify visual findings in LS, the Kleinhaus transport index (TI) was used (4,13,14). The TI includes the following parameters: transport kinetics (K), distribution of the tracer (D), appearance time of lymph nodes in minutes (T), visualization of lymph nodes (N), visualisation of lymph vessels (V);  $TI = K + D + (0,04 \times T) + N + V$  (Table 2). Normal lymphoscintigraphy pattern corresponded to TI less than 10. An impaired LS pattern in our study had a mean TI of 16 (range 12-19).

Moreover, pre-operatively LS had a significant predictive value (TI) in terms of risk of lymphedema appearance. To this regard LS proved to be an instrumental criteria to select patients at risk for secondary lymphedema.

Post-operatively LS demonstrated the patency of microlymphaticvenous anastomosis (patency rate: 95,6%) both through direct (visualization of preferential lymphatic pathway, disappearance of the tracer passing into the blood stream) and indirect (early liver uptake of the tracer) parameters in the LG group. In the CG on the other hand LS allowed to point out lymphatic drainage impairment in patients with secondary lymphedema.

## 5. Discussion

Notwithstanding the wide variability in lymphedema prevalence, the incidence of secondary arm lymphedema is significant. Sentinel lymph node biopsy (SLNB) was introduced and carried out to prevent lymphedema but, recent studies demonstrated that even with SLNB alone lymphedema rates are not negligible (13,17).

Therefore, prevention is of key importance to avoid lymphedema occurrence.

Axillary Reverse Mapping (ARM) procedure represents an attempt to identify and preserve arm lymphatic drainage. Success of this technique in preventing lymphedema will require ongoing follow-up and studies (6). Blue nodes were always located in the same position, at the lateral part of the dissection, under the axillary vein and just above the second intercostal brachial nerve (7). The main issue remains to make sure that the nodes identified are not metastatic and can be preserved during AD. Since the lymphatic pathways from the arm cannot be involved by metastatic process of the primary breast tumor, its preservation should not imply any risk of leaving undetected diseases in the axilla (1). With ARM technique the detection rate of blue lymphatics and nodes is 61-71%, and the preservation rate of 47% (1,6,7). The question is: can we spare what we find? The identification of afferent lymphatics and nodes belonging to the arm lymphatic pathways appears feasible. Nevertheless, the identification of the efferent lymphatics, which is mandatory to truly preserve the lymphatic flow of the arm, is almost impossible since the lymphatics departing from the blue nodes join the common lymphatic pathways draining the breast. Therefore, the preservation is practically impossible. That's why we conceived and carried out LYMPHA technique, which consist in performing LVA between arm lymphatics and collateral branches of the axillary vein at the same time as AD. Lymphatic-venous anastomoses are performed at the upper lateral part of the axilla, thus somehow protected from the negative effect of postop radiation. In fact, postop radiation did not cause any relevant problem in the patients with lymphatic-venous anastomoses in this study. Only in two patients, a transitory (for 3 and 5 days respectively) slight arm edema was observed which disappeared spontaneously. Patients were followed by volume measurements which allowed to demonstrate the absence of any negative effect of postop radiation. Furthermore, postop lymphoscintigraphy proved the patency of anastomoses long after surgery and



radiation. The preservation of arm lymphatics carries no risk of leaving disease in the axilla undetected, and it permits the prevention of lymphedema (10). Patients candidate for LYMPHA are those one addressed to AD with either clinical axillary N+ or SLN+. In pre-operative patients selection for LYMPHA clinical and instrumental criteria were evaluated (Fig.4).

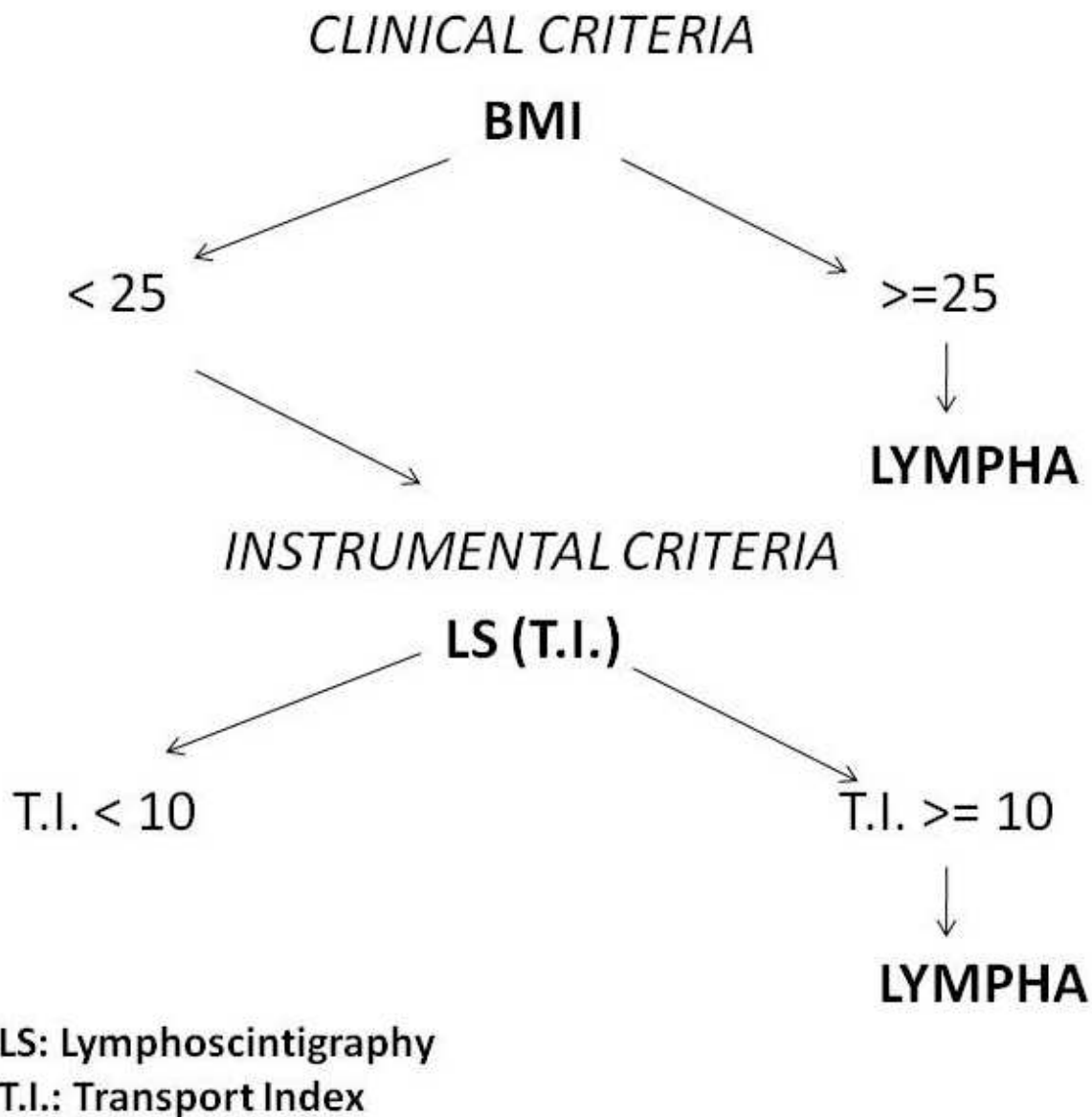


Fig. 4. Clinical and instrumental criteria to select patients for LYMPHA technique

History and physical examination of the patients, together with BMI, could allow to select patients at risk for lymphedema and this suspect could be confirmed by LS, using semiquantitative evaluation which is represented by TI (15-19). Preop lymphoscintigraphy is useful to select patients at risk for arm lymphedema. LS shows lymphatic impairment (in terms of transport index) compared to the contralateral arm already present pre-operatively.

The quality of life is gaining more and more importance thanks to the prolongation of survival brought about by advanced and combined treatment of different tumors. Surgery

has to be more and more conservative and try to maintain organ function and reduce morbidity. LYMPHA technique proved to represent a new strategy of treatment to reduce morbidity of axillary lymph nodal dissection when it is not possible to preserve arm lymphatic pathways due to the risk to leave tumoral diseases correlated to the breast cancer.

## 6. References

- [1] M.Thompson, S.Korourian, R.Henry-Tillman, L.Adkins, S.Mumford, K.C. Westbrook, and V.S.Klimberg. Axillary Reverse Mapping (ARM): A New Concept to Identify and Enhance Lymphatic Preservation. *Annals of Surgical Oncology* 2007; 14(6):1890-1895.
- [2] Britton TM, Buczacki SJ, Turner CL, et al. Venous changes and lymphedema 4 years after axillary surgery for breast cancer. *Br J Surg* 2007.
- [3] Soran A, D\_Angelo G, Begovic M, et al. Breast cancer-related lymphedema – what are the significant predictors and how they affect the severity of lymphedema. *Breast J* 2006; 12(6):536-43.
- [4] Purushotham AD, Bennett Britton TM, Klevesath MB et al. Lymph node status and breast cancer-related lymphedema. *Ann Surg.* 2007 Jul;246(1):42-5.
- [5] Sakorafasa GH, Perosa G, Cataliotti L, et al. Lymphedema following axillary lymph node dissection for breast cancer. *Surg Oncol* 2006; 15(3):153-165.
- [6] C.Nos, B.Lesieur, K.B.Clough, F.Lecuru. Blue Dye Injection in the Arm in Order to Conserve the Lymphatic Drainage of the Arm in Breast. *Cancer Patients Requiring an Axillary Dissection. Annals of Surgical Oncology* 14(9):2490-2496
- [7] R.Ponzone,, P.Mininanni, E.Cassina, P.Sismondi. Axillary Reverse Mapping in Breast Cancer: Can we Spare what we Find? *Annals of Surgical Oncology* 2007.
- [8] Jila A, Kim H, Nguyen VP, Dumont DJ, Semple J, Armstrong D, Seto E, Johnston M. Lymphangiogenesis following obstruction of large postnodal lymphatics in sheep. *Microvasc Res* 2007; 73:214-223.
- [9] Modi S, Stanton AWB, Svensson WE, Peters AM, Mortimer PS, Levick JR. Human lymphatic pumping measured in healthy and lymphoedematous arms by lymphatic congestion lymphoscintigraphy. *J Physiol* 2007; 583.1:271-285.
- [10] Boccardo F, Casabona F, De Cian F, Friedman D, Villa G, Bogliolo S, Ferrero S, Murelli F, Campisi C. Lymphedema microsurgical preventive healing approach: a new technique for primary prevention of arm lymphedema after mastectomy. *Ann Surg Oncol* 2009;16:703-708.
- [11] Boccardo FM, Casabona F, Friedman D, Puglisi M, De Cian F, Ansaldi F, Campisi C. Surgical Prevention of Arm Lymphedema After Breast Cancer Treatment. *Ann Surg Oncol.* 2011 Mar 3.
- [12] Campisi C, Boccardo F. Microsurgical techniques for lymphedema treatment: derivative lymphatic-venous microsurgery. *World J Surg.* 2004 Jun;28(6):609-13.
- [13] Sitzia J. Volume measurement in lymphedema treatment: examination of formulae. *Eur J Cancer Care* 1995; 4:11-16.
- [14] Casley-Smith JR. Measuring and representing peripheral oedema and its alterations. *Lymphology.* 1994;27:56 -70.
- [15] Sener SF, Winchester DJ, Martz CH, et al. Lymphedema after sentinel lymphadenectomy for breast carcinoma. *Cancer* 2001; 92(4):748-52.

- [16] Wilke LG, McCall LM, Posther KE, et al. Surgical complications associated with sentinel lymph node biopsy: results from a prospective international cooperative group trial. *Ann Surg Oncol* 2006; 13(4):491-500.
- [17] Ververs JM, Roumen RM, Vingerhoets AJ, et al. Risk, severity and predictors of physical and psychological morbidity after axillary lymph node dissection for breast cancer. *Eur J Cancer* 2001; 37(8):991-9.
- [18] Kleinhans E, Baumeister RG, Hanh D et al. Evaluation of transport Kinetics in lymphoscintigraphy: follow-up study in patients with transplanted lymphatic vessels. *Eur J Nucl Med*. 1985; 10:349-52.
- [19] Cambria RA, Gloviczki P, Naessens JM et al. Noninvasive evaluation of the lymphatic system with lymphoscintigraphy: a prospective, semiquantitative analysis in 386 extremities. *J Vasc Surg*. 1993;18:773-82.

IntechOpen



## **Topics in Cancer Survivorship**

Edited by Prof. Ravinder Mohan

ISBN 978-953-307-894-6

Hard cover, 290 pages

**Publisher** InTech

**Published online** 27, January, 2012

**Published in print edition** January, 2012

Cancer is now the leading cause of death in the world. In the U.S., one in two men and one in three women will be diagnosed with a non-skin cancer in their lifetime. Cancer patients are living longer than ever before. For instance, when detected early, the five-year survival for breast cancer is 98%, and it is about 84% in patients with regional disease. However, the diagnosis and treatment of cancer is very distressing. Cancer patients frequently suffer from pain, disfigurement, depression, fatigue, physical dysfunctions, frequent visits to doctors and hospitals, multiple tests and procedures with the possibility of treatment complications, and the financial impact of the diagnosis on their life. This book presents a number of ways that can help cancer patients to look, feel and become healthier, take care of specific symptoms such as hair loss, arm swelling, and shortness of breath, and improve their intimacy, sexuality, and fertility.

### **How to reference**

In order to correctly reference this scholarly work, feel free to copy and paste the following:

Corradino Campisi, Corrado C. Campisi and Francesco Boccardo (2012). Surgical Prevention of Arm Lymphedema in Breast Cancer Treatment, Topics in Cancer Survivorship, Prof. Ravinder Mohan (Ed.), ISBN: 978-953-307-894-6, InTech, Available from: <http://www.intechopen.com/books/topics-in-cancer-survivorship/surgical-prevention-of-arm-lymphedema-in-breast-cancer-treatment>

**INTECH**  
open science | open minds

### **InTech Europe**

University Campus STeP Ri  
Slavka Krautzeka 83/A  
51000 Rijeka, Croatia  
Phone: +385 (51) 770 447  
Fax: +385 (51) 686 166  
[www.intechopen.com](http://www.intechopen.com)

### **InTech China**

Unit 405, Office Block, Hotel Equatorial Shanghai  
No.65, Yan An Road (West), Shanghai, 200040, China  
中国上海市延安西路65号上海国际贵都大饭店办公楼405单元  
Phone: +86-21-62489820  
Fax: +86-21-62489821

© 2012 The Author(s). Licensee IntechOpen. This is an open access article distributed under the terms of the [Creative Commons Attribution 3.0 License](#), which permits unrestricted use, distribution, and reproduction in any medium, provided the original work is properly cited.

IntechOpen

IntechOpen