

Surgical Resolution of Chronic Tissue Irritation Caused by Extruded Endodontic Filling Material

(Résolution chirurgicale de l'irritation tissulaire chronique causée par l'extrusion d'un matériau d'obturation endodontique)

- Mahmoud R. Ektefaie, BSc, DMD •
- Haskell T. David, BA, MSc, DMD •
- Catherine F. Poh, DMD, PhD, Cert Pathology •

S o m m a i r e

La toxicité et l'innocuité relatives des matériaux d'obturation endodontiques, y compris la gutta-percha, dans les tissus vitaux, font encore l'objet de controverses. Dans le présent article, nous discutons de la toxicité possible de la gutta-percha et des agents de scellement ainsi que de la réaction à ceux-ci, et nous présentons 2 cas de réaction inflammatoire chronique et symptomatique où on a constaté que la gutta-percha et les matériaux d'obturation associés se sont extrudés hors du confinement de la structure radiculaire pour se loger dans les tissus mous et les os avoisinants. L'exérèse chirurgicale d'une gutta-percha extrudée entourée de tissu de granulation a accéléré la guérison ainsi que la résolution des symptômes à long terme

Mots clés MeSH : foreign-body reaction; gutta-percha; root canal filling materials

© J Can Dent Assoc 2005; 71(7):487-90
Cet article a été révisé par des pairs.

The success of root canal treatment depends on complete debridement and obturation of the root canal system. Inadequate obturation may result in the failure of endodontically treated teeth, because of the inability to establish a seal against fluids and microbes. However, foreign body reaction to extruded filling materials can also mimic a failure.¹ The most frequently used root canal filling material is gutta-percha, with or without a sealer. In vitro and animal studies have dealt with the "toxic trends"²⁻⁴ of and foreign body reaction^{1,5} to gutta-percha points within the root canal.

The purpose of this article is to report 2 clinical cases of overfilling with gutta-percha. In the first case, excess filling material was found to have perforated the cortical bone and become embedded in the mucoperiosteum. In the second case, excess obturation material was present in the periapical region. Both resulted in symptomatic chronic inflammatory reaction within bone and soft tissue.

Case Reports

Case 1

A 48-year-old man had experienced continuous pain and discomfort in the area of his left maxillary first molar (tooth

26) since it had been treated endodontically many years earlier. Because of presumed endodontic failure and at the request of the patient, the tooth was extracted. However, the pain persisted in the same region and, as a result, the patient was referred to us. A periapical radiograph revealed a 3–4 mm linear area of radiopaque foreign material, morphologically consistent with gutta-percha at the apical level of the previously extracted tooth 26 (Fig. 1a). Under local anesthesia, the bony region of this area was explored, but no gutta-percha or other foreign material was discovered. Because of the difficulty of localizing the radiopaque segment, it was decided to continue the exploratory surgery by raising a full-thickness flap and cutting a small window through buccal bone. The elevated soft tissue flap immediately revealed pink gutta-percha between the periosteum and the buccal submucosa at the corresponding bone height (Fig. 1b). The mass of gutta-percha with the surrounding granulation tissue was removed and submitted for pathology. Following this, the flap was repositioned and sutured in place. Healing progressed well and the symptoms resolved in 2 weeks (Fig. 1c). Histologic examination revealed fibrosis with foreign body giant cell reaction to gutta-percha. It also showed unknown

Case 1

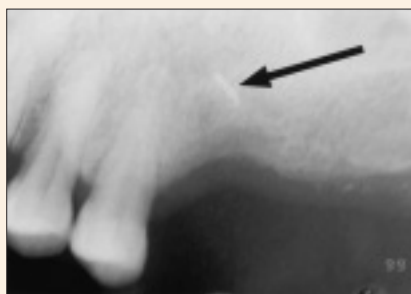


Figure 1a: Periapical radiograph showing a linear radiopaque area (arrow) at the apical level of the previously extracted left maxillary first molar.

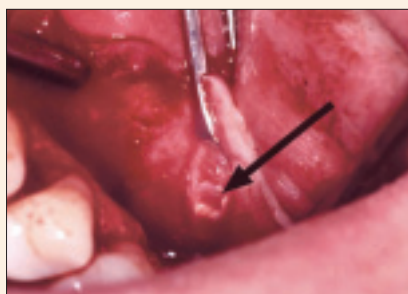


Figure 1b: Clinical photo during surgical procedure. Pink gutta-percha (arrow) was located between the periosteum and the buccal submucosa of the corresponding mucoperiosteal flap.

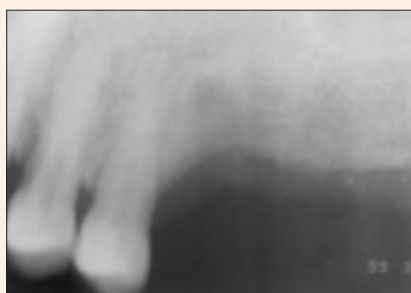

Figure 1c: A periapical radiograph taken during the 2-week follow-up visit.

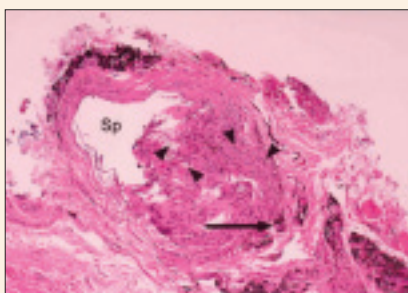


Figure 1d: Photomicrographs of oral biopsy specimen. The collapsed empty space (Sp) represents the location of gutta-percha dissolved during histology processing. The surrounding fibrosis tissue contains considerable refractile (arrowheads) and blackish granular non-refractile foreign material with giant cell reaction (arrow). (Hematoxylin and eosin staining, 100x.)

refractile and non-refractile foreign material (Fig. 1d) with minimal inflammation.

Case 2

A 41-year-old woman was referred for extraction of her right mandibular second premolar (tooth 45). The patient had persistent discomfort in the area of tooth 45 and paresthesia in the mental nerve distribution of the face for many years. Dental history revealed that tooth 45 had been endodontically treated 20 years earlier and a recent external injury had caused its crown to fall out. A panoramic image revealed the retained root of tooth 45 with previous root canal treatment and also a few fragments of radiopaque material in the periapical region (Fig. 2a). The extruded material seemed to have the same density as the gutta-percha inside the canal. Tooth 45 was extracted followed by deep curettage. The surgical sample from the apical region was submitted for pathologic evaluation. Two months later, the patient was pain free and the paresthesia was resolving (Fig. 2b). Furthermore, histologic

examination revealed minimal inflammation with fibrotic tissue surrounding empty spaces that represent gutta-percha dissolved during histologic processing (Fig. 2c).

Discussion

Gutta-percha has been the most widely used root canal filling material for over 100 years. Knowledge of its composition, properties and behaviour has grown. Most marketed gutta-percha points contain about 19% to 22% gutta-percha, 59% to 75% zinc oxide, 1% to 17% heavy metal salts and 1% to 4% wax or resin.^{6,7} Friedman and others⁷ further describe pure gutta-percha as a material that is rigid at ordinary temperatures, becomes pliable at 25°C to 30°C, softens at 60°C and melts at 100°C with partial decomposition. In addition, additives are incorporated into gutta-percha to improve its radiopacity, plasticity and age resistance. The composition of gutta-percha filling material varies among different manufacturers and this difference could account for the varying degrees of toxicity and tissue response.

Numerous early animal studies emphasized that gutta-percha itself is the least toxic material and is compatible with connective tissue.^{5,8,9} Wolfson and Seltzer⁵ studied the reaction of rat connective tissue to gutta-percha implants. Using an injection technique, they implanted gutta-percha cones in the fascial plane of the dorsal subcutaneous

tissues in rats. Histologically, the implanted gutta-percha produced an initial acute inflammatory reaction followed by fibrous encapsulation within 15 days. Therefore, they concluded that gutta-percha was “nontoxic” and “innocuous.” Similar studies^{8,9} revealed that gutta-percha might cause early short-term inflammatory tissue reaction only.

The inertness of gutta-percha, however, was challenged. Several in vitro cell culture studies demonstrated that it can be toxic to human dental pulp cells,³ mouse fibroblasts⁴ and inoculated bacteria.¹⁰ After evaluation of the reaction of mouse fibroblasts to multiple marketed gutta-percha preparations, Pascon and Spangberg⁴ proposed that this toxicity was attributed to the leakage of zinc ions, a major component of gutta-percha, into the culture medium.

Not every brand of gutta-percha causes similar irritation. Holland and co-workers¹¹ implanted 2 brands of gutta-percha into rat connective tissue and showed that only 1 type produced moderate to severe chronic inflammatory reaction. According to Sjögren and colleagues,¹² not only the brand of

Case 2

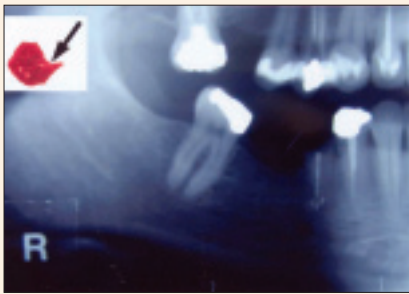


Figure 2a: A cropped panoramic image revealed previously endodontically treated tooth 45 with overfilled strong radiopaque material at the periapical area. (Inset: clinical photo of the surgical specimen reveals pink pointy gutta-percha [arrow] fragments.)

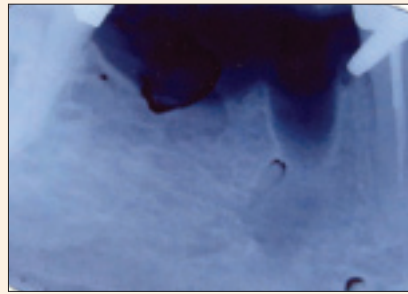


Figure 2b: Periapical radiograph taken at 2-month follow-up. Some artifacts due to development are present.

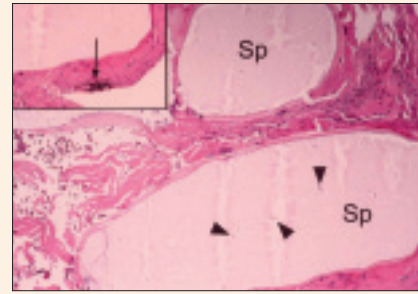


Figure 2c: Photomicrographs of surgical specimen. The empty spaces (Sp) containing refractile crystal-like foreign material (arrowheads) represent the gutta-percha that was partly dissolved during histology processing. The surrounding fibrosis tissue contains blackish granular non-refractile foreign material (arrow). (Hematoxylin and eosin staining, 100x; and inset, 400x.)

gutta-percha but also its size and surface characteristics resulted in different levels of inflammatory response and irritation. They tested 3 sizes of gutta-percha using subcutaneously implanted Teflon cages in guinea pigs. The large pieces were well encapsulated and the surrounding tissue was free of inflammation. The fine particles and exudates evoked an intense localized tissue response, characterized by the presence of macrophages and multinucleated giant cells. The researchers believed that the accumulation of macrophages might be an important factor in impairment of healing of periapical lesions.

Sealers can also cause inflammatory reactions. The most common practice in endodontics is to obturate the canal system with gutta-percha and sealer. In vitro and in vivo animal studies^{13–15} have shown that most sealers when overfilled induce varying degrees of periapical inflammation. However, these findings are limited to cell culture and animal studies.

Few clinical observations demonstrate that overfilling with gutta-percha, sealers or both can result in clinical symptoms. For example, displacement of extruded gutta-percha point from a root canal into the ethmoid sinus has been reported previously.¹⁶ The resultant symptomatic sinusitis resolved only after surgical removal of gutta-percha from the ethmoid sinus. Our first case also showed the displacement of overfilled gutta-percha through cortical bone and into the adjacent soft tissue. This is especially relevant for maxillary teeth where the buccal cortical bone is thin and the root apices are often in close proximity to the buccal plate. A clinician must, therefore, carefully measure and obturate canal systems using apex locator devices and radiographs to confirm working lengths.

In the case of inadvertent overfilling of canals, regular monitoring with or without surgical removal of overfilled material might be a proper management technique.

Endodontically overfilled canals that remain symptomatic may require apical surgery for resolution. There is clinical and histologic evidence that the presence of foreign materials, such as extruded root-filling materials, in the periapical area might complicate post-treatment healing of the periapical tissue.¹⁷ We recommend proper localization and evaluation of “overextended” radiopaque filling materials before any surgery to prevent an unnecessary, repeated or irreversible treatment. This can be achieved by taking multiple radiographs from different angles and using the buccal object rule to locate the extruded material. In our first case, the symptoms resolved only upon successful localization and removal of excess gutta-percha from the buccal alveolar periosteum.

Conclusion

Although the presence of microbial infection is the primary cause of root canal failure in well-treated teeth, foreign body reaction to extruded root canal filling materials can maintain the disease and symptoms.¹⁷ This current case series suggests that gutta-percha or sealers may cause an inflammatory reaction and pain when extruded beyond the confinement of the root canal system. Clinicians should keep in mind that overfilled or overextruded filling materials could be displaced or migrate into the adjacent soft tissue or bone and cause symptoms. If this happens, proper localization followed by surgical removal of extruded materials is an acceptable treatment approach for symptomatic relief and satisfactory long-term outcome. ♦



Dr. Ektefaie is a general dentist in private practice, North Vancouver, B.C. He is also a preclinical instructor at the faculty of dentistry, University of British Columbia, Vancouver, B.C.



Dr. David is an oral and maxillofacial surgeon in private practice, Port Coquitlam, B.C.



Dr. Poh is clinical assistant professor, University of British Columbia, Vancouver, B.C.

Correspondence to: Dr. Mahmoud R. Ektefaie, P.O. Box 2075, Station Terminal, Vancouver, BC V6B 3S3. E-mail: ektefaie@shaw.ca.

The authors have no declared financial interests.

References

1. Nair PN, Sjogren U, Krey G, Sundqvist G. Therapy-resistant foreign body giant cell granuloma at the periapex of a root-filled human tooth. *J Endod* 1990; 16(12):589-95.
2. Szep S, Grumann L, Ronge K, Schriever A, Schultze M, Heidemann D. In vitro cytotoxicity of medicated and nonmedicated gutta-percha points in cultures of gingival fibroblasts. *J Endod* 2003; 29(1):36-40.
3. Das S. Effect of certain dental materials on human pulp in tissue culture. *Oral Surg Oral Med Oral Pathol* 1981; 52(1):76-84.
4. Pascon EA, Spangberg LS. In vitro cytotoxicity of root canal filling materials: 1. Gutta-percha. *J Endod* 1990; 16(9):429-33.
5. Wolfson EM, Seltzer S. Reaction of rat connective tissue to some gutta-percha formulations. *J Endod* 1975; 1(12):395-402.
6. Cohen S, Burns RC. Pathways of the pulp. 7th ed. St. Louis: Mosby Inc.; 1998.
7. Friedman CE, Sandrik JL, Heuer MA, Rapp GW. Composition and physical properties of gutta-percha endodontic filling materials. *J Endod* 1977; 3(8):304-8.
8. Kawahara H, Yamagami A, Nakamura M Jr. Biological testing of dental materials by means of tissue culture. *Int Dent J* 1968; 18(2):443-67.
9. Olsson B, Wennberg A. Early tissue reaction to endodontic filling materials. *Endod Dent Traumatol* 1985; 1(4):138-41.
10. Moorer WR, Genet JM. Evidence for antibacterial activity of endodontic gutta-percha cones. *Oral Surg Oral Med Oral Pathol* 1982; 53(5):503-7.
11. Holland R, de Souza V, Nery MJ, de Mello W, Bernabe PF, Otoboni JA Jr. Reaction of rat connective tissue to gutta-percha and silver points. A long-term histological study. *Aust Dent J* 1982; 27(4):224-6.
12. Sjogren U, Sundqvist G, Nair PN. Tissue reaction to gutta-percha particles of various sizes when implanted subcutaneously in guinea pigs. *Eur J Oral Sci* 1995; 103(5):313-21.
13. Al-Nazhan S, Spangberg L. Morphological cell changes due to chemical toxicity of a dental material: an electron microscopic study on human periodontal ligament fibroblasts and L929 cells. *J Endod* 1990; 16(3):129-34.
14. Beltes P, Koulaouzidou E, Kotoula V, Kortsaris AH. In vitro evaluation of the cytotoxicity of calcium hydroxide-based root canal sealers. *Endod Dent Traumatol* 1995; 11(5):245-9.
15. Hong YC, Wang JT, Hong CY, Brown WE, Chow LC. The periapical tissue reactions to a calcium phosphate cement in the teeth of monkeys. *J Biomed Mater Res* 1991; 25(4):485-98.
16. Ishikawa M, Mizuno T, Yamazaki Y, Satoh T, Notani K, Fukuda H. Migration of gutta-percha point from a root canal into the ethmoid sinus. *Br J Oral Maxillofac Surg* 2004; 42(1):58-60.
17. Nair PN. Non-microbial etiology: foreign body reaction maintaining post-treatment apical periodontitis. *Endod Topics* 2003; 6(1):114-34.