

# Surgical Treatment of Migraine Headaches

**Bahman Guyuron, M.D., Tarvez Tucker, M.D., and Janine Davis, R.N.**

*Cleveland, Ohio*

This prospective study was conducted to investigate the role of removal of corrugator supercilii muscles, transection of the zygomaticotemporal branch of the trigeminal nerve, and temple soft-tissue repositioning in the treatment of migraine headaches. Using the criteria set forth by the International Headache Society, the research team's neurologist evaluated patients with moderate to severe migraine headaches, to confirm the diagnosis. Subsequently, the patients completed a comprehensive migraine headaches questionnaire and the team's plastic surgeon injected 25 units of botulinum toxin type A (Botox) into each corrugator supercilii muscle. The patients were asked to maintain an accurate diary of their migraine headaches and to complete a monthly questionnaire documenting pertinent information related to their headaches. Patients in whom the injection of Botox resulted in complete elimination of the migraine headaches then underwent resection of the corrugator supercilii muscles. Those who experienced only significant improvement underwent transection of the zygomaticotemporal branch of the trigeminal nerve with repositioning of the temple soft tissues, in addition to removal of the corrugator supercilii muscles. Once again, patients kept a detailed postoperative record of their headaches. Of the 29 patients included in the study, 24 were women and five were men, with an average age of 44.9 years (range, 24 to 63 years). Twenty-four of 29 patients (82.8 percent,  $p < 0.001$ ) reported a positive response to the injection of Botox, 16 (55.2 percent,  $p < 0.001$ ) observed complete elimination, eight (27.6 percent,  $p < 0.04$ ) experienced significant improvement (at least 50 percent reduction in intensity or severity), and five (17.2 percent, not significant) did not notice a change in their migraine headaches. Twenty-two of the 24 patients who had a favorable response to the injection of Botox underwent surgery, and 21 (95.5 percent,  $p < 0.001$ ) observed a postoperative improvement. Ten patients (45.5 percent,  $p < 0.01$ ) reported elimination of migraine headaches and 11 patients (50.0 percent,  $p < 0.004$ ) noted a considerable improvement. For the entire surgical group, the average intensity of the migraine headaches reduced from 8.9 to 4.1 on an analogue scale of 1 to 10, and the frequency of migraine headaches changed from an average of 5.2 per month to an average of 0.8 per month. For the group who only experienced an improvement, the intensity fell from 9.0 to 7.5 and the frequency was reduced from 5.6 to 1.0 per month. Only one patient

(4.5 percent, not significant) did not notice any change. The follow-up ranged from 222 to 494 days, the average being 347 days. In conclusion, this study confirms the value of surgical treatment of migraine headaches, inasmuch as 21 of 22 patients benefited significantly from the surgery. It is also evident that injection of Botox is an extremely reliable predictor of surgical outcome. (*Plast. Reconstr. Surg.* 112 (Suppl.): 164S, 2003.)

Migraine headaches affect 18 percent of women and 6 percent of men in the United States.<sup>1</sup> One-third of the patients with periodic or chronic migraine headaches are not helped by standard therapies. In addition, even the most efficacious medications do not entirely eliminate migraine headaches but only reduce their severity and frequency.

We have recently reported the unexpected elimination or improvement in migraine headaches noted following rejuvenation of the forehead involving removal of hyperactive corrugator supercilii muscles.<sup>2</sup> The retrospective study indicated that of 39 patients with migraine headaches who underwent a forehead aesthetic procedure, 15 (38.5 percent) reported complete disappearance of their headaches and 16 patients (41 percent) observed significant improvement within a mean follow-up period of 46.5 months.

This prospective study was conducted to confirm the findings of our retrospective study. The patients likely to have a successful outcome following surgery were identified using injection of botulinum toxin type A (Botox, Allergan, Inc., Irvine, Calif.). These patients underwent surgical removal of the corrugator supercilii muscles alone or in conjunction with transection of the zygomaticotemporal branch

From the Departments of Plastic Surgery and Neurology, Case Western Reserve University; and the American Migraine Center. Received for publication September 5, 2001.

Presented at the 70th Annual Meeting of the American Society of Plastic Surgeons, in Orlando, Florida, November 3 through 7, 2001.

Originally published in *Plastic and Reconstructive Surgery* in June, 2002 (*Plast. Reconstr. Surg.* 109: 2183, 2002).

of the trigeminal nerve and repositioning of the temple soft tissues to prevent recaptation of this nerve.

#### PATIENTS AND METHODS

Patients who complained of migraine headaches were initially evaluated by the research team's neurologist (T.T.) to confirm the diagnosis of migraine headaches on the basis of criteria set forth by the International Headache Society.<sup>3</sup> The patients completed a comprehensive migraine headaches questionnaire that contained 56 items and recorded their symptoms during the month before the procedures. Frequency, duration, characteristics, and severity of headaches, graded on an analogue scale from 1 to 10 (10 being very severe), were documented. Corrugator supercillii muscle hypertrophy was clinically assessed in all patients and graded from 1 to 5 (5 being significant). Patients with medical or neurologic conditions likely to induce migraine headaches were considered ineligible for the study. Similarly, those who were deemed unacceptable surgical risks and patients who were pregnant or nursing at the time of neurologic examinations were excluded from the study. In addition, patients whose migraine headaches responded to over-the-counter medications were barred from the study. Patients who were in good health, between 18 and 75 years old, and who experienced two or more moderate to severe migraine headaches each month were considered eligible for the study.

Twenty-five units of Botox were injected by the plastic surgeon (B.G.) into each corrugator supercillii muscle of the volunteers who fulfilled the study criteria. After injection of Botox, patients were asked to refrain from using any regular prophylactic migraine headaches medications and to keep an accurate diary of any headaches, including the details of symptoms, location, severity, and frequency of the headaches. The patients were instructed, however, to use their migraine headache medications if they experienced an acute attack.

Those patients who responded favorably to the injection of Botox with complete elimination of migraine headaches for at least 6 weeks, or those who observed significant (at least 50 percent) reduction in intensity or severity of their migraine headaches, were considered suitable candidates for surgery. Subjects who observed complete elimination of their migraine headaches following Botox injection un-

derwent a thorough resection of each corrugator supercillii muscle. Those patients who noted only improvement following Botox injection underwent a combination procedure similar to an endoscopic forehead rejuvenation. This consisted of complete removal of each corrugator supercillii muscle, transection of the zygomaticotemporal branch of the trigeminal nerve, and repositioning of the temple soft tissues to minimize the potential for recaptation of the transected nerves.

After injection or surgery, patients kept a diary of their headaches and completed a questionnaire on a monthly basis. A reduction in intensity or frequency of at least 50 percent was considered improvement. The results were then statistically analyzed using binomial distribution *Z* statistics with continuity correction. The *p* values were calculated by comparing the observed proportion on the basis of 29 patients undergoing Botox injection against 1 percent improvement and the proportion on the basis of 22 patients who underwent surgery when compared against 5 percent improvement, respectively. When comparing the presurgical and postsurgical frequency and intensity data, we used the two-tailed Wilcoxon signed rank test.

#### *Surgical Techniques*

For the transpalpebral approach,<sup>4,5</sup> a skin incision was made in the upper tarsal crease of each eyelid, approximately 1 inch in length, and deepened through the orbicularis muscle only. In the anatomic plane between the orbicularis muscle and orbital septum, the dissection was continued cephalad until the corrugator supercillii muscles were exposed. Preserving the supraorbital and supratrochlear nerves, both corrugator supercillii muscles were removed as thoroughly as possible. A small amount of fat, often protruding on the medial aspect of the upper eyelid, was harvested through a small opening in the orbital septum and applied to the corrugator supercillii muscle site. This fat graft was sutured in place using 6-0 polyglactin (Vicryl). The skin incision was repaired using 6-0 plain catgut.

The combination of corrugator supercillii muscle resection, temporal release, and transection of the zygomaticotemporal branch of the trigeminal nerve was performed through an endoscopic approach. Five half-inch incisions were made, one in the center and two on either side in the temple area. The endoscopic

access devices were inserted. A subperiosteal dissection was carried to the supraorbital rim, lateral orbital rim, zygomatic arch, and malar region. The zygomaticotemporal branch of the trigeminal nerve was transected and coagulated. The periosteum and the arcus marginalis were released over the lateral orbital region and the supraorbital area to allow repositioning of the tissues. The supraorbital nerves and each corrugator supercilii muscle were exposed. The glabellar area was dissected and the periosteum was released. Next, each corrugator supercilii muscle was removed as completely as was feasible. Fat graft, harvested from the temporal region, deep to the intermediate or deep temporal fascia, was applied to the corrugator supercilii muscle site. Fixation was achieved with 3-0 polydioxanone fascia sutures laterally and bone tunneling through the medial incision in the temple area. A suction drain was placed in position and anchored to the skin using 5-0 plain catgut. The incisions were repaired using a combination of 5-0 polyglactin (Vicryl) and 5-0 plain catgut.

RESULTS

Twenty-nine patients with a confirmed diagnosis of moderate to severe migraine headaches constituted the study group. There were 24 women and five men, closely matching the national gender-based distribution of the migraine headache patient population (Table I). The patients ranged in age from 24 to 63 years, with an average age of 44.9 years. The average corrugator supercilii muscle hypertrophy was 4.7, ranging from 4 to 5.

*Outcome following Injection of Botox*

After injection of Botox, 24 of the 29 patients (82.8 percent,  $p < 0.001$ ) noted an improvement in their migraine headaches. In 16 patients (55.2 percent,  $p < 0.001$ ), migraine headaches disappeared completely (Table II), whereas eight patients (27.6 percent,  $p < 0.04$ ) observed significant improvement for 6 consecutive weeks or more. The average frequency decreased from 6.4 to 2.1 per month and the intensity fell from 8.6 to 6.1 (Table II). Five

TABLE I  
Entire Patient Population

Patient	Age (years)	Gender	Aura/ Nonaura	Before Treatment			After Botox Injection			After Surgery			
				Corrugator Supercilii Muscle Hypertrophy	Migraine Headache Frequency per Month	Migraine Headache Intensity per Month	Migraine Headache Frequency per Month	Migraine Headache Intensity per Month	Botox Outcome	Migraine Headache Frequency per Month	Migraine Headache Intensity per Month	Days of Follow-Up	Surgical Outcome
1	47	F	A	4	6	9	2	8	SD	1.8	7.2	313	SD
2	40	F	A/N	5	8	9	0	0	E	0.2	5.0	320	SD
3	49	M	N	5	8	9	2	6	SD	0.7	9.5	277	SD
4	40	F	A	5	3	10	0	0	E	0	0	382	E
5	42	F	N	5	4	9	0	0	E				
6	35	F	N	5	8	9	12	7	NR				
7	38	F	A	5	5	10	2	9	SD				
8	44	M	A	4	4	10	0	0	E	0	0	461	E
9	47	M	A	4	5	8	2	7	SD	3.2	6.8	347	SD
10	53	F	A	5	3	10	0	0	E	0	0	361	E
11	41	F	N	5	6	7	0	0	E	6.0	6.7	311	NR
12	49	F	A	4	6	8	0	0	E	0	0	494	E
13	48	F	A	5	4	8	0	0	E	0	0	326	E
14	63	M	N	4	6	9	15	9	NR				
15	58	M	N	5	9	7	2	8	SD	0	0	340	E
16	53	F	A	4	3	9	0	0	E	0	0	312	E
17	47	F	N	5	4	8	1	4	SD	0.1	9	347	SD
18	34	F	A		5	9	0	0	E	0.7	6.4	404	SD
19	53	F	N	5	4	9	5	7	NR				
20	45	F	N	5	5	8	5	4	SD	1.5	5.7	340	SD
21	30	F	A	5	3	8	0	0	E	0	0	222	E
22	29	F	A	4	5	9	0	0	E	0.8	8	362	SD
23	49	F	N	5	9	10	0	0	E	1.5	9.7	306	SD
24	24	F	A	5	5	9	0	0	E	0	0	322	E
25	63	F	N	4	19	7	10	7	NR				
26	62	F	A	5	8	9	11	9	NR				
27	44	F	A	5	3	10	0	0	E	0.3	8.5	349	SD
28	38	F	N	4	8	10	1	3	SD	0	0	341	E
29	38	F	N	5	3	10	0	0	E	0.2	7.0	389	SD
Average	44.9	F 24 M 5	A 14 N 14	4.7	5.9	8.7	2.4	3.0	E 16 SD 8 NR 5	0.9	4.1	347	E 10 SD 11 NR 1

E, elimination; SD, significant decrease; NR, no response; A, aura; N, nonaura; M, male; F, female.

TABLE II  
Results of Botox Injection and Surgery

	Before Treatment	After Botox Injection/Surgery	<i>p</i> Value*
Group with elimination of MH after Botox injection ( <i>n</i> = 16)			
Average MH frequency	4.6	0	<0.001
Average MH intensity	9.1	0	<0.001
Group with significant decrease in MH after Botox injection ( <i>n</i> = 8)			
Average MH frequency	6.4	2.1	<0.04
Average MH intensity	8.6	6.1	<0.04
Group with no response to injection of Botox ( <i>n</i> = 5)			
Average MH frequency	9.0	10.6	NS
Average MH intensity	8.6	7.8	NS
Group with elimination of MH after surgery, mean follow-up: 356 days ( <i>n</i> = 10)			
Average MH frequency	4.8	0	0.01
Average MH intensity	8.9	0	0.01
Group with significant decrease in MH after surgery, mean follow-up: 341 days ( <i>n</i> = 11)			
Average MH frequency	5.6	1.0	0.004
Average MH intensity	9.0	7.5	0.04
Patient with no response to surgery, follow-up: 311 days ( <i>n</i> = 1)			
Average MH frequency	6.0	6.0	–
Average MH intensity	7.0	6.7	–

MH, migraine headache; NS, not significant.

\* Using Wilcoxon signed rank test.

patients (17.2 percent, not significant) reported no change (Table II). Two patients (6.9 percent) noted transient unilateral upper eyelid ptosis that lasted 2 weeks for one patient and 3 weeks for the other patient.

#### Outcome following Surgery

Of the 24 patients who noted a favorable response to injection of Botox, 22 underwent surgery. This group included 18 women and four men ranging in age from 24 to 58 years old. Of the 22 patients who underwent surgery, 21 (95.5 percent,  $p < 0.001$ ) observed an improvement in the migraine headaches. Ten patients (45.5 percent,  $p < 0.01$ ) noted elimination of migraine headaches (Table II) and 11 (50.0 percent,  $p < 0.004$ ) noted a significant improvement (Table II). The average intensity of migraine headaches for the entire surgical group was reduced from 8.9 to 4.1 ( $p < 0.04$ ) on an analogue scale of 1 to 10, and the frequency changed from 5.2 to an average of 0.8 ( $p < 0.001$ ) per month. When the group with improvement only was analyzed, the intensity fell from 9.0 to 7.5 and the frequency changed from 5.6 to 1.0 migraine headaches per month. Only one patient failed to notice an improvement (Table II). The follow-up ranged from 222 to 494 days, with an average of 347 days.

There was no incidence of wound infection. Three patients received an infusion of desmopressin (DDAVP) for moderately excessive

bleeding during surgery. All patients experienced some numbness in the temple area lasting 1 to 6 months, with an average of 2.3 months. All patients reported complete sensory recovery during the follow-up period. All patients noted aesthetic improvement, with the disappearance or diminution of the forehead line and better eyebrow position. The patient who failed to notice enough improvement stated that the location and the pattern of her migraine headaches were different when compared with her preoperative headaches. Her medical history confirmed long-standing perinatal sinus disease, and an internal nose examination revealed a notable deviation of the septum. Similarly, three of 11 patients who reported only improvement in migraine headaches stated that the pattern and the location of the migraine headaches were different postoperatively.

#### DISCUSSION

There has been no report of a surgical cure for conventional migraine headaches as a result of muscle resection or transection of the zygomaticotemporal branch of the trigeminal nerve. Partial or complete section of the trigeminal nerve has been advocated as an effective treatment for cluster-type headaches.<sup>6-10</sup> These surgical procedures, however, are complex, and the associated morbidity, especially

ophthalmic anesthesia, can have grave consequences.

Our surgical approach involves the peripheral branches of the trigeminal nerve and muscles affecting these terminal branches; as a result, the surgical procedures are less complicated and serious morbidity is extremely rare. The role of the trigeminal nerve in the pathogenesis of migraine headaches has been studied for over 30 years. It is postulated that stimulation of this nerve results in release of neuropeptides such as substance P, calcitonin gene-related peptide, and neurokinin A.<sup>11,12</sup> These peptides cause neurogenic inflammation.<sup>13-19</sup> What activates the terminal branches of the trigeminal nerve, however, remains unknown. We propose that these nerves are stimulated by strong contraction of the corrugator supercilii and the temporalis muscles. The supratrochlear and supraorbital nerves pierce the corrugator muscle to reach the cutaneous level (Fig. 1). Whereas the main trunk of the supratrochlear nerve passes through the corrugator supercilii muscles, only branches of the supraorbital nerve, rather than the main nerve, traverse in between muscle fibers. The zygomaticotemporal branch of the maxillary division exits from the orbit, wraps around the lateral orbital wall, and exits from the temporalis fascia and muscle to reach the cutaneous level. This nerve may be irritated by being compressed between the temporalis muscle fibers or by being pressed against the lateral orbital wall by this muscle. The occipitalis muscle, by compressing the greater occipital nerve, can also result in head pain and possibly migraine headaches. Finally, perinasal sinus linings (frontal, ethmoid, maxillary, and sphenoid)

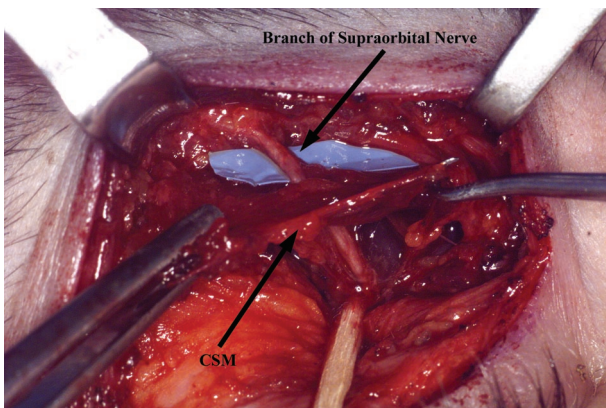


FIG. 1. Intraoperative photograph documenting penetration of the corrugator supercilii muscle by the branches of the supraorbital nerve.

may serve as a trigger point, if irritated by abnormal air turbulence. Turbulence may result from septal deviation or abnormal sinus drainage caused by enlargement of the turbinates. The ophthalmic and maxillary divisions of the trigeminal nerve innervate these cavities. The patient who did not benefit from the surgery may have suffered from activation of another dormant trigger point that was located in the sinus cavities. In our experience and that of others,<sup>18</sup> identification and elimination of the sinus trigger points may result in a significant improvement in migraine headaches.

The patients in this study who did not respond completely to the removal of corrugator supercilii muscles or transection of the zygomaticotemporal branch of the trigeminal nerve, in all likelihood, harbor other trigger points that may be identified. We have developed an algorithm to detect possible trigger points in a sequential fashion. Patients with migraine headaches receive an injection of Botox in different trigger sites, in a logical and stepwise manner. We have launched another study involving 125 patients. After the trigger points are identified using our comprehensive algorithm, they are eliminated with surgical maneuvers. Patients who undergo surgery are then compared with the patients who receive placebo injection and serve as a control group, selected on a random basis. This study will include a 5-year assessment, an extensive outcomes evaluation including quality-of-life and socioeconomic parameters of patients who undergo migraine surgery compared with the control group.

The statistical analysis for the present study was conducted assuming spontaneous disappearance of migraine headaches in 1 percent of the patients in the group who underwent injection of Botox and 5 percent of the patients who were subjected to surgical amelioration of the migraine headaches. These percentages were selected very conservatively, knowing that it may take as long as 5 years for the patients in the age group matching to those who were included in this study to observe such a change.<sup>19,20</sup> This conservative approach was chosen to lend added statistical value to our findings.

In this prospective study, careful patient selection and injection of Botox enabled us to identify the patients who will have a high likelihood of benefiting from removal of the corrugator supercilii muscles. Use of Botox has

proved to be an extremely reliable prognosticator. Botox is currently being studied for temporary treatment and prevention of migraine headaches with or without aura.<sup>21</sup> Injection of Botox into the frontalis, temporalis, glabellar, and occipital areas has been found to reduce the severity and frequency of migraine headaches in small studies.<sup>22,23</sup> Larger trials are currently under way.<sup>24</sup> Interestingly, Botox may be as effective in treating migraine headaches as it is in treating tension-type headaches.<sup>25</sup> In addition, two pilot open-labeled studies have shown improvement in headache severity scores and reduction in headache duration in patients with chronic and episodic tension-type headaches.<sup>26</sup>

The mechanism of action of Botox in relieving headaches is not yet fully understood. Botox inhibits release of acetylcholine at the neuromuscular junction, thereby decreasing muscle tone. Relief of headache pain may be because of this mechanism or the inhibition of exocytosis of neurotransmitters and neurally active substances, which play an inflammatory role in the pathogenesis of migraine headaches.<sup>27</sup> Botulinum toxin may also have a direct effect on peripheral sensory nerves, although this is unlikely. We suggest that the majority of nonorganic headaches are related to irritation of the trigeminal nerve branches, resulting in inflammation and release of neuropeptides. When the inflammation reaches the meninges, it may result in localized inflammation, inducing severe headaches, nausea, photophobia, and other characteristics of migraine headaches. Considering that a vast number of migraine headaches are provoked by stress or light exposure and many of these patients exhibit significant hypertrophy of corrugator muscles (Fig. 2), the muscle theory as a cardinal factor and impingement of the trigeminal nerve branches becomes more compelling. It is our belief that Botox, like surgical ablation, by virtue of paralyzing the offending muscle, eliminates the trigger point, hence avoiding the migraine headaches. Response to the injection of Botox, our retrospective study, and this prospective study set the foundation for our suppositions.

Two of our five patients who did not respond to the injection of Botox in the corrugator supercillii muscles elected to undergo forehead rejuvenation. Both patients reported complete elimination of migraine headaches after surgery. Because transection of the zygomatico-

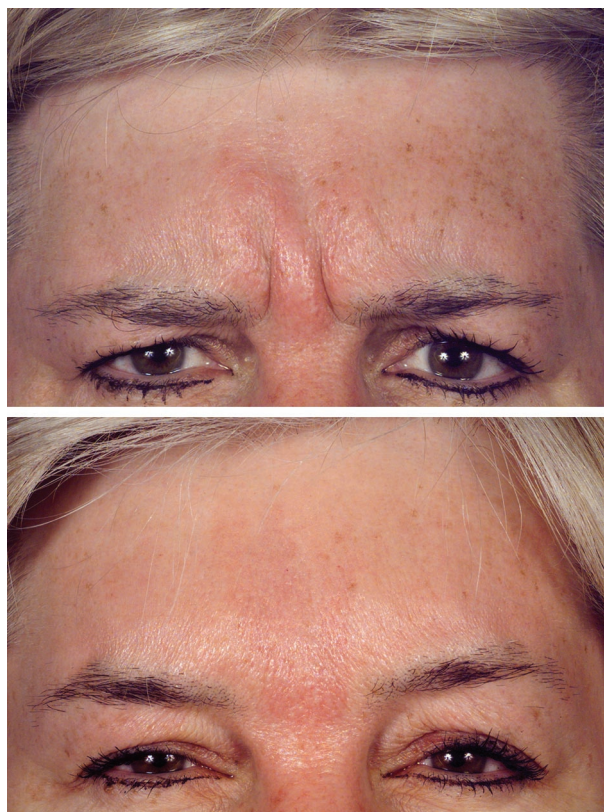

FIG. 2. Preoperative and postoperative views of a patient with migraine headaches, revealing the magnitude of corrugator supercillii muscle hypertrophy while frowning (*above*), and while attempting to frown (*below*) after removal of corrugator supercillii muscles, transection of the zygomaticotemporal branch of the trigeminal nerve, and temple soft-tissue repositioning.

temporal branch of the trigeminal nerve was part of this procedure, it prompted us to incorporate this maneuver into those patients who did not observe elimination of the migraine headaches after injection of Botox in the corrugator supercillii muscles. It is our belief that this nerve is another trigger point, being compressed by the temporalis muscle. Although the follow-up for this study group, by itself, is not sufficient to reach a convincing conclusion as to the long-term benefits of surgery, combining this study and the results of our retrospective study with an average follow-up of 47 months leaves no question that this method has an amaranthine effect on migraine headaches.

In conclusion, we propose that the facial muscles play an important role in inducing migraine headaches and that elimination of the impinging effects on the peripheral branches of the trigeminal nerve may have a prodigious role in the treatment of migraine

headaches. Because 21 of 22 patients responded positively to surgery, we conclude that surgical treatment of migraine headaches is successful. Even in patients who did not experience complete elimination of migraine headaches, the reduction in frequency was remarkable. Considering that 21 of 22 patients (95.5 percent,  $p < 0.001$ ) who were selected to undergo surgery on the basis of favorable response to Botox injection enjoyed a positive outcome from the surgery, it is logical to conclude that Botox is an extremely reliable prognosticator of the surgical outcome for the treatment of migraine headaches.

*Bahman Guyuron, M.D.  
29017 Cedar Road  
Cleveland, Ohio 44124  
bguyuron@aol.com*

#### ACKNOWLEDGMENTS

The authors gratefully acknowledge the invaluable assistance from Saied Amini, Ph.D., M.B.A., J.D., in statistical analysis, and Bryan Michelow, M.D., in preparation of the manuscript.

#### REFERENCES

1. Stewart, W. F., Shechter, A., and Rasmussen, B. K. Migraine prevalence: A review of population-based studies. *Neurology* 44 (6 Suppl. 4): S17, 1994.
2. Guyuron, B., Varghai, A., Michelow, B. J., Thomas, T., and Davis, J. Corrugator supercilii muscle resection and migraine headaches. *Plast. Reconstr. Surg.* 106: 429, 2000.
3. Headache Classification Committee of the International Headache Society. Classification and diagnostic criteria for headache disorders, cranial neuralgias and facial pain. *Cephalalgia* 8 (Suppl. 7): 1, 1988.
4. Guyuron, B. Corrugator supercilii resection through blepharoplasty incision. *Plast. Reconstr. Surg.* 107: 604, 2001.
5. Guyuron, B. Surgical Control of Migraine Headaches. Microsoft PowerPoint Presentation, 2001.
6. Stein, J. IHS: Surgery improves chronic cluster headache. *Docguide* July 2, 2001.
7. Kunkel, R. S., and Dohn, D. F. Surgical treatment of chronic migrainous neuralgia. *Cleve. Clin. Q.* 41: 189, 1974.
8. Horton, B. T., MacLean, A. R., and Craig, W. M. A new syndrome of vascular headache: Results of treatment with histamine. Preliminary report. *Mayo Clin. Proc.* 14: 257, 1939.
9. Maxwell, R. E. Surgical control of chronic migrainous neuralgia by trigeminal ganglio-rhizolysis. *J. Neurosurg.* 57: 459, 1982.
10. Miller, H. Pain in the face. *Br. Med. J.* 2: 577, 1968.
11. Goetz, C., and Pappert, E. *Textbook of Clinical Neurology*. Philadelphia: Saunders, 1999.
12. Moskowitz, M. A. The neurobiology of vascular head pain. *Ann. Neurol.* 16: 157, 1984.
13. Williamson, D. J., and Hargreaves, R. J. Neurogenic inflammation in the context of migraine. *Microsc. Res. Tech.* 53: 167, 2000.
14. Grosser, K., Oelkers, R., Hummel, T., et al. Olfactory and trigeminal event-related potentials in migraine. *Cephalalgia* 20: 621, 2000.
15. de Tommaso, M., Guido, M., Libro, G., et al. The three responses of the blink reflex in adult and juvenile migraine. *Acta Neurol. Belg.* 100: 96, 2000.
16. Moskowitz, M. The trigeminovascular system: Scientific basis of migraine. Presented at the 49th Annual Meeting of the American Academy of Neurology, Boston, April 12–19, 1997.
17. Goadsby, P. J. Advances in the pharmacotherapy of migraine: How knowledge of pathophysiology is guiding drug development. *Drugs R. D.* 2: 361, 1999.
18. Levine, H. Personal communication.
19. Silberstein, S. D. Menstrual migraine. *J. Womens Health Gen. Based Med.* 8: 919, 1999.
20. Silberstein, S. D., and Lipton, R. B. Epidemiology of migraine. *Neuroepidemiology* 12: 179, 1993.
21. Binder, W., Brin, M. F., Blitzer, A., Schenrock, L., and Diamond, B. Botulinum toxin type A (BTX-A) for migraine: An open label assessment. *Mov. Disord.* 13 (Suppl. 2): 241, 1998.
22. Wheeler, A. H. Botulinum toxin A: Adjunctive therapy for refractory headaches associated with pericranial muscle tension. *Headache* 38: 468, 1998.
23. Jankovic, J., and Brin, M. F. Botulinum toxin: Historical perspective and potential new indications. *Muscle Nerve Suppl.* 6: S129, 1997.
24. Ward, T. *Pericranial Injections of Two Dosages of Botulinum Toxin Type A in the Prophylactic Treatment of Migraine*. Rancho Mirage, Calif.: Annenberg Center for Health Sciences at Eisenhower, 2000.
25. Silberstein, S., Mathew, N., Saper, J., and Jenkins, S. Botulinum toxin type A as a migraine preventive treatment. *Headache* 40: 445, 2000.
26. *The Use of Botulinum Toxin Type A for Headache Management*. Rancho Mirage, Calif.: Annenberg Center for Health Sciences at Eisenhower, 2000.
27. Hohne-Zell, B., Galler, A., Schepp, W., et al. Functional importance of synaptobrevin and SNAP-25 during exocytosis of histamine by rat gastric enterochromaffin-like cells. *Endocrinology* 138: 5518, 1997.