



Survey of the management of acute traumatic first-time anterior shoulder dislocation among trauma clinicians in the UK

MARK CHONG, DIMITRIS KARATAGLIS, DUNCAN LEARMONTH

The Royal Orthopaedic Hospital NHS Trust, Birmingham, UK

ABSTRACT

INTRODUCTION The aim of this work was to survey how acute traumatic first-time anterior shoulder dislocation (AFSD) is managed among trauma clinicians in UK using a postal questionnaire.

PATIENTS AND METHODS A total of 150 questionnaires were sent out to active consultant members of the British Trauma Society in the UK. Questions were laid out in two 'workgroups'. In Workgroup One, an assortment of questions was included regarding choices and methods of analgesia, methods of monitoring used, methods of reduction, and position of immobilisation. In Workgroup Two, three different case scenarios were analysed to look into the 'post-reduction' management.

RESULTS The response rate was 60%. Of respondents, 22% have a local protocol for managing AFSD. Almost all respondents recommended pre- and post-reduction X-rays as standard practice. Most respondents favoured systemic analgesia and sedation with airways' monitoring, as opposed to intra-articular anaesthesia (68 versus 9). Eighty-four respondents advocated immobilisation in internal rotation compared to six in external rotation. Only 19% (16 of 84) of respondents would perform an immediate arthroscopic stabilisation in young, fit patients presenting with this type of injury.

CONCLUSIONS This survey revealed variations among trauma clinicians in managing AFSD on the 'front-line'. There is a need to address the issue of intra-articular analgesia, immobilisation technique and management of AFSD in the young patient with regards to immediate surgical intervention. We suggest that these issues be revised and clarified, ideally in a randomised, controlled, clinical trial prior to the introduction of a protocol for managing this problem.

KEYWORDS

Anterior shoulder dislocation – UK survey – External rotation – Arthroscopic stabilisation

CORRESPONDENCE TO

Mark Chong, The Royal Orthopaedic Hospital NHS Trust, Bristol Road South, Northfield, Birmingham B31 2AP, UK
E: sengye@aol.com

Acute traumatic first-time anterior shoulder dislocations (AFSDs) are frequently seen in accident and emergency departments. The incidence of primary anterior dislocation is estimated to be around 12.3 per 100,000.¹ Although AFSD is a relatively common problem in accident and emergency departments, a standard management protocol is still lacking as exhibited by the Dutch study of te Slaa *et al.*² Evidently, there are no current standardised guidelines for managing this common condition in the UK. We conducted a questionnaire survey among active consultant members of the British Trauma Society (BTS) in 2004. The aim of this survey was to find out how AFSD is managed among UK trauma clinicians in the current clinical setting and to highlight certain clinical issues regarding the management of AFSD. Studies from Japan and Australia have advocated the use of immobilisation in external rotation following

reduction of anterior shoulder dislocation.^{3–5} We aimed to determine whether this method of immobilisation is currently being used in clinical practice among those who deal with this problem in the 'front-line'. Our second objective was to find out what the current trend in the management of AFSD among different age groups, especially the younger population where high recurrence rates are well documented in the literature.^{1,6} These and various other topics regarding the immediate management of AFSD are outlined in this paper.

Patients and Methods

During the period January–May 2004, 150 questionnaires were sent out to all active consultant members of BTS practising in various hospitals across the UK.

Table 1 Respondents based on speciality

Specialty	Responses (n)
Orthopaedic	49
Accident and emergency	17
Anaesthetist	6
Non-specified	18
Total	90

Questionnaires were mailed and returned in a pre-paid, self-addressed envelope. The emphasis was on the management of AFSD from the point of entry in a casualty department to departure and aftercare.

Questions were laid out in two 'workgroups'. In Workgroup One, an assortment of questions was included regarding choices and methods of analgesia, methods of monitoring used, methods of reduction, and position of immobilisation. In Workgroup Two, three different case scenarios were analysed to look into the 'post-reduction' management. Case scenarios were divided into three distinct age groups: young (< 25 years old), middle-aged (30–65 years old) and elderly (> 65 years old). Only responses from consultants still actively involved in trauma care at the time of the survey was conducted were included into the final result analysis. The questionnaire responses were recorded and analysed in Microsoft Access and Excel (v. 2003; Redmond, WA, USA).

Results

Analysis of Workgroup One

The response rate was 60% (90 of 150). Orthopaedic surgeons formed the majority of the respondents. This was followed by accident and emergency consultants and consultant anaesthetists (Table 1).

Only 22.2% (20 of 90) admitted to having a local protocol for the management of AFSD in casualty departments. All respondents (100%) advocated the use of X-rays pre-reduction and 98.9% (89 of 90) recommended post-reduction X-rays to confirm successful reduction. In addition, 63.3% (57 of 90) recommended analgesia whilst waiting to be seen by a doctor. Out of those 57 respondents who recommended early analgesia, 'entonox' was the most popular choice (Table 2).

Of respondents, 73.3% (66 of 90) recommended opiates as their first choice of analgesia prior to reduction. In addition to opiates, midazolam was recommended as the first choice of sedation prior to reduction. Only 10% (9 of 90) of respondents recommended intra-articular anaesthesia prior to reduction (Table 3).

Table 2 Responses to issues upon arrival of patient to a casualty department (door-to-cubicle)

WORKGROUP ONE	
Questions – from 'door-to-cubicle'	Total respondents
1. Is there a protocol in your hospital?	20
2. Is pre-reduction X-ray used?	90
3. Is post-reduction X-ray used?	89
4. Analgesia on arrival?	57
Types of analgesia used on arrival to casualty (n = 57)	
Entonox	46
Opiates	4
Others	1
Non-specified	6

Table 3 Responses on analgesia and sedative choices during pre-reduction period

5. Systemic analgesia during reduction	
Opiates	66
Pethidine	12
Others	1
Non-specified	11
6. Choice of systemic sedation during reduction	
Midazolam/diazepam	68
Propofol	7
Others	2
Non-specified	2
7. Is intra-articular anaesthesia used?	9

The majority of the (93.3%; 84 of 90) respondents advocated shoulder immobilisation in internal rotation with only 6.7% (6 of 90) recommended immobilisation in external rotation following reduction (Table 4).

Table 4 Choice of immobilisation post-reduction

Questions – How would you immobilise the shoulder post-reduction?	Total respondents (%)
Internal rotation	93.3 (84 of 90)
External rotation	6.7 (6 of 90)

Analysis of Workgroup Two

The response rates derived from Workgroup Two were as follows: 93.3% (84 of 90) in case 1 – young and athletic; 94.4% (85 of 90) in case 2 – active middle-aged; and 93.3% (84 of 90) in case 3 – active elderly. The breakdown of the responses according to case scenarios were as follows. Out of the 84 respondents in case scenario one, 81% (68 of 84) preferred the conservative treatment for young athletic patients as compared to only 16 respondents who chose surgery. The mean duration of immobilisation was 4.83 weeks (range, 1–12 weeks) and the mean duration of follow-up was 9.23 weeks (range, 1–52 weeks). The mean duration of immobilisation after surgical treatment was 2 weeks (range, 1–3 weeks) and the mean duration of follow-up was 8.86 months (range, 1–24 months).

Out of the 85 respondents in case scenario two, 96.5% (82 of 85) respondents preferred the conservative treatment for the middle-aged, active patients. The mean duration of immobilisation was 4 weeks (range, 1–12 weeks) and the mean duration of follow-up was 10.24 weeks (range, 1–52 weeks). Only three respondents preferred the surgical treatment for this group of patients. The mean duration of follow-up following surgical management was 12 months.

Out of the 84 respondents in case scenario three, 97.6% (82 of 84) respondents chose conservative treatment for the elderly patients and only two respondents would advocate surgery. The mean duration of immobilisation was 4.76 weeks (range, 1–24 weeks) and the mean duration of follow-up was 13.48 weeks (range, 1–32 weeks). The mean duration for immobilisation after surgical treatment in this category was 9 weeks (range, 6–12 weeks). The most common surgical treatment recommended for AFSD across all ranges of age group is early arthroscopic Bankart repair (see Table 5).

Discussion

Shoulder dislocation is the most common joint dislocation in the human body.¹ For centuries, this problem has been

managed with a scope to prevent further recurrence. Although this is a common traumatic condition, a comprehensive management protocol is still lacking.² Our objective was to collect information regarding management of patients with AFSD by trauma clinicians in the UK. We are aware of one similar study conducted among members of the British Shoulder and Elbow Society on the management of shoulder dislocation. However, the respondents of this study were mainly orthopaedic surgeons with specialist interest in upper limb.⁷ Their views may not accurately represent current practices among ‘generalist’ trauma clinicians who treat this particular problem as they present in the UK. This survey was sent out to active consultant members of BTS in 2004, as they were considered to be most appropriate, given their clinical seniority in trauma management issues.

All respondents felt that it was necessary to request pre-reduction X-rays, while 99% (89 of 90) of respondents recommended the use of post-reduction radiographs. Traditional teaching in orthopaedics and emergency medicine dictates the use of pre- and post-reduction radiographs to supplement clinical findings in managing shoulder dislocation. This notion has been challenged recently by some authors as it was felt that an experienced clinician, given a proper clinical guideline, can selectively eliminate the use of pre-reduction radiographs.^{8–10} Furthermore, post-reduction radiographs are felt to add very little to the early management of patients.^{8,10} This seems reasonable when one considers the benefits of avoiding unnecessary films in every patient with shoulder dislocation in terms of cost, time saving and decrease in radiation exposure. However, many respondents felt that both pre- and post-reduction films are necessary in order to guide clinical practice in terms of confirming anatomical reduction and to demonstrate that no further fracture has occurred during reduction procedure. Furthermore, the current medicolegal climate of clinical medicine renders it necessary to have radiographic evidence to support the documentation of injury.

Table 5 Responses for Workgroup Two based on three different case scenarios

Choices of immobilisation/duration of immobilisation/follow-up	Case 1 – Young (< 25 years old), athletic	Case 2 – Middle aged (30–65 years old), active	Case 3 – Elderly (> 65 years old), active
Response rate	93.3% (84 of 90)	94.4% (85 of 90)	93.3% (84 of 90)
Conservative	68	82	82
Duration of immobilisation (weeks)	Mean 4.83 (range, 1–12)	Mean 4.00 (range, 1–12)	Mean 4.76 (range, 1–12)
Duration of follow up (weeks)	Mean 9.23 (range, 1–52)	Mean 10.24 (range, 1–52)	Mean 13.48 (range, 1–32)
Surgery	16	3	2
Duration of immobilisation (weeks)	Mean 2.00 (range, 1–3)	–	Mean 9.00 (range, 6–12)
Duration of follow-up (months)	Mean 8.86 (range, 1–24)	12	–

Only 10% (9 of 90) respondents recommended intra-articular analgesia during shoulder reduction. The use of intra-articular analgesia in shoulder reduction has been shown in prospective randomised studies to be cost-effective and a safe procedure with fewer complications.^{11,12} However, a prospective, randomised, non-blinded study to ascertain whether these results could be reproducible failed to show any statistical significant differences.¹⁵ Given the evidence thus far, intra-articular analgesia is probably worth our consideration, especially in patients where parenteral analgesics or sedation is contra-indicated for other medical reasons.

Independent studies conducted in Japan and Australia, using magnetic resonance imaging and cadaveric specimens have shown the advantage of immobilisation in external rotation.^{3,4} Immobilisation of the arm in external rotation better approximates the Bankart lesion to the glenoid neck compared to the traditional internal rotation.³⁻⁵ Itoi *et al.*⁵ reported no recurrence in dislocation following immobilisation in external rotation for 3 weeks in a randomised, prospective, clinical trial

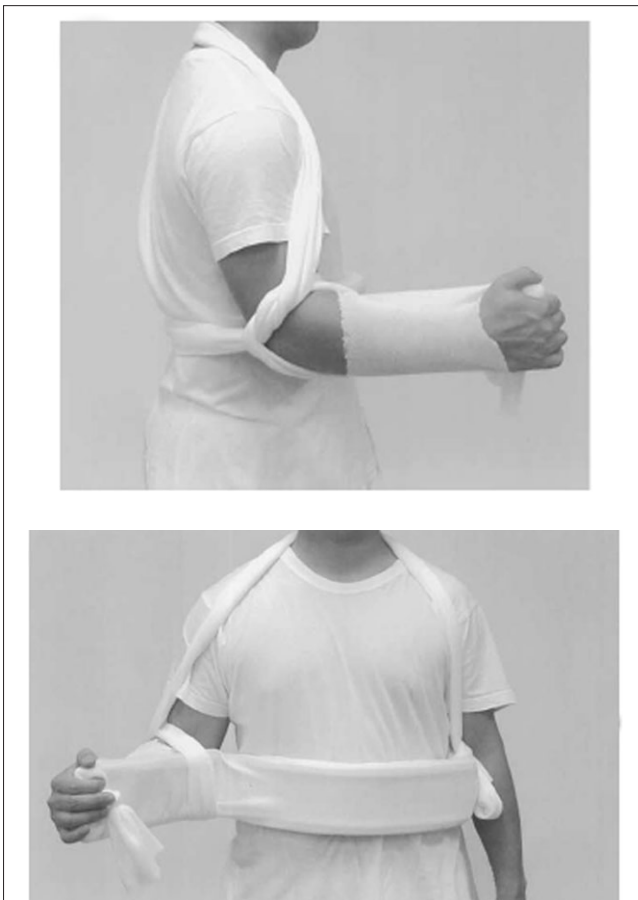


Figure 1 Immobilisation of shoulder in external rotation (side and front view). Picture adopted from Itoi *et al.*⁵ with permission from *The Journal of Shoulder and Elbow Surgery* Board of Trustees.

(Fig. 1). The optimal angle in which the shoulder should be immobilised and the duration of immobilisation remains a matter of debate. Internal rotation still remains the preferred position of immobilisation amongst trauma clinicians, as only six respondents advocated external rotation. The above cited studies advocating immobilisation in external rotation should not cause us to abandon the traditional practice of immobilising arm in internal rotation completely. It should, however, prompt us to question the current opinion in depth. A larger prospective study with longer duration of follow-up is needed to validate these findings.

Arthroscopic stabilisation of AFSD has been shown in prospective trials to be more effective than conventional non-operative treatment. In recent years, a number of studies showed a significant reduction in recurrence rate in patients with AFSD who had undergone arthroscopic stabilisation. The failure rates in conservatively treated patient ranges from 47–92% versus 11–22% in the surgically treated group.^{14–18} Most notably, Kirkley *et al.*,¹⁷ in a prospective randomised clinical trial with 24-months' follow-up, compared arthroscopic stabilisation with a non-operative treated group and found that not only was the recurrence rate lower in the surgically treated group but there was a statistically significant difference in disease-specific quality of life in favour of the operative group. Despite these cited studies, opinions among UK clinicians are still divided. This survey demonstrated that only a small number of respondents would perform immediate operative stabilisation in young, fit patients presenting with this problem. The respondents were less keen in considering surgical management for middle-aged, and even more so in the elderly patient. One plausible explanation for this is that some of the best published results in the literature advocating the use of immediate arthroscopic stabilisation were conducted on a population of US 'military recruits' rather than the 'general' population.^{15,16} These recruits are likely to be more compliant and their participation in active sports may be a mandatory part of their training. Therefore, the results derived from these excellent centres may not be applicable to the average population. However, we found two multicentre clinical trials from Canada and Sweden that revealed superior results in early arthroscopic intervention among younger patient (< 30 years old) group that reflect more typically of the 'general' UK population.^{17,19} Despite this, these studies have short periods of follow-up. Meanwhile, opinions among clinicians will remain divided due to the aforementioned shortfalls of these cited studies. It is, therefore, not surprising to find that UK trauma clinicians are still very 'conservative' in their approach to this particular clinical dilemma. The question remains as to whether a more aggressive approach towards immediate arthroscopic treatment will significantly reduce the recurrence rate. More randomised trials with longer duration of follow-up are required to determine the efficacy of each treatment arms and the age at which immediate repair is necessary in a general population.

The mean duration of immobilisation and follow-up suggested for the conservatively treated group among the young, fit patient was 4.83 weeks and 9.23 weeks, respectively. However, total length of follow-up in the elderly group was 13.48 weeks. This seems a relatively long time, especially in the elderly patients who are less likely to sustain a Bankart lesion and more likely to develop stiffness following prolonged immobilisation. Traditional teaching advocated only 3 weeks of immobility, as anything up to and over this time, the influence on prognosis is minimal.⁶ Although the majority of our respondents consist of orthopaedic trauma surgeons, some of the respondents were from other 'front-line' specialities. Whether this represents a lack of exposure among the 'non-orthopaedic' clinicians to the after-care of AFSD patient in fracture clinics (where most AFSD patient are referred) when evaluating the duration of immobilisation and follow-up is not known.

There are several limitations to this study. It is important to note that this was a survey aimed at a chosen selection of participants. As is the case with any survey, respondents vary their answers according to what they assume the enquirer would like to hear. Furthermore, it was assumed that all patients with acute, first-time shoulder dislocation present themselves immediately to the accident and emergency department. This is not always the case, as some patients will inevitably be treated in a primary care setting, or may not even come across a health professional at all if they are managed in the 'field'. The results of this survey should be interpreted in light of these biases.

Conclusions

There is significant variation in response to the issues incorporated in this survey. On the basis of our results, only a small minority of respondents in our survey who would recommend the use of intra-articular analgesia for pain relief, immobilise the shoulder in external rotation following reduction, or proceed to immediate arthroscopic stabilisation despite its proven efficacy in some published literature. We suggest that these three issues be revised and clarified, ideally in a randomised, controlled, clinical trial prior to the introduction of a protocol for managing this problem.

Acknowledgements

The authors would like to thank all participants from the British Trauma Society of the UK who responded to the survey.

References

- Kroner K, Lind T, Jensen J. The epidemiology of shoulder dislocations. *Arch Orthop Trauma Surg* 1989; **108**: 288–90.
- te Slaa RL, Wijffels MPJM, Marti RK. Questionnaire reveals variations in the management of acute first time shoulder dislocations in The Netherlands. *Eur J Emerg Med* 2003; **10**: 58–61.
- Itoi E, Sashi R, Minagawa H, Shimizu T, Wakabayashi I, Sato K. Position of immobilization after dislocation of the glenohumeral joint. A study with use of magnetic resonance imaging. *J Bone Joint Surg Am* 2001; **83**: 661–7.
- Hatrick C, O'Leary S, Miller B, Goldberg J, Sonnabend D, Walsh W. Should acute anterior dislocation of the shoulder be treated in external rotation. Transactions of the 48th Annual Meeting of the Orthopedic Research Society, Dallas, Texas; 2002; Poster 0830. Available at: <www.ors.org/Transactions/48/0830.PDF> (accessed May 2004).
- Itoi E, Hatakeyama Y, Kido T, Sato T, Minagawa H, Wakabayashi I *et al*. A new method of immobilization after traumatic anterior dislocation of the shoulder: a preliminary study. *J Shoulder Elbow Surg* 2003; **12**: 413–5.
- Rowe CR. Prognosis in dislocation of the shoulder. *J Bone Joint Surg Am* 1956; **38**: 957–77.
- Freudmann M, Hay S. Traumatic anterior shoulder dislocation in the young patient; what do you do? [Abstract; Proceedings from the 2003 meeting of the British Trauma Society]. *Injury Extra* 2003; **34**: 24.
- Hendey G, Kinlaw K. Clinically significant postreduction radiographic abnormalities in anterior shoulder dislocations. *Ann Emerg Med* 1996; **28**: 399–402.
- Shuster M, Abu-Laban RB, Boyd J. Prereduction radiographs in clinically evident anterior shoulder dislocation. *Am J Emerg Med* 1999; **17**: 653–8.
- Hendey GW. Necessity of radiographs in the emergency department management of shoulder dislocations. *Ann Emerg Med* 2000; **36**: 108–13.
- Matthes DE, Roberts T. Intraarticular lidocaine versus intravenous analgesic for reduction of acute anterior shoulder dislocations. A prospective randomised study. *Am J Sports Med* 1995; **23**: 54–8.
- Suder PA, Mikkelsen JB, Hougaard K, Jensen PE. Reduction of traumatic, primary anterior shoulder dislocations with local anaesthesia. *J Shoulder Elbow Surg* 1994; **3**: 288–94.
- Kosnik J, Shamsa F, Raphael E, Huang R, Malachias Z, Georgiadis GM. Anesthetic methods for reduction of acute shoulder dislocations: a prospective randomised study comparing intraarticular lidocaine with intravenous analgesia and sedation. *Am J Emerg Med* 1999; **17**: 566–70.
- Bottoni CR, Wilckens JH, DeBerardino TM, D'Alleyrand J-CG, Rooney RC, Harprate JK *et al*. A prospective, randomised evaluation of arthroscopic stabilisation versus nonoperative treatment in patients with acute, traumatic, first-time shoulder dislocations. *Am J Sports Med* 2002; **30**: 576–80.
- Arciero RA, Wheeler JH, Ryan JB, McBride JT. Arthroscopic Bankart repair versus nonoperative treatment for acute, initial anterior shoulder dislocations. *Am J Sports Med* 1994; **22**: 589–94.
- Wheeler JH, Ryan JB, Arciero RA, Molinari RN. Arthroscopic versus nonoperative treatment of acute shoulder dislocations in young athletes. *Arthroscopy* 1989; **5**: 213–7.
- Kirkley A, Griffin S, Richards C, Miniaci A, Mohtadi N. Prospective randomised clinical trial comparing the effectiveness of immediate arthroscopic stabilisation versus immobilisation and rehabilitation in first time anterior dislocation of the shoulders. *Arthroscopy* 1999; **15**: 507–14.
- te Slaa RS, Brand R, Marti RK. A prospective arthroscopic study of acute first-time anterior shoulder dislocation in the young: A five-year follow-up study. *J Shoulder Elbow Surg* 2003; **12**: 529–34.
- Wintzell G, Haglund-Akerlind Y, Nowak J, Larsson S. Arthroscopic lavage compared with nonoperative treatment for traumatic primary anterior shoulder dislocation: a 2-year follow-up of a prospective randomized study. *J Shoulder Elbow Surg* 1999; **8**: 399–402.