

# Circulation

JOURNAL OF THE AMERICAN HEART ASSOCIATION



## **Sustained Suppression of Neointimal Proliferation by Sirolimus-Eluting Stents: One-Year Angiographic and Intravascular Ultrasound Follow-Up**

J. Eduardo Sousa, Marco A. Costa, Alexandre C. Abizaid, Benno J. Rensing, Andrea S. Abizaid, Luiz F. Tanajura, Ken Kozuma, Glenn Van Langenhove, Amanda G.M.R. Sousa, Robert Falotico, Judith Jaeger, Jeffrey J. Popma and Patrick W. Serruys

*Circulation* 2001;104;2007-2011

DOI: 10.1161/hc4201.098056

Circulation is published by the American Heart Association, 7272 Greenville Avenue, Dallas, TX 72514

Copyright © 2001 American Heart Association. All rights reserved. Print ISSN: 0009-7322. Online ISSN: 1524-4539

The online version of this article, along with updated information and services, is located on the World Wide Web at:

<http://circ.ahajournals.org/cgi/content/full/104/17/2007>

Subscriptions: Information about subscribing to *Circulation* is online at  
<http://circ.ahajournals.org/subscriptions/>

Permissions: Permissions & Rights Desk, Lippincott Williams & Wilkins, 351 West Camden Street, Baltimore, MD 21202-2436. Phone 410-5280-4050. Fax: 410-528-8550. Email:  
[journalpermissions@lww.com](mailto:journalpermissions@lww.com)

Reprints: Information about reprints can be found online at  
<http://www.lww.com/static/html/reprints.html>

## Sustained Suppression of Neointimal Proliferation by Sirolimus-Eluting Stents

### One-Year Angiographic and Intravascular Ultrasound Follow-Up

J. Eduardo Sousa, MD, PhD; Marco A. Costa, MD, PhD; Alexandre C. Abizaid, MD, PhD; Benno J. Rensing, MD, PhD; Andrea S. Abizaid, MD; Luiz F. Tanajura, MD; Ken Kozuma, MD; Glenn Van Langenhove, MD, PhD; Amanda G.M.R. Sousa, MD, PhD; Robert Falotico, PhD; Judith Jaeger, BA; Jeffrey J. Popma, MD; Patrick W. Serruys, MD, PhD

**Background**—We have previously reported a virtual absence of neointimal hyperplasia 4 months after implantation of sirolimus-eluting stents. The aim of the present investigation was to determine whether these results are sustained over a period of 1 year.

**Methods and Results**—Forty-five patients with de novo coronary disease were successfully treated with the implantation of a single sirolimus-eluting Bx VELOCITY stent in São Paulo, Brazil (n=30, 15 fast release [group I, GI] and 15 slow release [GII]) and Rotterdam, The Netherlands (15 slow release, GIII). Angiographic and volumetric intravascular ultrasound (IVUS) follow-up was obtained at 4 and 12 months (GI and GII) and 6 months (GIII). In-stent minimal lumen diameter and percent diameter stenosis remained essentially unchanged in all groups (at 12 months, GI and GII; at 6 months, GIII). Follow-up in-lesion minimal lumen diameter was 2.28 mm (GIII), 2.32 mm (GI), and 2.48 mm (GII). No patient approached the  $\geq 50\%$  diameter stenosis at 1 year by angiography or IVUS assessment, and no edge restenosis was observed. Neointimal hyperplasia, as detected by IVUS, was virtually absent at 6 months ( $2 \pm 5\%$  obstruction volume, GIII) and at 12 months (GI= $2 \pm 5\%$  and GII= $2 \pm 3\%$ ).

**Conclusions**—This study demonstrates a sustained suppression of neointimal proliferation by sirolimus-eluting Bx VELOCITY stents 1 year after implantation. (*Circulation*. 2001;104:2007-2011.)

**Key Words:** angiography ■ drugs ■ stents ■ restenosis ■ ultrasonics

Despite major technological advances in the past decades, of which the coronary stent is one of the most important, the percutaneous treatment of coronary artery disease is still hampered by a 20% to 30% incidence of restenosis. The list of candidate therapies and devices for prevention of restenosis after angioplasty is long and ever expanding. However, few if any have substantially improved the result of stenting for the treatment of de novo lesions. Intracoronary radiation has so far proven to be effective for the treatment of in-stent restenosis but not for the treatment of de novo lesions.<sup>1</sup> As a result of their ability to deliver prolonged and sufficient intramural drug concentrations to the target coronary segment, drug-eluting stents have emerged as a potential solution for restenosis. Our group has recently reported an almost complete absence of neointimal hyperplasia 4 months after implantation of sirolimus-eluting Bx VELOCITY stents.<sup>2</sup> The local release of sirolimus (rapamycin, Rapamune), a natural macrocyclic lactone with potent immunosuppressive action,<sup>3</sup>

resulted in elimination of restenosis in this first series of patients. Comparable results have only been observed after the implantation of high-activity  $\beta$ -emitting stents (9 mm<sup>3</sup> of neointimal hyperplasia at 6-month follow-up).<sup>4</sup> However, a worrying late progression of in-stent neointimal hyperplasia was observed between 6 months and 1 year after implantation of radioactive stents.<sup>5</sup>

---

#### See p 1996

---

The aim of the present investigation was to determine whether sirolimus-eluting stents produce a sustained suppression of the neointimal proliferation over a period of 1 year or merely delay the restenosis process.

#### Methods

##### Study Population

Forty-five patients with native coronary artery disease and angina pectoris were successfully treated with the implantation of a single

---

Received July 10, 2001; revision received August 14, 2001; accepted August 15, 2001.

From the Institute Dante Pazzanese of Cardiology (J.E.S., M.A.C., A.C.A., A.S.A., L.F.T., A.G.M.R.S.), São Paulo, Brazil; Thoraxcenter, Dijkzigt University Hospital (B.J.R., K.K., G.V.L. P.W.S.), Rotterdam, The Netherlands; Cordis, a Johnson and Johnson Company (R.F., J.J.), Warren, NJ; and Brigham and Women's Hospital (J.J.P.), Boston, Mass.

Correspondence to Professor J. Eduardo Sousa, MD, PhD, Director of the Institute Dante Pazzanese of Cardiology, Av. Dr Dante Pazzanese, 500 - Ibirapuera, 04012180, São Paulo, Brazil. E-mail [jesousa@uol.com.br](mailto:jesousa@uol.com.br)

© 2001 American Heart Association, Inc.

*Circulation* is available at <http://www.circulationaha.org>

sirolimus-eluting Bx VELOCITY stent. Only lesions  $\leq 18$  mm in length and vessels  $\geq 3$  and  $\leq 3.5$  mm in diameter were included. Total occlusion, ostial or thrombus containing lesions, unprotected left main disease with  $>50\%$  stenosis, occurrence of myocardial infarction within the preceding 72 hours, and left ventricular ejection fraction  $<30\%$  were the major exclusion criteria. Thirty patients were electively treated with two different formulations of sirolimus-eluting stents (fast release [FR],  $n=15$ , group I, and slow release [SR],  $n=15$ , group II) at the Institute Dante Pazzanese of Cardiology, São Paulo, Brazil. A third cohort of patients ( $n=15$ , group III) was treated with SR sirolimus-eluting stents at the Thoraxcenter, Erasmus University Rotterdam, The Netherlands.

### Drug-Polymer Matrix and Elution Kinetics

Sirolimus was blended in a mixture of nonerodable polymers, and a 5- $\mu\text{m}$ -thick layer of sirolimus-polymer matrix was applied onto the surface of the Bx VELOCITY stent (Cordis), a laser-cut 316L stainless-steel balloon-expandable stent.

The drug is almost completely eluted by 15 days after implantation in the FR formulation. Another layer of drug-free polymer was applied on top of the drug-polymer matrix to introduce a diffusion barrier and prolong drug release to  $>28$  days in the SR formulation. All stents, regardless of the coating composition, were loaded with a fixed amount of sirolimus per unit of metal surface area (140  $\mu\text{g}$  sirolimus/ $\text{cm}^2$ ).

In vivo experiments have shown that sirolimus levels in whole blood peak at 1 hour ( $2.6 \pm 0.7$  ng/mL, FR;  $0.9 \pm 0.2$  ng/mL, SR) after implantation and fall below the lower limit of quantification by 72 hours (0.4 ng/mL) (Bruce D. Klugherz, unpublished data, 2000). Taking into account that renal transplant patients maintain chronic blood levels of rapamycin between 8 and 17 ng/mL, the peak blood level after implantation of a sirolimus-eluting stent is absolutely negligible.

### Stent Procedure

Stents were implanted according to standard practice, after balloon predilatation and followed by high-pressure ( $>12$  atmospheres) balloon after dilatation. All stents were 18 mm long and 3 to 3.5 mm in diameter. Heparin was given to maintain the activated clotting time  $>300$  seconds. Patients received aspirin (325 mg/d, indefinitely) started at least 12 hours before the procedure and a 300-mg loading dose of clopidogrel immediately after stent implantation and 75 mg/d for 60 days. The protocol was approved by the Medical Ethical Committees of both institutions, and written informed consent was obtained from every patient.

### Angiographic and IVUS Procedures

Patients in São Paulo (groups I and II) underwent intravascular ultrasound (IVUS) and angiographic follow-up at 4 and 12 months. In Rotterdam (group III), patients returned for repeat angiography and IVUS assessment at 6 months, the classical restenosis time point. Intracoronary nitrates were administered immediately before each angiographic and IVUS acquisition. Postprocedure angiography was performed in at least 2 orthogonal projections, which were repeated at the follow-up studies. Quantitative angiographic analysis was done by an independent core laboratory (Brigham and Women's Hospital, Boston, Mass).

The segments subject to three-dimensional (3D) IVUS reconstruction were examined with a 30-MHz single-element mechanical transducer (ClearView, CVIS, Boston Scientific Corporation). A constant pullback speed of 0.5 mm/s was used for IVUS image acquisitions. A complete IVUS run was recorded on s-VHS tape for offline 3D reconstruction. At 12 months, IVUS images were also acquired using an ECG-triggered pullback device with a stepping motor at 0.2 mm/step (EchoScan, Tomtec) to assure a precise quantification of neointimal hyperplasia volume. This system acquires images coinciding with the peak of the R wave, eliminating the artifacts caused by the movement of the heart during the cardiac cycle and ultimately improving the quality of image for 3D volumetric quantification. Volumetric IVUS analysis was carried out by

an independent core laboratory (Cardialysis BV, Rotterdam, The Netherlands).<sup>6,7</sup>

### Quantitative Measurements

Two coronary segments were subjected to quantitative angiography, in-stent and in-lesion segments. The in-stent analysis encompassed only the 18-mm-long segment covered by the stent. The in-lesion segment was defined as the stent plus 5 mm proximal and 5 mm distal to the edge or the nearest side branch. In-stent and in-lesion restenosis was defined as  $\geq 50\%$  diameter stenosis (DS) at follow-up, located within the stent and target lesion, respectively. Edge restenosis was defined as  $\geq 50\%$  DS at follow-up, located at the proximal or distal edge. Minimal lumen diameter (MLD) and percent DS were calculated for each segment.

Quantitative IVUS analyses of the stent segment were performed at all time points. Lumen and stent boundaries were detected using a minimum-cost algorithm. Total stent and lumen volumes were calculated as previously described. Intimal hyperplasia (IH) volume was calculated as stent volume minus luminal volume. Feasibility, reproducibility, and interobserver and intraobserver variability of these measurements have been validated previously.<sup>8</sup>

### Statistical Analysis

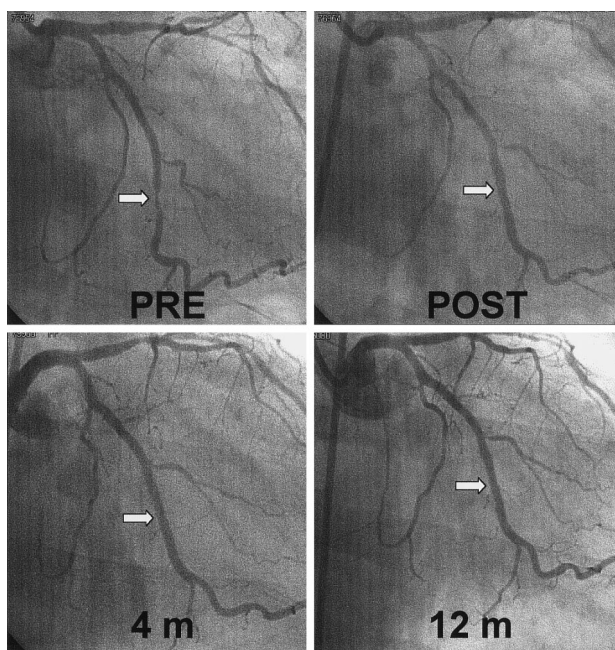
Continuous variables are expressed as mean  $\pm$  SD. Comparisons between postintervention and follow-up measurements were performed with a 2-tailed paired *t* test. Comparisons between groups were performed using unpaired Student's *t* test. A *P* value  $<0.05$  was considered statistically significant.

### Results

Baseline characteristics were similar between the 3 groups. Overall, 29 patients were male, 32 had stable angina, and 13 were unstable. Mean age was 55.1 (group I), 57.9 (group II) and 60 years (group III). Six patients had a history of diabetes mellitus. Clopidogrel was discontinued at 60 days in all patients.

At the Thoraxcenter, 1 of the 15 patients died on day 2 of a cerebral hemorrhage. She had received abciximab during the procedure and for 12 hours thereafter. Two additional patients (group III) suffered a vessel occlusion during or immediately after the procedure attributable to distal edge dissection and were successfully treated with additional stenting. Subsequent clinical follow-up was uneventful for both patients, and no restenosis was detected at 6-month angiographic follow-up. Finally, 1 asymptomatic patient from Rotterdam refused repeat angiography; thus, 13 completed 6-month angiographic and IVUS follow-up. As reported previously,<sup>2</sup> all patients in groups I and II were discharged without any clinical event. One asymptomatic patient (group II) refused repeat angiography at 12 months.

A representative sequence of angiograms from a single patient are shown in Figure 1. Preprocedure reference vessel diameter (RD) was  $2.85 \pm 0.46$  mm, and postprocedure MLD was  $2.47 \pm 0.38$ -mm (in-lesion) and  $2.9 \pm 0.27$ -mm (in-stent) in the Rotterdam patients (group III). Four-month data from groups I and II have been reported previously.<sup>2</sup> One-year in-stent MLD (group I,  $2.73 \pm 0.3$  mm; group II,  $2.87 \pm 0.4$  mm) and percent DS (group I,  $8.9 \pm 6.1\%$ ; group II,  $6.7 \pm 7\%$ ) remained essentially unchanged compared with 4-month follow-up. At 6 months (group III), in-stent MLD was  $2.66 \pm 0.3$  mm, and percent DS was  $8.9 \pm 7.6\%$  ( $P=NS$  compared with postprocedure). Changes in in-lesion MLD and percent DS are shown in Figure 2. At 12 months,

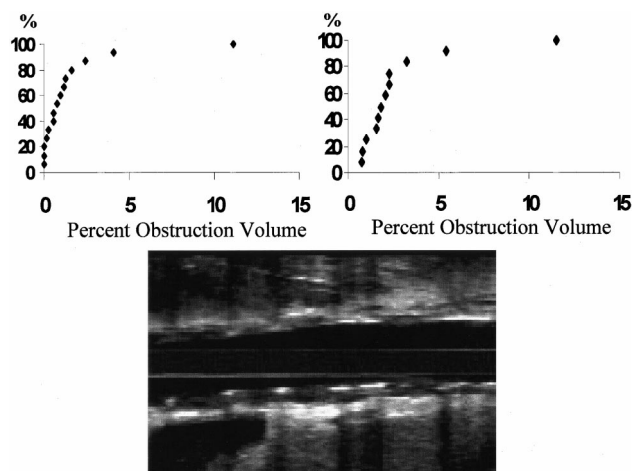


**Figure 1.** Angiography shows a lesion in the mid portion of the left circumflex marginal branch (white arrow), which was treated with the implantation of a sirolimus-coated BX-velocity stent (top right). Lumen dimensions remained unchanged at 4- and 12- month follow-up (bottom).

in-lesion angiographic lumen dimension showed a small decrease compared with postprocedure in both groups (Figure 2,  $P < 0.01$ ). Between 4 months and 12 months, a very small decrease, albeit statically significant ( $P = 0.004$ ), in in-lesion MLD was observed in group I. No patient approached the  $\geq 50\%$  DS at 1-year by angiography or IVUS assessment, and no edge restenosis was observed.

At 6-month follow-up, lumen volume was  $156.7 \pm 63.6 \text{ mm}^3$  (versus  $156.5 \pm 64.1 \text{ mm}^3$  at postprocedure,  $P = \text{NS}$ ) and intimal hyperplasia volume was  $5.7 \pm 17.7 \text{ mm}^3$  (group III). Thus, the percent obstruction volume was  $2 \pm 4.98\%$ , similar to the results reported at 4 months in the patients from São Paulo.<sup>2</sup>

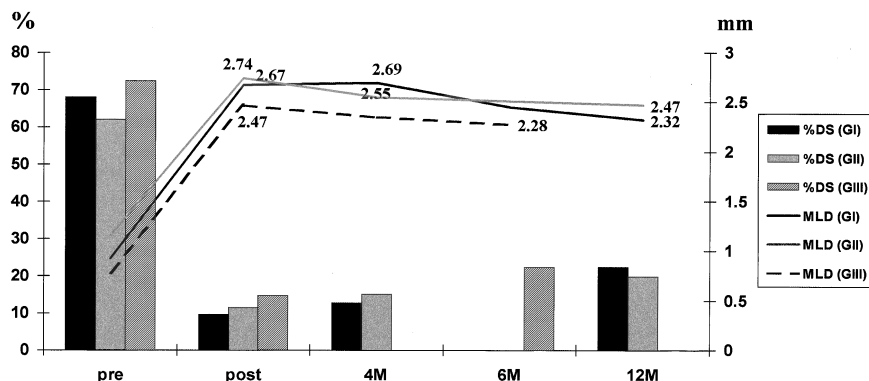
One-year volumetric IVUS data (Figure 3) from the São Paulo patients were actually better than those reported previously at 4-month follow-up.<sup>2</sup> Only 2 patients had  $>10\%$  IH after 12 months (Figure 3). Differences in the method of volumetric quantification probably explain these findings. As



**Figure 3.** Cumulative distribution curves of percent obstruction volumes in group I (left) and group II (right) at 12-month follow-up. Longitudinal IVUS reconstruction illustrates the virtual absence of in-stent intimal hyperplasia at 12 months (bottom).

a result of the virtual absence of neointimal hyperplasia, the automated contour detection algorithm that was used for the original analysis superimposed the contours of the stent and lumen boundaries in the majority of the cases. Thus, the core laboratory analyst used a “copy and shrink” tool of the quantitative analysis software to dissociate the two contours. This action led to an overestimation of the amount of IH. At 12-month follow-up analysis, the lumen and stent contours were not dissociated artificially, unless IH was clearly visualized. To compare 4-month and 12-month IVUS data, the core laboratory reanalyzed the 4-month IVUS images using the same methodology used at 12 months (Table).

In one patient (group I), 12-month IVUS assessment showed an unstable plaque proximal to the stent. Lesion vulnerability was characterized by positive vessel remodeling and a large lipid pool delimited by a thin fibrous cap (Figure 4). This preexisting plaque increased progressively from the time of the initial procedure, producing a linear deterioration in lumen dimensions (MLD was 2.85 mm postprocedure, 2.51 mm at 4 months, and 2.02 mm at 12 months). No sign of thrombus was detected by angiography or IVUS. At 12 months, the patient was asymptomatic and had a negative stress test. However, at 14-month follow-up, he returned with a non-Q-wave myocardial infarction. Angiography showed



**Figure 2.** In-lesion percent diameter stenosis (%DS) and MLD over a period of 1 year. Angiographic follow-up was performed at 4 and 12 months in group I (GI) and GII and at 6 months in GIII.

**Three-Dimensional Volumetric IVUS Measurements 4 and 12 Months After Implantation of Sirolimus-Eluting Stent**

Follow-up period, mo	Stent Volume, mm <sup>3</sup>		Lumen Volume, mm <sup>3</sup>		IH Volume, mm <sup>3</sup>		Obstruction Volume, %	
	4	12	4	12	4	12	4	12
Group I	134±30	127±26	134±30	124±25	0.4±0.8	3.2±8.5	0.3±0.6	2.3±5.5
Group II	138±21	127±30	137±22	124±30	0.3±0.9	2.5±3.4	0.3±0.8	2.2±3.4

No statistical differences were observed between groups or between 4-month and 12-month data within the same group.

the target vessel occluded proximal to the stent, and repeat angioplasty was performed.

The remaining 29 patients of the first 2 cohorts (groups I and II) have now completed 15-month clinical follow-up uneventfully. Similarly, the 14 Rotterdam patients were asymptomatic, with no additional adverse events up to 9 months after the index procedure.

### Discussion

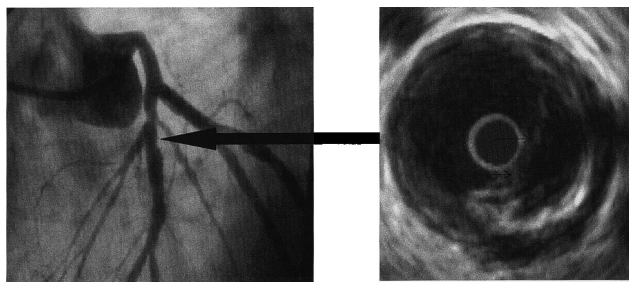
The present study demonstrates a potent, long-lasting inhibitory effect on neointimal proliferation exerted by the local release of sirolimus via a stent platform. Regardless of the coating formulation (SR or FR) or population treated (São Paulo or Rotterdam), neointimal hyperplasia, as detected by both angiography and volumetric IVUS quantification, was minimal at all time points (4, 6, or 12 months).

The lack of restenosis observed in this first series of patients treated with sirolimus-eluting Bx VELOCITY stents is probably a consequence of the scaffolding properties of the stent as well as the potent cytostatic effect of sirolimus.<sup>9,10</sup> Like cyclosporin A and tacrolimus (FK506), sirolimus binds to specific cytosolic proteins. However, the mechanism of action of sirolimus is distinct from other immunosuppressive agents that act solely by inhibiting DNA synthesis. The sirolimus:FKBP complex binds to a specific cell-cycle regulatory protein, the mTOR (mammalian target of rapamycin), and inhibits its activation.<sup>11</sup> The inhibition of mTOR induces cell-cycle arrest in late G1 phase.<sup>12-14</sup> The upregulation of FK506-binding protein 12 (FKBP12) observed in human neointimal smooth muscle cells additionally supports the potential antirestenotic effect of sirolimus.<sup>15</sup> Preclinical data have demonstrated the efficacy of both systemic<sup>13,16</sup> and local administration (via drug-eluting stent) (Andrew J. Carter,

unpublished data, 2000) of sirolimus in reducing neointimal hyperplasia in different models of restenosis.

A concern about potential late complications, such as late thrombosis, associated with new therapies is a legacy from our previous experience with intracoronary radiation therapy.<sup>17</sup> In our series, one patient (out of 44) experienced a thrombotic event involving the target coronary artery 14 months after the procedure. It is important to note that IVUS showed an unstable plaque located proximal to the stent that grew progressively in size over the period of observation. The relationship between unstable plaque, as characterized by IVUS, and coronary thrombosis has been reported previously and may explain this unexpected event.<sup>18,19</sup> Experimental investigations have shown a similar degree of re-endothelialization between bare and sirolimus-coated stents occurring as early as 30 days after implantation (Andrew J Carter, unpublished data, 2001), ie, sirolimus does not seem to delay endothelialization. Nevertheless, one cannot completely rule out the possibility of late-stent thrombosis as a cause of vessel occlusion in this case. The occurrence of this somewhat anecdotal event should be interpreted with caution. Data from large randomized multicenter trials, already underway, will be necessary to definitively address this important question.

After our previous study showing a surprising near-absence of IH 4 months after implantation of sirolimus-eluting stents,<sup>2</sup> the logical question was whether this effect would be permanent or whether it merely represented a delay in the proliferative response. The basis for these concerns is the unexpected late-luminal deterioration observed with catheter-based radiation systems and radioactive stents,<sup>1,5</sup> although the mechanisms of action of sirolimus-eluting stents differ considerably from intracoronary brachytherapy. In the present study, angiographic lumen dimensions and IVUS-detected IH volume assessed both at 6-month follow-up (in group III) and at 12 months (groups I and II) was not substantially different from what was observed at 4 months (Table). Thus, at 12-month follow-up, there is no evidence of significant late catch up, and the 12-month IH volume observed in the present study is less than one third of that reported with any previously tested antirestenosis therapy.<sup>6,7</sup> If the findings of the present investigation are confirmed by large, randomized, placebo-controlled trials, this technology is likely to have a major impact on the treatment of coronary artery disease in the near future.



**Figure 4.** Angiography of the left anterior descending artery showing a nonsignificant stenosis at the proximal edge of the stent (white arrow) at 12-month follow-up. IVUS cross-sectional image at the site of the lesion shows an eccentric plaque with a large lipid pool (L) delimited by a fibrous cap (arrows). This vessel was occluded 2 months later.

### Acknowledgments

We are indebted to the patients for their participation in this research. We gratefully appreciate the invaluable contribution of the medical and technical staffs of the Institute Dante Pazzanese of Cardiology

and Thoraxcenter. We also thank Dr Brian Firth for his careful review of the manuscript and constructive comments.

## References

1. Teirstein PS, Massullo V, Jani S, et al. Two-year follow-up after catheter-based radiotherapy to inhibit coronary restenosis. *Circulation*. 1999;99:243–247.
2. Sousa JE, Costa MA, Abizaid A, et al. Lack of neointimal proliferation after implantation of sirolimus-coated stents in human coronary arteries: a quantitative coronary angiography and three-dimensional intravascular ultrasound study. *Circulation*. 2001;103:192–195.
3. Groth CG, Backman L, Morales JM, et al. Sirolimus (rapamycin)-based therapy in human renal transplantation: similar efficacy and different toxicity compared with cyclosporine. Sirolimus European Renal Transplant Study Group. *Transplantation*. 1999;67:1036–1042.
4. Kay IP, Sabate M, Costa MA, et al. Positive geometric vascular remodeling is seen after catheter-based radiation followed by conventional stent implantation but not after radioactive stent implantation. *Circulation*. 2000;102:1434–1439.
5. Kay IP, Wardeh AJ, Kozuma K, et al. Radioactive stents delay but do not prevent in-stent neointimal hyperplasia. *Circulation*. 2001;103:14–17.
6. Acute platelet inhibition with abciximab does not reduce in-stent restenosis (ERASER study): the ERASER Investigators. *Circulation*. 1999;100:799–806.
7. Costa MA, Sabaté M, Kay IP, et al. Three-dimensional intravascular ultrasonic volumetric quantification of stent recoil and neointimal formation of two new generation tubular stents. *Am J Cardiol*. 2000;85:135–139.
8. von Birgelen C, de Vrey EA, Mintz GS, et al. ECG-gated three-dimensional intravascular ultrasound: feasibility and reproducibility of the automated analysis of coronary lumen and atherosclerotic plaque dimensions in humans. *Circulation*. 1997;96:2944–2952.
9. Poon M, Marx SO, Gallo R, et al. Rapamycin inhibits vascular smooth muscle cell migration. *J Clin Invest*. 1996;98:2277–2283.
10. Gonzalez J, Harris T, Childs G, et al. Rapamycin blocks il-2-driven t cell cycle progression while preserving t cell survival. *Blood Cells Mol Dis*. 2001;27:572–585.
11. Roque M, Reis ED, Cordon-Cardo C, et al. Effect of p27 deficiency and rapamycin on intimal hyperplasia: in vivo and in vitro studies using a p27 knockout mouse model. *Lab Invest*. 2001;81:895–903.
12. Roque M, Cordon-Cardo C, Fuster V, et al. Modulation of apoptosis, proliferation, and p27 expression in a porcine coronary angioplasty model. *Atherosclerosis*. 2000;153:315–322.
13. Gallo R, Padurean A, Jayaraman T, et al. Inhibition of intimal thickening after balloon angioplasty in porcine coronary arteries by targeting regulators of the cell cycle. *Circulation*. 1999;99:2164–2170.
14. Marx SO, Jayaraman T, Go LO, et al. Rapamycin-FKBP inhibits cell cycle regulators of proliferation in vascular smooth muscle cells. *Circ Res*. 1995;76:412–417.
15. Zohlhofer D, Klein CA, Richter T, et al. gene expression profiling of human stent-induced neointima by cDNA array analysis of microscopic specimens retrieved by helix cutter atherectomy: detection of FK506-binding protein 12 upregulation. *Circulation*. 2001;103:1396–1402.
16. Gregory CR, Huie P, Billingham ME, et al. Rapamycin inhibits arterial intimal thickening caused by both alloimmune and mechanical injury: its effect on cellular, growth factor, and cytokine response in injured vessels. *Transplantation*. 1993;55:1409–1418.
17. Costa MA, Sabate M, van der Giessen WJ, et al. Late coronary occlusion after intracoronary brachytherapy. *Circulation*. 1999;100:789–792.
18. Ge J, Chirillo F, Schwedtman J, et al. Screening of ruptured plaques in patients with coronary artery disease by intravascular ultrasound. *Heart*. 1999;81:621–627.
19. Schoenhagen P, Ziada KM, Kapadia SR, et al. Extent and direction of arterial remodeling in stable versus unstable coronary syndromes: an intravascular ultrasound study. *Circulation*. 2000;101:598–603.