

REVIEW ARTICLE

Dan L. Longo, M.D., *Editor*

Syndromes of Thrombotic Microangiopathy

James N. George, M.D., and Carla M. Nester, M.D.

From the Department of Biostatistics and Epidemiology, College of Public Health, and the Department of Internal Medicine, College of Medicine, University of Oklahoma Health Sciences Center, Oklahoma City (J.N.G.); and the Stead Family Department of Pediatrics and Department of Internal Medicine, University of Iowa, Iowa City (C.M.N.). Address reprint requests to Dr. George at the Departments of Internal Medicine and Biostatistics and Epidemiology, University of Oklahoma Health Sciences Center, P.O. Box 26901, Oklahoma City, OK 73126-0901, or at james-george@ouhsc.edu.

N Engl J Med 2014;371:654-66.

DOI: 10.1056/NEJMr1312353

Copyright © 2014 Massachusetts Medical Society.

THE THROMBOTIC MICROANGIOPATHY (TMA) SYNDROMES ARE EXTRAORDINARILY diverse. They may be hereditary or acquired. They occur in children and adults. The onset can be sudden or gradual. Despite their diversity, TMA syndromes are united by common, defining clinical and pathological features. The clinical features include microangiopathic hemolytic anemia, thrombocytopenia, and organ injury.¹ The pathological features are vascular damage that is manifested by arteriolar and capillary thrombosis with characteristic abnormalities in the endothelium and vessel wall.² We focus on nine disorders that we describe as primary TMA syndromes, for which there is evidence supporting a defined abnormality as the probable cause (Table 1 and Fig. 1; and the interactive graphic, available with the full text of this article at NEJM.org). For clarity of this discussion, the names that have been chosen for these syndromes reflect their cause.³ However, we retain the common names of thrombotic thrombocytopenic purpura (TTP) for ADAMTS13 deficiency-mediated TMA and the hemolytic-uremic syndrome for Shiga toxin-mediated TMA (ST-HUS) because these names are familiar. We do not use the term “atypical HUS,” which was historically used to distinguish heterogeneous, uncharacterized syndromes from ST-HUS, since the term lacks both specificity and a suggestion of cause. We also do not use the term “idiopathic” with any of the primary TMA syndromes.

The presence of a causal abnormality, such as ADAMTS13 deficiency or a complement mutation, may not be clinically expressed until a condition, such as pregnancy, surgery, or an inflammatory disorder, precipitates an acute TMA episode. The treatment of such patients is focused on the cause of the primary TMA syndrome, not the precipitating condition. These patients are distinct from many other patients who have microangiopathic hemolytic anemia and thrombocytopenia that are manifestations of an underlying disorder (Table 2). The treatment of such patients is focused on the underlying disorder.

Knowledge of the pathogenesis, management, and outcomes of the primary TMA syndromes has accelerated in recent years (Fig. 2; and Table S1 in the Supplementary Appendix, available at NEJM.org). The objective of this review is to provide a unified perspective of these syndromes.

TTP (ACQUIRED AND HEREDITARY)

BACKGROUND

In 1924, Moschcowitz described a 16-year-old girl with weakness, pallor, purpura, and hemiparesis who died after 14 days with cardiac failure. Autopsy revealed hyaline thrombi in terminal arterioles and capillaries throughout most organs, including the kidneys.⁴ This report was the first description of TMA, presumably TTP, also called ADAMTS13 deficiency-mediated TMA.

CAUSE

In 1982, unusually large multimers of von Willebrand factor were observed in patients with chronic, relapsing (hereditary) TTP.⁵ This finding led to the discovery of

Table 1. Primary Thrombotic Microangiopathy (TMA) Syndromes.*

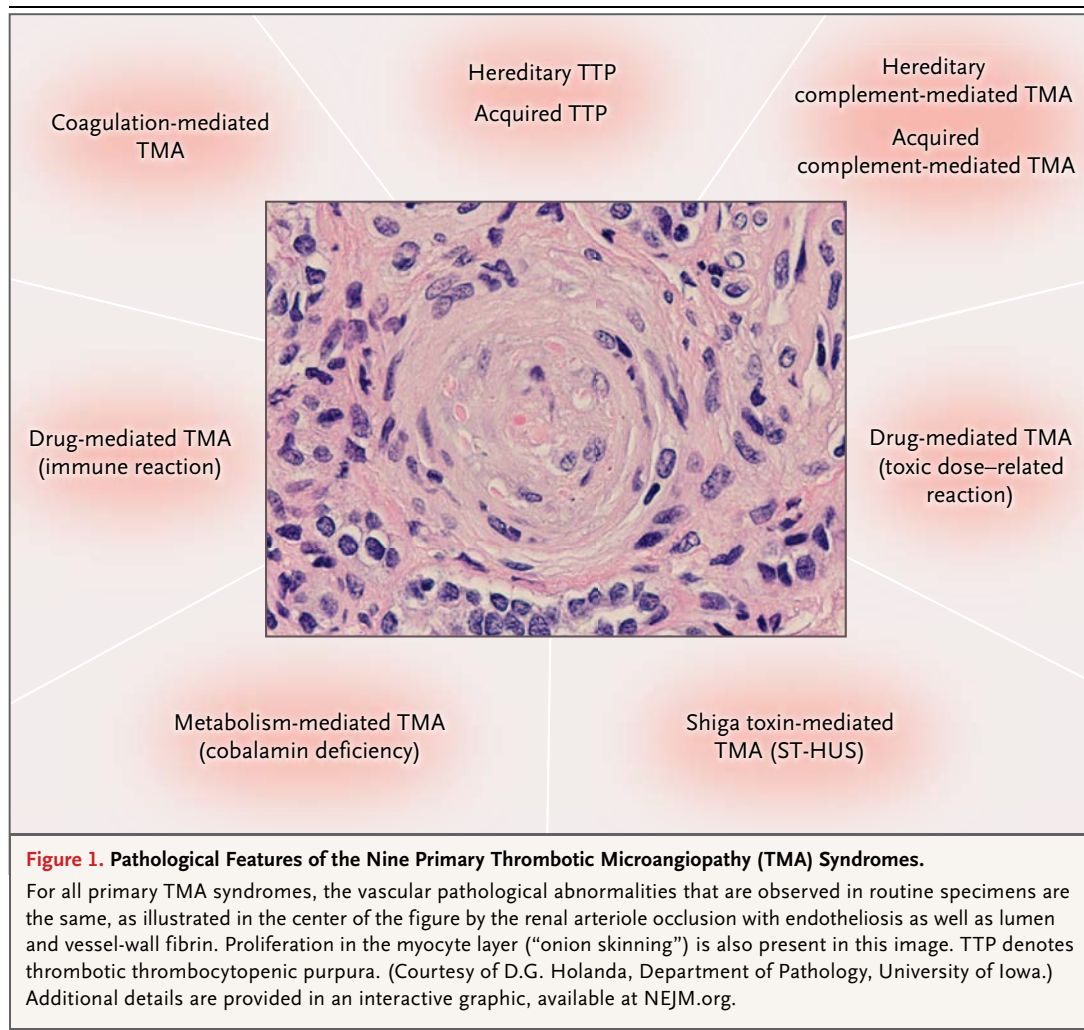
Name	Cause	Clinical Features	Initial Management
Hereditary disorders			
ADAMTS13 deficiency–mediated TMA (also called TTP)	Homozygous or compound heterozygous <i>ADAMTS13</i> mutations	Initial presentation is typically in children but may also be in adults; possible evidence of ischemic organ injury; acute kidney injury is uncommon; patients with heterozygous mutations are asymptomatic.	Plasma infusion
Complement-mediated TMA	Mutations in <i>CFH</i> , <i>CFI</i> , <i>CFB</i> , <i>C3</i> , <i>CD46</i> , and other complement genes causing uncontrolled activation of the alternative pathway of complement	Initial presentation is often in children but may also be in adults; acute kidney injury is common; patients with heterozygous mutations may be symptomatic.	Plasma infusion or exchange, anti-complement agent
Metabolism-mediated TMA	Homozygous mutations in <i>MMACHC</i> (encoding methylmalonic aciduria and homocystinuria type C protein)	Initial presentation is typically in children <1 year of age; also reported in one young adult with hypertension and acute kidney injury.	Vitamin B ₁₂ , betaine, folic acid
Coagulation-mediated TMA	Homozygous mutations in <i>DGKE</i> ; mutations in <i>PLG</i> and <i>THBD</i> also implicated	Initial presentation with acute kidney injury is typically in children <1 year of age with <i>DGKE</i> mutations; clinical features of disorders associated with other mutations have not been described.	Plasma infusion
Acquired disorders			
ADAMTS13 deficiency–mediated TMA (also called TTP)	Autoantibody inhibition of ADAMTS13 activity	Initial presentation is uncommon in children; often presents with evidence of ischemic organ injury; acute kidney injury is uncommon.	Plasma exchange, immunosuppression
Shiga toxin–mediated TMA (also called ST-HUS)	Enteric infection with a Shiga toxin–secreting strain of <i>Escherichia coli</i> or <i>Shigella dysenteriae</i>	Initial presentation is more common in young children, typically with acute kidney injury; most cases are sporadic; large outbreaks also occur.	Supportive care
Drug-mediated TMA (immune reaction)	Quinine and possibly other drugs, with multiple cells affected by drug-dependent antibodies	Initial presentation is a sudden onset of severe systemic symptoms with anuric acute kidney injury.	Removal of drug, supportive care
Drug-mediated TMA (toxic dose–related reaction)	Multiple potential mechanisms (e.g., VEGF inhibition)	Gradual onset of renal failure occurs over weeks or months.	Removal of drug, supportive care
Complement-mediated TMA	Antibody inhibition of complement factor H activity	Initial presentation is acute kidney injury in children or adults.	Plasma exchange, immunosuppression, anticomplement agent

* The primary TMA syndromes are described by evidence supporting a defined cause. Shiga toxin–mediated TMA (also called Shiga toxin–related hemolytic–uremic syndrome [ST-HUS]) occurs primarily in children and may be the most common of the nine primary TMA syndromes. Among adults, acquired thrombotic thrombocytopenic purpura (TTP) may be the most common primary TMA syndrome; acquired TTP is rare in children, in whom the incidence may be similar to that of hereditary TTP. The frequencies of TMAs that are mediated by complement, metabolism, coagulation, or drugs are unknown. The demonstration of antibodies that can neutralize the activity of complement factor H suggests that acquired TMA mediated by a deficiency in complement factor H may occur. DGKE denotes diacylglycerol kinase ϵ , PLG plasminogen, THBD thrombomodulin, and VEGF vascular endothelial growth factor.

a von Willebrand factor–cleaving protease^{6,7} that was subsequently characterized as ADAMTS13.⁸ ADAMTS13 cleaves von Willebrand factor multimers that are secreted from vascular endothelial cells.¹ ADAMTS13 deficiency results in unusually large von Willebrand factor multimers and the risk of platelet thrombi in small vessels with high shear rates.¹

Hereditary TTP (also called Upshaw–Schul-

man syndrome) is caused by homozygous or compound heterozygous *ADAMTS13* mutations.⁸ Patients with heterozygous mutations have no apparent abnormalities.⁹ Acquired TTP is an autoimmune disorder caused by autoantibody inhibition of ADAMTS13 activity.¹ The incidence of acquired TTP is much greater in adults (2.9 cases per 1 million per year) than in children (0.1 cases per 1 million per year).¹⁰ Factors that are associ-



An interactive graphic detailing the nine TMA disorders is available at NEJM.org

ated with an increased frequency of this disorder include an age of 18 to 50 years, black race, and female sex.¹⁰

PRESENTATION AND DIAGNOSIS

Among the primary TMA syndromes, TTP is unique for rarely causing severe acute kidney injury (Fig. 3). The clinical features of hereditary TTP are recurrent episodes of microangiopathic hemolytic anemia and thrombocytopenia, often with neurologic abnormalities or other signs of organ injury. Diagnosis of hereditary TTP requires documentation of ADAMTS13 deficiency and an absence of ADAMTS13 autoantibody inhibitor, and confirmation requires documentation of ADAMTS13 mutations. Hereditary TTP may be apparent at birth, with microangiopathic hemolytic anemia and thrombocytopenia, or not

until adulthood, when it may be precipitated by a condition such as pregnancy.^{9,11,12} Although the severity of the condition may be related to ADAMTS13 mutations,¹³ observations of heterogeneity among siblings suggest that clinical manifestations require additional genetic or environmental factors, similar to observations in *Adamts13*-deficient mice.¹⁴

Presenting clinical features of acquired TTP are diverse; some patients have minimal abnormalities, whereas others are critically ill.¹⁵ Weakness, gastrointestinal symptoms, purpura, and transient focal neurologic abnormalities are common. However, one third of patients have no neurologic abnormalities. Most patients have normal or only transient, mildly elevated creatinine values. Diagnostic criteria are the presence of microangiopathic hemolytic anemia and

thrombocytopenia without another apparent cause. Thus, the exclusion of other primary TMA syndromes may not be possible.¹⁶ An ADAMTS13 level indicating less than 10% of normal activity supports the clinical diagnosis of acquired TTP. It identifies almost all patients at risk for relapse, but this level is neither sufficiently sensitive to identify all patients with TTP nor sufficiently specific to exclude patients with underlying disorders.^{17,18}

TREATMENT

The treatment for hereditary TTP is ADAMTS13 replacement by plasma infusion.¹⁹ Patients with severe plasma allergic reactions have been effectively treated with plasma-derived factor VIII concentrate that contains ADAMTS13.²⁰ Although many patients require plasma only when thrombocytopenia or symptoms occur, others may require regular prophylactic plasma infusions.

Before the use of plasma exchange, survival from acquired TTP was 10%.²¹ In 1991, a randomized, controlled trial documented a survival rate of 78% with plasma exchange.²² The high mortality without treatment creates urgency to begin plasma exchange, which often results in treatment of patients who do not have TTP.¹⁶ Glucocorticoids are standard treatment; rituximab and other immunosuppressive agents are appropriate when the clinical course is complicated. Dialysis is rarely required.¹⁶

LONG-TERM OUTCOMES

The long-term outcomes of patients with hereditary TTP are unknown. Experimental data suggest that ADAMTS13 provides protection against atherosclerosis,²³ but it is unknown whether patients with hereditary TTP are at increased risk for cardiovascular disease. Long-term follow-up of patients with acquired TTP has revealed a risk of relapse¹⁷ and an increased prevalence of cognitive impairment,²⁴ major depression, systemic lupus erythematosus, hypertension, and death.²⁵

FUTURE NEEDS

If long-term follow-up shows that hereditary TTP causes increased morbidities, prophylactic treatment will become more important. The development of recombinant ADAMTS13 would make prophylactic treatment simpler and safer. For the treatment of patients with acquired TTP, safer and more accessible alternatives to plasma exchange are needed.

Table 2. Common Disorders Associated with Microangiopathic Hemolytic Anemia and Thrombocytopenia.*

Systemic infection
Systemic cancer
Severe preeclampsia, eclampsia, HELLP syndrome
Severe hypertension
Autoimmune disorders (e.g., systemic lupus erythematosus, systemic sclerosis, antiphospholipid syndrome)
Hematopoietic stem-cell or organ transplantation

* Listed are disorders that may initially suggest the diagnosis of a primary TMA syndrome. Many different systemic infections (viral, such as human immunodeficiency virus and cytomegalovirus; fungal, such as aspergillus; and bacterial) and many different systemic cancers may be associated with microangiopathic hemolytic anemia and thrombocytopenia without overt disseminated intravascular coagulation (DIC). Many other disorders, such as any condition associated with DIC, may also present with microangiopathic hemolytic anemia and thrombocytopenia and must also be considered as alternative causes in the evaluation of patients for the possible diagnosis of a primary TMA syndrome. Some of these disorders (e.g., severe hypertension, systemic lupus erythematosus, and systemic sclerosis) may also be associated with the characteristic pathological features of TMA. These disorders may directly cause the clinical and pathological features of TMA, a hypothesis supported by resolution of these features with effective treatment of the disorder. HELLP denotes hemolysis, elevated liver-enzyme levels, and low platelets.

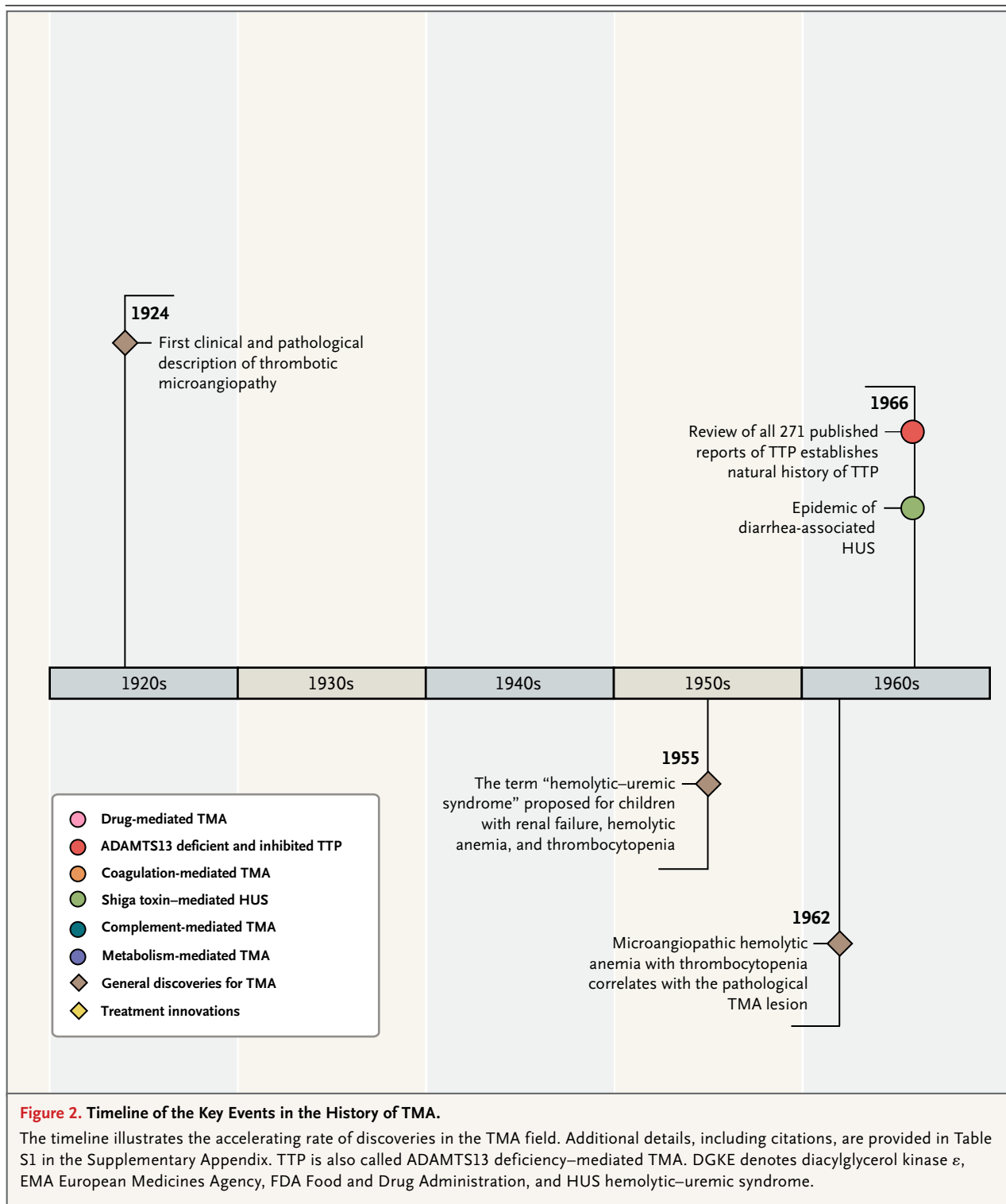
COMPLEMENT-MEDIATED TMA (ACQUIRED AND HEREDITARY)

BACKGROUND

TMA that is characterized by predominant renal failure and described as HUS was recognized as a familial disorder in 1975.^{26,27} In 1981, two brothers with TMA were found to have a deficiency of complement factor H.²⁸ The association between TMA and mutations in the gene encoding complement factor H (CFH) was established in 1998.²⁹ Subsequently, mutations in multiple other factors facilitating increased complement activation by the alternative pathway have been identified in patients with TMA.

CAUSE

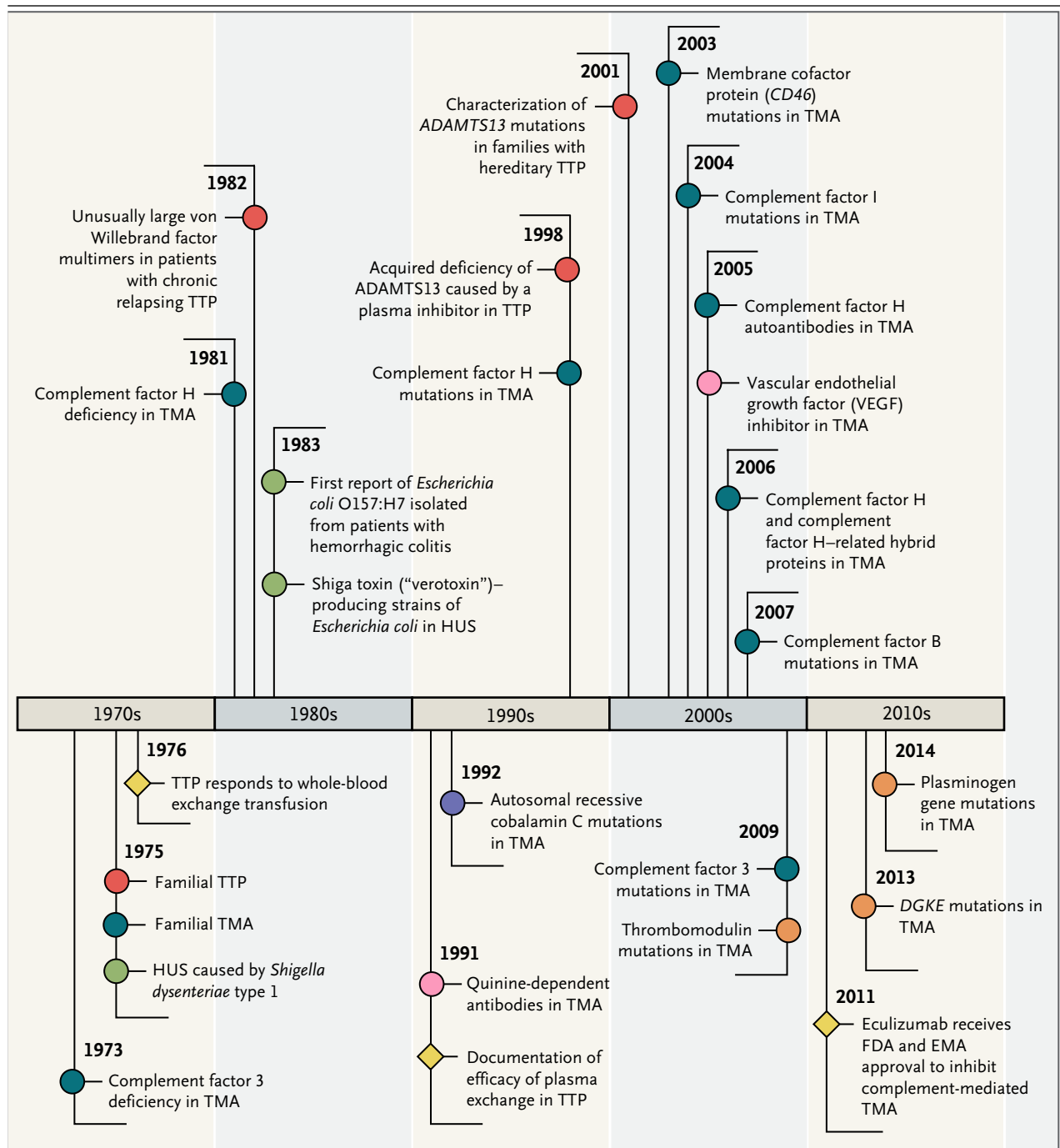
Complement-mediated TMA results from uncontrolled activation of the alternative pathway of complement. Unlike the other two pathways of complement activation, the alternative pathway is constitutively active as a result of spontaneous hydrolysis of C3 to C3b. In the absence of normal regulation, C3b deposition on tissues may increase markedly, resulting in increased formation of the C5b-9 terminal complement complex (also called the membrane-attack complex) and injury of normal cells. The precise role of complement dysregulation in TMA has not been fully



defined. Endothelial injury as well as complement dysregulation on the platelet surface causing activation may be involved.³⁰

Hereditary complement-mediated TMA may

result from either a loss-of-function mutation in a regulatory gene (*CFH*, *CFI*, or *CD46*) or a gain-of-function mutation in an effector gene (*CFB* or *C3*).^{31,32} Most complement mutations that are



associated with TMA are heterozygous, even though many family members with heterozygous mutations are asymptomatic. A difference between probands and family members in the presence of additional modifying genes may explain this discrepancy. Other genetic abnormalities have been identified in patients with complement-mediated TMA, including single-nucleotide polymorphisms in *CFH* and *CD46*,

copy-number variations in the *CFH*-related 1 and 3 genes (*CFHR1* and *CFHR3*), and fusion genes of the *CFHR* region with *CFH* caused by nonallelic homologous recombination. These additional genetic abnormalities may contribute to the loss of alternative pathway regulation and increased risk of TMA. In addition to genetic abnormalities, a functional deficiency in complement factor H may result from antibodies to the comple-

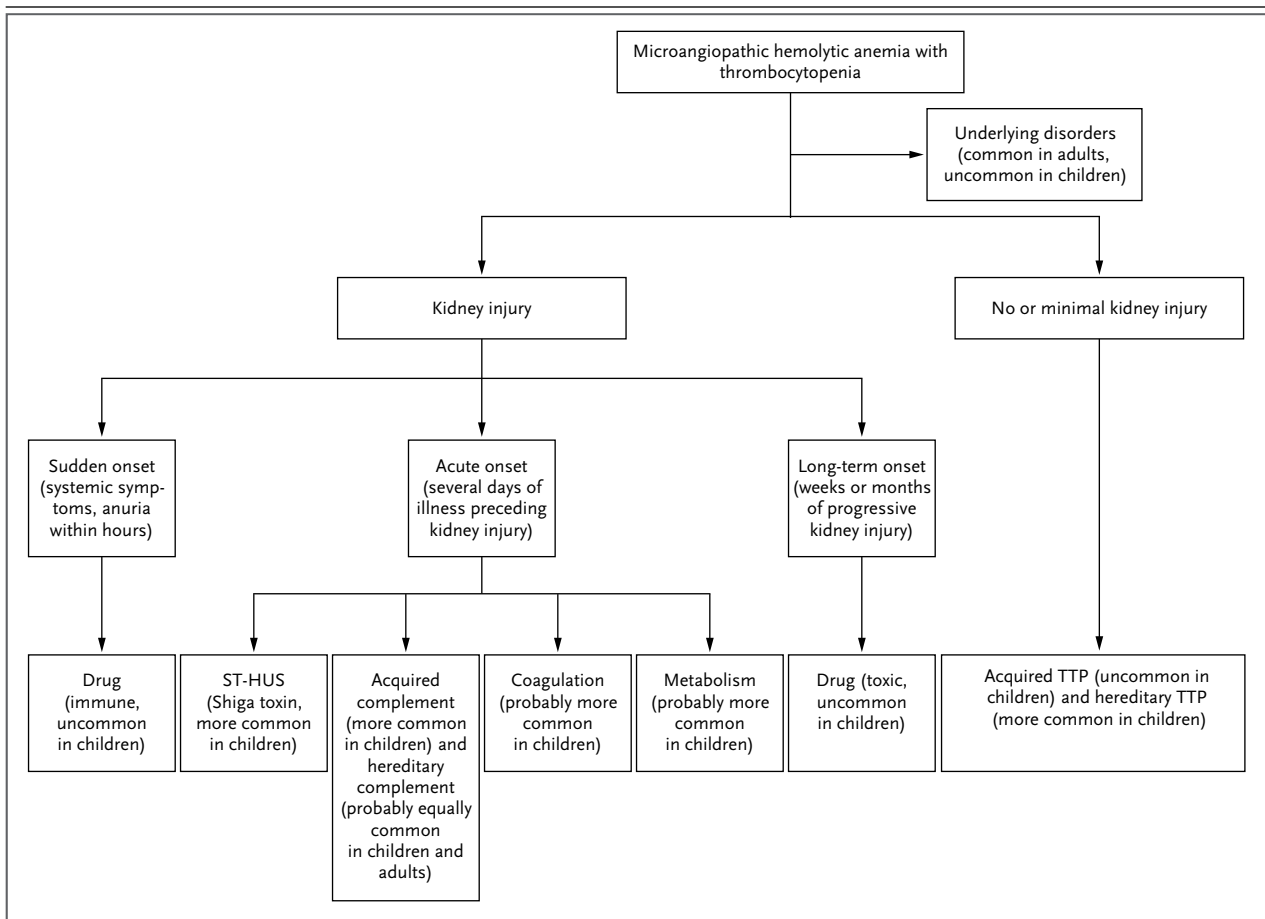


Figure 3. Algorithm for the Evaluation of Children and Adults Presenting with Microangiopathic Hemolytic Anemia and Thrombocytopenia.

After the exclusion of common underlying disorders, the severity of kidney injury is a distinguishing feature. Among patients with severe acute kidney injury, the initial clinical diagnosis is related to the pace of onset of kidney injury. In this regard, complement-mediated TMA that may be acquired is not distinguished from hereditary complement-mediated TMA. Although kidney injury is characteristic of complement-mediated TMA, it may be minimal. Several conditions (e.g., pregnancy, surgery, and inflammatory disorders) may precipitate acute TMA episodes. Not included in this algorithm are patients with microangiopathic hemolytic anemia and thrombocytopenia in whom neither an underlying condition nor a primary TMA syndrome is identified. Such patients with idiopathic disease represent about 20% of all adults who present with microangiopathic hemolytic anemia and thrombocytopenia. TTP is also called ADAMTS13 deficiency–mediated TMA.

ment, resulting in acquired TMA. CFH antibodies account for about 10% of complement-mediated TMA. These antibodies are responsible for defective CFH-dependent cell protection.

PRESENTATION AND DIAGNOSIS

Acute kidney injury and hypertension are prominent abnormalities in complement-mediated TMA. Current diagnostic criteria are those that were used in clinical trials involving a total of 37 patients, which supported the approval of eculizumab (a humanized monoclonal antibody

that blocks the generation of C5a and C5b) for the treatment of “atypical HUS” in 2011. These criteria include all of the following: a serum creatinine level at or above the upper limit of the normal range, microangiopathic hemolytic anemia, thrombocytopenia, ADAMTS13 activity of 5% or more, and negative stool tests for Shiga toxin–producing infection.³³ These criteria are not specific; they may also occur in all other primary TMA syndromes as well as in other patients with microangiopathic hemolytic anemia and thrombocytopenia. Complement

genetic studies, now commercially available with a rapid return of results, may provide a more specific diagnosis. Normal plasma levels of C3, C4, and complement factors H, B, and I do not exclude the diagnosis of complement-mediated TMA.

TREATMENT

Anticomplement therapy can be used to supplement plasma therapy and potentially preempt liver transplantation.³⁴ Eculizumab is currently the only available anticomplement agent. Its effect may be limited among patients who have C5 mutations.³⁵ The nonspecific diagnostic criteria and the fact that patients with no identified complement mutation may have a response to anticomplement therapy makes the decision to use an anticomplement agent as initial therapy difficult.^{31,33} Anticomplement therapy is a reasonable initial treatment for patients with antibodies against complement factor H. However, the use of immunosuppression to reduce the antibody titer should be considered. The high cost of eculizumab (wholesale acquisition cost for 1 year of treatment for an adult, \$614,736; University of Oklahoma Medical Center Pharmacy, March 5, 2014) and the implication that it should be continued indefinitely are critical issues. The risk of meningococcal infection in connection with eculizumab therapy must be considered.

LONG-TERM OUTCOMES

Before the use of eculizumab, the risks of end-stage renal disease or death and of recurrence after kidney transplantation were primarily dependent on mutational analyses, with *CFH* mutations causing the greatest risk.³¹ It is assumed that anticomplement treatment will improve outcomes.

FUTURE NEEDS

Clinical trials to determine the most appropriate length of anticomplement therapy and to develop surveillance markers to confirm renal remission are critical. Further genetic investigation is required to explain the heterozygosity and low penetrance of currently identified complement mutations and also to determine the cause of disease in patients who may have complement-mediated TMA but in whom no mutation has been identified.

SHIGA TOXIN-MEDIATED HEMOLYTIC-UREMIC SYNDROME

BACKGROUND

The name “hemolytic-uremic syndrome” was first proposed in 1955.³⁶ The typical clinical features of ST-HUS were first described in a 1962 report involving five children between the ages of 6 and 10 months who had diarrhea preceding renal failure.³⁷ An infectious cause was suspected, but an association between ST-HUS and an enteric infection, *Shigella dysenteriae* type 1, was not recognized until 1975.³⁸ It was not until 1983, during an investigation of outbreaks of hemorrhagic colitis, that *Escherichia coli* O157:H7 was identified as a pathogen.³⁹ The same year, the association between ST-HUS and Shiga toxin-producing *E. coli* was described.⁴⁰ Multiple *E. coli* strains produce Shiga toxin; *E. coli* O157:H7 is the most common pathogen associated with ST-HUS in Europe and the Americas.^{41,42} *S. dysenteriae* type 1 remains an endemic cause of ST-HUS in other countries.⁴³ Although ST-HUS is popularized by large outbreaks,^{44,45} most occurrences are sporadic.⁴⁶ ST-HUS is much more common among children (median age, 2 years), in whom mortality is 3%.⁴⁷ ST-HUS in adults is more severe, with higher mortality.⁴⁷

CAUSE

Shiga toxin-producing *E. coli* are common intestinal bacteria in cattle, consistent with the rural predominance of endemic ST-HUS.⁴² Outbreaks result from contaminated water, beef products, vegetables, and other foods.^{42,44,45} Cell damage results when Shiga toxin binds to globotriaosylceramide (Gb3, also known as CD77 or ceramide trihexoside) on endothelial cells,⁴⁸ as well as to renal mesangial cells⁴⁹ and epithelial cells (podocytes⁵⁰ and tubular cells⁵¹). Cell apoptosis results from Gb3 binding, endocytosis, retrograde transport, cytosolic translocation of Shiga toxin, and subsequent ribosomal inactivation.⁵² Shiga toxin is also cell-activating, proinflammatory, and prothrombotic⁵³ and facilitates thrombosis by inducing endothelial secretion of von Willebrand factor.⁴⁸

PRESENTATION AND DIAGNOSIS

Severe abdominal pain and diarrhea, often bloody, begin several days after contaminated food is consumed. Thrombocytopenia and renal

failure begin as gastrointestinal symptoms resolve.⁴¹ Shiga toxin is identified by means of stool analyses during the acute colitis phase but may not be identifiable when ST-HUS begins.⁵⁴

TREATMENT

Treatment remains supportive. Early, aggressive hydration has a renal protective role.⁴¹ Patients commonly require dialysis.⁴⁷ The benefits of plasma exchange and anticomplement treatment are uncertain.

LONG-TERM OUTCOMES

Hypertension and neurologic abnormalities may persist after the acute phase has resolved. End-stage renal disease rarely occurs.⁵⁵

FUTURE NEEDS

The prevention of enterohemorrhagic infections and ST-HUS by public health measures (e.g., food safety and hygiene education) is the greatest need.⁴⁶ New agents that neutralize Shiga toxin may provide effective treatment for ST-HUS.

DRUG-MEDIATED TMA (IMMUNE REACTION)

BACKGROUND

Adverse drug reactions can be caused by non-dose-related idiosyncratic, immunologic reactions or toxic effects that are dependent on dose and timing.⁵⁶ Both types of reactions are associated with TMA. Immune reaction in drug-mediated TMA was first recognized in 1980 in a patient who had repeated episodes of acute kidney injury, hemolysis, and thrombocytopenia after documented exposures to quinine.⁵⁷ Subsequent studies confirmed this recurrence pattern and further implicated quinine by describing quinine-dependent antibodies that were reactive with multiple cell types.^{58,59} Although many other drugs have been reported to be associated with TMA, only quinine-associated TMA has been supported by documentation of drug-dependent antibodies. Quetiapine⁶⁰ and gemcitabine⁶¹ are the only other drugs for which association with acute episodes of TMA has been supported by recurrent acute episodes with repeated exposures.

CAUSE

Drug-dependent antibody binding to antigens on multiple cells may be facilitated by drugs contain-

ing structural elements that are complementary to domains on both the epitope and antibody.⁶² Quinine-dependent antibodies may mediate TMA, in part, by activation of endothelial cells.⁶³

PRESENTATION AND DIAGNOSIS

Drug-mediated TMA may be suspected by the sudden onset of severe systemic symptoms, often with anuric acute kidney injury, within hours after drug exposure. There may be a history of illness after previous exposures to the suspected drug. The association with quinine may be overlooked because exposure may occur over many years and may not be reported by the patient without explicit questions. Exposure may include tablets or quinine-containing beverages. Documentation of drug-dependent antibodies supports the clinical diagnosis; however, a negative test does not exclude a drug association.

TREATMENT

Supportive care and drug avoidance may be the only beneficial management. Plasma exchange is often begun because TTP is suspected and a drug-mediated cause is uncertain.

LONG-TERM OUTCOMES

Chronic kidney disease with hypertension is common.⁵⁹ End-stage renal disease may occur.

FUTURE NEEDS

Rapidly available testing for drug-dependent antibodies is needed to assist in the clinical diagnosis. Understanding the mechanism of acute kidney injury may provide insight for targeted treatment.

DRUG-MEDIATED TMA (TOXIC DOSE-RELATED REACTION)

BACKGROUND

Many drugs, including immunosuppressive and chemotherapeutic agents and vascular endothelial growth factor (VEGF) inhibitors, have been reported to cause TMA through dose- and time-dependent toxicity. Evidence supporting a causal role is limited.

CAUSE

There may be multiple mechanisms for toxic drug-mediated kidney injury. Among the likely roles of calcineurin inhibitors (such as cyclo-

sporine and tacrolimus) is their ability to cause endothelial dysfunction and increased platelet aggregation, possibly through the inhibition of prostacyclin. The inhibition of VEGF function in renal endothelial cells and podocytes causes gradual development of glomerular TMA.^{64,65}

PRESENTATION AND DIAGNOSIS

The typical presentation is gradual loss of kidney function with hypertension.⁶⁵ Abrupt, severe TMA may occur, as with intravenous abuse of the opiate oxymorphone.⁶⁶

TREATMENT

Supportive care and drug avoidance may be the only beneficial management. For some drugs, such as calcineurin inhibitors, dose reduction, rather than drug avoidance, may be sufficient.

LONG-TERM OUTCOMES

Microangiopathic hemolytic anemia and thrombocytopenia often resolve. Renal failure may persist.

FUTURE NEEDS

Determining how drug toxicity causes TMA, or identifying alternative explanations for TMA in these patients, is essential.

METABOLISM-MEDIATED TMA

BACKGROUND

Cobalamin C disease is a hereditary disorder of cobalamin (vitamin B₁₂) metabolism that may cause TMA and multiple organ dysfunction in infants.^{67,68} In addition, TMA has been reported in one adult.⁶⁹

CAUSE

Disorders of cobalamin metabolism result from homozygous or compound heterozygous mutations in a gene encoding the methylmalonic aciduria and homocystinuria type C protein (MMACHC). The resulting deficiency in methylcobalamin causes hyperhomocysteinemia, decreased plasma methionine levels, and methylmalonic aciduria. Abnormal cobalamin C metabolism is associated with platelet activation, generation of reactive oxygen species, endothelial dysfunction, increased tissue factor expression, and coagulation activation.⁷⁰

PRESENTATION AND DIAGNOSIS

Infants with cobalamin C disease have diverse developmental abnormalities. The one reported adult presented with microangiopathic hemolytic anemia, thrombocytopenia, acute kidney injury, and hypertension; he had no relevant personal or family history.

TREATMENT

Parenteral hydroxycobalamin is the principal treatment for infants. When the above-mentioned adult patient did not have a response to anticomplement treatment, an intracellular defect of vitamin B₁₂ metabolism was suspected and confirmed by routinely available tests, which showed hyperhomocysteinemia, decreased plasma methionine, methylmalonic aciduria, and normal plasma vitamin B₁₂ levels. He had a response to treatment with hydroxycobalamin, betaine, and folic acid.⁶⁹

LONG-TERM OUTCOMES

Neurologic sequelae are common in affected infants. Chronic kidney disease with hypertension and proteinuria has been reported in up to 40% of patients. End-stage renal disease and the recurrence of TMA appear to be prevented by replacement treatment.

FUTURE NEEDS

Greater awareness of cobalamin C–induced TMA and greater use of routine screening tests for cobalamin deficiency are required.

COAGULATION-MEDIATED TMA

BACKGROUND

Genetic abnormalities of thrombomodulin,⁷¹ plasminogen,³² and a protein kinase C–associated protein, diacylglycerol kinase ϵ (DGKE),^{72,73} have been identified in patients with TMA. These findings suggest that there may be a primary role for coagulation proteins in the pathogenesis of TMA syndromes.

CAUSE

The question of whether the role of thrombomodulin in TMA is primarily related to coagulation or is mediated solely by complement requires further study. The role of DGKE has been documented in two reports describing 22 patients in 12 families.^{72,73} All the patients had homozygous

or compound heterozygous *DGKE* mutations. Patients with heterozygous mutations had no clinical abnormalities. In one report, no mutations of complement regulatory genes were identified.⁷³ It has been proposed that a homozygous mutation in the gene encoding *DGKE* leads to a loss of function, resulting in protein kinase C (PKC) activation. PKC activation facilitates the up-regulation of prothrombotic factors (von Willebrand factor, tissue factor, and plasminogen activator inhibitor 1) and the down-regulation of the VEGF receptor. Decreased VEGF function with resulting renal podocyte injury may also be a consequence of *DGKE* mutations. The sum of these events is a shift to a prothrombotic state.⁷⁴ Communication between the coagulation system and the complement system may have a role in the pathogenesis of TMA.

PRESENTATION AND DIAGNOSIS

Patients with *DGKE* mutations present with acute kidney injury. Most of these patients who have been studied were under the age of 1 year.^{72,73}

TREATMENT

The benefits of plasma infusion or exchange and immunosuppression have been inconsistent. Relapses have occurred while patients were receiving anticomplement therapy.

LONG-TERM OUTCOMES

End-stage renal disease is common. Four children with this disorder have undergone kidney transplantation; one has had recurrent kidney injury.⁷²

FUTURE NEEDS

Determining the prevalence of these syndromes and understanding the mechanisms leading to TMA are essential.

MECHANISMS OF ORGAN INJURY

The above-mentioned causes of the primary TMA syndromes do not explain why kidney injury is predominant in all except for TTP. TTP causes extensive kidney microvascular thrombi,⁷⁵ yet severe acute kidney injury and chronic kidney disease are rare.^{16,25} The difference may be that the pathogenesis of TTP is primarily related to vascular thrombosis, whereas the pathogenesis of

the other primary TMA syndromes also includes injury to resident renal cells and endothelial cells. For example, in patients with ST-HUS, Shiga toxin causes injury to epithelial podocytes,⁵⁰ mesangial cells,⁴⁹ and renal tubular cells.⁵¹ VEGF inhibitors affect glomerular epithelial podocytes,^{64,65} and enhanced protein kinase C activation in patients with *DGKE* mutations may cause podocyte injury.⁷⁴ Understanding the mechanism of injury to resident renal cells in complement-mediated TMA, by quinine-dependent antibodies, or in cobalamin C disease requires further study.

There are also distinct differences with respect to the risk of chronic kidney disease among the seven primary TMA syndromes in which acute kidney injury is typically present. Among the acquired syndromes, chronic kidney injury rarely develops in patients with ST-HUS,⁵⁵ perhaps because ST-HUS does not recur. However, patients with only a single recognized episode of quinine-induced TMA commonly have chronic kidney injury.⁵⁹ Among the hereditary syndromes, there is also substantial variety in the severity of kidney injury. Patients with complement mutations may present at any age, whereas those with *DGKE* mutations typically present with acute kidney injury in infancy.⁷³ These variations in the clinical manifestations of TMA syndromes emphasize the need for greater understanding of the mechanisms of disease.

CONCLUSIONS

In recent years, there has been a dramatic acceleration in our understanding of the primary TMA syndromes. New discoveries with respect to causal mechanisms have created opportunities for specific treatments. The availability of specific treatments has created the need for rapid, specific diagnoses. The use of effective treatments has decreased mortality but has also revealed previously unrecognized long-term morbidities. These advances predict continuing acceleration of our understanding of the primary TMA syndromes.

Dr. George reports receiving fees for serving on advisory boards from Alexion; and Dr. Nester receiving grant support from Celldex and fees for serving on advisory boards from Alexion. No other potential conflict of interest relevant to this article was reported.

Disclosure forms provided by the authors are available with the full text of this article at NEJM.org.

REFERENCES

- Moake JL. Thrombotic microangiopathies. *N Engl J Med* 2002;347:589-600.
- Laszik ZG, Silva FG. Hemolytic uremic syndrome, thrombotic thrombocytopenia purpura, and other thrombotic microangiopathies and coagulopathies. In: Jennett JC, Olson JL, Schwartz MM, Silva FG, eds. *Heptinstall's pathology of the kidney*. 6th ed. Philadelphia: Lippincott Williams & Wilkins, 2007:699-762.
- Jennette JC, Falk RJ, Bacon PA, et al. 2012 Revised international Chapel Hill consensus conference nomenclature of vasculitides. *Arthritis Rheum* 2013;65:1-11.
- Moschcowitz E. Hyaline thrombosis of the terminal arterioles and capillaries: a hitherto undescribed disease. *Proc N Y Pathol Soc* 1924;24:21-4.
- Moake JL, Rudy CK, Troll JH, et al. Unusually large plasma factor VIII: von Willebrand factor multimers in chronic relapsing thrombotic thrombocytopenic purpura. *N Engl J Med* 1982;307:1432-5.
- Furlan M, Robles R, Lämmle B. Partial purification and characterization of a protease from human plasma cleaving von Willebrand factor to fragments produced by in vivo proteolysis. *Blood* 1996; 87:4223-34.
- Tsai H-M. Physiologic cleavage of von Willebrand factor by a plasma protease is dependent on its conformation and requires calcium ion. *Blood* 1996;87:4235-44.
- Levy GG, Nichols WC, Lian EC, et al. Mutations in a member of the ADAMTS gene family cause thrombotic thrombocytopenic purpura. *Nature* 2001;413:488-94.
- Fujimura Y, Matsumoto M, Isonishi A, et al. Natural history of Upshaw-Schulman syndrome based on ADAMTS13 gene analysis in Japan. *J Thromb Haemost* 2011;9: Suppl 1:283-301.
- Reese JA, Muthurajah DS, Kremer Hovinga JA, Vesely SK, Terrell DR, George JN. Children and adults with thrombotic thrombocytopenic purpura associated with severe, acquired Adamts13 deficiency: comparison of incidence, demographic and clinical features. *Pediatr Blood Cancer* 2013;60:1676-82.
- Fuchs WE, George JN, Dotin LN, Sears DA. Thrombotic thrombocytopenic purpura: occurrence two years apart during late pregnancy in two sisters. *JAMA* 1976;235:2126-7.
- Moatti-Cohen M, Garrec C, Wolf M, et al. Unexpected frequency of Upshaw-Schulman syndrome in pregnancy-onset thrombotic thrombocytopenic purpura. *Blood* 2012;119:5888-97.
- Lotta LA, Wu HM, Mackie IJ, et al. Residual plasmin activity of ADAMTS13 is correlated with phenotype severity in congenital thrombotic thrombocytopenic purpura. *Blood* 2012;120:440-8.
- Motto DG, Chauhan AK, Zhu G, et al. Shigatoxin triggers thrombotic thrombocytopenic purpura in genetically susceptible ADAMTS13-deficient mice. *J Clin Invest* 2005;115:2752-61.
- George JN, Chen Q, Deford CC, Al-Nouri ZL. Ten patient stories illustrating the extraordinarily diverse clinical features of patients with thrombotic thrombocytopenic purpura and severe ADAMTS13 deficiency. *J Clin Apher* 2012;27:302-11.
- George JN. How I treat patients with thrombotic thrombocytopenic purpura: 2010. *Blood* 2010;116:4060-9. [Erratum, *Blood* 2011;117:5551.]
- Kremer Hovinga JA, Vesely SK, Terrell DR, Lämmle B, George JN. Survival and relapse in patients with thrombotic thrombocytopenic purpura. *Blood* 2010;115: 1500-11.
- Froehlich-Zahnd R, George JN, Vesely SK, et al. Evidence for a role of anti-ADAMTS13 autoantibodies despite normal ADAMTS13 activity in recurrent thrombotic thrombocytopenic purpura. *Haematologica* 2012;97:297-303.
- Furlan M, Robles R, Morselli B, Sandoz P, Lämmle B. Recovery and half-life of von Willebrand factor-cleaving protease after plasma therapy in patients with thrombotic thrombocytopenic purpura. *Thromb Haemost* 1999;81:8-13.
- Naik S, Mahoney DH. Successful treatment of congenital TTP with a novel approach using plasma-derived factor VIII. *J Pediatr Hematol Oncol* 2013;35:551-3.
- Amorosi EL, Ultmann JE. Thrombotic thrombocytopenic purpura: report of 16 cases and review of the literature. *Medicine* 1966;45:139-59.
- Rock GA, Shumak KH, Buskard NA, et al. Comparison of plasma exchange with plasma infusion in the treatment of thrombotic thrombocytopenic purpura. *N Engl J Med* 1991;325:393-7.
- Gandhi C, Khan MM, Lentz SR, Chauhan AK. ADAMTS13 reduces vascular inflammation and the development of early atherosclerosis in mice. *Blood* 2012;119: 2385-91.
- Kennedy AS, Lewis QF, Scott JG, et al. Cognitive deficits after recovery from thrombotic thrombocytopenic purpura. *Transfusion* 2009;49:1092-101.
- Deford CC, Reese JA, Schwartz LH, et al. Multiple major morbidities and increased mortality during long-term follow-up after recovery from thrombotic thrombocytopenic purpura. *Blood* 2013; 122:2023-9.
- Kaplan BS, Chesney RW, Drummond KN. Hemolytic uremic syndrome in families. *N Engl J Med* 1975;292:1090-3.
- Farr MJ, Roberts S, Morley AR, Dewar DF, Uldall PR, Uldall PR. The haemolytic uraemic syndrome — a family study. *Q J Med* 1975;44:161-88.
- Thompson RA, Winterborn MH. Hypocomplementaemia due to a genetic deficiency of beta 1H globulin. *Clin Exp Immunol* 1981;46:110-9.
- Warwicker P, Goodship TH, Donne RL, et al. Genetic studies into inherited and sporadic hemolytic uremic syndrome. *Kidney Int* 1998;53:836-44.
- Ståhl A-L, Vaziri-Sani F, Heinen S, et al. Factor H dysfunction in patients with atypical hemolytic uremic syndrome contributes to complement deposition on platelets and their activation. *Blood* 2008; 111:5307-15.
- Noris M, Caprioli J, Bresin E, et al. Relative role of genetic complement abnormalities in sporadic and familial aHUS and their impact on clinical phenotype. *Clin J Am Soc Nephrol* 2010;5:1844-59.
- Bu F, Maga T, Meyer NC, et al. Comprehensive genetic analysis of complement and coagulation genes in atypical hemolytic uremic syndrome. *J Am Soc Nephrol* 2014;25:55-64.
- Legendre CM, Licht C, Muus P, et al. Terminal complement inhibitor eculizumab in atypical hemolytic-uremic syndrome. *N Engl J Med* 2013;368:2169-81.
- Loriat C, Fakhouri F, Ariceta G, et al. An international view on the management of atypical hemolytic uremic syndrome. *Pediatr Nephrol* (in press).
- Nishimura J-I, Yamamoto M, Hayashi S, et al. Genetic variants in C5 and poor response to eculizumab. *N Engl J Med* 2014;370:632-9.
- Gasser C, Gautier E, Steck A, Siebenmann RE, Oechslin R. Hämolytisch-urämische Syndrome: bilaterale Nierenrindennekrosen bei akuten erworbenen hämolytischen Anämien. *Schweiz Med Wochenschr* 1955;85:905-9.
- Javett SN, Senior B. Syndrome of hemolysis, thrombopenia and nephropathy in infancy. *Pediatrics* 1962;29:209-23.
- Rahaman MM, Jamiul Alam AK, Islam MR, Greenough WBI III. Shiga bacillus dysentery associated with marked leukocytosis and erythrocyte fragmentation. *Johns Hopkins Med J* 1975;136:65-70.
- Riley LW, Remis RS, Helgeson SD, et al. Hemorrhagic colitis associated with a rare *Escherichia coli* serotype. *N Engl J Med* 1983;308:681-5.
- Karmali MA, Steele BT, Petric M, Lim C. Sporadic cases of haemolytic-uraemic syndrome associated with faecal cytotoxin and cytotoxin-producing *Escherichia coli* in stools. *Lancet* 1983;1:619-20.
- Tarr PI, Gordon CA, Chandler WL. Shiga-toxin-producing *Escherichia coli* and haemolytic uraemic syndrome. *Lancet* 2005;365:1073-86.

42. Pennington H. *Escherichia coli* O157. *Lancet* 2010;376:1428-35.
43. Wittenberg DF. Emerging and re-emerging diseases — epidemic enterohaemorrhagic infections 100 years after Shiga. *S Afr Med J* 1999;89:750-2.
44. Bell BP, Goldoft M, Griffin PM, et al. A multistate outbreak of *Escherichia coli* O157:H7-associated bloody diarrhoea and hemolytic uremic syndrome from hamburgers: the Washington experience. *JAMA* 1994;272:1349-53.
45. Buchholz U, Bernard H, Werber D, et al. German outbreak of *Escherichia coli* O104:H4 associated with sprouts. *N Engl J Med* 2011;365:1763-70.
46. Maki DG. Don't eat the spinach — controlling foodborne infectious disease. *N Engl J Med* 2006;355:1952-5.
47. Karpac CA, Li X, Terrell DR, et al. Sporadic bloody diarrhoea-associated thrombotic thrombocytopenic purpura-haemolytic uraemic syndrome: an adult and paediatric comparison. *Br J Haematol* 2008;141:696-707.
48. Huang J, Motto DG, Bundle DR, Sadler JE. Shiga toxin B subunits induce VWF secretion by human endothelial cells and thrombotic microangiopathy in ADAMTS13-deficient mice. *Blood* 2010;116:3653-9.
49. Robinson LA, Hurley RM, Lingwood C, Matsell DG. *Escherichia coli* verotoxin binding to human paediatric glomerular mesangial cells. *Pediatr Nephrol* 1995;9:700-4.
50. Ergonul Z, Clayton F, Fogo AB, Kohan DE. Shigatoxin-1 binding and receptor expression in human kidneys do not change with age. *Pediatr Nephrol* 2003;18:246-53.
51. Hughes AK, Ergonul Z, Stricklett PK, Kohan DE. Molecular basis for high renal cell sensitivity to the cytotoxic effects of shigatoxin-1: upregulation of globotriaosylceramide expression. *J Am Soc Nephrol* 2002;13:2239-45.
52. Endo Y, Tsurugi K, Yutsudo T, Takeda Y, Ogasawara T, Igarashi K. Site of action of a Vero toxin (VT2) from *Escherichia coli* O157:H7 and of Shiga toxin on eukaryotic ribosomes: RNA N-glycosidase activity of the toxins. *Eur J Biochem* 1988;171:45-50.
53. Chandler WL, Jelacic S, Boster DR, et al. Prothrombotic coagulation abnormalities preceding the hemolytic-uremic syndrome. *N Engl J Med* 2002;346:23-32. [Erratum, *N Engl J Med* 2002;346:715.]
54. Garg AX, Suri RS, Barrowman N, et al. Long-term renal prognosis of diarrhea-associated hemolytic uremic syndrome: a systematic review, meta-analysis, and meta-regression. *JAMA* 2003;290:1360-70.
55. Rosales A, Hofer J, Zimmerhackl L-B, et al. Need for long-term follow-up in enterohemorrhagic *Escherichia coli*-associated hemolytic uremic syndrome due to late-emerging sequelae. *Clin Infect Dis* 2012;54:1413-21.
56. Edwards IR, Aronson JK. Adverse drug reactions: definitions, diagnosis, and management. *Lancet* 2000;356:1255-9.
57. Webb RF, Ramirez AM, Hocken AG, Pettit JE. Acute intravascular haemolysis due to quinine. *N Z Med J* 1980;91:14-6.
58. Gottschall JL, Neahring B, McFarland JG, Wu G-G, Weitekamp LA, Aster RH. Quinine-induced immune thrombocytopenia with hemolytic uremic syndrome: clinical and serological findings in nine patients and review of literature. *Am J Hematol* 1994;47:283-9.
59. Kojouri K, Vesely SK, George JN. Quinine-associated thrombotic thrombocytopenic purpura-hemolytic uremic syndrome: frequency, clinical features, and long-term outcomes. *Ann Intern Med* 2001;135:1047-51.
60. Huynh M, Chee K, Lau DHM. Thrombotic thrombocytopenic purpura associated with quetiapine. *Ann Pharmacother* 2005;39:1346-8.
61. Saif MW, Xyla V, Makrilia N, Bliziotis I, Syrigos K. Thrombotic microangiopathy associated with gemcitabine: rare but real. *Expert Opin Drug Saf* 2009;8:257-60.
62. Bougie DW, Wilker PR, Aster RH. Patients with quinine-induced immune thrombocytopenia have both “drug-dependent” and “drug-specific” antibodies. *Blood* 2006;108:922-7.
63. Glynne P, Salama A, Chaudhry A, Swirsky D, Lightstone L. Quinine-induced immune thrombocytopenic purpura followed by hemolytic uremic syndrome. *Am J Kidney Dis* 1999;33:133-7.
64. Sartelet H, Toupance O, Lorenzato M, et al. Sirolimus-induced thrombotic microangiopathy is associated with decreased expression of vascular endothelial growth factor in kidneys. *Am J Transplant* 2005;5:2441-7.
65. Eremina V, Jefferson JA, Kowalewska J, et al. VEGF inhibition and renal thrombotic microangiopathy. *N Engl J Med* 2008;358:1129-36.
66. Thrombotic thrombocytopenic purpura (TTP)-like illness associated with intravenous Opana ER abuse — Tennessee, 2012. *MMWR Morb Mortal Wkly Rep* 2013;62:1-4.
67. Russo P, Doyon J, Sonsino E, Ogier H, Saudubray J-M. A congenital anomaly of vitamin B₁₂ metabolism: a study of three cases. *Hum Pathol* 1992;23:504-12.
68. Geraghty MT, Perlman EJ, Martin LS, et al. Cobalamin C defect associated with hemolytic-uremic syndrome. *J Pediatr* 1992;120:934-7.
69. Cornec-Le Gall E, Delmas Y, De Parscau L, et al. Adult-onset eculizumab-resistant hemolytic uremic syndrome associated with cobalamin C deficiency. *Am J Kidney Dis* 2014;63:119-23.
70. Coppola A, Davi G, De Stefano V, Mancini FP, Cerbone AM, Di Minno G. Homocysteine, coagulation, platelet function, and thrombosis. *Semin Thromb Hemost* 2000;26:243-54.
71. Delvaeye M, Noris M, De Vriese A, et al. Thrombomodulin mutations in atypical hemolytic-uremic syndrome. *N Engl J Med* 2009;361:345-57.
72. Ozaltin F, Li B, Rauhauser A, et al. DGKE variants cause a glomerular microangiopathy that mimics membranoproliferative GN. *J Am Soc Nephrol* 2013;24:377-84.
73. Lemaire M, Frémeaux-Bacchi V, Schaefer F, et al. Recessive mutations in DGKE cause atypical hemolytic-uremic syndrome. *Nat Genet* 2013;45:531-6.
74. Quaggin SE. DGKE and atypical HUS. *Nat Genet* 2013;45:475-6.
75. Hosler GA, Cusumano AM, Hutchins GM. Thrombotic thrombocytopenic purpura and hemolytic uremic syndrome are distinct pathologic entities: a review of 56 autopsy cases. *Arch Pathol Lab Med* 2003;127:834-9.

Copyright © 2014 Massachusetts Medical Society.

IMAGES IN CLINICAL MEDICINE

The *Journal* welcomes consideration of new submissions for Images in Clinical Medicine. Instructions for authors and procedures for submissions can be found on the *Journal*'s website at NEJM.org. At the discretion of the editor, images that are accepted for publication may appear in the print version of the *Journal*, the electronic version, or both.