

E. Emery  
A. Redondo  
A. Rey

## Syringomyelia and Arnold Chiari in scoliosis initially classified as idiopathic: experience with 25 patients

Received: 5 July 1996  
Revised: 6 October 1996  
Accepted: 22 October 1996

E. Emery (✉) · A. Redondo · A. Rey  
Department of Neurosurgery,  
Beaujon Hospital,  
100 Blvd du Général Leclerc,  
F-92110 Clichy, France  
Fax +33-1-47396635

**Abstract** The authors analysed the clinical and radiological findings and the surgical management of 25 patients admitted for scoliosis classified as idiopathic at first presentation, but in fact associated with spinal cord and/or brain stem anomalies. Twenty patients had syringomyelia, 19 had Chiari malformation. Scoliosis was the only presenting symptom when all these patients were referred to the orthopaedic surgeon. On examination, five patients had normal neurological findings,

while the others showed very mild neurological deficits. The diagnosis of syringomyelia and Chiari malformation was established by MRI, which is the best form of neuroradiological examination for discovering spinal abnormalities. Neurosurgical treatment is strongly recommended as the first step in the management of “pseudo” idiopathic scoliosis.

**Key words** Spinal cord · Scoliosis · Syringomyelia · Chiari malformation · Surgical management

### Introduction

Spinal cord anomalies in congenital spinal deformity are probably more common than has been suggested previously [13, 17]. With the development of MRI, syringomyelia and Chiari I malformation are increasingly being found in patients classified as having idiopathic scoliosis [17].

Accordingly, since 1988 spinal and cranial posterior fossa MRI has been performed in any patient admitted to our hospital with a supposed idiopathic scoliosis and 25% of these patients were diagnosed to have spinal cord and/or brain stem anomalies associated with scoliosis. We analysed the clinical and radiological findings and the surgical management of these patients.

### Patients and methods

Between 1988 and 1995, 100 patients were admitted to the orthopaedic department of Beaujon Hospital because of progression of an “idiopathic” scoliosis. Spinal and cranial MRI was performed in all the admitted patients. Twenty-five patients of this series had an

associated syringomyelia and/or Chiari I malformation and were referred to the neurosurgical team. There were 10 females and 15 males, aged between 12 and 40 years old (mean age 30 years).

The type of curvature and the spinal level of scoliosis were noted for each patient. The spinal curvature measurements, performed with the Cobb technique (as recommended by the Scoliosis Research Society), were available for all the patients. Each patient was examined by a neurologist so as to detect even very mild neurological deficits.

All patients underwent conventional radiographic examinations that included standing frontal and lateral plain views of the entire spine and MRI of the spine and the cranial posterior fossa.

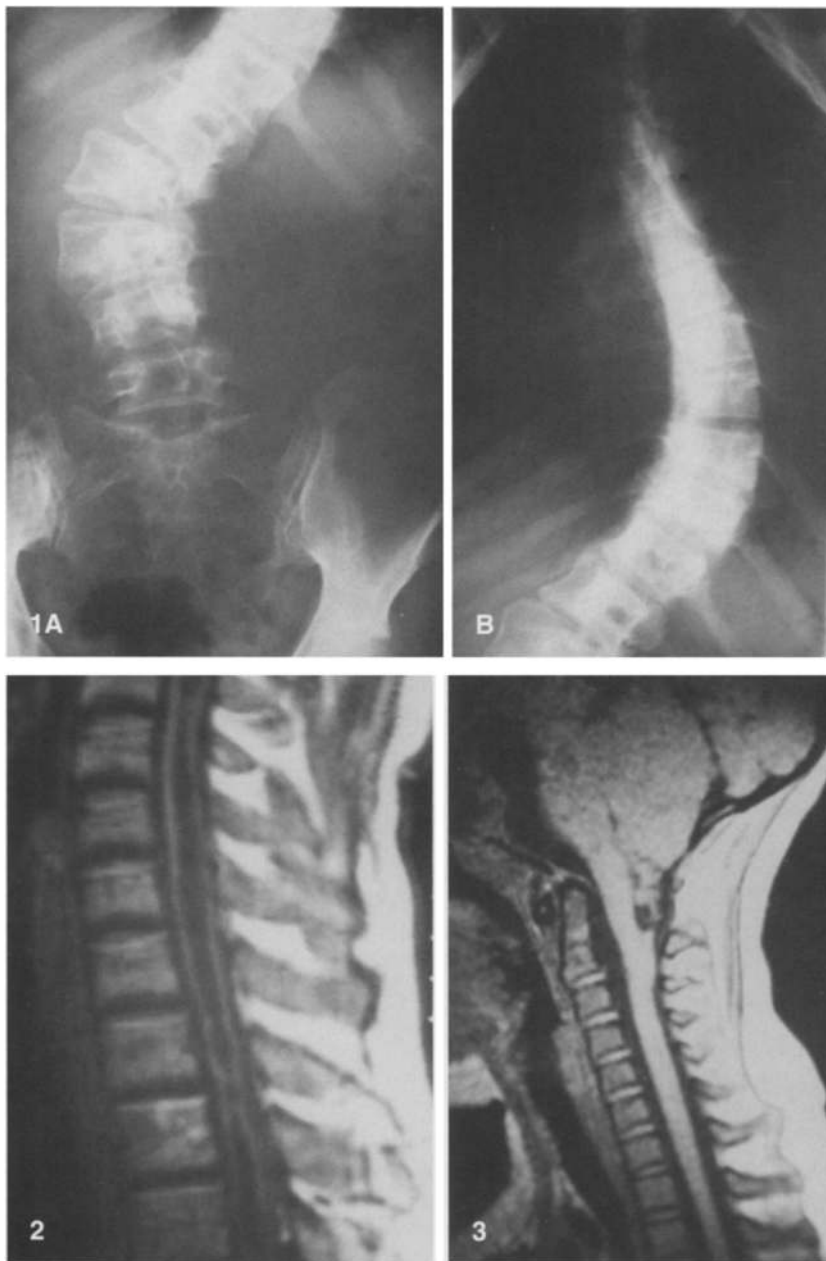
### Results

The scoliosis curve was thoracic in 17 cases and thoracolumbar in 8 (Fig. 1). Analysis of the curvature revealed a convex right thoracic curve in seven cases and a convex right thoracolumbar curve in two cases. Atypical spinal curvature findings included a convex left thoracic curve in ten cases and a convex left thoracolumbar curve in six. The scoliosis curve magnitude ranged from 15° to 56°, with a mean Cobb angle of 30° at the time of presentation. Thus, spinal curvature measurements revealed *mild scol-*

**Fig. 1 A, B** Preoperative anteroposterior plain radiograph demonstrating a thoracolumbar scoliosis before surgery

**Fig. 2** T1-weighted sagittal MR image of cervical syringomyelia

**Fig. 3** T1-weighted sagittal MR image of a Chiari malformation type II



*iosis* ( $< 20^\circ$ ) in 4 cases, *moderate scoliosis* ( $20^\circ$ – $40^\circ$ ) in 10 cases and *severe scoliosis* ( $> 40^\circ$ ) in 11 cases.

Clinical neurological status was precisely evaluated. Five patients had painful scoliosis. Neurological examination revealed no abnormalities in five patients. Two patients presented only abnormal abdominal reflexes. The others presented very mild neurological deficits (Table 1).

Six patients presented syringomyelia without Chiari malformation (Fig. 2). The spinal level of syringomyelia was cervical in five patients and cervicothoracic in one. For these patients, the clinical status was normal in one and five patients had a mild neurological dysfunction.

**Table 1** Neurological deficits in 25 scoliotic patients with associated syringomyelia and/or Chiari I malformations. Some of them had several neurological deficits

Neurological deficit	No. of cases
Motor weakness	7
Sensibility abnormality	16
Diminished deep tendon reflexes	11
Mild pyramidal syndrome	12
Bladder dysfunction	2

Fourteen patients had syringomyelia associated with Chiari malformation. A mild neurological deficit was noted in 11 of them, while the examination findings were normal in the 3 others.

Five patients had only a Chiari I malformation, diagnosed by MRI (Fig. 3), and this congenital anomaly was associated with abnormal neurological findings in four of them. One patient had normal neurological findings.

All the patients were treated neurosurgically before undergoing orthopaedic treatment. The surgical management of syringomyelia without Chiari malformation was a syringo-subarachnoid shunting performed with a tiny T-catheter (four cases) or a foramen magnum decompression (two cases). Patients with a Chiari malformation alone or associated with syringomyelia had a foramen magnum decompression with a duraplasty. In one patient this surgical procedure was followed by a syringo-subarachnoid shunt, 4 months later, because of the absence of clinical and radiological improvement.

Clinical follow-up was assessed on the basis of neurological status and the progression of scoliosis. All the patients admitted for a painful scoliosis improved, and 6 patients out of 7 with a motor weakness and 10 patients out of 16 with a sensibility abnormality improved. The other neurological deficits remained stable.

All patients also underwent postoperative MRI which revealed regression of the syringomyelia in all except one. Patients were also followed postoperatively, with upright and lateral scoliosis survey radiographs, at 3, 6 and 12 months and annually thereafter. Postoperative results at the 3-month follow-up examination regarding the evolution of scoliosis, were as follows: 8 patients (4 with mild scoliosis, 4 with moderate scoliosis) had improved and did not need any specific treatment for scoliosis; 14 patients (5 with moderate scoliosis, 9 with severe scoliosis) remained unchanged; and 3 patients (1 with moderate scoliosis, 2 with severe scoliosis) had worsened. Accordingly, orthopaedic treatment with a specific brace was instituted in four patients, with an improved clinical and radiological result 6 and 12 months later. Thirteen patients were referred to the orthopaedic surgeon for surgical treatment of the scoliosis. This surgical treatment was carried out after an average of 6 months from the time of the neurosurgical procedure (range 15 days–1 year). All patients underwent a posterior spinal fusion with placement of Cotrel Dubousset rods. Three of them underwent anterior spinal surgery before the posterior procedure. No neurological complications were reported after the orthopaedic surgery, which was performed under the control of somatosensory evoked potentials.

## Discussion

In the literature, the incidence of spinal cord and brain stem anomalies in “idiopathic” scoliosis varies from 4%

**Table 2** Literature review. Incidence of spinal cord and brain stem anomalies in idiopathic scoliosis

Report	Incidence of spinal anomalies (%)
Blake et al. (1986) [4]	58
Nokes et al. (1987) [13]	53
Samuelsson et al. (1991) [17]	7
Bradford et al. (1991) [5]	38
Lena et al. (1992) [9]	50
Arai et al. (1993) [2]	4

to 58% (Table 2). Most authors stress that a neurogenic cause of scoliosis should always be considered before classifying it as idiopathic [2–6, 8, 13, 17].

The aetiology and pathogenesis of progressive scoliosis remain unknown. In some papers, the authors distinguish between “paralytic scoliosis” and “idiopathic scoliosis” [1, 8, 11, 15]. “Paralytic scoliosis” is observed with severe dysraphism in children and it is always a very evolutive scoliosis. “Idiopathic scoliosis” is observed in both children and adults. The initial neurological examination is unremarkable. In a few cases, neurological anomalies appear at follow-up, and underlying spinal cord anomalies are thus diagnosed.

The aetiology of scoliosis associated with syringomyelia is still unknown. Some authors assume that the location of syringomyelia and the severity of neurological involvement are not related to the magnitude or location of the scoliosis [8, 11]. Considering the coexistence between scoliosis and syringomyelia, Aboulker concludes that scoliosis may predispose a patient to syringomyelia, because of the appearance of radicular lesions and the modifications of the spinal CSF balance that appear on the convexity of scoliosis [1]. Other authors consider that scoliosis occurs as a consequence of syringomyelia, because of the imbalance in the strength of the paravertebral muscles. They assume that the anterior horn, which innervates the muscles of the trunk, is damaged by an asymmetrically expanded syringomyelia [8].

Patients with neurological symptoms are more likely to have underlying spinal anomalies, and MRI is the best examining modality to detect them [2–5, 10, 13, 17]. However, 20% of the patients with anomalies on MRI did not present neurological symptoms. In fact, many of the spinal anomalies associated with scoliosis produce no or only minimal symptoms, except in the case of tethered cords or diastematomyelia, in which motor weakness or sphincter dysfunction is common [6, 7, 9, 11, 12].

So, which clinical signs in scoliosis are considered as suspicious? First, a progressive scoliosis curve in a child of less than 11 years is unusual, and we recommend routine use of MRI for these children, even those with unremarkable clinical neurological examinations. The other pathological circumstances or neurological signs are left

thoracic or thoracolumbar scoliosis, painful scoliosis (or back pain), a mild painful stiff neck, abnormal deep tendon reflexes (diminished, increased, asymmetrical), muscle atrophy, minimal sensory loss, minimal weakness of a limb, absence of an abdominal cutaneous reflex and scabs under the brace. These anomalies may be present at the initial examination or may occur a few months or even years later in a child with idiopathic scoliosis. Therefore, follow-up with regular neurological examinations is essential in any case of idiopathic scoliosis [6, 8, 16].

MRI is an accurate means of diagnosing many of the lesions associated with scoliosis. It is the ideal screening tool in children with idiopathic scoliosis [3, 5, 8, 10, 12, 13, 17]. The spinal cord is best demonstrated on T2-weighted images, where the contrast between spinal cord and CSF is greatest. Sagittal images are preferred to assess the form of the brain stem and position of the cerebellar tonsils. Conversely, when examining the spinal cord, axial images show the size and extent of a syrinx best, especially when the scoliosis is severe.

In our opinion, indications for MRI are left thoracic scoliosis, a juvenile idiopathic scoliosis with onset before 11 years, any mild neurological deficit or pain, and planned surgical treatment of idiopathic scoliosis. It is also important to carry out a complete examination of the spine to rule out the possibility of a tethered cord or other intraspinal anomaly.

The management of scoliosis associated with intraspinal anomalies has changed in recent years [6–9, 11, 16]. In the past, operative correction of scoliosis was associated with a high incidence of neurological complications, including paraplegia [14, 18]. Therefore, in accordance with many other authors, we suggest operating first on spinal cord or brain stem anomalies [6, 7, 9, 11, 17]. Whenever a Chiari malformation is diagnosed, even when associated with a syringomyelia, we always carry out a craniocervical decompression. This consists of opening the foramen magnum with an upper-cervical decompression and creating a magna cisterna. A duraplasty may complete the decompression. In most cases, the syringomyelia regresses within 3 months, as assessed on the post-operative MRI. If it does not, shunting of the syringo-

myelia may be performed. We apply a syringo-subarachnoid shunt with a tiny T-catheter under surgical microscope. Other authors use syringo-peritoneal or syringopleural shunts [9]. We do not think that decompression of the posterior fossa and a shunt procedure of the syrinx should be undertaken at the same time.

One should keep in mind that neurosurgical procedures may stabilize or improve neurological function, may stop progression of scoliosis, at least transiently, and may make surgical correction of scoliosis less dangerous [11, 17].

Once the neurological treatment is completed, the problem is when and how to treat the scoliosis. The length of time one should wait after a drainage procedure or a craniocervical decompression before proceeding with scoliosis surgery is not always specified in reports of other series. If the scoliosis improves or remains stable, it may be prudent to wait, and undergo regular clinical and radiographic follow-ups. In most cases, however, the progression of scoliosis is arrested only temporarily by drainage of the syrinx. In these cases, treatment of the scoliosis must be undertaken: orthopaedic management for mild or moderate scoliosis and surgical correction for severe scoliosis.

We think that treatment of the scoliosis may commence between 3 and 6 months after neurosurgical treatment, or even earlier for severe scoliosis (four cases of severe scoliosis in our series were operated on 2 weeks after the neurosurgical procedure). It is nonetheless useful to carry out MRI of the spine so as to assess the functional subarachnoid shunt and observe evidence of reduction in size of the syrinx.

## Conclusion

Neurosurgeons and orthopaedic surgeons should keep in mind the fact that syringomyelia and Chiari malformation are not rare in apparently idiopathic scoliosis. The use of MRI is strongly recommended in any scoliotic patient referred for surgery. Neurosurgical treatment should always be performed before any orthopaedic procedure.

## References

1. Aboulker J (1979) La syringomyélie et les liquides intra-rachidiens. *Neurochirurgie* 25 [Suppl 1]: 9–132
2. Arai S, Ohtsuka Y, Moriya H, Kitahare H, Minimi S (1993) Scoliosis associated with syringomyelia. *Spine* 18: 1591–1592
3. Barnes PD, Brody JD, Jaramillo D, Akbar JU, Emans JB (1993) Atypical idiopathic scoliosis: MR imaging evaluation. *Radiology* 186: 247–253
4. Blake NS, Lynch AS, Dowling FE (1986) Spinal cord abnormalities in congenital scoliosis. *Ann Radiol* 29: 237–241
5. Bradford DS, Heithoff KB, Cohen M (1991) Intraspinal abnormalities and congenital spine deformities: a radiographic and MRI study. *J Pediatr Orthop* 11: 36–41
6. Depotter J, Rigault P, Pouliquen JC, Padovani JP, Hirsch JF, Regnier D, Besson G, Touzet PH, Guigand O, Guyonvarch G (1987) Syringomyélie et scoliose chez l'enfant et l'adolescent. A propos de 14 cas. *Rev Chir Orthop* 73: 203–212
7. Forin V, Hautefort P, Beauvais P, Zerah M (1990) Scoliose et syringomyélie de l'enfant. A propos de 10 cas. *Ann Réadaptation Méd Phys* 33: 449–459

8. Isu T, Chono Y, Iwasaki Y, Koyanagi I, Akino M, Abe H, Abunmi K, Kaneda K (1992) Scoliosis associated with syringomyelia presenting in children. *Childs Nerv Syst* 8:97–100
9. Lena G, Boudawara Z, Genitori L, Cavalhero S, Choux M (1992) 14 cas de syringomyélie communicante associée à une malformation de chiari type I chez l'enfant. *Neurochirurgie* 38:297–303
10. Lewonoswski K, King JD, Nelson MD (1992) Routine use of magnetic resonance imaging in idiopathic scoliosis patients less than eleven years of age. *Spine* 17:S109–115
11. Muhonen MG, Menezes AH, Sawin PD, Weinstein ST (1992) Scoliosis in pediatric Chiari malformations without myelodysplasia. *J Neurosurg* 77:69–77
12. Nohria V, Oakes WJ (1991) Chiari I malformation: a review of 43 patients. *Pediatr Neurosurg* 16:222–227
13. Nokes SR, Murtagh FR, Jones JD, Downing M, Arington JA, Turetsky D, Silbiger ML (1987) Childhood scoliosis: MR imaging. *Radiology* 164:791–797
14. Noordeen MHHH, Taylor BA, Edgar MA (1994) Syringomyelia. A potential risk factor in scoliosis surgery. *Spine* 19:1406–1409
15. Oldfield EH, Muraszko K, Shawker TH, Patronas NJ (1994) Pathophysiology of syringomyelia associated with Chiari I malformation of the cerebellar tonsils. Implications for diagnosis and treatment. *J Neurosurg* 80:3–15
16. Phillips WA, Hensinger PN, Kling TF (1990) Management of scoliosis due to syringomyelia in childhood and adolescence. *J Pediatr Orthop* 10:351–354
17. Samuelsson L, Lindell D, Kogler H (1991) Spinal cord and brain stem anomalies in scoliosis. MR screening of 26 cases. *Acta Orthop Scand* 62:403–406
18. Williams B (1979) Orthopaedic features in the presentation of syringomyelia. *J Bone Joint Surg [Br]* 61:314–323