

Systemic inflammation induces a profound long term brain cell injury in rats

Long Fan¹, Tianlong Wang^{1*}, Lirong Chang², Yizhi Song², Yan Wu², and Daqing Ma³

¹Department of Anesthesiology, Xuanwu Hospital, Capital Medical University, Beijing, China,

*Email: w_tl5595@hotmail.com; ²Department of Anatomy, Capital Medical University, Beijing, China; ³Anaesthetics, Pain Medicine & Intensive Care, Department of Surgery and Cancer, Imperial College London, Chelsea and Westminster Hospital, London, UK

The long term impact of neuroinflammation induced by systemic inflammation on astroglial transcription factor nuclear factor (NF)- κ B activation in the sub-region of hippocampus as well as its' association with the ultra-structural changes in brain cells are yet unknown. In this study, rats received 10 mg/kg of lipopolysaccharide (LPS, ip injection) and NF- κ Bp65 expression on the astroglia as well as the neuronal and astroglial ultra-structural changes and/or death and microvasculature damage were assessed with immunofluorescence and transmission electron microscopy respectively up to 16 days after treatment. The results showed that in the CA1 and CA3 region of the hippocampus, the fluorescence intensity of NF- κ Bp65 was increased from day 1 after LPS injection, reaching a peak at day 3, and stayed at higher level when compared to the control up to 16 days after LPS treatment ($P < 0.05$). Electron microscopy studies revealed sustainable substructural alterations, injury or even death of astrocytes, neurons and capillaries even after 16 days post LPS injection. Our study demonstrated that long-term sustainable activation of astroglial NF- κ B following systemic inflammation was associated with brain cell and microvasculature injury in the sub-region of the hippocampus which ultimately likely results in brain functional impairment.

Key words: astroglial NF- κ Bp65, LPS, systemic inflammation, hippocampus, microvasculature injury

INTRODUCTION

Sepsis, with an increasing incidence in recent years, has been considered as a leading cause of non-cardiac mortality in intensive care units (Iwashyna et al. 2010). It has been recognized that sepsis causes not only acute but also chronic brain dysfunction (Barichello et al. 2005, Semmler et al. 2007, 2012, Streck et al. 2008, Chavan et al. 2012). Indeed sepsis survivors often present with serious long-term cognitive impairment that can affect as many as 70% of septic patients after discharge from hospitals (Czapski et al. 2010). The impact of sepsis on the pathophysiological alterations of the brain began to receive attention recently but the underlying molecular mechanisms remain unknown (Semmler et al. 2007). Accumulating evidence sug-

gests that systemic inflammation following sepsis in turn results in neuroinflammation which ultimately causes neuron loss and cognitive impairment (Brambilla et al. 2005, Qin et al. 2007, Lee et al. 2008, Weberpals et al. 2009, Zhou et al. 2012, Kaizaki et al. 2013). In fact, a close association between the peripheral inflammation and neurodegeneration diseases such as Multiple sclerosis (MS), Alzheimer's (AD), and Parkinson's disease (PD) was well documented in the literature (Collins et al. 2012, Eikelenboom et al. 2012, Franks and Slansky 2012, Lee et al. 2013). Systemic inflammation, following a sustained sepsis induced neuroinflammatory response, may be responsible for worsening CNS function but the cellular ultra-structural changes in the brain still needs to be determined.

Astrocytes are the most abundant cell type in the central nervous system (CNS) and in response to injury, reactive astrocytes are the prominent source of inflammatory mediators (e.g. cytokines, chemokines,

Correspondence should be addressed to T. Wang
Email: w_tl5595@hotmail.com

Received 14 May 2014, accepted 16 July 2014

and adhesion molecules) (Fan et al. 2013). These are closely associated with neuroinflammation (Combes et al. 2012, Orellana et al. 2012, Bade et al. 2013). Previous studies suggested that sustained overactivation of astrocytes *via* the transcription factor NF- κ B are closely related with the neuroinflammatory process, worsening traumatic spinal cord injury. Conversely selective inhibition of astroglial NF- κ B activation results in a reduction of inflammatory injury and improves the neuronal regeneration and functional recovery of the spinal cord (Bethea et al. 1998, Brambilla et al. 2005, 2009b). Furthermore, transgenic inactivation of astroglial NF- κ B leads to a protective effect (Brambilla et al. 2009a,b). Taken together, it is likely that NF- κ B activation in astrocytes, following neuroinflammation from systemic sepsis, plays a key role in the pathophysiology of the development of the CNS disorder. However, the long-term effects of astroglial NF- κ B activation following

sepsis on hippocampal astroglial, neuronal and vascular ultrastructure remain unknown. The aim of the present study was to investigate the impact of astroglial NF- κ B activation on astroglial, neuronal and vascular cell ultrastructural from the early to late stages of systemic inflammation induced by lipopolysaccharide (LPS) injection in rats.

METHODS

Animals

After obtained approval from the animal use committee of Capital Medical University, Male Wistar rats, weighing 250–300 g (provided by Capital Medical University), were housed 2–3 per cage under standard conditions at a room temperature of 22°C (\pm 1°C) and with a 12-h light–dark cycle. Food and water were freely accessed *ad libitum*.

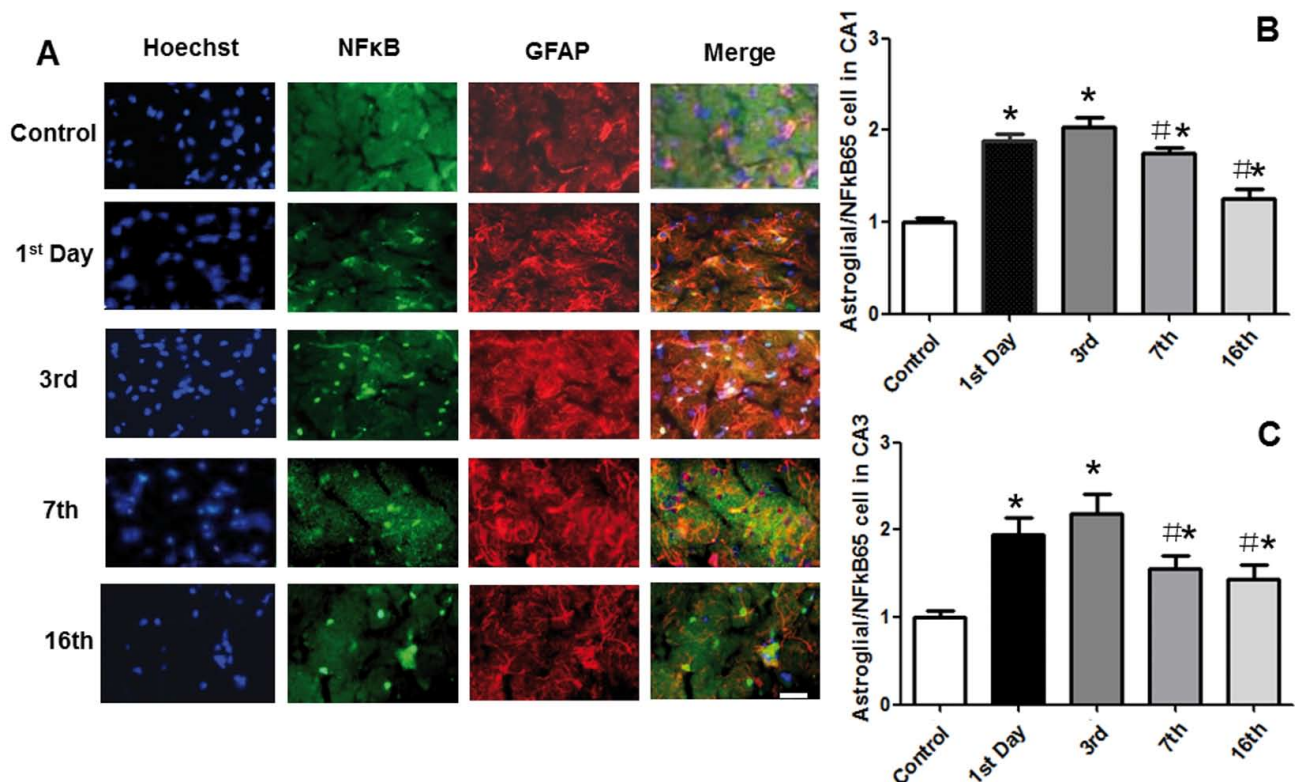


Fig. 1. Activation of astroglial NF- κ B(65) in the CA1 and CA3 region of hippocampus in septic rats. (A) Activated astroglial NF- κ Bp65 against a time-course in the CA1 region of hippocampus after lipopolysaccharide injection. Nuclei were stained with Hoechst 33342 (blue fluorescence), and NF- κ Bp65 expression was labeled in green fluorescence, and glial fibrillary acidic protein (GFAP), a marker of active astrocyte, was labeled in red and then triple labels were merged. (B) Mean data of activated astroglial NF- κ Bp65 in the CA1 region. (C) Mean data of activated astroglial NF- κ Bp65 in the CA3 region. Results are mean \pm SEM ($n=5$); * $P<0.05$ vs. control, # $P<0.05$ vs. 3rd day. Scale bar is 100 μ m.

Experimental design

Rats received 10 mg/kg of lipopolysaccharide (LPS) (0127:B8, *E. coli*; Sigma, St. Louis, MO, USA) dissolved in 1 ml sodium chloride (0.9%) intraperitoneally. The dose of LPS was chosen from previous reports (Semmler et al. 2005, Weberpals et al. 2009) in which systemic inflammation was clearly evident. Rats ($n=4$) only receiving 0.9% saline injection served as controls. They were killed by an over dose of thiopentone (50 mg/kg; ip) and perfused with chilled 0.1 M phosphate buffer (pH 7.4) and 4% paraformaldehyde.

The brains from rats treated with LPS post-treatment day 1, 3, 7 and 16 ($n=8$) were harvested together with the naïve controls ($n=4$). Among those brains, 4 brains in each time point were used for immunofluo-

rescence staining and electron microscopy examination respectively.

Immunofluorescence

Tissues were mounted in OCT compound and frozen at $-18\text{ }^{\circ}\text{C}$. Coronal brain sections ($25\text{ }\mu\text{m}$) were cut using a cryostat (CM1850, Leica, Mannheim, Germany). The studied tissue sections were selected according to anatomical landmarks corresponding to the atlas of Paxinos and Watson between Bregma -2.30 and Bregma -3.60 for immunofluorescence staining. The triple-expression of NF- κ B, GFAP and nuclear morphology was evaluated on adjacent tissue sections. For each stained marker, sections from all time points were

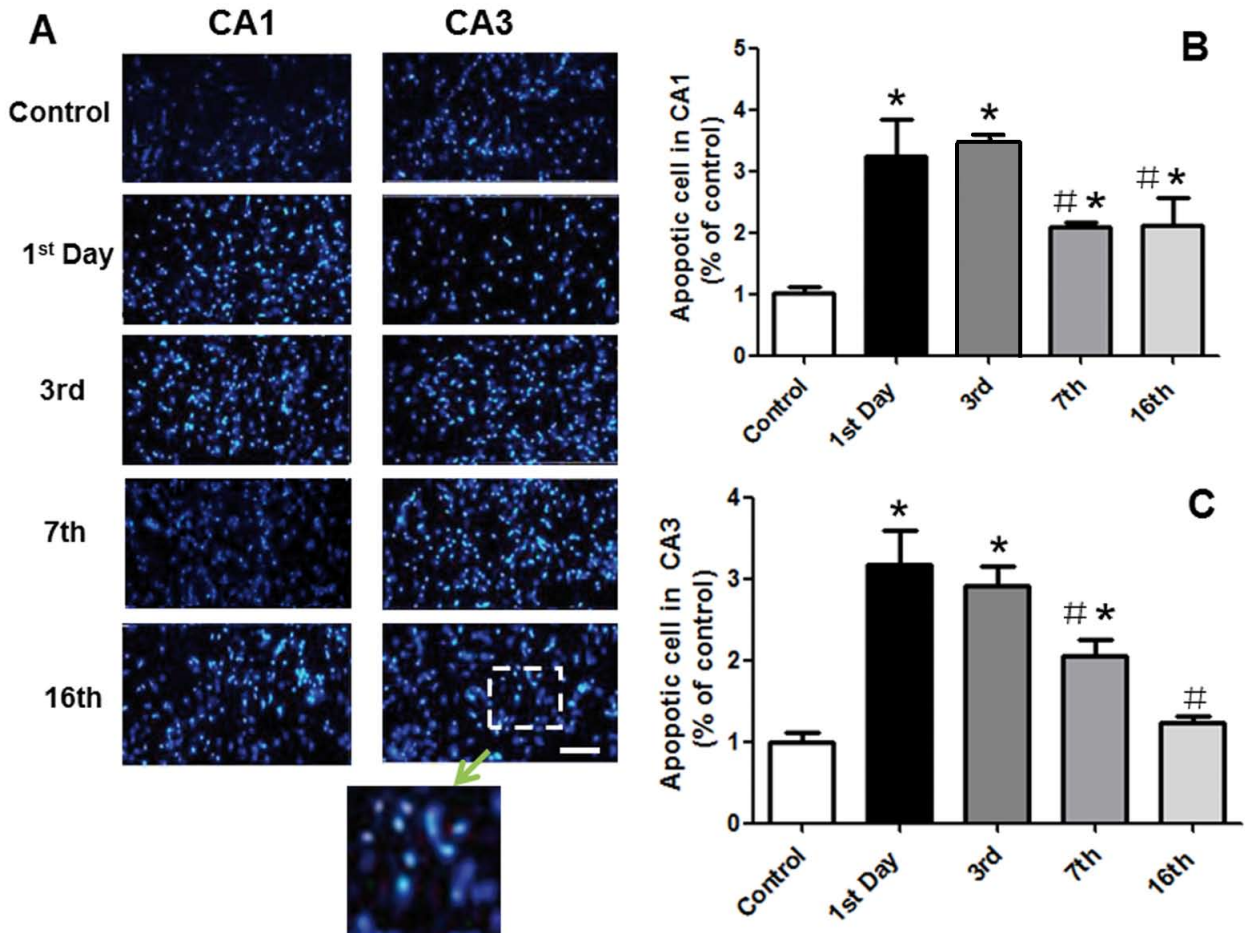


Fig. 2. Cell apoptosis in the CA1 and CA3 region of hippocampus in septic rats. (A) Hoechst 33342-stained nuclei displaying pyknosis in the CA1 and CA3 region indicating the wide spread of apoptotic cells. (B) Mean number of apoptotic cells in the CA1 region. (C) Mean number of apoptotic cells in the CA3 region. Results are mean \pm SEM ($n=5$); * $P<0.05$ vs. control, # $P<0.05$ vs. 3rd day. Scale bar is 200 μm .

stained simultaneously to ensure the identical conditions for subsequent quantitative analysis.

Sections were washed three times (10 min each) with 1× PBS, blocked in 0.1 M PBS containing 5% horse serum, and 0.3% Triton X-100 for 1 h at room temperature and then incubated for 24 h at 4°C with first primary antibody: NF-κB (p65 active form; 1:200; CHEMICON, Reutlingen, Germany) and GFAP (1:500; Sigma, Saint Louis, MI). After thorough washing, sections were incubated with Alexa Fluor 488-conjugated goat anti-rabbit IgG (1:500; Molecular Probes, Eugene, OR, USA) or Alexa Fluor 594-conjugated goat anti-mouse IgG (1:500; Molecular Probes, Eugene, OR, USA) for 2 hours at room temperature. Control sections in which primary antibodies or secondary antibodies were omitted showed no labeled cells. All sections were counterstained with Hoechst 33342 (1:1000; Roche, Shanghai, China) for 10 min.

Cell counts

Areas of interest, the CA1 and CA3 region of the hippocampus, were observed with a Leica fluores-

cence microscope (DM 5000 B, Leica GmbH, Wetzlar, Germany) with excitation and emission wavelengths of 470 and 525 (AlexaFluor1 488), 590 and 617 nm (Alexa Fluor 594), and 340 nm (Hoechst 33342), respectively. Micrographs were captured and processed with Adobe Photoshop 7.0 in a blinded manner. The number of triple-colocalization of NF-κBp65/GFAP/ Hoechst in the all groups was counted in the CA1 and CA3 region in random 10 sections/animal/time point. For Hoechst 33342 staining alone, stained nuclei displaying pyknosis were counted. The average of cell counts from 10 sections was normalized with cell counts from control and then expressed as a % of control.

Transmission electron microscopy (TEM)

The hippocampal tissue blocks (2×2×2 mm) were further post-fixed in glutaraldehyde solution (2.5%) for 2 h, followed by being embedded in the epoxy resin. Then the embedded tissues were cut into ultra-thin sections with an ultramicrotome using the diamond knife and mounted on 150 mesh copper grids. After being stained with uranylacetate and lead citrate, the speci-

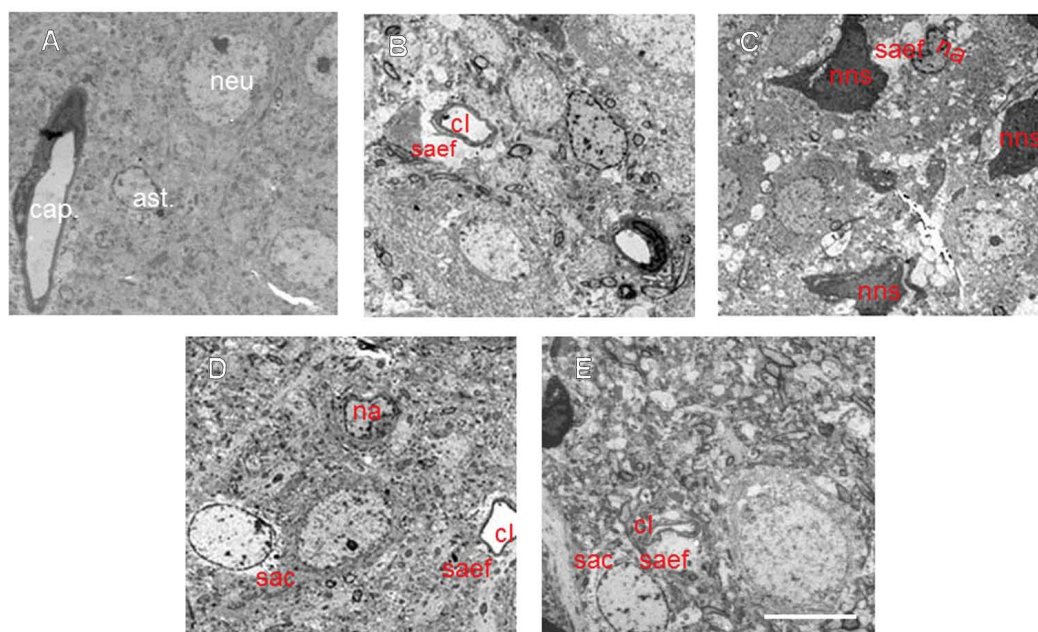


Fig. 3. Electron micrographs of astrocyte, surrounding capillary and neuron in the hippocampus. (A) Naïve control: (ast) normal astrocyte; (neu) neuron; (cap) capillary. (B) 1st day after lipopolysaccharide (LPS) administration (ip), swollen astrocyte end feet and compressed capillary lumen were readily seen. (C) 3rd day after LPS (ip), necrotic neurons and astrocyte. (D) 7th day after LPS (ip), swollen astrocyte and compressed capillary lumen. (E) 16th day after LPS (ip), swollen astrocyte end feet and compressed capillary lumen still can be found. (saef) swollen astrocyte end feet surrounding capillary lumen; (na) necrotic astrocyte; (sac) swollen astrocyte cytoplasm; (nns) necrotic neuron surrounding with swollen astrocyte; (cl) capillary lumen. Scale bar is 10 μ m

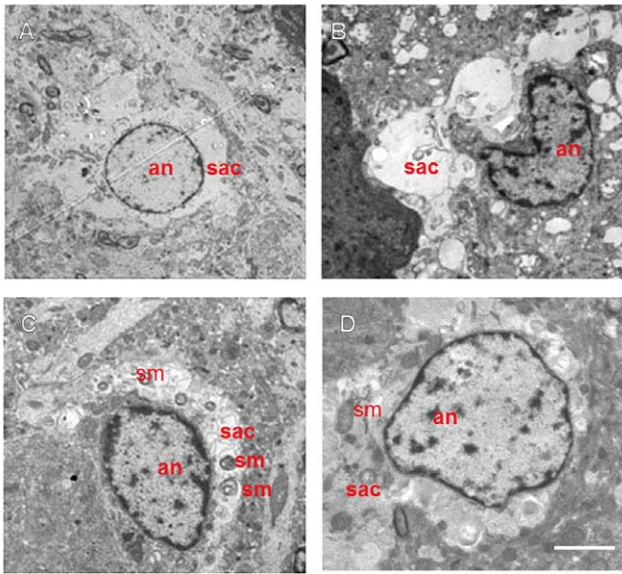


Fig. 4. Electron micrographs of astrocyte in different time point after lipopolysaccharide (LPS) injection. (A) 1st day after LPS injection, swollen astrocyte; (B) 3rd day after LPS injection, necrotic astrocyte; (C) 7th day after LPS injection, swollen astrocyte with swollen mitochondria; (D) 16th day after LPS injection, mild swollen astrocyte. (Sac) Swollen astroglia cytoplasm; (sm) swollen mitochondria; (an) astroglial nuclei. Scale bar is 5 μ m.




Fig 5. Electron micrographs of capillary in different time point after LPS injection. (A) 1st day after LPS injection; (B) 7th day after LPS injection; (C) 16th day after LPS injection. (ast) swollen astrocyte end feet; (cap) compressed capillary lumen; (mit) swollen mitochondria. Scale bar is 10 μ m

mens were observed with a transmission electron microscopy (HITACHI-7650, Hitachi High-Technologies Corporation, Shanghai, China) (Ku et al. 2010).

Statistical analysis

All results are expressed as mean \pm SEM. Data were analyzed with one-way ANOVA followed by *post-hoc* Student-Newman-Keuls or Kruskal-Wallis test for multiple comparisons where appropriate. A level of $P < 0.05$ was considered to be statistically significant. Correlation analyses were performed using Pearson's correlation coefficient. All statistical analyses were carried out using SPSS software (Ver. 11.5, IBM, Chicago, IL, USA).

RESULTS

Astroglial NF- κ Bp65 activation in the CA1 and CA3 region of hippocampus after LPS injection

NF- κ Bp65 is expressed at a relative lower level when astrocytes are in the rest state (Fig. 1A,B). However, under a stress challenge, e.g. in the case of systemic inflammatory response induced by LPS ip injection, active astroglial NF- κ Bp65 overexpression occurred and in the CA1 region of hippocampus, the fluorescence intensity of active astroglial NF- κ Bp65 was increased 1 day after LPS injection, reaching a peak at the post-treatment day 3, and was maintained above baseline level 16 days after LPS injection (Fig. 1A). When triple-localization of GFAP, NF- κ B and nuclei were counted, it was increased by 90% and 100% relative to control 1 and 3 day after LPS injection respectively ($P < 0.05$). It was declined at 7 and 16 days after LPS administration but still significant higher than baseline (Fig. 1B). Similar pattern changes were also found in the CA3 region (Fig. 1C).

Apoptotic cells in the CA1 and CA3 region of hippocampus

Hoechst 33342 is a cell fluorescent permeable dye with an affinity for DNA. It allows a detailed analysis of nuclear morphology for evaluation of cell death. Hoechst 33342-stained nuclei displaying pyknosis can be considered as apoptotic cells. In the region CA1 of hippocampus, the number of apoptotic cells was increased by 220% at day 1 after LPS injection and

reached an increase of 250% at day 3 when compared to that of the control group ($P < 0.05$). This level then decreased slightly but still stayed at a significant higher level up to 16 days after LPS injection ($P < 0.05$) (Fig. 2A,B). In the CA3 region, the number of apoptotic cells changed similarly to the trend in CA1 except that it returned to near the normal level 16 day after LPS injection (Fig. 2A,C). When the correlation between apoptotic cell number (Fig. 2) and triple-expression of GFAP, NF- κ B and Hoechst 33342 nuclei number (Fig. 1) was made, there was clearly a positive correlation found in the CA1 ($r^2 = 0.516$; $P = 0.008$) and CA3 ($r^2 = 0.698$; $P = 0.0001$) region, respectively.

Ultrastructural changes of astrocytes and neuron under electron microscopy

After clarifying the inflammatory response (Fig. 1) and apoptotic cells (Fig. 2), we then focused on the ultra-structure changes of astrocytes and the surrounding neuron. When compared to the normal control (Fig. 3A), the morphological changes that can be readily seen were the presence of swollen astrocytes and karyopyknosis neuron from day 1 (Fig. 3B) to day 16 (Fig. 3E) after LPS injection. The most severe cell death was found in day 3 (Fig. 3C) after LPS injection. These changes were more evident with higher magnification images (Fig. 4), in particular the swollen astroglia with heavily injured mitochondria can be seen clearly (Fig. 4C).

The ultrastructural changes of microvessels

Compressed capillary lumen and swollen astrocyte end feet are the most common changes in all time points. In swollen astrocytes, astrocytic end feet adjacent to the vascular basement membrane covered an increased surface and contained swollen mitochondria in an empty-looking cytoplasm characterized by a low electron density (Fig. 5).

DISCUSSION

The present study found sustained astroglial NF κ Bp65 activation in the CA1 and CA3 region of hippocampus up to 16 days after LPS injection in rats. Astroglial NF κ B positive cells are well correlated with the apoptotic cells in the hippocampus indicating that LPS induced systemic inflammation in turn resulted in neuroinflammation mediated by NF κ B which ultimately

caused cell death. Cellular ultra-structural changes of astrocytes, neurons, and surrounding vessels and even cell death were readily detected throughout the whole study period. All these findings may give solid pathological foundation to why sepsis survivors often present with serious long-term cognitive impairment.

Sepsis often invokes severe systemic inflammation and subsequently results in multi-organ dysfunction including the brain. However, the impact of systemic inflammation on the central nervous system and underlying mechanisms remain elusive (Czapski et al. 2010). Lipopolysaccharide (LPS), a bacteria endotoxin, is a potent inflammatory agent (Reyes et al. 2003) and has been used to stimulate the host response (Meltzer et al. 2003). In fact, intraperitoneal injection of LPS exerts a myriad of effects in rats including cognitive dysfunction, electrophysiological, metabolic and morphological changes in the brain (Semmler et al. 2007, 2008). A question to how is the LPS-signal mediated inflammation systemically reaching to the brain eventually reminds not fully elusive. However, a series of studies proved that LPS can damage brain blood barrier directly (Ghosh et al. 2014) and can cause leukocytes infiltrating into the brain matter (Pieper et al. 2013). All but for more than these changes can induce brain inflammation *via* several pathways (Fung et al. 2012) for systemic cytokines induced by LPS directly moving into the brain and then causing glial activation. The latter in turn generates more cytokines and finally cause cognitive impairment (Vasconcelos et al. 2014) *via* various mechanisms *per se* (Lyman et al. 2014).

It is noted that a relatively short-term (mainly 2–4 day after LPS injection) morphological changes in neurons and microglia was reported previously. In this study, we have determined such changes last more than two weeks. Surprisingly, the sustained pathological changes in astrocytes, neurons and microvessels in the hippocampus were for the first time found in our study. Such changes may ultimately result in brain functional impairment including cognition dysfunction as reported previously (Weberpals et al. 2009, Terrando et al. 2012)

Evidence points to the primary role of astrocytes in the pathogenesis of the CNS disorders related to neuroinflammation, including migraine, epilepsy, inflammatory demyelinating diseases, metabolic disorders, metal intoxications, neurodegenerative disorders, and schizophrenia (De Keyser et al. 2008, Kovacs et al. 2012, Phatnani et al. 2013, Wagner et al. 2013). NF κ B is a pleiotropic transcription factor, which regulates the

expression of hundred genes, including many cytokines, chemokines, and adhesion molecules involved in inflammatory processes (Memet 2006, Ashall et al. 2009). Our data demonstrated that in our model of septic CNS injury, elevated expression of activated astroglial NF κ Bp65 in rats is related to apoptosis in the hippocampus. These results were further evidence showing that hippocampal-specific astroglial NF κ Bp65 activation is involved in neuronal damage and associated with neurological dysfunction including cognitive impairment following sepsis.

Electron microscopy studies revealed sustained sub-structural alterations of astrocyte and the surrounding neuron and capillaries even 16 days after LPS injection. It has been reported that NF κ B activation induced the concomitant increase in expression of COX-2 and iNOS genes (Huang et al. 2006, Olajide et al. 2013), which may lead to the formation of a superoxide anion (O $_2^{\bullet-}$) and nitric oxide (NO \bullet) that can form peroxynitrite (Kim et al. 2005), a very potent oxidising agent. Swollen mitochondria distributed widely in astrocyte may indicate an energy deficit, and abundant astroglial NF κ B activation may lead to secondary oxidative stress, which may ultimately damage neurons; the damage having clearly been shown in our study (Fig. 3). Furthermore, we also found that although the ultra-structural changes of astrocytes are earlier than those of neurons, neuronal structural changes are more serious and irreversible towards death at the late stage (Fig. 3C). Whether this implies that the normal astroglial function is essential for neurons to survive or neurons are more vulnerable than astrocytes warrants further study. In addition, combining specific neuronal marker and GFAP for double immuno-staining to see how both neurons and glia interacts in a long term run after sepsis is needed in further study as well.

CONCLUSION

In summary, our data indicates that the neuroinflammatory responses induced by the systemic administration of LPS evokes a time-dependent alteration in astroglia NF κ B in the hippocampus as well as brain cell ultrastructural changes and death together with microvascular injury. This ultimately results in a functional impairment of the brain. A better understanding of active NF κ B signaling pathways in astrocytes in acute systemic inflammation may provide a preventive or therapeutic strategy of modulating neuroinflammation and brain cell injury in various brain disorders.

REFERENCES

- Ashall L, Horton CA, Nelson DE, Paszek P, Harper CV, Sillitoe K, Ryan S, Spiller DG, Unitt JF, Broomhead DS, Kell DB, Rand DA, See V, White MR (2009) Pulsatile stimulation determines timing and specificity of NF-kappaB-dependent transcription. *Science* 324: 242–246.
- Bade AN, Zhou B, Epstein AA, Gorantla S, Poluektova LY, Luo J, Gendelman HE, Boska MD, Liu Y (2013) Improved visualization of neuronal injury following glial activation by manganese enhanced MRI. *J Neuroimmune Pharmacol* 8: 1027–1036.
- Barichello T, Martins MR, Reinke A, Feier G, Ritter C, Quevedo J, Dal-Pizzol F (2005) Cognitive impairment in sepsis survivors from cecal ligation and perforation. *Crit Care Med* 33: 221–223; discussion 262–223.
- Bethea JR, Castro M, Keane RW, Lee TT, Dietrich WD, Yeziarski RP (1998) Traumatic spinal cord injury induces nuclear factor-kappaB activation. *J Neurosci* 18: 3251–3260.
- Brambilla R, Bracchi-Ricard V, Hu WH, Frydel B, Bramwell A, Karmally S, Green EJ, Bethea JR (2005) Inhibition of astroglial nuclear factor kappaB reduces inflammation and improves functional recovery after spinal cord injury. *J Exp Med* 202:145–156.
- Brambilla R, Hurtado A, Persaud T, Esham K, Pearse DD, Oudega M, Bethea JR (2009a) Transgenic inhibition of astroglial NF-kappa B leads to increased axonal sparing and sprouting following spinal cord injury. *J Neurochem* 110: 765–778.
- Brambilla R, Persaud T, Hu X, Karmally S, Shestopalov VI, Dvorianchikova G, Ivanov D, Nathanson L, Barnum SR, Bethea JR (2009b) Transgenic inhibition of astroglial NF-kappa B improves functional outcome in experimental autoimmune encephalomyelitis by suppressing chronic central nervous system inflammation. *J Immunol* 182: 2628–2640.
- Chavan SS, Huerta PT, Robbiati S, Valdes-Ferrer SI, Ochani M, Dancho M, Frankfurt M, Volpe BT, Tracey KJ, Diamond B (2012) HMGB1 mediates cognitive impairment in sepsis survivors. *Mol Med* 18: 930–937.
- Collins LM, Toulouse A, Connor TJ, Nolan YM (2012) Contributions of central and systemic inflammation to the pathophysiology of Parkinson's disease. *Neuropharmacology* 62: 2154–2168.
- Combes V, Guillemin GJ, Chan-Ling T, Hunt NH, Grau GE (2012) The crossroads of neuroinflammation in infectious diseases: endothelial cells and astrocytes. *Trends Parasitol* 28: 311–319.

- Czapski GA, Gajkowska B, Strosznajder JB (2010) Systemic administration of lipopolysaccharide induces molecular and morphological alterations in the hippocampus. *Brain Res* 1356: 85–94.
- De Keyser J, Mostert JP, Koch MW (2008) Dysfunctional astrocytes as key players in the pathogenesis of central nervous system disorders. *J Neurol Sci* 267: 3–16.
- Eikelenboom P, Hoozemans JJ, Veerhuis R, van Exel E, Rozemuller AJ, van Gool WA (2012) Whether, when and how chronic inflammation increases the risk of developing late-onset Alzheimer's disease. *Alzheimers Res Ther* 4: 15.
- Fan YY, Zhang JM, Wang H, Liu XY, Yang FH (2013) Leukemia inhibitory factor inhibits the proliferation of primary rat astrocytes induced by oxygen-glucose deprivation. *Acta Neurobiol Exp (Wars)* 73: 485–494.
- Franks AL, Slansky JE (2012) Multiple associations between a broad spectrum of autoimmune diseases, chronic inflammatory diseases and cancer. *Anticancer Res* 32: 1119–1136.
- Fung A, Vizcaychipi M, Lloyd D, Wan Y, Ma D (2012) Central nervous system inflammation in disease related conditions: mechanistic prospects. *Brain Res* 1446: 144–155.
- Ghosh A, Birngruber T, Sattler W, Kroath T, Ratzler M, Sinner F, Pieber TR (2014) Assessment of Blood-Brain Barrier Function and the Neuroinflammatory Response in the Rat Brain by Using Cerebral Open Flow Microperfusion (cOFM). *PLoS One* 9: e98143.
- Huang TH, Tran VH, Duke RK, Tan S, Chrusasik S, Roufogalis BD, Duke CC (2006) Harpagoside suppresses lipopolysaccharide-induced iNOS and COX-2 expression through inhibition of NF-kappa B activation. *J Ethnopharmacol* 104: 149–155.
- Iwashyna TJ, Ely EW, Smith DM, Langa KM (2010) Long-term cognitive impairment and functional disability among survivors of severe sepsis. *JAMA* 304: 1787–1794.
- Kaizaki A, Tien LT, Pang Y, Cai Z, Tanaka S, Numazawa S, Bhatt AJ, Fan LW (2013) Celecoxib reduces brain dopaminergic neuronal dysfunction, and improves sensorimotor behavioral performance in neonatal rats exposed to systemic lipopolysaccharide. *J Neuroinflammation* 10: 45.
- Kim DH, Cho KH, Moon SK, Kim YS, Choi JS, Chung HY (2005) Cytoprotective mechanism of baicalin against endothelial cell damage by peroxynitrite. *J Pharm Pharmacol* 57: 1581–1590.
- Kovacs R, Heinemann U, Steinhäuser C (2012) Mechanisms underlying blood-brain barrier dysfunction in brain pathology and epileptogenesis: role of astroglia. *Epilepsia* 53 (Suppl) 6: 53–59.
- Ku S, Yan F, Wang Y, Sun Y, Yang N, Ye L (2010) The blood-brain barrier penetration and distribution of PEGylated fluorescein-doped magnetic silica nanoparticles in rat brain. *Biochem Biophys Res Commun* 394: 871–876.
- Lee JW, Lee YK, Yuk DY, Choi DY, Ban SB, Oh KW, Hong JT (2008) Neuro-inflammation induced by lipopolysaccharide causes cognitive impairment through enhancement of beta-amyloid generation. *J Neuroinflammation* 5: 37.
- Lee YJ, Choi DY, Yun YP, Han SB, Oh KW, Hong JT (2013) Epigallocatechin-3-gallate prevents systemic inflammation-induced memory deficiency and amyloidogenesis via its anti-neuroinflammatory properties. *J Nutr Biochem* 24: 298–310.
- Lyman M, Lloyd DG, Ji X, Vizcaychipi MP, Ma D (2014) Neuroinflammation: the role and consequences. *Neurosci Res* 79: 1–12.
- Meltzer JC, MacNeil BJ, Sanders V, Pylypas S, Jansen AH, Greenberg AH, Nance DM (2003) Contribution of the adrenal glands and splenic nerve to LPS-induced splenic cytokine production in the rat. *Brain Behav Immun* 17: 482–497.
- Memet S (2006) NF-kappaB functions in the nervous system: from development to disease. *Biochem Pharmacol* 72: 1180–1195.
- Olajide OA, Bhatia HS, de Oliveira AC, Wright CW, Fiebich BL (2013) Inhibition of neuroinflammation in LPS-activated microglia by cryptolepine. *Evid Based Complement Alternat Med* 2013: 459723.
- Orellana JA, von Bernhardi R, Giaume C, Saez JC (2012) Glial hemichannels and their involvement in aging and neurodegenerative diseases. *Rev Neurosci* 23: 163–177.
- Phatnani HP, Guarnieri P, Friedman BA, Carrasco MA, Muratet M, O'Keeffe S, Nwakeze C, Pauli-Behn F, Newberry KM, Meadows SK, Tapia JC, Myers RM, Maniatis T (2013) Intricate interplay between astrocytes and motor neurons in ALS. *Proc Natl Acad Sci U S A* 110: E756–765.
- Pieper C, Pieloch P, Galla HJ (2013) Pericytes support neutrophil transmigration via interleukin-8 across a porcine co-culture model of the blood-brain barrier. *Brain Res* 1524: 1–11.
- Qin L, Wu X, Block ML, Liu Y, Breese GR, Hong JS, Knapp DJ, Crews FT (2007) Systemic LPS causes chronic neuroinflammation and progressive neurodegeneration. *Glia* 55: 453–462.

- Reyes TM, Walker JR, DeCino C, Hogenesch JB, Sawchenko PE (2003) Categorically distinct acute stressors elicit dissimilar transcriptional profiles in the paraventricular nucleus of the hypothalamus. *J Neurosci* 23: 5607–5616.
- Semmler A, Frisch C, Debeir T, Ramanathan M, Okulla T, Klockgether T, Heneka MT (2007) Long-term cognitive impairment, neuronal loss and reduced cortical cholinergic innervation after recovery from sepsis in a rodent model. *Exp Neurol* 204: 733–740.
- Semmler A, Hermann S, Mormann F, Weberpals M, Paxian SA, Okulla T, Schafers M, Kummer MP, Klockgether T, Heneka MT (2008) Sepsis causes neuroinflammation and concomitant decrease of cerebral metabolism. *J Neuroinflammation* 5: 38.
- Semmler A, Okulla T, Sastre M, Dumitrescu-Ozimek L, Heneka MT (2005) Systemic inflammation induces apoptosis with variable vulnerability of different brain regions. *J Chem Neuroanat* 30: 144–157.
- Semmler A, Widmann CN, Okulla T, Urbach H, Kaiser M, Widman G, Mormann F, Weide J, Fliessbach K, Hoeft A, Jessen F, Putensen C, Heneka MT (2012) Persistent cognitive impairment, hippocampal atrophy and EEG changes in sepsis survivors. *J Neurol Neurosurg Psychiatry* 84: 62–69.
- Streck EL, Comim CM, Barichello T, Quevedo J (2008) The septic brain. *Neurochem Res* 33: 2171–2177.
- Terrando N, Rei Fidalgo A, Vizcaychipi M, Cibelli M, Ma D, Monaco C, Feldmann M, Maze M (2012) The impact of IL-1 modulation on the development of lipopolysaccharide-induced cognitive dysfunction. *Crit Care* 14: R88.
- Vasconcelos AR, Yshii LM, Viel TA, Buck HS, Mattson MP, Scavone C, Kawamoto EM (2014) Intermittent fasting attenuates lipopolysaccharide-induced neuroinflammation and memory impairment. *J Neuroinflammation* 11: 85.
- Wagner DC, Scheibe J, Glocke I, Weise G, Deten A, Boltze J, Kranz A (2013) Object-based analysis of astroglial reaction and astrocyte subtype morphology after ischemic brain injury. *Acta Neurobiol Exp (Wars)* 73: 79–87.
- Weberpals M, Hermes M, Hermann S, Kummer MP, Terwel D, Semmler A, Berger M, Schafers M, Heneka MT (2009) NOS2 gene deficiency protects from sepsis-induced long-term cognitive deficits. *J Neurosci* 29: 14177–14184.
- Zhou J, Chen Y, Huang GQ, Li J, Wu GM, Liu L, Bai YP, Wang J (2012) Hydrogen-rich saline reverses oxidative stress, cognitive impairment, and mortality in rats submitted to sepsis by cecal ligation and puncture. *J Surg Res* 178: 390–400.