

REVIEW ARTICLE

Tauopathies with parkinsonism: clinical spectrum, neuropathologic basis, biological markers, and treatment options

A. C. Ludolph^{a*}, J. Kassubek^{a*}, B. G. Landwehrmeyer^{a*}, E. Mandelkow^b, E.-M. Mandelkow^b, D. J. Burn^c, D. Caparros-Lefebvre^d, K. A. Frey^e, J. G. de Yébenes^f, T. Gasser^g, P. Heutink^h, G. Höglingerⁱ, Z. Jamrozik^j, K. A. Jellinger^k, A. Kazantsev^l, H. Kretschmar^m, A. E. Langⁿ, I. Litvan^o, J. J. Lucas^p, P. L. McGeer^q, S. Melquist^r, W. Oertelⁱ, M. Otto^a, D. Paviour^s, T. Reum^t, A. Saint-Raymond^u, J. C. Steele^v, M. Tolnay^w, H. Tumani^a, J. C. van Swieten^x, M. T. Vanier^y, J.-P. Vonsattel^z, S. Wagner^{aa} and Z. K. Wszolek^{bb*} for the Reisingburg Working Group for Tauopathies With Parkinsonism

^aDepartment of Neurology, University of Ulm, Ulm, Germany; ^bMax Planck Unit for Structural Molecular Biology, c/o DESY, Notkestr., Hamburg, Germany; ^cInstitute for Ageing and Health, Newcastle University, Campus for Ageing and Vitality, Newcastle upon Tyne, UK; ^dCentre Hospitalier de Valenciennes, Résidence du Val d'Escaut, Avenue Desandrouin, Valenciennes, France; ^eUniversity of Michigan Medical Center, 1500 E Medical Center Dr, Ann Arbor, MI, USA; ^fHospital Ramon y Cajal, Neurology, Carretera Colmenar, Madrid, Spain; ^gUniversitätsklinikum Tübingen, Zentrum für Neurologie, Hoppe-Seyler-Strasse, Tübingen, Germany; ^hVU University Medical Center, Department of Clinical Genetics and Anthropogenet, van der Boechorststraat, Amsterdam, the Netherlands; ⁱPhilipps-Universität, Neurologie, Rudolf-Bultmann-Strasse, Marburg, Germany; ^jMedical University of Warsaw, Neurology, Banacha, Warsaw, Poland; ^kInstitute of Clinical Neurobiology, Kenyongasse, Vienna, Austria; ^lMassachusetts General Hospital, MIND/Harvard Medical School, Charlestown, MA, USA; ^mInstitut für Neuropathologie, BrainNet (German Brain Bank), Feodor-Lynen-Strasse, Munich, Germany; ⁿToronto Western Hospital, Movement Disorders Center, Toronto, ON, Canada; ^oUniversity of Louisville, School of Medicine/Department of Neurology, Louisville, KY, USA; ^pCentro de Biología Molecular "Severo Ochoa," Universidad Autónoma de Madrid and CiberNed, Cantoblanco, Madrid, Spain; ^qUniversity of British Columbia, Kinsmen Laboratory of Neurological Research, Vancouver, BC, Canada; ^rMayo Clinic, Department of Neuroscience, Jacksonville, FL, USA; ^sNational Hospital for Neurology, Dementia Research Centre, London, England; ^tBundesinstitut für Arzneimittel & Medizinprodukte, Wissenschaftlicher Service/Klinische Prüfungen, Georg-Kiesinger-Allee, Bonn, Germany; ^uEuropean Medicines Agency (EMA), Scientific Advice and Orphan Drugs Sector, 7 Westferry Circus, Canary Wharf, London, England; ^vGuam Memorial Hospital, Neurology, Carlos Camacho Way, Tamuning, Guam; ^wInstitut für Pathologie, Schönbeinstrasse, Basel, Switzerland; ^xUniversity Hospital Rotterdam, Department of Neurology, Erasmus MC, Dr Molewaterplein, GD Rotterdam, the Netherlands; ^yInstitut National de la Santé et de la Recherche Médicale, Unit 820, Laënnec Medical School, Lyon, France; ^zNew York Brain Bank, Columbia University, Pathology, Babies Hospital, New York, NY, USA; ^{aa}Deutsche PSP-Gesellschaft e.V. (PSP Germany), c/o S. Wagner, Könnertstrasse, Leipzig, Germany; and ^{bb}Mayo Clinic, Department of Neurology, Jacksonville, FL, USA

Keywords:

corticobasal degeneration, frontotemporal dementia with parkinsonism linked to chromosome 17, microtubule-associated protein tau, multiple system atrophy, Parkinson disease, parkinsonism, progressive supranuclear palsy, tauopathies

Tauopathies with parkinsonism represent a spectrum of disease entities unified by the pathologic accumulation of hyperphosphorylated tau protein fragments within the central nervous system. These pathologic characteristics suggest shared pathogenetic pathways and possible molecular targets for disease-modifying therapeutic interventions. Natural history studies, for instance, in progressive supranuclear palsy, frontotemporal dementia with parkinsonism linked to chromosome 17, corticobasal degeneration, and Niemann-Pick disease type C as well as in amyotrophic lateral sclerosis/Parkinson–dementia complex permit clinical characterization of the disease phenotypes and are crucial to the development and validation of biological markers for differential diagnostics and disease monitoring, for example, by use of neuroimaging or proteomic approaches. The wide pathologic and clinical spectrum of the tauopathies with parkinsonism is reviewed in this article, and perspectives on future advances in the understanding of the pathogenesis are given, together with potential therapeutic strategies.

Received 29 September 2008

Accepted 28 November 2008

Correspondence: Prof Dr Albert C. Ludolph, Department of Neurology, University of Ulm, Oberer Eselsberg 45, 89081 Ulm, Germany (tel.: +49 731 1771200; fax: +49 731 1771202; e-mail: albert.ludolph@rku.de.)

*These authors contributed equally to the work.

Introduction

The term *tauopathies* refers generally to neurodegenerative diseases with prominent tau pathology in the CNS, predominantly within the neuronal compartment, but also within glial cells. Tau is an abundant micro-

tubule-associated protein, physiologically expressed in neurons. In tauopathies, the soluble tau protein detaches from microtubules and forms abnormal, fibrillar structures of aggregated, hyperphosphorylated, and ubiquitinated tau. The molecular composition of tau aggregates in tauopathies is becoming better understood, resulting in the definition of etiologically heterogeneous, clinically and neuropathologically overlapping disease entities. Some tauopathies are characterized by parkinsonism, which may be partially responsive to levodopa; others are characterized by dementia with signs of frontal lobe dysfunction; still others are characterized by a motor neuron disorder phenotype. Neuropathology and clinical syndromes can be categorized as follows (Table 1):

- predominant tau pathology/prominent parkinsonism;
- predominant tau pathology/variable parkinsonism;
- predominant tau pathology/parkinsonism uncommon;
- tau pathology associated with β -amyloid deposition or
- tau deposition with other pathology.

The increasing number of tauopathies described in distinct geographic regions (Guam, Guadeloupe, New Guinea, and others) add potential causative genetic and environmental factors to the disease spectrum. Postencephalitic parkinsonism (PEP) and dementia pugilistica are examples of tauopathies that reinforce the need to consider viral and traumatic etiologies. Subsuming distinct disease entities under the term *tauopathy* may

be justified simply for practical reasons because the clinical phenotypes are related. In addition, the term may lead to insights into overlapping pathogenetic and etiologic aspects of the discrete diseases, which then may be amenable to disease-modifying treatment strategies.

The debate over combining or separating the disease entities prompted formation of the Reisenburg Working Group for Tauopathies With Parkinsonism. Here, we review the current understanding of these disorders and their pathogenesis and outline strategies that may lead to formation of an international scientific task force to expedite development of novel treatment approaches.

The clinical spectrum of tauopathies

Progressive supranuclear palsy

Progressive supranuclear palsy (PSP; Steele-Richardson-Olszewski syndrome) is a tauopathy with predominant tau pathology and prominent parkinsonism. Although the clinical features are well defined [1], the 'classical' picture may represent only a part of the whole disease spectrum. Subtle signs in the earliest stages of PSP may hamper a confident diagnosis of PSP, and more than 90% of the patients are seen by more than 2 physicians before a diagnosis is made [2]. Moreover, a correct diagnosis is usually made 3.6–4.9 years after the onset of clinical signs, and even the National Institute of Neurological Disorders and Stroke/Society for Progressive Supranuclear Palsy (NINDS/SPSP) criteria detect only 50–75% of patients within 3 years of disease onset [3].

Clinical signs at onset are most frequently impaired mobility, falls, cognitive deficits, and bulbar signs [4]. A number of PSP phenotypic variants have been described recently. These include a more indolent form with a Parkinson disease (PD)-like presentation, including bradykinesia and rigidity, response to levodopa, asymmetric onset, and tremor [5] and a pure akinetic form with gait freezing and an apraxia of speech with delayed or even absent core PSP features. Table 2 details the NINDS/SPSP diagnostic inclusion criteria for PSP.

The neuropathologic features of PSP [6] include predominant midbrain atrophy; to a lesser extent, atrophy of the pallidum, thalamus, and subthalamic nucleus; and mild symmetric frontal atrophy. The histopathology is characterized by neuronal changes (globose and flame-shaped neurofibrillary tangles, neuropil threads) and glial tau pathology (tufted astrocytes, thorn-shaped astrocytes, oligodendrial coiled bodies), which show a distinct topographic distribution [7].

Table 1 The phenotypical spectrum of tauopathies with parkinsonism

Predominant tau pathology/prominent parkinsonism
Progressive supranuclear palsy
Corticobasal degeneration
Postencephalitic parkinsonism (encephalitis lethargica)
Parkinsonism–dementia complex of Guam (Kii, Papua)
Guadeloupean parkinsonism
Miscellaneous cases – 'tangle parkinsonism,' <i>LRRK2</i> mutations
Predominant tau pathology/variable parkinsonism
FTDP-17
Predominant tau pathology/parkinsonism uncommon
Pick disease
Argyrophilic grain disease
Tau pathology associated with amyloid deposition
Dementia pugilistica (prominent parkinsonism)
Alzheimer disease (parkinsonism variable)
Down syndrome
Familial British dementia/familial Danish dementia
Tau deposition with other pathology
Niemann-Pick disease type C
Neurodegeneration with brain iron accumulation type 1
SSPE
Myotonic dystrophy

FTDP-17, frontotemporal dementia with parkinsonism linked to chromosome 17; SSPE, subacute sclerosing panencephalitis.

Table 2 Mandatory inclusion criteria by PSP category (NINDS/SPSP diagnostic inclusion criteria)

PSP category	Mandatory inclusion criteria
Possible (clinically probable)	Gradually progressive disorder, age onset > 40 year <i>Either</i> vertical supranuclear gaze paresis <i>or</i> both slowing of vertical saccades and prominent postural instability with falls in first year No evidence of other diseases that could explain above
Probable (clinically definite)	Gradually progressive disorder, age onset > 40 year Vertical supranuclear palsy <i>and</i> prominent postural instability with falls in first year of disease onset No evidence of other diseases that could explain above
Definite	Clinically probable or possible PSP <i>and</i> histopathologic evidence of typical PSP

NINDS/SPSP, National Institute of Neurological Disorders and Stroke/Society for Progressive Supranuclear Palsy; PSP, progressive supranuclear palsy.

PSP is a predominant 4-repeat tauopathy, and predominant, insoluble 4-repeat tau can also be detected in the white matter.

Corticobasal degeneration

Corticobasal degeneration (CBD), also a predominant 4-repeat tauopathy, is thought to be a rare disease, but its incidence is potentially underestimated because the diagnostic criteria are biased toward the classical syndrome ('parietoperceptuomotor syndrome'). Important neuropathologic features are cortical and nigral atrophy; microscopically there are numerous swollen cortical neurons as well as tau-immunoreactive astrocytic plaques not seen in other tauopathies. Clinical manifestations of CBD include movement disorders (akinesia, rigidity, limb dystonia, focal reflex myoclonus, postural/action tremor, postural instability); cerebral cortical features (cortical sensory loss, apraxia, alien limb, frontal release signs, dementia, dysphasia); and other features (corticospinal tract signs, oculomotor dysfunction, eyelid motor dysfunction, dysarthria, dysphagia). Because the majority of investigations lack neuropathologic confirmation and in at least one-third of the patients with this phenotype the underlying pathology does not correspond to CBD, it has been suggested that this phenotype be considered a spectrum of diseases rather than a defined disease entity [8]. For instance, in neuropathologically studied cases, a 'corticobasal syndrome' was observed in PSP, Pick disease, Alzheimer disease (AD), frontotemporal dementia with

parkinsonism, and frontotemporal lobar degeneration with ubiquitin-positive inclusions. In neuropathologic studies, CBD pathology was found to be associated with several clinical syndromes, e.g. primary progressive aphasia, frontal lobe dementia, dementia/apraxia/parkinsonism, speech apraxia, and Balint syndrome.

Frontotemporal dementia with parkinsonism

In frontotemporal dementia with parkinsonism linked to chromosome 17 (FTDP-17), an increasing number of mutations in the *MAPT* (microtubule-associated protein tau) gene cause a wide spectrum of clinical presentations [9]. Age at onset ranges from the 20s to very old age. Disease duration is 8–10 years with most mutations, but it is much longer with some, particularly the R406W mutation. The clinical phenotype is dominated by dementia of the frontal lobe type (P301L, G272V, and others); of the Alzheimer type (R406W, S320F); or by psychosis, hallucinations, and delusions (V337M). The parkinsonian component ranges from a classical, but not dopa-sensitive syndrome with rigidity, bradykinesia, postural tremor, and resting tremor (N279K, N296H) to a clinical picture resembling PSP (delN296, S305S, N279K) and CBD (P301S). A motor neuron component is unusual in most *MAPT* mutations. The K317M mutation, however, is associated with amyotrophy, fasciculations, and denervation. Intrafamilial variation may exist. Recently, the importance of progranulin mutations was discovered for frontotemporal dementia [10], and in fact, this may now be the commonest cause of familial corticobasal syndrome.

Pick disease

The neuropathology of Pick disease shows circumscribed atrophy of the frontal, frontotemporal, and frontoparietotemporal cortices and of ballooned neurons as well as Pick bodies, i.e. neuronal aggregates of hyperphosphorylated tau. In addition, Pick cells can be found; these are similar to ballooned neurons found in various neurodegenerative diseases.

Niemann-Pick disease type C

Niemann-Pick disease type C is an atypical lysosomal lipid storage disease caused by two different genetic defects affecting cellular transport of unesterified cholesterol and glycosphingolipids [11]. Symptomatic individuals of juvenile or adult age typically present with neurologic or psychiatric signs. The neurologic phenotype includes cerebellar ataxia (76%), vertical supranuclear ophthalmoplegia (75%), and a movement disorder with variable features (58%), as well as

cognitive (61%) and behavioral and affective impairments (45%). Splenomegaly is present in 54% of adult cases. Neuropathologically, apart from neuronal storage, numerous tau-positive tangles and neuropil threads have been observed in midbrain and cerebral cortex. Diagnosis is confirmed by demonstration of lysosomal cholesterol storage in cultured fibroblasts (filipin test) or by genetic analysis. The relationship of the biochemical phenotype to the neuropathologic changes, including tau pathology, has not been clarified. There is no clinical benefit from cholesterol inhibitors in mice or in patients. A clinical trial using miglustat is ongoing.

Postencephalitic parkinsonism

In the first description of PEP, Dr Constantin von Economo presented three syndromes associated with the disease, a somnolent-ophthalmoplegic, a hyperkinetic, and an amyostatic-akinetic variant. Sometimes symptoms occurred years after encephalitis lethargica epidemics. The classical inflammatory lesions in the tegmentum of the midbrain include neuronal loss, gliosis, and tau pathology, but cortical lesions consisting of neuropil threads and neurofibrillary tangles are present as well. Although difficult to differentiate histopathologically [7], differences between PSP and PEP exist at the molecular level. PEP is characterized by straight filaments with a combination of 3-repeat and 4-repeat tau isoforms. PSP is characterized by a predominance of 4-repeat tau aggregates.

Geographically distinct tauopathies

Tauopathies in distinct geographic areas [12,13] include the amyotrophic lateral sclerosis (ALS)/Parkinson-dementia complex (PDC) of Guam, New Guinea, and the Kii peninsula of Japan, which shows striking neuropathologic similarities with PSP and PEP. For several centuries, ALS/PDC has occurred in the indigenous families of these three locales, but recently, the incidence and prevalence rates have dramatically declined. The primary etiologic factors are still unknown. A unique linear retinal pigment epitheliopathy (LRPE) is present in 50% of patients with ALS/PDC, but in only 15% of the asymptomatic Chamorro people of the Mariana Islands. Of 17 patients who had a diagnosis of this retinopathy in the early 1980s, 11 (65%) developed ALS/PDC, three died of other causes, and three are still alive with no evidence of neurodegenerative disease. LRPE is seen also in the Kii peninsula. The role of this unique retinopathy, which may mark the etiologic event of ALS/PDC, is not yet identified.

A recurring hypothesis as to causation of the Guam disease is exposure to *fadang*, the local name given to the false sago palm, *Cycas micronesica*. However, attempts to verify the necessary toxicity through controlled experiments have failed, rendering the hypothesis untenable [14].

Another model disease of great interest is atypical parkinsonism in the French West Indies [15]. Some of the patients on the islands of Guadeloupe and Martinique show overlap with PSP (probable PSP, 22%), but the majority have unclassified non-dopa-responsive parkinsonism (38%) and probable PD (25%). The unclassifiable syndrome does not show fluctuations, hallucinations, and ophthalmoplegia and is seen only in Afro-Caribbeans, mixed race, and Indian populations. Autopsies in two cases revealed a synucleinopathy with typical Lewy bodies in the substantia nigra [16]. Tau deposits were sparse in the unclassifiable syndrome but typical in the PSP-like cases. Potential etiologic factors, in particular the consumption of plants from the Annonaceae family, are still under discussion. These plants are of particular interest because they contain mitochondrial toxins such as isoquinolines, berberines, and acetogenins, which cause neurodegeneration in cell and animal models [17,18].

Genetics

The discovery in 1998 that mutations in the *tau* gene are a cause of hereditary forms of FTDP-17 [19,20] showed that tau depositions as neurofibrillary tangles may link directly to mutations in the *tau* gene. These mutations might affect microtubule binding and assembly or might cause increased self-aggregation or affect alternative splicing of exon 10. Studies of gene expression patterns showed that those in tauopathies differ from those in normal-aged controls, AD patients, and patients with PSP and that the pattern in patients with frontotemporal dementia and Pick disease may represent a distinct group. Further studies will address the temporal and spatial development of these alterations in humans but also transgenic mouse models.

Several families with a progressive PSP-like phenotype have been described [21]. *MAPT* and *PARK2* mutations may cause a PSP-like picture. An additional locus on chromosome 1q31.1 was described in a large family from Extremadura, Spain; the mutation and the respective gene are not yet identified.

Mutations in the *LRRK2* gene cause a familial, autosomal dominant parkinsonism. Phenotypically, *LRRK2* mutations may present as a PSP-like parkinsonism as well as typical idiopathic PD. Interestingly, PSP-like clinical presentations correspond neuropathologically to a tauopathy, whereas most PD-like

presentations have an alpha-synucleinopathy as their pathologic substrate [22]. PSP-like pathology due to a *LRRK2* mutation appears to be a relatively rare cause of PSP; screening of PSP brain bank cases for the L1441C and G2019S mutations was negative. However, antibodies to the *LRRK2* protein (NB 300-268) label Lewy bodies in PD and a subset of neurofibrillary tangles in AD and PDC of Guam [23].

The *MAPT* H1 haplotype of tau is the only consistently confirmed genetic risk locus for PSP [24]. Examination of H1 haplotype-specific single nucleotide polymorphism can account for only a portion of the overall H1 haplotype association, suggesting that the H2 haplotype plays a protective role. A pooled genome-wide association study has identified an additional risk locus for PSP on chromosome 11p11-12 which contains the genes *DDB2* and *ACP2* [25]. Further characterization of this locus and additional genome-wide association studies are under way. Previously, genetic association for the polymorphism Val380Leu in sporadic and familial PSP has been reported [26].

There are two classes of *MAPT* mutations: (i) mutations that alter the tau protein sequences and thus might affect tau binding to microtubules and tau aggregation, and (ii) mutations that are silent on the protein level but alter alternative splicing of exon 10, leading mostly to excess 4-repeat tau. If excess 4-repeat tau is present, tangles are predominantly 4-repeat tau, and a glial pathology is observed. In brain, expression of the six major tau isoforms is affected mainly by alternative splicing of exons 2, 3, and 10. Phenotype is influenced by the cellular expression pattern of different *MAPT* mutations; for example, the V337M mutation leads to neurofibrillary tangles in the cortex whilst sparing the hippocampus. In contrast, the Q336R mutation preferentially affects hippocampal structures. Splicing regulation can be influenced by differential expression or phosphorylation of splicing factors, which again leads to different mutation-induced phenotypes. In PSP, the reason that 4-repeat tau is increased in specific cells is unknown – for example, whether a specific mechanism causes only 4-repeat tau to aggregate or whether a specific mechanism may exist that affects only cells that produce excess 4-repeat tau needs to be determined. Key pathophysiologic mechanisms underlying various tauopathies are presented in Fig. 1 and summarized in Table 3.

Biomarkers

Imaging techniques have the potential to serve as longitudinal biomarkers in tauopathies with parkinsonism. In the neuroradiologic part of the European Neuroprotection and Natural History in Parkinson Plus

Syndromes trial (NNIPPS), MRI evaluation was done in 632 patients (434 for multiple system atrophy, 298 for PSP) with internationally validated semiquantitative scales by two blinded reading centers. If discrepancies existed, a consensus reading was performed in each case. In PSP patients, midbrain atrophy, enlargement of the aqueduct of Sylvius, an increased interpeduncular angle, and punctate upper mesencephalic hyperintensities were particularly pronounced. A significant correlation between oculomotor signs and midbrain atrophy as well as punctate upper mesencephalic hyperintensities was observed. The longitudinal data obtained in the NNIPPS study is yet to be analyzed.

There have been first results obtained in a longitudinal MRI study in PSP ($n = 17$) and in the parkinsonian variant of multiple system atrophy (MSA-P) ($n = 9$) [27]. Because cross-sectional imaging can only suggest that change has occurred, quantitative serial assessments are mandatory. If this approach is used, PSP, MSA-P, and control brains could be reliably distinguished by the measurement of annual atrophy rates (percentage per year). For example, the rate of midbrain atrophy in PSP is seven times that in healthy controls, whereas the pontine atrophy rate in MSA-P is 20 times that in healthy controls. In PSP, a worsening of motor deficits was associated with greater rates of midbrain atrophy. Increased rates of frontal atrophy in PSP were associated with decreasing executive ('frontal') function. If power calculations for clinical trials are performed, the use of regional rather than whole brain atrophy rates serves as a practical and powerful tool to reflect the progressive course of the disease and its potential modification [28].

The use of PET in patients with tauopathies may improve diagnostic confidence. The fluorodeoxyglucose (FDG) metabolic pattern of PSP involves the medial frontal cortex and the midbrain, a pattern that is not observed in idiopathic PD, MSA-P, or CBD [29]. FDG PET can also be used to detect functional deficits in asymptomatic carriers of familial PSP genes [30]. In the future, progress can be expected with the use of markers that bind to hyperphosphorylated tau, in particular quinoline and benzimidazole derivatives.

Conflicting results have been published on CSF findings in atypical parkinsonian diseases. Well-established nonspecific markers for neurodegenerative diseases such as the levels of total tau protein, phospho-tau protein, and β -amyloid peptide appear to be of limited value [31]. However, some reports describe higher levels of total tau protein in individual patients with CBD and PSP, whereas phospho-tau protein was always within normal range in patients with PSP. Increased levels of neurofilament light chain were described in patients with PSP and the cerebellar variant

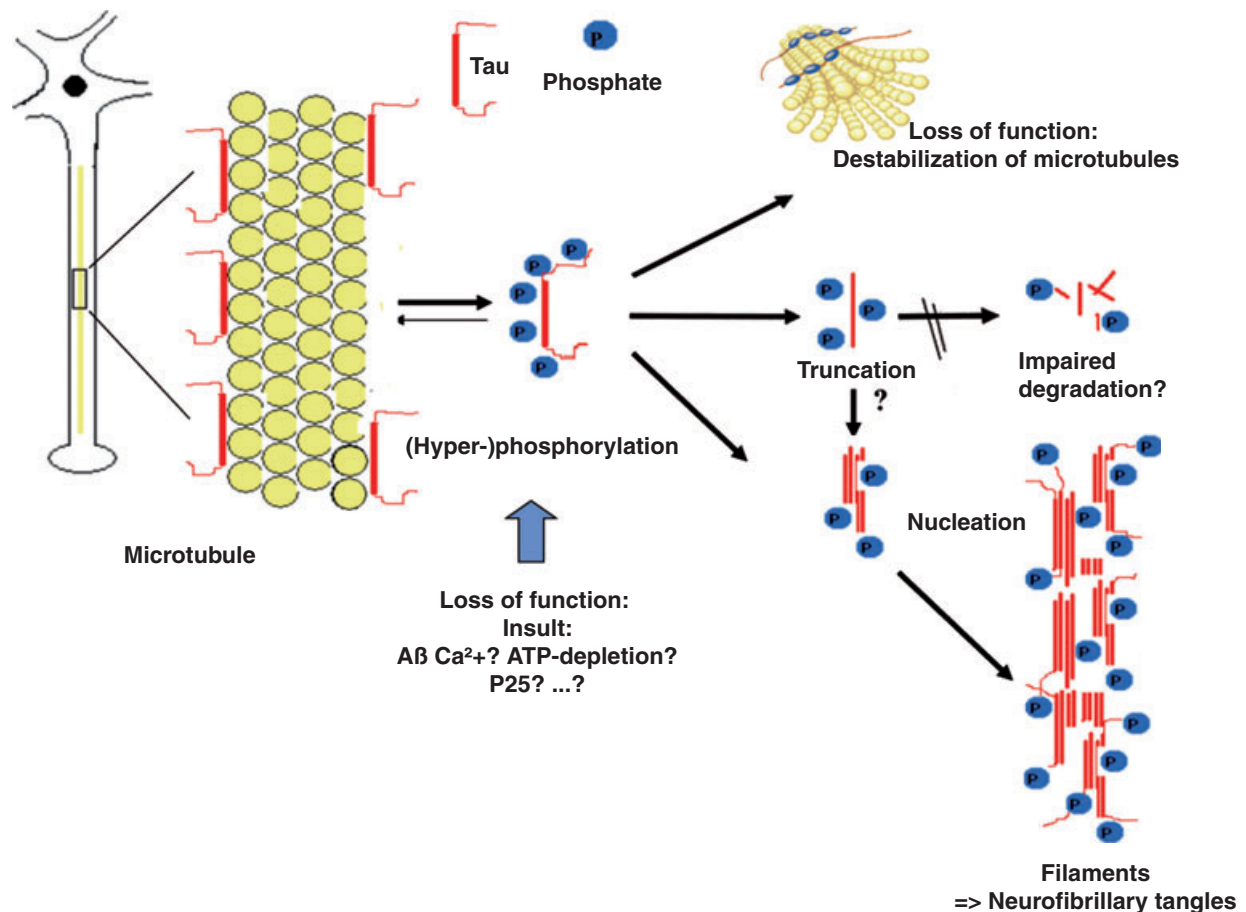


Figure 1 Sketch of the putative pathophysiology underlying tauopathies of various etiologies. The physiologic role of tau as a stabilizer of neuronal microtubules by binding to microtubules can be disrupted through a multitude of insults (raised intracellular calcium levels, energy depletion, $A\beta$, etc), resulting in a hyperphosphorylation of tau at specific sites. Hyperphosphorylation of tau leads to altered binding of tau to neuronal microtubules, causing a destabilization of microtubule dynamics, such as the disintegration of microtubules, resulting in a disruption of microtubule-motor protein (dynactin–dynein complex, kinesin complex) interactions. This dysfunction of cytoskeletal properties may lead to a misdistribution of microtubule-associated cell components, e.g. mitochondria. In addition, tau fragments generated through proteolytic processes result in presumably toxic truncated tau species, e.g. displaying a reduced degradability. Finally, tau proteins or fragments of tau detached from microtubules may form filamentous aggregates (neurofibrillary tangles) through various intermediate conformations and a seeding process (nucleation).

of multiple system atrophy, whereas levels of neurofilament light chains were within the normal range in patients with PD, CBD, and MSA-P [32]. Similar findings were observed by others, although high levels of neurofilament light chain were also described in patients with MSA-P. Further neurochemical research, including proteomic approaches, must address exact clinical characteristics and the stage of the disease to determine whether a biomarker might be useful in the early diagnosis or differential diagnosis.

Pathogenesis and treatment

Glycogen synthase kinase-3 (GSK-3) may play an important role in the pathogenesis of tauopathies and

may represent a therapeutic target. This serine/threonine kinase exists in 2 isoforms (alpha and beta) encoded by 2 different genes, is most abundant in CNS in adults, and participates in many signaling cascades, including insulin/insulinlike growth factor 1 and Wnt signaling pathways. Increased GSK-3 activity may play a role in tauopathies because it can phosphorylate tau *in vivo* in most sites that are found hyperphosphorylated in AD-tau [33], but it also accumulates in pre-tangles [34,35] and interacts with presenilin 1, which may result in increased activity of the enzyme. To study the consequences of sustained increased GSK-3 activity in adult tissues and to explore the therapeutic potential of GSK-3 inhibition, conditional transgenic mice that overexpress either wild-type GSK-3 or a dominant-

Table 3 Possible mechanisms of tau toxicity in neurons

Background: Known modes of function of tau:

1. Binding and stabilization of neuronal microtubules, regulated by
 - Alternative splicing
 - Phosphorylation
2. Anchoring protein for microtubule-associated cell components, e.g.
 - Kinases (GSK-3b, MAP kinase, MARK)
 - Phosphatases (PP-1, PP-2a)
 - Scaffold proteins (14-3-3)
 - Chaperones (hsp70, Pin-1)
 - Motor proteins (dynactin-dynein complex, kinesin complex)

Hence, toxic functions of tau could arise from

- Altered binding to microtubules (over- or understabilization affecting microtubule dynamics), due to changes in expression (e.g. haplotype H1c), alternative splicing (as in FTDP-17 mutations), phosphorylation (e.g. altered signal transduction, with subsequent changes in microtubule binding), or changes in microtubule affinity (as in some FTDP-17 mutations)
- Altered distribution of other microtubule-associated cell components
- Changes in microtubule-motor interactions

Further toxic functions of tau could arise from

- Inhibition of axonal traffic by excess tau bound to microtubule surface
- Aggregation of tau after detachment from microtubules (neurofibrillary tangles)
- Toxicity of tau fragments generated by proteolysis (by unknown mechanisms)

FTDP-17, frontotemporal dementia with parkinsonism linked to chromosome 17; GSK-3b, glycogen synthase kinase-3b; hsp, heat shock protein; MAP, microtubule-associate protein; MARK, microtubule affinity regulating kinase; Pin, peptidyl prolyl *cis-trans* isomerase; PP, phosphatase.

negative form of the kinase have been generated. Mice with neuronal overexpression of wild-type GSK-3 show electrophysiologic abnormalities, histopathologic alterations (increased tau phosphorylation and neuronal loss without tau filament formation) [36], and impaired spatial recognition [37], consistent with the notion of increased GSK-3 activity participating in the etiology of AD and other tauopathies. Interestingly, the AD-like phenotype of Tet/GSK-3 mice fully reverts after restoration of normal GSK-3 activity in these conditional transgenic mice [38], thus supporting the therapeutic potential of GSK-3 inhibitors. Besides, low-dose treatment with lithium (a GSK-3 inhibitor) convincingly prevents neuropathologic changes in mice with increased GSK-3 activity that also express FTDP-17 [39]. However, GSK-3 knock-out mice die of liver failure in early embryonic development. Therefore, complete and early downregulation of GSK-3 might not be a useful approach. Regulatable Tet/DN-GSK-3 mice were developed to explore the efficacy and adverse effects of GSK-3 inhibition. Mice with decreased GSK-3 activity as a consequence of DN-GSK-3 expression showed increased incidence of neuronal apoptosis in brain

regions involved in motor control such as striatum and cortex and concomitant deficit in motor coordination, thus warning of potential neurologic toxicity of GSK-3 pharmacologic inhibition beyond physiologic levels. Interestingly, the reversibility analysis in these mice also suggests that adverse effects are likely to subside if excessive GSK-3 inhibition is halted. Further analysis of these mice combined with transgenic models of tauopathies is expected to shed light on the therapeutic potential of pharmacologic GSK-3 inhibition in tauopathies.

The emphasis on kinases to explain the hyperphosphorylation of tau is a popular approach but may not be firmly supported by basic science data. Upregulation and downregulation of kinases in cells or mice yield contradictory results. GSK-3 β has many targets, and inhibitors such as lithium have many targets as well. Moreover, hyperphosphorylation of tau (and other proteins) can be achieved simply by a slight drop in body temperature that shifts the balance of kinase and phosphatase activity [40].

Mitochondrial dysfunction is thought to play an important role in the development of tau pathology. The Guadeloupe disease may serve as a good model for sporadic PSP [15]. The consumption of Annonaceae plants is an identified risk factor for the disease. The toxic principle of Annonaceae plants may be mitochondrial toxins, such as isoquinolinic alkaloids and acetogenins. It has been shown *in vitro* that Annonaceae plants are toxic for dopaminergic neurons [41] by potent inhibition of complex I [42]. After systemic administration, the compound enters the brain of experimental rodents and selectively destroys striatal and nigral neurons [43]. Similar effects can be shown by the systemic administration of the complex I inhibitor rotenone, a compound used, amongst other things, for eradicating unwanted fish in the tropics [44]. In addition, an accumulation of hyperphosphorylated tau and the tau accumulation in neuronal and glial cells were observed [45]. Because this observation is complementary to evidence of mitochondrial dysfunction in PSP [46], two pilot trials, one with coenzyme Q10 and another with creatine, pyruvate, and niacinamide, in PSP have been proposed.

Chronic inflammation may play a major role in the pathogenesis of tauopathies; inflammation may drive the disease process through self-attack on viable tissue. McGeer and McGeer [47] introduced the term *autotoxic diseases* (to be distinguished from *autoimmune diseases*) and considered tauopathy a typical example of autotoxic disease. Activated microglia mediate such toxicity by producing harmful concentrations of free radicals, glutamate, cytokines, complement proteins, and prostaglandins. Retrospective studies [48,49] have reported

findings consistent with the concept that nonsteroidal antiinflammatories may have disease-modifying potential.

Based on our current understanding of the pathophysiology and pathobiochemistry of tauopathies, the pharmacologic modification of tau hyperphosphorylation, tau conformation, tau fragmentation, and tau aggregation may be considered as potential therapeutic targets in tauopathies. Since tau hyperphosphorylation leads to destabilization of microtubules ('loss of function'), stabilizing drugs (for example, paclitaxel) have been used in tauopathy models and were shown to be effective in preventing A β -induced neurodegeneration and even to reverse fast axonal transport deficits [50]. Tau hyperphosphorylation is a putative gain of the functional mechanism by which paired helical filaments are formed. To influence this potentially toxic mechanism, tau kinase inhibition may be the pharmacologic target to modify the disease process, as stated above regarding GSK-3. However, understanding the redundancy and the sequential activation of kinases may be necessary before these compounds can be tested. It has been shown recently that a small molecular inhibitor of kinases has a beneficial effect in the P301L mouse model [51], showing that this concept can be proven in principle. Most interesting for potential human trials is the demonstration that lithium as well as specific GSK-3 β inhibitors blocks tau pathology [39,52]. Activation of tau phosphatase as a therapeutic mechanism, however, may have competing effects and requires better understanding. Another therapeutic path may be use of the prolyl isomerase Pin1 to restore the function of tau by altering its conformation. An understanding of the normal function of Pin1 is only beginning; deletion of the gene encoding Pin1 leads to a neurologic phenotype with tau hyperphosphorylation, tau filament formation, and neuronal degeneration [53]. Inhibition of tau proteolysis may prevent neurotoxicity [54] and tau aggregation [55]. Caspases and other cytosolic proteases are suspected of being involved in the proteolytic processing of tau. Finally, tau aggregation is accelerated by the presence of polyanions (e.g. RNA, acidic peptides, or fatty acid micelles). Several classes of compounds were shown to inhibit tau aggregation, such as anthraquinones, phenothiazines, benzothiazoles, and polyphenols [56]. Such compounds are able to relieve the aggregation-dependent toxicity of tau in cell models. An immunotherapeutic approach to brain diseases with aggregating proteins has shown promise [57], although opposite experiences have also been reported [58]. Table 4 includes information on different therapeutic targets that may be used in drug development and treatment.

The path of drug discovery leads from target validation to *in vitro* assay development (yeast, cell

Table 4 Possible therapeutic targets in tauopathies

1. Tau hyperphosphorylation
Inhibition of tau kinases
Activation of tau phosphatases
2. Tau conformation
3. Tau fragmentation
4. Tau aggregation
Cytoskeletal dysfunction (axonal/dendritic)
Neuroinflammation

cultures), compound library design, and screening to *in vivo* experimental trials for efficacy and toxicity (*Drosophila melanogaster* and rodents), and finally from transgenic animal models to human applications. A synopsis of transgenic models is presented in Table 5.

Methods for comprehensive clinical assessment of PSP are highly relevant, with a special focus on end-points for therapeutic interventions, i.e. existing scales like the Unified Parkinson Disease Rating Scale Part III, Addenbrook's Cognitive Examination, and newly devised disease-specific scales such as the Golbe PSP scale [82] and future 'composite' scales such as the NNIPPS scale. Functional milestones such as falls, dysphagia, and percutaneous endoscopic gastrostomy insertion may serve as end-points and are all consistently related to survival [4]. For the purpose of a therapeutic trial, it was postulated that:

- a large geographic area or a multicenter trial is required;
- early modification of the disease will be difficult because nonspecific features would create noise; and
- hard end-points may be death or functional measures such as motor milestones.

In a systematic PubMed search, van Balken and Litvan [83] found 96 reports on clinical trials describing 842 PSP patients. Taken together, the results were generally disappointing; only mild and transient benefits were reported in studies with multiple methodologic problems. van Balken and Litvan pointed out that future trials should have more rigorous methods, should be randomized, double-blind, and placebo-controlled, and should use only validated outcome measures. It is hoped that experimental trials in tau animal models will accelerate research in humans.

Given the variability of the clinical picture and the low prevalence of tauopathies, knowledge on the spectrum of the diseases must include rare disease forms and their early clinical differentiation (CBD, PSP-parkinsonism, and other rare forms dominated by apraxias or frontal dementias). The importance of performing autopsies on as many cases as possible cannot be overemphasized. Current clinical criteria are imperfect, and they are complicated by the frequency of overlapping pathologies. Most importantly, the causation of

Table 5 Synopsis of transgenic models for tauopathies

Tg Name	Species	Tau isoform	Mutation(s)	Promoter
JNPL3 [59]	<i>Mus musculus</i>	h4R0N	P301L	mPrP
rTg4510 [60]	<i>M. musculus</i>	h4R0N	P301L	CamKII-driven Tta/TetO ^a
htau [61]	<i>M. musculus</i>	All 6 human isoforms ^b	None	hMAPT
Tg lines 7, 43 [62]	<i>M. musculus</i>	h3R0N	None	mPrP
pR5 [63]	<i>M. musculus</i>	h4R2N	P301L	mThy1.2
ALZ7 [64]	<i>M. musculus</i>	h4R2N	None	hThy1
ALZ17 [65]	<i>M. musculus</i>	h4R2N	None	mThy1.2
Tg214 [66]	<i>M. musculus</i>	h4R2N	V337M	PDGF
R406W [67]	<i>M. musculus</i>	h4R2N	R406W	CamKII
T-279 [68]	<i>M. musculus</i>	h4R2N ^c	N279K	MAPT
Tau (P301S) [69]	<i>M. musculus</i>	h4R0N	P301S	mThy1.2
PS19 [70]	<i>M. musculus</i>	h4R1N	P301S	mPrP
Tau4R2N [71,72]	<i>M. musculus</i>	h4R2N	None	mThy1.2
GFAP/tau Tg [72]	<i>M. musculus</i>	h4R1N	None	GFAP
K3 [73]	<i>M. musculus</i>	h4R0N	K369I	mThy1.2
nWT Tg [74]	<i>M. musculus</i>	h4R1N	None	CNP
PL Tg [74]	<i>M. musculus</i>	h4R1N	P301L	CNP
Tau RD mice [75]	<i>M. musculus</i>	h4R ^d	deltaK280	CamKII-driven Tta/TetO ^a
Tau RD mice [75]	<i>M. musculus</i>	h4R ^d	deltaK280 + I277P + I308P	CamKII-driven Tta/TetO ^a
3 × Tg-AD [76]	<i>M. musculus</i>	h4R0N	P301L ^c	mThy1.2
Tg30 [77]	<i>M. musculus</i>	h4R1N	P301S + G272V	Thy1
gl-Tau ^{wt} [78]	<i>Drosophila melanogaster</i>	h4R0N	None	G1
(UAS)Tau ^{wt} [79]	<i>D. melanogaster</i>	h4R0N	None	UAS ^f
(UAS)Tau ^{R406W} [79]	<i>D. melanogaster</i>	h4R0N	R406W	UAS ^f
(UAS)Tau ^{V337M} [79]	<i>D. melanogaster</i>	h4R0N	V337M	UAS ^f
N-1 [80]	<i>Caenorhabditis elegans</i>	h4R1N	None	aex-3
T301 ^L [80]	<i>C. elegans</i>	h4R1N	P301L	aex-3
T337 ^M [80]	<i>C. elegans</i>	h4R1N	V337M	aex-3
Tg(eno2:Tau) ^{P1406} [81]	<i>Danio rerio</i>	h4R0N	None	eno2

^aInducible Tet-OFF system.^bCreated on MAPT (-/-) background.^cTau mini-gene construct.^dOnly contain microtubule repeat domain (aa 244–372).^eAlso contains mutated hPSEN1 (M146V) and hAPP (swe) genes.^fPan neuronal (elav-GAL4) or cholinergic specific (cha-GAL4) expression.

the syndromes described remains unknown, and only through further studies of diseased tissue can definitive answers be obtained. In addition, a database must be developed that reliably reflects the natural history of the diseases. The NNIPPS study is a natural history study that is attempting to establish such a database using early diagnostic criteria. An indirect excitotoxic pathway resulting from mitochondrial failure has been proposed to be a part of pathogenesis of cell damage in PSP [15,16]. Therefore, the NNIPPS investigators used the putative glutamate release blocker riluzole as a disease-modifying agent in PSP, but the therapeutic study failed to show a beneficial effect of the drug. However, the 3-year longitudinal assessment of the

clinical phenotype in 767 patients with MSA or PSP will presumably be a way to identify more neuroprotective compounds in the future. The NNIPPS study has shown that these early inclusion criteria are predictive for neuropathologic classification. In addition, the natural history data will enable precise power calculations for functional measures and the end-point, survival. The need for further studies of symptomatic treatment approaches to PSP, in particular for the treatment and prevention of falls, dysphagia, and sepsis, is also important [2].

To test the clinical efficacy of potential disease-modifying compounds, a network of investigators interested in these 'orphan' diseases has the potential

to expedite identification of novel therapies. Such a network may be particularly relevant for disorders affecting patients dispersed over large geographic areas. Investigator-initiated networks facilitate the development and harmonization of assessment tools and should provide data-capture systems for affordable human trials in these rare diseases. To achieve this goal of conducting human trials, clinicians and basic scientists as well as patient organizations should collaborate. The aims of the lay organizations are 2-fold: first, they want to be an interface between researchers and patients, and second, they attempt to provide patients insight into daily life problems and current scientific views of the disease.

In Europe, the Committee for Orphan Medicinal Products of the European Medicines Agency is responsible for opinions on orphan designation, provides incentives for the development of medicines for rare diseases, advises the European commission on orphan policy, and seeks international cooperation for rare diseases. European criteria for orphan designation include rarity (≤ 5 affected of 10 000 population), seriousness of the condition (life-threatening or disabling), and the lack of satisfactory methods of treatment. Up to February 2008, 783 orphan applications had been submitted to the European Medicines Agency; 541 were positive, amongst which 365 (67%) were based on significant benefit and 80% of those were based on potential improved efficacy.

Summary and future perspectives

In general, the participants of the Reisenburg Working Group for Tauopathies With Parkinsonism felt strongly that the time has come to introduce disease-modifying therapeutic strategies into the field of tauopathies with parkinsonism. However, it was clear that many hurdles must be overcome until cost-effective therapeutic trials can be efficiently organized and eventually result in generally accepted therapies.

Importantly, the NNIPPS data have shown that early diagnosis and differential diagnosis of atypical parkinsonism are possible, and longitudinal data obtained in the trial can be used for designing future trials. It was felt that the transgenic mice developed on the basis of mutations in the *MAPT* gene can serve as models in which experimental therapeutic development occurs. However, the step from murine research to human research is not easy; the first methodologic step would be the standardization and validation of mouse studies [84]. If these experimental treatments can be developed, the question remains open whether these therapies can influence only 1 phenotype ('pattern of

vulnerability') or can be used in a broader sense ('etiology based') in tauopathies with parkinsonism with different phenotypes.

A complicating factor may be overlapping etiologies for tauopathies; tauopathies may be the result of environmental influences (e.g. PEP), an interplay between genetic factors and environment (e.g. Guam disease), or exclusively genetic (e.g. FTDP-17). However, even in the latter – given the variability of phenotypes – modifying factors, either genetic or environmental, play a role. Certainly, the step from murine to human research can occur more easily if disease-relevant biomarkers are established. Whether MRI techniques can serve this translational step is unproven; theoretically, biochemical markers should do better if the pathogenetic hypothesis is strong.

The most attractive potential therapeutic targets are neuroinflammation accompanying tauopathies, prevention of tau aggregation and tau hyperphosphorylation, stabilization of microtubules, and tau dephosphorylation. Interestingly, a number of drugs (such as lithium, valproic acid, and memantine) with well-known profiles of adverse effects can target these pathogenetic steps. Identification of disease-modifying strategies for tauopathies with parkinsonism is imperative and will be realized, although we cannot tell now how long this development will require.

Acknowledgements

Dr Wszolek is supported by research grant P50-NS40256 from the Morris K. Udall Center of Excellence in Parkinson's Disease Research and by research grant C06-01 from the Pacific Alzheimer Research Foundation (PARF).

This paper is dedicated to the 80th birthday of Patrick McGeer, whose critical thinking, knowledge, enthusiasm, and humor greatly influenced us.

Dr Wszolek has a financial interest associated with technology entitled 'Identification of Mutations in PARK8, a Locus for Familial Parkinson's Disease,' Mayo Clinic case #2004-185. A nonprovisional patent application has been filed for this technology, and it has been licensed to a third party. No royalties have accrued to Dr Wszolek; however, Mayo Clinic has received royalties of greater than \$10,000, the federal threshold for significant financial interest, and Dr Wszolek has contractual rights to receive future royalties.

Disclosure

The authors report no conflict of interest except as described in the acknowledgment.

References

- Litvan I, Agid Y, Calne D, *et al.* Clinical research criteria for the diagnosis of progressive supranuclear palsy (Steele-Richardson-Olszewski syndrome): report of the NINDS-SPSP international workshop. *Neurology* 1996; **47**: 1–9.
- Santacruz P, Uttl B, Litvan I, Grafman J. Progressive supranuclear palsy: a survey of the disease course. *Neurology* 1998; **50**: 1637–1647.
- Lopez OL, Litvan I, Catt KE, *et al.* Accuracy of four clinical diagnostic criteria for the diagnosis of neurodegenerative dementias. *Neurology* 1999; **53**: 1292–1299.
- Nath U, Ben-Shlomo Y, Thomson RG, Lees AJ, Burn DJ. Clinical features and natural history of progressive supranuclear palsy: a clinical cohort study. *Neurology* 2003; **60**: 910–916.
- Williams DR, de Silva R, Paviour DC, *et al.* Characteristics of two distinct clinical phenotypes in pathologically proven progressive supranuclear palsy: Richardson's syndrome and PSP-parkinsonism. *Brain* 2005; **128**(Pt 6): 1247–1258.
- Steele JC, Richardson JC, Olszewski J. Progressive supranuclear palsy: a heterogeneous degeneration involving the brain stem, basal ganglia and cerebellum with vertical gaze and pseudobulbar palsy, nuchal dystonia and dementia. *Archives of Neurology* 1964; **10**: 333–359.
- Litvan I, Hauw JJ, Bartko JJ, *et al.* Validity and reliability of the preliminary NINDS neuropathologic criteria for progressive supranuclear palsy and related disorders. *Journal of Neuropathology and Experimental Neurology* 1996; **55**: 97–105.
- Boeve BF, Lang AE, Litvan I. Corticobasal degeneration and its relationship to progressive supranuclear palsy and frontotemporal dementia. *Annals of Neurology* 2003; **54**(Suppl 5): S15–S19.
- van Swieten J, Spillantini MG. Hereditary frontotemporal dementia caused by Tau gene mutations. *Brain Pathology* 2007; **17**: 63–73.
- Baker M, Mackenzie IR, Pickering-Brown SM, *et al.* Mutations in progranulin cause tau-negative frontotemporal dementia linked to chromosome 17. *Nature* 2006; **442**: 916–919.
- Vanier MT, Millat G. Niemann-Pick disease type C. *Clinical Genetics* 2003; **64**: 269–281.
- Steele JC. Parkinsonism-dementia complex of Guam. *Movement Disorders* 2005; **20**(Suppl 12): S99–S107.
- Caparros-Lefebvre D, Steele J, Kotake Y, Ohta S. Geographic isolates of atypical Parkinsonism and tauopathy in the tropics: possible synergy of neurotoxins. *Movement Disorders* 2006; **21**: 1769–1771.
- Steele JC, McGeer PL. The ALS/PDC syndrome of Guam and the cycad hypothesis. *Neurology* 2008; **70**: 1984–1990.
- Caparros-Lefebvre D, Elbaz A, Caribbean Parkinsonism Study Group. Possible relation of atypical parkinsonism in the French West Indies with consumption of tropical plants: a case-control study. *Lancet* 1999; **354**: 281–286.
- Caparros-Lefebvre D, Sergeant N, Lees A, *et al.* Guadeloupean parkinsonism: a cluster of progressive supranuclear palsy-like tauopathy. *Brain* 2002; **125**(Pt 4): 801–811.
- Lannuzel A, Hoglinger GU, Verhaeghe S, *et al.* Atypical parkinsonism in Guadeloupe: a common risk factor for two closely related phenotypes? *Brain* 2007; **130**(Pt 3): 816–827.
- Escobar-Khondiker M, Hollerhage M, Muriel MP, *et al.* Annonacin, a natural mitochondrial complex I inhibitor, causes tau pathology in cultured neurons. *Journal of Neuroscience* 2007; **27**: 7827–7837.
- Hutton M, Lendon CL, Rizzu P, *et al.* Association of missense and 5'-splice-site mutations in tau with the inherited dementia FTDP-17. *Nature* 1998; **393**: 702–705.
- Spillantini MG, Murrell JR, Goedert M, Farlow MR, Klug A, Ghetti B. Mutation in the tau gene in familial multiple system tauopathy with presenile dementia. *Proceedings of the National Academy of Sciences of the United States of America* 1998; **95**: 7737–7741.
- de Yebenes JG, Sarasa JL, Daniel SE, Lees AJ. Familial progressive supranuclear palsy: description of a pedigree and review of the literature. *Brain* 1995; **118**(Pt 5): 1095–1103.
- Wszolek ZK, Pfeiffer RF, Tsuboi Y, *et al.* Autosomal dominant parkinsonism associated with variable synuclein and tau pathology. *Neurology* 2004; **62**: 1619–1622.
- Miklossy J, Arai T, Guo JP, *et al.* LRRK2 expression in normal and pathologic human brain and in human cell lines. *Journal of Neuropathology and Experimental Neurology* 2006; **65**: 953–963.
- Baker M, Litvan I, Houlden H, *et al.* Association of an extended haplotype in the tau gene with progressive supranuclear palsy. *Human Molecular Genetics* 1999; **8**: 711–715.
- Melquist S, Craig DW, Huentelman MJ, *et al.* Identification of a novel risk locus for progressive supranuclear palsy by a pooled genomewide scan of 500,288 single-nucleotide polymorphisms. *American Journal of Human Genetics* 2007; **80**: 769–778.
- Ros R, Ampuero I, García de Yébenes J. Parkin polymorphisms in progressive supranuclear palsy. *Journal of the Neurological Sciences* 2008; **268**: 176–178.
- Paviour DC, Price SL, Jahanshahi M, Lees AJ, Fox NC. Longitudinal MRI in progressive supranuclear palsy and multiple system atrophy: rates and regions of atrophy. *Brain* 2006; **129**(Pt 4): 1040–1049.
- Paviour DC, Price SL, Lees AJ, Fox NC. MRI derived brain atrophy in PSP and MSA-P: determining sample size to detect treatment effects. *Journal of Neurology* 2007; **254**: 478–481.
- Eckert T, Barnes A, Dhawan V, *et al.* FDG PET in the differential diagnosis of parkinsonian disorders. *NeuroImage* 2005; **26**: 912–921.
- Piccini P, de Yebenez J, Lees AJ, *et al.* Familial progressive supranuclear palsy: detection of subclinical cases using 18F-dopa and 18fluorodeoxyglucose positron emission tomography. *Archives of Neurology* 2001; **58**: 1846–1851.
- Mollenhauer B, Bibl M, Esselmann H, *et al.* Tauopathies and synucleinopathies: do cerebrospinal fluid beta-amyloid peptides reflect disease-specific pathogenesis? *Journal of Neural Transmission* 2007; **114**: 919–927.
- Brettschneider J, Petzold A, Sussmuth SD, *et al.* Neurofilament heavy-chain NfH(SMI35) in cerebrospinal fluid supports the differential diagnosis of Parkinsonian syndromes. *Movement Disorders* 2006; **21**: 2224–2227.
- Mandelkow EM, Drewes G, Biernat J, *et al.* Glycogen synthase kinase-3 and the Alzheimer-like state of micro-

- tubule-associated protein tau. *FEBS Letters* 1992; **314**: 315–321.
34. Pei JJ, Braak E, Braak H, *et al.* Distribution of active glycogen synthase kinase 3 β (GSK-3 β) in brains staged for Alzheimer disease neurofibrillary changes. *Journal of Neuropathology and Experimental Neurology* 1999; **58**: 1010–1019.
 35. Ferrer I, Barrachina M, Puig B. Glycogen synthase kinase-3 is associated with neuronal and glial hyperphosphorylated tau deposits in Alzheimer's disease, Pick's disease, progressive supranuclear palsy and corticobasal degeneration. *Acta Neuropathologica* 2002; **104**: 583–591.
 36. Lucas JJ, Hernandez F, Gomez-Ramos P, Moran MA, Hen R, Avila J. Decreased nuclear β -catenin, tau hyperphosphorylation and neurodegeneration in GSK-3 β conditional transgenic mice. *EMBO Journal* 2001; **20**: 27–39.
 37. Hernandez F, Borrell J, Guaza C, Avila J, Lucas JJ. Spatial learning deficit in transgenic mice that conditionally over-express GSK-3 β in the brain but do not form tau filaments. *Journal of Neurochemistry* 2002; **83**: 1529–1533.
 38. Engel T, Hernandez F, Avila J, Lucas JJ. Full reversal of Alzheimer's disease-like phenotype in a mouse model with conditional overexpression of glycogen synthase kinase-3. *Journal of Neuroscience* 2006; **26**: 5083–5090.
 39. Engel T, Goni-Oliver P, Lucas JJ, Avila J, Hernandez F. Chronic lithium administration to FTDP-17 tau and GSK-3 β overexpressing mice prevents tau hyperphosphorylation and neurofibrillary tangle formation, but preformed neurofibrillary tangles do not revert. *Journal of Neurochemistry* 2006; **99**: 1445–1455.
 40. Duff K, Planel E. Untangling memory deficits. *Nature Medicine* 2005; **11**: 826–827.
 41. Lannuzel A, Michel PP, Caparros-Lefebvre D, Abaul J, Hocquemiller R, Ruberg M. Toxicity of Annonaceae for dopaminergic neurons: potential role in atypical parkinsonism in Guadeloupe. *Movement Disorders* 2002; **17**: 84–90.
 42. Lannuzel A, Michel PP, Hoglinger GU, *et al.* The mitochondrial complex I inhibitor annonacin is toxic to mesencephalic dopaminergic neurons by impairment of energy metabolism. *Neuroscience* 2003; **121**: 287–296.
 43. Champy P, Hoglinger GU, F  ger J, *et al.* Annonacin, a lipophilic inhibitor of mitochondrial complex I, induces nigral and striatal neurodegeneration in rats: possible relevance for atypical parkinsonism in Guadeloupe. *Journal of Neurochemistry* 2004; **88**: 63–69.
 44. Betarbet R, Sherer TB, MacKenzie G, Garcia-Osuna M, Panov AV, Greenamyre JT. Chronic systemic pesticide exposure reproduces features of Parkinson's disease. *Nature Neuroscience* 2000; **3**: 1301–1306.
 45. Hoglinger GU, Lannuzel A, Khondiker ME, *et al.* The mitochondrial complex I inhibitor rotenone triggers a cerebral tauopathy. *Journal of Neurochemistry* 2005; **95**: 930–939.
 46. Albers DS, Swerdlow RH, Manfredi G, *et al.* Further evidence for mitochondrial dysfunction in progressive supranuclear palsy. *Experimental Neurology* 2001; **168**: 196–198.
 47. McGeer PL, McGeer EG. The inflammatory response system of brain: implications for therapy of Alzheimer and other neurodegenerative diseases. *Brain Research. Brain Research Reviews* 1995; **21**: 195–218.
 48. Chen H, Zhang SM, Hernan MA, *et al.* Nonsteroidal anti-inflammatory drugs and the risk of Parkinson disease. *Archives of Neurology* 2003; **60**: 1059–1064.
 49. McGeer PL, McGeer E, Rogers J, Sibley J. Anti-inflammatory drugs and Alzheimer disease. *Lancet* 1990; **335**: 1037.
 50. Zhang B, Maiti A, Shively S, *et al.* Microtubule-binding drugs offset tau sequestration by stabilizing microtubules and reversing fast axonal transport deficits in a tauopathy model. *Proceedings of the National Academy of Sciences of the United States of America* 2005; **102**: 227–231.
 51. Le Corre S, Klafki HW, Plesnila N, *et al.* An inhibitor of tau hyperphosphorylation prevents severe motor impairments in tau transgenic mice. *Proceedings of the National Academy of Sciences of the United States of America* 2006; **103**: 9673–9678.
 52. Noble W, Planel E, Zehr C, *et al.* Inhibition of glycogen synthase kinase-3 by lithium correlates with reduced tauopathy and degeneration in vivo. *Proceedings of the National Academy of Sciences of the United States of America* 2005; **102**: 6990–6995.
 53. Liou YC, Sun A, Ryo A, *et al.* Role of the prolyl isomerase Pin1 in protecting against age-dependent neurodegeneration. *Nature* 2003; **424**: 556–561.
 54. Wang YP, Biernat J, Pickhardt M, Mandelkow E, Mandelkow EM. Stepwise proteolysis liberates tau fragments that nucleate the Alzheimer-like aggregation of full-length tau in a neuronal cell model. *Proceedings of the National Academy of Sciences of the United States of America* 2007; **104**: 10252–10257.
 55. Gamblin TC, Chen F, Zambrano A, *et al.* Caspase cleavage of tau: linking amyloid and neurofibrillary tangles in Alzheimer's disease. *Proceedings of the National Academy of Sciences of the United States of America* 2003; **100**: 10032–10037.
 56. Pickhardt M, Gazova Z, von Bergen M, *et al.* Anthraquinones inhibit tau aggregation and dissolve Alzheimer's paired helical filaments in vitro and in cells. *Journal of Biological Chemistry* 2005; **280**: 3628–3635.
 57. Asuni AA, Boutajangout A, Quartermain D, Sigurdsson EM. Immunotherapy targeting pathological tau conformers in a tangle mouse model reduces brain pathology with associated functional improvements. *Journal of Neuroscience* 2007; **27**: 9115–9129.
 58. Rosenmann H, Grigoriadis N, Karussis D, *et al.* Tauopathy-like abnormalities and neurologic deficits in mice immunized with neuronal tau protein. *Archives of Neurology* 2006; **63**: 1459–1467.
 59. Lewis J, McGowan E, Rockwood J, *et al.* Neurofibrillary tangles, amyotrophy and progressive motor disturbance in mice expressing mutant (P301L) tau protein. *Nature Genetics* 2000; **25**: 402–405 (Erratum in: *Nat Genet* 2000 Sep;26(1):127).
 60. Santacruz K, Lewis J, Spires T, *et al.* Tau suppression in a neurodegenerative mouse model improves memory function. *Science* 2005; **309**: 476–481.
 61. Duff K, Knight H, Refolo LM, *et al.* Characterization of pathology in transgenic mice over-expressing human genomic and cDNA tau transgenes. *Neurobiology of Disease* 2000; **7**: 87–98.
 62. Ishihara T, Hong M, Zhang B, *et al.* Age-dependent emergence and progression of a tauopathy in transgenic

- mice overexpressing the shortest human tau isoform. *Neuron* 1999; **24**: 751–762.
63. Gotz J, Chen F, Barmettler R, Nitsch RM. Tau filament formation in transgenic mice expressing P301L tau. *Journal of Biological Chemistry* 2001; **276**: 529–534.
 64. Gotz J, Probst A, Spillantini MG, *et al.* Somatodendritic localization and hyperphosphorylation of tau protein in transgenic mice expressing the longest human brain tau isoform. *EMBO Journal* 1995; **14**: 1304–1313.
 65. Probst A, Gotz J, Wiederhold KH, *et al.* Axonopathy and amyotrophy in mice transgenic for human four-repeat tau protein. *Acta Neuropathologica* 2000; **99**: 469–481.
 66. Tanemura K, Akagi T, Murayama M, *et al.* Formation of filamentous tau aggregations in transgenic mice expressing V337M human tau. *Neurobiology of Disease* 2001; **8**: 1036–1045.
 67. Tatebayashi Y, Miyasaka T, Chui DH, *et al.* Tau filament formation and associative memory deficit in aged mice expressing mutant (R406W) human tau. *Proceedings of the National Academy of Sciences of the United States of America* 2002; **99**: 13896–13901.
 68. Dawson HN, Cantillana V, Chen L, Vitek MP. The tau N279K exon 10 splicing mutation recapitulates frontotemporal dementia and parkinsonism linked to chromosome 17 tauopathy in a mouse model. *Journal of Neuroscience* 2007; **27**: 9155–9168.
 69. Allen B, Ingram E, Takao M, *et al.* Abundant tau filaments and nonapoptotic neurodegeneration in transgenic mice expressing human P301S tau protein. *Journal of Neuroscience* 2002; **22**: 9340–9351.
 70. Yoshiyama Y, Higuchi M, Zhang B, *et al.* Synapse loss and microglial activation precede tangles in a P301S tauopathy mouse model. *Neuron* 2007; **53**: 337–351 (Erratum in: *Neuron*. 2007 Apr 19;54:343–344).
 71. Spittaels K, Van den Haute C, Van Dorpe J, *et al.* Prominent axonopathy in the brain and spinal cord of transgenic mice overexpressing four-repeat human tau protein. *American Journal of Pathology* 1999; **155**: 2153–2165.
 72. Forman MS, Lal D, Zhang B, *et al.* Transgenic mouse model of tau pathology in astrocytes leading to nervous system degeneration. *Journal of Neuroscience* 2005; **25**: 3539–3550.
 73. Ittner LM, Fath T, Ke YD, *et al.* Parkinsonism and impaired axonal transport in a mouse model of frontotemporal dementia. *Proceedings of the National Academy of Sciences of the United States of America* 2008; **105**: 15997–16002.
 74. Higuchi M, Zhang B, Forman MS, Yoshiyama Y, Trojanowski JQ, Lee VM. Axonal degeneration induced by targeted expression of mutant human tau in oligodendrocytes of transgenic mice that model glial tauopathies. *Journal of Neuroscience* 2005; **25**: 9434–9443.
 75. Mocanu MM, Nissen A, Eckermann K, *et al.* The potential for beta-structure in the repeat domain of tau protein determines aggregation, synaptic decay, neuronal loss, and coassembly with endogenous Tau in inducible mouse models of tauopathy. *Journal of Neuroscience* 2008; **28**: 737–748.
 76. Oddo S, Caccamo A, Shepherd JD, *et al.* Triple-transgenic model of Alzheimer's disease with plaques and tangles: intracellular A β and synaptic dysfunction. *Neuron* 2003; **39**: 409–421.
 77. Schindowski K, Bretteville A, Leroy K, *et al.* Alzheimer's disease-like tau neuropathology leads to memory deficits and loss of functional synapses in a novel mutated tau transgenic mouse without any motor deficits. *American Journal of Pathology* 2006; **169**: 599–616.
 78. Jackson GR, Wiedau-Pazos M, Sang TK, *et al.* Human wild-type tau interacts with wingless pathway components and produces neurofibrillary pathology in *Drosophila*. *Neuron* 2002; **34**: 509–519.
 79. Wittmann CW, Wszolek MF, Shulman JM, *et al.* Tauopathy in *Drosophila*: neurodegeneration without neurofibrillary tangles. *Science* 2001; **293**: 711–714.
 80. Kraemer BC, Zhang B, Leverenz JB, Thomas JH, Trojanowski JQ, Schellenberg GD. Neurodegeneration and defective neurotransmission in a *Caenorhabditis elegans* model of tauopathy. *Proceedings of the National Academy of Sciences of the United States of America* 2003; **100**: 9980–9985.
 81. Bai Q, Garver JA, Hukriede NA, Burton EA. Generation of a transgenic zebrafish model of Tauopathy using a novel promoter element derived from the zebrafish eno2 gene. *Nucleic Acids Research* 2007; **35**: 6501–6516.
 82. Golbe LI, Ohman-Strickland PA. A clinical rating scale for progressive supranuclear palsy. *Brain* 2007; **130**(Pt 6): 1552–1565.
 83. van Balken I, Litvan I. Current and future treatments in progressive supranuclear palsy. *Current Treatment Options in Neurology* 2006; **8**: 211–223.
 84. Ludolph AC, Bendotti C, Blaugrund E, *et al.* Guidelines for the preclinical in vivo evaluation of pharmacological active drugs for ALS/MND: report on the 142nd ENMC international workshop. *Amyotrophic Lateral Sclerosis* 2007; **8**: 217–223.