

TCA PEEL IN THE TREATMENT OF MACULAR AMYLOIDOSISNandini A. S¹, Sharath Kumar B. C²**HOW TO CITE THIS ARTICLE:**

Nandini A. S, Sharath Kumar B. C, "TCA Peel in the Treatment of Macular Amyloidosis". Journal of Evolution of Medical and Dental Sciences 2014; Vol. 3, Issue 45, September 18; Page: 11090-11095, DOI: 10.14260/jemds/2014/3447

ABSTRACT: BACKGROUND AND OBJECTIVES: Macular amyloidosis (MA) represents a common variant of primary localized cutaneous amyloidosis with a characteristic female preponderance. Hyperpigmentation associated with MA poses a significant aesthetic problem for patients and there are no effective treatment modalities proven for the same. The present study was done to know the safety and efficacy of TCA (trichloroacetic acid) peel in the treatment of MA. **MATERIALS & METHODS:** A total of 25 patients with clinical diagnosis of macular amyloidosis were included in the study. TCA peel was done at an interval of 6 weeks between sessions. First session was done with 10% TCA and further sessions with 20 % TCA. Clinical response to treatment after each session was graded according to quarentile grading and any adverse effects were noted. **RESULTS:** A total of 25 patient. were included of which 22 were females and 3 males. Clinical improvement was more than 51% in 50% of patients after 3 sessions. Mean improvement scores increased proportionately with each session. Side effects included burning sensation during the procedure, peeling for almost 2 weeks and hyperpigmentation/ hypopigmentation. **INTERPRETATION AND CONCLUSION:** TCA peel is an effective and also cost effective treatment for the hyperpigmentation of macular amyloidosis. Disadvantages being long peeling time and possibility of hyper and hypopigmentation.

KEYWORDS: TCA, macular amyloidosis, treatment.

INTRODUCTION: Macular amyloidosis (MA) is a common variant of primary localized cutaneous amyloidosis with a characteristic female preponderance^[1-7] and the age of onset ranging between 21 and 50 years.^[7] MA presents clinically as hyperpigmented patches with rippled pattern. Though the most commonly involved sites are interscapular area, extremities- forearms and shin, rarely MA can also be seen over clavicles, breast, neck and axilla.^[8-12] The etiology still is not very clear though many risk factors like race, genetics, female gender, sun exposure, atopy, friction and autoimmunity have been proposed.^[3,6,10,12-17]

MA has a high incidence in Asia, Middle East and South America, but is rarely seen in European and North American countries.^[2,8] The hyperpigmentation involving areas of the upper back, arms and legs poses an important aesthetic problem. In general, the treatment of cutaneous amyloidosis is disappointing.

Various treatment modalities used for primary cutaneous amyloidosis include- topical corticosteroids, photoprotection, topical dimethyl sulfoxide DMSO 10%, UVB therapy, etretinate, acetretin, cyclophosphamide, cyclosporine, dermabrasion and Q-switched Nd YAG laser^[8-26] though none of these have given satisfactory results.

AIMS AND OBJECTIVES: The present study was done to know the efficacy and safety of TCA-trichloroacetic acid peel in treatment of MA.

ORIGINAL ARTICLE

MATERIAL & METHODS: Twenty five patients who were clinically diagnosed to have macular amyloidosis and were concerned about the hyperpigmentation, attending the OPD of department of dermatology, KIMS hospital, Bangalore over a period of 10 months in 2009 were included in the study.

Inclusion Criteria:

- Age more than 15yrs.
- Patients willing for the peeling.

Exclusion Criteria:

- Patients with keloidal tendency.
- With active infection in treatment area.
- Unrealistic expectations.
- Pregnancy and lactation.

A detailed history and examination involving age/sex, duration of the disease, skin type, sites of involvement and past treatment were noted.

Prepeel procedure involved priming the skin for at least a week with glycolic/ retinoic acid derivative creams for topical application. Photoprotection was started. And general measures were advised like avoiding scrubbing or any form of friction during or after bathing and avoiding very hot water for bathing. Patients were explained about the procedure and the peeling seen after the peel.

Informed consent taken and documentation done before each session. First session of TCA peel was done with 10% of TCA peel followed by 20 % in further sessions. Post peel procedure was followed which included photoprotection, moisturizer to counteract the peeling discomfort.

Demelanising creams after 15 days of peeling

Interval between sessions varied between 6 weeks (majority) to 2 months. Clinical improvement after each session was noted and graded according to quarentile grading.

RESULTS: A total of 25 patient were included in the study of which 22 were females and 3 males. Youngest age being 21 yrs and oldest being 48 yrs. Majority (13 patient) had Fitzpatrick skin type III followed by skin type IV (10 patient) and skin type V (2 patient).

All 25 patient, included had upper limb involvement and of these 10 patient also had involvement of back in the form of hyperpigmented patches. Pruritus was associated in only 5 patient (20%). Duration of the disease ranged from 1 yr to 20 yrs with a mean disease duration of 6.8 yrs.

All 25 patient had 1st session of TCA peel with 10 % TCA. 22 patient underwent 2nd session, 20 patient - 3rd session, 7 patient - 4th session and 3 patient - fifth session and all of which were with 20% TCA. After first session 2 patient had 25 to 50 % improvement. After 2nd session 15 patient had more than 25 % improvement. After 3rd session 10 (50 %) patient. had more than 51% improvement. And all patient who underwent 4th and 5th sessions had more than 51% improvement. (Table 1, graph 1).

Adverse effects noted include burning sensation during the procedure in 92% (23) patient. Peeling of skin in peel site was noted which started after around 4 to 5 days and lasted for almost 15

ORIGINAL ARTICLE

to 20 days. Post inflammatory hyperpigmentation was seen in 4 patient (16%) and post inflammatory hypopigmentation was seen in 1 pt (4%).

DISCUSSION: Macular amyloidosis is one of the forms of primary localized cutaneous amyloidosis, others being lichen amyloidosis, nodular amyloidosis and biphasic (macular +lichen) amyloidosis. Macular amyloidosis (MA) is more common of all the types. Though amyloidosis has been reported to be frequently associated with pruritus,^[27] in our study only 20 % patient. had pruritus and the main concern of these patient. Was hyperpigmentation which posed a major aesthetic problem? There are not much studies which address the treatment for this hyperpigmentation though reports of some cases responding to topical steroid, UVB, topical DMSO have been reported. Q- Switched NdYAG laser have been found to be effective but it is expensive. Hence the present study with TCA peel was conducted.

A total of 25 patient. were included of which 22 were females. This reinforces the female preponderance seen in other studies which has been attributed to the frequent medical assistance sought by females for this cosmetic problem and also a possible role of hormones.^[27] The duration of the MA varied from 1 yr to 20 yrs which indicated the chronicity of the problem. All patient in our study had upper limb involvement and only 50 % of them had back involvement which is unlike other studies which show back as the predominant area of involvement. Majority of patient had been using topical therapy or glycolic peels with no satisfactory results.

TCA peel sessions were done as described above in materials and methods. Initial (1st session) 10 % TCA was used to know how pt would respond to a low strength, look for adverse effects and also to prepare pt for further sessions of increased strengths of TCA. 20 % TCA was used for further sessions (2nd to 5th). 20% TCA gave significant peeling and also was also associated with moderate burning sensation during procedure and hence the concentration was not increased any further.

Clinical improvement of more than 25% was seen after first session itself in 2 patient. 3 patient had only one session- all 3 patient. (1male & 2 females) could not afford to cover their hands during the peeling stage due to their profession. After 2nd session 15 patient had more than 25 % improvement. And these patients were quite happy. After 3rd session 10 (50%) patient. had more than 51% improvement. All these patient with more than 51% improvement were very satisfied. Of all patient 7 showed 70% improvement and were extremely happy.

Mean improvement scores increased significantly and proportionately with each session except 5th session (probably because of very small number of patient in 5th session) as indicated by the p value. Also noted was the better improvement of upper limb pigmentation as compared with not so good improvement of back pigmentation probably a result of more sincere care with photoprotection and demelanising creams of upper limbs due to easy accessibility and visibility.

Adverse effects noted include burning sensation during the procedure in 92% (23) patient which is expected in TCA peel. Peeling of skin in peel site was noted which started after around 4 to 5 days and lasted for almost 15 to 20 days. This was the main concern of the patients as they had to cover the area till peeling subsided. Post inflammatory hyperpigmentation was seen in 4 patient (16%) and post inflammatory hypopigmentation was seen in 1 pt (4%).

Post inflammatory hyperpigmentation was managed with topical steroid and demelanising creams though it took almost 3-5 months. But post inflammatory hypopigmentation though seen in

ORIGINAL ARTICLE

only one pt was more troublesome as it was in type IV skin and was very obvious and was managed with topical tacrolimus ointment and took almost 6 months to subside. It could have been probably managed better with targeted phototherapy if that was available. In view of hypopigmentation we can even do a test patch before doing the whole area in type IV skin patient.

CONCLUSION: TCA peel offers a good and cost effective modality of treatment for patients with MA not responding to topical creams to give quite satisfactory results. But with proper pre-procedure counseling of pt. and to be able to effectively deal with the adverse effects.

LIMITATION OF THE STUDY: Long term follow up needed to see how long the efficacy can be maintained.

REFERENCES:

1. Palitz LL, Peck S. Amyloidosis cutis: A macular variant. *AMA Arch Derm Syphilol.* 1952; 65: 451-7. [PubMed].
2. Habermann MC, Montenegro MR. Primary cutaneous amyloidosis: Clinical, laboratorial and histopathological study of 25 cases. Identification of gamma globulins and C3 in the lesions by immunofluorescence. *Dermatologica.* 1980; 160: 240-8. [PubMed].
3. Al-Ratrout JT, Satti MB. Primary localized cutaneous amyloidosis: A clinicopathologic study from Saudi Arabia. *Int J Dermatol.* 1997; 36: 428-34. [PubMed].
4. Lines RR, 3rd, Hansen RC. A hyperpigmented, rippled eruption in a Hispanic woman: Macular amyloidosis. *Arch Dermatol.* 1997; 133: 383-6. [PubMed].
5. Djuanda A, Wiryadi BE, Sularsito SA, Hidayat D. The epidemiology of cutaneous amyloidosis in Jakarta (Indonesia). *Ann Acad Med Singapore.* 1988; 17:536-40. [PubMed].
6. Eswaramoorthy V, Kaur I, Das A, Kumar B. Macular amyloidosis: Etiological factors. *J Dermatol.* 1999; 26: 305-10. [PubMed].
7. Rasi A, Khatami A, Javaheri SM. Macular amyloidosis: An assessment of prevalence, sex, and age. *Int J Dermatol.* 2004; 43: 898-9. [PubMed].
8. Kibbi AG, Rubeiz NG, Zaynoun ST, Kurban AK. Primary localized cutaneous amyloidosis. *Int J Dermatol.* 1992; 31: 95-8. [PubMed].
9. Chang YT, Wong CK, Chow KC, Tsai CH. Apoptosis in primary cutaneous amyloidosis. *Br J Dermatol.* 1999; 140:210-5. [PubMed].
10. Shanon J, Sagher F. Interscapular cutaneous amyloidosis. *Arch. Dermatol.* 1970; 102:195-8. [PubMed].
11. Tanigaki T, Hata S, Kitano Y, Nomura M, Sano S, Endo H, et al. Unusual pigmentation on the skin over trunk bones and extremities. *Dermatologica.* 1985; 170:235-9. [PubMed].
12. Somani V, Shailaja H, Sita V, Razvi F. Nylon friction dermatitis: A Venereol distinct subset of macular amyloidosis. *Indian J Dermatol Venerol Leprol.* 1995; 61:145-7. [PubMed]
13. Wong CK. Cutaneous amyloidoses. *Int J Dermatol.* 1987; 26:273-7. [PubMed].
14. Shanon J. Cutaneous amyloidosis associated with atopic disorders. *Dermatologica.* 1970; 141: 297-302. [PubMed].
15. Onuma L, Vega M, Arenas R, Dominguez L. Friction amyloidosis. *Int J Dermatol.* 1994; 33: 74. [PubMed].

ORIGINAL ARTICLE

17. Hashimoto K, Kobayashi H. Histogenesis of amyloid in the skin. *Am J Dermatopathol.* 1980; 2: 165–71. [PubMed].
18. Siragusa M, Ferri R, Cavallari V, Schepis C. Friction melanosis, friction amyloidosis, macular amyloidosis, towel melanosis: Many names for the same clinical entity. *Eur J Dermatol.* 2001; 11: 545–8.[PubMed].
19. Ozkaya-Bayazit E, Kavak A, Gungor H, Ozarmagan G. Intermittent use of topical dimethyl sulfoxide in macular and papular amyloidosis. *Int J Dermatol.* 1998; 37: 949–54. [PubMed].
20. Pandhi R, Kaur I, Kumar B. Lack of effect of dimethyl sulphoxide in cutaneous amyloidosis. *J Dermatolog Treat.* 2002; 13: 11–4. [PubMed].
21. Hudson LD. Macular amyloidosis: Treatment with ultraviolet B. *Cutis.* 1986; 38: 61–2. [PubMed]
22. Hernandez-Nunez A, Dauden E, Moreno de Vega MJ, Fraga J, Aragues M, Garcia-Diez A. Widespread biphasic amyloidosis: Response to acitretin. *Clin Exp Dermatol.* 2001; 26: 256–9. [PubMed].
23. Marschalko M, Daroczy J, Soos G. Etretnate for the treatment of lichen amyloidosis. *Arch Dermatol.*1988; 124: 657–9. [PubMed].
24. Aram H. Failure of etretinate (RO 10-9359) in lichen amyloidosis. *Int J Dermatol.* 1986; 25: 206.[PubMed].
25. Behr FD, Levine N, Bangert J. Lichen amyloidosis associated with atopic dermatitis: Clinical resolution with cyclosporine. *Arch Dermatol.* 2001; 137: 553–5. [PubMed].
26. Wong CK, Li WM. Dermabrasion for lichen amyloidosis: Report of a long-term study. *Arch Dermatol.*1982; 118: 302–4. [PubMed].
27. Ostovari N, Mohtasham N, Oadras M, Malekzad F. 532-nm and 1064-nm Q-switched Nd: YAG laser therapy for reduction of pigmentation in macular amyloidosis patches. *J Eur Acad Dermatol Venereol.*2008; 22: 442–6. [PubMed].
28. Bandhlish A, Aggarwal A, Koranne R V. A Clinico-Epidemiological Study of Macular Amyloidosis from North India. *Indian J Dermatol.* 2012 Jul-Aug; 57 (4): 269–274.

Table 1: Results of TCA peel for macular amyloidosis after various sessions.

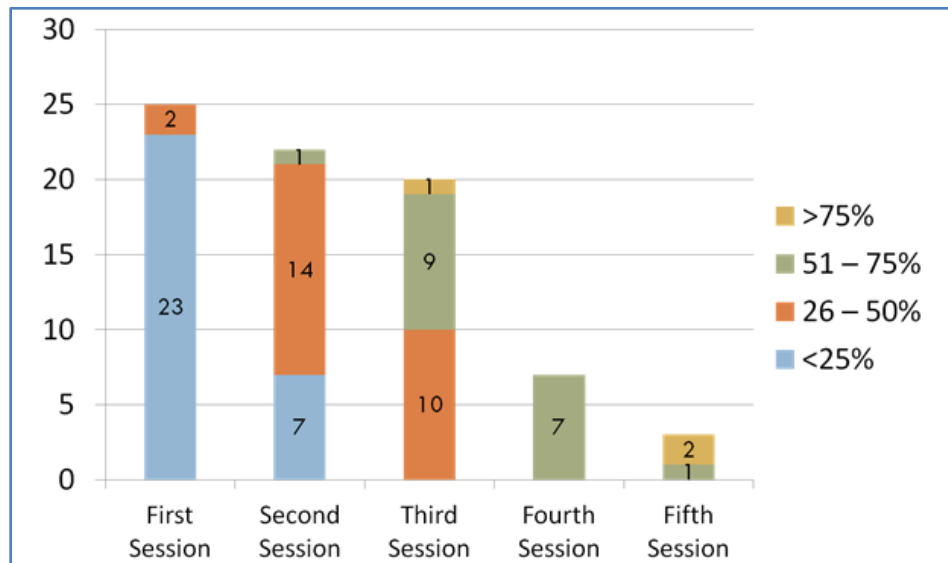
Improvement Score	1 st session	2 nd session	3 rd session	4 th session	5 th session
<25%	23	7	0	0	0
25-50 %	2	14	10	0	0
51-75 %	0	1	9	7	1
>75 %	0	0	1	0	2
Total	25	22	20	7	3
Significance*	-	Z= -3.991 P <0.001	Z= -3.869 P <0.001	Z=-2.460 P =0.014	Z=-1.633 P =0.102

Table 1

ORIGINAL ARTICLE

*Wilcoxon Signed rank test

Graph 1: Results of TCA peel for macular amyloidosis after various sessions.



Graph 1

AUTHORS:

1. Nandini A. S.
2. Sharath Kumar B. C.

PARTICULARS OF CONTRIBUTORS:

1. Assistant Professor, Department of Dermatology, Kempegowda Institute of Medical Sciences, Bangalore.
2. Professor and HOD, Department of Dermatology, Kempegowda Institute of Medical Sciences, Bangalore.

NAME ADDRESS EMAIL ID OF THE CORRESPONDING AUTHOR:

Dr. Nandini A. S,
Assistant Professor,
Department of Dermatology,
Kempegowda Institute of Medical Sciences,
Bangalore.
Email: drnandinias2002@yahoo.co.in

Date of Submission: 30/08/2014.
Date of Peer Review: 01/09/2014.
Date of Acceptance: 11/09/2014.
Date of Publishing: 18/09/2014.