

Temporal lobe regions engaged during normal speech comprehension

Jennifer T. Crinion,¹ Matthew A. Lambon-Ralph,² Elizabeth A. Warburton,³ David Howard⁴ and Richard J. S. Wise¹

¹MRC Clinical Sciences Centre, Cyclotron Unit, Hammersmith Hospital, London, ²Department of Psychology, University of Manchester, Manchester, ³Department of Medicine, Addenbrooke's Hospital, Cambridge and ⁴Department of Speech, University of Newcastle, Newcastle upon Tyne, UK

Correspondence to: Jennifer Crinion, MRC Clinical Sciences Center, Cyclotron Unit, Hammersmith Hospital, Du Cane Road, London W12 0NN, UK
E-mail: j.crinion@ion.ucl.ac.uk

Summary

Processing of speech is obligatory. Thus, during normal speech comprehension, the listener is aware of the overall meaning of the speaker's utterance without the need to direct attention to individual linguistic and paralinguistic (intonational, prosodic, etc.) features contained within the speech signal. However, most functional neuroimaging studies of speech perception have used metalinguistic tasks that required the subjects to attend to specific features of the stimuli. Such tasks have demanded a forced-choice decision and a motor response from the subjects, which will engage frontal systems and may include unpredictable top-down modulation of the signals observed in one or more of the temporal lobe neural systems engaged during speech perception. This study contrasted the implicit comprehension of simple narrative speech with listening to

reversed versions of the narratives: the latter are as acoustically complex as speech but are unintelligible in terms of both linguistic and paralinguistic information. The result demonstrated that normal comprehension, free of task demands that do not form part of everyday discourse, engages regions distributed between the two temporal lobes, more widely on the left. In particular, comprehension is dependent on anterolateral and ventral left temporal regions, as suggested by observations on patients with semantic dementia, as well as posterior regions described in studies on aphasic stroke patients. The only frontal contribution was confined to the ventrolateral left prefrontal cortex, compatible with observations that comprehension of simple speech is preserved in patients with left posterior frontal infarction.

Keywords: narrative speech comprehension; temporal lobes

Abbreviations: FG = fusiform gyrus; fMRI = functional MRI; IFG = inferior frontal gyrus; IPL = inferior parietal lobe; PAC = primary auditory cortex; SPMs = statistical parametric maps; STS = superior temporal sulcus; STG = superior temporal gyrus; T+ = the six subjects in this group were asked to identify, at the end of each scan, whether there were two or three different narrators in each story and reversed story; T- = the 11 subjects in this group were asked to listen closely to the stimuli but there was no explicit task demand.

Introduction

Functional neuroimaging studies on normal subjects have demonstrated that speech or speech-like sounds, contrasted with simpler acoustic stimuli, increase activity in the left and right lateral superior temporal gyrus (STG), extending ventrally as far as the dorsal bank of the superior temporal sulcus (STS) (Binder *et al.*, 1997; Belin *et al.*, 2000). This corresponds to the response of lateral auditory cortex in monkeys, where recordings from single cells have shown that the maximal response is to complex sounds, including species specific vocalization (Rauschecker, 1998). There is a lack of

agreement about the specialization of the left and right temporal lobes for detecting particular acoustic features contained within the speech signal, and whether there are auditory cortical regions that are speech specific in their response. Notwithstanding these important debates on the detail of specialization within the auditory cortex, the bilateral superior temporal response when subjects undergoing functional neuroimaging heard words, is in close accord with the clinical literature on so-called word deafness (an agnosia for speech associated with little, if any, impairment of

language). This syndrome is usually associated with damage to both the left and right STG (Auerbach *et al.*, 1982).

Clinical observations over many decades have demonstrated that verbal comprehension, both lexical and sentential semantics, is largely lateralized to the left cerebral hemisphere in most individuals. Although there are fewer studies on the comprehension of paralinguistic information, from rising intonation to cue a question through to awareness of the identity, sex and emotional state of a speaker, it is generally agreed that the right temporal lobe is involved. The study of acquired brain disease to investigate more precisely the localization of access to verbal meaning has resulted in descriptions of quite different brain regions in the left temporal lobe. The literature on aphasic stroke patients emphasizes the importance of the posterior temporal and inferior parietal cortex (Alexander *et al.*, 1989). In contrast, studies on the variant of fronto-temporal dementia known as semantic dementia, associated with a progressive and ultimately profound loss of the knowledge of single word meaning, indicate that anterior and ventral temporal lobe cortex may be central to word comprehension (Mummery *et al.*, 2000; Chan *et al.*, 2001; Galton *et al.*, 2001). This, in turn, contrasts with the observations on epileptic patients who have undergone anterior temporal lobectomies, who are reported to have no more than mild language deficits postoperatively (Trenerry, 1996). Nevertheless, some recent studies have reported that early-onset temporal lobe epilepsy patients have a semantic knowledge deficit that contributes to their anomia (Bell *et al.*, 2001). Finally, a role for the ventral temporal lobe, particularly the fusiform gyrus (FG), in language has been shown both by electrophysiological techniques at the time of epilepsy surgery (Burnstine *et al.*, 1990) and by neuropsychological tests on patients with left posterior cerebral artery territory infarcts (De Renzi *et al.*, 1987). Recently, there has been speculation that perirhinal cortex, which in man may extend into the anterior FG, may have a role in semantic memory, based on research in non-human primates (Murray and Richmond, 2001).

The comprehension of the additional meaning conveyed by sentential structure has been attributed broadly to left perisylvian temporal cortex, with a possible contribution of the right for more complex syntax. Patients with damage to the left inferior frontal gyrus (IFG) generally recover to have good comprehension of both single words and the more simple sentence structures, although they have impaired understanding of complex sentence structures (Mohr *et al.*, 1978; Grodzinsky *et al.*, 1999). It has been proposed that this is because complex syntax requires controlled rather than automatic access to sentential meaning.

This study was designed to determine the anatomical routes by which narrative speech maps on to the mental representations of meaning. The hypothesis was that it would demonstrate a number of left temporal lobe regions, posterior, anterior and ventral, a distributed network the parts of which have been demonstrated separately in different patient groups. The chosen baseline task, reversed versions of the

narratives, which has the same acoustic complexity as forward speech, was expected to control for early acoustic processing of the speech signal in both left and right superior temporal cortex. As reversing speech destroys normal stress and prosodic patterns, it was also expected that right temporal lobe activation would be observed, although with no prediction about location within the lobe.

A particular aim was to contrast the result from this study with the description of other functional neuroimaging studies designed to investigate speech perception and comprehension. Many of these studies used metalinguistic task demands, requiring subjects to attend to specific acoustic, semantic or syntactic features in the stimuli and make a forced-choice response based on their assessment of the stimuli in relation to the specific task demand. This is quite unlike automatic comprehension during normal discourse, which for the most part does not require controlled access to the acoustic or syntactic structure of speech or to semantic memory. Therefore, we predicted that there would be little or no involvement of the left IFG. Although the use of specific tasks on selected stimuli may be expected to reveal the location of the particular phonetic, phonological, lexical or syntactic process under investigation as a change in regional activity, signal specific to the task demand may dominate the activation pattern, depending on study design. Furthermore, neural activity within systems responsible for the execution of the task may modulate the neural activity, and hence the observed signal, within the acoustic or linguistic systems under investigation. We expected, therefore, that the results from this study would be quite different from many other studies that investigated speech comprehension, more accurately demonstrating the neural systems involved in the comprehension of speech during everyday communication.

Methods

Subjects

Seventeen right-handed normal volunteers (seven females), mean age 56 years (range 37–88 years) gave informed consent to participate in the study. All had English as their first language. The Hammersmith Hospitals NHS Trust Ethics Committee approved the project, and permission to administer radioisotopes was given by the Department of Health.

Stimuli

All stimuli used were children's stories, designed for a normal reading age of 4–6 years, obtained from the Oxford Reading Tree Scheme (Hunt, 1996). The length of each story was ~250 words and 45 sentences, read at 150 words per min. The selected stories comprised nouns of high frequency and imageability within simple sentence structures. Eight stories were recorded, five with three different narrators (at least one male and female) and three with two narrators (male and

female). Using SoundEdit16™ computer software, the waveform for each story was reversed. Reversal destroyed the intelligibility of the stories while retaining the overall acoustic complexity. The stories and reversed stories were only used once during each subject's study, across 16 scans. The order of presentation was randomized, both within and between subjects. Presentation was binaural via headphones, with the volume set at a comfortable level for each subject.

Eleven subjects were asked to listen closely to the stimuli during the course of each scan (T−). This was the main study. A further six subjects listened to the same stimuli but they were asked to identify at the end of each scan whether they had heard two or three different narrators in each story and reversed story (T+). The purpose of the T− and T+ arms to this study was to address what has been termed 'conceptual' processing. Binder *et al.* (1999) have argued that during a 'rest' state or during the 'passive' perception of stimuli, stimulus-independent thoughts (i.e. daydreams or ruminations) intrude and may activate brain regions that are also involved in higher processes involved in speech comprehension and production. Therefore, a study of 'passive' speech comprehension can be criticized for failing to control for the effect of 'conceptual' processing on the observed distribution of brain activity. The introduction of attention to voice identity was intended to exclude stimulus-independent thoughts. The assumption was made, based on a principle established in a previous study, that attention to a paralinguistic component of the speech signal would not suppress processing of the verbal meaning of the stimuli (Price *et al.*, 1996). Exploring interactions between regional activity in the T− and T+ groups was intended to reveal the influence, if any, of incidental 'conceptual' processing in the main study.

We deliberately kept an A–B design to improve the power of the study, safe in the knowledge that many previous studies of speech perception contrasting many different baseline stimuli have demonstrated superior temporal lobe activation by speech and not deactivation by the baseline tasks (which, in some studies, have included reversed speech). Therefore, the possibility that all or some of our temporal lobe signal is not due to a response to speech but to a deactivation in response to reversed speech seems very improbable.

PET data acquisition

Subjects were studied using a CTI-Siemens ECAT EXACT HR++/966 PET scanner operated in high-sensitivity 3D mode (Spinks *et al.*, 2000). H₂¹⁵O was administered intravenously and the data were acquired in one 90 s frame, beginning with the rising phase of the head curve. The relative distribution of regional cerebral blood flow in the brain is indexed by the accumulated counts over the scanning period. The interval between successive H₂¹⁵O administrations was 6 min. Corrections for attenuation were made using a transmission scan with an external source of caesium 125. Images were reconstructed by 3D filtered back projection (Hanning filter, cut-off frequency 0.5 cycles/pixel) and displayed in a

128 × 128 pixel format with 95 planes, creating ~2 mm cubic voxels.

Image data analysis

SPM99 software (Wellcome Department of Cognitive Neurology, Queen Square, London: <http://www.fil.ion.ucl.ac.uk/spm>) was used to realign the individual PET scans. These were then spatially transformed into standard Montreal Neurological Institute stereotactic space (the anatomical normalization template available in SPM99) and smoothed using an isotropic 10 mm full-width, half-maximum Gaussian kernel to account for variation in gyral anatomy and to improve the signal-to-noise ratio. On a voxel-by-voxel basis, statistical parametric maps (SPMs) of the *t*-statistics of the contrasts were created and transformed into Z-scores. Group analyses were performed, but each subject was entered as a separate study in the design matrix to facilitate inspection of the contribution from each subject's data to an activated voxel. A fixed effects model, with a threshold of $P < 0.05$ (Z-score >4.8), corrected for analyses across the whole volume of the brain, was used to establish, within the population studied, the distribution of activations, both within and between the T− and T+ groups. To increase confidence that the results common to the T− and T+ groups can be generalized to the rest of the English-speaking, right-handed population, the data from all 17 subjects were subjected to a random effects analysis, and the common activations between the T− and T+ groups are reported at a threshold $P < 0.05$, corrected. This assumed no *a priori* hypotheses about the activations being located predominantly in the temporal lobes, and therefore is a very conservative analysis. All analyses included a blocked, subject-specific ANCOVA (analysis of covariance) with global counts as confound to remove the effect of global changes in perfusion across scans.

Results

For the six subjects who had to identify the number of narrators (T+ group), the mean correct responses for the stories was 81.25% (range 62.5–100%), and for the reversed stories was 46.25% (range 25–75%).

When contrasting stories with reversed stories (Table 1 and Fig. 1), the distributions of the activated regions were very similar in the T− and T+ studies. They were observed along the lateral left temporal cortex, with a number of main peaks within clusters of significantly activated voxels. These were located in cortex posterior to primary auditory cortex (PAC), in the posterior STS and at the junction of the posterior STG with the inferior parietal lobe (IPL), and in cortex anterolateral to PAC, in the STS and middle temporal gyrus. In addition, there was activation of the ventral left temporal lobe, within the occipito-temporal sulcus that separates the inferior temporal from the fusiform gyri. On the right, there was significant activation of anterolateral cortex. There was no evidence of activation of the ventral

Table 1 Significant activations when contrasting stories with reversed stories

Region	Peak coordinates (Z score)		
	11 subjects T- <i>x y z (Z)</i>	6 subjects T+ <i>x y z (Z)</i>	Common activations <i>x y z (Z)</i>
Left inferior frontal gyrus			
Ventral IFG	-44 +26 -16 (4.3)	-46 +26 -14 (4.7)	-44 +26 -16 (6.4)
Lateral left temporal cortex			
Rostral cortex	-52 +08 -20 (Inf.)	-52 +08 -20 (7.6)	-52 +08 -20 (Inf.) [-52 +10 -18 (5.3)]
	-44 +20 -24 (5.9)	-44 +20 -24 (5.2)	-44 +20 -24 (7.7) [-46 +16 -16 (5.6)]
Mid STS	-56 -10 -10 (7.3)	-58 -06 -14 (7.0)	-58 -06 -12 (Inf.)
Caudal STS	-58 -46 +04 (6.7)	-60 -40 +02 (7.5)	-58 -42 +02 (Inf.)
STG-IPL junction	-56 -56 +18 (5.9)	-54 -52 +24 (5.9)	-56 -52 +20 (Inf.) [-56 -58 +18 (5.4)]
Ventral left temporal cortex			
FG	-42 -18 -36 (6.1)	-42 -16 -34 (4.7)	-42 -16 -34 (6.9) [-42 -16 -38 (5.6)]
Lateral right temporal cortex			
Rostral STS	+52 +10 -28 (6.2)	+60 +12 -18 (5.1)	+50 +14 -24 (Inf.) [+52 +06 -32 (8.0)]
Mid STS	+56 -08 -18 (6.3)	+58 -10 -14 (7.3)	+56 -08 -18 (Inf.) [+60 -04 -18 (8.3)]
Caudal STS	(<i>Z</i> < 4.0)	(<i>Z</i> < 4.0)	+60 -36 0 (4.9)
STG-IPL junction	(<i>Z</i> < 4.0)	+60 -56 +22 (5.1)	+64 -54 +2 (4.5)

Coordinates, in millimetres, refer to the location in the standard Montreal Neurological Institute stereotactic space of the voxels with the peak *Z*-score within a particular region ($P < 0.05$, corrected). The results using a fixed effects statistical model are shown and, for the common activations across the T- and T+ groups, the conservative results using a random effects statistical model ($P < 0.05$, corrected) are also reported, in square brackets.

right temporal cortex at a peak voxel threshold as low as $P < 0.01$, uncorrected. Increased activity in the posterior right STG-IPL junction only reached significance in the T+ group, in a cluster of seven voxels. Inspection of the data showed that the individual responses in this region were very variable in the T- group.

Whatever the threshold for the level of voxel-level significance, the numbers of voxels in the cluster posterior to the left PAC were always considerably larger than those on the right. Anterior to the PAC, the numbers of voxels in the left and right clusters in both the T- and T+ studies were approximately equal. There were no activation peaks in the middle and inferior temporal gyri caudal to the coronal plane of the anterior commissure (Fig. 2), even at a threshold of $P < 0.01$, uncorrected. Outside the temporal lobes, there was a subthreshold increase in activity (*Z*-scores >4.0 but <4.8) in the left IFG in both the T- and T+ groups, ventral to the pars opercularis and hence ventral to classic Broca's area.

In the T+ group, discriminating the number of narrators was difficult, the accuracy being below ceiling for the stories and at chance for the reversed stories. The assumption was made that the task demand minimized stimulus-independent thoughts. The absence of any differences in the distribution of activations in the T+ and T- groups provided evidence that stimulus-independent thoughts during 'passive' listening, which might have reduced the chance of finding possible

activations in supramodal association cortex associated with comprehension of the narratives, was not a confound.

Reversal of speech does not alter the fundamental frequency of the acoustic signal, a major cue to the sex of the speaker, but it destroys more subtle acoustic cues that allow discrimination between individuals of the same sex. The contrast of reversed stories with stories in the T+ group revealed one significantly activated region in the left dorsal anterior cingulate cortex. This region was not activated in the same contrast in the T- group (*Z*-score <2.3). Therefore, this activation corresponds to the task demand, activity being greater with the increase in task difficulty with reversed stories.

Discussion

The contrast of the two conditions in this study demonstrated a number of robust activations. On the left, these were distributed posterolateral to PAC, anterolateral to PAC and in ventral temporal cortex. All these regions have been suggested by clinical observations on patients with focal cerebral disease to be involved in word comprehension (De Renzi *et al.*, 1987; Alexander *et al.*, 1989; Luders *et al.*, 1991; Hodges *et al.*, 1992; Schaffler *et al.*, 1994; Nobre and McCarthy, 1995; Damasio *et al.*, 1996; Neary *et al.*, 1998; Berthier, 2001; Chan *et al.*, 2001; Galton *et al.*, 2001). On the

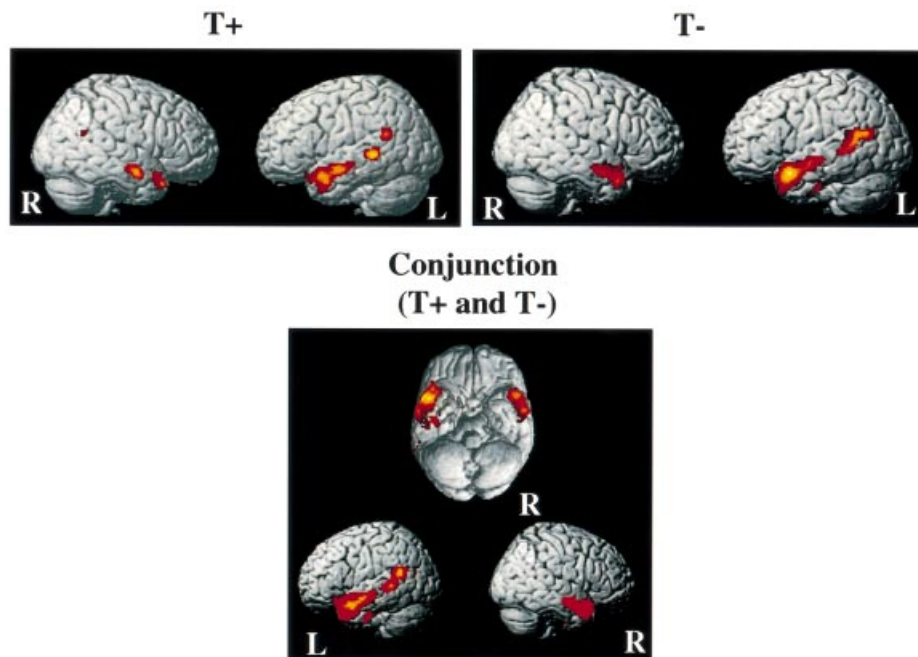


Fig. 1 Regions of significant difference when contrasting stories with reversed stories in the T+ and T- groups individually and the conjunction of the two groups depicted on three-dimensional renderings of a standard MRI scan template. The figures are thresholded at $P < 0.05$ (corrected). T+: the six subjects in this group were asked to identify, at the end of each scan, whether there were two or three different narrators in each story and reversed story. T-: the 11 subjects in this group were asked to listen closely to the stimuli but there was no explicit task demand.

right, there was one region anterolateral to PAC. Other than the ventral region on the left, all other regions were closely distributed in and around the STS.

The activated regions were distributed very similarly in the T- and T+ groups, with the exception of a small region at the right STG-IPL junction. This reproducibility, using separate groups of subjects but the same stimuli, affords considerable confidence in the data. A small region in the left IFG, ventral to classic 'Broca's' area, was just below the conservative statistical threshold in each study. The coordinates for the peak voxel in the two studies were almost identical, and this 'conjunction' makes it reasonable to conclude that the ventrolateral left IFG is engaged during the comprehension of simple narratives.

There are two issues about the study design. The first relates to the use of 'passive' listening. The behavioural neurosciences, both animal and human, have a long tradition of using tasks that require a response from the subject during the experiment. Measurements of reaction times and error rates may be of considerable interest in themselves but, in addition, relatively fast reaction times coupled with few errors imply that the subject is closely attending to the stimuli in the context of the task demand. This avoids the criticism of 'not knowing what the subjects were doing'. However, speech comprehension is an automatic process (Warren and Marslen-Wilson, 1987). A subject cannot shut his ears and,

although he can pay more or less attention to what he is listening to, each subject was motivated, he was asked to attend closely to the stimuli, and the stories, although simple in plot and language, are vivid and were read with animation. Furthermore, intersubject variability in response to the stimuli would not have been apparent in the group analyses. What was common was the intelligibility of the stories, in terms of both linguistic and paralinguistic features, compared with the reversed stories. As far as possible, an effect of stimulus-independent thoughts common to the group that might have reduced the observed distribution of regional activity changes was ruled out.

Incorporating explicit metalinguistic tasks into a study design introduces the confound of changes of activity associated with signalling the outcome of a forced-choice decision on each stimulus. Such tasks engage prefrontal and motor systems. The assumption has been made in some studies that including a forced-choice decision in the baseline task with which the active condition will be contrasted will control for, i.e. 'subtract' activity associated with, the frontal processes involved. However, if the stimulus and/or the type of decision is different between the two conditions, this is an unwarranted assumption: mnemonic control when accessing memory for associative knowledge about a word's referents is quite different from the auditory working memory required to count the number of syllables within that word. Thus, there

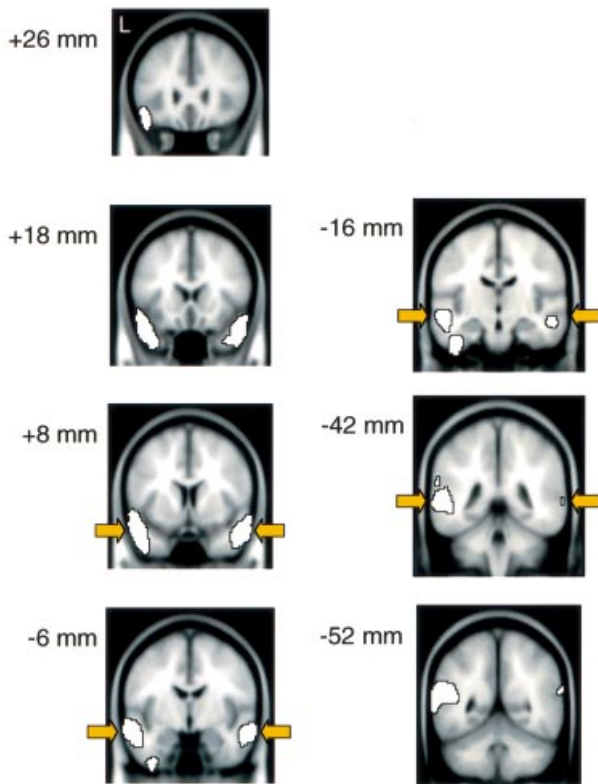


Fig. 2 Coronal sections of a standard MRI scan showing regions of significant activation, for the contrast of stories with reversed stories consistent for both groups in the anterior temporal lobe, from $y = +26$ mm to $y = -52$ mm. Figures are thresholded at $P < 0.05$ (corrected).

have been many publications demonstrating activation of the left IFG in tasks requiring a choice and response (verbal or finger press) based on features of individual speech or speech-like stimuli (Petersen *et al.*, 1990; Demonet *et al.*, 1992; Kapur *et al.*, 1994; Buckner *et al.*, 1995; Demb *et al.*, 1995). The left IFG is not directly involved in speech perception, and recent studies have clearly emphasized that the activity within left IFG reflects executive control over access to short- or long-term memory representations, depending on task demand, in more posterior regions (Thompson-Schill *et al.*, 1997). Thus, left IFG activity during speech perception is associated with ‘top-down’ and not ‘bottom-up’ processing. The left IFG activation in this study was in a region previously associated with the explicit retrieval of semantic knowledge, whether the stimuli were words or sentences. The relatively weak left IFG activation in this study accords with the mostly automatic nature of simple narrative speech comprehension in normal subjects and its preservation in patients with lesions of the left IFG. A related observation in studies of single word metalinguistic tasks is the reduction in activity within inferior left prefrontal cortex observed after the subjects repeatedly rehearse the same semantic task on the same stimuli (Raichle *et al.*, 1994). We can, however,

speculate that comprehension of passages of speech that may have been more ‘difficult’ to understand would have been associated with greater left IFG activity. The complexity might be lexical semantic (*she felt a lemon could mean she felt like a fool or she squeezed a yellow citrus fruit to test its freshness*) or syntactic (*ink was spilt on the carpet by the boy compared with the boy spilt ink on the carpet*). Based on a previous neuroimaging study, controlled access to semantic or syntactic features to assist comprehension would result in differently distributed activations within the left IFG (Dapretto and Bookheimer, 1999).

The second issue relates to the use of the simple ‘subtraction’ design to identify regions involved in speech comprehension. Over the scanning period necessary for data acquisition in PET scanning, the acoustic complexity of speech and reversed speech was identical. Critically, reversed speech is unintelligible, in terms of both its linguistic and paralinguistic content. Therefore, the contrast could be expected to demonstrate speech comprehension, conveyed principally by lexical semantics and simple syntax, supplemented by intonational and prosodic features. Based on longstanding evidence from observations on patients, it is reasonable to conclude that the left hemisphere regions were engaged predominantly by verbal meaning and the right temporal region by non-verbal meaning. We cannot exclude the possibility that a component of the observed signal in the contrast reflects pre-lexical processing late in the stages of acoustic analysis. It has been argued that reversed speech contains phonetic information, based on a relative inter-subject consistency when subjects attempted to transcribe reversed words (Binder *et al.*, 2000). If true, the activations in this study could be attributable entirely to lexical processing and beyond. However, constancy of transcription is dependent both on culture and on literacy. English speakers think ducks say *quack*, French speakers think they say *coin*, but, of course, ducks produce no human speech sounds at all. Illiterates cannot perform tasks reliant on segmentation of words and non-words: phonetic awareness is a product of learning an alphabetic script independent of normal speech perception (Pettersson *et al.*, 2000).

The key observation from this study is that processing occurs both anterolateral and posterolateral to PAC in the left hemisphere. Other PET studies that have looked at spoken word and sentence perception have demonstrated activation extending forwards in the temporal lobes (Perani *et al.*, 1998; Tzourio *et al.*, 1998; Papathanassiou *et al.*, 2000; Scott *et al.*, 2000). This has been the case less commonly with studies using functional MRI (fMRI). This difference is methodological: PET is equally sensitive to activity changes across the entire brain, but susceptibility artefact in fMRI studies makes it relatively difficult to image signal change in certain brain regions, including the anterior temporal lobe (see <http://www.fmrib.ox.ac.uk/~wilson/research/>) (Devlin *et al.*, 2000). A major issue, unresolved by this present study, is the relative importance of each of the components of the distributed system in the left temporal lobe for speech comprehension.

The most common view is that the profound incomprehension that may accompany left posterior temporal/inferior parietal infarction and the relative preservation of language functions in patients who have had an anterior temporal lobectomy for epilepsy argues for a posterior system being central to language comprehension. This view, however, is vulnerable to criticism.

First, there is a very large bias in the stroke aphasia literature. Embolic temporo-parietal infarcts are common, but isolated infarction of the anterior left temporal lobe is rare for two reasons: (i) the branch from the carotid artery circulation that supplies the anterior temporal lobe often arises proximal to the bifurcation of the middle cerebral artery, and it is the latter site where emboli commonly lodge and then pass down one or more distal branches; and (ii) in many subjects, the posterior cerebral artery may supply much of the anterior temporal lobe. Thus, by default, the performances of patients with left temporo-parietal infarction are compared with those of patients with left anterior temporal lobectomies. Nevertheless, the syndrome of transcortical sensory aphasia, with loss of knowledge of word meaning, although most usually ascribed to posterior infarction, can also accompany anterior lesions (Maeshima *et al.*, 1999; Berthier, 2001). Critically, auditory information projecting forwards in the temporal lobe must arise from PAC and surrounding periauditory cortex. We currently are investigating whether infarction of the posterior third of the superior temporal lobe, including PAC, has a major impact on the function of structurally intact ipsilateral anterolateral cortex. If so, then any accompanying loss of comprehension may be attributable as much to disconnection of anterolateral temporal cortex as destruction of temporo-parietal cortex.

Secondly, although the epilepsy surgical literature suggests that loss of anterior cortex has little impact on language functions, there are unresolved issues on the effects of chronic, uncontrolled epilepsy on reorganization of language systems (Helmstaedter *et al.*, 1994; Springer *et al.*, 1999; Bell *et al.*, 2000, 2001). The conclusions from studies on patients with semantic dementia strongly support a major role for anterior and ventral temporal cortex in lexical semantics (Chan *et al.*, 2001; Galton *et al.*, 2001).

Thirdly, anatomical connectivity between the dorsal temporal lobe and inferior prefrontal cortex must be considered. Metalinguistic verbal tasks have revealed two anatomically separable activations in the left IFG: one ventral and anterior and the other more dorsal and posterior. Broadly speaking, ventral and anterior prefrontal cortex is associated with tasks that emphasize access to semantic memory. The response of the more dorsal and posterior region is much less task specific. Although it has been activated in some studies of single word semantics (Thompson-Schill *et al.*, 1997, 1999; Roskies *et al.*, 2001), it is also engaged by phonological tasks that rely on an accurate analysis of sequences of speech sounds, such as span tasks and monitoring for phonemes embedded within words or non-words (Demonet *et al.*, 1994; Burton *et al.*, 2000). Grammatical tasks, which are also reliant

on holding sequences of words in working memory, similarly activate more dorsal and posterior prefrontal cortex (Caplan *et al.*, 1999; Dapretto and Bookheimer, 1999). It has been well established in non-human primates, and the same appears to be true in human, that the reciprocal connections of dorsolateral temporal cortex to inferior prefrontal cortex are topographically arranged: anterior temporal cortex projects to the ventrolateral IFG, and posterior temporal cortex to dorsolateral prefrontal cortex (Romanski *et al.*, 1999). Although this transition is gradual, at the two extremes there are clearly discernible white matter tracts: anterior is the uncinate fasciculus and posterior is the superior longitudinal fasciculus (of which part is the arcuate fasciculus). By associating the ventral and inferior IFG with the control of access to semantic memories, then the direct link must lie with regions within anterior temporal cortex. Similarly, the function of posterior temporal regions must be controlled directly by dorsolateral prefrontal and premotor cortex, a link associated with verbal working memory and phonological processing.

The importance of these distinctions has a direct bearing on aphasia recovery. Aphasic patients with left middle cerebral artery territory infarcts understand the meaning of objects and picture of objects. The semantic processing of pictures of objects is strongly associated with ventrolateral and medial temporal lobe activations (D'Esposito *et al.*, 1997; Buchel *et al.*, 1998), lying within posterior cerebral artery territory: the route to semantics through visual recognition remains intact in aphasic patients. The goal in the rehabilitation of aphasic speech comprehension is to enhance access to semantics through auditory cortex. This study has shown that there are two routes in the left hemisphere through which this may be achieved, and the techniques and strategies for each route, whether behavioural or pharmacological, may be quite different. One is through posterior temporal cortex, under the control of dorsolateral prefrontal and premotor cortex. The second is through anterior temporal cortex, often intact in aphasic stroke, resulting in poor comprehension, and reciprocally connected to ventral and inferior prefrontal cortex.

References

- Alexander MP, Hiltbrunner B, Fischer RS. Distributed anatomy of transcortical sensory aphasia. *Arch Neurol* 1989; 46: 885–92.
- Auerbach S, Allard T, Naeser M, Alexander MP, Albert ML. Pure word deafness. Analysis of a case with bilateral lesions and a defect at the prephonemic level. *Brain* 1982; 105: 271–300.
- Belin P, Zatorre RJ, Lafaille P, Ahad P, Pike B. Voice-selective areas in human auditory cortex. *Nature* 2000; 403: 309–12.
- Bell BD, Davies KG, Hermann BP, Walters G. Confrontation naming after anterior temporal lobectomy is related to age of acquisition of the object names. *Neuropsychologia* 2000; 38: 83–92.

- Bell BD, Hermann BP, Woodard AR, Jones JE, Rutecki PA, Seth R, et al. Object naming and semantic knowledge in temporal lobe epilepsy. *Neuropsychology* 2001; 15: 434–43.
- Berthier ML. Unexpected brain–language relationships in aphasia: evidence from transcortical sensory aphasia associated with frontal lobe lesions. *Aphasiology* 2001; 15: 99–130.
- Binder JR, Frost JA, Hammeke TA, Cox RW, Rao SM, Prieto T. Human brain language areas identified by functional magnetic resonance imaging. *J Neurosci* 1997; 17: 353–62.
- Binder JR, Frost JA, Hammeke TA, Bellgowan PS, Rao SM, Cox RW. Conceptual processing during the conscious resting state. A functional MRI study. *J Cogn Neurosci* 1999; 11: 80–95.
- Binder JR, Frost JA, Hammeke TA, Bellgowan PS, Springer JA, Kaufman JN, et al. Human temporal lobe activation by speech and nonspeech sounds. *Cereb Cortex* 2000; 10: 512–28.
- Buchel C, Price C, Friston K. A multimodal language region in the ventral visual pathway. *Nature* 1998; 394: 274–7.
- Buckner RL, Raichle ME, Petersen SE. Dissociation of human prefrontal cortical areas across different speech production tasks and gender groups. *J Neurophysiol* 1995; 74: 2163–73.
- Burnstine TH, Lesser RP, Hart J Jr, Uematsu S, Zinreich SJ, Krauss GL, et al. Characterization of the basal temporal language area in patients with left temporal lobe epilepsy. *Neurology* 1990; 40: 966–70.
- Burton M, Small S, Blumstein S. The role of segmentation in phonological processing: an fMRI investigation. *J Cogn Neurosci* 2000; 12: 679–90.
- Caplan D, Alpert N, Waters G. PET studies of syntactic processing with auditory sentence presentation. *Neuroimage* 1999; 9: 343–51.
- Chan D, Fox NC, Scahill RI, Crum WR, Whitwell JL, Leschziner G, et al. Patterns of temporal lobe atrophy in semantic dementia and Alzheimer's disease. *Ann Neurol* 2001; 49: 433–42.
- D'Esposito M, Detre JA, Aguirre GK, Stallcup M, Alsop DC, Tippet LJ, et al. A functional MRI study of mental image generation. *Neuropsychologia* 1997; 35: 725–30.
- Damasio H, Grabowski TJ, Tranel D, Hichwa RD, Damasio AR. A neural basis for lexical retrieval. *Nature* 1996; 380: 499–505.
- Dapretto M, Bookheimer S. Form and content: dissociating syntax and semantics in sentence comprehension. *Neuron* 1999; 24: 427–32.
- De Renzi E, Zambolin A, Cristi G. The pattern of neuropsychological impairment associated with left posterior cerebral artery infarcts. *Brain* 1987; 110: 1099–116.
- Demb JB, Desmond JE, Wagner AD, Vaidya CJ, Glover GH, Gabrieli JD. Semantic encoding and retrieval in the left inferior prefrontal cortex: a functional MRI study of task difficulty and process specificity. *J Neurosci* 1995; 15: 5870–8.
- Demonet J-F, Chollet F, Ramsay S, Cardebat D, Nespoulous J-D, Wise R, et al. The anatomy of phonological and semantic processing in normal subjects. *Brain* 1992; 115: 1753–68.
- Demonet JF, Price C, Wise R, Frackowiak RS. A PET study of cognitive strategies in normal subjects during language tasks. Influence of phonetic ambiguity and sequence processing on phoneme monitoring. *Brain* 1994; 117: 671–82.
- Devlin JT, Russell RP, Davis MH, Price CJ, Wilson J, Moss HE, et al. Susceptibility-induced loss of signal: comparing PET and fMRI on a semantic task. *Neuroimage* 2000; 11: 589–600.
- Galton CJ, Gomez-Anson B, Antoun N, Scheltens P, Patterson K, Graves M, et al. Temporal lobe rating scale: application to Alzheimer's disease and frontotemporal dementia. *J Neurol Neurosurg Psychiatry* 2001; 70: 165–73.
- Grodzinsky Y, Pinango MM, Zurif E, Drai D. The critical role of group studies in neuropsychology: comprehension regularities in Broca's aphasia. *Brain Lang* 1999; 67: 134–47.
- Helmstaedter C, Kurthen M, Linke DB, Elger CE. Right hemisphere restitution of language and memory functions in right hemisphere language-dominant patients with left temporal lobe epilepsy. *Brain* 1994; 117: 729–37.
- Hodges JR, Patterson K, Oxbury S, Funnell E. Semantic dementia. Progressive fluent aphasia with temporal lobe atrophy. *Brain* 1992; 115: 1783–806.
- Hunt R, Page T, Pemberton S. Oxford Reading Tree. Stages 4–6. Oxford: Oxford University Press, 1996.
- Kapur S, Craik FI, Tulving E, Wilson AA, Houle S, Brown GM. Neuroanatomical correlates of encoding in episodic memory: levels of processing effect. *Proc Natl Acad Sci USA* 1994; 91: 2008–11.
- Luders H, Lesser RP, Hahn J, Dinner DS, Morris HH, Wyllie E, et al. Basal temporal language area. *Brain* 1991; 114: 743–54.
- Maeshima S, Kuwata T, Masuo O, Yamaga H, Okita R, Ozaki F, et al. Transcortical sensory aphasia due to a left frontal subcortical haemorrhage. *Brain Inj* 1999; 13: 927–33.
- Mohr JP, Pessin MS, Finkelstein S, Funkenstein HH, Duncan GW, Davis KR. Broca aphasia: pathologic and clinical. *Neurology* 1978; 28: 311–24.
- Mummery CJ, Patterson K, Price CJ, Ashburner J, Frackowiak RS, Hodges JR. A voxel-based morphometry study of semantic dementia: relationship between temporal lobe atrophy and semantic memory. *Ann Neurol* 2000; 47: 36–45.
- Murray EA, Richmond BJ. Role of perirhinal cortex in object perception, memory, and associations. *Curr Opin Neurobiol* 2001; 11: 188–93.
- Neary D, Snowden JS, Gustafson L, Passant U, Stuss D, Black S, et al. Frontotemporal lobar degeneration: a consensus on clinical diagnostic criteria. *Neurology* 1998; 51: 1546–54.
- Nobre AC, McCarthy G. Language-related field potentials in the anterior-medial temporal lobe: II. Effects of word type and semantic priming. *J Neurosci* 1995; 15: 1090–8.
- Papathanassiou D, Etard O, Mellet E, Zago L, Mazoyer B, Tzourio-Mazoyer N. A common language network for comprehension and production: a contribution to the definition of language epicenters with PET. *Neuroimage* 2000; 11: 347–57.
- Perani D, Paulesu E, Galles NS, Dupoux E, Dehaene S, Bettinardi V, et al. The bilingual brain. Proficiency and age of acquisition of the second language. *Brain* 1998; 121: 1841–52.

- Petersen SE, Fox PT, Snyder AZ, Raichle ME. Activation of extrastriate and frontal cortical areas by visual words and word-like stimuli. *Science* 1990; 249: 1041–4.
- Petersson K, Reis A, Askelof S, Castro-Caldas A, Ingvar M. Language processing modulated by literacy: a network analysis of verbal repetition in literate and illiterate subjects. *J Cogn Neurosci* 2000; 12: 364–82.
- Price CJ, Wise RJ, Frackowiak RS. Demonstrating the implicit processing of visually presented words and pseudowords. *Cereb Cortex* 1996; 6: 62–70.
- Raichle ME, Fiez JA, Videen TO, MacLeod A-M, Pardo JV, Fox PT, et al. Practice-related changes in human brain functional anatomy during nonmotor learning. *Cereb Cortex* 1994; 4: 8–26.
- Rauschecker JP. Cortical processing of complex sounds. *Curr Opin Neurobiol* 1998; 8: 516–21.
- Romanski LM, Tian B, Fritz J, Mishkin M, Goldman-Rakic PS, Rauschecker JP. Dual streams of auditory afferents target multiple domains in the primate prefrontal cortex. *Nat Neurosci* 1999; 2: 1131–6.
- Roskies AL, Fiez JA, Balota DA, Raichle ME, Petersen SE. Task-dependent modulation of regions in the left inferior frontal cortex during semantic processing. *J Cogn Neurosci* 2001; 13: 829–43.
- Schaffler L, Luders HO, Morris HH III, Wyllie E. Anatomic distribution of cortical language sites in the basal temporal language area in patients with left temporal lobe epilepsy. *Epilepsia* 1994; 35: 525–8.
- Scott SK, Blank CC, Rosen S, Wise RJ. Identification of a pathway for intelligible speech in the left temporal lobe. *Brain* 2000; 123: 2400–6.
- Spinks, TJ, Jones T, Bloomfield PM, Bailey DL, Miller M, Hogg D, et al. Physical characteristics of the ECAT EXACT3D positron tomograph. *Phys Med Biol* 2000; 45: 2601–18.
- Springer JA, Binder RJ, Hammeke TA, Swanson SJ, Frost JA, Bellgowan PS, et al. Language dominance in neurologically normal and epilepsy subjects. A functional MRI study. *Brain* 1999; 122: 2033–46.
- Thompson-Schill SL, D'Esposito M, Aguirre GK, Farah MJ. Role of left inferior prefrontal cortex in retrieval of semantic knowledge: a reevaluation. *Proc Natl Acad Sci USA* 1997; 94: 14792–7.
- Thompson-Schill SL, D'Esposito M, Kan IP. Effects of repetition and competition on activity in left prefrontal cortex during word generation. *Neuron* 1999; 23: 513–22.
- Trenerry MR. Neuropsychologic assessment in surgical treatment of epilepsy. *Mayo Clin Proc* 1996; 71: 1196–200.
- Tzourio N, Crivello F, Mellet E, Nkanga-Ngila B, Mazoyer B. Functional anatomy of dominance for speech comprehension in left handers vs right handers. *Neuroimage* 1998; 8: 1–16.
- Warren P, Marslen-Wilson W. Continuous uptake of acoustic cues in spoken word recognition. *Percept Psychophys* 1987; 41: 262–75.

Received July 2, 2002. Revised October 24, 2002.

Accepted November 11, 2002