

## Clinical Study

# The Accuracy of Computer-Assisted Implant Surgery Performed Using Fully Guided Templates versus Pilot-Drill Guided Templates

Daniele De Santis,<sup>1</sup> Luciano Malchiodi,<sup>1</sup> Alessandro Cucchi ,<sup>2</sup> Adam Cybulski ,<sup>3</sup> Giuseppe Verlato,<sup>4</sup> Federico Gelpi,<sup>1</sup> and Pier Francesco Nocini<sup>1</sup>

<sup>1</sup>Department of Surgery, Dentistry, Paediatrics and Gynaecology, University of Verona, Italy

<sup>2</sup>Department of Biomedical and Neuromotor Science, University of Bologna, Italy

<sup>3</sup>Institute of Radiology, University of Verona, Verona, Italy

<sup>4</sup>Department of Diagnostics and Public Health, University of Verona, Verona, Italy

Correspondence should be addressed to Alessandro Cucchi; [dr.cucchi@hotmail.com](mailto:dr.cucchi@hotmail.com)

Received 9 August 2018; Accepted 8 January 2019; Published 8 April 2019

Academic Editor: Marília G. de Oliveira

Copyright © 2019 Daniele De Santis et al. This is an open access article distributed under the Creative Commons Attribution License, which permits unrestricted use, distribution, and reproduction in any medium, provided the original work is properly cited.

**Purpose.** Computer-assisted stereolithographically guided surgery allows an ideal implant placement for prosthetic restoration. Two types of stereolithographic templates are currently available: a fully guided template and a pilot-drill guided template. The purpose of this study was (i) to evaluate the accuracy of implant insertion using these types of surgical templates and (ii) to define parameters influencing accuracy. **Materials and Methods.** 20 patients were enrolled and divided into 2 study groups: in group A, implants were placed using CAD-CAM templates with fully guided sleeves; in group B, implants were placed with a template with only pilot-drill guided sleeves. Pre- and postoperative computed tomographies were used to measure differences between final positions of implants and virtually planned positions. Three linear discrepancies (coronal, apical, and depth) and two angular ones (buccolingual and mesiodistal) were measured. Correlations between accuracy and jaws of interest, implant length and diameters, and type of edentulism were also analysed. **Results.** A total of 50 implants were inserted in 15 patients using CAD-CAM templates: 23 implants in group A and 27 in group B. The mean coronal deviations were 1.16 and 1.11 mm ( $P = 0.35$ ), respectively; the mean apical deviations were 1.65 and 1.71 mm ( $P = 0.22$ ); the mean depth deviations were 0.95 and  $-0.68$  mm ( $P = 0.032$ ); the mean buccolingual angular deviations were  $4.16^\circ$  and  $6.72^\circ$  ( $P = 0.042$ ); and the mean mesiodistal ones were  $2.81^\circ$  and  $5.61^\circ$  ( $P = 0.029$ ). In addition, the accuracy was statistically influenced only by implant diameter for coronal discrepancy ( $P = 0.035$ ) and by jaw of interest for mesiodistal angulation ( $P = 0.045$ ). **Conclusion.** Fully guided implant surgery was more accurate than pilot-drill guided surgery for different parameters. For both types of surgery, a safety margin of at least 2mm should be preserved during implant planning to prevent damage to nearby anatomical structures.

## 1. Introduction

Over the past decades, implant dentistry has become widely used to rehabilitate edentulism [1]. Implant success requires precise preoperative planning [2]. The quantity of available bone and the design of the final prosthesis are of fundamental importance in terms of implant longevity [3, 4]. Different techniques have been developed to transfer the ideal implant position (established during planning) to the surgical field, using templates [5].

Early in the era of prosthetically guided surgery, the templates were made by dental technicians and the ideal implant position was chosen with reference to (principally) mechanical and aesthetic factors. Bone volume analysis was the province of the clinician and was performed with the aid of two-dimensional radiographs at the planning stage or evaluated intraoperatively when a mucoperiosteal flap was raised. These limitations were removed by the introduction of three-dimensional (3D) radiographic techniques, 3D implant planning software, and 3D stereolithographic (SLA) printing

[6]. In addition, multislice computed tomography (MSCT) allows detailed preoperative evaluation of neighbouring anatomical structures and bone quantity and quality. Implant planning software matches CT data to wax up information, allowing the clinician to view a 3D image of the jaw when planning implant positioning in terms of bone anatomy and prosthetic rehabilitation. Rapid prototyping techniques make it possible to transfer the virtual implant position to the oral cavity using an SLA template. Several digital planning software suites are available; all of them produce surgical guides based on combinations of drills and sleeves and are generally of two types, facilitating either fully guided or part-guided surgery. The former type guides the surgeon during preparation of the osteotomy and implant placement; the latter type is used only to prepare the implant bed.

The advantages of fully guided techniques are (1) the possibility of implant insertion without raising a mucoperiosteal flap (affording biological benefits) [7, 8]; (2) greater predictability of immediate loading and the possibility of placing a prefabricated prosthesis [9, 10]; (3) improved patient and clinician comfort because of a shorter operative time [11–13]; and (4) easier treatment of patients with other health problems [14, 15]. However, flapless guided surgery is associated with certain drawbacks including (1) a limited view of anatomical structures, (2) the impossibility of managing a flap for aesthetic reasons, (3) the impossibility of correcting implant deviations in either axis or depth, and (4) a reduction in the level of keratinised tissues [16, 17].

Today, a pilot-drill template might be considered a fair compromise between traditional and fully guided surgery, combining the benefits of computer planning with preservation of the freedom afforded to the clinician to adjust the implant inclination and depth to the patient's anatomy after raising a flap. The literature contains many studies on the reliability and accuracy of fully guided implant surgery, but only a few reported studies have analysed discrepancies associated with implant placement using pilot guided techniques [18]. The aim of this prospective study was to evaluate the accuracy of computer-guided implant placement using both a fully guided template and a pilot-drill template produced by NobelBiocare®; we compared the results and defined parameters influencing accuracy.

## 2. Materials and Methods

**2.1. Study Design.** This study was designed as a pilot, non-randomized, parallel-group, double-blinded clinical trial. The study included patients that were referred to Dental and Maxillofacial Clinic, Department of Odontostomatological Surgery, Paediatrics, and Gynaecology of the University of Verona for implant-prosthetic restoration from September 2016 to March 2017. All patients were informed about the study protocol and signed a written informed consent, approved by board members of University of Verona. After enrollment, a unique identification number for data collection and analysis was assigned to each patient.

The inclusion criteria were patient eligible for implant surgery in edentulous areas; a minimal incisal distance of 40 mm between the opposite arches; absence of dental elements

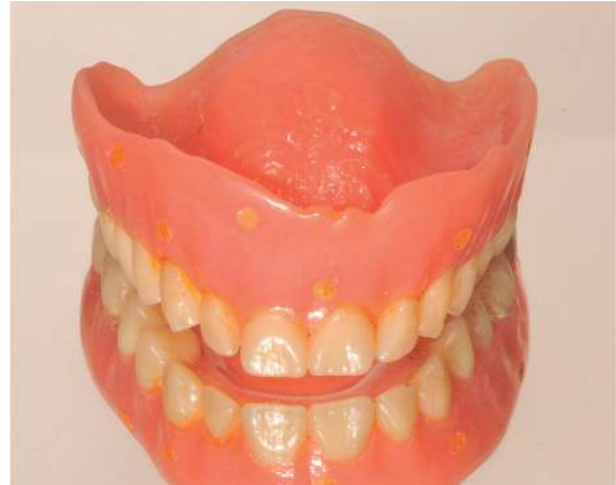

FIGURE 1: Mobile prosthesis adapted with gutta-percha markers.

in the opposite arch obstructing template insertion or the surgical drills; and the presence of adequate keratinised gingiva for proper healing and implant health. The exclusion criteria were bone height < 8 mm; inadequate oral hygiene; smoking habit > 10 cig./day; abuse of alcohol or drugs; pregnancy; local or systemic infection; uncontrolled metabolic disease; severe hepatic or renal dysfunction; HIV, HBV, or HCV; chemotherapy or radiotherapy within the last 5 years; immunosuppression therapy; autoimmune disorders; or bisphosphonate therapy.

Since no previous studies compared the accuracy of computer-assisted implant surgery performed using fully guided templates versus pilot-drill guided templates, the present research was considered a pilot study and no sample size calculation was performed. The number of patients was set at 10 patients for each group.

Consequently, twenty patients were divided into 2 study groups: group A, in which the preparation of implants sites was performed with a fully guided template; and group B, in which the site preparation was accomplished with pilot-drill template.

**2.2. Presurgical Protocol.** Each patient received an orthopantomography (OPG) and a computed tomography (CT) for evaluation of bone volume and planning of implant-supported restoration. All virtual implant planning was performed by the same expert operator, following the manufacture guidelines for guided implant surgery (NobelGuide®, Nobel Biocare Holding AG, Zurich, Switzerland) [19–22]. Radiographic templates were prepared for completely edentulous patients. If a mobile prosthesis was present, this was transformed into a radiographic guide (Figure 1); if not, a new resin-based radiographic guide was fabricated, with a minimum number of six gutta-percha markers included in the prosthesis (Figure 2); a radiographic bite index of condensed silicone was included (Figure 3); successively, a CT of the patient with the radiographic guide stabilized in the correct intraoral position with reference to the bite index was taken; finally, a second CT scan using the same parameters

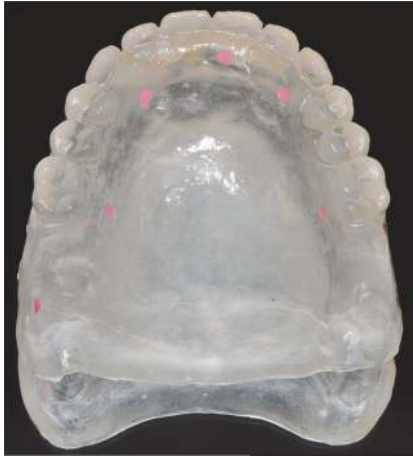

FIGURE 2: Radiographic template in transparent acrylic resin with gutta-percha markers.

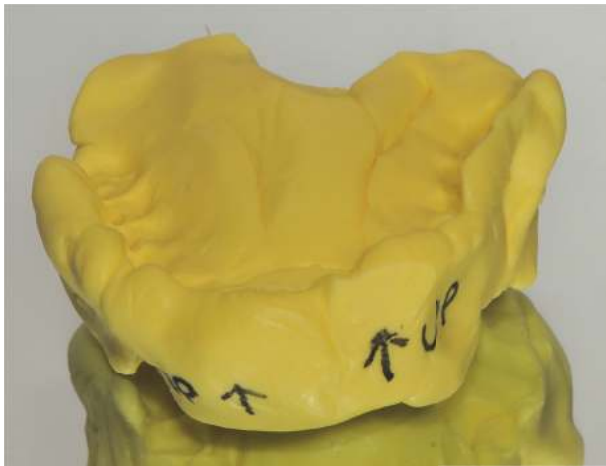

FIGURE 3: Bite index in condensation silicone.

was made of the scan template, using the “Double Scan Technique” [23]. The DICOM files obtained were uploaded to software and matched using the fiducial radiopaque markers (Nobelclinical®, Nobel Biocare Holding AG, Zurich, Switzerland).

For partially edentulous patients, anatomical features were acquired with a CT scan. In terms of prosthetic details, a technician prepared a removable wax-up on the master cast. Next, the technician scanned the models with and without the wax-up using a laboratory scanner (NobelProcera 2G System®, Nobel Biocare Holding AG, Zurich, Switzerland). DICOM files from the CT scan and *.nxa* files from the scans of the waxed-up models were uploaded to the planning software and matched via their corresponding anatomical features (SmartFusion® technique, Nobel Biocare Holding AG, Zurich, Switzerland).

For every dataset, the implants were virtually planned in the optimal prosthetic and anatomical positions. Particularly, the need for a 2-mm safety margin to protect all anatomical structures and the cortical bone walls was

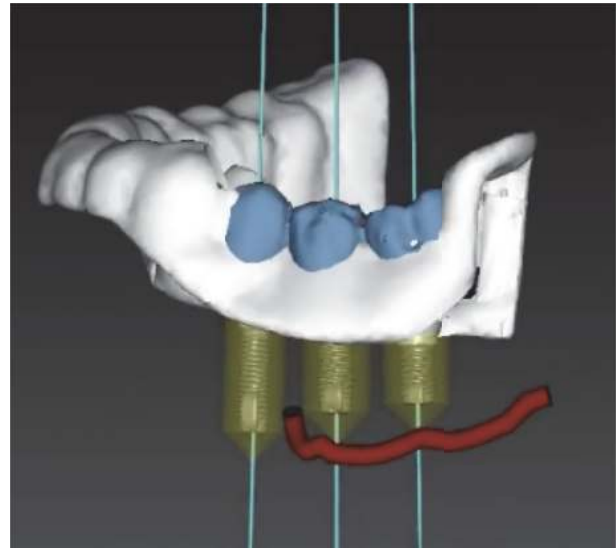


FIGURE 4: Safety distance of 2 mm around planned implant.

respected (Figure 4). A minimum of three anchor pins were placed in completely edentulous patients to ensure stability of the surgical template during implantation: anchor pins were usually placed in sites of central incisor and first premolars, on the buccal side; additional pins were placed in sites of canine or first molar, if possible. This was not necessary in partially edentulous patients because the teeth stably supported the guide. After review of the 3D rendering of the surgical guide, the guide was printed using the SLA process.

**2.3. Surgical Protocol.** One hour before surgery, patients were administered 2 g of amoxicillin for antibiotic prophylaxis. All surgeries were performed under local anaesthesia with 4% articaine and epinephrine 1:100.000.

In completely edentulous patients, the surgical guide was correctly positioned using a surgical index and was fixed with 3 anchor pins prior to the surgery; in partially edentulous patients, the guide was positioned over the natural teeth and was stabilized using anchor pins.

In group A (fully guided surgery), the preparation of implants sites were accomplished using all surgical drills and relative metal reducers needed to adapt the drill diameter to the metal sleeves; implants were similarly placed using guided implant mount and related adapter. In group B (pilot-drill guided surgery), the site osteotomy started with the surgical guide with 2-mm diameter sleeves; after that, the guide was removed and the osteotomy continued without guide using sequentially the remaining drills; similarly, implants were placed without surgical guide (Figure 5). The implants used were characterized by a double-variable thread self-drilling and self-tapping expanding tapered design with oxidized surface (NobelActive, Nobel Biocare Holding AG, Zurich, Switzerland). The manufacturer provides implant diameter from 3 to 5 mm and implant length from 7 to 18 mm, but only implants ranging between 8.5 and 15 mm were used in the present study.

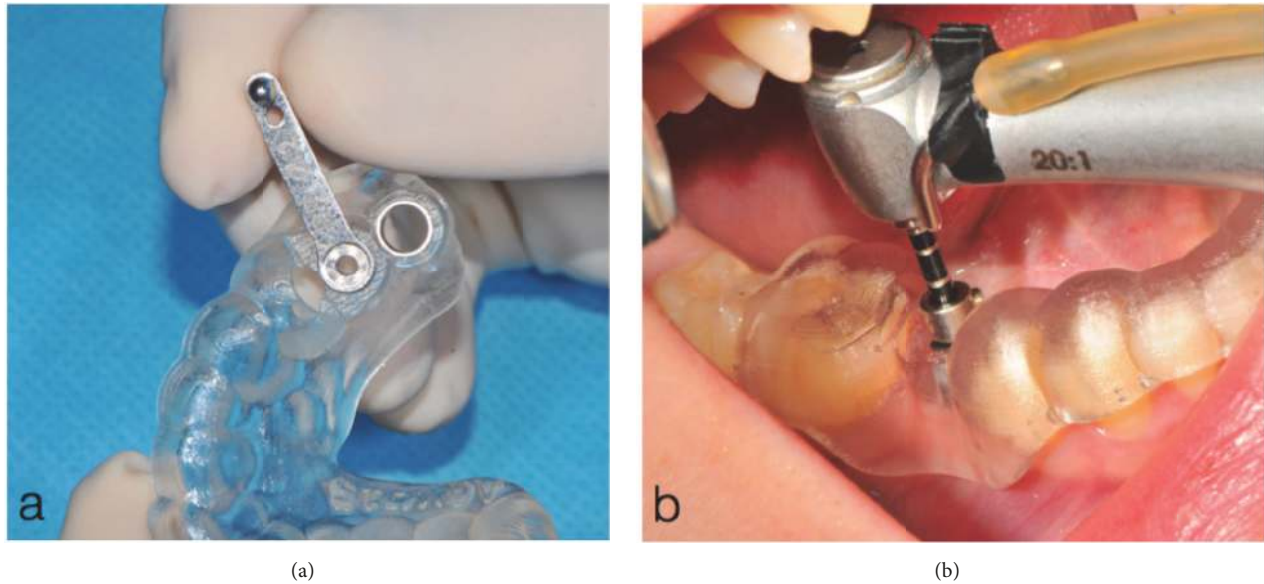


FIGURE 5: (a) Metal reducer inserted in the sleeve within the full guided template and (b) the pilot-drill template during the first osteotomy.

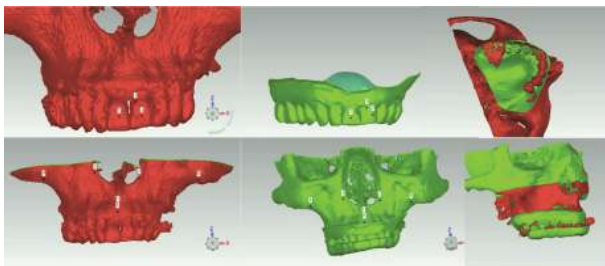


FIGURE 6: Different virtual images superimposed using corresponding anatomical markers.

Since all implants were placed with a flapless approach, sutures were not necessary and healing screws were placed for soft tissue healing. Patients were instructed to rinse three times a day with chlorhexidine 0.2% and to assume amoxicillin 1g three times a day for 4 days.

**2.4. Superimposition and Variables.** A digital method was employed to superimpose the postoperative MSCT on the preoperative MSCT used for virtual planning. For every patient, physical components such as the master model, the radiographic template, the surgical template, and the surgical drills were scanned to obtain virtual volumes (Laser 3Shape Wieland D200; 3Shape®, Copenhagen, Denmark). The DICOM data of the pre- and postoperative CTs were segmented (Slicer 3D 4.0) to obtain 3D reconstructions of the jaws with the fiducial markers and the intrabony implants. As the 3D axes varied, it was necessary to normalise the virtual images exploiting common anatomical landmarks before analysing discrepancies (Geomagic WRAP 2016, Research Triangle Park, NC, USA) (Figure 6). From the single-image package obtained for each patient, it was possible to calculate differences between the planned and actual parameters



FIGURE 7: Reconstruction of virtual drills inside the sleeves to reproduce the planned implant.

(RhinoCeros® 4.0; McNeel Europe, Barcelona, Spain). The actual parameters were derived from postoperative CT scans whereas the planned parameters were acquired from the surgical template. The surgical drills were virtually positioned inside sleeves within the guides and the geometries of the virtual implants reproduced along the drill axis 9 mm from the coronal margins of the sleeves (Figure 7).

For each implants the following variables were collected and analysed by a single blinded operator before and after computer-assisted surgery: (1) C-L: coronal linear deviation (distance between the coronal centre of the planned and the placed implant); (2) A-L: apical linear deviation (distance between the apical centre of the planned and placed implant); (3) D-L: depth linear deviation (distance between the coronal centre of the planned implant and a straight line orthogonal to the longitudinal axis of the implant, passing through the coronal centre of the placed implant); (4) BL-A: buccolingual angular deviation (angle made by the axes of the planned and placed implants, measured on the plane transverse to the arch curvature); (5) MD-A: mesiodistal angular deviation (angle made by the axes of the planned and placed implants, measured on the plane tangent to the arch curvature) (Figures 8 and 9).

**2.5. Statistical Analysis.** Each patient was considered in terms of the number of implants received. Each planned and actual implant was compared in terms of the above-mentioned

TABLE 1: Patients and treatment characteristics.

N° of subjects (n=15)	Group A	7
	Group B	8
N° of implants (n=50)	Group A	23
	Group B	27
Gender	Male	7
	Female	8
Type of edentulism	Total edentulism	29
	Partial edentulism	23
Type of arch	Upper jaw	29
	Lower jaw	21
Implant length	< 11 mm	11
	> 11 mm	39

TABLE 2: Patients and treatment characteristics for group A (fully guided templates) and for group B (pilot-drill guided templates).

	Group A (fully)	Group B (pilot)
N of subject (n=15)	7	8
N of implants (n=50)	23	27
Gender: male (n=7)	3	4
Gender: female (n=8)	4	4
Type of edentulism: total (n=29)	9	20
Type of edentulism: partial (n=23)	14	9
Type of arch: upper (n=29)	15	14
Type of arch: lower (n=21)	8	13
Implant length: <11,5 (n=11)	6	5
Implant length: >11,5 (n=39)	17	22

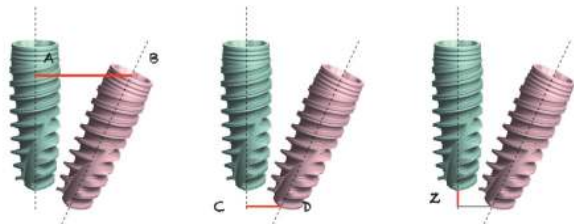


FIGURE 8: Depiction of linear deviation parameters examined.

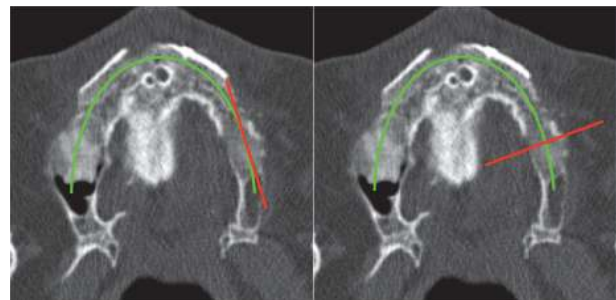


FIGURE 9: Depiction of angular deviation parameters examined.

variables. These 5 quantitative variables were used to observe the accuracy of the 2 types of surgical guides. The qualitative variables, including jaw of interest (mandible/maxilla), type of edentulism (partial/complete), implant length (8.5, 10, 11.5, 13, 15 mm), and implant diameter (3, 3.5, 4.3, and 5 mm), were analysed to identify significant correlations to the implant accuracy. Data were analysed by a single blinded statistician using statistical software (Stata® software, StataCorp, College Station, TX, USA). The nonparametric Wilcoxon-Mann-Whitney test was used to observe significant differences between the 2 study groups while Spearman tests were used to identify significant variables related to the discrepancies. Since no similar studies were published comparing fully guided templates versus pilot-drill guided templates, sample

size was fixed at 10 patients for each group. The level of significance was set to  $\alpha < 0.05$ .

### 3. Results

In total, 15 patients out of 20 patients were treated (mean age = 54.7 years; 7 males, 8 females; 9 upper jaws, 6 lower jaws). 50 implants were inserted using the CAD-CAM templates: 23 implants in 7 patients for group A and 27 implants in 8 patients for group B. Patient and treatment characteristics were reported in Tables 1 and 2. Two patients were excluded from the study because they referred bisphosphonates therapy the day of surgery; one patient was excluded because of

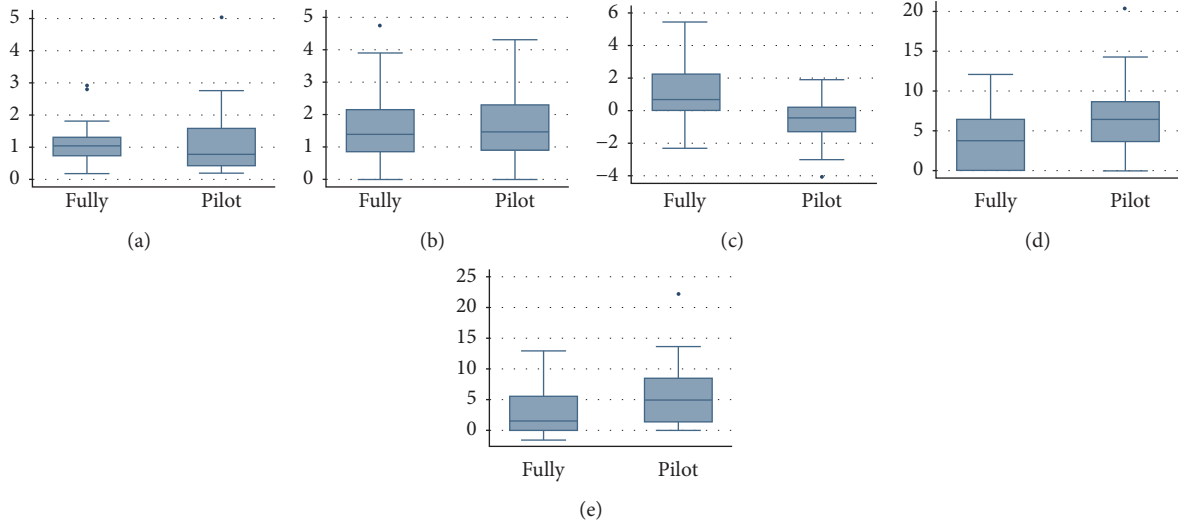


FIGURE 10: Box and whisker plot graphic of (a) coronal, (b) apical, (c) depth, (d) buccolingual angular, and (e) mesiodistal angular deviations.

TABLE 3: Overall deviation values of guided-assisted implant surgery.

	Mean	SD	Min	Max
Coronal linear deviation (mm)	1.13	0.89	0.19	5.04
Apical linear deviation (mm)	1.68	1.13	0.0	4.75
Depth linear deviation (mm)	0.07	1.70	0.0	5.42
Buccolingual angular deviation (°)	5.55	4.38	0.0	20.37
Mesiodistal angular deviation (°)	4.33	4.81	0.0	22.25

TABLE 4: Deviation values between planned and placed implants in the 2 study groups.

	Fully drill guided		Pilot drill guided		P-value
	Mean ± SD	Range (min-max)	Mean ± SD	Range (min-max)	
Coronal Linear deviation (mm)	1.16 ± 0.68	0.19 - 2.92	1.11 ± 1.05	0.20 - 5.04	P=0.35
Apical Linear Deviation (mm)	1.65 ± 1.17	0.0 - 4.75	1.70 ± 1.12	0.0 - 4.31	P=0.22
Depth Linear Deviation (mm)	0.95 ± 1.70	0.0 - 5.42	-0.68 ± 1.31	0.0 - 4.11	P=0.032 *
Buccolingual Angular deviation (°)	4.16 ± 3.59	0.0 - 12.05	6.73 ± 4.70	0.0 - 20.37	P=0.042 *
Mesiodistal Angular deviation (°)	2.81 ± 3.89	0.0 - 13.02	5.62 ± 5.19	0.0 - 22.25	P=0.029 *

impossibility to stabilized surgical guide due to poor bone quality; and two patients were excluded because of the refusal of postoperative MSCT.

The mean coronal deviation between the planned and placed implants was 1.16 and 1.11 mm for fully guided surgery (groups A) and pilot-drill guided surgery (group B), respectively; the mean apical deviation was 1.65 mm and 1.71 mm; the mean depth deviation was 0.95 mm and -0.68 mm; the mean buccolingual angular deviation was 4.16° and 6.72°; and the mean mesiodistal angular deviation was 2.81° and 5.61° (Figure 10).

The nonparametric Wilcoxon-Mann-Whitney rank-sum test revealed a statistically significant difference between fully guided and pilot-drill guided surgery in terms of depth deviation, buccolingual angular deviation, and mesiodistal angular deviation, whereas the differences between the coronal and

apical deviations were not statistically significant. Mean, SD, range, and P-values were reported in Tables 3 and 4.

Correlation tests revealed that jaw of interest significantly influenced the mesiodistal angular deviation (P=0.035), with better accuracy in the lower jaw than upper jaw. Moreover, slight differences were observed for apical deviation and buccolingual angular deviation (P=0.055 and P=0.062). To underline that in the upper jaw, mean values for group A were constantly better than group B (P<0.001).

According to the type of edentulism, overall computer-guided surgery seemed to be more accurate in partially edentulous patients compared to totally edentulous patients, with statistical differences for depth linear deviation and buccolingual angular deviation (P=0.049 and P=0.037, respectively), while other parameters did not show significant differences (P=0.061, P=0.053, and P=0.071). No significant differences

TABLE 5: Mean values of accuracy according to implant diameter.

	3-mm diameter	3.5-mm diameter	4.3-mm diameter	5-mm diameter	P-value
Coronal Linear deviation (mm)	0.78 ± 0.46	1.11 ± 0.37	1.64 ± 0.71	2.92 ± 0.27	P=0.045 *
Apical Linear Deviation (mm)	2.00 ± 0.60	0.71 ± 0.75	1.60 ± 1.24	3.91 ± 0.31	P=0.32
Depth Linear Deviation (mm)	0.26 ± 1.21	1.20 ± 1.52	0.43 ± 0.7	0.54 ± 0.29	P=0.18
Buccolingual Angular deviation (°)	7.24 ± 2..90	1.47 ± 1.75	3.45 ± 2.81	1.32 ± 0.12	P=0.84
Mesiodistal Angular deviation (°)	2.12 ± 2.55	2.03 ± 1.89	2.76 ± 0.62	5.03 ± 0.44	P=0.068

were observed between the 2 groups in relation to the type of edentulism ( $P>0.01$ ).

Moreover, implant length influenced the accuracy of all parameters, where implants longer than 11 mm showed higher values than those shorter than 11mm, but no strong statistical correlations were observed ( $P>0.1$ ).

Finally, a strong correlation was observed between diameter and coronal linear deviation ( $P>0.036$ ). Increase of diameter constantly increases the coronal discrepancy, resulting in a statistically significant difference ( $P=0.045$ ). Mean values were reported in Table 5.

#### 4. Discussion

Current guided-surgery software allows clinicians to optimise 3D implant positioning, observing anatomical limitations and affording successful prosthetic rehabilitation. Guided implant surgery templates help the clinician to transfer virtually planned surgery to well-established implant procedures. However, discrepancies between virtually planned and real parameters are well documented in the literature. To the best of recent knowledge, all reported in vivo data are comparable to the present results. A recent work [24] reported mean values of 1.32 mm (range 0.88–1.68 mm) for coronal deviation and 1.52 mm (range 1.16–1.98 mm) for apical deviation and identified factors influencing accuracy during data acquisition. Another retrospective study used the same implant system [25]: the mean apical deviation was 1.09 mm (range: 0.24–3.62), the mean coronal deviation 0.80 mm (range: 0.10–2.68), the mean depth deviation  $-0.15$  mm (range: 2.33–2.05), and the mean angle deviation  $2.26^\circ$  (range: 0.24–11.74). Cassetta et al. reported [26] that the mean global deviation at the shoulder of the implant was  $1.47 \pm 0.68$  mm and  $1.83 \pm 1.03$  mm at the apex and the mean angular deviation  $5.09 \pm 3.70^\circ$ . The first two cited studies featured fully guided surgery and the last featured final implant insertion without a surgical template.

These results are similar to those of a recent systematic review [27] analysing only fully guided in vivo surgeries: 1.04 mm (range 0.85–1.24) for coronal deviation, 1.45 mm (range 1.18–1.73) for apical deviation, and  $4.06^\circ$  (range 3.50–4.62) for angular deviation. The cited review did not consider in vitro or ex vivo studies because the relevant factors would differ from those of clinical studies [28, 29]. Here, we evaluated several variables in terms of the accuracy of implant placement. The accuracy of upper jaw surgery was better than that of lower jaw surgery in terms of deviations in three parameters, explained by the lower bone density and the larger supporting surface of the maxilla. Similar results

were found in two earlier studies [25, 30], but a systematic review [31] found no differences and two other studies [32, 33] found that lower jaw accuracy was better. Implant placement in partially edentulous patients was found somewhat more accurate than in fully edentulous patients in terms of all deviation parameters, but statistical significance was not attained. This may be explained by the stability of supporting tissues: teeth in the first group but only mucosa in the second one. Similar results have been reported in the literature [34, 35]. In addition, a recent systematic review [36] found that tooth-supported guides were better than bone- and mucosa-supported guides, although statistical significance was not apparent. Another difference between our partially and fully edentulous patients was the data acquisition mode (SmartFusion for the former but the less accurate double-scan mode for the latter) [37]. We also found that implants shorter than 11 mm were associated with smaller deviations than longer implants in terms of all parameters except depth; similar results have been reported in the literature [14, 37, 38].

It has been reported [39] that guided implant surgery greatly improved implant placement accuracy compared with traditional implant surgery; guided surgery competently deals with a complex anatomy, is minimally invasive, aesthetically sensitive, and affords immediate loading. Despite the excellent accuracy, fully guided surgery cannot be applied in all clinical situations. Counter indications are the high cost, an insufficient interocclusal distance, insufficient space between the remaining teeth to allow placement of a fully guided surgical sleeve, the impossibility of correcting the bone crest or regeneration of intrabony defects when a flapless procedure is performed, the need for soft tissue management in the aesthetic zone, and a deficiency of keratinised tissue.

The recently introduced pilot-drill template may be useful in such situations. This template features guide sleeves for only 2-mm pilot drills; the osteotomy is completed and the implant inserted by the clinician. Pilot-drill template-guided surgery represents a compromise between fully guided surgery and traditional implant surgery, preserving the benefits of both techniques (transfer of the implant to the planned position and correct inclination within the surgical field; raising of a flap, and implant placement while monitoring the anatomical borders). However, the benefits of flapless surgery are lost [7]. Moreover, open flap surgery allows the clinician to place the implant under the crestal margin of the bone.

We compared pilot-drill guided and fully guided surgery; the accuracy of the former surgery was lower in terms of depth and angular deviations. In particular, the mean depth

deviation was 0.95 mm more superficial than the planned depth in the fully guided group, but 0.68 mm deeper in the pilot-drill group. This is obviously attributable to the absence of drill stops during the former surgery. In addition, the marginal positioning of implants in the fully guided group may reflect surgical prudence during flapless osteotomy and implant insertion. Moreover, the deeper positioning in the pilot-drill group may reflect an intraoperative decision to insert an implant subcrestally or to impart adequate torque. The significantly higher discrepancy in angular deviation evident in the pilot-drill group may also be explained by the fact that all osteotomies and implant placements were performed without guidance.

One *ex vivo* study analysed the accuracies of implant placement via half-guided and fully guided surgery [40]. Unlike our approach, all osteotomies were template-guided; only implant placement was not. Overall, fully guided surgery was somewhat more accurate than half-guided surgery, but the differences were not significant. Only two *in vivo* studies have explored the accuracy of pilot-drill guided surgery [41, 42]. Both found higher discrepancies in the pilot-drill template group than in the fully guided group. One study analysed depth and lateral deviations in particular, reporting significantly lower accuracy in the pilot-drill group than in the fully guided group in terms of depth and global lateral and mesiodistal deviations. The other study reported statistically significant differences between a pilot-drill group and a fully guided group in terms of coronal, apical, and angular deviations; accuracy was better in the fully guided group. Similar outcomes were reported in a recent systematic review [18] comparing the accuracy of half-guided and fully guided *in vivo* studies. The global mean deviations were  $1.10 \pm 0.09$  mm at the shoulder,  $1.40 \pm 0.12$  mm at the apex,  $0.74 \pm 0.103$  mm in terms of depth, and  $3.98 \pm 0.33^\circ$  in terms of angular deviation. The deviations were greater for half-guided surgery, and the differences in angular and apical deviations were statistically significant.

The limits of the present study were the small number of included patients and the great deal of subjectivity in the pilot-drill group. Although the “hand” of the operator is decisive in the occurrence of some deviation from the expected outcomes, these results can be useful for sample size calculation of further studies, establishing a minimum number of patients based on a statistical test to draw relevant conclusions. However, the major limit of this study is the lack of randomization that reduces the relevance of results. Randomized clinical trials must be completed to confirm the differences between the 2 computer-assisted approaches. Another limit is obviously the impossibility to have a blinded operator during surgical procedures, which can influence the accuracy in the pilot-drill group due to expertise, capability, or preference.

Computer-aided implant surgery affords excellent accuracy and implant survival, allowing precise implant placement using an SLA surgical template. However, total absence of error is not guaranteed.

For this reason, the EAO Consensus Conference of 2012 [43] recommended safety margins of 1.2 mm coronally and 0.5 mm vertically and emphasised that

early stage implant clinicians must climb a learning curve.

However, the deviation of placed from planned implants was larger when pilot-drill guided surgery was used and, as reported at the 4th EAO Consensus Conference of 2015 [44], guided implant placement was more accurate than freehand placement, both performed after fully guided osteotomy. We finally recommend that a safety margin of at least 2 mm should be respected to prevent damage to nearby anatomical structures. Further clinical studies are needed.

Since the results found that several variables influence the accuracy of implant placement (jaw of interest, type of edentulism, supporting-guide tissue, implant length and diameter), the fully guided implant surgery technique should be preferred when influencing factors are not favourable.

The pilot-drill guided technique has shown similar results in almost all variables and could be suggested as reliable surgical guide in simple cases and a useful prosthetic guide in other cases. Considering the overall accuracy of both computer-guided surgeries, these techniques should be chosen for more difficult cases only if influencing factors are favourable.

The authors could suggest the pilot-drill guided surgery when (1) coronal osteoplasty is required; (2) flap-raising is essential to improve the view near important anatomical structures; (3) soft tissue plastic surgery is needed; (4) implantation under crestal bone is planned; (5) keratinised tissue is sparse; (6) a bone-regeneration procedure is required; (7) an implant is to be placed near remaining teeth; and (8) the interocclusal distance is insufficient.

## 5. Conclusions

The pilot-drill guided technique has shown similar results in almost all variables and could be suggested as reliable surgical guide in simple cases and a useful prosthetic guide in other cases. Considering the overall accuracy of both computer-guided surgeries, these techniques should be chosen for more difficult cases only if influencing factors are favourable.

## Data Availability

The data used to support the findings of this study are available from the corresponding author upon request.

## Conflicts of Interest

The authors declare that they have no conflicts of interest.

## Acknowledgments




The authors wish to thank doctors Simone Marconcini, Damiano Formentini, and Marco Minniti for their invaluable assistance and support during the developing of this work. The English language in this document has been checked by at least two professional editors, both native speakers. For a certificate, please see <http://www.textcheck.com/certificate/zMWfPf>.



## References

- [1] T. Albrektsson, L. Sennerby, and A. Wennerberg, "State of the art of oral implants," *Periodontology 2000*, vol. 47, no. 1, pp. 15–26, 2008.
- [2] T. Tanner, "Treatment planning for dental implants: considerations, indications, and contraindications," *Dental Update*, vol. 24, no. 6, pp. 253–260, 1997.
- [3] P. F. Nocini, D. De Santis, F. Ferrari, and G. P. Bertele, "A customized distraction device for alveolar ridge augmentation and alignment of ankylosed teeth," *The International Journal of Oral & Maxillofacial Implants*, vol. 19, no. 1, pp. 133–144, 2004.
- [4] D. De Santis, A. Cucchi, G. Rigoni, and C. Longhi, "Short implants with oxidized surface in posterior areas of atrophic jaws: 3- to 5-year results of a multicenter study," *Clinical Implant Dentistry and Related Research*, vol. 17, no. 3, pp. 442–452, 2015.
- [5] K. M. D'Souza and M. A. Aras, "Types of implant surgical guides in dentistry: a review," *Journal of Oral Implantology*, vol. 38, no. 5, pp. 643–652, 2012.
- [6] A. Azari and S. Nikzad, "Computer-assisted implantology: historical background and potential outcomes - a review," *The International Journal of Medical Robotics and Computer Assisted Surgery*, vol. 4, no. 2, pp. 95–104, 2008.
- [7] A. G. Sclar, "Guidelines for flapless surgery," *Journal of Oral and Maxillofacial Surgery*, vol. 65, no. 7, pp. 20–32, 2007.
- [8] F. Vohra, A. A. Al-Kheraif, K. Almas, and F. Javed, "Comparison of crestal bone loss around dental implants placed in healed sites using flapped and flapless techniques: a systematic review," *Journal of Periodontology*, vol. 86, no. 2, pp. 185–191, 2015.
- [9] P. Maló, M. De Araújo Nobre, A. Lopes, C. Francischone, and M. Rigolizzo, "'All-on-4' immediate-function concept for completely edentulous maxillae: a clinical report on the medium (3 years) and long-term (5 years) outcomes," *Clinical Implant Dentistry and Related Research*, vol. 14, no. 1, pp. e139–e150, 2012.
- [10] A. Lopes, P. Maló, M. de Araújo Nobre, E. Sánchez-Fernández, and I. Gravito, "The nobelGuide® all-on-4® treatment concept for rehabilitation of edentulous jaws: a retrospective report on the 7-years clinical and 5-years radiographic outcomes," *Clinical Implant Dentistry and Related Research*, vol. 19, no. 2, pp. 233–244, 2017.
- [11] V. Arisan, C. Z. Karabuda, and T. Özdemir, "Implant surgery using bone- and mucosa-supported stereolithographic guides in totally edentulous jaws: surgical and post-operative outcomes of computer-aided vs. standard techniques," *Clinical Oral Implants Research*, vol. 21, no. 9, pp. 980–988, 2010.
- [12] E. Nkenke, S. Eitner, M. Radespiel-Tröger, E. Vairaktaris, F. W. Neukam, and M. Fenner, "Patient-centred outcomes comparing transmucosal implant placement with an open approach in the maxilla: a prospective, non-randomized pilot study," *Clinical Oral Implants Research*, vol. 18, no. 2, pp. 197–203, 2007.
- [13] T. Fortin, J. L. Bosson, M. Isidori, and E. Blanchet, "Effect of flapless surgery on pain experienced in implant placement using an image-guided system," *The International Journal of Oral & Maxillofacial Implants*, vol. 21, no. 2, pp. 298–304, 2006.
- [14] J. D'Haese, T. van de Velde, A. Komiyama, M. Hultin, and H. de Bruyn, "Accuracy and complications using computer-designed stereolithographic surgical guides for oral rehabilitation by means of dental implants: a review of the literature," *Clinical Implant Dentistry and Related Research*, vol. 14, no. 3, pp. 321–335, 2012.
- [15] D. De Santis, L. Trevisiol, A. Cucchi, L. C. Canton, and P. F. Nocini, "Zygomatic and maxillary implants inserted by means of computer-assisted surgery in a patient with a cleft palate," *The Journal of Craniofacial Surgery*, vol. 21, no. 3, pp. 858–862, 2010.
- [16] M.-M. Romero-Ruiz, R. Mosquera-Perez, J.-L. Gutierrez-Perez, and D. Torres-Lagares, "Flapless implant surgery: a review of the literature and 3 case reports," *Journal of Clinical and Experimental Dentistry*, vol. 7, no. 1, pp. e146–e152, 2015.
- [17] P. F. Nocini, R. Castellani, G. Zanotti et al., "Extensive keratinized tissue augmentation during implant rehabilitation after le fort I osteotomy: using a new porcine collagen membrane (Mucoderm)," *The Journal of Craniofacial Surgery*, vol. 25, no. 3, pp. 799–803, 2014.
- [18] F. Bover-Ramos, J. Viña-Almunia, J. Cervera-Ballester, M. Peñarocha-Diago, and B. García-Mira, "Accuracy of implant placement with computer-guided surgery: a systematic review and meta-analysis comparing cadaver, clinical, and in vitro studies," *The International Journal of Oral & Maxillofacial Implants*, vol. 33, no. 1, pp. 101–115, 2018.
- [19] P. F. Nocini, R. Castellani, G. Zanotti, D. Bertossi, U. Luciano, and D. De Santis, "The use of computer-guided flapless dental implant surgery (NobelGuide) and immediate function to support a fixed full-archprosthesis in fresh-frozen homologous patients with bone grafts," *The Journal of Craniofacial Surgery*, vol. 24, no. 6, pp. e551–e558, 2013.
- [20] P. F. Nocini, M. Albanese, R. Castellani et al., "Application of the 'all-on-four' concept and guided surgery in a mandible treated with a free vascularized fibula flap," *The Journal of Craniofacial Surgery*, vol. 23, no. 6, pp. e628–e631, 2012.
- [21] D. De Santis, L. Malchiodi, A. Cucchi, L. C. Canton, L. Trevisiol, and P. F. Nocini, "Computer-assisted surgery: double surgical guides for immediate loading of implants in maxillary postextractive sites," *The Journal of Craniofacial Surgery*, vol. 21, no. 6, pp. 1781–1785, 2010.
- [22] D. De Santis, L. C. Canton, A. Cucchi, G. Zanotti, E. Pistoia, and P. F. Nocini, "Computer-assisted surgery in the lower jaw: double surgical guide for immediately loaded implants in postextractive sites-technical notes and a case report," *Journal of Oral Implantology*, vol. 36, no. 1, pp. 61–68, 2010.
- [23] D. van Steenberghe, R. Glauser, U. Blombäck et al., "A computed tomographic scan-derived customized surgical template and fixed prosthesis for flapless surgery and immediate loading of implants in fully edentulous maxillae: a prospective multicenter study," *Clinical Implant Dentistry and Related Research*, vol. 7, supplement 1, pp. S111–S120, 2005.
- [24] T. Testori, M. Robiony, A. Parenti et al., "Evaluation of accuracy and precision of a new guided surgery system: a multicenter clinical study," *International Journal of Periodontics and Restorative Dentistry*, vol. 34, pp. 58–69, 2014.
- [25] A. Pettersson, A. Komiyama, M. Hultin, K. Näsström, and B. Klinge, "Accuracy of virtually planned and template guided implant surgery on edentate patients," *Clinical Implant Dentistry and Related Research*, vol. 14, no. 4, pp. 527–537, 2012.
- [26] M. Cassetta, L. V. Stefanelli, M. Giansanti, and S. Calasso, "Accuracy of implant placement with a stereolithographic surgical template," *The International Journal of Oral & Maxillofacial Implants*, vol. 27, no. 3, pp. 655–663, 2012.
- [27] A. Tahmaseb, D. Wismeijer, W. Coucke, and W. Derksen, "Computer technology applications in surgical implant dentistry: a systematic review," *The International Journal of Oral & Maxillofacial Implants*, vol. 29, pp. 25–42, 2014.

- [28] A. Pettersson, T. Kero, L. Gillot et al., "Accuracy of CAD/CAM-guided surgical template implant surgery on human cadavers: part I," *Journal of Prosthetic Dentistry*, vol. 103, no. 6, pp. 334–342, 2010.
- [29] N. Van Assche, D. Van Steenberghe, M. E. Guerrero et al., "Accuracy of implant placement based on pre-surgical planning of three-dimensional cone-beam images: a pilot study," *Journal of Clinical Periodontology*, vol. 34, no. 9, pp. 816–821, 2007.
- [30] M. Cassetta, L. V. Stefanelli, M. Giansanti, A. Di Mambro, and S. Calasso, "Depth deviation and occurrence of early surgical complications or unexpected events using a single stereolithographic surgi-guide," *International Journal of Oral and Maxillo-facial Surgery*, vol. 40, no. 12, pp. 1377–1387, 2011.
- [31] N. van Assche, M. Vercruyssen, W. Coucke, W. Teughels, R. Jacobs, and M. Quirynen, "Accuracy of computer-aided implant placement," *Clinical Oral Implants Research*, vol. 23, supplement 6, pp. 112–123, 2012.
- [32] O. Ozan, K. Orhan, and I. Turkyilmaz, "Correlation between bone density and angular deviation of implants placed using CT-generated surgical guides," *The Journal of Craniofacial Surgery*, vol. 22, no. 5, pp. 1755–1761, 2011.
- [33] G. A. Di Giacomo, J. V. Da Silva, A. M. Da Silva, G. H. Paschoal, P. R. Cury, and G. Szarf, "Accuracy and complications of computer-designed selective laser sintering surgical guides for flapless dental implant placement and immediate definitive prosthesis installation," *Journal of Periodontology*, vol. 83, no. 4, pp. 410–419, 2012.
- [34] A. E. Ersoy, I. Turkyilmaz, O. Ozan, and E. A. McGlumphy, "Reliability of implant placement with stereolithographic surgical guides generated from computed tomography: clinical data from 94 implants," *Journal of Periodontology*, vol. 79, no. 8, pp. 1339–1345, 2008.
- [35] C. Vasak, G. Watzak, A. Gahleitner, G. Strbac, M. Schemper, and W. Zechner, "Computed tomography-based evaluation of template (NobelGuide™)-guided implant positions: a prospective radiological study," *Clinical Oral Implants Research*, vol. 22, no. 10, pp. 1157–1163, 2011.
- [36] Y. N. Raico Gallardo, I. R. T. da Silva-Olivio, E. Mukai, S. Morimoto, N. Sesma, and L. Cordaro, "Accuracy comparison of guided surgery for dental implants according to the tissue of support: a systematic review and meta-analysis," *Clinical Oral Implants Research*, vol. 28, no. 5, pp. 602–612, 2017.
- [37] L. M. Verhamme, G. J. Meijer, T. Boumans, A. F. J. de Haan, S. J. Bergé, and T. J. J. Maal, "A clinically relevant accuracy study of computer-planned implant placement in the edentulous maxilla using mucosa-supported surgical templates," *Clinical Implant Dentistry and Related Research*, vol. 17, no. 2, pp. 343–352, 2015.
- [38] E. Naziri, A. Schramm, and F. Wilde, "Accuracy of computer-assisted implant placement with insertion templates," *GMS Interdisciplinary Plastic Reconstructive Surgery*, 2016.
- [39] P. Shen, J. Zhao, L. Fan et al., "Accuracy evaluation of computer-designed surgical guide template in oral implantology," *Journal of Cranio-Maxillo-Facial Surgery*, vol. 43, no. 10, pp. 2189–2194, 2015.
- [40] S. Kühn, S. Zürcher, T. Mahid, M. Müller-Gerbl, A. Filippi, and P. Cattin, "Accuracy of full guided vs. half-guided implant surgery," *Clinical Oral Implants Research*, vol. 24, no. 7, pp. 763–769, 2013.
- [41] M. Vercruyssen, C. Cox, W. Coucke, I. Naert, R. Jacobs, and M. Quirynen, "A randomized clinical trial comparing guided implant surgery (bone- or mucosa-supported) with mental navigation or the use of a pilot-drill template," *Journal of Clinical Periodontology*, vol. 41, no. 7, pp. 717–723, 2014.
- [42] M. Vercruyssen, W. Coucke, I. Naert, R. Jacobs, W. Teughels, and M. Quirynen, "Depth and lateral deviations in guided implant surgery: an RCT comparing guided surgery with mental navigation or the use of a pilot-drill template," *Clinical Oral Implants Research*, vol. 26, no. 11, pp. 1315–1320, 2015.
- [43] A. Sicilia, D. Botticelli, L. Cordaro et al., "Computer-guided implant therapy and soft- and hard-tissue aspects. The third EAO consensus conference 2012," *Clinical Oral Implants Research*, vol. 23, no. 6, pp. 157–161, 2012.
- [44] C. H. F. Hämmerle, L. Cordaro, N. van Assche et al., "Digital technologies to support planning, treatment, and fabrication processes and outcome assessments in implant dentistry. Summary and consensus statements. The 4th EAO consensus conference 2015," *Clinical Oral Implants Research*, vol. 26, supplement 11, pp. 97–101, 2015.



**Hindawi**  
Submit your manuscripts at  
[www.hindawi.com](http://www.hindawi.com)

