

The Anatomy of the Medial Part of the Knee

By Robert F. LaPrade, MD, PhD, Anders Hauge Engebretsen, Medical Student,
Thuan V. Ly, MD, Steinar Johansen, MD, Fred A. Wentorf, MS, and Lars Engebretsen, MD, PhD

Investigation performed at the University of Minnesota, Minneapolis, Minnesota

Background: While the anatomy of the medial part of the knee has been described qualitatively, quantitative descriptions of the attachment sites of the main medial knee structures have not been reported. The purpose of the present study was to verify the qualitative anatomy of medial knee structures and to perform a quantitative evaluation of their anatomic attachment sites as well as their relationships to pertinent osseous landmarks.

Methods: Dissections were performed and measurements were made for eight nonpaired fresh-frozen cadaveric knees with use of an electromagnetic three-dimensional tracking sensor system.

Results: In addition to the medial epicondyle and the adductor tubercle, a third osseous prominence, the gastrocnemius tubercle, which corresponded to the attachment site of the medial gastrocnemius tendon, was identified. The average length of the superficial medial (tibial) collateral ligament was 94.8 mm. The superficial medial collateral ligament femoral attachment was 3.2 mm proximal and 4.8 mm posterior to the medial epicondyle. The superficial medial collateral ligament had two separate attachments on the tibia. The distal attachment of the superficial medial collateral ligament on the tibia was 61.2 mm distal to the knee joint. The deep medial collateral ligament consisted of menisiofemoral and menisiotibial portions. The posterior oblique ligament femoral attachment was 7.7 mm distal and 6.4 mm posterior to the adductor tubercle and 1.4 mm distal and 2.9 mm anterior to the gastrocnemius tubercle. The medial patellofemoral ligament attachment on the femur was 1.9 mm anterior and 3.8 mm distal to the adductor tubercle.

Conclusions: The medial knee ligament structures have a consistent attachment pattern.

Clinical Relevance: Identification of the gastrocnemius tubercle and the quantitative relationships presented here will be useful in the study of anatomic repairs and reconstructions of complex ligamentous injuries that involve the medial knee structures.

While the medial collateral ligament is the most frequently injured ligament in the knee¹⁻⁴, and while a better understanding of its functional anatomy, biomechanics, and healing has been obtained over the past twenty years⁵⁻⁹, we have found that its anatomy has only been described qualitatively, and there is controversy about descriptions of some aspects of its anatomy that have been contradictory or incomplete^{2,6,10-15}. The medial ligament complex of the knee includes one large ligament and a series of capsular thickenings and tendinous attachments. The superficial medial collateral ligament is commonly called the tibial collateral ligament, whereas the deep medial collateral ligament is also

called the mid-third medial capsular ligament^{10,16}. The capsular attachments from the main common tendon of the semimembranosus have been called the posterior oblique ligament^{5,17-20}. However, there appears to be controversy about whether the posterior oblique ligament is a distinct structure or if it is a portion of the superficial medial collateral ligament, termed the oblique fibers of the superficial medial collateral ligament^{2,10,13-17}.

An extensive literature search revealed that, while there are many qualitative descriptions of the anatomy of the medial part of the knee^{2,5,6,10,13-15,21}, there are no specific quantitative descriptions of the medial knee structures. Many of these

Disclosure: In support of their research for or preparation of this work, one or more of the authors received, in any one year, outside funding or grants in excess of \$10,000 from Health East, Norway, and the Norwegian Research Council (grant #42692) and the Sports Medicine Research Fund of the Minnesota Medical Foundation. Neither they nor a member of their immediate families received payments or other benefits or a commitment or agreement to provide such benefits from a commercial entity. No commercial entity paid or directed, or agreed to pay or direct, any benefits to any research fund, foundation, division, center, clinical practice, or other charitable or nonprofit organization with which the authors, or a member of their immediate families, are affiliated or associated.

complex structures have been illustrated either with oversimplifications of their attachments to both bone and other structures or with liberal interpretations of their courses by the illustrators, which makes it difficult to compare the attachments and courses of many separate structures among studies^{2,5,6,10,13-15,21}. The purpose of the present study was to verify the qualitative anatomy of medial knee structures and to perform a quantitative evaluation of their anatomic attachment sites as well as their relationships to pertinent osseous landmarks.

Materials and Methods

Gross Anatomy Dissections

Twenty femora from the bone box specimens of the Department of Anatomy at the University of Minnesota were qualitatively analyzed to examine the osseous prominences of the medial side of the knee. The locations of these osseous prominences were then used to help to identify and analyze the osseous prominences seen during the fresh-frozen knee dissections.

Dissections were performed on eight nonpaired fresh-frozen cadaveric knees that had no sign of previous injury, knee abnormality, or disease. The mean age of the donors had been fifty-nine years (range, forty-four to seventy-two years) at the time of death. Each cadaveric knee was stored frozen at -20°C and was allowed to thaw overnight prior to dissection.

Anatomic Measurements

The Polhemus FASTRAK electromagnetic three-dimensional tracking sensor system (Polhemus, Colchester, Vermont) was used to quantitatively identify the insertion sites of the measured structures and related osseous landmarks^{22,23}. This device is a six-degrees-of-freedom measuring device that tracks the position and orientation of a receiver relative to a transmitter with use of low-frequency magnetic fields. The transmitter device produces a pulsed magnetic field. In turn, the receiver device contains a small solenoid that senses the magnetic field. The magnetic field produced by the transmitter device has different effects depending on the receiver position in the magnetic field, and the position and orientation with respect to the axes of the transmitter can then be calculated instantaneously (MotionMonitor; Innovative Sports Training, Chicago, Illinois). The transmitter-to-receiver separation range in the present study was 300 to 480 mm, which was within the previously reported optimal range of 100 to 700 mm for these testing conditions to minimize positional error²². The knee was placed into a device that fixed the specimen relative to the transmitter device. A probe was connected to the electromagnetic tracking system and acted as the receiver device to measure the three-dimensional coordinate location of the structure or structures of interest. Distances of interest were calculated with use of three-dimensional data points. The accuracy of this measurement system has been reported to be within 0.3° and 0.3 mm ²³.

After placement of the knee into the holding device, me-

ticulous sharp dissection of the structures of the medial and posteromedial aspects of the knee was performed with use of either a knife blade or a fine-pointed hemostat. After the initial measurements of each specific structure were made by placing the Polhemus measuring probe against the edge of the structure and recording its three-dimensional coordinate location, the attachment sites were dissected down to bone and outlined and the perimeters of the attachment sites were identified with the measuring probe.

The perimeters of the tibial attachment sites of the medial structures were identified first. All measurements were made by the same individual (R.F.L.) to avoid interobserver error. Each attachment site was recorded by tracing its outline with the measuring probe immediately after it was sharply dissected off bone. Measurements were made along the periphery of each attachment site. Joint line measurements were made to the edge of the articular cartilage surfaces of the medial femoral condyle for structures attached to the femur and to the medial tibial plateau for structures attached to the tibia.

Once all of the desired structures and osseous landmarks were identified, the outlines of both the distal part of the femur and the proximal part of the tibia were collected to establish a three-dimensional axis on which to map the locations of the structures. The coordinates of each identified point were used to calculate the areas of the insertion sites, the centroid of each insertion, and the distances between the centroids. The distances between structures were then broken down into anterior-posterior, medial-lateral, and proximal-distal components. The distances measured with this system were straight-line distances and did not take into account osseous prominences or depressions. For this reason, small variations in measured distances occurred between the osseous landmarks and the separate anatomic structures.

Results

Measurements are reported to the midpoint of a structure's attachment site and osseous landmarks. All distances and areas are reported as averages for each structure (see Appendix). Attachment areas for identified structures are listed in a table the Appendix. Straight-line distances between the centers of structures are reported in tables in the Appendix, whereas proximal-distal and anterior-posterior attachment relationships are described in this section.

Medial Femoral Osseous Landmarks

Qualitative analysis of the femora from the bone box specimens revealed that the medial epicondyle was the most anterior and distal osseous prominence over the medial aspect of the medial femoral condyle. The adductor tubercle was located at the distal edge of a thin ridge of bone, called the medial supracondylar line, along the medial aspect of the distal part of the femur. The adductor tubercle was located proximal and posterior to the medial epicondyle. A third osseous prominence, which we have called the gastrocnemius tubercle, was identified; this structure was slightly distal and posterior to

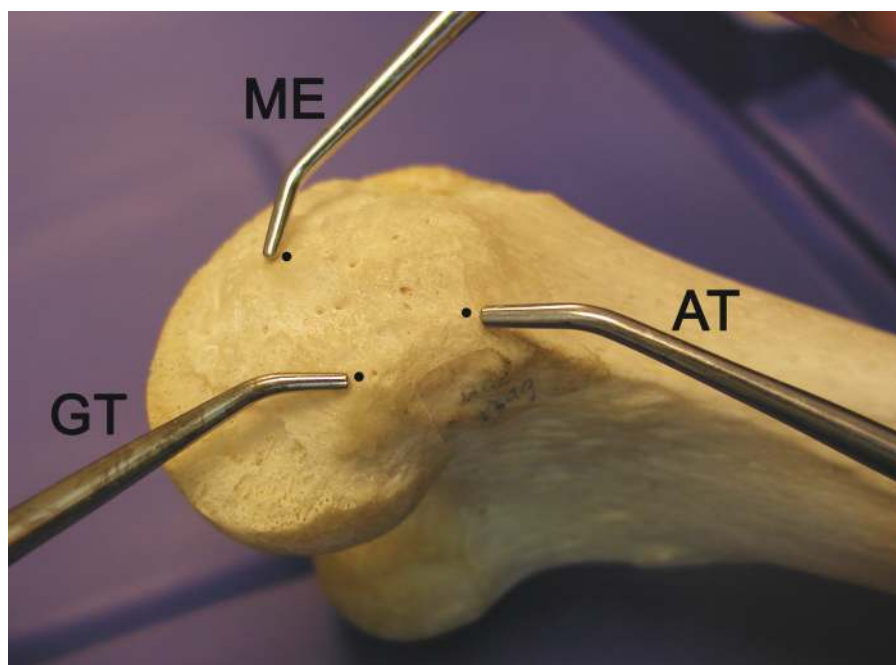


Fig. 1
Photograph of a femur from a bone box specimen (distal-medial view, right knee) with pointers demonstrating the relationships between the medial epicondyle (ME), the adductor tubercle (AT), and the gastrocnemius tubercle (GT). The dots are placed at the highest point of each structure.

the adductor tubercle and was close to a small depression, which corresponded to the location of the attachment of the medial gastrocnemius tendon (Figs. 1 and 2).

Quantitative analysis of these osseous landmarks in the dissected knees revealed that the adductor tubercle was 12.6 mm (range, 9.0 to 15.2 mm) proximal and 8.3 mm (range, 5.9 to 11.6 mm) posterior to the medial epicondyle. The gastrocnemius tubercle was 9.4 mm (range, 7.1 to 11.8 mm) distal and 8.7 mm (range, 6.8 to 12.5 mm) posterior to the adductor tubercle and 6.0 mm (range, 4.4 to 8.9 mm) proximal and 13.7 mm (range, 10.8 to 15.8 mm) posterior to the medial epicondyle.

Superficial Medial Collateral Ligament (Tibial Collateral Ligament)

The superficial medial collateral ligament was the largest structure over the medial aspect of the knee. It had one femoral and two tibial attachments. The quantitative relationships and attachment areas of the superficial medial collateral ligament are listed in tables in the Appendix.

The femoral attachment of the superficial medial collateral ligament was round to slightly oval in shape and was located in a depression that was an average of 3.2 mm (range, 1.6 to 5.2 mm) proximal and 4.8 mm (range, 2.5 to 6.3 mm) posterior to the medial epicondyle (Figs. 2 and 3). There was no firm attachment between the superficial medial collateral ligament and the underlying deep medial collateral ligament, and no definable bursae were identified between these two structures.

As the superficial medial collateral ligament coursed distally, it had two separate tibial attachments (Figs. 2 and 4). Between these two distinct tibial attachments, the superficial medial collateral ligament was separated from the tibia by the inferior medial genicular artery and vein, along with its corresponding nerve branch from the tibial nerve, and some fine fascial and adipose tissues. The proximal attachment of the superficial medial collateral ligament was primarily to soft tissues rather than directly to bone. The majority of the soft tissue deep to the proximal tibial attachment of the superficial medial collateral ligament was the anterior arm of the semimembranosus tendon, which itself attached directly to bone. The distal tibial attachment was broad-based and was located just anterior to the posteromedial crest of the tibia. The majority of the distal attachment was located within the pes anserine bursa and formed a large portion of the posterior floor of this bursa. The posterior aspect of the tibial portion of the superficial medial collateral ligament blended with the distal tibial expansion off the semimembranosus tendon²⁴ along its distal aspect.

Deep Medial Collateral Ligament (Mid-Third Medial Capsular Ligament)

The deep medial collateral ligament was a thickening of the medial joint capsule that was most distinct along its anterior border, where it roughly paralleled the anterior aspect of the superficial medial collateral ligament. It was most easily identified along its anterior femoral course, where the joint capsule that coursed toward the medial part of the patella was

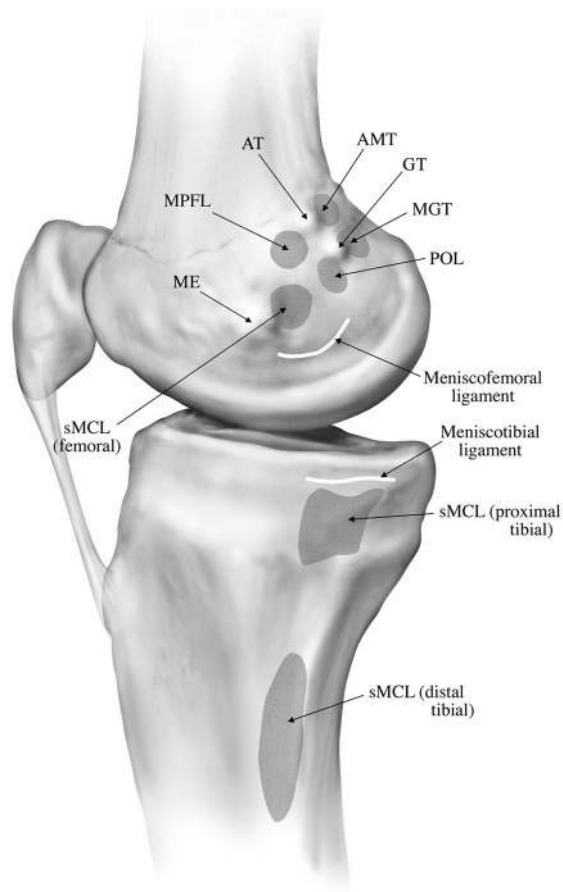


Fig. 2

Illustration of the femoral osseous landmarks and attachment sites of the main medial knee structures. AT = adductor tubercle, GT = gastrocnemius tubercle, ME = medial epicondyle, AMT = adductor magnus tendon, MGT = medial gastrocnemius tendon, sMCL = superficial medial collateral ligament, MPFL = medial patellofemoral ligament, and POL = posterior oblique ligament.

visibly thinner and had a different fiber orientation. The posterior border of the deep medial collateral ligament blended with and became inseparable from the central arm of the posterior oblique ligament, just posterior to the posterior edge of the superficial medial collateral ligament.

The deep medial collateral ligament consisted of distinct menisiofemoral and menisiotibial ligament components (Fig. 5). The menisiofemoral ligament was consistently longer in the proximal-to-distal direction than the menisiotibial portion (see Appendix). The menisiotibial ligament portion of the deep medial collateral ligament was a consistently shorter and thicker structure and attached just distal to the edge of the articular cartilage of the medial tibial plateau (see Appendix).

Posterior Oblique Ligament

The posterior oblique ligament consisted of three fascial attachments that coursed off the distal aspect of the semimembranosus tendon at the knee and have been previously termed

the superficial, central (tibial), and the capsular arms^{2,17} (Fig. 6). The distances from the femoral attachment of the posterior oblique ligament to other specific osseous landmarks are listed in a table in the Appendix. On the average, the posterior oblique ligament attached on the femur 7.7 mm (range, 6.1 to 9.8 mm) distal and 6.4 mm (range, 4.5 to 10.6 mm) posterior to the adductor tubercle and 1.4 mm (range, 0.8 to 2.1 mm) distal and 2.9 mm (range, 2.1 to 4.1 mm) anterior to the third osseous prominence over the medial part of the knee, the gastrocnemius tubercle.

The superficial arm of the posterior oblique ligament consisted of a thin fascial expansion. Proximally it coursed medial to the anterior arm of the semimembranosus, and distally it followed the posterior border of the superficial medial collateral ligament (Fig. 6). Proximally it blended into the central arm of the posterior oblique ligament, whereas distally it was parallel to the posterior border of the superficial medial collateral ligament until it blended into the distal tibial expansion of the semimembranosus and its tibial attachment²⁴.

The central arm was the largest and thickest portion of the posterior oblique ligament (Figs. 7-A and 7-B). It coursed from the distal aspect of the main semimembranosus tendon and was a thick fascial reinforcement of both the menisiofem-

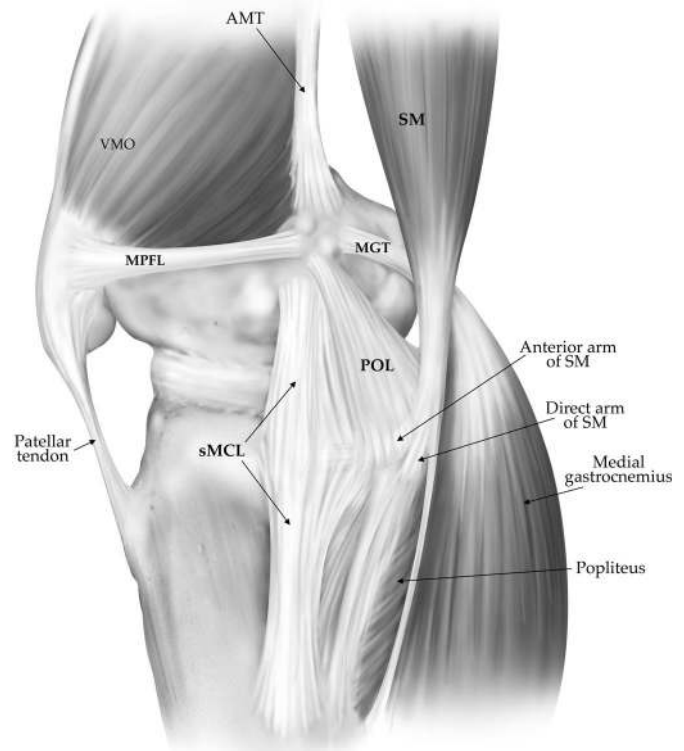


Fig. 3

Illustration of the main medial knee structures (right knee). VMO = vastus medialis obliquus muscle, MPFL = medial patellofemoral ligament, POL = posterior oblique ligament, sMCL = superficial medial collateral ligament, SM = semimembranosus muscle, MGT = medial gastrocnemius tendon, and AMT = adductor magnus tendon.

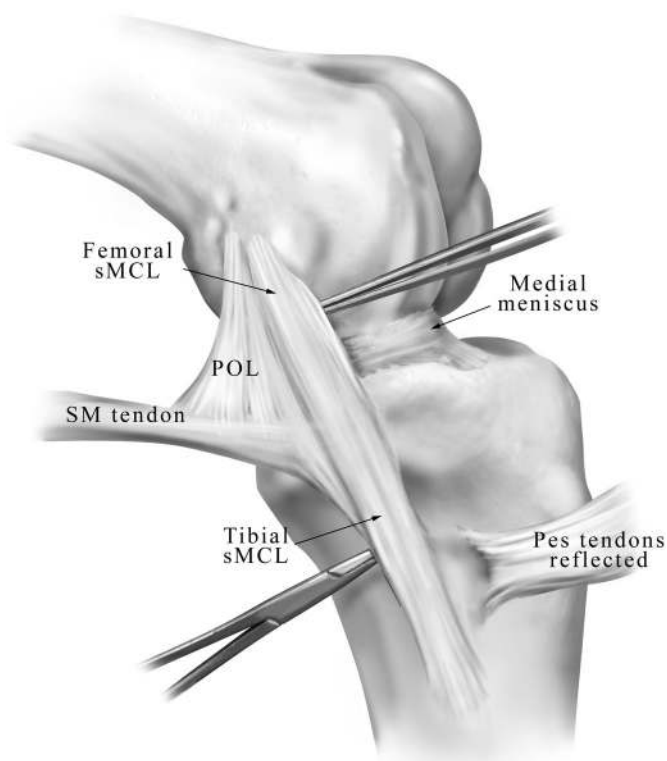


Fig. 4
Illustration of the superficial medial collateral ligament (sMCL) (medial aspect, left knee). The proximal forceps are under the anterior edge of the femoral portion, and the distal hemostat is between the proximal and distal tibial attachments. SM = semimembranosus, and POL = posterior oblique ligament.

oral and meniscotibial portions of the posteromedial capsule, and it also had a stout attachment to the medial meniscus. Anteriorly, it merged with the posterior fibers of the superficial medial collateral ligament. The central arm of the posterior oblique ligament could be differentiated from the superficial medial collateral ligament by the proximal course of its fan-like fibers, which ran more posteriorly toward its femoral attachment than did the fibers of the superficial medial collateral ligament, which coursed more anteriorly toward its femoral attachment (Fig. 6). Its distal attachment was primarily to the posteromedial aspect of the medial meniscus, the meniscotibial portion of the posteromedial capsule, and the posteromedial part of the tibia.

The capsular arm of the posterior oblique ligament consisted of a thin proximal fascial expansion off the anterior aspect of the distal part of the semimembranosus tendon (Fig. 6). It was located posterior and lateral to the meniscofemoral capsular attachments of the central arm and had no fibers that coursed toward the tibia. The capsular arm primarily blended with the meniscofemoral portion of the posteromedial joint capsule and the medial aspect of the oblique popliteal ligament, and it also attached to the soft tissues over the medial gastrocnemius tendon, the adductor magnus tendon expan-

sion to the medial gastrocnemius, and the adductor magnus tendon femoral attachment. Qualitatively, it was less stout overall than the central arm, and it did not have any osseous attachment.

Medial Patellofemoral Ligament

The medial patellofemoral ligament was located anterior to, and in a distinct extra-articular layer from, the medial joint capsule. The distal border of the vastus medialis obliquus muscle attached along the majority of the proximal edge of the medial patellofemoral ligament (Fig. 8). It was from this proximal margin that the medial patellofemoral ligament was consistently identified. Distally, it could be distinguished as a distinct thickening within the fascial layer, which coursed between the proximal-medial edge of the patella and its femoral attachment. The medial patellofemoral ligament had a broad-based attachment to the superomedial aspect of the medial border of the patella. On the average, the midpoint of the medial patellofemoral ligament patellar attachment was located 41.4% of the length from the proximal tip of the patella along the total patellar length (proximal to distal). The average overall length of the patella in these knees was 48.4 mm (range, 38.1 to 55.8 mm). The ligament then coursed medially toward the femoral attachments of the adductor magnus tendon and superficial medial collateral ligament and attached primarily to soft tissues between these two structures (Fig. 2). The me-

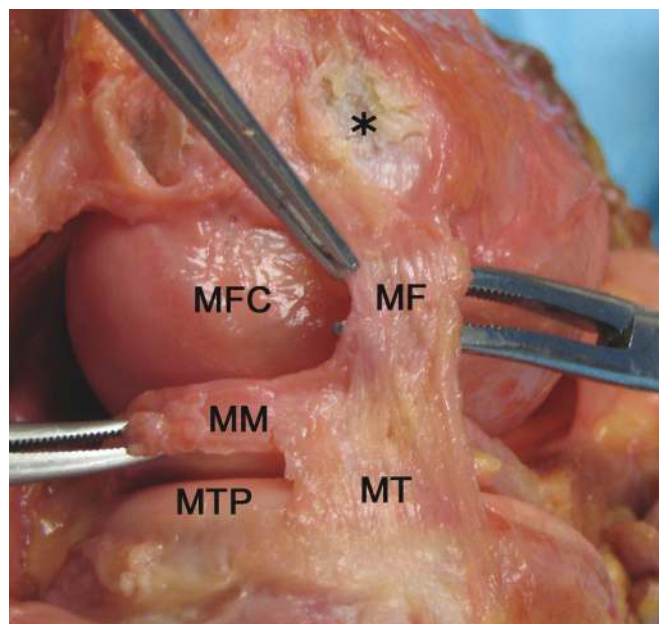


Fig. 5
Photograph of the meniscofemoral (MF) and meniscotibial (MT) portions of the deep medial collateral ligament (medial aspect, left knee) with the posterior oblique ligament and remaining medial capsule removed. The asterisk indicates the femoral attachment site of superficial medial collateral ligament. MM = posterior aspect of medial meniscus, MFC = posterior aspect of medial femoral condyle, and MTP = posterior aspect of medial tibial plateau.

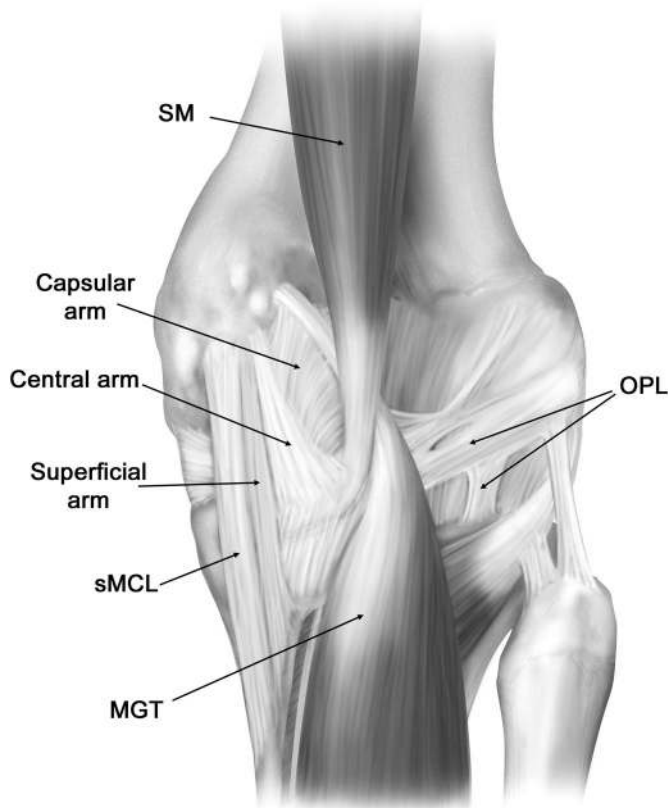


Fig. 6

Illustration of the three arms of the posterior oblique ligament (postero-medial aspect, right knee). sMCL = superficial medial collateral ligament, SM = semimembranosus muscle, MGT = medial gastrocnemius tendon, and OPL = oblique popliteal ligament.

dial patellofemoral ligament attachment on the femur was an average of 10.6 mm (range, 8.0 to 13.4 mm) proximal and 8.8 mm (range, 6.7 to 10.3 mm) posterior to the medial epicondyle and 1.9 mm (range, 1.3 to 3.2 mm) anterior and 3.8 mm (range, 2.1 to 6.3 mm) distal to the adductor tubercle. The average length of the medial patellofemoral ligament was 65.2 mm (range, 56.8 to 77.8 mm) between its patellar and femoral attachment sites.

Adductor Magnus Tendon

The adductor magnus tendon attached in an osseous depression an average of 3.0 mm (range, 1.8 to 4.6 mm) posterior and 2.7 mm (range, 1.6 to 4.3 mm) proximal to the adductor tubercle and did not attach directly to the adductor tubercle (Fig. 2). The distal-medial aspect of the adductor magnus tendon had a thick fascial expansion, which fanned out postero-medially and attached to the medial gastrocnemius tendon, the capsular arm of the posterior oblique ligament, and the posteromedial capsule (Fig. 9). At its attachment site to the medial gastrocnemius tendon, the fascial expansion averaged 15.7 mm (range, 11.2 to 21.3 mm) in width.

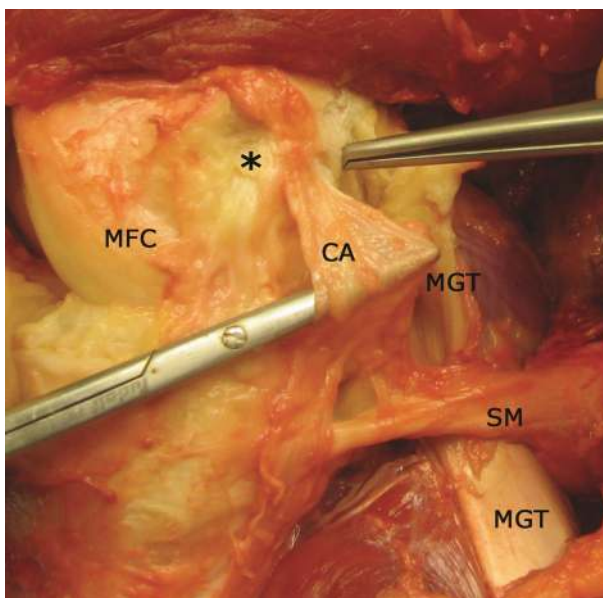


Fig. 7-A

Photograph (Fig. 7-A) and illustration (Fig. 7-B) demonstrating the central arm (CA) of the posterior oblique ligament (medial aspect, right knee). The asterisk indicates the femoral attachment of the superficial medial collateral ligament (sMCL) (removed). The tip of the forceps is at the medial gastrocnemius attachment (removed). MGT = medial gastrocnemius tendon, SM = semimembranosus tendon, MFC = anterior aspect of medial femoral condyle, ME = medial epicondyle, POL = posterior oblique ligament, and VMO = vastus medialis obliquus muscle.

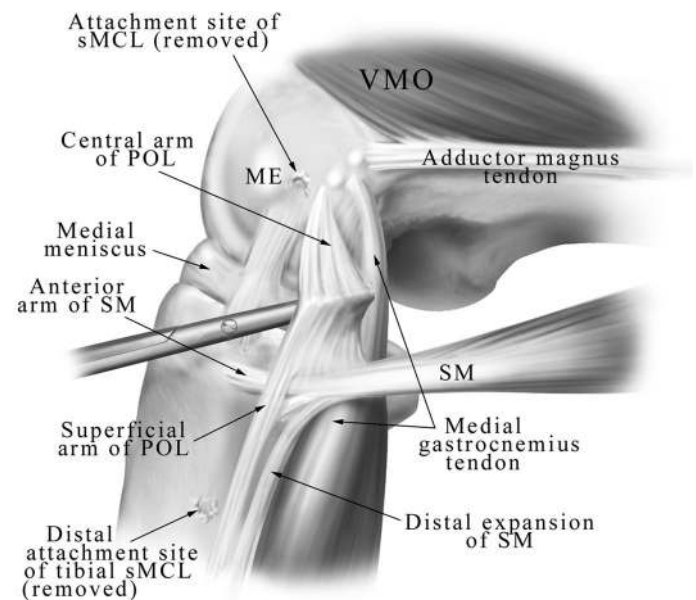


Fig. 7-B

The distal-lateral aspect of the adductor magnus tendon had a very thick tendinous sheath that attached to the medial supracondylar line. The vastus medialis obliquus muscle had its medial attachment both along this thick tendinous sheath and also along the lateral aspect of the adductor magnus tendon.

Medial Gastrocnemius Tendon

The medial gastrocnemius tendon was formed at the medial edge of the medial gastrocnemius muscle belly (Fig. 10). It attached an average of 2.6 mm (range, 1.4 to 4.4 mm) proximal and 3.1 mm (range, 2.6 to 3.6 mm) posterior in a depression adjacent to a third osseous prominence over the medial aspect of the medial femoral condyle, the gastrocnemius tubercle, and the tendon attachment was an average of 5.3 mm (range, 4.0 to 7.2 mm) distal and 8.1 mm (range, 6.1 to 10.3 mm) posterior to the adductor tubercle (Figs. 2 and 10) (see Appendix). As noted previously, the medial gastrocnemius tendon had a thick fascial attachment along its lateral aspect to the adductor magnus tendon and a thin fascial attachment along its medial and posterior aspect to the capsular arm of the posterior oblique ligament.

Pes Anserine Tendon Attachments

The pes anserine tibial attachment consisted of the sartorius, gracilis, and the semitendinosus tendinous attachments on the anteromedial aspect of the proximal part of the tibia. The sartorius tendon fascia was intimately attached to the superficial fascial layer, whereas the gracilis and semitendinosus tendons were located on the posterior (deep) surface of the superficial fascial layer over the medial aspect of the knee. Once the pes anserine tendons were reflected laterally, their distinct individual attachment sites were easily identified as each individual tendon attached in an almost linear fashion at the lateral edge of the pes anserine bursa, which was present in all knees (Fig. 11). The sartorius tendon attached more proximally, followed by the gracilis tendon and the semitendinosus tendon. The average tendon widths were 8.0 mm (range, 5.7 to 9.3 mm) for the sartorius, 8.4 mm (range, 6.2 to 11.4 mm) for the gracilis, and 11.3 mm (range, 7.5 to 15.8 mm) for the semitendinosus at their tibial attachment sites. The midpoint of the lateral attachment of the gracilis on the tibia averaged 8.2 mm (range, 2.8 to 11.3 mm) proximal and 13.4 mm (range, 10.3 to 15.5 mm) anterior to the distal osseous attachment of the superficial medial collateral ligament.

Semimembranosus Tendon Tibial Attachments

The semimembranosus tendinous attachments on the medial and posteromedial parts of the tibia consisted of the anterior and direct arms (see Appendix). The anterior arm attached deep to the proximal tibial attachment of the superficial medial collateral ligament in an oval-shaped pattern, and its attachment was distal to the tibial joint line. The direct arm attached to the proximal aspect of the posteromedial part of the tibia in a small groove just proximal to the tuberculum

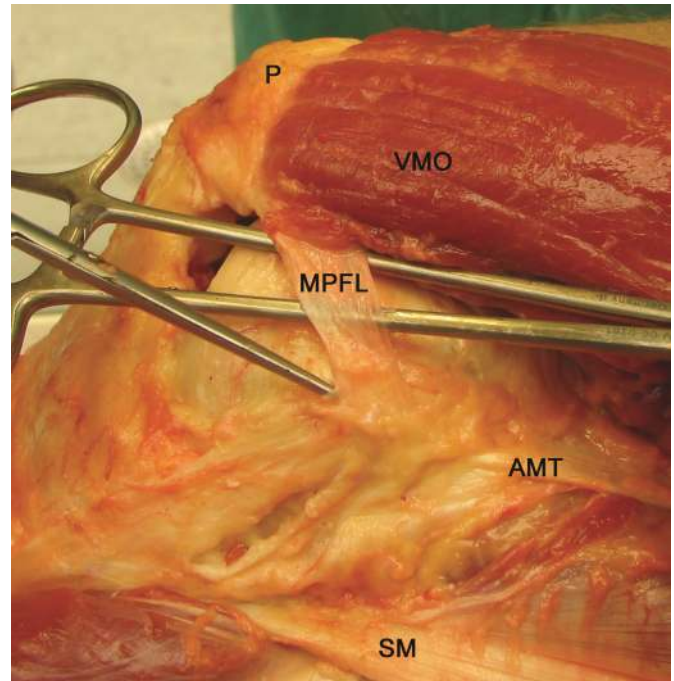


Fig. 8

Photograph of the isolated medial patellofemoral ligament (MPFL) with the posterior vastus medialis obliquus (VMO) fibers elevated off the ligament (medial view, right knee). The needle driver is under the medial patellofemoral ligament, and the pointer is at the distal edge of the medial patellofemoral ligament. The deeper medial capsule has been removed. AMT = adductor magnus tendon, p = patella, and SM = semimembranosus tendon.

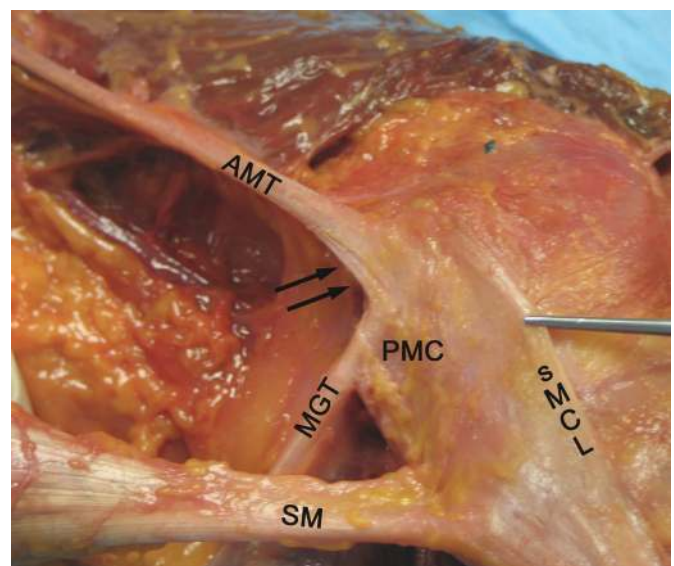


Fig. 9

Photograph of the femoral attachment of the adductor magnus tendon (AMT) and its fascial expansion (arrows) to the medial gastrocnemius tendon (MGT) and posteromedial capsule (PMC) (medial view, right knee). The forceps is holding the anterior edge of superficial medial collateral ligament (sMCL). SM = semimembranosus tendon.

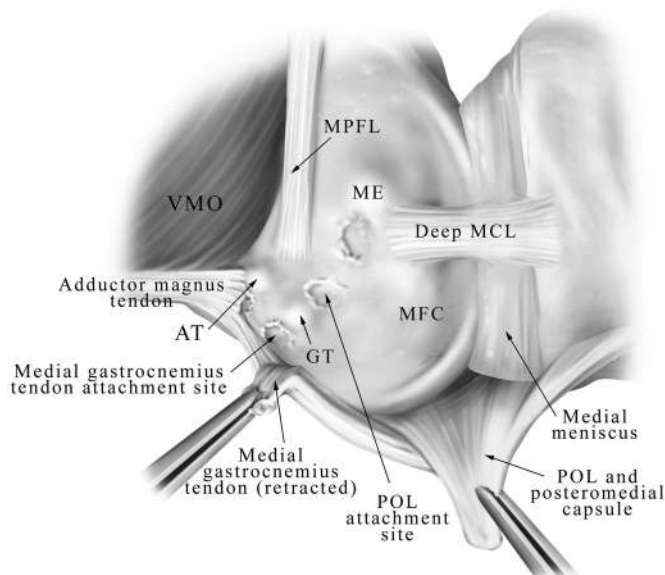


Fig. 10
Illustration of the femoral attachment sites of the medial gastrocnemius and adductor magnus tendons and their relationship to the adductor and gastrocnemius tubercles (medial view, right knee). Both tendons are detached from their osseous attachments. AT = adductor tubercle, GT = gastrocnemius tubercle, MCL = medial collateral ligament, ME = medial epicondyle, MFC = medial femoral condyle, MPFL = medial patellofemoral ligament, POL = posterior oblique ligament, and VMO = vastus medialis obliquus muscle.

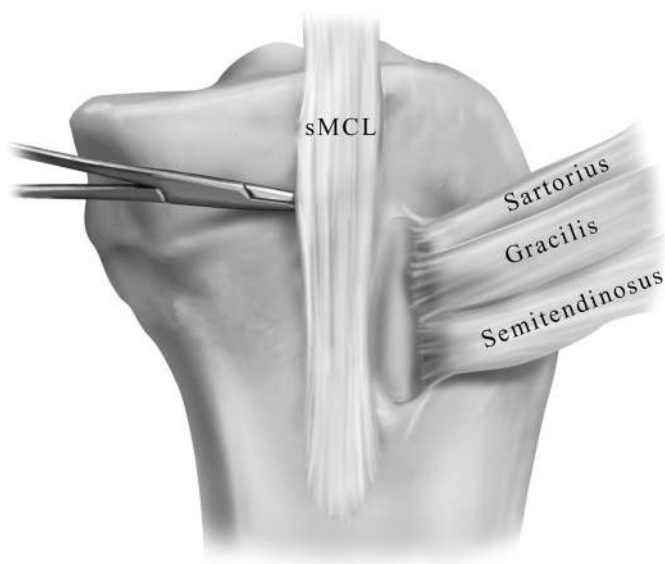


Fig. 11
Illustration of the lateral edge of the pes anserine bursa, demonstrating the distinct attachment sites of the sartorius, gracilis, and semitendinosus tendons (medial view, left knee). The hemostat is under the gap between the proximal and distal tibial attachments of the superficial medial collateral ligament (sMCL).

tendinis prominence²⁵. The attachment was posterior to the medial tibial crest and distal to the posteromedial aspect of the joint line. The semimembranosus bursa had its distal border along the proximal edge of the tibial attachment of the direct arm. The semimembranosus bursa continued medial to the anterior arm, until the anterior arm attached to bone along the posteromedial part of the tibia.

Discussion

While the qualitative anatomy of the medial side of the knee has been described previously^{2,10,11,13-15,17,20,26}, no comprehensive detailed quantitative anatomy descriptions have been published, to our knowledge. We found that many previous descriptions of the qualitative attachment sites of the medial part of the knee were inaccurate once the individual structures were isolated and measured, especially for the femoral attachment sites of the superficial medial collateral ligament, the posterior oblique ligament, and the medial patellofemoral ligament.

We believe that it is important to report on and understand the course of the individual structures and the attachment sites rather than to attempt to describe them in layers¹⁰. The layered description is not useful for surgical approaches because the area where the medial sided structures are actually separated into three layers is quite small¹⁰. In fact, the authors who introduced this layered description reported that the only distinct location where there were three tissue planes was directly over the superficial medial collateral ligament and occasionally over the medial patellofemoral ligament¹⁰. In the majority of locations, there are only individual structures deep to the superficial crural fascial layer and there is not an intervening middle layer. Thus, we recommend that consideration be made to minimizing the use of the three-layered anatomy description of medial-sided knee structures and that clinical and magnetic resonance imaging descriptions of medial knee anatomy refer to individual structures.

Femoral Osseous Prominences

In all femora that were analyzed for the present study, there were always three separate osseous prominences over the medial aspect of the knee. Until this study, we were unaware of the presence of a third femoral osseous prominence. In some knees, this prominence was the largest of the three. It was located slightly distal and posterior to the adductor tubercle. As the medial gastrocnemius tendon attached close to this third osseous prominence, we propose that it be named the *gastrocnemius tubercle*. We also found that the posterior oblique ligament attachment was adjacent to the gastrocnemius tubercle, which means that its attachment was closer to the gastrocnemius tubercle than to the adductor tubercle. We believe that a great deal of the confusion in the previously published literature with regard to the location of the femoral attachments of the medial patellofemoral ligament and the posterior oblique ligament has been due to the lack of recognition of the gastrocnemius tubercle. In addition, we believe that it is important for clinicians to recognize the

presence of this gastrocnemius tubercle as it could be incorrectly identified as the adductor tubercle by palpation, resulting in non-anatomic repairs or reconstructions of medial knee injuries.

Superficial Medial Collateral Ligament (Tibial Collateral Ligament)

The superficial medial collateral ligament is the largest structure of the medial part of the knee and has been qualitatively well described in the literature^{10,13-15,20}. Our measurements agree with those of previous investigators, who have described it to be between 10 and 12 cm in overall length^{10,20,26}.

We found the superficial medial collateral ligament to have one proximal femoral attachment, which was not directly to the medial epicondyle but was centered in a small depression slightly proximal and posterior to the center of the medial epicondyle. Palmer's description²⁷ of the femoral attachment of the superficial medial collateral ligament, although vague, seems to be the closest one to our findings; he noted that it attached in an approximately 2-cm oval pattern "in the neighborhood of the area over which the condylar axis shifts". While other authors have reported that the superficial medial collateral ligament attached directly to the medial epicondyle^{10,13-15,17,18,20,25,26,28,29}, we did not find any instances in which it attached directly there.

We found the superficial medial collateral ligament had two distinct tibial attachments. The proximal tibial attachment was primarily to soft tissues directly over the anterior arm of the semimembranosus, whereas the distal tibial attachment was directly to bone. Brantigan and Voshell^{14,15} also previously reported that the superficial medial collateral ligament attached inferiorly to two points on the tibia, and other investigators^{14,27} have reported that the distal aspect of the superficial medial collateral ligament attached approximately 6 cm distal to the joint line, which is in agreement with our findings.

Deep Medial Collateral Ligament (Mid-Third Medial Capsular Ligament)

We found the deep medial collateral ligament to consist of a thickening of the medial joint capsule, deep and firmly adherent to, but separable from, the superficial medial collateral ligament, with distinct menisofemoral and meniscotibial components. The menisofemoral ligament portion attached distal and deep to the femoral attachment of the superficial medial collateral ligament. The meniscotibial portion, which was much shorter and thicker than the menisofemoral ligament portion, attached just distal to the edge of the articular cartilage of the medial tibial plateau. Others have also reported that the deep medial collateral ligament was composed of menisofemoral and meniscotibial portions^{26,30}.

Posterior Oblique Ligament

The attachment sites and course of the posterior oblique ligament have been a source of confusion in the litera-

ture^{17,18,20,25}. We found the three components of the posterior oblique ligament, previously described by Hughston and Eilers¹⁷ as the superficial, central, and capsular arms, to be readily identified. While we found that all three structures were continuous with each other, defined attachment patterns were consistently identified and outlined. The two primarily anterior arms, the central and superficial arms, blended into each other to form a common femoral attachment, which was proximal and posterior to the femoral attachment of the superficial medial collateral ligament. The femoral attachment of the posterior oblique ligament was not to the adductor tubercle^{17,18} or medial epicondyle²⁵, as described previously; rather, the ligament attached 7.7 mm distal and 6.4 mm posterior to the adductor tubercle and 1.4 mm distal and 2.9 mm anterior to the gastrocnemius tubercle. Thus, in effect, the femoral attachment of the posterior oblique ligament is closer to the gastrocnemius tubercle than to the adductor tubercle.

We also found that the central arm of the posterior oblique ligament forms the main portion of this structure. While the central arm has been also referred to as the tibial arm in the literature^{2,4,16,17}, we have chosen to call this portion of the posterior oblique ligament the central arm according to the original description by Hughston and Eilers¹⁷. This is because this structure is centrally located, with its main structure and static function^{5,9} being more intertwined with its proximal femoral course rather than its more distally based tibial course. The other two components are thin structures. The superficial layer is a thin structure that runs parallel to the posterior aspect of the superficial medial collateral ligament, which blends distally with the distal tibial expansion of the semimembranosus²⁴, while the capsular arm is also thin and attaches primarily to the posteromedial joint capsule. Thus, it appears that the main structure that would need to be repaired or reconstructed in this anatomic area following a posteromedial knee injury would be the central arm of the posterior oblique ligament. In fact, we found that the central arm was the portion of the posterior oblique ligament that merged with and reinforced the posteromedial capsule, was adherent to the medial meniscus, and formed the main portion of the femoral attachment of the posterior oblique ligament.

In some of the earlier literature on medial knee anatomy^{10,13-15}, the superficial medial collateral ligament was reported to have an oblique posterior portion, which is now recognized as the posterior oblique ligament. All of those previous descriptions^{10,13,14,15} fit with our description of the main portion of the central arm of the posterior oblique ligament.

Medial Patellofemoral Ligament

We found that the medial patellofemoral ligament was a distinct structure that was located anterior to the deeper medial joint capsule and was distinctly extracapsular from the underlying medial joint capsule in all cases. We found that its attachment width along the superomedial border of the

patella was similar to the attachment width described by Steensen et al.³¹. It then coursed distal-medial to the adductor tubercle to its femoral attachment. The location of its femoral attachment has been variably described to be at either the medial epicondyle^{25,32}, at the anterior aspect of the medial epicondyle^{31,33}, or just distal to the adductor tubercle³⁴. As noted previously, we found its femoral attachment to be located closer to the adductor tubercle than to the medial epicondyle, which agrees with the description provided by Tuxoe et al.³⁴.

Adductor Magnus Tendon

In the present study, we found that the adductor magnus tendon attached in a small depression slightly posterior and proximal to the adductor tubercle and not directly to the tip of the tubercle as described previously^{15,25,29}. It also had a thick fascial attachment, which extended posteriorly from the distal aspect of the tendon to attach to the proximal aspect of the medial gastrocnemius tendon and posteromedial joint capsule. To our knowledge, this fascial attachment between the adductor magnus and medial gastrocnemius tendons has not been specifically described previously.


Medial Gastrocnemius Tendon

We found that the medial gastrocnemius tendon attached in a small depression that was proximal and adjacent to a third osseous prominence, which we have called the gastrocnemius tubercle, located over the posteromedial edge of the medial femoral condyle. Our findings differed somewhat from those reported by Standring²⁵, who did not note the presence of the gastrocnemius tubercle and who reported that the medial gastrocnemius tendon attached in a depression at the upper and posterior aspect of the medial femoral condyle, just behind the adductor tubercle. While we did find that the medial gastrocnemius tendon attached in a small osseous depression in this region, it was actually posterior to the gastrocnemius tubercle and not the adductor tubercle.

Overview

In the present study, we quantitatively determined the anatomic attachment sites of the medial knee structures and their relationships to pertinent osseous landmarks. In addition, a third osseous prominence over the medial part of the knee, the gastrocnemius tubercle, was identified. With the improved knowledge of the attachment anatomy and courses of structures of the medial part of the knee, knee surgeons and radiologists should be able to improve their interpretation of injuries to the soft-tissue structures of this area. In addition, this detailed knowledge of the quantitative attachment sites of these medial knee structures will prove to be useful in the evaluation of techniques and outcomes studies of anatomic repairs and reconstructions of posttraumatic ligamentous injuries that involve the medial and posteromedial knee structures.

Appendix

 Tables showing details of the measurements made in this study are available with the electronic versions of this article, on our web site at jbjs.org (go to the article citation and click on "Supplementary Material") and on our quarterly CD-ROM (call our subscription department, at 781-449-9780, to order the CD-ROM). ■

NOTE: The authors thank Melissa Kath, BA, and John Redmond, BA, for their work on the laboratory portion of this project.

Robert F. LaPrade, MD, PhD
Thuan V. Ly, MD
Fred A. Wentorf, MS
Department of Orthopaedic Surgery, University of Minnesota, 2450
Riverside Avenue, R200, Minneapolis, MN 55454. E-mail address for R.F.
LaPrade: lapra001@umn.edu

Anders Hauge Engebretsen, Medical Student
Steinar Johansen, MD
Lars Engebretsen, MD, PhD
Department of Orthopaedic Surgery, Ullevål University Hospital, Uni-
versity of Oslo, N-0407 Oslo, Norway

References

1. Grood ES, Noyes FR, Butler DL, Suntay WJ. Ligamentous and capsular restraints preventing straight medial and lateral laxity in intact human cadaver knees. *J Bone Joint Surg Am.* 1981;63:1257-69.
2. Hughston JC. The importance of the posterior oblique ligament in repairs of acute tears of the medial ligaments in knees with and without an associated rupture of the anterior cruciate ligament. *J Bone Joint Surg Am.* 1994;76:1328-44.
3. Kannus P. Long-term results of conservatively treated medial collateral ligament injuries of the knee joint. *Clin Orthop Relat Res.* 1988;226:103-12.
4. LaPrade RF. The medial collateral ligament complex and the posterolateral aspect of the knee. In: Arendt EA, editor. *Orthopaedic knowledge update. Sports medicine 2.* Rosemont, IL: American Academy of Orthopaedic Surgeons; 1999. p 327-40.
5. Fischer RA, Arms SW, Johnson RJ, Pope MH. The functional relationship of the posterior oblique ligament to the medial collateral ligament of the human knee. *Am J Sports Med.* 1985;13:390-7.
6. Haimes JL, Wroble RR, Grood ES, Noyes FR. Role of the medial structures in the intact and anterior cruciate ligament-deficient knee. Limits of motion in the human knee. *Am J Sports Med.* 1994;22:402-9.
7. Inoue M, McGurk-Burleson E, Hollis JM, Woo SL. Treatment of the medial collateral ligament injury. I: The importance of anterior cruciate ligament on the varus-valgus knee laxity. *Am J Sports Med.* 1987;15:15-21.
8. Quapp KM, Weiss JA. Material characterization of human medial collateral ligament. *J Biomech Eng.* 1998;120:757-63.
9. Warren LF, Marshall JL, Girgis F. The prime static stabilizer of the medial side of the knee. *J Bone Joint Surg Am.* 1974;56:665-74.
10. Warren LF, Marshall JL. The supporting structures and layers on the medial side of the knee: an anatomical analysis. *J Bone Joint Surg Am.* 1979; 61:56-62.
11. Ivey M, Prud'homme J. Anatomic variations of the pes anserinus: a cadaver study. *Orthopedics.* 1993;16:601-6.
12. Kaplan EB. Factors responsible for the stability of the knee joint. *Bull Hosp Joint Dis.* 1957;18:51-9.
13. Last RJ. Some anatomical details of the knee joint. *J Bone Joint Surg Br.* 1948;30:683-9.
14. Brantigan OC, Voshell AF. The mechanics of the ligaments and menisci of the knee joint. *J Bone Joint Surg Am.* 1941;23:44-66.
15. Brantigan OC, Voshell AF. The tibial collateral ligament: its function, its

bursae, and its relation to the medial meniscus. *J Bone Joint Surg Am.* 1943; 25:121-31.

16. Hughston JC, Andrews JR, Cross MJ, Moschi A. Classification of knee ligament instabilities. Part I. The medial compartment and cruciate ligaments. *J Bone Joint Surg Am.* 1976;58:159-72.

17. Hughston JC, Eilers AF. The role of the posterior oblique ligament in repairs of acute medial (collateral) ligament tears of the knee. *J Bone Joint Surg Am.* 1973;55:923-40.

18. Sims WF, Jacobson KE. The posteromedial corner of the knee: medial-sided injury patterns revisited. *Am J Sports Med.* 2004;32:337-45.

19. Poliacu Prose L, Lohman AH, Huson A. The collateral ligaments of the knee joint in the cat and man. Morphological and functional study of the internal arrangement of fibers. *Acta Anat (Basel).* 1988;133:70-8.

20. Loredó R, Hodler J, Pedowitz R, Yeh LR, Trudell D, Resnick D. Posteromedial corner of the knee: MR imaging with gross anatomic correlation. *Skeletal Radiol.* 1999;28:305-11.

21. Sullivan D, Levy IM, Sheskier S, Torzilli PA, Warren RF. Medial restraints to anterior-posterior motion of the knee. *J Bone Joint Surg Am.* 1984;66:930-6.

22. An KN, Jacobsen C, Berglund LJ, Chao EY. Application of a magnetic tracking device to kinesiologic studies. *J Biomech.* 1988;21:613-20.

23. McKellop H, Hoffman R, Sarmiento A, Ebramzadeh E. Control of motion of tibial fractures with use of a functional brace or an external fixator. A study of cadavera with use of a magnetic motion sensor. *J Bone Joint Surg Am.* 1993; 75:1019-25.

24. LaPrade RF, Morgan PM, Wentorf FA, Johansen S, Engebretsen L. The anatomy of the posterior aspect of the knee: an anatomic study. *J Bone Joint Surg Am.* 2007;89:758-64.

25. Knee. In: Standring S, editor. *Gray's anatomy: the anatomical basis of clinical practice.* 39th ed. New York: Churchill Livingstone; 2005. p 1471-88.

26. De Maeseneer M, Van Roy F, Lenchik L, Barbaix E, De Ridder F, Osteaux M. Three layers of the medial capsular and supporting structures of the knee: MR imaging-anatomic correlation. *Radiographics.* 2000;20:S83-9.

27. Palmer I. On the injuries to the ligaments of the knee joint. A clinical study. *Acta Chir Scand.* 1938;81 Suppl 53:3-282.

28. Leg/knee. In: Thompson JC, editor. *Netter's concise atlas of orthopaedic anatomy.* Teterboro, NJ: Icon Learning Systems; 2002. p 199-242.

29. Moore KL, Dalley AF. *Clinically oriented anatomy.* New York: Williams and Wilkins; 1999. Lower limb; p 503-663.

30. Slocum DB, Larson RL. Rotatory instability of the knee. Its pathogenesis and a clinical test to demonstrate its presence. *J Bone Joint Surg Am.* 1968; 50:211-25.

31. Steensen RN, Dopirak RM, McDonald WG 3rd. The anatomy and isometry of the medial patellofemoral ligament: implications for reconstruction. *Am J Sports Med.* 2004;32:1509-13.

32. Amis AA, Firer P, Mountney J, Senavongse W, Thomas NP. Anatomy and biomechanics of the medial patellofemoral ligament. *Knee.* 2003;10:215-20. Erratum in: *Knee.* 2004;11:73.

33. Feller JA, Feagin JA Jr, Garrett WE Jr. The medial patellofemoral ligament revisited: an anatomical study. *Knee Surg Sports Traumatol Arthrosc.* 1993; 1:184-6.

34. Tuxoe JL, Teir M, Winge S, Nielsen PL. The medial patellofemoral ligament: a dissection study. *Knee Surg Sports Traumatol Arthrosc.* 2002; 10:138-40.