

## CME

# The Anesthetic Considerations of Tracheobronchial Foreign Bodies in Children: A Literature Review of 12,979 Cases

Christina W. Fidkowski, MD,\* Hui Zheng, PhD,† and Paul G. Firth, MBChB\*‡

Asphyxiation by an inhaled foreign body is a leading cause of accidental death among children younger than 4 years. We analyzed the recent epidemiology of foreign body aspiration and reviewed the current trends in diagnosis and management. In this article, we discuss anesthetic management of bronchoscopy to remove objects. The reviewed articles total 12,979 pediatric bronchoscopies. Most aspirated foreign bodies are organic materials (81%, confidence interval [CI] = 77%–86%), nuts and seeds being the most common. The majority of foreign bodies (88%, CI = 85%–91%) lodge in the bronchial tree, with the remainder catching in the larynx or trachea. The incidence of right-sided foreign bodies (52%, CI = 48%–55%) is higher than that of left-sided foreign bodies (33%, CI = 30%–37%). A small number of objects fragment and lodge in different parts of the airways. Only 11% (CI = 8%–16%) of the foreign bodies were radio-opaque on radiograph, with chest radiographs being normal in 17% of children (CI = 13%–22%). Although rigid bronchoscopy is the traditional diagnostic “gold standard,” the use of computerized tomography, virtual bronchoscopy, and flexible bronchoscopy is increasing. Reported mortality during bronchoscopy is 0.42%. Although asphyxia at presentation or initial emergency bronchoscopy causes some deaths, hypoxic cardiac arrest during retrieval of the object, bronchial rupture, and unspecified intraoperative complications in previously stable patients constitute the majority of in-hospital fatalities. Major complications include severe laryngeal edema or bronchospasm requiring tracheotomy or reintubation, pneumothorax, pneumomediastinum, cardiac arrest, tracheal or bronchial laceration, and hypoxic brain damage (0.96%). Aspiration of gastric contents is not reported. Preoperative assessment should determine where the aspirated foreign body has lodged, what was aspirated, and when the aspiration occurred (“what, where, when”). The choices of inhaled or IV induction, spontaneous or controlled ventilation, and inhaled or IV maintenance may be individualized to the circumstances. Although several anesthetic techniques are effective for managing children with foreign body aspiration, there is no consensus from the literature as to which technique is optimal. An induction that maintains spontaneous ventilation is commonly practiced to minimize the risk of converting a partial proximal obstruction to a complete obstruction. Controlled ventilation combined with IV drugs and paralysis allows for suitable rigid bronchoscopy conditions and a consistent level of anesthesia. Close communication between the anesthesiologist, bronchoscopist, and assistants is essential. (*Anesth Analg* 2010;111:1016–25)

Aspiration of foreign bodies by children is a common problem around the world. Asphyxiation from inhaled foreign bodies is a leading cause of accidental death among children younger than 4 years. During the 19th century, treatment of foreign body aspiration by

purges, bleeding, and emetics were largely ineffective. Mortality was estimated at 23%. This rate plummeted with the development of bronchoscopic techniques for the removal of these foreign bodies.<sup>1</sup> In 1897, Gustav Killian, a German otolaryngologist, performed the first bronchoscopy using a rigid esophagoscope to successfully remove a pig bone from a farmer’s right main bronchus.<sup>1,2</sup> Algernon Coolidge performed the first successful removal of a tracheal foreign body in the United States at the Massachusetts General Hospital in 1898.<sup>1</sup> Shortly thereafter, Chevalier Jackson developed the lighted bronchoscope and several specialized instruments for the removal of foreign bodies.<sup>3</sup> He pioneered developments in the field and saved the lives of hundreds of children who had aspirated objects.<sup>4</sup> While early clinicians used topical anesthesia, general anesthesia became commonplace for the removal of aspirated objects with increased experience with the rigid bronchoscope and advances in anesthetic delivery. The flexible bronchoscope was introduced by Shigeto Ikeda in 1966,<sup>5</sup> and the removal of an airway foreign body using this instrument was reported in the 1970s.<sup>6</sup>

From the \*Department of Anesthesia, Critical Care and Pain Medicine, and the †Biostatistics Center, Massachusetts General Hospital, Boston; and the ‡Department of Anesthesia, Massachusetts Eye and Ear Infirmary, Boston. Christina W. Fidkowski is now affiliated with the Department of Anesthesiology, Henry Ford Hospital, Detroit, Michigan.

Accepted for publication June 10, 2010.

Statistical and administrative support funded by the Department of Anesthesia, Critical Care and Pain Medicine, Massachusetts General Hospital, Boston, and the Department of Anesthesia, Massachusetts Eye and Ear Infirmary, Boston.

Supplemental digital content is available for this article. Direct URL citations appear in the printed text and are provided in the HTML and PDF versions of this article on the journal’s Web site ([www.anesthesia-analgesia.org](http://www.anesthesia-analgesia.org)).

Address correspondence and reprint requests to Paul G. Firth, Department of Anesthesia, Critical Care and Pain Medicine, Massachusetts General Hospital, Boston, MA 02114. Address e-mail to [pfirth@partners.org](mailto:pfirth@partners.org).

Copyright © 2010 International Anesthesia Research Society  
DOI: 10.1213/ANE.0b013e3181ef3e9c

Over the years, the steady accumulation of clinical reports has provided greater insight into the management of foreign body aspiration in children. In part as a result, morbidity and mortality from foreign body aspiration have drastically diminished. This article analyzes the recent epidemiology of foreign body aspiration, reviews the current trends in diagnosis and management, and discusses anesthetic management for bronchoscopy.

### CURRENT TRENDS IN FOREIGN BODY ASPIRATION

A preliminary Medline search of the literature from 1950 to 2009 yielded nearly 20,000 cases of foreign body aspiration in children. Before 2000, however, most case series were small, included both aspirated and ingested objects, mingled adult and pediatric patients, or were reported in various styles in differing specialist journals that precluded meta-analysis. In addition, anesthetic and surgical techniques have altered considerably in recent years, making a detailed review of older series less relevant. However, numerous large case series have been published recently that collectively allow for a clearer representation of the problem of pediatric aspiration, as well as current trends in management. A Medline search using the keywords *foreign body aspiration* with limits of the year 2000 to present was performed on October 1, 2009. Analysis was limited to studies (1) containing only patients with suspected or proven foreign body aspiration, (2) with >100 patients, (3) containing only children ages 18 years and younger, and (4) written in English. Of the 698 articles obtained, 33 met the inclusion criteria, of which 3 were excluded for containing duplicate patient data. The 30 articles reviewed report 12,979 children with suspected foreign body aspiration, of whom 11,145 were found to have aspirated an object.<sup>7-36</sup> Twenty-seven of these studies are retrospective analyses, and 3 studies are prospective analyses of all children with suspected or actual foreign body aspiration.<sup>12,13,19</sup> The cases in these series occurred within the last 20 years in 21 studies,<sup>8,9,11,12,14-18,20,21,23-26,28-31,33,34</sup> 8 covered a larger time span dating back to the 1980s,<sup>10,13,19,22,27,32,35,36</sup> and 1 study covered a 30-year time frame starting in 1973.<sup>7</sup>

To obtain a robust estimate of the various rates (true positive, gender, foreign body type and location, and radiographic outcome distributions), we applied a meta-analysis to the published data to account for the number of patients, the number of foreign body cases, and the number of outcomes reported in these 30 articles.<sup>7-36</sup> These meta-analyses use a Bayesian model to consider variations in study design, inclusion and exclusion criteria, and the study population among the different reported studies.

Most patients with aspirated foreign bodies are children younger than 3 years. Four series reported the median age, and 7 series reported the mean age of children with aspirated foreign bodies. The median and the mean age ranged from 1 to 2 years<sup>12,18,21,33</sup> and from 2.1 to 3.8 years,<sup>11,12,14,26,28,29,32</sup> respectively. With the exception of 2 Turkish studies with a high incidence of adolescent girls aspirating headscarf pins,<sup>24,34</sup> boys account for 61% (confidence interval [CI] = 59%–63%) of children with foreign body aspiration.<sup>7,9,17,21,22,26-29,32,33</sup>

**Table 1. Sensitivity, Specificity, Positive Predictive Value (PPV), and Negative Predictive Value (NPV) of a Witnessed Aspiration Effect for Foreign Body Aspiration**

	Sensitivity	Specificity	PPV	NPV
Aydogan et al. (1887, 1493) <sup>7</sup>	93.2	45.1	86.5	63.6
Ciftci et al. (663, 563) <sup>11</sup>	91.1	46.0	90.5	47.9
Tomaske et al. (370, 221) <sup>35</sup>	74.7	53.7	70.5	58.8
Ayed et al. (235, 206) <sup>8</sup>	81.6	37.9	90.3	22.4
Tokar et al. (214, 152) <sup>34</sup>	84.9	87.1	94.2	70.1
Skoulakis et al. (210, 130) <sup>31</sup>	91.5	56.3	77.3	80.4
Kiyan et al. (207, 153) <sup>25</sup>	37.3	96.3	96.6	35.1
Erikci et al. (189, 127) <sup>16</sup>	58.3	87.1	90.2	50.5
Heyer et al. (160, 122) <sup>20</sup>	75.4	92.1	96.8	53.8
Cohen et al. (142, 61) <sup>12</sup>	83.6	32.1	48.1	72.2

Values are percentages.

Data were available from 10 of the 30 studies that were reviewed. Study size is denoted (*n*, *n*) to represent the total number of patients and the number of patients with an aspirated foreign body, respectively.

Most (81%, CI = 77%–86%) of the aspirated foreign bodies are organic materials.<sup>7,9-11,19-21,23,24,26-36</sup> Nuts (especially peanuts) and seeds (mainly sunflower and watermelon) are the most commonly aspirated foreign bodies reported in almost all studies. The exception to this finding is an Italian series that found teeth to be the most commonly aspirated objects (33/121).<sup>13</sup> In adolescent Turkish females, headscarf pins are commonly aspirated.<sup>24,34</sup> As was reported in 24 studies, the majority of foreign bodies (88%, CI = 85%–91%) lodge in the bronchial tree, with the remainder catching in the larynx or trachea.<sup>7,9,10,12-19,22,25-36</sup> A higher incidence of right-sided foreign bodies (52%, CI = 48%–55%) in comparison with left-sided foreign bodies (33%, CI = 30%–37%) was reported in all of these studies, with the exception being a small series in Israel.<sup>12</sup> A small number of objects fragment and lodge in different parts of the airways.

A history of a witnessed choking event is highly suggestive of an acute aspiration. Data were available to determine the sensitivity, specificity, positive predictive value, and negative predictive value of a witnessed event in 10 studies (Table 1).<sup>7,8,11,12,16,20,25,31,34,35</sup> Children with aspirated foreign bodies typically present with the symptoms of coughing, dyspnea, wheezing, cyanosis, or stridor. Data were available in 10 studies to determine the sensitivity and the specificity of these presenting signs and symptoms (Table 2).<sup>8,12,16,20,23,25,29,31,34,35</sup> A history of cough is highly sensitive for foreign body aspiration but is not very specific. On the other hand, a history of cyanosis or stridor is very specific for foreign body aspiration but is not very sensitive. Signs and symptoms typical in delayed presentations include unilateral decreased breath sounds and rhonchi, persistent cough or wheezing, recurrent or nonresolving pneumonia, or rarely, pneumothorax.

**Table 2. Sensitivity (Sens) and Specificity (Spec) of Symptoms for Foreign Body Aspiration**

	Cough		Dyspnea		Wheeze		Cyanosis		Stridor	
	Sens	Spec	Sens	Spec	Sens	Spec	Sens	Spec	Sens	Spec
Tomaske et al. (370, 221) <sup>35</sup>	87.8	45.0			57.9	73.2			39.4	74.5
Ayed et al. (235, 206) <sup>8</sup>	80.1	34.5			30.1	65.5			16.5	65.5
Tokar et al. (214, 152) <sup>34</sup>	94.1	32.3			27.6	66.1				
Skoulakis et al. (210, 130) <sup>31</sup>	82.3	53.8	24.6	85.0			5.4	100	11.5	98.8
Kiyan et al. (207, 153) <sup>25</sup>	67.3	20.4	16.3	74.1	79.1	27.8	7.2	98.1		
Erikci et al. (189, 127) <sup>16</sup>	51.2	83.9	4.7	93.5	18.9	93.5				
Shivakumar et al. (165, 105) <sup>29</sup>	92.4	8.3	61.9	66.7	64.8	0	12.4	100	4.8	100
Heyer et al. (160, 122) <sup>20</sup>	41.0	55.3	33.6	68.4						
Kadmon et al. (150, 80) <sup>23</sup>			51.3	12.9					18.8	72.9
Cohen et al. (142, 61) <sup>67</sup>	93.4	28.4	14.8	92.6						

Values are percentages.

Data were available from 10 of the 30 studies that were reviewed to determine the sensitivity (Sens) and specificity (Spec) of the symptoms of cough, dyspnea, wheeze, cyanosis, and stridor for foreign body aspiration. Study size is denoted (n, n) to represent the total number of patients and the number of patients with an aspirated foreign body, respectively.

**Table 3. Sensitivity (Sens) and Specificity (Spec) of Radiographic Findings for Foreign Body Aspiration**

	Air trapping		Atelectasis		Mediastinal shift		Infiltrate	
	Sens	Spec	Sens	Spec	Sens	Spec	Sens	Spec
Tokar et al. (214, 152) <sup>34</sup>	41.7	91.9	12.6	71.0			11.9	74.2
Skoulakis et al. (210, 130) <sup>31</sup>	39.2	91.6	9.2	88.8			0	76.3
Kiyan et al. (207, 153) <sup>25</sup>	63.8	79.6	8.0	94.4			4.4	94.4
Shivakumar et al. (165, 105) <sup>29</sup>	49.5	80.0	22.9	83.3			3.8	41.7
Heyer et al. (160, 122) <sup>20</sup>	62.3	97.4	8.2	97.4	20.5	97.4	18.9	84.2
Kadmon et al. (150, 80) <sup>23</sup>	50.0	90.0			38.8	97.1		
Cohen et al. (142, 61) <sup>67</sup>	49.2	86.4	6.6	96.3	13.1	100	14.8	79.0

Values are percentages.

Data were available from 8 of the 30 studies that were reviewed to determine the sensitivity (Sens) and specificity (Spec) of the radiographic findings of localized air trapping, atelectasis, mediastinal shift, and infiltrate for foreign body aspiration. Study size is denoted (n, n) to represent the total the number of patients and the number of patients with an aspirated foreign body, respectively.

Most stable patients had chest radiographs. As was reported in 20 studies, only 11% (CI = 8%–16%) of the foreign bodies were radio-opaque.<sup>7,9,12–17,19,20,23–25,27–29,32,34–36</sup> Chest radiographs were normal in 17% (CI = 13%–22%) of children with aspirated objects as were reported in 14 studies.<sup>9,11,12,17,22,24,25,27–29,32–35</sup> The common radiographic abnormalities included localized emphysema and air trapping, atelectasis, infiltrate, and mediastinal shift. Data were available in 8 studies to calculate the sensitivity and specificity of these radiographic findings (Table 3).<sup>11,12,20,23,25,29,31,34</sup> Pneumothorax and pneumomediastinum are less common findings on chest radiograph (range: 0.1%–3.7%), as was reported in 7 studies.<sup>14,15,22,28,32,33</sup>

While rigid bronchoscopy was used solely for the removal of foreign bodies in most studies, both flexible and rigid bronchoscopies were used in 4 series.<sup>12,13,20,33</sup> A minority of foreign bodies were removed by flexible bronchoscopy in 3 of these studies (range: 4.1%–10.7%),<sup>12,13,20</sup> whereas Tang et al.<sup>33</sup> reported successful removal by flexible bronchoscopy in 91.3% of children with foreign body aspiration. For this study, local anesthesia with sedation was used during bronchoscopy. For children undergoing rigid bronchoscopy, general anesthesia was used in all studies, and details regarding the anesthetic technique were provided in 12 studies. Both inhaled<sup>7,15,31,36</sup> and IV<sup>13,19</sup> inductions were reported. Similarly, anesthesia was maintained with either inhaled<sup>15,19,31,36</sup> or IV<sup>20,22,25</sup> drugs or a balanced anesthetic.<sup>13</sup> Five studies reported the use of neuromuscular blockers.<sup>7,9,15,19,22</sup> Bittencourt et al.<sup>9</sup> and

Hasdiraz et al.<sup>19</sup> used paralysis as needed during the procedure and attempted to maintain spontaneous ventilation when possible. On the other hand, Divisi et al.<sup>13</sup> commented that spontaneous ventilation is not suitable for rigid bronchoscopy because of resultant oxygen desaturation and used a balance anesthetic with sevoflurane and remifentanyl. Shivakumar et al.<sup>29</sup> used jet ventilation to prevent oxygen desaturation. None of the authors commented on using drying drugs such as glycopyrolate before bronchoscopy. Seven studies commented on using steroids for laryngeal edema, with the majority of those authors favoring steroid use only as needed,<sup>7,13,19,22,30</sup> as opposed to routine administration.<sup>25,36</sup> In 4 studies, antibiotics were given routinely preoperatively,<sup>19,25</sup> postoperatively,<sup>36</sup> or as a 5-day course,<sup>30</sup> whereas authors in 3 studies favored antibiotic administration only as needed for infection.<sup>7,13,24</sup>

Major iatrogenic complications were specified in 21 studies with 9437 children with aspirated foreign bodies. The other 9 studies did not provide details or rates of complications. These complications included severe laryngeal edema or bronchospasm requiring tracheotomy or reintubation, pneumothorax, pneumomediastinum, cardiac arrest, tracheal or bronchial laceration, and hypoxic brain damage. These major complications occurred in 91 of these 9437 children (0.96%) (Table 4). Of the 11 cardiac arrests that were reported, 1 occurred after induction of anesthesia in a child who was hypoxic on admission, 5 occurred during bronchoscopy because of hypoxia (3) or bleeding (2), and the remaining 5 were not specified. Other reported

**Table 4. Morbidity Associated with Bronchoscopy for the Removal of Tracheobronchial Foreign Bodies**

Complication	Total n
Major nonfatal complications (n = 91)	
Severe laryngeal edema or bronchospasm requiring tracheotomy or reintubation <sup>15,19,22,25,27,30,32</sup>	43
Pneumothorax or pneumomediastinum <sup>7,11,15,18,19,22,30,32,33</sup>	27
Cardiac arrest <sup>11,15,25,27</sup>	11
Hypoxic brain damage <sup>20,21</sup>	5
Tracheal or bronchial laceration requiring repair <sup>11,15,27</sup>	5
Other serious complications (n = 136)	
Infection <sup>13,19,21,26,32</sup>	58
Failed bronchoscopy requiring thoracotomy (27) <sup>7,8,11,13,15,19,36</sup> or tracheotomy (10) <sup>7,15</sup>	37
Bleeding <sup>15,19,27</sup>	29
Thoracotomy (5) <sup>8,15,19</sup> or tracheotomy (7) <sup>7,32</sup> —not specified	12

Major iatrogenic complications, as were specified in 21 studies, occurred in 91 of the 9437 children with aspirated foreign bodies. Other serious complications occurred in 136 of these 9437 children.

**Table 5. Mortality Associated with Bronchoscopy for the Removal of Tracheobronchial Foreign Bodies**

Cause of death (n = 43)	n
Cardiac/respiratory arrest	37
Hypoxic arrest at presentation <sup>7,9,11,22,27,32,36</sup>	15
Arrest due to tracheal foreign body <sup>19,26</sup>	5
Cardiac arrest during bronchoscopy, not specified <sup>10,11</sup>	3
Postoperative arrest <sup>19,29</sup>	3
Hypoxic arrest due to shifting foreign body <sup>22</sup>	2
Rupture of puss under pressure behind foreign body <sup>19</sup>	1
Respiratory arrest due to inhaled cement powder <sup>19</sup>	1
Not specified <sup>15</sup>	7
Bronchial rupture <sup>15</sup>	2
Severe bronchospasm <sup>15</sup>	1
Postoperative infection <sup>11</sup>	1
Multiorgan failure <sup>21</sup>	1
Not specified <sup>18</sup>	1

Deaths, as were specified in 26 studies, occurred in 43 of the 10,236 children with aspirated foreign bodies.

serious complications included infection, bleeding, and failed bronchoscopic removal that necessitated thoracotomy or tracheotomy to remove the object (Table 4).

Mortality data were obtained from 26 articles with 43 deaths among 10,236 children (0.42%) with aspirated foreign bodies (Table 5). The remaining 4 articles did not provide details of death rates. Twenty-five deaths occurred in the 5 largest series with 5927 children (0.42%).<sup>7,15,19,22,33</sup> In 2003, Eren et al.<sup>15</sup> reported 10 deaths in 1068 children (0.94%) undergoing rigid bronchoscopy for foreign body removal under general anesthesia in Turkey. Seven died of hypoxic arrest during bronchoscopy, 2 of bronchial rupture, and 1 of intractable bronchospasm. Shortly thereafter, their countrymen Aydogan et al. reported 4 deaths in 1493 children (0.27%) with foreign body aspiration undergoing rigid bronchoscopy over a 31-year period.<sup>7</sup> All 4 fatalities

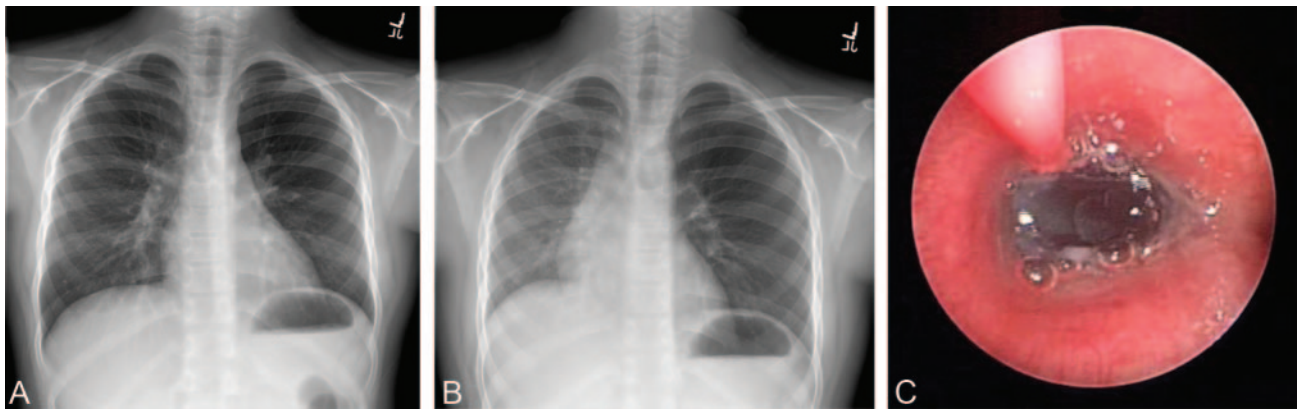
were in children presenting with acute cyanosis and respiratory distress. Hasdiraz et al.<sup>19</sup> reported 8 deaths in 911 Turkish children (0.88%) with foreign body aspiration undergoing rigid bronchoscopy. Three children developed cardiac arrest from total tracheal obstruction, 2 had heart failure and bronchopneumonia at the time of bronchoscopy and developed cardiac arrest postoperatively, 1 developed respiratory arrest due to inhalation of cement powder, 1 developed sepsis and respiratory failure after explosive release of purulent discharge from behind the foreign body, and 1 developed a respiratory arrest after a negative bronchoscopy and was found to have a tracheal foreign body at autopsy. In 2008, Hui et al.<sup>22</sup> reported 3 deaths among 1428 children (0.21%) undergoing rigid bronchoscopy over a 22-year period in China. Two died after foreign body displacement during bronchoscopy, and 1 died of asphyxia during a delay before bronchoscopy. In 2009, Tang et al.<sup>33</sup> reported no deaths among 1027 children in China undergoing bronchoscopy for foreign body removal. In that series, 938 foreign bodies were removed by flexible bronchoscopy, and 89 foreign bodies were removed by rigid bronchoscopy. Of the remaining 18 deaths in the 21 other reports, 10 were due to irreversible cardiac arrest on admission.<sup>9,11,27,32,36</sup>

## DIAGNOSIS AND MANAGEMENT

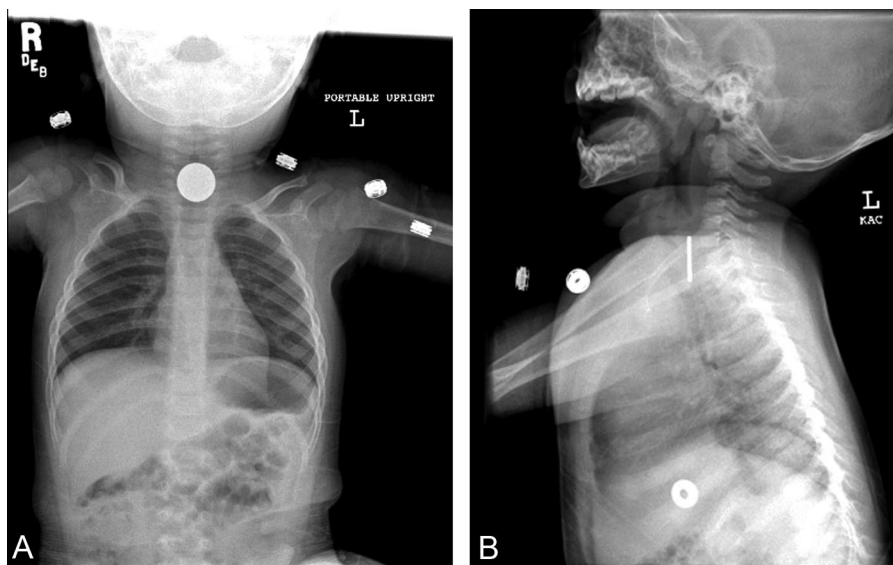
A suggestive history is important in diagnosing an aspirated object, because it is often difficult to make a definitive diagnosis on the basis of an abnormal physical examination or radiological studies alone. The work-up of the stable patient should include a chest radiograph to assess for other potential causes of symptoms, to identify a radio-opaque foreign body, or to detect the position of a foreign body on the basis of localized emphysema and air-trapping, atelectasis, infiltrate, or mediastinal shift.<sup>37</sup> The common abnormality of unilateral hyperinflation seen on the chest radiograph due to air trapping behind the foreign body is best viewed at end expiration (Fig. 1). (Video 1; see Supplemental Digital Content 1, <http://links.lww.com/AA/A169>; see the Appendix for video legends). Although a decubitus view has been suggested to look for air trapping in the dependent lung of small children who cannot cooperate with expiratory films, one study found this to be an unreliable technique.<sup>38</sup>

Neck radiographs may be helpful in managing upper aerodigestive tract foreign bodies. The alignment of flat objects, such as coins, may suggest the location of an object (Fig. 2A, 2B). Tracheal objects tend to align in the sagittal plane, whereas esophageal objects tend to align in the anterior plane. An object that overlaps the boundaries of the airway on an anterior-posterior view is unlikely to be inside the airway. Lateral radiographs may show soft tissue swelling, loss of cervical lordosis, or an object posterior to the trachea. Proximal esophageal objects can be removed with a forceps under direct vision, with the laryngoscope blade inserted into the esophagus to visualize the body and protect the airway during removal of the object.

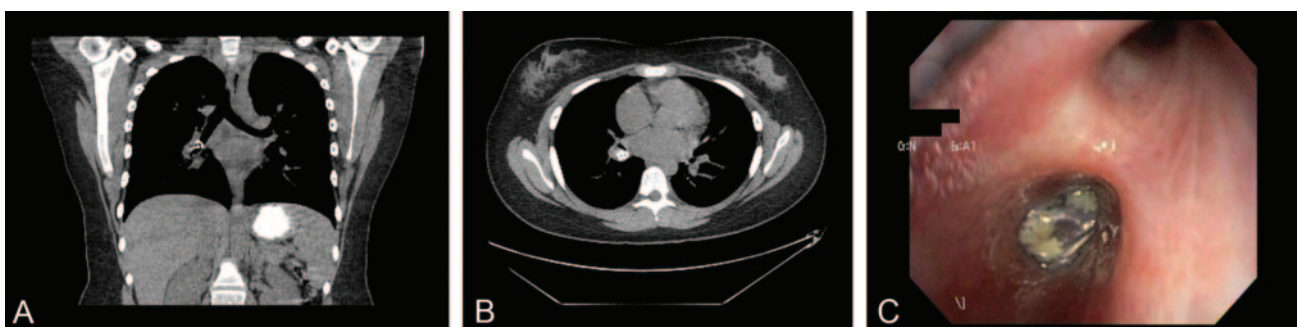
Thoracic computed tomography (CT) and virtual bronchoscopy—a reformatted 3-dimensional CT image that generates intraluminal views of the airway to the sixth and seventh generation bronchi—are emerging as new modalities to diagnose tracheobronchial foreign bodies in children



**Figure 1.** A, Chest radiograph on end inspiration of a patient with a delayed presentation of an aspirated foreign body aspiration. B, Chest radiograph on end expiration. Delayed emptying of the left lung suggests local air trapping. The foreign body was in the left bronchus. C, The offending object seen on rigid bronchoscopy. The airway edema (white-gray) can be seen around the black foreign body, with bubbles reflecting delayed air release during expiration. A Fogarty catheter is passed beyond the object in preparation for dislodgement. Images courtesy of Dr. Dan Doody, Department of Surgery, Massachusetts General Hospital, Boston, Massachusetts.



**Figure 2.** A, The sagittal orientation of a proximal aerodigestive foreign body suggests an esophageal location. B, A lateral view can demonstrate a position posterior to the esophagus. Images courtesy of Dr. Allan Goldstein, Department of Surgery, Massachusetts General Hospital, Boston, Massachusetts.



**Figure 3.** A, B, Computerized tomography scan of an aspirated soda can top, using a low-resolution pediatric protocol to minimize radiation exposure. The object was not seen on initial chest radiograph. A small aluminum object, although metal, has insufficient radiopacity for a plain chest radiograph, and the object did not produce major obstruction leading to overt pulmonary changes. A computed tomography (CT) scan has a greater range of sensitivity. C, The offending object in the bronchus intermedius. (Images courtesy of Dr. Pallavi Sagar, Department of Radiology, and Dr. David Lawlor, Department of Surgery, Massachusetts General Hospital, Boston, MA.)

(Fig. 3).<sup>39,40</sup> CT and virtual bronchoscopy are more sensitive diagnostic modalities for foreign body aspiration in comparison with conventional chest radiography.<sup>41,42</sup> Secretions, tumors, or other obstructive lesions can produce

false-positive findings. In a retrospective analysis, spiral CT correctly identified all 42 children with aspirated foreign bodies.<sup>41</sup> In that study, 3 children had false-positive CT images due to excess bronchial secretions, and 6 children

had true negative scans. In 2 retrospective studies, virtual bronchoscopy correctly identified 11 of 11 and 15 of 23 children, respectively, with aspirated foreign bodies.<sup>42,43</sup> No false-positive virtual bronchoscopies were reported in those studies. The diagnostic utility of virtual bronchoscopy has also been shown prospectively.<sup>44,45</sup> Haliloglu et al.<sup>45</sup> demonstrated that virtual bronchoscopy findings correlated with those of conventional bronchoscopy in 23 children, of whom 7 had foreign body aspiration and 16 did not have foreign body aspiration. In a prospective study of 37 children with suspected foreign body aspiration, 16 had a positive virtual bronchoscopy, of whom 13 had a foreign body found with conventional bronchoscopy, and 3 had either mucous plugs or a schwannoma found with conventional bronchoscopy.<sup>44</sup> The remaining 21 patients had a negative bronchoscopy and were observed with improvement in their symptoms.<sup>44</sup> These studies demonstrate that CT and virtual bronchoscopy correctly identified all cases of foreign body aspiration. Therefore, some authors suggested that children with a negative CT and virtual bronchoscopy may not require conventional bronchoscopy as a definitive work-up.<sup>44</sup>

A drawback of CT and virtual bronchoscopy is the potential for excessive radiation exposure. A chest radiograph exposes the child to 0.1 mSv of radiation, equivalent to several days of background environmental radiation. Although a high-resolution pediatric chest CT can involve up to 7 mSv of radiation, a lower-resolution scan protocol using 1.5 mSv is usually sufficient to diagnose a foreign body. Adequate 3-dimensional views can be subsequently formatted from this level of detail.

Further limitations include the cost and limited availability of equipment and radiologists. In addition, CT examination is limited to stable and cooperative children, because anesthesia in a remote location for a child with an unstable object that can potentially acutely obstruct the airway poses significant risks.

Although rigid bronchoscopy has traditionally been the definitive method to diagnose and remove tracheobronchial foreign bodies, a diagnostic flexible bronchoscopy under local anesthesia may be indicated for patients without a clear history or findings of aspiration.<sup>23,46–48</sup> In a prospective study, children with convincing evidence of foreign body aspiration were examined with rigid bronchoscopy under general anesthesia, whereas others with less-suggestive findings underwent flexible bronchoscopy with local anesthesia.<sup>47</sup> Of the 28 children who underwent rigid bronchoscopy, 23 (82%) had a foreign body aspiration. Of the 55 children who underwent flexible bronchoscopy, only 17 (34%) had a foreign body aspiration. Another prospective study found that 43 (84%) of 51 children who underwent rigid bronchoscopy and only 7 (37%) of 19 children undergoing flexible bronchoscopy had positive studies for foreign body aspiration.<sup>48</sup> Both studies found a significant association of aspirated foreign bodies with unilateral decreased breath sounds, localized wheezing, and obstructive emphysema on chest radiograph.<sup>47,48</sup> These authors recommended that children undergo rigid bronchoscopy only if they have acute asphyxiation, a radio-opaque foreign body, unilateral pulmonary signs, or obstructive emphysema. All other children should undergo

a diagnostic flexible bronchoscopy. When this algorithm was applied retrospectively, the negative finding rate of rigid bronchoscopy decreased from 18% to 4% and from 16% to 6%, respectively.<sup>47,48</sup> No adverse events were reported with flexible bronchoscopy.<sup>47,48</sup> Therefore, diagnostic flexible bronchoscopy in selected children minimizes the potential complications of rigid bronchoscopies. More recently, Kadmon et al.<sup>23</sup> proposed a computer model based on history, physical examination, and radiographic findings to calculate a score that predicts the likelihood of foreign body aspiration in children. They further suggested an algorithm to observe a child, perform diagnostic flexible bronchoscopy, or perform therapeutic rigid bronchoscopy on the basis of the calculated score. A prospective study is warranted to determine the utility of this model.

In addition to aiding in the diagnosis of aspirated foreign bodies, flexible bronchoscopy is becoming more popular for the removal of foreign bodies.<sup>33,49–52</sup> In a large retrospective study, a foreign body was successfully removed by flexible bronchoscopy in 938 (91.3%) children.<sup>33</sup> Flexible bronchoscopy is better suited for removing foreign bodies from distal airways and upper lobe bronchi, because of the smaller diameter and greater flexibility in comparison with the rigid bronchoscope. Fewer instruments, however, are available for use with the flexible bronchoscope to remove the foreign bodies. Rigid bronchoscopy continues to be used to remove aspirated foreign bodies because multiple extraction instruments are available and because it provides good visualization, controls the airway, and allows ventilation.

## ANESTHETIC MANAGEMENT FOR BRONCHOSCOPY

Anesthetic considerations encompass preoperative assessment, management techniques for flexible or rigid bronchoscopy, and postbronchoscopic disposition.

### Preoperative Assessment

The preoperative assessment should determine where the aspirated foreign body has lodged, what was aspirated, and when the aspiration occurred. If the foreign body is located in the trachea, the child is at risk for complete airway obstruction and should be taken urgently to the operating room. Conversely, the risk of complete airway obstruction is less if the object is firmly lodged beyond the carina. It is important to determine the type of foreign body: Organic materials can absorb fluid and swell, oils from nuts cause localized inflammation, and sharp objects can pierce the airway. The time since the aspiration should be established because airway edema, granulation tissue, and infection may make retrieval more difficult with delayed presentations. A recently aspirated object may move to a different position with coughing.

The time of the last meal should be established to assess the risk of aspiration. There are no reports of aspiration of gastric contents in the literature surveyed, although fatal progression of obstruction has been reported.<sup>7,9,11,22,27,32,36</sup> In acute cases, therefore, the dangers of delayed removal appear to outweigh the risk of a full stomach in a well-conducted anesthetic. In urgent cases, the stomach can be suctioned through a large-bore gastric tube after induction but before the bronchoscope is inserted to minimize the risk of

gastric aspiration. In delayed presentations in which bronchoscopy is not urgent, a preanesthetic fast is appropriate.

The airway patency should be assessed. If the patient is in severe distress, urgent bronchoscopy should be performed. If the patient is stable, however, some authors suggest that bronchoscopy may be performed during normal daytime operating hours to ensure optimal conditions with an experienced bronchoscopist and anesthesiologist.<sup>53</sup> These authors found no increase in morbidity in stable patients by delaying bronchoscopy for a suspected foreign body until the next available elective daytime slot.<sup>53</sup>

### Anesthetic Considerations for Rigid Bronchoscopy

Because surgeon and anesthesiologist share management of a potentially obstructed airway, clear communication and good cooperation are essential. Before induction, a detailed anesthetic and operative plan should be discussed. The 3 main anesthetic issues involve the methods of induction, ventilation during bronchoscopy, and maintenance of anesthesia.

The choice of induction is dominated by the consideration of converting a proximal partial obstruction into a complete obstruction. The conversion from spontaneous negative pressure breathing to positive pressure ventilation theoretically risks dislodging an unstable proximal body, causing complete obstruction.<sup>54</sup> Although hypoxic arrest during the initial stages of bronchoscopy is a recognized cause of death,<sup>10,11,19</sup> the relative contributions of obstruction on initial presentation, during the induction of anesthesia, and from dislodgement during bronchoscopy, are unclear from published accounts. A survey of 838 pediatric anesthesiologists found that the majority preferred an inhaled induction when foreign bodies were present in the tracheobronchial tree.<sup>55</sup> A cautious IV induction that maintains spontaneous ventilation is also possible, although this was not an option in that particular survey study. While the optimal method of induction is not definitively established, maintaining spontaneous ventilation during the induction of a patient with a proximal foreign body is commonly practiced.

After induction of general anesthesia, the rigid bronchoscope is inserted through the glottic opening. The anesthesia circuit is connected to the sideport of the bronchoscope to allow ventilation. Both spontaneous ventilation and controlled ventilation are feasible for removal of foreign bodies. Spontaneous ventilation around the bronchoscope may be more suitable for removal of proximal bodies, during which leakage around the scope may make effective positive pressure ventilation difficult. Manually closing the mouth and nose can diminish a large leak around the scope and improve ventilation. Positive pressure ventilation down the bronchoscope, with intermittent apnea while manipulating the object, may be more suitable for distal retrieval. The use of optical forceps allows for positive pressure ventilation to be maintained while the foreign body is being manipulated so that periods of apnea can be minimized (Video 2; see Supplemental Digital Content 2, <http://links.lww.com/AA/A170>; see the Appendix for video legends). Because airway trauma and rupture are significant and potentially fatal complications, it is essential to avoid coughing and bucking secondary to the intense stimulation from a rigid bronchoscope deep in the

bronchial tree. Movement can be prevented with neuromuscular blocking drugs<sup>9,54,56,57</sup> or with a deep level of anesthesia. One study suggests that topicalization of the tracheobronchial mucosal using a rigid bronchoscope coated with local anesthetic gel improves surgical conditions and more effectively maintains spontaneous ventilation while decreasing the doses of anesthetics.<sup>58</sup> Although the risk of positive pressure ventilation causing distal air trapping by a ball-valve effect has been suggested,<sup>59,60</sup> there is no clear clinical evidence in the literature surveyed to support this as a practical concern.

A retrospective review of 94 children with aspirated foreign bodies detected no difference in adverse events on the basis of the type of ventilation.<sup>61</sup> However, 5 of 18 children who were maintained on assisted ventilation and 11 of 26 who were maintained on spontaneous ventilation were switched to controlled ventilation. A prospective study of 36 children with aspirated foreign bodies found that controlled ventilation is more effective than is spontaneous ventilation.<sup>54</sup> All children in the spontaneous ventilation group were switched to either assisted or controlled ventilation because of coughing and bucking. It is possible, however, that the necessity of switching from spontaneous to either assisted or controlled ventilation was due to an inadequate depth of anesthesia with inhaled drugs rather than an inherent problem with spontaneous ventilation.<sup>62</sup> Larger prospective studies, with both inhaled and IV maintenance techniques, are necessary to further evaluate whether spontaneous or controlled ventilation is more advantageous. In a nonrandomized observational study, manual jet ventilation was shown to decrease the incidence of intraoperative hypoxemia in comparison with manual controlled ventilation and spontaneous ventilation.<sup>63</sup> Manual jet ventilation may better allow oxygenation and ventilation of the unobstructed lung during manipulation of the foreign body because the jet ventilation catheter was inserted separately from the bronchoscope.<sup>63</sup>

Halothane and sevoflurane are 2 volatile anesthetics that are widely used in pediatric practice. Meretoja et al.<sup>64</sup> compared sevoflurane with halothane in 120 children undergoing bronchoscopy, gastroscopy, or combined procedures. They reported a higher incidence of cardiac arrhythmias (nodal rhythm, bigeminy or ventricular ectopy) in the halothane group (18/60 vs. 4/60). Batra et al.<sup>65</sup> compared the 2 drugs in 44 children undergoing bronchoscopy specifically for foreign body removal and found a higher incidence of cardiac arrhythmias in the halothane group (7/22 vs. 2/22). When comparing halothane and sevoflurane for 62 pediatric bronchoscopies, Davidson<sup>66</sup> found no differences in cord closure, desaturations, breath holding, or coughing.

Although inhaled drugs have traditionally been used for the maintenance of anesthesia,<sup>54,59,61,67</sup> total IV techniques are becoming more popular in the pediatric population.<sup>56,62,68,69</sup> A total IV anesthetic with propofol (200 to 400  $\mu\text{g} \cdot \text{kg}^{-1} \cdot \text{min}^{-1}$ ) and remifentanyl (0.05 to 0.2  $\mu\text{g} \cdot \text{kg}^{-1} \cdot \text{min}^{-1}$ ) infusions in combination with vocal cord topicalization with lidocaine (1 mg  $\cdot \text{kg}^{-1}$ ) allows for spontaneous ventilation.<sup>62</sup> Children younger than 3 years of age can tolerate higher doses of remifentanyl and still maintain spontaneous ventilation in comparison with older children.<sup>70</sup> An advantage of an IV anesthetic is that it provides

a constant level of anesthesia irrespective of ventilation. By contrast, hypoventilation and leaks around the rigid bronchoscope may produce an inadequate depth of inhaled anesthesia. Pollution of the operating room, due to the combination of leaks around the rigid bronchoscope and high gas flows needed for ventilation, are additional drawbacks of inhalation anesthetics. Chen et al.<sup>63</sup> showed that a total IV technique with spontaneous ventilation was associated with a higher incidence of body movement, breath holding, and laryngospasm in comparison with an inhaled technique. However, the doses of IV propofol ( $100$  to  $150 \mu\text{g} \cdot \text{kg}^{-1} \cdot \text{min}^{-1}$ ) and remifentanyl ( $0.1 \mu\text{g} \cdot \text{kg}^{-1} \cdot \text{min}^{-1}$ ) were less than those previously described to provide anesthesia and maintain spontaneous ventilation.

Dropping the foreign body during retrieval is a potentially life-threatening complication.<sup>71,72</sup> The vocal cords should be well relaxed, either by residual topicalization, paralysis, or an adequate depth of anesthesia, before removal of the foreign body through the larynx. Dropping the foreign body has a higher correlation with the experience level of the bronchoscopist than with the mode of ventilation.<sup>72</sup> If the object is dropped in the proximal airway and cannot immediately be removed, pushing it back into a bronchus can eliminate an obstruction. If a bronchial body falls into the other bronchus, there is potential for complete airway obstruction due to edema and inflammation at the original site.<sup>71</sup> In the setting of a marginal airway, optimization of other components of ventilation is essential. Ventilation may be impaired not only by the object, but also proximally by upper-airway soft tissue or cord closure, and distally by atelectasis after prolonged intraoperative hypoventilation. Optimal head position, open cords, reinflation of atelectatic segments, and slow prolonged breaths with adequate pressure can provide ventilation past a partial obstruction. If ventilation is impossible, emergent efforts must be made to extract or move the object. In severe cases of cardiopulmonary failure due to foreign body obstruction, extracorporeal membrane oxygenation may facilitate foreign body removal and cardiopulmonary recovery.<sup>73</sup>

After the extraction of the foreign body and the removal of the rigid bronchoscope, the choice of ventilation during emergence is influenced by pulmonary gas exchange and the degree of airway edema. For uncomplicated cases, spontaneous ventilation assisted by mask ventilation as needed may be adequate. Intubation during emergence may be indicated for a marginal airway, pulmonary compromise, or residual neuromuscular blockade.

### Anesthetic Considerations for Flexible Bronchoscopy

Flexible bronchoscopy can be performed with local anesthetic topicalization and sedation in both children and adults.<sup>47-49,74-77</sup> IM meperidine and oral diazepam,<sup>75</sup> IV midazolam or fentanyl,<sup>75</sup> and atropine and diazepam<sup>49,76</sup> or sublingual codeine<sup>74</sup> have been successfully used to sedate adolescents and adults. Topical lidocaine to the nasopharynx and larynx was combined with  $0.1$  to  $0.3 \text{ mg/kg}$  rectal midazolam for 19 younger children.<sup>48</sup> Aerosolized lidocaine in combination with an IM dose of either atropine ( $0.01$  to  $0.02 \text{ mg/kg}$ ) and diazepam ( $0.1$  to  $0.2$

$\text{mg/kg}$ ) or midazolam ( $0.1$  to  $0.15 \text{ mg/kg}$ ) was used for sedation in 938 young children who had a foreign body removed by flexible bronchoscopy.<sup>33</sup> In that series, the flexible bronchoscope was inserted intranasally unless nasal stenosis was present.<sup>33</sup>

In smaller children who are unable to cooperate, several techniques of general anesthesia have been reported. A balanced anesthetic using IV propofol and sevoflurane with topical lidocaine and oxymetazoline was used for 23 children ages 9 months to 16 years.<sup>50</sup> The fiberoptic bronchoscope was then inserted through a T-piece on the child's facemask and advanced transnasally. In a series of 6 children ages 1.2 to 5 years spontaneously breathing under sevoflurane anesthesia, the bronchoscope was inserted through a swivel adapter on a laryngeal mask airway.<sup>52</sup> The foreign bodies were removed en bloc with the laryngeal mask with no adverse events. Flexible bronchoscopy through endotracheal tubes under general anesthesia is also described in which the foreign body, bronchoscope, and endotracheal tube are removed en bloc.<sup>51</sup> A standard pediatric bronchoscope ( $3.6 \text{ mm}$  outer diameter) can be used with a size 4.5 or larger endotracheal tube, whereas standard adult bronchoscopes ( $4.9 \text{ mm}$  diameter) will fit into size 2 or larger laryngeal mask.

### Postoperative Considerations

Early discharge after uncomplicated bronchoscopy is reasonable. In one study, 187 (65%) children were discharged home within 4 hours after rigid bronchoscopy.<sup>78</sup> In another study, 82 (60.7%) children had a hospital stay  $<1$  day.<sup>32</sup> Prolonged pulmonary recovery may prevent early discharge. Predictive factors of prolonged recovery included evidence of inflammation on preoperative radiographs, aggravation of pulmonary lesions on postoperative films, and a prolonged duration of bronchoscopy.<sup>28,79</sup> Ciftci et al.<sup>11</sup> found bronchoscopy time ( $57 \pm 2.9$  minutes vs.  $23 \pm 1.2$  minutes) to be prolonged in children with postoperative complications in comparison with those without complications. Chen et al.<sup>63</sup> found that postoperative hypoxemia was associated with prolonged emergence from anesthesia and with foreign bodies that were plant seeds.

### CONCLUSIONS

Aspiration of a foreign body is a potentially lethal event. Although many deaths occur before arrival at the hospital, anesthesia and bronchoscopy to remove the offending item are associated with considerable mortality and morbidity. Outcomes have improved over the years because of advances in anesthesia and bronchoscopy. Although several anesthetic techniques are effective for managing children with foreign body aspiration, there is no consensus from the literature as to which technique is optimal. An induction that maintains spontaneous ventilation is commonly practiced to minimize the risk of converting a partial proximal obstruction to a complete obstruction. Controlled ventilation combined with IV drugs and paralysis allows for suitable rigid bronchoscopy conditions and a consistent level of anesthesia. The use of CT and virtual bronchoscopy to diagnose foreign body aspiration and the use of flexible bronchoscopy for the diagnosis and removal of foreign bodies may decrease the necessity for rigid bronchoscopy



under general anesthesia in patients with suspected foreign body aspiration. As a result, morbidity and mortality in these children may further decrease. Regardless of the management strategy, close cooperation within a skilled surgical and anesthetic team is essential to avoid the potential hazards of foreign body aspiration. ■■

**ACKNOWLEDGMENTS**

We wish to thank the following for assistance in preparation of this manuscript: Daniel Doody, MD, Gennadiy Fuzaylov, MD, Allan Goldstein, MD, Kenan Haver, MD, David Lawlor, MD, and Pallavi Sagar, MD, all of the Massachusetts General Hospital; Cory Collins, DO, and Christopher Hartnick, MD, both of the Massachusetts Eye and Ear Infirmary; and all of Harvard Medical School, Boston, Massachusetts.

**APPENDIX: VIDEO CAPTIONS**

**Video 1.** Rigid bronchoscopy down the left mainstem bronchus. Bubbles formed by release of trapped air can be seen during spontaneous breathing.

**Video 2.** An optical forceps is used to grasp and remove the object via rigid bronchoscopy.

**REFERENCES**

1. Clerf LH. Historical aspects of foreign bodies in the air and food passages. *South Med J* 1975;68:1449–54
2. Zaytoun GM, Rouadi PW, Baki DH. Endoscopic management of foreign bodies in the tracheobronchial tree: predictive factors for complications. *Otolaryngol Head Neck Surg* 2000;123:311–6
3. Jackson C. *The Life of Chevalier Jackson: An Autobiography*. New York: Macmillan, 1938
4. Jackson C. *Foreign Bodies in the Air and Food Passages. Charted Experiences in Cases from no. 631 to no. 1155 at the Bronchoscopic Clinic*. New Bedford: Reynolds the Printer, 1923
5. Miyazawa T, Miyazu Y, Kanoh K, Iwamoto Y. Flexible bronchoscopy historical perspective. In: edited by Beamis J, Mathur P, Mehta A, eds. *Interventional Pulmonary Medicine* (1st ed., chap. 3). New York: M. Dekker, 2004:33–48
6. Dikensoy O, Usalan C, Filiz A. Foreign body aspiration: clinical utility of flexible bronchoscopy. *Postgrad Med J* 2002;78:399–403
7. Aydogan LB, Tuncer U, Soyulu L, Kiroglu M, Ozsahinoglu C. Rigid bronchoscopy for the suspicion of foreign body in the airway. *Int J Pediatr Otorhinolaryngol* 2006;70:823–8
8. Ayed AK, Jafar AM, Owayed A. Foreign body aspiration in children: diagnosis and treatment. *Pediatr Surg Int* 2003;19:485–8
9. Bittencourt PF, Camargos PA, Scheinmann P, de Blic J. Foreign body aspiration: clinical, radiological findings and factors associated with its late removal. *Int J Pediatr Otorhinolaryngol* 2006;70:879–84
10. Brkic F, Delibegovic-Dedic S, Hajdarovic D. Bronchoscopic removal of foreign bodies from children in Bosnia and Herzegovina: experience with 230 patients. *Int J Pediatr Otorhinolaryngol* 2001;60:193–6
11. Ciftci AO, Bingol-Kologlu M, Senocak ME, Tanyel FC, Buyukpamukcu N. Bronchoscopy for evaluation of foreign body aspiration in children. *J Pediatr Surg* 2003;38:1170–6
12. Cohen S, Avital A, Godfrey S, Gross M, Kerem E, Springer C. Suspected foreign body inhalation in children: what are the indications for bronchoscopy? *J Pediatr* 2009;155:276–80
13. Divisi D, Di Tommaso S, Garramone M, Di Francescantonio W, Crisci RM, Costa AM, Gravina GL, Crisci R. Foreign bodies aspirated in children: role of bronchoscopy. *Thorac Cardiovasc Surg* 2007;55:249–52
14. Emir H, Tekant G, Besik C, Elicevik M, Senyuz OF, Buyukunal C, Sarimurat N, Yeke D. Bronchoscopic removal of tracheobroncheal foreign bodies: value of patient history and timing. *Pediatr Surg Int* 2001;17:85–7
15. Eren S, Balci AE, Dikici B, Doblan M, Eren MN. Foreign body aspiration in children: experience of 1160 cases. *Ann Trop Paediatr* 2003;23:31–7

16. Eriki V, Karaçay S, Arıkan A. Foreign body aspiration: a four-years experience. *Ulus Travma Acil Cerrahi Derg* 2003;9:45–9
17. Girardi G, Contador AM, Castro-Rodríguez JA. Two new radiological findings to improve the diagnosis of bronchial foreign-body aspiration in children. *Pediatr Pulmonol* 2004;38:261–4
18. Gregori D, Salerni L, Scarinzi C, Morra B, Berchiolla P, Snidero S, Corradetti R, Passali D, Klaus A, Isidor H, Gernot S, Jan B, Bernard B, Karchev T, Tzolov T, Ranko M, Lana K, Ivo S, Mirko T, Caye-Thomasen P, Anne P, Volker J, Onder G, Simasko N, Matilda C, Christopoulos I, Pass'À li GC, Pass'À li F, Damiani V, Mieczysław C, Dorin S, Gheorghe DC, Janka J, Miha Z, Ales G, Ales M, Lorenzo R, Javier C, Pontus S, Philippe P, Ahmed C, Metin OT, Ozden CA, Riza D, John G, Peter R, Rupert O. Foreign bodies in the upper airways causing complications and requiring hospitalization in children aged 0–14 years: results from the ESFBI study. *Eur Arch Otorhinolaryngol* 2008;265:971–8
19. Hasdiraz L, Oguzkaya F, Bilgin M, Bicer C. Complications of bronchoscopy for foreign body removal: experience in 1,035 cases. *Ann Saudi Med* 2006;26:283–7
20. Heyer CM, Bollmeier ME, Rossler L, Nuesslein TG, Stephan V, Bauer TT, Rieger CH. Evaluation of clinical, radiologic, and laboratory prebronchoscopy findings in children with suspected foreign body aspiration. *J Pediatr Surg* 2006;41:1882–8
21. Higuchi O, Adachi Y, Ichimaru T, Asai M, Kawasaki K. Foreign body aspiration in children: a nationwide survey in Japan. *Int J Pediatr Otorhinolaryngol* 2009;73:659–61
22. Hui H, Na L, Zhijun CJ, Fugao ZG, Yan S, Niankai ZK, Jingjing CJ. Therapeutic experience from 1428 patients with pediatric tracheobronchial foreign body. *J Pediatr Surg* 2008;43:718–21
23. Kadmon G, Stern Y, Bron-Harlev E, Nahum E, Battat E, Schonfeld T. Computerized scoring system for the diagnosis of foreign body aspiration in children. *Ann Otol Rhinol Laryngol* 2008;117:839–43
24. Karakoc F, Karadag B, Akbenlioglu C, Ersu R, Yildizeli B, Yuksel M, Dagli E. Foreign body aspiration: what is the outcome? *Pediatr Pulmonol* 2002;34:30–6
25. Kiyani G, Gocmen B, Tugtepe H, Karakoc F, Dagli E, Dagli TE. Foreign body aspiration in children: the value of diagnostic criteria. *Int J Pediatr Otorhinolaryngol* 2009;73:963–7
26. Mahafza T, Khader Y. Aspirated tracheobronchial foreign bodies: a Jordanian experience. *Ear Nose Throat J* 2007;86:107–10
27. Roda J, Nobre S, Pires J, Estêvão MH, Félix M. Foreign bodies in the airway: a quarter of a century's experience. *Rev Port Pneumol* 2008;14:787–802
28. Roh JL, Hong SJ. Lung recovery after rigid bronchoscopic removal of tracheobronchial foreign bodies in children. *Int J Pediatr Otorhinolaryngol* 2008;72:635–41
29. Shivakumar AM, Naik AS, Prashanth KB, Shetty KD, Praveen DS. Tracheobronchial foreign bodies. *Indian J Pediatr* 2003;70:793–7
30. Shubha AM, Das K. Tracheobronchial foreign bodies in infants. *Int J Pediatr Otorhinolaryngol* 2009;73:1385–9
31. Skoulakis CE, Doxas PG, Papadakis CE, Proimos E, Christodoulou P, Bizakis JG, Velegrakis GA, Mamoulakis D, Helidonis ES. Bronchoscopy for foreign body removal in children. A review and analysis of 210 cases. *Int J Pediatr Otorhinolaryngol* 2000;53:143–8
32. Tan HK, Brown K, McGill T, Kenna MA, Lund DP, Healy GB. Airway foreign bodies (FB): a 10-year review. *Int J Pediatr Otorhinolaryngol* 2000;56:91–9
33. Tang LF, Xu YC, Wang YS, Wang CF, Zhu GH, Bao XE, Lu MP, Chen LX, Chen ZM. Airway foreign body removal by flexible bronchoscopy: experience with 1027 children during 2000–2008. *World J Pediatr* 2009;5:191–5
34. Tokar B, Ozkan R, Ilhan H. Tracheobronchial foreign bodies in children: importance of accurate history and plain chest radiography in delayed presentation. *Clin Radiol* 2004;59:609–15
35. Tomaske M, Gerber AC, Stocker S, Weiss M. Tracheobronchial foreign body aspiration in children—diagnostic value of symptoms and signs. *Swiss Med Wkly* 2006;136:533–8

36. Yadav SP, Singh J, Aggarwal N, Goel A. Airway foreign bodies in children: experience of 132 cases. *Singapore Med J* 2007;48:850–3
37. Pinto A, Scaglione M, Pinto F, Guidi G, Pepe M, Del Prato B, Grassi R, Romano L. Tracheobronchial aspiration of foreign bodies: current indications for emergency plain chest radiography. *Radiol Med* 2006;1112:497–506
38. Assefa D, Amin N, Stringel G, Dozor AJ. Use of decubitus radiographs in the diagnosis of foreign body aspiration in young children. *Pediatr Emerg Care* 2007;23:154–7
39. Sodhi KS, Saxena AK, Singh M, Rao KL, Khandelwal N. CT virtual bronchoscopy: new non invasive tool in pediatric patients with foreign body aspiration. *Indian J Pediatr* 2008;75:511–3
40. Veras TN, Hornburg G, Schnier AM, Pinto LA. Use of virtual bronchoscopy in children with suspected foreign body aspiration. *J Bras Pneumol* 2009;35:937–41
41. Hong SJ, Goo HW, Roh JL. Utility of spiral and cine CT scans in pediatric patients suspected of aspirating radiolucent foreign bodies. *Otolaryngol Head Neck Surg* 2008;138:576–80
42. Kosucu P, Ahmetoglu A, Koramaz I, Orhan F, Ozdemir O, Dinc H, Okten A, Gumele HR. Low-dose MDCT and virtual bronchoscopy in pediatric patients with foreign body aspiration. *AJR Am J Roentgenol* 2004;183:1771–7
43. Huang HJ, Fang HY, Chen HC, Wu CY, Cheng CY, Chang CL. Three-dimensional computed tomography for detection of tracheobronchial foreign body aspiration in children. *Pediatr Surg Int* 2008;24:157–60
44. Adaletli I, Kurugoglu S, Ulus S, Ozer H, Elicevik M, Kantarci F, Mihmanli I, Akman C. Utilization of low-dose multidetector CT and virtual bronchoscopy in children with suspected foreign body aspiration. *Pediatr Radiol* 2007;37:33–40
45. Haliloglu M, Ciftci AO, Oto A, Gumus B, Tanyel FC, Senocak ME, Buyukpamukcu N, Besim A. CT virtual bronchoscopy in the evaluation of children with suspected foreign body aspiration. *Eur J Radiol* 2003;48:188–92
46. Even L, Heno N, Talmon Y, Samet E, Zonis Z, Kugelman A. Diagnostic evaluation of foreign body aspiration in children: a prospective study. *J Pediatr Surg* 2005;40:1122–7
47. Martinot A, Closset M, Marquette CH, Hue V, Deschildre A, Ramon P, Remy J, Leclerc F. Indications for flexible versus rigid bronchoscopy in children with suspected foreign-body aspiration. *Am J Respir Crit Care Med* 1997;155:1676–9
48. Righini CA, Morel N, Karkas A, Rey E, Ferretti K, Pin I, Schmerber S. What is the diagnostic value of flexible bronchoscopy in the initial investigation of children with suspected foreign body aspiration? *Int J Pediatr Otorhinolaryngol* 2007;71:1383–90
49. Gencer M, Ceylan E, Koksall N. Extraction of pins from the airway with flexible bronchoscopy. *Respiration* 2007;74:674–9
50. Ramirez-Figueroa JL, Gochicoa-Rangel LG, Ramirez-San Juan DH, Vargas MH. Foreign body removal by flexible fiberoptic bronchoscopy in infants and children. *Pediatr Pulmonol* 2005;40:392–7
51. Swanson KL, Prakash UB, Midthun DE, Edell ES, Utz JP, McDougall JC, Brutinel WM. Flexible bronchoscopic management of airway foreign bodies in children. *Chest* 2002;121:1695–1700
52. Yazbeck-Karam VG, Aouad MT, Baraka AS. Laryngeal mask airway for ventilation during diagnostic and interventional fiberoptic bronchoscopy in children. *Paediatr Anaesth* 2003;13:691–4
53. Mani N, Soma M, Massey S, Albert D, Bailey CM. Removal of inhaled foreign bodies—middle of the night or the next morning? *Int J Pediatr Otorhinolaryngol* 2009;73:1085–9
54. Soodan A, Pawar D, Subramaniam R. Anesthesia for removal of inhaled foreign bodies in children. *Paediatr Anaesth* 2004;14:947–52
55. Kain ZN, O'Connor TZ, Berde CB. Management of tracheobronchial and esophageal foreign bodies in children: a survey study. *J Clin Anesth* 1994;6:28–32
56. Sersar SI, Rizk WH, Bilal M, El Diasty MM, Eltantawy TA, Abdelhakam BB, Elgamel AM, Bieh AA. Inhaled foreign bodies: presentation, management and value of history and plain chest radiography in delayed presentation. *Otolaryngol Head Neck Surg* 2006;134:92–9
57. Soysal O, Kuzucu A, Ulutas H. Tracheobronchial foreign body aspiration: a continuing challenge. *Otolaryngol Head Neck Surg* 2006;135:223–6
58. Yu H, Yang XY, Liu B. EMLA cream coated on the rigid bronchoscope for tracheobronchial foreign body removal in children. *Laryngoscope* 2009;119:158–61
59. Baraka A. Bronchoscopic removal of inhaled foreign bodies in children. *Br J Anaesth* 1974;46:124–6
60. Farrell PT. Rigid bronchoscopy for foreign body removal: anaesthesia and ventilation. *Paediatr Anaesth* 2004;14:84–9
61. Litman RS, Ponnuri J, Trogan I. Anesthesia for tracheal or bronchial foreign body removal in children: an analysis of ninety-four cases. *Anesth Analg* 2000;91:1389–91
62. Buu NT, Ansermino M. Anesthesia for removal of inhaled foreign bodies in children. *Paediatr Anaesth* 2005;15:533
63. Chen LH, Zhang X, Li SQ, Liu YQ, Zhang TY, Wu JZ. The risk factors for hypoxemia in children younger than 5 years old undergoing rigid bronchoscopy for foreign body removal. *Anesth Analg* 2009;109:1079–84
64. Meretoja OA, Taivainen T, Raiha L, Korpela R, Wirtavuori K. Sevoflurane-nitrous oxide or halothane-nitrous oxide for paediatric bronchoscopy and gastroscopy. *Br J Anaesth* 1996;76:767–71
65. Batra YK, Mahajan R, Bangalia SK, Chari P, Rao KL. A comparison of halothane and sevoflurane for bronchoscopic removal of foreign bodies in children. *Ann Card Anaesth* 2004;7:137–43
66. Davidson A. The correlation between bispectral index and airway reflexes with sevoflurane and halothane anaesthesia. *Paediatr Anaesth* 2004;14:241–6
67. Cohen SR, Geller KA. Anesthesia and pediatric endoscopy: the surgeon's view. *Otolaryngol Clin North Am* 1981;14:705–13
68. Maddali MM, Badur RS, Fernando MS, Alsajwani MJ. Total contralateral atelectasis during rigid bronchoscopy in a child with scarf pin aspiration. *Paediatr Anaesth* 2006;16:1095–7
69. Perrin G, Colt HG, Martin C, Mak MA, Dumon JF, Gouin F. Safety of interventional rigid bronchoscopy using intravenous anesthesia and spontaneous assisted ventilation: a prospective study. *Chest* 1992;102:1526–30
70. Barker N, Lim J, Amari E, Malherbe S, Ansermino JM. Relationship between age and spontaneous ventilation during intravenous anesthesia in children. *Paediatr Anaesth* 2007;17:948–55
71. Kumar S, Saxena AK, Kumar M, Rautela RS, Gupta N, Goyal A. Anesthetic management during bronchoscopic removal of a unique, friable foreign body. *Anesth Analg* 2006;103:1596–7
72. Pawar DK. Dislodgement of bronchial foreign body during retrieval in children. *Paediatr Anaesth* 2000;10:333–5
73. Brown KL, Shefler A, Cohen G, DeMunter C, Pigott N, Goldman AP. Near-fatal grape aspiration with complicating acute lung injury successfully treated with extracorporeal membrane oxygenation. *Pediatr Crit Care Med* 2003;4:243–5
74. Mise K, Jurcev Savicevic A, Pavlov N, Jankovic S. Removal of tracheobronchial foreign bodies in adults using flexible bronchoscopy: experience 1995–2006. *Surg Endosc* 2009;23:1360–4
75. Tariq SM, George J, Srinivasan S. Inhaled foreign bodies in adolescents and adults. *Monaldi Arch Chest Dis* 2005;63:193–8
76. Uskul TB, Turker H, Arslan S, Slevi A, Kant A. Use of fiberoptic bronchoscopy in endobronchial foreign body removal in adults. *Turkish Resp J* 2007;8:39–42
77. Wong KS, Lai SH, Lien R, Hsia SH. Retrieval of bronchial foreign body with central lumen using a flexible bronchoscope. *Int J Pediatr Otorhinolaryngol* 2002;62:253–6
78. Tomaske M, Gerber AC, Weiss M. Anesthesia and periinterventional morbidity of rigid bronchoscopy for tracheobronchial foreign body diagnosis and removal. *Paediatr Anaesth* 2006;16:123–9
79. Chung MK, Jeong HS, Ahn KM, Park SH, Cho JK, Son YI, Baek CH. Pulmonary recovery after rigid bronchoscopic retrieval of airway foreign body. *Laryngoscope* 2007;117:303–7