

# Headache Medicine in Brazil: Review

## The Cerebellum and Migraine

Maurice Vincent, MD, PhD; Nouchine Hadjikhani, MD

**Clinical and pathophysiological evidences connect migraine and the cerebellum. Literature on documented cerebellar abnormalities in migraine, however, is relatively sparse. Cerebellar involvement may be observed in 4 types of migraines: in the widespread migraine with aura (MWA) and migraine without aura (MWOA) forms; in particular subtypes of migraine such as basilar-type migraine (BTM); and in the genetically driven autosomal dominant familial hemiplegic migraine (FHM) forms. Cerebellar dysfunction in migraineurs varies largely in severity, and may be subclinical. Purkinje cells express calcium channels that are related to the pathophysiology of both inherited forms of migraine and primary ataxias, mostly spinal cerebellar ataxia type 6 (SCA-6) and episodic ataxia type 2 (EA-2). Genetically driven ion channels dysfunction leads to hyperexcitability in the brain and cerebellum, possibly facilitating spreading depression waves in both locations. This review focuses on the cerebellar involvement in migraine, the relevant ataxias and their association with this primary headache, and discusses some of the pathophysiological processes putatively underlying these diseases.**

**Key words:** migraine, familial hemiplegic migraine, cerebellum, progressive ataxia, episodic ataxia

**Abbreviations:** IHS International Headache Society, MWA migraine with aura, MWOA migraine without aura, SD spreading depression, GABA gamma-aminobutyric acid, SCA spinal cerebellar ataxia, BTM basilar-type migraine, FHM familial hemiplegic migraine, EAAT1 excitatory aminoacid transporter 1, EA episodic ataxia, TGA transient global amnesia, SPECT single photon emission computed tomography, CW calcium waves

(*Headache* 2007;47:820-833)

Migraine is a common disease that affects 10 to 12% of the population and is considered by the World Health Organization as one of the most disabling neurological disorders.<sup>1</sup> Migraine attacks typically occur

in varying intervals, each lasting 4 to 72 hours by definition. The unilateral, mostly side-shifting throbbing pain, located predominantly to the frontal parts of the cranium, may be intense enough to interrupt daily activity and worsens with physical activity. Nausea, vomiting, photo and phonophobia frequently accompany the annoying moderate to severe pain. A series of different neurological focal abnormalities named aura (from the Greek “breath,” gentle breeze), mostly visual in nature, but also sometimes sensory, motor, or dysphasic, may occur in close association with the pain, typically before the headache onset.<sup>2</sup> The International Headache Society (IHS) classifies migraine headaches, among other less frequent subtypes, as migraine with aura (MWA), or migraine without aura (MWOA), according to the presence of aura symptoms.<sup>3</sup>

---

**From the Hospital Universitário Clementino Fraga Filho, Faculdade de Medicina, Universidade Federal do Rio de Janeiro, Brazil (Dr. Vincent); Athinoula A. Martinos Center for Biomedical Imaging, Massachusetts General Hospital, Harvard Medical School, Charlestown, MA (Dr. Hadjikhani); and Division of Health Sciences and Technology, Harvard-MIT, Cambridge, MA (Dr. Hadjikhani).**

**Address all correspondence to Dr. Maurice Vincent, Avenida das Américas, 1155/504, CEP 22631-000 Rio de Janeiro, Brazil.**

**Accepted for publication August 31, 2006.**

**Pathophysiological Theories in Migraine.**—The mechanisms underlying migraine attacks remain fairly unknown, although accumulating data have demonstrated that this ailment is a primary brain disorder.<sup>4</sup> A dispute whether migraine had either a nervous or a vascular origin, polarizing the 2 so-called “vascular” and “neuronal” theories, has been present for many years,<sup>5</sup> but the central nervous system more probably seems to be the ultimate source of migraine. The hitherto suitable vascular theory, which popularized the expression “vascular headache,” has been challenged by the information that aura and headache did not parallel changes in the vasculature.<sup>6</sup> The possibility that abnormal brain hyperexcitability primarily originates migraine attacks is now widely accepted,<sup>7</sup> and the disease threshold, at least partially, seems to be determined by genetic predisposition.<sup>8</sup> The hyperexcitability has been confirmed by the relatively higher susceptibility of the migrainous cortex to phosphene induction secondary to transcranial magnetic stimulation.<sup>9</sup> It seems, therefore, that the vascular responses take place because of primarily triggered events in the nervous system intimacy.

**Spreading Depression.**—Spreading depression (SD) consists of a spreading wave of depolarization associated with a reduction of the cortical activity that lasts for minutes with a propagation speed of around 3 mm/min. The expression “cortical spreading depression” (CSD) is widespread, but since this phenomenon is not exclusively cortical—it has been recorded in various tissues including the basal ganglia and thalamus,<sup>10,11</sup> cerebellum,<sup>12-15</sup> tectum and olfactory bulb,<sup>12</sup> retina,<sup>16-22</sup> and spinal cord<sup>23</sup>—we believe that “spreading depression” is a better denomination.

In 1945, Leão and Morrison suggested for the first time that SD could be related to the pathophysiology of migraine<sup>24</sup> and Leão postulated that circulatory changes were in close connection with SD waves.<sup>25</sup> SD compatible circulatory changes were subsequently found in migraineurs, making the possibility of SD being an important phenomenon in this disease even more attractive.<sup>6</sup> SD is accompanied by an initial hyperperfusion, followed by prolonged and pronounced spreading hypoperfusion.<sup>26</sup> The genetically hyperexcitable brain in migraine probably facilitates paroxysms of SD-like phenomena—initiating each of them

the cascade of events ultimately leading to the attacks. Functional imaging studies support the possibility of SD underlying migraine episodes.<sup>27</sup> The trigeminovascular system comprised of the trigeminal fibers innervating meningeal and brain vessels is activated by SD,<sup>28</sup> leading to plasma extravasation and vasodilatation (neurogenic inflammation) in the dura mater.<sup>29</sup> The ability of triptans, a class of 5-HT<sub>1</sub> agonists, to block neurogenic inflammation and neuropeptide release centrally, has supported the defense of its use as effective antimigraine agents.<sup>30-32</sup>

**The Cerebellum.**—Although Herophilus (335 to 280 B.C.) is usually cited for firstly recognizing the cerebellum (from Latin, “small brain”) as distinct from the brain, Aristotle did so before (“The history of animals” book I, part XVI, 350 B.C.). Galen (131 to 200 A.D.) called the vermis “the worm-like outgrowth,” Luigi Rolando (1773 to 1831) concluded the cerebellum was a motor structure, and Marie-Jean-Pierre Flourens (1794 to 1867) finally linked the cerebellum to coordination.<sup>33,34</sup> The relatively simpler structure of the cerebellum is highly specific and uniform, with cells arranged in layers in the cerebellar cortex connected each other by a repetitive microcircuitry.<sup>35</sup> The Purkinje cells are the source of cerebellar output. Therefore, malfunction in Purkinje cells severely impairs motor planning and coordination.

## CEREBELLAR DISORDERS IN COMMON MWA AND MWoA FORMS OF MIGRAINE

In spite of the fact that balance changes and vertigo have been recognized in migraine, only a few studies have specifically assessed cerebellar function between or during attacks. In migraine, stabilometry studies have revealed ictal and interictal balance abnormalities in treatment-free patients.<sup>36,37</sup> Vestibulo-cerebellar function also seems compromised in migraineurs, with abnormal nystagmus in calorimetric testing and decrease in saccadic eye-movement accuracy.<sup>38</sup> In addition, subclinical cerebellar impairment expressed as a lack of fine coordination has been shown interictally in migraineurs.<sup>39</sup> Altogether, these findings indicate that migraine affects cerebellar function.<sup>39</sup>

It is not surprising that vestibular abnormalities may be detected in migraine patients, as about

2/3 of migraineurs are sensitive to motion and 1/4 may present with paroxysmal vertigo.<sup>40,41</sup> Although a positive family history and previous motion sickness in childhood do not contribute to the diagnosis of MWA, vestibular abnormalities are associated with this type of headache.<sup>42,43</sup> Visual dysfunction may also impair coordination and probably impacts balance in migraine.<sup>44</sup> Spatiotemporal function and motion processing are reportedly abnormal in migraineurs interictally<sup>45,46</sup> and visual fields and contrast functions differ from controls.<sup>47</sup>

### **BASILAR-TYPE MIGRAINE**

Cerebellar dysfunction has been recognized in relation to special forms of migraine for many years. The expression “cerebellar migraine” was used in some German<sup>48,49</sup> and Czech<sup>50</sup> early publications. In 1961, Bickerstaff described what he called “basilar artery migraine,”<sup>51</sup> making the expression “basilar migraine” popular in neurology. According to the IHS, BTM is characterized by aura symptoms clearly originating from the brainstem and/or both hemispheres, without motor deficits.<sup>3</sup> Symptoms may include dysarthria, vertigo, tinnitus, hypacusia, diplopia, visual symptoms, ataxia, decreased level of consciousness, and bilateral paresthesias.<sup>52</sup> BTM has been considered more prevalent in adolescent girls with very positive family histories, but a recent analysis does not support BTM, which presents with ataxia in 5% of the cases, as a distinct migraine subform.<sup>53</sup> The pathophysiology of BTM is not known. Circulatory changes and episodes of stroke putatively related to basilar-type migraine have been reported.<sup>54</sup> Such infarcts have also been reported in the thalamus<sup>55</sup> and the occipital areas.<sup>56-58</sup> Knowing the genetic mechanisms behind certain forms of migraine, scrutiny indicates that many migraine patients previously described according to their clinical pictures as “cerebellar migraine” or “basilar migraine,” probably carried one of the known ion channel related mutations. A mutation at the FHM2 locus at the ATP1A2 gene has been described in familial BTM without hemiplegia, suggesting a connection between BTM and hemiplegic migraine.<sup>59</sup> BTM most probably represents a variation of MWA rather than another migraine subtype, as 95% of the BTM patients experience typical aura as in MWA.<sup>53</sup>

### **FAMILIAL HEMIPLEGIC MIGRAINE AND THE CEREBELLUM-RELATED DISORDERS**

FHM is an autosomal dominant disorder characterized by migraine attacks with hemiplegic aura. The diagnosis is based on the presence of aura including motor weakness and at least one first- or second-degree relative suffering from migraine with aura that presents with motor deficits.<sup>3</sup> A multitude of associated symptoms may be present, including ataxia, seen in one-third of the families.<sup>60</sup> Three types of FHM have been described so far: FHM-1 is consequent to mutations of the CACNA1A gene coding for a P/Q calcium channel;<sup>61</sup> FHM-2 is due to the mutation of the ATP1A2 gene coding for the alpha2 subunit of the Na/K astrocytic ATPase,<sup>62,63</sup> and FHM-3 follows a mutation of the SCN1A gene coding for a neuron voltage-gated sodium channel.<sup>64</sup> The FHM phenotype includes hemiplegic migraine, seizure, prolonged coma, hyperthermia, sensory deficit, and transient or permanent cerebellar signs, such as ataxia, nystagmus, and dysarthria.<sup>65</sup>

In FHM-1, the CACNA1A gene encodes the  $\alpha_{1A}$  (CA<sub>v</sub>2.1) subunit of the high voltage-gated P/Q type of calcium channel. This channel is expressed throughout the central nervous system, particularly in the cerebellar Purkinje cells, where it mediates depolarization-induced Ca<sup>2+</sup> influx into presynaptic terminals and glutamate release.<sup>66,67</sup> P/Q calcium channels play a pivotal role in neurotransmitter release<sup>68</sup> and influence neuronal excitability.<sup>69</sup> The consequences of different missense mutations in the CACNA1A gene may lead to gain-of-function of human P/Q-type calcium channels, although not all studies agree in this respect.<sup>70</sup> New animal models may provide important insights in this field. A knockin mouse expressing the human R192Q pure FHM-1 mutation was genetically engineered and recently studied. This mouse shows gain-of-function P/Q Ca<sup>2+</sup> channel function as evidenced by opening of calcium channels at lower levels of depolarization, lower threshold for SD and faster propagation speed.<sup>71</sup> These findings open the possibility of SD-like phenomena in the cerebellum as a justification for cerebellar dysfunction in migraine patients. Human evidence confirming this hypothesis is however not yet available.

**Table.—Cerebellar Symptoms in Earlier FHM Descriptions**

Author (Reference)	Year	Gender	Age	Possible Cerebellar/Vestibular Signs and Symptoms
Ohta et al <sup>(151)</sup>	1967	Male	59	Unsteady gait, mild dysarthria, incoordination of the limbs.
		Male	30	Apparent horizontal nystagmus on lateral gaze
		Female	19	—
		Male	13	—
		Male	59	Slow speech and unsteady gait
Young et al <sup>(152)</sup>	1970	Male	33	Mild ataxia, worse during migraine attacks, nystagmus
		Male	32	Nystagmus
		Male	4	Nystagmus
		Male	4	Nystagmus
Codina et al <sup>† (153)</sup>	1971	Female	44	Nystagmus
		Male	14	Nystagmus
		Male	49	Nystagmus
Zifkin et al <sup>‡ (154)</sup>	1980	Male	22	Nystagmus

Further cases described without cerebellar or vestibular abnormalities:

<sup>†</sup>Four cases; <sup>‡</sup>one case.

The mechanisms behind the neurological symptom complex linked to CACNA1A, ATP1A2, and SCN1A genes, respectively involved with FHM 1, 2, and 3, remain partially unclear. Noteworthy is the fact that, despite the type of ion channel involved, all mutations result in hyperexcitability and may be related to hemiplegic migraine, epilepsy, and/or ataxic disorders.

Cerebellar symptoms in FHM have been recognized in many families (Table). Such symptoms may be produced by lesion in the cerebellum itself or in structures with afferent or efferent cerebellar connections, such as the brainstem. Thus, the exact origin of symptoms such as nystagmus and ataxia in migraine patients cannot be definitely related to the cerebellum. On the other hand, the atrophy found in FMH and the calcium channel abnormalities in the cerebellum indicate that symptoms are probably cerebellar in nature.

Around 20% of the hemiplegic migraine patients show permanent mild cerebellar deficits.<sup>72</sup> Unconsciousness, fever, and confusion may occur associated with the hemiplegic attacks and ataxia, usually accompanied by cerebellar atrophy.<sup>73,74</sup>

### SPINOCEREBELLAR AND EPISODIC ATAXIAS

The CACNA1A mutations are also involved with cerebellar diseases, namely episodic ataxia type 2 (EA-2) and spinocerebellar ataxia type 6 (SCA-6). Hered-

itary EAs are genetic conditions typically characterized by recurrent clumsiness triggered by exertion, stress, or fatigue with a favorable response to acetazolamide.<sup>75,76</sup> Spinocerebellar ataxias (SCA) are genetic non-paroxysmal, moderate to severe ataxias of late onset characterized by progressive cerebellar degeneration leading to incoordination. Other cerebellar symptoms associated with spinal cord signs, such as motor deficit, as well as vibratory and proprioceptive sensory loss.<sup>75</sup> The myriad of cerebellar symptoms include dysarthria, dysmetria, tremor, and nystagmus of various types.<sup>77</sup>

A series of EA mutations have been found so far,<sup>76,78-80</sup> and a complete loss of the P/Q function has been suggested to underlie the pathophysiology of EA-2.<sup>81</sup> Different nomenclature in successive descriptions have confused the understanding of non-progressive ataxias.<sup>82-84</sup> SCA-6 has been associated with small expansions of a CAG repeat at the 3' end of the CACNA1A gene, and point mutations are responsible for the allelic disorders related to EA-2.<sup>60,79,85-87</sup> The genetics behind these phenotypes, however, may vary.<sup>88</sup> Regardless of the mutation type, hyperexcitability seem to stand behind all the different phenotypes. Interestingly, a mutation in the glutamate transporter excitatory aminoacid transporter 1 (EAAT1) is also related to episodic ataxia (EA), seizures, migraine, and alternating hemiplegia.<sup>89</sup> EAAT1 is expressed particularly in the cerebellum and brain stem.

The mutation in EAAT1 may lead to a reduced capacity for glutamate reuptake, increasing hyperexcitability. This reproduces the pathophysiological conditions present in channelopathies leading to FHM, episodic/progressive ataxias and coma after minor head trauma.

SCA-6 represents the form of progressive ataxia with closest relation to FHM pathophysiology, as this form of SCA is also linked to the CACNA1A gene.<sup>90,91</sup> Different mutations have been linked to the phenotype of SCA-6, sometimes associated with FHM.<sup>92</sup> There may be marked cerebellar atrophy on MR examination in these patients.<sup>93</sup> Not only mutations occur at the same gene, but in 20% of FHM patients permanent cerebellar symptoms are present.<sup>94,95</sup>

The phenotypes of such disorders may vary between and within families.<sup>91,96</sup> EA-2 patients may sometimes have non-hemiplegic migraine, which presents after the onset of the ataxic symptoms.<sup>97</sup> Interestingly, EA patients may present constant cerebellar symptoms and signs such as nystagmus and cerebellar atrophy. The migraine-progressive episodic ataxias symptoms interchange indicate that the cerebellar disorders related to channelopathies intermingle and may represent different aspects from the same abnormality. Mechanisms behind ataxias in migraine disorders most probably involve membrane dysfunction. Purkinje cells, where P/Q-type calcium channels are mostly expressed, fire according to intrinsic regular spontaneous pacemaking.<sup>98</sup> This intrinsic pacemaking activity is irregular in P/Q-mutant Purkinje cells as well as in  $\omega$ -agatoxin IVA-blocked P/Q-type calcium channel in wild Purkinje cells. The defective P/Q calcium current decreases the function of calcium-activated potassium ( $K_{Ca}$ ) channels, which are fundamental for the precision of the Purkinje cells intrinsic firing. EBIO, a channel activator that increases the affinity of  $K_{Ca}$  channels for calcium, recovers the regular firing in affected Purkinje cells.<sup>99</sup> This makes the  $K_{Ca}$  channel a potential therapeutic target not only for EA-2, but also for related symptoms in migraine disorders.

### COMA, CEREBELLUM, AND MIGRAINE

One of the conditions associated with cerebellar dysfunction, FHM and the CACNA1A gene is fatal coma after mild head trauma.<sup>100-102</sup> Some mutations

have been related to this phenotype. Patients carrying the T666M mutation in CACNA1A gene,<sup>103</sup> but not exclusively as the chromosome 1 has also been implicated in this kind of abnormality<sup>104</sup>—may present coma following relatively mild head trauma, with brain edema and sometimes long-lasting coma.<sup>101-103,105-107</sup> The S218L mutation was shown to produce particularly severe brain edema after trauma.<sup>108</sup>

As a hypothesis, the mechanisms leading to coma can be understood as follows: minor trauma, a relatively irrelevant depolarizing stimulus in healthy subjects, may elicit SD in patients with a particularly marked  $Ca_v2.1$  channel gain of function, both in the brain and cerebellum. Further activation may then take place through a positive feedback leading to  $Ca_v2.1$ -dependent glutamate release, activation of NMDA receptors, de novo increase of extracellular  $K^+$ , glutamate release, and more NMDA receptor activation.<sup>109</sup> SD may disrupt the blood-brain barrier by activating MMP-9, one of the proteases implicated in BBB opening,<sup>110</sup> leading to brain edema and coma. Interestingly, the long-lasting edema and coma take place after a time interval following the trauma. This indicates that the process is not dependent on immediate neuronal impulses and neurotransmitters release, but on time consuming progressive changes. Moreover, the resulting pathophysiological state is a self-perpetuating process with a relatively slow recovery rate. Positive SD and calcium waves (see below) feedbacks in particularly excitable subjects would fit with these requirements. Transient global amnesia (TGA), a potentially SD related disorder,<sup>111</sup> may also be induced by minor head trauma, just as coma in some patients with genetic forms of migraine where cerebellar abnormalities may be present.<sup>112</sup>

### THE ACETAZOLAMIDE EFFECT

Acetazolamide, a reversible inhibitor of the enzyme carbonic anhydrase, is a drug known for its benefit in EA-2.<sup>79,113,114</sup> Acetazolamide-responsive episodic symptoms, typical of EA-2, have also been shown in SCA-6.<sup>115</sup> The effect of acetazolamide in EAs was found in 1978 by chance, when patients received this drug after being erroneously diagnosed as periodic paralysis.<sup>114</sup> Acetazolamide response has been

described in FHM with associated ataxia<sup>74</sup> and in migraineurs without cerebellar symptoms.<sup>116</sup>

Acetazolamide does not usually diminish the frequency or intensity of FHM, being mostly indicated for use in EA-2. However, there are 2 FHM reports with clear acetazolamide response.<sup>74,116</sup> Formal trials using acetazolamide in migraine are few. In an open uncontrolled pilot study, the efficacy and tolerability of acetazolamide were addressed in 22 MWA patients. 68.2% reported a reduction of MA episodes higher than 50%.<sup>117</sup> A randomized clinical trial was performed comparing 500 mg oral acetazolamide versus placebo in 53 IHS migraine patients (27 in the placebo group). This study had to be interrupted prematurely due to many side effects related withdrawals. So far, the authors did not find a difference between the active drug and placebo.<sup>118</sup> Acetazolamide was also shown to interrupt aura status in 3 patients.<sup>119</sup>

The acetazolamide mechanism of action in episodic ataxia type 2 (EA-2) is still mysterious. It is interesting that topiramate, an effective antimigraine prophylactic agent, shares with acetazolamide the property of carbonic anhydrase inhibition.<sup>120</sup> Besides, it was recently reported to suppress the susceptibility to cortical spreading depression in experimental animals.<sup>121</sup> Acetazolamide induces metabolic acidosis. It is possible that this drug increases the extracellular concentration of free protons in the brain tissue including the cerebellum.<sup>113</sup> Since calcium channels are sensitive to pH changes, acetazolamide could restore normal function in mutant calcium channels through acidification. However, acetazolamide does not modify the channel properties through either pH-dependent or pH-independent mechanisms.<sup>122</sup> Alternatively, since acetazolamide activate large-conductance  $K_{Ca}$  channels, which are in normal conditions exclusively activated in Purkinje cells by P/Q-type calcium channels, it is possible that this drug acts by restoring Purkinje cells pacemaking properties.<sup>99</sup>

### CEREBELLAR CIRCULATORY CHANGES

Circulatory changes may take place in the cerebellum during migraine attacks. Following sumatriptan administration, a vasoconstricting antimigraine agent, infarction has been described in the cerebellum, showing that this area was probably predisposed to ischemia

as compared to other regions.<sup>123</sup> Decreased perfusion and cerebellar symptoms, including dysarthria, ataxia, and dizziness have been described in migraine.<sup>124,125</sup> Such circulatory changes can outlast the symptoms.<sup>125</sup> Stroke in the posterior circulation has been reported in migraine<sup>54,123</sup> including in children,<sup>126</sup> mostly diagnosed as “basilar migraine.” The posterior circulation territory, particularly the cerebellum, shows significantly increased risk for infarct-like MRI findings compared to the remaining of the nervous system. The highest risk is in MWA with at least 1 attack per month, in the absence of stroke history.<sup>127</sup> According to the CAMERA study, the percent of all these small, infarct-like lesions in the posterior circulation in MWA, MWoA, and controls were 81, 47, and 44%, respectively; the majority was in vascular border zones; and multiple posterior circulation lesions were identified exclusively among the migraine patients.<sup>128</sup>

The nature and pathophysiology of such infratentorial lesions are not known. Since the cerebellar circulation has relatively few anastomoses, it is prone to watershed infarcts.<sup>129</sup> SD related reduction in rCBF could, theoretically, induce more infarcts in this territory as compared to areas where collateral circulation is available. Although subjects do not present overt stroke symptoms, it is possible the subclinical cerebellar signs and symptoms in migraine<sup>36,38,39</sup> are secondary to small infarcts in the posterior circulation.

### SPREADING DEPRESSION AND THE CEREBELLUM

Leão and Martins-Ferreira first published a 24 line note on SD in the cerebellum, quadrigeminal plate, and olfactory bulb<sup>12</sup> and mentioned that the cerebellum is naturally resistant to SD. Fífková et al described SD in the rat cerebellum<sup>13</sup> and Young wrote on the SD in the elasmobranch fish (*Raja erinacea*, *Raja ocellata*).<sup>14</sup> As also pointed by Nicholson in 1984, reviewing cerebellar SD in different species,<sup>15</sup> the cerebellum does not easily supports this phenomenon, unless some “conditioning” takes place. This may happen by raising the extracellular  $K^+$ , removing most of the  $NaCl$ , or replacing the chloride with another anion. During SD, extracellular calcium concentration falls, reflecting  $Ca^{2+}$  influx with consequent intracellular  $Ca^{2+}$  overload, that may, if sufficiently high,

promote cell death.<sup>130</sup> Just as in the isolated retina and hippocampus, also in the turtle cerebellum SD occurs in the absence of blood flow, meaning that SD is not dependent on vascular or blood influence.<sup>15</sup> If cerebellar SD is related to EA-2, pH changes alone may be not sufficient for explaining the acetazolamide effect. Alternatively, SD could occur in the cerebellum through facilitating mechanisms not involving pH reduction.

Other cortical self-propagating waves with potential implications in cerebellar diseases and migraine have been demonstrated. Spreading acidification and depression (SAD) has been observed in the rat cerebellar cortex following suprathreshold electrical stimulation.<sup>131</sup> Substantial differences show that SAD and SD are not the same phenomenon. SAD spreads at a greater rate of 50 to 110 m/s, continues for 1 to 2 minutes, is accompanied by a powerful suppression of the pre and postsynaptic responses, with a refractory period of 90 seconds. Differently from SD, SAD induces no extracellular DC shift, do not change blood vessels and has a shorter recovery period. Besides, the conditioning required for SD in the cerebellum is not required to elicit SAD. While SD propagates radially outwards from the initiating point, SAD spreads perpendicularly to an activated beam of parallel fibers, which makes its spreading pattern dependent on the cerebellar cortex neuronal architecture. Pharmacologically, AMPA receptor blocking, which has little effect on SD, affects SAD, the opposite occurring with NMDA receptor blocking. SAD depends on extracellular  $Ca^{2+}$ , while SD does not depend that strictly.<sup>132</sup> SAD has been implicated in the pathophysiology of EA-1, where pathology is related to a  $K_v1.1$  voltage-gated potassium channel abnormality,<sup>133</sup> and is not likely to be involved with the cerebellar symptoms in migraine.

Astrocytes respond to glutamate with rapid calcium influx that propagate as waves from one cell to its neighbors.<sup>134</sup> The so-called calcium waves (CW) constitute a signaling system that allows astrocytes to rapidly activate adjacent astrocytes and neurons, through gap junctions, and extracellular messengers,<sup>135,136</sup> modulating synaptic transmission and neuronal activity.<sup>137</sup> CWs are also triggered by neuronal activity<sup>138</sup> and may be involved in blood flow regulation. CWs have been implicated in cortical spread-

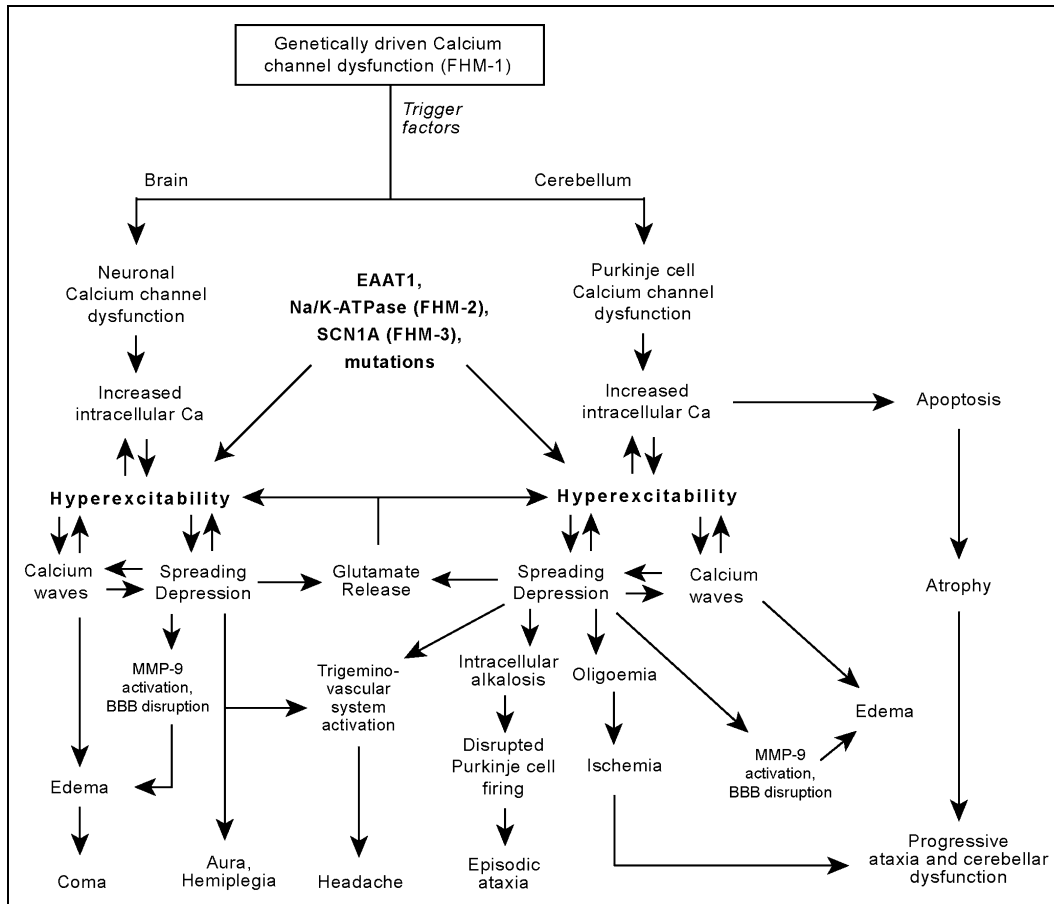
ing depression. They were demonstrated in cell cultures and tissue preparations in different cell populations,<sup>139,140</sup> and precede SD waves in hippocampal cultures.<sup>141,142</sup> Although these 2 forms of waves are related, SD does occur in calcium-free incubated hippocampal slices where CWs are abolished, demonstrating that the latter is not an obligatory requirement for the former.<sup>142</sup> Since FHM and the related CACNA1A mutations diseases directly involve calcium fluxing, it is tempting to consider that CWs associated with SD might have a pathophysiological role in this context.<sup>143</sup> The glutamate release induced by abnormal  $Ca_v2.1$  channels in migraine could theoretically lead to not only SD, but also CW activation and further vasodilatation, contributing particularly to the phenotype of brain edema and coma following head trauma. The astrocytes' role in brain water homeostasis regulation<sup>144</sup> also supports this possibility.

## STRUCTURAL CHANGES IN THE CEREBELLUM AND MIGRAINE

Few studies have specifically addressed cerebellar structural changes in migraine. Dichgans et al found Magnetic Resonance Spectroscopy ( $^1H$ -MRS) abnormalities in FHM-1 with reduced N-acetyl-aspartate (NAA), glutamate and elevated myo-inositol (mI) in the cerebellum, compatible with neuronal damage. Increased pH in the cerebrum and cerebellum, which normalized following acetazolamide treatment, as well as high lactate peak in half of the subjects has been reported in EA-2 patients.<sup>145</sup> Autopsy studies have shown pathological abnormalities in SCA including mild atrophy of the cerebellar folia, reduced number of Purkinje cells especially in the vermis, swelling of the Purkinje cell axons, decrease in granular cells, reduced number of dendrites in the molecular layers of Purkinje cells, and cerebellar cortical degeneration with reduced thickness of the molecular layer.<sup>100,146</sup> In FHM, cerebellar vermis atrophy and cortical cerebellar degeneration accompanied with Bergman glia proliferation have been described.<sup>147</sup>

## FINAL REMARKS

Taken together, the data suggest that the cerebellum is implicated not only with FHM, but also with more typical migraine forms such as MWA and



**Fig.—**The brain and the cerebellum may share common pathophysiological mechanisms leading to different clinical pictures, which combine in diverse ways, largely varying in severity. Hyperexcitability, the pivotal abnormality in migraine, may be due to inherited calcium channel malfunction, as in *CANCA1A* mutations, or other mutations, such as excitatory aminoacid transporter 1 (EAAT1), Na/k-ATPase, or *SCN1A*. Trigger factors in susceptible individuals, such as trauma or angiography, would lead to paroxysmal spreading depression and related calcium waves, leading to temporary dysfunction in both cerebrum and cerebellum. Headache may be explained by SD activation of trigeminal (anterior circulation, the rostral third of the basilar artery and the superior cerebellar artery) and/or C2 sensory fibers (remaining vessels of the vertebrobasilar system). Progressive symptoms could be the result of cumulative ischaemic lesions and progressive atrophy provoked by exaggerated calcium influx. BBB: blood–brain barrier and MMP-9: matrix metalloprotease.

MWoA. The ionic and signaling changes present in migraine may affect also the cerebellum potentially leading to cerebellar dysfunction (Fig.). Cerebellar symptomatology, which does not depend on the presence of headache, may be episodic, suggesting an underlying transitory neuropathological change in the cerebellum such as SD; or present as a constant-progressive disorders. In this case, an increase in  $\text{Ca}^{2+}$  influx secondary to defective  $\text{Ca}^{2+}$  channels expressed by Purkinje cells would favor apoptosis, possibly in a cumulative, slowly progressive pattern. Alternatively, cumulative microvascular ischemia in watershed cerebellar areas secondary to successive migraine attacks

could also impair cerebellar function with time in some cases. The pain may be produced by CGRP-containing sensory nerves activated by SD in the anterior circulation (trigeminal fibers) and/or posterior circulation (C2 fibers). Trigeminal fibers may also be partially activated by SD in some parts of the cerebellum as the rostral third of the basilar artery as well as the superior cerebellar artery are innervated by the trigeminal nerve.<sup>148,149</sup>

Knowledge on the genetic mechanisms leading to dysfunction in ion channels, ion pumps, and transporters has improved our understanding of migraine and related cerebellar disorders, although puzzling



questions still remain. It is unclear how a multitude of phenotypes including minor trauma with edema and coma, fever, pleocytosis, hemiplegic migraine, and cerebellar ataxias, is related to a single mutation. The clinical picture in EA, for example, may vary to a great extent, such as from isolated mild ataxia to a constellation of symptoms suggestive of cerebellum, brainstem, and cortex dysfunction.<sup>150</sup> This may indicate that phenotypic pleomorphism is a rule rather than an exception in these ailments. If an SD-like phenomenon underlies this group of diseases, it is likely that it may sometimes either not be clinically expressed, or manifest in different forms or degrees.

Cases reported as “basilar migraine,” “footballer’s migraine” or “cerebellar migraine” do not seem to constitute distinct entities. They may actually correspond to mere variations within the migraine channelopathy spectrum. As the molecular mechanisms implicated in migraine, ataxia, coma after minor trauma, and related disorders are better understood, it seems probable that clinical terms will be reviewed, and classifications will be established on a genetic-biochemical basis.

*Acknowledgments: The study was supported by a NIH grant 5PO1 NS 35611-09. MV is indebted to CAPES – Coordenação de Aperfeiçoamento de Pessoal de Nível Superior, Ministry of Education, Brazil; and Fulbright, USA, for a visiting professor scholarship. The authors acknowledge Professor Michael Moskowitz for his reviewing of this manuscript. Suggestions and comments by Dr. Alexandre Façanha daSilva and Cristina Granziera are appreciated.*

*Conflict of Interest: None*

## REFERENCES

- Leonardi M, Steiner TJ, Scher AT, Lipton RB. The global burden of migraine: Measuring disability in headache disorders with WHO’s Classification of Functioning, Disability and Health (ICF). *J Headache Pain*. 2005;6:429-440.
- Goadsby PJ. Migraine: Diagnosis and management. *Intern Med J*. 2003;33:436-442.
- Headache Classification Subcommittee of the International Headache Society. The International Classification of Headache Disorders. *Cephalalgia*. 2004;24(suppl 1).
- Goadsby PJ, Lipton RB, Ferrari MD. Migraine—current understanding and treatment. *N Engl J Med*. 2002;346:257-270.
- Parsons AA, Strijbos PJ. The neuronal versus vascular hypothesis of migraine and cortical spreading depression. *Curr Opin Pharmacol*. 2003;3:73-77.
- Olesen J, Larsen B, Lauritzen M. Focal hyperemia followed by spreading oligemia and impaired activation of rCBF in classic migraine. *Ann Neurol*. 1981;9:344-352.
- Welch KM. Brain hyperexcitability: The basis for antiepileptic drugs in migraine prevention. *Headache*. 2005;45(suppl 1):S25-S32.
- Haan J, Kors EE, Vanmolkot KR, van den Maagdenberg AM, Frants RR, Ferrari MD. Migraine genetics: An update. *Curr Pain Headache Rep*. 2005;9:213-220.
- Young WB, Oshinsky ML, Shechter AL, Gebeline-Myers C, Bradley KC, Wassermann EM. Consecutive transcranial magnetic stimulation: Phosphene thresholds in migraineurs and controls. *Headache*. 2004;44:131-135.
- Trachtenberg MC, Hull CD, Buchwald NA. Electrophysiological concomitants of spreading depression in caudate and thalamic nuclei of the cat. *Brain Res*. 1970;20:219-231.
- Vinogradova LV, Koroleva VI, Bures J. Re-entry waves of Leao’s spreading depression between neocortex and caudate nucleus. *Brain Res*. 1991;538:161-164.
- Leão AAP, Martins-Ferreira H. Nota acerca da depressão alastrante no cerebelo, tubérculo quadrigêmeo anterior e bulbo olfativo. *An Acad Bras Cienc*. 1961;22:34-40.
- Fifková E, Bures J, Koshtoyants OK, Krivánek J. T.W. Leão’s spreading depression in the cerebellum of the rat. *Experientia*. 1961;17:572-573.
- Young W. Spreading depression in elasmobranch cerebellum. *Brain Res*. 1980;199:113-126.
- Nicholson C. Comparative neurophysiology of spreading depression in the cerebellum. *An Acad Bras Cienc*. 1984;56:481-494.
- Martins-Ferreira H, de Oliveira Castro G, Struchiner CJ, Rodrigues PS. Circling spreading depression in isolated chick retina. *J Neurophysiol*. 1974;37:773-784.

17. Martins-Ferreira H, de Oliveira Castro G. Spreading depression in isolated chick retina. *Vision Res.* 1971; 11(suppl 3):71-84.
18. Martins-Ferreira H. Depressão alastrante na retina. *An Acad Bras Cienc.* 1962;34:44.
19. Martins-Ferreira H. Spreading depression in the chicken retina. In: Ookawa T, ed. *The Brain and Behavior of the Fowl*. 1st ed. Tokyo: Japan Scientific Societies Press; 1983:317-333.
20. Maranhão-Filho PA, Martins-Ferreira H, Vincent MB, Ribeiro LJ, Novis SA. Sumatriptan blocks spreading depression in isolated chick retina. *Cephalalgia.* 1997;17:822-825.
21. Martins-Ferreira H. Propagation of spreading depression in isolated chick retina. In: Lehmenkühler A, Grottemaier KH, Tegtmeier F, eds. *Migraine: Basic Mechanisms and Treatment*. Monchen. Wien, Baltimore: Urban and Schwarzenberg; 1993:533-546.
22. do Carmo RJ, Martins-Ferreira H. Spreading depression of Leao probed with ion-selective microelectrodes in isolated chick retina. *An Acad Bras Cienc.* 1984;56:401-421.
23. Streit DS, Ferreira Filho CR, Martins-Ferreira H. Spreading depression in isolated spinal cord. *J Neurophysiol.* 1995;74:888-890.
24. Leão AAP, Morison RS. Propagation of spreading cortical depression. *J Neurophysiol.* 1945;8:33-45.
25. Leão AAP. Pial circulation and spreading depression of activity in the cerebral cortex. *J Neurophysiol.* 1944;7:391-396.
26. Edvinsson L, Uddman R. Neurobiology in primary headaches. *Brain Res Brain Res Rev.* 2005;48:438-456.
27. Hadjikhani N, Sanchez Del Rio M, Wu O, et al. Mechanisms of migraine aura revealed by functional MRI in human visual cortex. *Proc Natl Acad Sci U S A.* 2001;98:4687-4692.
28. Moskowitz MA, Nozaki K, Kraig RP. Neocortical spreading depression provokes the expression of c-fos protein-like immunoreactivity within trigeminal nucleus caudalis via trigeminovascular mechanisms. *J Neurosci.* 1993;13:1167-1177.
29. Moskowitz MA. The neurobiology of vascular head pain. *Ann Neurol.* 1984;16:157-168.
30. Buzzi MG, Moskowitz MA. The antimigraine drug, sumatriptan (GR43175), selectively blocks neurogenic plasma extravasation from blood vessels in dura mater. *Br J Pharmacol.* 1990;99:202-209.
31. Buzzi MG, Moskowitz MA. Evidence for 5-HT<sub>1B/1D</sub> receptors mediating the antimigraine effect of sumatriptan and dihydroergotamine. *Cephalalgia.* 1991;11:165-168.
32. Jansen I, Edvinsson L, Mortensen A, Olesen J. Sumatriptan is a potent vasoconstrictor of human dural arteries via a 5-HT<sub>1</sub>-like receptor. *Cephalalgia.* 1992;12:202-205.
33. Barlow JS. *The Cerebellum and Adaptive Control*. New York: Cambridge University Press; 2002.
34. Schmahmann JD. Disorders of the cerebellum: Ataxia, dysmetria of thought, and the cerebellar cognitive affective syndrome. *J Neuropsychiatry Clin Neurosci.* 2004;16:367-378.
35. Goldowitz D, Hamre K. The cells and molecules that make a cerebellum. *Trends Neurosci.* 1998;21:375-382.
36. Ishizaki K, Mori N, Takeshima T, et al. Static stabilometry in patients with migraine and tension-type headache during a headache-free period. *Psychiatry Clin Neurosci.* 2002;56:85-90.
37. Cho AA, Clark JB, Rupert AH. Visually triggered migraine headaches affect spatial orientation and balance in a helicopter pilot. *Aviat Space Environ Med.* 1995;66:353-358.
38. Harno H, Hirvonen T, Kaunisto MA, et al. Subclinical vestibulocerebellar dysfunction in migraine with and without aura. *Neurology.* 2003;61:1748-1752.
39. Sandor PS, Mascia A, Seidel L, de Pasqua V, Schoenen J. Subclinical cerebellar impairment in the common types of migraine: A three-dimensional analysis of reaching movements. *Ann Neurol.* 2001;49:668-672.
40. Baloh RW. Neurotology of migraine. *Headache.* 1997;37:615-621.
41. Cutrer FM, Baloh RW. Migraine-associated dizziness. *Headache.* 1992;32:300-304.
42. Toglia JU, Thomas D, Kuritzky A. Common migraine and vestibular function. Electronystagmographic study and pathogenesis. *Ann Otol Rhinol Laryngol.* 1981;90(3pt1):267-271.
43. Kayan A, Hood JD. Neuro-otological manifestations of migraine. *Brain.* 1984;107 (pt4):1123-1142.
44. Guerraz M, Yardley L, Bertholon P, et al. Visual vertigo: Symptom assessment, spatial orientation and postural control. *Brain.* 2001;124(pt8):1646-1656.
45. McKendrick AM, Vingrys AJ, Badcock DR, Heywood JT. Visual dysfunction between migraine events. *Invest Ophthalmol Vis Sci.* 2001;42:626-633.

46. McKendrick AM, Badcock DR. Motion processing deficits in migraine. *Cephalalgia*. 2004;24:363-372.
47. Yenice O, Onal S, Incili B, Temel A, Afsar N, Tanrida Gcaron T. Assessment of spatial-contrast function and short-wavelength sensitivity deficits in patients with migraine. *Eye*. 2006.
48. Polak O, Grof P. Kleinhirnmigräne bei basilarer impression. *Psychiatr Neurol (Basel)*. 1966;152:246-257.
49. Heidrich R. Cerebellar migraine. *Psychiatr Neurol Med Psychol (Leipz)*. 1961;13:42-46.
50. Chrást B. Migraena cerebellaris. *Bratisl Lékarškék Listy*. 1954;9:271-276.
51. Bickerstaff ER. Basilar artery migraine. *Lancet*. 1961;277:15-17.
52. Golden GS, French JH. Basilar artery migraine in young children. *Pediatrics*. 1975;56:722-726.
53. Kirchmann M, Thomsen LL, Olesen J. Basilar-type migraine. Clinical, epidemiologic and genetic features. *Neurology*. 2006;66:880-886.
54. Bernsen HJ, Van de Vlasakker C, Verhagen WI, Prick MJ. Basilar artery migraine stroke. *Headache*. 1990;30:142-144.
55. Sabharwal RK, Mehndiratta MM, Gupta M, Anjaneyulu A, Malhotra LK, Khwaja G. Cerebellar and thalamic infarctions in basilar artery migraine. *J Assoc Physicians India*. 1990;38:237-238.
56. Ganji S, Williams W, Furlow J. Bilateral occipital lobe infarction in acute migraine: Clinical, neurophysiological, and neuroradiological study. *Headache*. 1992;32:360-365.
57. Seto H, Shimizu M, Futatsuya R, et al. Basilar artery migraine. Reversible ischemia demonstrated by Tc-99m HMPAO brain SPECT. *Clin Nucl Med*. 1994;19:215-218.
58. Muellbacher W, Mamoli B. Prolonged impaired consciousness in basilar artery migraine. *Headache*. 1994;34:282-285.
59. Ambrosini A, D'Onofrio M, Grieco GS, et al. Familial basilar migraine associated with a new mutation in the ATP1A 2 gene. *Neurology*. 2005;65:1826-1828.
60. Kors EE, Haan J, Giffin NJ, et al. Expanding the phenotypic spectrum of the CACNA1A gene T666M mutation: A description of 5 families with familial hemiplegic migraine. *Arch Neurol*. 2003;60:684-688.
61. Ophoff RA, Terwindt GM, Vergouwe MN, et al. Familial hemiplegic migraine and episodic ataxia type-2 are caused by mutations in the Ca<sup>2+</sup> channel gene CACNL1A4. *Cell*. 1996;87:543-552.
62. Ducros A, Joutel A, Vahedi K, et al. Mapping of a second locus for familial hemiplegic migraine to 1q21-q23 and evidence of further heterogeneity. *Ann Neurol*. 1997;42:885-890.
63. Vanmolkot KR, Kors EE, Hottenga JJ, et al. Novel mutations in the Na<sup>+</sup>, K<sup>+</sup>-ATPase pump gene ATP1A2 associated with familial hemiplegic migraine and benign familial infantile convulsions. *Ann Neurol*. 2003;54:360-366.
64. Dichgans M, Freilinger T, Eckstein G, et al. Mutation in the neuronal voltage-gated sodium channel SCN1A in familial hemiplegic migraine. *Lancet*. 2005;366:371-377.
65. Spadaro M, Ursu S, Lehmann-Horn F, et al. A G301R Na<sup>+</sup>/K<sup>+</sup>-ATPase mutation causes familial hemiplegic migraine type 2 with cerebellar signs. *Neurogenetics*. 2004;5:177-185.
66. Mintz IM, Venema VJ, Swiderek KM, Lee TD, Bean BP, Adams ME. P-type calcium channels blocked by the spider toxin omega-Aga-IVA. *Nature*. 1992;355:827-829.
67. Mori Y, Friedrich T, Kim MS, et al. Primary structure and functional expression from complementary DNA of a brain calcium channel. *Nature*. 1991;350:398-402.
68. Dunlap K, Luebke JI, Turner TJ. Exocytotic Ca<sup>2+</sup> channels in mammalian central neurons. *Trends Neurosci*. 1995;18:89-98.
69. Pineda JC, Waters RS, Foehring RC. Specificity in the interaction of HVA Ca<sup>2+</sup> channel types with Ca<sup>2+</sup>-dependent AHPs and firing behavior in neocortical pyramidal neurons. *J Neurophysiol*. 1998;79:2522-2534.
70. Hans M, Luvisetto S, Williams ME, et al. Functional consequences of mutations in the human alpha1A calcium channel subunit linked to familial hemiplegic migraine. *J Neurosci*. 1999;19:1610-1619.
71. van den Maagdenberg AM, Pietrobon D, Pizzorusso T, et al. A Cacna1a knockin migraine mouse model with increased susceptibility to cortical spreading depression. *Neuron*. 2004;41:701-710.
72. Ducros A, Denier C, Joutel A, et al. Recurrence of the T666M calcium channel CACNA1A gene mutation in familial hemiplegic migraine with progressive cerebellar ataxia. *Am J Hum Genet*. 1999;64:89-98.
73. Vahedi K, Denier C, Ducros A, et al. CACNA1A gene de novo mutation causing hemiplegic migraine, coma, and cerebellar atrophy. *Neurology*. 2000;55:1040-1042.

74. Battistini S, Stenirri S, Piatti M, et al. A new CACNA1A gene mutation in acetazolamide-responsive familial hemiplegic migraine and ataxia. *Neurology*. 1999;53:38-43.
75. Margolis RL. The spinocerebellar ataxias: Order emerges from chaos. *Curr Neurol Neurosci Rep*. 2002;2:447-456.
76. Hawkes CH. Familial paroxysmal ataxia: Report of a family. *J Neurol Neurosurg Psychiatry*. 1992;55:212-213.
77. Harada H, Tamaoka A, Watanabe M, Ishikawa K, Shoji S. Downbeat nystagmus in two siblings with spinocerebellar ataxia type 6 (SCA 6). *J Neurol Sci*. 1998;160:161-163.
78. Friend KL, Crimmins D, Phan TG, et al. Detection of a novel missense mutation and second recurrent mutation in the CACNA1A gene in individuals with EA-2 and FHM. *Hum Genet*. 1999;105:261-265.
79. Jen J, Kim GW, Baloh RW. Clinical spectrum of episodic ataxia type 2. *Neurology*. 2004;62:17-22.
80. Denier C, Ducros A, Durr A, Eymard B, Chassande B, Tournier-Lasserre E. Missense CACNA1A mutation causing episodic ataxia type 2. *Arch Neurol*. 2001;58:292-295.
81. Guida S, Trettel F, Pagnutti S, et al. Complete loss of P/Q calcium channel activity caused by a CACNA1A missense mutation carried by patients with episodic ataxia type 2. *Am J Hum Genet*. 2001;68:759-764.
82. Kvistad PH, Dahl A, Skre H. Autosomal recessive non-progressive ataxia with an early childhood debut. *Acta Neurol Scand*. 1985;71:295-302.
83. Tranebjaerg L, Teslovich TM, Jones M, et al. Genome-wide homozygosity mapping localizes a gene for autosomal recessive non-progressive infantile ataxia to 20q11-q13. *Hum Genet*. 2003;113:293-295.
84. Steckley JL, Ebers GC, Cader MZ, McLachlan RS. An autosomal dominant disorder with episodic ataxia, vertigo, and tinnitus. *Neurology*. 2001;57:1499-1502.
85. Mantuano E, Veneziano L, Jodice C, Frontali M. Spinocerebellar ataxia type 6 and episodic ataxia type 2: Differences and similarities between two allelic disorders. *Cytogenet Genome Res*. 2003;100:147-153.
86. Frontali M. Spinocerebellar ataxia type 6: Channelopathy or glutamine repeat disorder? *Brain Res Bull*. 2001;56:227-231.
87. Jen J. Familial episodic ataxias and related ion channel disorders. *Curr Treat Options Neurol*. 2000;2:429-431.
88. Jodice C, Mantuano E, Veneziano L, et al. Episodic ataxia type 2 (EA2) and spinocerebellar ataxia type 6 (SCA6) due to CAG repeat expansion in the CACNA1A gene on chromosome 19p. *Hum Mol Genet*. 1997;6:1973-1978.
89. Jen JC, Wan J, Palos TP, Howard BD, Baloh RW. Mutation in the glutamate transporter EAAT1 causes episodic ataxia, hemiplegia, and seizures. *Neurology*. 2005;65:529-534.
90. Zhuchenko O, Bailey J, Bonnen P, et al. Autosomal dominant cerebellar ataxia (SCA6) associated with small polyglutamine expansions in the alpha 1A-voltage-dependent calcium channel. *Nat Genet*. 1997;15:62-69.
91. Alonso I, Barros J, Tuna A, et al. Phenotypes of spinocerebellar ataxia type 6 and familial hemiplegic migraine caused by a unique CACNA1A missense mutation in patients from a large family. *Arch Neurol*. 2003;60:610-614.
92. Alonso I, Barros J, Tuna A, et al. A novel R1347Q mutation in the predicted voltage sensor segment of the P/Q-type calcium-channel alpha-subunit in a family with progressive cerebellar ataxia and hemiplegic migraine. *Clin Genet*. 2004;65:70-72.
93. Richter S, Dimitrova A, Maschke M, et al. Degree of cerebellar ataxia correlates with three-dimensional MRI-based cerebellar volume in pure cerebellar degeneration. *Eur Neurol*. 2005;54:23-27.
94. Ducros A, Denier C, Joutel A, et al. The clinical spectrum of familial hemiplegic migraine associated with mutations in a neuronal calcium channel. *N Engl J Med*. 2001;345:17-24.
95. Elliott MA, Peroutka SJ, Welch S, May EF. Familial hemiplegic migraine, nystagmus, and cerebellar atrophy. *Ann Neurol*. 1996;39:100-106.
96. Kors EE, Melberg A, Vanmolkot KR, et al. Childhood epilepsy, familial hemiplegic migraine, cerebellar ataxia, and a new CACNA1A mutation. *Neurology*. 2004;63:1136-1137.
97. Jen J, Yue Q, Nelson SF, et al. A novel nonsense mutation in CACNA1A causes episodic ataxia and hemiplegia. *Neurology*. 1999;53:34-37.
98. Nam SC, Hockberger PE. Analysis of spontaneous electrical activity in cerebellar Purkinje cells acutely isolated from postnatal rats. *J Neurobiol*. 1997;33:18-32.

99. Walter JT, Alvina K, Womack MD, Chevez C, Khodakhah K. Decreases in the precision of Purkinje cell pacemaking cause cerebellar dysfunction and ataxia. *Nat Neurosci.* 2006;9:389-397.
100. Kors EE, Terwindt GM, Vermeulen FL, et al. Delayed cerebral edema and fatal coma after minor head trauma: Role of the CACNA1A calcium channel subunit gene and relationship with familial hemiplegic migraine. *Ann Neurol.* 2001;49:753-760.
101. Fitzsimons RB, Wolfenden WH. Migraine coma. Meningitic migraine with cerebral oedema associated with a new form of autosomal dominant cerebellar ataxia. *Brain.* 1985;108(pt3):555-577.
102. Munte TF, Muller-Vahl H. Familial migraine coma: A case study. *J Neurol.* 1990;237:59-61.
103. Wada T, Kobayashi N, Takahashi Y, Aoki T, Watanabe T, Saitoh S. Wide clinical variability in a family with a CACNA1A T666m mutation: Hemiplegic migraine, coma, and progressive ataxia. *Pediatr Neurol.* 2002;26:47-50.
104. Tan BB. Migraine versus glaucoma—A diagnostic dilemma. *Ann Acad Med Singapore.* 1990;19:856-858.
105. Corbin D, Martyr T, Graham AC. Migraine coma. *J Neurol Neurosurg Psychiatry.* 1991;54:744.
106. Echenne B, Ducros A, Rivier F, et al. Recurrent episodes of coma: An unusual phenotype of familial hemiplegic migraine with linkage to chromosome 1. *Neuropediatrics.* 1999;30:214-217.
107. Sareen D. Interesting case of migraine presenting with recurrent episodes of migraine coma. *J Assoc Physicians India.* 2000;48:1031.
108. Tottene A, Pivotto F, Fellin T, Cesetti T, van den Maagdenberg AM, Pietrobon D. Specific kinetic alterations of human CaV2.1 calcium channels produced by mutation S218L causing familial hemiplegic migraine and delayed cerebral edema and coma after minor head trauma. *J Biol Chem.* 2005;280:17678-17686.
109. Pietrobon D. Migraine: New molecular mechanisms. *Neuroscientist.* 2005;11:373-386.
110. Gursoy-Ozdemir Y, Qiu J, Matsvaka N, et al. Cortical spreading depression activates and upregulates MMP-9. *J Clin Invest.* 2004;113:1447-1455.
111. Olesen J, Jorgensen MB. Leao's spreading depression in the hippocampus explains transient global amnesia: A hypothesis. *Acta Neurol Scand.* 1986;73:219-220.
112. Haas DC, Ross GS. Transient global amnesia triggered by mild head trauma. *Brain.* 1986;109(pt2):251-257.
113. Bain PG, O'Brien MD, Keevil SF, Porter DA. Familial periodic cerebellar ataxia: A problem of cerebellar intracellular pH homeostasis. *Ann Neurol.* 1992;31:147-154.
114. Griggs RC, Moxley RT, 3rd, LaFrance RA, McQuillen J. Hereditary paroxysmal ataxia: Response to acetazolamide. *Neurology.* 1978;28:1259-1264.
115. Jen JC, Yue Q, Karrim J, Nelson SF, Baloh RW. Spinocerebellar ataxia type 6 with positional vertigo and acetazolamide responsive episodic ataxia. *J Neurol Neurosurg Psychiatry.* 1998;65:565-568.
116. Athwal BS, Lennox GG. Acetazolamide responsiveness in familial hemiplegic migraine. *Ann Neurol.* 1996;40:820-821.
117. de Simone R, Marano E, Di Stasio E, Bonuso S, Fiorillo C, Bonavita V. Acetazolamide efficacy and tolerability in migraine with aura: A pilot study. *Headache.* 2005;45:385-386.
118. Vahedi K, Taupin P, Djomby R, et al. Efficacy and tolerability of acetazolamide in migraine prophylaxis: A randomised placebo-controlled trial. *J Neurol.* 2002;249:206-211.
119. Haan J, Sluis P, Sluis LH, Ferrari MD. Acetazolamide treatment for migraine aura status. *Neurology.* 2000;55:1588-1589.
120. Shank RP, Doose DR, Streeter AJ, Bialer M. Plasma and whole blood pharmacokinetics of topiramate: The role of carbonic anhydrase. *Epilepsy Res.* 2005;63:103-112.
121. Ayata C, Jin H, Kudo C, Dalkara T, Moskowitz MA. Suppression of cortical spreading depression in migraine prophylaxis. *Ann Neurol.* 2006;59:652-661.
122. Spacey SD, Hildebrand ME, Materek LA, Bird TD, Snutch TP. Functional implications of a novel EA2 mutation in the P/Q-type calcium channel. *Ann Neurol.* 2004;56:213-220.
123. Jayamaha JE, Street MK. Fatal cerebellar infarction in a migraine sufferer whilst receiving sumatriptan. *Intensive Care Med.* 1995;21:82-83.
124. Crawford JS, Konkol RJ. Familial hemiplegic migraine with crossed cerebellar diaschisis and unilateral meningeal enhancement. *Headache.* 1997;37:590-593.
125. Lee TG, Solomon GD, Kunkel RS, Raja S. Reversible cerebellar perfusion in familial hemiplegic migraine. *Lancet.* 1996;348:1383.

126. Harbaugh RE, Saunders RL, Reeves AG. Pediatric cerebellar infarction: Case report and review of the literature. *Neurosurgery*. 1982;10:593-596.
127. Kruit MC, van Buchem MA, Hofman PA, Bakkers JT, Terwindt GM, Ferrari MD, et al. Migraine as a risk factor for subclinical brain lesions. *JAMA*. 2004;291:427-434.
128. Kruit MC, Launer LJ, Ferrari MD, van Buchem MA. Infarcts in the posterior circulation territory in migraine. The population-based MRI CAMERA study. *Brain*. 2005;128:2068-2077.
129. Duvernoy H, Delon S, Vannson JL. The vascularization of the human cerebellar cortex. *Brain Res Bull*. 1983;11:419-480.
130. Guerini D, Coletto L, Carafoli E. Exporting calcium from cells. *Cell Calcium*. 2005;38:281-289.
131. Chen G, Hanson CL, Dunbar RL, Ebner TJ. Novel form of spreading acidification and depression in the cerebellar cortex demonstrated by neutral red optical imaging. *J Neurophysiol*. 1999;81:1992-1998.
132. Ebner TJ, Chen G. Spreading acidification and depression in the cerebellar cortex. *Neuroscientist*. 2003;9:37-45.
133. Comu S, Giuliani M, Narayanan V. Episodic ataxia and myokymia syndrome: A new mutation of potassium channel gene Kv1.1. *Ann Neurol*. 1996;40:684-687.
134. Cornell-Bell AH, Finkbeiner SM, Cooper MS, Smith SJ. Glutamate induces calcium waves in cultured astrocytes: Long-range glial signaling. *Science*. 1990;247:470-473.
135. Charles A. Intercellular calcium waves in glia. *Glia*. 1998;24:39-49.
136. Simard M, Arcuino G, Takano T, Liu QS, Nedergaard M. Signaling at the gliovascular interface. *J Neurosci*. 2003;23:9254-9262.
137. Nedergaard M. Direct signaling from astrocytes to neurons in cultures of mammalian brain cells. *Science*. 1994;263:1768-1771.
138. Dani JW, Chernjavsky A, Smith SJ. Neuronal activity triggers calcium waves in hippocampal astrocyte networks. *Neuron*. 1992;8:429-440.
139. Newman EA, Zahs KR. Calcium waves in retinal glial cells. *Science*. 1997;275:844-847.
140. Guthrie PB, Knappenberger J, Segal M, Bennett MV, Charles AC, Kater SB. ATP released from astrocytes mediates glial calcium waves. *J Neurosci*. 1999;19:520-528.
141. Kunkler PE, Kraig RP. Calcium waves precede electrophysiological changes of spreading depression in hippocampal organ cultures. *J Neurosci*. 1998;18:3416-3425.
142. Basarsky TA, Duffy SN, Andrew RD, MacVicar BA. Imaging spreading depression and associated intracellular calcium waves in brain slices. *J Neurosci*. 1998;18:7189-7199.
143. Pietrobon D. Calcium channels and channelopathies of the central nervous system. *Mol Neurobiol*. 2002;25:31-50.
144. del Zoppo GJ, Hallenbeck JM. Advances in the vascular pathophysiology of ischemic stroke. *Thromb Res*. 2000;98:73-81.
145. Sappey-Marinié D, Vighetto A, Peyron R, Broussolle E, Bonmartin A. Phosphorus and proton magnetic resonance spectroscopy in episodic ataxia type 2. *Ann Neurol*. 1999;46:256-259.
146. Sasaki H, Kojima H, Yabe I, et al. Neuropathological and molecular studies of spinocerebellar ataxia type 6 (SCA6). *Acta Neuropathol (Berl)*. 1998;95:199-204.
147. Takahashi T, Arai N, Shimamura M, et al. Autopsy case of acute encephalopathy linked to familial hemiplegic migraine with cerebellar atrophy and mental retardation. *Neuropathology*. 2005;25:228-234.
148. Ruskell GL, Simons T. Trigeminal nerve pathways to the cerebral arteries in monkeys. *J Anat*. 1987;155:23-37.
149. Saito K, Moskowitz MA. Contributions from the upper cervical dorsal roots and trigeminal ganglia to the feline circle of Willis. *Stroke*. 1989;20:524-526.
150. Baloh RW, Yue Q, Furman JM, Nelson SF. Familial episodic ataxia: Clinical heterogeneity in four families linked to chromosome 19p. *Ann Neurol*. 1997;41:8-16.
151. Ohta M, Araki S, Kuroiwa Y. Familial occurrence of migraine with a hemiplegic syndrome and cerebellar manifestations. *Neurology*. 1967;17(8pt1):813-817.
152. Young GF, Leon-Barth CA, Green J. Familial hemiplegic migraine, retinal degeneration, deafness, and nystagmus. *Arch Neurol*. 1970;23:201-209.
153. Codina A, Acarin PN, Miquel F, Noguera M. Migraine Hémiplégique associée à un nystagmus. *Rev Neurol (Paris)*. 1971;124:526-530.
154. Zifkin B, Andermann E, Andermann F, Kirkham T. An autosomal dominant syndrome of hemiplegic migraine, nystagmus, and tremor. *Ann Neurol*. 1980;8:329-332.