

The clinical use of stress echocardiography in non-ischaemic heart disease: recommendations from the European Association of Cardiovascular Imaging and the American Society of Echocardiography

Patrizio Lancellotti^{1,2*}, Patricia A. Pellikka³, Werner Budts⁴, Farooq A. Chaudhry⁵, Erwan Donal⁶, Raluca Dulgheru¹, Thor Edvardsen⁷, Madalina Garbi⁸, Jong-Won Ha⁹, Garvan C. Kane³, Joe Kreeger¹⁰, Luc Mertens¹¹, Philippe Pibarot¹², Eugenio Picano¹³, Thomas Ryan¹⁴, Jeane M. Tsutsui¹⁵, and Albert Varga¹⁶

¹Department of Cardiology, University of Liège Hospital, GIGA-Cardiovascular Sciences, Liège, Belgium; ²Gruppo Villa Maria Care and Research, Anthea Hospital, Bari, Italy; ³Division of Cardiovascular Ultrasound, Department of Cardiovascular Medicine, Mayo Clinic, Rochester, MN, USA; ⁴Congenital and Structural Cardiology University Hospitals Leuven, Leuven; ⁵Echocardiography Laboratories, Mount Sinai Medical Center, Icahn School of Medicine at Mount Sinai, Zena and Michael A. Wiener Cardiovascular Institute and Marie-Josée and Henry R. Kravis Center for Cardiovascular Health, NY, USA; ⁶Service de Cardiologie, CHU RENNES et LTSI U 1099 – Université Rennes-1, Rennes, France; ⁷Department of Cardiology, Oslo University Hospital, Rikshospitalet and University of Oslo, Oslo, Norway; ⁸King's Health Partners, King's College Hospital NHS Foundation Trust, London, UK; ⁹Cardiology Division, Yonsei University College of Medicine, Seoul, South Korea; ¹⁰Echo Lab, Children's Healthcare of Atlanta, Emory University School of Medicine Atlanta, Georgia, USA; ¹¹Echocardiography, The Hospital for Sick Children, University of Toronto, Toronto, Canada; ¹²Québec Heart & Lung Institute/Institut Universitaire de Cardiologie et de Pneumologie de Québec, Department of Cardiology, Laval University and Canada Research Chair in Valvular Heart Disease, QC, Canada; ¹³Institute of Clinical Physiology, National Research Council, Pisa, Italy; ¹⁴Ohio State University, Columbus, OH, USA; ¹⁵Heart Institute – University of São Paulo Medical School and Fleury Group, São Paulo, Brazil; and ¹⁶Institute of Family Medicine, University of Szeged, Hungary

Received 11 August 2016; accepted after revision 12 August 2016

A unique and highly versatile technique, stress echocardiography (SE) is increasingly recognized for its utility in the evaluation of non-ischaemic heart disease. SE allows for simultaneous assessment of myocardial function and haemodynamics under physiological or pharmacological conditions. Due to its diagnostic and prognostic value, SE has become widely implemented to assess various conditions other than ischaemic heart disease. It has thus become essential to establish guidance for its applications and performance in the area of non-ischaemic heart disease. This paper summarizes these recommendations.

Keywords

Cardiomyopathy • Congenital heart disease • Heart failure • Pulmonary hypertension • Stress echocardiography • Stress test • Valvular heart disease

Table of contents

Introduction	1192	Dobutamine.....	1197
Stress echocardiography methods.....	1193	Vasodilators.....	1197
Haemodynamic effects of myocardial stressors.....	1193	Image acquisition.....	1197
Exercise.....	1193	Interpretation of the test.....	1199
Dobutamine.....	1193	Safety	1199
Vasodilators.....	1193	Diastolic stress echocardiography	1200
Stress echocardiography protocols.....	1193	Interpretation and haemodynamic correlation.....	1200
Treadmill	1193	Impact on treatment.....	1202
Bicycle	1197	Hypertrophic cardiomyopathy	1202
		Impact on treatment.....	1203
		Heart failure and non-ischaemic cardiomyopathy.....	1204

* Corresponding author. Tel: +32 4 366 71 94; Fax: +32 4 366 71 95. E-mail: plancellotti@chu.ulg.ac.be

Published on behalf of the European Society of Cardiology. All rights reserved. © The Author 2016. For permissions please email: journals.permissions@oup.com.

Differentiating non- <i>ischaemic</i> from <i>ischaemic</i> cardiomyopathy.....	1206
Cardiac resynchronization therapy.....	1206
Response to therapy.....	1206
Native valve disease.....	1206
Mitral regurgitation.....	1208
Primary MR.....	1208
Secondary MR.....	1208
Impact on treatment.....	1208
Aortic regurgitation.....	1209
Severe aortic regurgitation without symptoms.....	1209
Non-severe aortic regurgitation with symptoms.....	1209
Impact on treatment.....	1209
Mitral stenosis.....	1209
Severe mitral stenosis without symptoms.....	1209
Non-severe mitral stenosis with symptoms.....	1209
Impact on treatment.....	1210
Aortic stenosis.....	1210
Asymptomatic severe aortic stenosis.....	1210
Impact on treatment.....	1211
Low-flow, low-gradient aortic stenosis.....	1212
Low-flow, low-gradient aortic stenosis with reduced left ventricular ejection fraction.....	1212
Impact on treatment.....	1212
Low-Flow, low-gradient aortic stenosis with preserved ventricular ejection fraction.....	1212
Multivalvular heart disease.....	1214
Post valve procedures.....	1215
Aortic and mitral prosthetic valves.....	1215
Mitral valve annuloplasty.....	1216
Pulmonary hypertension and pulmonary arterial pressure.....	1217
Pulmonary artery pressure with exercise in normal individuals.....	1218
Screening for susceptibility for high altitude pulmonary edema and chronic mountain sickness.....	1218
Screening for pulmonary hypertension in patients at high risk for pulmonary arterial hypertension.....	1218
SE in patients with established pulmonary hypertension.....	1219
Athletes' hearts.....	1219
Congenital heart disease.....	1219
Atrial septal defect.....	1219
Tetralogy of Fallot.....	1220
Treated coarctation of the aorta.....	1220
Univentricular hearts.....	1220
Systemic right ventricle.....	1222
Training and competencies.....	1222
Summary and future directions.....	1223
References.....	1223

Abbreviations

ACC: American College of Cardiology
 AHA: American Heart Association
 AR: aortic regurgitation
 AS: aortic stenosis

AVA: aortic valve area
 AVR: aortic valve replacement
 CHD: congenital heart disease
 CW: continuous wave
 EACTS: European association of cardiothoracic surgery
 EF: ejection fraction
 EOA: effective orifice area
 ESC: European society of cardiology
 HAPE: high altitude pulmonary edema
 HCM: hypertrophic cardiomyopathy
 LF: low flow
 LG: low gradient
 LV: left ventricle
 LVOT: left ventricle outflow tract
 LVOTO: left ventricle outflow tract obstruction
 MR: mitral regurgitation
 MS: mitral stenosis
 PAH: pulmonary arterial hypertension
 PAP: pulmonary artery pressure
 PH: pulmonary hypertension
 PPM: patient–prosthesis mismatch
 PVR: pulmonary vascular resistance
 Q: flow rate
 RV: right ventricle
 RVOT: right ventricular outflow tract
 RVFAC: right ventricular fractional area change
 SPAP: systolic pulmonary artery pressure
 SE: Stress echocardiography
 TAPSE: tricuspid annular plane systolic excursion
 TR: tricuspid regurgitation

Introduction

Stress echocardiography (SE) has most frequently been applied to the assessment of known or suspected *ischaemic* heart disease.^{1,2} Stress-induced *ischaemia* results in the development of new or worsening regional wall motion abnormalities in the region subtended by a stenosed coronary artery; imaging increases the accuracy of the stress electrocardiogram for the recognition of *ischaemia* and high-risk features.

However, *ischaemic* heart disease is only one of the many diseases and conditions that can be assessed with SE. In recent years, SE has become an established method for the assessment of a wide spectrum of challenging clinical conditions, including systolic or diastolic heart failure, non-*ischaemic* cardiomyopathy, valvular heart disease, pulmonary hypertension (PH), athletes' hearts, congenital heart disease (CHD), and heart transplantation.^{3,4} Due to the growing body of evidence supporting the use of SE beyond the evaluation of *ischaemia*, its increasing implementation in many echocardiography laboratories and its recognized diagnostic and prognostic value, it has thus become essential to establish guidance for its applications and performance. This paper provides recommendations for the clinical applications of SE to non-*ischaemic* heart disease. When clinically indicated, *ischaemia* can also be assessed in conjunction with assessments of non-*ischaemic* conditions, but it is not the focus of this document.

Stress echocardiography methods

SE provides a dynamic evaluation of myocardial structure and function under conditions of physiological (exercise) or pharmacological (inotrope, vasodilator) stress. The images obtained during SE permit matching symptoms with cardiac involvement. SE can unmask structural/functional abnormalities, which—although occult in the resting or static state—may occur under conditions of activity or stress, and lead to wall motion abnormalities, valvular dysfunction, or other haemodynamic abnormalities.^{5–8}

Exercise is the test of choice for most applications. As a general rule, any patient capable of physical exercise should be tested with an exercise modality, as this preserves the integrity of the electromechanical response and provides valuable information regarding functional status. Performing echocardiography at the time of exercise also allows links to be drawn among symptoms, cardiovascular workload, wall motion abnormalities, and haemodynamic responses, such as pulmonary pressure and transvalvular flows and gradients. Exercise echocardiography can be performed using either a treadmill or bicycle ergometer protocol. Semi-supine bicycle exercise is, however, technically easier than upright bicycle or treadmill exercise, especially when multiple stress parameters are assessed at the peak level of exercise.

Pharmacological stress does not replicate the complex haemodynamic and neurohormonal changes triggered by exercise. This includes psychological motivation and the response to exercise of the central and peripheral nervous systems, lungs and pulmonary circulation, right ventricle (RV) and left ventricle (LV), myocardium, valves, coronary circulation, peripheral circulation, and skeletal muscle.^{9–11} Dobutamine is the preferred alternative modality for the evaluation of contractile and flow reserve. Vasodilator SE is especially convenient for combined assessment of wall motion and coronary flow reserve, which may be indicated in dilated non-ischaemic cardiomyopathy and hypertrophic cardiomyopathy (HCM).^{12,13}

A flexible use of exercise, dobutamine, and vasodilator stresses maximizes versatility, avoids specific contraindications of each, and makes it possible to tailor the appropriate test to the individual patient (Table 1).⁹

Haemodynamic effects of myocardial stressors

All SE stressors have associated haemodynamic effects. As a common outcome, they result in a myocardial supply/demand mismatch and may induce ischaemia in the presence of a reduction in coronary flow reserve, due to epicardial stenoses, LV hypertrophy, or microvascular disease.¹⁰ Exercise and inotropic stressors normally provoke a generalized increase of regional wall motion and thickening, with an increment of ejection fraction (EF) mainly caused by a reduction of systolic dimensions.

Exercise

During treadmill or bicycle exercise, heart rate normally increases two- to three-fold, contractility three- to four-fold, and systolic blood pressure by $\geq 50\%$,¹¹ while systemic vascular resistance decreases. LV end-diastolic volume initially increases (increase in venous return) to sustain the increase in stroke volume through the

Frank–Starling mechanism and later falls at high heart rates. For most patients, both duration of exercise and maximum workload and achieved heart rate are slightly lower in the supine bicycle position, due primarily to the development of leg fatigue at an earlier stage of exercise. Then, for a given level of stress in the supine position, the end-diastolic volume and mean arterial blood pressure are higher. These differences contribute to a higher wall stress and an associated increase in myocardial oxygen demand and filling pressures compared with an upright bicycle test.¹¹ In response to exercise, there is a variable increase in pulmonary artery pressure (PAP), for which the degree depends on the intensity of the test. Coronary blood flow also increases three- to five-fold in normal subjects,¹⁴ but much less (< 2 -fold) in one-third of patients with non-ischaemic dilated or HCM. In the presence of a reduction in coronary flow reserve, the regional myocardial oxygen-supply mismatch determines subendocardial myocardial ischaemia and regional dysfunction, which can be observed in 10–20% of patients with angiographically normal coronary arteries and either dilated or HCM.

Dobutamine

Dobutamine acts directly and mainly on β -1 adrenergic receptors of the myocardium, producing an increase in heart rate and contractility. The increase in the determinants of myocardial oxygen consumption is substantial: heart rate increases two- to three-fold, end-diastolic volume 1.2-fold, and systolic arterial pressure 1.5- to 2-fold. Myocardial contractility (measured as elastance) increases over four-fold in normal subjects and much less so (less than two-fold) in patients with dilated cardiomyopathy.¹⁵ The activation of β -2 adrenergic receptors by dobutamine contributes to the mild decrease in blood pressure common at higher dobutamine dose, through a vasodilatory effect. During dobutamine infusion, LV end-systolic volume decreases to a greater extent than LV end-diastolic volume while the cardiac output increases as a result of increased heart rate and stroke volume. Compared with exercise, there is a lesser recruitment of venous blood volume with dobutamine, so that LV volumes and wall stress increase less with dobutamine.

Vasodilators

Vasodilator SE can be performed with dipyridamole, adenosine, or regadenoson, all using the same metabolic pathway, increasing endogenous adenosine levels (dipyridamole), increasing exogenous adenosine levels (adenosine), or directly acting on vascular A_{2A} adenosine receptors (with higher receptor specificity for regadenoson and less potential for complications). These vasodilators produce a small decrease in blood pressure, a modest tachycardia, and a minor increase in myocardial function.^{12,13} In the presence of a critical epicardial stenosis or microcirculatory dysfunction, vasodilator administration results in heterogeneity of coronary blood flow between areas subtended by stenosed vs. normal coronary arteries, a supply–demand mismatch, and a decrease in subendocardial flow in areas of coronary artery stenosis via steal phenomena.

Stress echocardiography protocols

Treadmill

The advantage of treadmill exercise echocardiography is the widespread availability of the treadmill system and the wealth of clinical

Table 1 Targeted parameters to be assessed during SE

SE indication	SE query	Type of stress	Sequence of image acquisition	Levels of image acquisition	SE result	SE report
Diastolic stress echo						
Diastolic function	Diastolic dysfunction \pm SPAP increase as reason for HF symptoms and signs	Exercise	PW Doppler E and A, PW Tissue Doppler e'_{rb} , TR CW Doppler for SPAP	Baseline, low workload, peak exercise	E/e' increase \pm SPAP increase	Diastolic dysfunction
Cardiomyopathies						
Hypertrophic cardiomyopathy	LVOTO/diastolic dysfunction/dynamic MR/inducible ischaemia as reason for symptoms, or to plan treatment/lifestyle advice	Exercise	CW Doppler LVOT velocity, TR CW Doppler for SPAP, PW Doppler E and A, PW Tissue Doppler e' , colour flow Doppler for MR, LV views for RWMA	Baseline, low workload, peak exercise, for treadmill, immediately post-exercise	LVOTO \pm SPAP increase E/e' increase \pm SPAP increase MR appearance/increase RWMA	Exertion-induced LVOTO Diastolic dysfunction Dynamic MR Inducible ischaemia
Dilated cardiomyopathy	Contractile reserve, inducible ischaemia, diastolic reserve, SPAP change, dynamic MR, pulmonary congestion	Exercise	LV views, PW Doppler E and A, PW tissue Doppler e' , TR CW Doppler for SPAP, Colour flow Doppler for MR, lung images	Baseline, low workload, peak exercise	Contractility increase No contractility increase E/e' increase \pm SPAP increase RWMA Lung comets MR increase/decrease	Contractile reserve No contractile reserve Pulmonary congestion Dynamic MR/functional MR Inotropic reserve No inotropic reserve CRT responder
	Inotropic reserve, inducible ischaemia	Dobutamine	LV views	Baseline, low dose \pm high dose	Contractility increase No contractility increase RWMA	Contractile reserve No contractile reserve Inducible ischaemia
Cardiac resynchronization therapy	Inotropic reserve, viability in paced area	Dobutamine	LV views	Baseline, low dose	Contractility increase No contractility increase EF increase, paced area viability	Inotropic reserve No inotropic reserve CRT responder
Native valve disease						
Aortic stenosis	Severe AS with no symptoms	Exercise	LV views, colour flow Doppler for MR, TR CW Doppler for SPAP, AV CW Doppler, LVOT PW Doppler	Baseline, low workload, peak exercise	Symptoms \pm LVEF drop/no increase a/o GLS \pm RWMA \pm SPAP increase \pm MR appearance/increase \pm gradient increase	Severe AS with symptoms/ pulmonary hypertension/ dynamic MR/no contractile reserve/inducible ischaemia/non-compliant valve
	Non-severe AS with symptoms	Exercise	AV CW Doppler, LVOT PW Doppler, LV views, Colour flow Doppler for MR	Baseline, low workload, peak exercise	Gradient increase + no/min AVA increase \pm LVEF drop/no increase a/o GLS \pm RWMA \pm MR appearance/increase \pm SPAP increase	Non-compliant valve/no contractile reserve/inducible ischaemia/dynamic MR/pulmonary hypertension
	Low-flow, low-gradient AS	Dobutamine	AV CW Doppler, LVOT PW Doppler, LV views	Baseline, low dose	No/min SV increase \pm LVEF drop/no increase a/o GLS \pm gradient increase \pm no/min AVA increase	No flow reserve/no LV contractile reserve/true-severe AS
		Exercise	LVOT PW Doppler, AV CW Doppler, LV views	Baseline, low workload		

Continued

Primary mitral regurgitation	Severe MR with no symptoms	Exercise	LV views, TR CW Doppler for SPAP	Baseline, low workload, peak exercise	Symptoms, SPAP increase, LV EF failure to increase	Severe MR with symptoms/ pulmonary hypertension/ no contractile reserve
	Non-severe MR with symptoms	Exercise	Colour flow Doppler for MR, LV views, TR CW Doppler for SPAP	Baseline, low workload, peak exercise	MR increase No MR increase	Severe MR with symptoms Symptoms unrelated with MR
Secondary mitral regurgitation	Change in MR severity with exertion \pm SPAP increase	Exercise	Colour flow Doppler for MR, TR CW Doppler for SPAP, LV views	Baseline, low workload, peak exercise	MR increase \pm SPAP increase MR decrease	Dynamic MR, assess severity Functional MR
	Severe AR with no symptoms	Exercise	LV views	Baseline, low workload, peak exercise	Symptoms EF failure to increase	Severe AR with symptoms/no LV contractile reserve
Aortic Regurgitation	Non-severe AR with symptoms	Exercise	LV views, Colour flow Doppler for MR, TR CW Doppler for SPAP	Baseline, low workload, peak exercise	RWMA \pm SPAP increase \pm MR appearance/increase	Inducible ischaemia/ pulmonary hypertension/ dynamic MR
	Severe MS with no symptoms	Exercise	TR CW Doppler for SPAP	Baseline, low workload, peak exercise	Symptoms \pm SPAP increase	Severe MS with symptoms/ pulmonary hypertension
Mitral stenosis	Non-severe MS with symptoms	Exercise	TR CW Doppler for SPAP, MV CW Doppler for mean gradient	Baseline, low workload, peak exercise	MV gradient increase \pm SPAP increase	Severe MS
		Dobutamine	MV CW Doppler for mean gradient	Baseline, low dose		
Multivalvular disease	Discordance in between symptoms and severity of valve disease	Exercise	Combination on the above depending on combination of features at baseline	Baseline, low workload, peak exercise	Re-evaluate symptoms/severity of valve disease	Symptoms due or not to valve disease
Post valve procedures						
Aortic valve prosthesis	Stenosis/PPM with or without low flow	Exercise	AV CW Doppler, LVOT PW Doppler, TR CW Doppler for SPAP, LV views, Colour flow Doppler for MR	Baseline, low workload, peak exercise	Symptoms \pm gradient increase + no/min EOA increase \pm SPAP increase \pm RWMA \pm MR appearance/increase	Significant stenosis or PPM/ inducible ischaemia/ dynamic MR
		Dobutamine	AV CW Doppler, LVOT Doppler, LV views	Baseline, low dose		
Mitral valve prosthesis	Stenosis/PPM	Exercise	TR CW Doppler for SPAP, MV CW Doppler for mean gradient	Baseline, low workload, peak exercise	Symptoms \pm gradient increase \pm SPAP increase	Significant stenosis or PPM
		Dobutamine	MV CW Doppler for mean gradient	Baseline, low workload		
Mitral valve annuloplasty	Iatrogenic MS	Exercise	TR CW Doppler for SPAP, MV CW Doppler for mean gradient	Baseline, low workload, peak exercise	Gradient increase \pm SPAP increase	Iatrogenic MS
		Dobutamine	MV CW Doppler for mean gradient	Baseline, low workload		

Continued

Table 1 Continued

SE indication	SE query	Type of stress	Sequence of image acquisition	Levels of image acquisition	SE result	SE report
Pulmonary hypertension						
Pulmonary hypertension	Symptoms and SPAP on exertion	Exercise	TR CW Doppler for SPAP, RV views	Baseline, low workload, peak exercise	SPAP increase	Regrade severity
Cor pulmonale ^a	RV contractile reserve and SPAP	Exercise	RV views, TR CW Doppler for SPAP	Baseline, low workload, peak exercise	RV contractility increase	RV contractile reserve
Athlete's heart						
Symptomatic athlete	Assess response to exercise and symptoms	Exercise	LV views, LVOT CW Doppler for LVOTO, TR CW Doppler for SPAP, Colour flow Doppler for MR, lung images	Baseline, low workload, peak exercise	RWMA LVOTO Pathologic SPAP increase MR appearance/increase Lung comets	Induced ischaemia LVOTO Pulmonary hypertension Dynamic MR Pulmonary congestion
Congenital heart disease						
Atrial septal defect	SPAP and RV contractile reserve	Exercise	TR CW Doppler, RV views	Baseline, low workload, peak exercise	SPAP increase RV contractility increase	Regrade severity RV contractile reserve
	RV contractile reserve	Dobutamine	RV views	Baseline, low workload	RV contractility increase	RV contractile reserve
Tetralogy of Fallot	RV and LV contractile reserve	Exercise	RV views, TAPSE, PW Tissue Doppler	Baseline, low workload, peak exercise	RV/LV contractility increase	RV/LV contractile reserve
Aortic coarctation	Assessment of severity and of LV contractile reserve	Exercise	Descending aorta CW Doppler, LV views	Baseline, low workload, peak exercise	Gradient increase LV contractility increase	Regrade severity LV contractile reserve
Univentricular hearts	Assessment of contractile reserve and haemodynamic consequences of exercise	Exercise	Ventricular views, colour flow Doppler to detect atrio-ventricular valve regurgitation, CW Doppler to measure gradients	Baseline, low workload, peak exercise	Contractility increase Other abnormalities	Contractile reserve Describe and grade

AR, aortic regurgitation; AV, aortic valve; CW, continuous wave; EF, ejection fraction; LV, left ventricle; LVOTO, LV outflow tract obstruction; MR, mitral regurgitation; MS, mitral stenosis; MV, mitral valve; PW, pulse wave; RV, RV; RWMA, regional wall motion abnormality; PPM, prosthesis–patient mismatch; SPAP, systolic pulmonary artery pressure; TAPSE, tricuspid annular systolic plane excursion; TR, tricuspid regurgitation.

^aCor pulmonale refers to the altered structure (e.g. hypertrophy or dilatation) and/or impaired function of the RV that results from pulmonary hypertension.

^be' often refers to averaged septal and lateral velocities, though either septal or lateral velocity can be used since the goal is to determine the change from rest to exercise.

experience that has accumulated with this form of stress testing (Supplementary data online 1). Commonly used treadmill protocols are the Bruce and modified Bruce protocols. The latter has two warmup stages, each lasting 3 min. The first is at 1.7 mph and a 0% grade, and the second is at 1.7 mph and a 5% grade.

Bicycle

Bicycle ergometer exercise echocardiography may be performed with the patient upright or on a special semi-recumbent bicycle, which may have left lateral tilt to facilitate apical imaging. The patient pedals against an increasing workload at a constant cadence (Figure 1). The workload is escalated in a stepwise fashion while imaging is performed. Successful bicycle stress testing requires the patient's cooperation to maintain the correct cadence and coordination to perform the pedalling action. Causes of test cessation and definition of abnormal stress test are listed in Figure 2.

Dobutamine

For detection of inotropic response in HF patients, stages of 5 min are used, starting from 5 up to 20 $\mu\text{g}/\text{kg}/\text{min}$ (Figure 3). To fully recruit the inotropic reserve in patients with HF and under β -blocker therapy, doses up to 40 $\mu\text{g}/\text{kg}/\text{min}$ may be required. Atropine coadministration is associated with higher rate of complications in those with a history of neuropsychiatric symptoms, reduced LV function, or small body habitus.⁹ In assessment of the patient with possible

severe aortic valve stenosis, the maximal dose is usually 20 $\mu\text{g}/\text{kg}/\text{min}$; higher doses are less safe and probably unnecessary. The dobutamine infusion is started as usual at 5 $\mu\text{g}/\text{kg}/\text{min}$ but titrated upward in steps of 2.5–5 $\mu\text{g}/\text{kg}/\text{min}$ every 5–8 min. After each increment in dobutamine dose, a period of 2–3 min before starting the image acquisition will allow the haemodynamic response to develop.

Vasodilators

Administration of dipyridamole (0.84 mg/kg over 6 min or the same dose over 10 min, or an initial dose of 0.56 mg/kg over 4 min sometimes followed by 4 min of no dose and additional 0.28 mg/kg over 2 min), adenosine (140 $\mu\text{g}/\text{kg}/\text{min}$ over 4–6 min to a maximum of 60 mg), or regadenoson (0.4 mg over 10 s) is performed without the administration of atropine.

Image acquisition

The echocardiographic imaging acquisition protocol of choice varies according to the objectives of the test and the stressor used (Tables 1 and 2). Several parameters can be assessed, including ventricular and valvular function, valvular and subvalvular gradients, regurgitant flows, left and right heart haemodynamics including systolic pulmonary artery pressure (SPAP), ventricular volumes, B-lines (also called ultrasound lung comets, a sign of extravascular lung water), and epicardial coronary flow reserve.

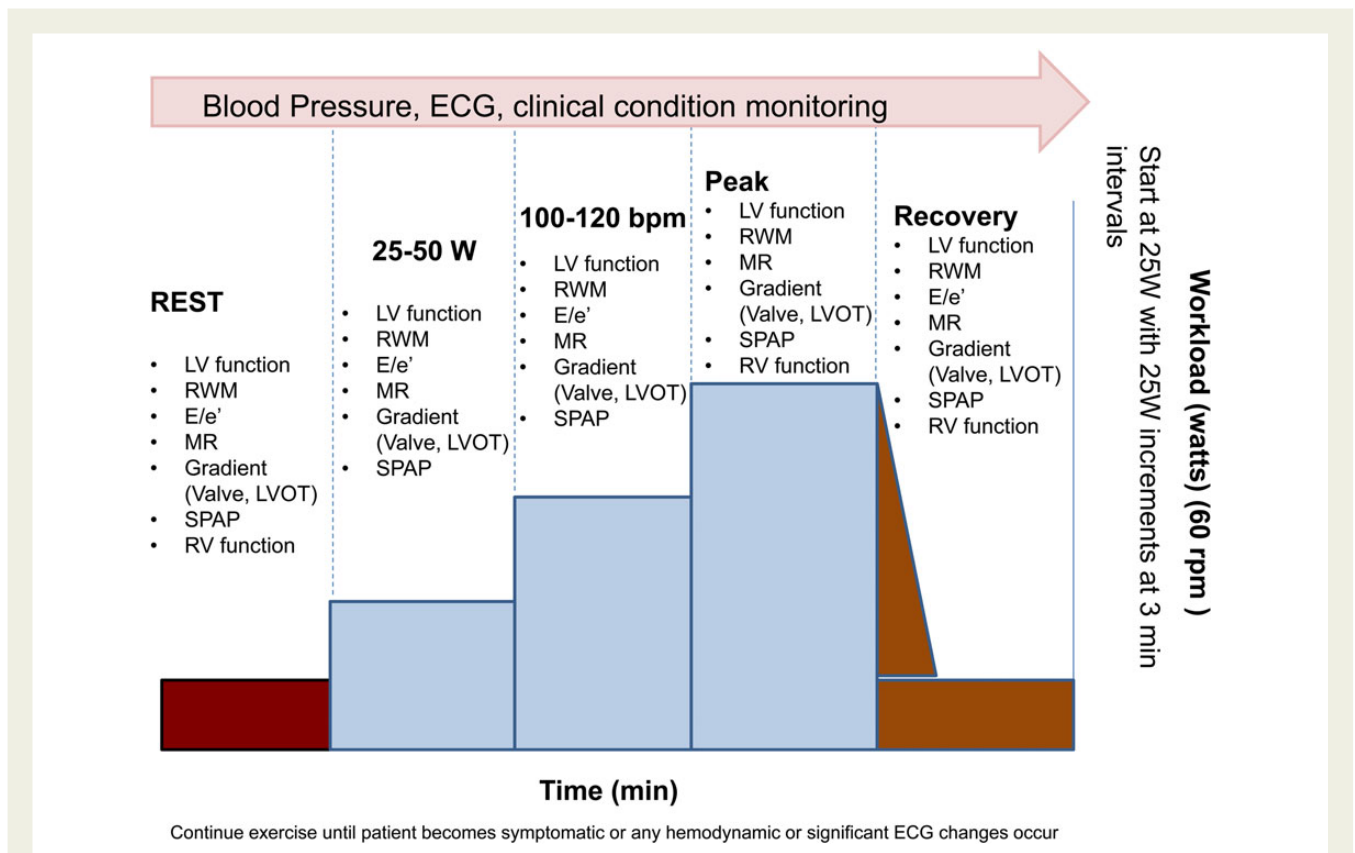


Figure 1 Exercise echocardiography protocol and parameters that can be assessed at each stage. bpm, beats per minute; LV, left ventricle; LVOT, LV outflow tract; MR, mitral regurgitation; E/e', ratio of early transmitral diastolic velocity to early TDI velocity of the mitral annulus; RWM, regional wall motion; RV, right ventricle; SPAP, systolic pulmonary artery pressure; W, watts; rpm, rotations per minute. Valve refers to aortic or mitral valve.

Diagnostic end-points	Causes of test cessation	Abnormal test (≥ 1 criteria)
<ul style="list-style-type: none"> • Max dose/Workload • Target heart rate • Obvious ECG positivity • Obvious Echo positivity • Severe chest pain 	<ul style="list-style-type: none"> • Intolerable symptoms • Muscular exhaustion • Hypertension (220/120 mmHg) • Symptomatic hypotension (>40 mmHg decrease) • Arrhythmias (SVT, AF, frequent or complex ventricular ectopy) 	<ul style="list-style-type: none"> • Symptoms: angina, dyspnea, dizziness, syncope or near-syncope, fatigue at low workload • Ischemia <ul style="list-style-type: none"> • ≥ 2 mm ST segment depression in comparison to baseline level • New or worsening RWMA • Arrhythmias (NS and SVT) • Specific targeted features*

Figure 2 Diagnostic end-points, causes of test cessation and definition of abnormal stress test. Asterisk indicates specific targeted features relates to cut-off values associated with poor outcome in defined population (i.e. >50 mmHg intraventricular obstruction). NS, non-sustained; SVT, sustained ventricular tachycardia.

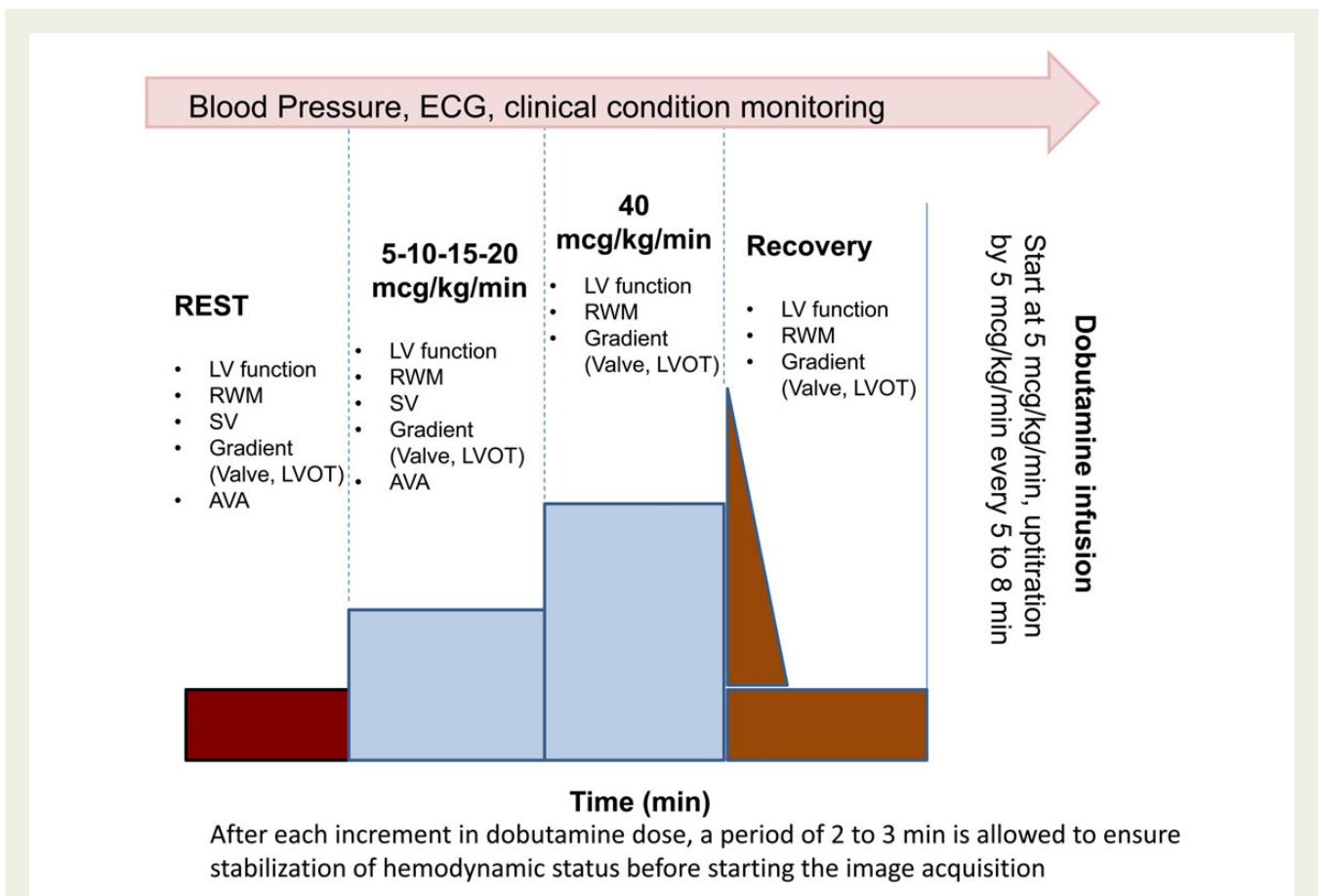


Figure 3 Dobutamine echocardiography protocol. A low-dose (up to 20 μ /kg/min) test is recommended in patients with low-flow, low-gradient aortic stenosis and reduced LVEF. In patients with heart failure that are receiving beta-blocker therapy, high doses up to 40 μ g/kg/min (without atropine) of dobutamine are often required. AVA, aortic valve area; LV, left ventricle; LVOT, LV outflow tract; RWM, regional wall motion; SV, stroke volume. Valve refers to aortic or mitral valve.

When either treadmill or upright bicycle exercise is performed, most protocols rely on post-exercise imaging, which is generally limited to apical, parasternal and/or subcostal views. It is imperative to complete post-exercise imaging as soon as possible since wall motion changes, valve gradients, and pulmonary haemodynamics

normalize quickly during recovery. To accomplish this, the patient is moved immediately from the treadmill to an imaging table and placed in the left lateral decubitus position so that imaging can be completed within 1–2 min. However, when the LVOT gradient is assessed in athletes or HCM patients, it may be more relevant to

Table 2 SE cut-off values associated with clinical significance, outcome or limited response to therapy

Parameters	Cut-off values
Intraventricular obstruction	• LVOT gradient >50 mmHg
Inadequate functional reserve	• Δ WMSI <0.25 in dilated cardiomyopathy (ESE, DSE)
	• Δ LVEF <7.5% in patients with biventricular pacing and heart failure (ESE, DSE)
	• Δ LVEF <4–5% in Primary MR, AR (ESE)
	• Δ global longitudinal strain <2% in Primary MR (ESE)
Inadequate flow reserve	• Δ stroke volume <20% (DSE)
Dynamic mitral regurgitation	• Δ EROA \geq 10–13 mm ² in MR patients (ESE)
Systolic pulmonary hypertension	• SPAP \geq 60 mmHg (ESE)
Limited valve compliance/fixed stenosis	• Mean transmitral gradient in MS <ul style="list-style-type: none"> • >15 mmHg (ESE) • >18 mmHg (DSE)
	• Mean transaortic gradient in AS <ul style="list-style-type: none"> • ΔMPG > 18–20 mmHg (ESE)
Prosthesis dysfunction or PPM	• Mean transmitral gradient in MV Prosthesis <ul style="list-style-type: none"> • >10 mmHg (ESE or DSE)
	• Mean transaortic gradient in AV Prosthesis <ul style="list-style-type: none"> • >20 mmHg (ESE or DSE)
Functional MS after mitral valve repair	• Δ mean transmitral gradient >7 mmHg
RV dysfunction	• TAPSE <19 mm in Primary MR (ESE)
Increase in B-lines	• >5 (28-region chest scan) (ESE)
Reduced coronary flow reserve (CFR)	• CFR <2.0 (VSE)

Δ , changes from rest to peak stress; AS, aortic stenosis; CFR, coronary flow reserve; DSE, dobutamine stress echocardiography; EROA, effective regurgitant orifice area; ESE, exercise stress echocardiography; LVOT, left ventricular outflow tract; MS, mitral stenosis; MR, mitral regurgitation; RV, right ventricle; SPAP, systolic pulmonary artery pressure; TAPSE, tricuspid annulus plane systolic excursion; VSE, vasodilator stress echocardiography.

obtain this measurement with the patient in the upright position, since cardiac symptoms in these patients are noted most commonly in this position, during or immediately after exercise.

The most important advantage of semi-supine bicycle exercise is the chance to obtain images during the various levels of exercise, rather than relying on post-exercise imaging. With the patient in the supine position, it is relatively easy to record images from multiple views during graded exercise. With upright bicycle ergometer testing, by having the patient lean forward over the handlebars or extend the arms, apical images can be obtained in the majority.^{1,2} During supine exercise echocardiography, imaging should thus be performed throughout the test, at peak exercise, and very early in the recovery phase.²

Interpretation of the test

The type of SE protocol used should always be included in the report. During both exercise and inotropic stress, a normal response involves the augmentation of function in all LV segments and increases in LVEF and cardiac output.^{1,2} The presence of a new or worsening wall motion abnormality identifies ischaemia while the improvement of regional wall motion by \geq 1 grade in dysfunctioning segments characterizes recruitable viable myocardium.¹⁶ Global contractile reserve in patients with no regional resting dysfunction is often defined as an increase by \geq 5% in LVEF while a flow reserve is defined as an increase in forward stroke volume by \geq 20%. Any change in cardiac function (improvement or worsening in wall motion, EF, or global longitudinal function as assessed by strain rate imaging), haemodynamic parameters (stroke volume, SPAP, E/e' , LV outflow tract (LVOT) gradients), severity of valvular disease (improvement or worsening of mitral regurgitation (MR), aortic valve area and pressure gradients) must be reported

according to the specific diagnostic question. Blood pressure and heart rate must also be reported to understand the relationship between contractile and haemodynamic responses. During vasodilator SE, the presence of viability and/or ischaemia and the degree of coronary flow reserve should be described.

Safety

SE is an extremely safe diagnostic tool in the evaluation of patients with suspected or known CAD.⁸ In patients with non-ischaemic heart disease, only limited or indirect data are available regarding the safety of the tests.^{8,17,18} Further studies and registries are needed to establish the safety of various stressors in these populations.

Key points

In the SE laboratory, a variety of parameters may be assessed: ventricular function, valvular gradients and regurgitant flows, left and right heart haemodynamics including pulmonary artery systolic pressure, and ventricular volumes. As it is not feasible to assess all possible parameters during stress, the variables of potential diagnostic interest should be prioritized for the individual patient based on the perceived importance of each. Physiology determines the choice of the stress and the key echocardiographic variables of interest. Exercise is the test of choice for most applications. Bicycle ergometer stress testing is optimal for obtaining Doppler data during exercise, but patient endurance is generally less than with treadmill exercise unless the patient has trained cycling muscles. Dobutamine is the preferred alternative modality for the evaluation of contractile reserve (as in dilated cardiomyopathy or aortic valve stenosis with LV dysfunction). Vasodilation is the preferred modality for the evaluation of coronary flow reserve, which can provide prognostically relevant information in cardiomyopathies.

Diastolic stress echocardiography

The importance of diastolic dysfunction for symptoms such as shortness of breath, exertional fatigue, or poor exercise capacity has been increasingly recognized, and diastolic dysfunction is considered to be the main cause in ~40% of patients presenting with clinical HF.^{19,20}

Diastolic SE generally refers to the use of exercise Doppler echocardiography to detect impaired LV diastolic function reserve and the resulting increase in LV filling pressures^{21–23} in patients with unexplained dyspnoea or subclinical diastolic dysfunction (e.g. diabetic cardiomyopathy, hypertensive patients). Nonetheless, it is mainly of value in patients with suspected HF with preserved LVEF and borderline diastolic abnormalities at rest. *Figure 4* summarizes when diastolic SE should be considered in clinical practice. *Figures 5* and *6* show examples of diastolic stress results.

Exercise using a supine bicycle is the recommended modality for diastolic SE as it allows the acquisition of Doppler recordings throughout the test and the non-invasive assessment of exercise diastolic function reserve. Treadmill exercise SE is an alternative as diastolic abnormalities may persist after exercise. Preload augmentation by passive leg raise might also represent a non-exercise alternative since it provides additional information identifying patients with exercise-induced LV filling pressure elevation and lower exercise capacity.

A diastolic SE protocol can be used as a stand-alone test or it can be added to the assessment of regional wall motion abnormalities. Mitral E, A, E/A (1–2 mm sample volume pulsed wave Doppler

placed at the tip of mitral valve), e' (5- to 10-mm sample volume pulsed wave tissue Doppler, septal and/or lateral mitral annulus, Nyquist limit at 15–20 cm/s with adjustment of gain and filter), E/e' , and SPAP should be recorded at baseline, at low-level exercise, and during the recovery period. The variables E and e' are usually recorded at 100–110 bpm, when E and A waves are not yet fused. Although less evidence is available, post-exercise assessment during the recovery period can be performed, especially when there has been an abrupt increase in heart rate with low level of exercise.¹⁹ Recordings are obtained using the apical four-chamber view and a total of 5–10 cardiac cycles should be recorded. For the patient unable to exercise, diastolic function can be assessed during passive leg raise. The patient's legs are passively elevated for 3 min,²⁴ and similar Doppler-echocardiographic parameters are recorded. The limitations of E/e' as non-invasive estimates of LV filling pressures as assessed by resting echocardiography are also applicable for diastolic SE.

Interpretation and haemodynamic correlation

In middle-aged healthy subjects, the E/e' ratio does not change significantly with exercise because of proportional increases in both the mitral inflow and annular velocities^{25–28}; this represents the normal diastolic response for exercising subjects. Conversely, an increase in the E/e' ratio and/or SPAP with exercise has been shown to parallel increases in the LV end-diastolic pressure as recorded by invasive measurements.²²

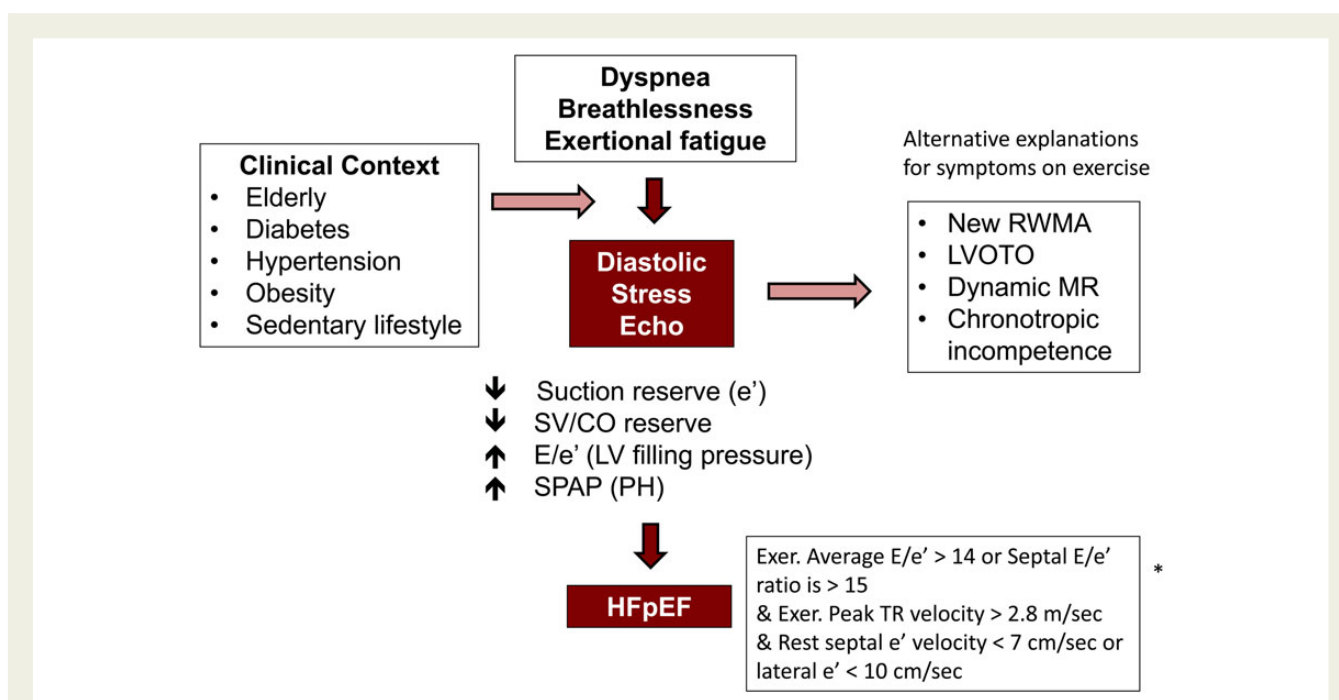


Figure 4 Diastolic SE performed for the assessment of dyspnoea, breathlessness, or exertional fatigue. Asterik indicates criteria used to diagnose heart failure with preserved LV EF. CO, cardiac output; Exer, exercise; LVOTO, LV outflow tract obstruction; MR, mitral regurgitation; RWMA, regional wall motion abnormality; SV, stroke volume; E , early transmitral diastolic velocity; e' , early TDI velocity of the mitral annulus; SPAP, systolic pulmonary artery pressure; PH, pulmonary hypertension; TR, tricuspid regurgitation; HFpEF, heart failure with preserved LVEF.

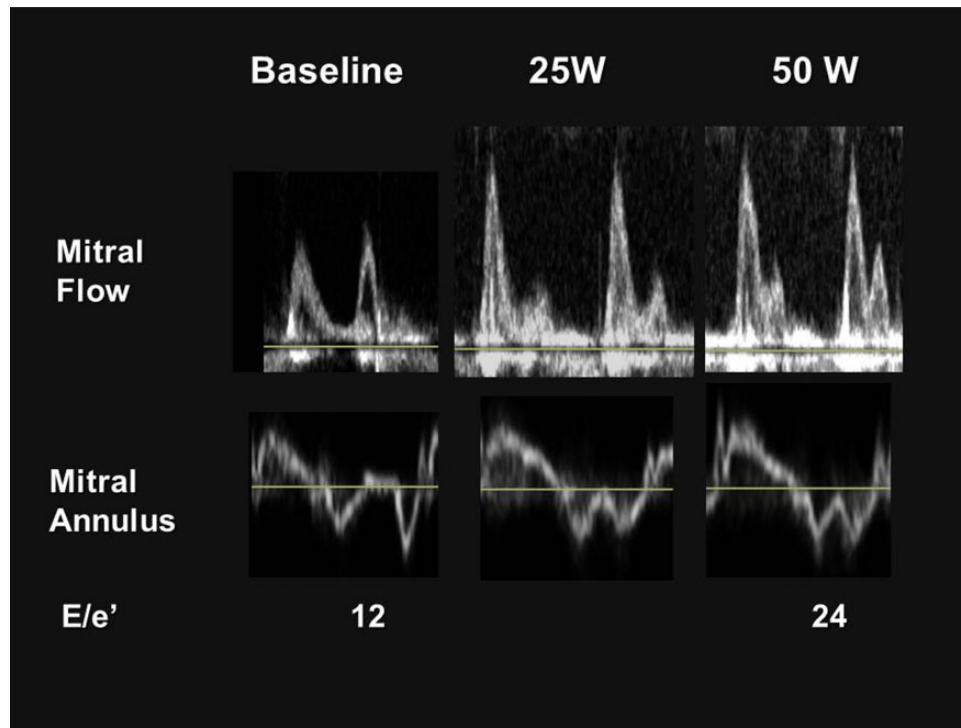


Figure 5 Mitral flow and annular velocity at rest, during supine bicycle exercise and recovery in a 71-year-old man with exertional dyspnoea. At baseline, mitral inflow pattern revealed abnormal relaxation with normal range of E/e' .¹² However, mitral inflow pattern dramatically changed after 5 min of supine bicycle exercise from normal to restrictive physiology with significantly elevated E/e' . The variable e' refers to septal velocities.

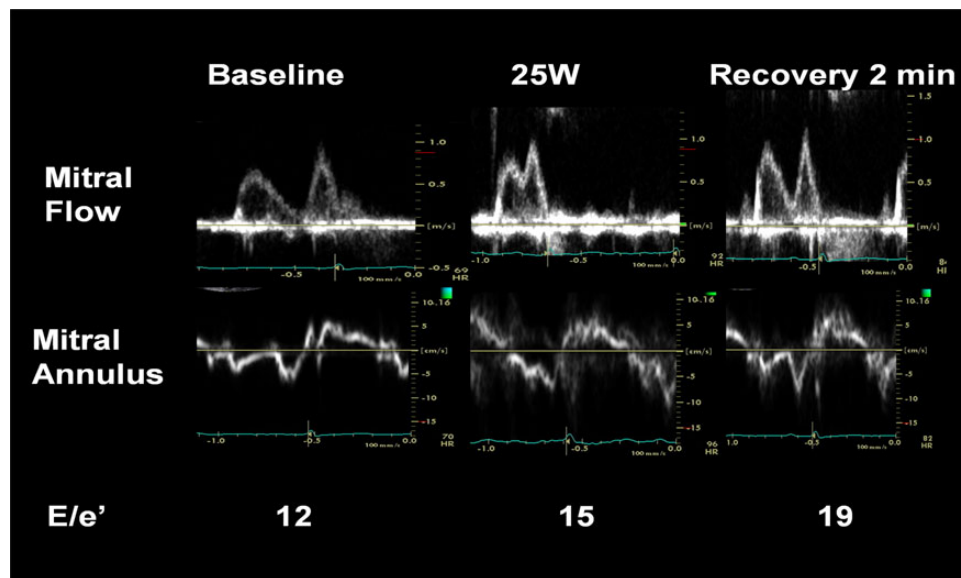


Figure 6 Mitral flow and annular velocity at rest, during supine bicycle exercise, and in recovery in a 56-year-old woman with hypertension and exertional dyspnoea. Because of tachycardia even with mild exercise, E/e' could not be measured at 50 W of exercise. Note that E/e' was significantly elevated even after cessation of exercise and was higher than at rest and during exercise.

A diastolic exercise SE is definitively normal if the septal E/e' is <10 at rest and with exercise, and the peak tricuspid regurgitation (TR) velocity is <2.8 m/s at rest and with stress.²⁹ A study is abnormal

when the average E/e' ratio is >14 , and the septal e' velocity is <7 cm/s at baseline.^{21,22,25–28} Peak TR velocity >3.1 m/s with exercise usually indicates an abnormal response, but aerobically trained

athletes can normally generate higher pressures.³⁰ Additionally, SPAP at rest and with exercise increases with advancing age.²⁷ Thus, the workload achieved as well as the patient's age must be taken into consideration. Systolic pulmonary artery pressure measurement with exercise has been found to be helpful in aiding the assessment of diastolic filling pressure with exercise.^{27,28} It has been shown that the upper normal SPAP is <35 mmHg at rest and <43 mmHg at exercise.³¹ Exercise E/e' > 13, lower amplitude of changes in diastolic longitudinal velocities, and induced PH (SPAP \geq 50 mmHg) are markers of adverse outcomes.^{28–33}

Passive leg raise can induce heterogeneous changes in mitral inflow and mitral annular velocities in patients with abnormal relaxation.²⁴ Patients with relaxation abnormality and $E/e' < 15$ at rest but increased $E/e' > 15$ during leg raise, defined as 'unstable' relaxation abnormality, were older, more often female, and had lower diastolic reserve and exercise capacity when compared with patients with persistent $E/e' < 15$. In addition, e' response to passive leg raise was significantly correlated with diastolic reserve indexes during exercise.²⁴

Since e' velocity is inversely correlated with the time constant of isovolumic relaxation (τ)^{1–3} and administration of dobutamine enhanced LV relaxation and early diastolic recoil, an increase in e' velocity during dobutamine SE could be an indicator of impaired myocardial longitudinal diastolic contractile reserve.³⁴ Of note, persistent restrictive LV filling pattern during dobutamine SE is associated with poorer long-term outcome in patients with ischaemic cardiomyopathy.³⁵

Impact on treatment

The diagnosis of impaired diastolic reserve in conjunction with increased E/e' with exercise, an estimate of LV filling pressure, in

patients with suspected HF with preserved LVEF may be beneficial in guiding therapy or monitoring the effect of treatment.

Key points

Exercise-induced changes in E/e' allow recognition of impaired LV diastolic function reserve and the resulting increase in LV filling pressures during exercise in patients with dyspnoea and suspected heart failure with preserved LVEF. Exercise Doppler echocardiography is helpful in the assessment of the symptomatic patient with normal or equivocal diastolic function during resting images.

Hypertrophic cardiomyopathy

Hypertrophic cardiomyopathy is a heterogeneous inherited cardiomyopathy with variable phenotypic expression. Although some patients are asymptomatic, others have HF, and some present with sudden death.³⁶ Disease progression is often due to diastolic dysfunction, MR, and LVOT obstruction (LVOTO).³⁷

Exercise SE is safe and commonly used to assess inducible LVOTO, especially in patients with equivocal symptoms, to determine functional capacity prior to a corrective therapeutic procedure, and for individual risk stratification³⁸ (Figure 7). In the ESC guidelines, exercise echocardiography is recommended in symptomatic patients if bedside manoeuvres fail to induce LVOTO \geq 50 mmHg and is rated as class IIa, level of evidence B in the ACC/AHA guidelines.³⁷ Post-prandial gradients are higher than those performed in

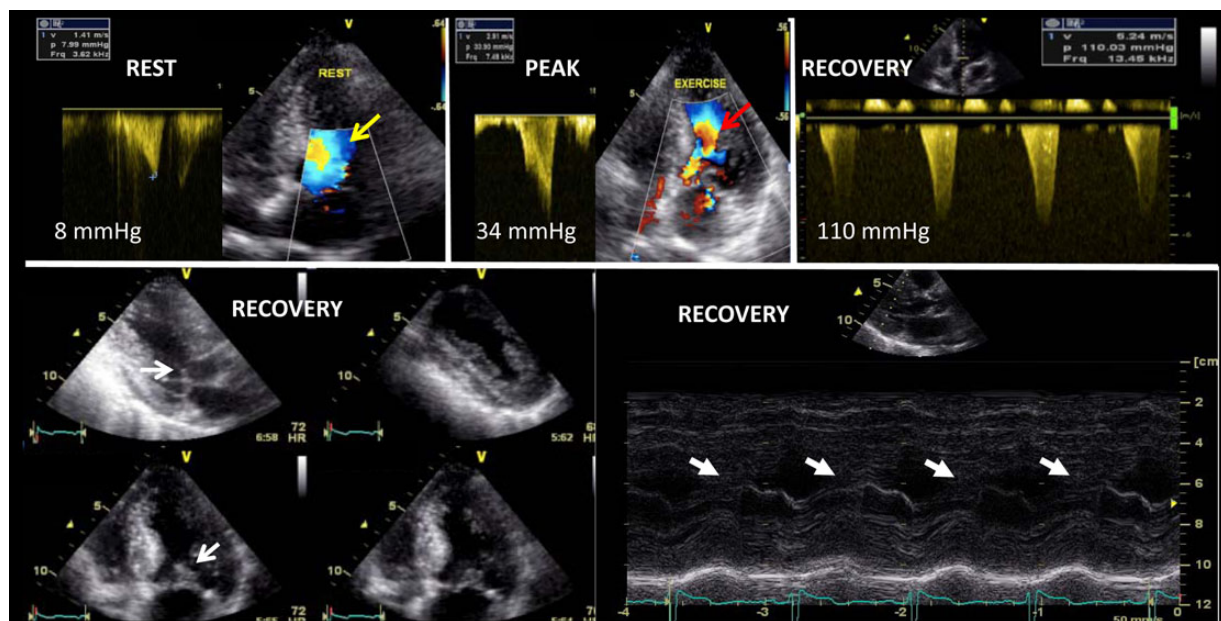


Figure 7 Example of dynamic intraventricular obstruction during exercise echocardiography in a dyspneic patient with HCM. *Top*: Increase in left ventricular outflow tract velocity and gradient associated with a marked flow acceleration (red arrow) (note the laminar flow at rest (yellow arrow)). Note the greater increase in intraventricular gradient after exercise due to the decrease in venous return. *Bottom*: Systolic anterior motion of the mitral valve identified on 2D (left) and M-mode (right) echocardiography (white arrows).

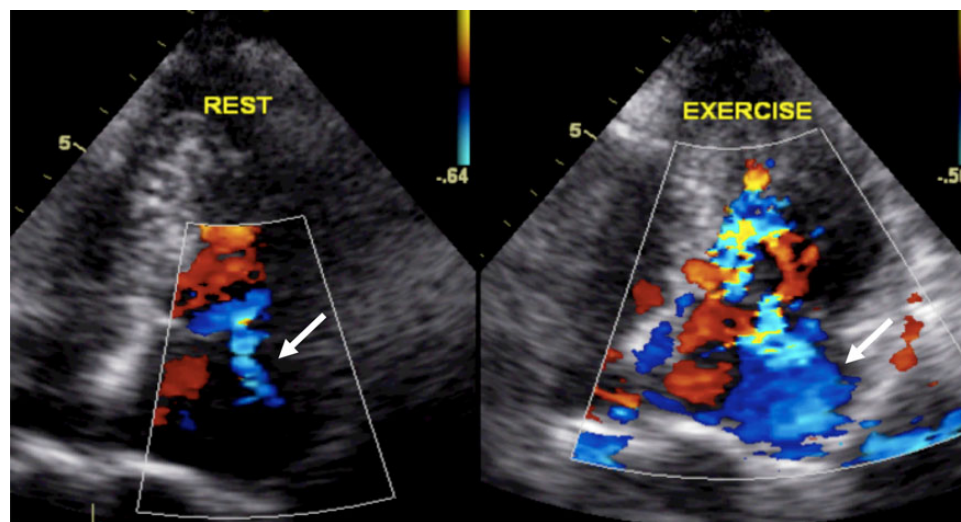


Figure 8 Significant increase in mitral regurgitation during exercise echocardiography (mild at rest and severe at exercise) in a patient with HCM.

the fasting state and pre-treatment with β -blockers is known to reduce the incidence and severity of exercise-induced LVOTO.³⁹

Approximately one-third of patients have resting systolic anterior motion of the mitral valve leaflets that results in LVOTO, while another third have latent obstruction unmasked only during manoeuvres that change loading conditions (standing, Valsalva, nitrates, exercise) and LV contractility.^{40–43} Of note, pharmacological provocation with dobutamine is not recommended, as it is not physiological, can be poorly tolerated, and can induce LVOTO even in normal subjects.⁴⁴ However, dobutamine or isoproterenol is used routinely in the operating room both pre- and post bypass to evaluate septal contact of the mitral valve leaflets and to guide the extent of the myectomy and surgical management of the mitral valve, which may require plication. Often, amyl nitrite may not reproduce exercise-induced gradients.⁴⁵

Exercise Doppler echocardiography can be performed in a standing, sitting, or semi-supine position. The echocardiographic parameters are assessed during exercise and at the beginning of the recovery period, when preload decreases. In patients with equivocal symptoms, if exercise SE does not produce LVOTO gradients, assessment for post-exercise standing gradients should be considered. An upright position after exercise causes a greater decrease in preload. Assessment of post-prandial exercise standing gradient may also be considered.^{14,46} In patients already under β -blockers, treatment should not be withdrawn prior to exercise SE.

The following parameters can be evaluated during the test, especially during semi-supine exercise: blood pressure, symptoms, heart rate, electrocardiographic changes, LVOTO, LV systolic/diastolic (E/e') function, MR, and SPAP (Figures 8–10). Post-exercise testing mainly focuses on LVOTO induction, SPAP, and diastolic parameters. Effort should be made to distinguish the subvalvular gradient from the MR jet. A limited exercise capacity, an abnormal blood pressure response (hypotensive or blunted response), significant ST-depression, inducible wall motion abnormalities, blunted

coronary flow reserve (dipyridamole test),¹² exercise LVOTO (>50 mmHg), and blunted systolic function reserve are all parameters of worse prognosis.^{37,38,47–49} Dynamic increase in MR, often in relation to systolic anterior motion of the mitral valve, blunted changes in e' (no diastolic reserve), increase in E/e' , and PH at exercise are all markers of poor exercise tolerance.^{50,51} 2D strain imaging of LV function can be accurately performed at 100–120 bpm^{52–54} and is more sensitive to identify subtle changes in intrinsic myocardial function. A blunted increase in global longitudinal strain (limited contractile reserve) favours diagnosis of HCM rather than athletes' heart.⁵⁵ Intriguingly, some patients can display a paradoxical decrease in LVOTO during exercise, which is associated with a more favourable outcome and suggests alternative reasons for dyspnoea.⁵⁶

Impact on treatment

Identification of LVOTO (haemodynamically significant if ≥ 50 mmHg) is important in the management of symptoms and assessment of individual risk. Resting LVOTO carries a moderate increase in overall mortality and risk of sudden cardiac death in patients with HCM. Surgical myectomy with or without mitral valve surgery or alcohol septal ablation may be indicated in symptomatic patients with haemodynamically significant LVOTO despite optimal medical treatment.^{36,57} Exercise SE also allows monitoring of the efficacy of β -blocker therapy.

Key points

Exercise SE is an important and useful tool for evaluation of symptoms and monitoring the response to therapy in patients with HCM. Dynamic LVOTO (>50 mmHg) can be easily assessed. Abnormal blood pressure response to exercise, blunted contractile (systolic) and diastolic reserve, and worsened MR are associated with poor exercise capacity and outcome. SE is not indicated when a gradient >50 mmHg is present at rest or with Valsalva manoeuvre.

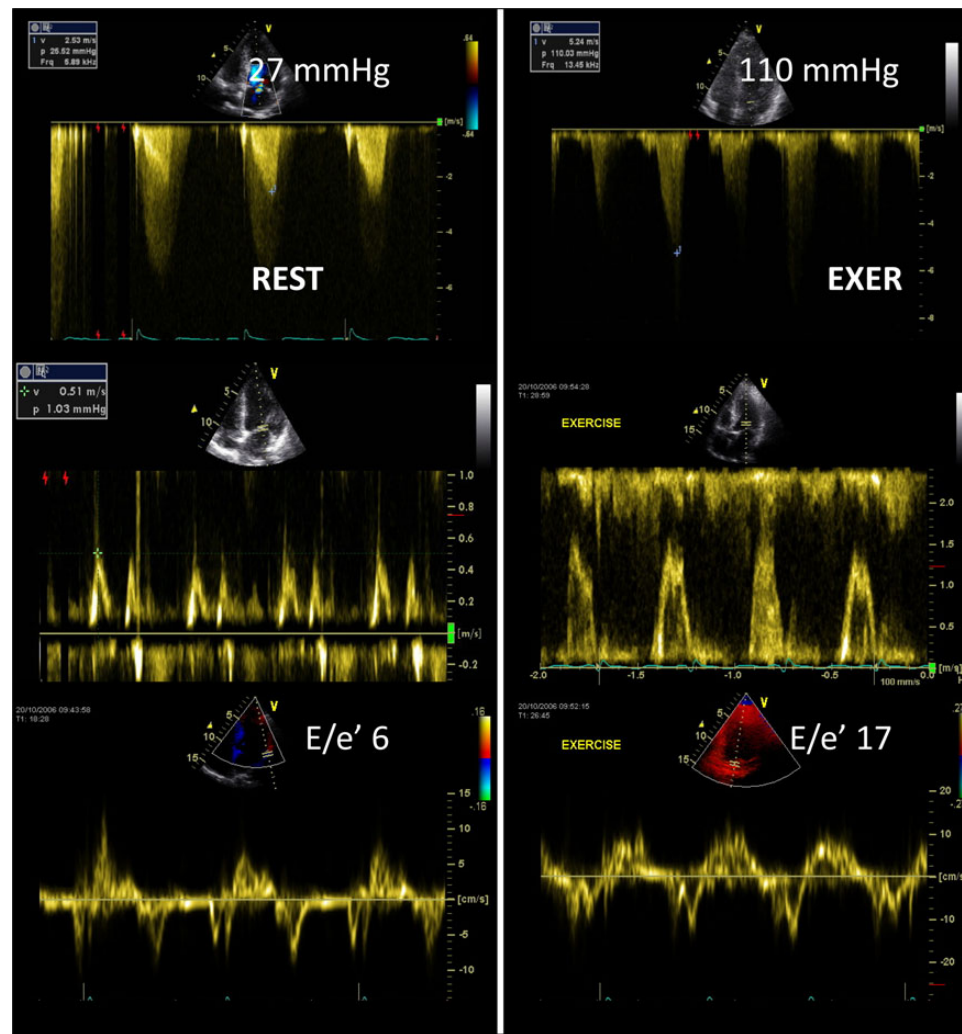


Figure 9 Dyspneic patient with HCM, increased dynamic intraventricular obstruction (top) and left ventricular filling pressure (bottom, E/e') during exercise echocardiography.

Heart failure with depressed LV systolic function and non-ischaemic cardiomyopathy

Non-ischaemic cardiomyopathy is relatively common in patients presenting with HF and is associated with a high mortality rate.⁵⁸ In these patients, increased circulating catecholamines are accompanied by a decreased density and downregulation of β -receptors, which is associated with poor response to β adrenergic blocking agents and worse outcomes.⁵⁹ Studies have shown that myocardial contractile response to exogenous catecholamines has important prognostic implications.⁶⁰

In early stages of heart failure, when resting LVEF is still preserved, a blunted contractile reserve can identify incipient, pre-clinical myocardial damage. Such a response may be used in detection of early chemotherapy-induced cardiotoxicity, thalassemia, and hypertensive and diabetic cardiomyopathy.^{61–65} In the overt stage of non-ischaemic

cardiomyopathy, residual myocardial contractile reserve as assessed by SE can assist to distinguish ischaemic from non-ischaemic disease, for outcome assessment, and aid to clinical decision making.⁶⁶

Although dobutamine SE is most often used, exercise SE can also be performed. Several protocols including low-dose (10 $\mu\text{g}/\text{kg}/\text{min}$) to high-dose (40 $\mu\text{g}/\text{kg}/\text{min}$) dobutamine SE have been used to evaluate contractile reserve, changes in LV volumes and EF. There is, however, no consensus on the optimal dobutamine protocol to evaluate patients with non-ischaemic cardiomyopathy. One of the advantages of high-dose compared with low-dose dobutamine in this cohort of patients is that the high dose is more likely to invoke a contractile response especially if the patients are on β -blockers, thus decreasing the chances of a false-negative finding. However, high-dose dobutamine is more likely to cause significant arrhythmias.^{67,68}

Alternatively, exercise SE protocols may be used, sometimes with longer stages to permit acquisition of more data at each stage, including systolic and diastolic reserve, SPAP, dynamic MR, or B-lines (Figure 11). B-lines or lung comets are discrete, laser-like, vertical,

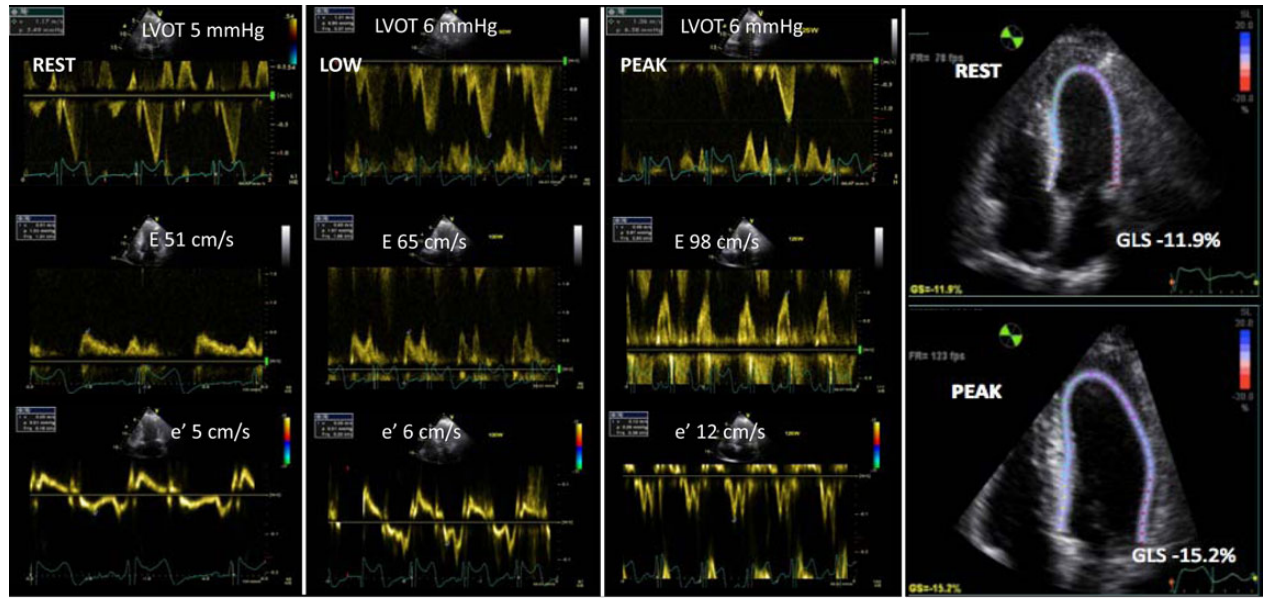


Figure 10 Breathless patient with HCM and chronic obstructive pulmonary disease. Exercise echocardiography reveals the presence of systolic (increase in global longitudinal strain [GLS]) and diastolic (increase in e') reserve without significant increase in E/e' (left ventricular filling pressure). These data suggest that the symptoms are mainly due to the pulmonary disease.

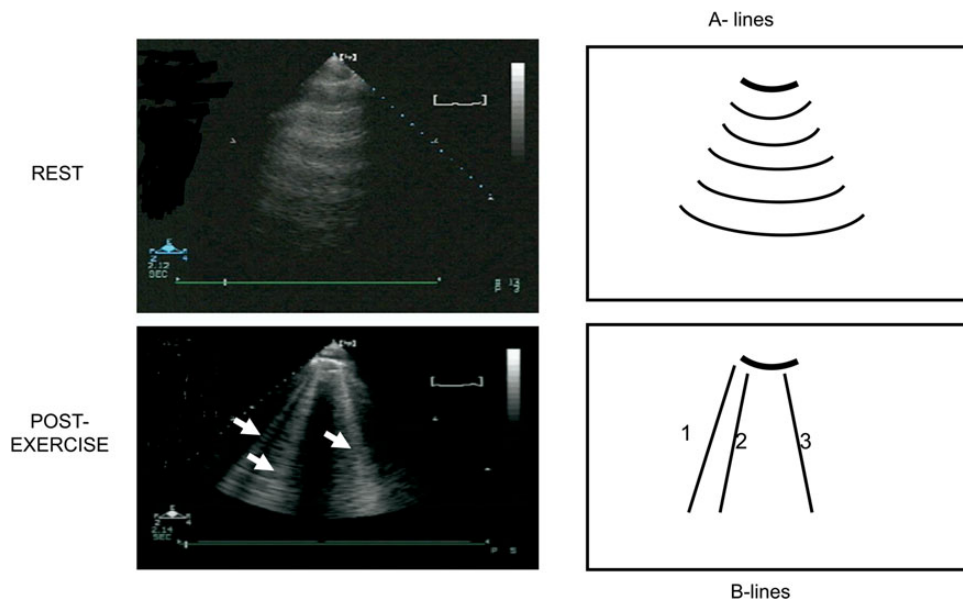


Figure 11 Lung ultrasound (third right intercostal space) at rest (left upper panel) and immediately after exercise (left lower panel). On the right panels, the schematic drawing showing normal, parallel, horizontal A-lines at rest (right upper panel), and three vertical B-lines (arrows) departing from the pleural line after exercise (right lower panel). The exercise-induced appearance of B-lines (also called ultrasound lung comets, ULC) reflects the acute increase of extravascular lung water. ULC presence is frequently associated with elevated PCWP and/or reduced EF.

hyperechoic images that arise from the pleural line, extend to the bottom of the screen without fading, and move synchronously with respiration.

..... Dipyridamole SE is rarely used to assess contractile reserve, but
 may be useful in patients on β -blockers, and is associated with less
 arrhythmias.⁶⁸

In patients with either preserved or reduced LVEF, the absence of contractile reserve is often associated with limited coronary flow reserve.^{69,70} It is a marker of latent LV systolic dysfunction and sub-clinical cardiomyopathy.

In dilated non-ischaemic cardiomyopathy, patients with significant improvement in their wall motion score index and LVEF during dobutamine infusion have a better survival rate, fewer hospitalizations for HF,⁷¹ and an increase in the LVEF during follow-up.⁷² Alternatively, dobutamine SE can be used in patients with HF with ambulation difficulties.⁷³ Patients with inotropic contractile reserve respond better to β -blockers.^{73,74} The presence of inotropic contractile reserve was also associated with a decrease in the need for cardiac transplantation^{75,76} and correlates inversely with the extent of interstitial fibrosis and scarred myocardium.⁷⁷ These findings have also been extended in specific aetiology of cardiomyopathy, including in peripartum and in HIV cardiomyopathy, where the presence of inotropic contractile reserve correlates with subsequent recovery of LV function at follow-up and also better outcomes.⁷⁸ When the purpose of the dobutamine SE is to seek for LV contractile reserve and not myocardial ischaemia, atropine is not administered. In patients with non-ischaemic cardiomyopathy, blunted coronary flow reserve or the absence of contractile reserve during dipyridamole test is also a marker of poor prognosis.^{79,80}

In both patients with preserved or reduced LVEF, the presence and the amount of B-lines (lung comets) likely correlate with the estimated LV filling pressure and the presence of pulmonary interstitial edema.^{81–83} The demonstration of B-lines during exercise SE seems a feasible way for demonstrating that exertional dyspnoea is related to pulmonary congestion.⁸⁴

Differentiating non-ischaemic from ischaemic cardiomyopathy

Differentiating non-ischaemic from ischaemic cardiomyopathy may be challenging since patients with non-ischaemic cardiomyopathy may have frequent episodes of chest pain and electrocardiographic evidence of myocardial infarction. Moreover, the distinction between ischaemic and non-ischaemic cardiomyopathy with SE may be impossible in patients presenting with severely dilated LV with very low EF and extensive and severe wall motion abnormalities. It should be emphasized that in such patients, only coronary angiography may be able to make the distinction between ischaemic and non-ischaemic aetiology. However, it has been shown using SE that patients with ischaemic cardiomyopathy are more likely to display >6 akinetic segments at peak dobutamine test, less improvement in regional wall motion at low-dose dobutamine, and more frequently a biphasic response (improvement at low-dose followed by subsequent deterioration at peak dose).^{85,86} In a study using stress long-axis function (long-axis M-mode and pulse wave tissue Doppler of the lateral, septal, and posterior walls), ischaemic cardiomyopathy was identified with greater sensitivity and specificity than with standard wall motion score index, particularly in the presence of a left bundle branch block.⁸⁷

Cardiac resynchronization therapy

Several studies^{88–97} have shown a direct relationship between the presence of inotropic contractile reserve as assessed by low-dose

dobutamine SE and improvement in ventricular function after cardiac resynchronization therapy. During dobutamine infusion, an increase of LVEF by $\geq 7.5\%$ identified responders to cardiac resynchronization therapy.⁸⁸ Furthermore, patients are more likely to be non-responders to cardiac resynchronization therapy if the LV pacing lead is placed in the region of no contractile reserve (scarred myocardium).⁹⁶ The presence of inotropic contractile reserve during dobutamine SE also has incremental but lower predictive power than echocardiographic mechanical dyssynchrony parameters such as septal flash (Figure 12).^{97–101} The degree of response (improvement of EF during dobutamine infusion) correlates directly with the number of segments demonstrating inotropic contractile reserve.^{96,97}

Response to therapy

β -Blockers are an important treatment option for patients with HF.^{78,102} Data on the role of dobutamine SE for identifying responders to β -blocker therapy in HF patients are emerging.^{103,104} These studies have consistently shown that patients with inotropic contractile reserve not only tend to have improvement in global LV function and EF but also respond better to β -blockers. Hence, in patients with inotropic contractile reserve, β -blocker therapy results in improvement in both regional and global LV function compared with patients without inotropic contractile reserve.^{103,104} The improvement in regional and global LV functions is more pronounced in patients with non-ischaemic compared with ischaemic cardiomyopathy. Thus, in patients with non-ischaemic cardiomyopathy the presence of inotropic contractile reserve can predict who will respond to β -blocker therapy.

Key points

In patients with heart failure, SE is useful to identify the cause of dyspnoea and clinical deterioration and for individual risk stratification. SE also appears promising for guiding and monitoring response to treatment. The absence of contractile reserve is a strong determinant of outcome and a potential marker of response to cardiac resynchronization therapy.

Native valve disease

The clinical indications for SE in native valve disease can be classified into three categories: severe valve disease without symptoms, non-severe valve disease with symptoms, and valve disease with low flow.^{105–107} In all cases, the purpose of the test is to identify the patients in need of intervention, namely those patients with severe valve disease and symptoms, LV systolic dysfunction, or other haemodynamic consequences (Figure 13).^{108,109} Therefore, in severe valve disease without symptoms the main aim of the test is to elicit symptoms, which may not be otherwise appreciated because of sedentary lifestyle. Additionally, the haemodynamic consequences of exertion in the patient with severe valve disease, such as exercise-induced hypotension or arrhythmia, may be uncovered. In non-severe valve disease with symptoms, the main aim of the test is to question whether the valve disease is actually severe, re-grading

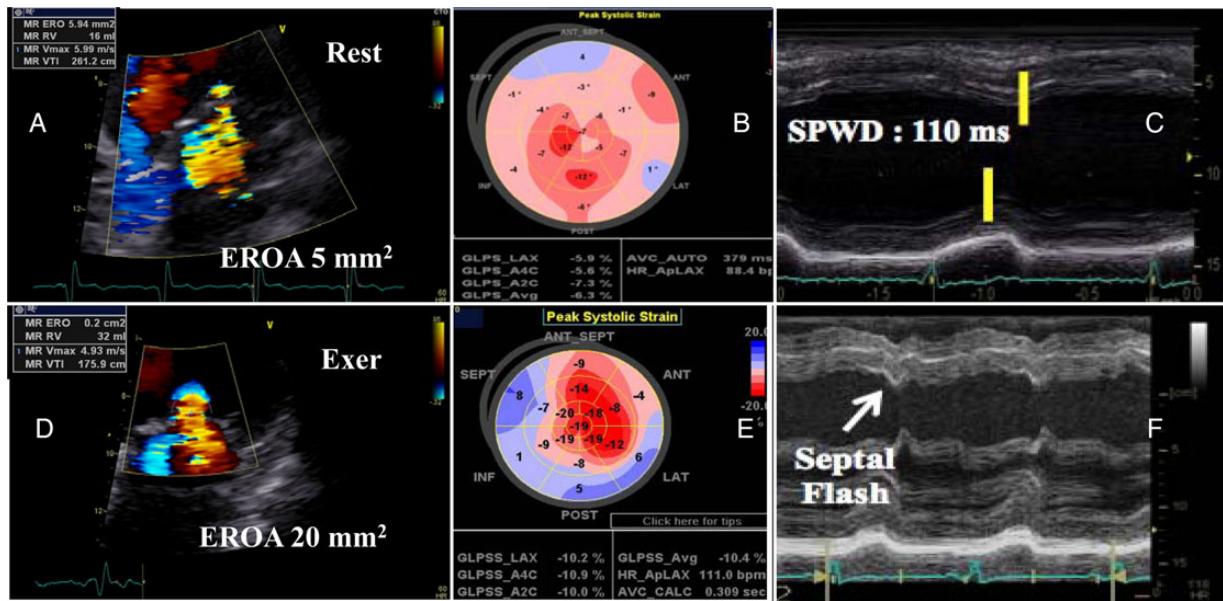


Figure 12 Patient with idiopathic cardiomyopathy and limited exercise capacity. (A–C) Rest evaluation; (D–F) exercise echocardiography results. From rest to exercise, there is an increase in mitral regurgitation severity (A and E) and in left ventricular dyssynchrony (B–F). (A and D) increase in effective regurgitant orifice area (EROA) during test. (B and F) Bulls-eye figures of longitudinal peak systolic strain values in the LV. From rest to exercise, global strain increases (–6.3% to –10.4%) indicating the presence of contractile reserve. During exercise, there is a significant dyssynchrony between the infero-lateral wall and the anteroseptum wall (regional strain color-coded changes from orange to blue). (C and F) M-Mode echocardiogram showing the occurrence of a septal flash (rapid inward motion of the septum within the isovolumic contraction period) at exercise. SPWD, septal posterior wall motion delay.

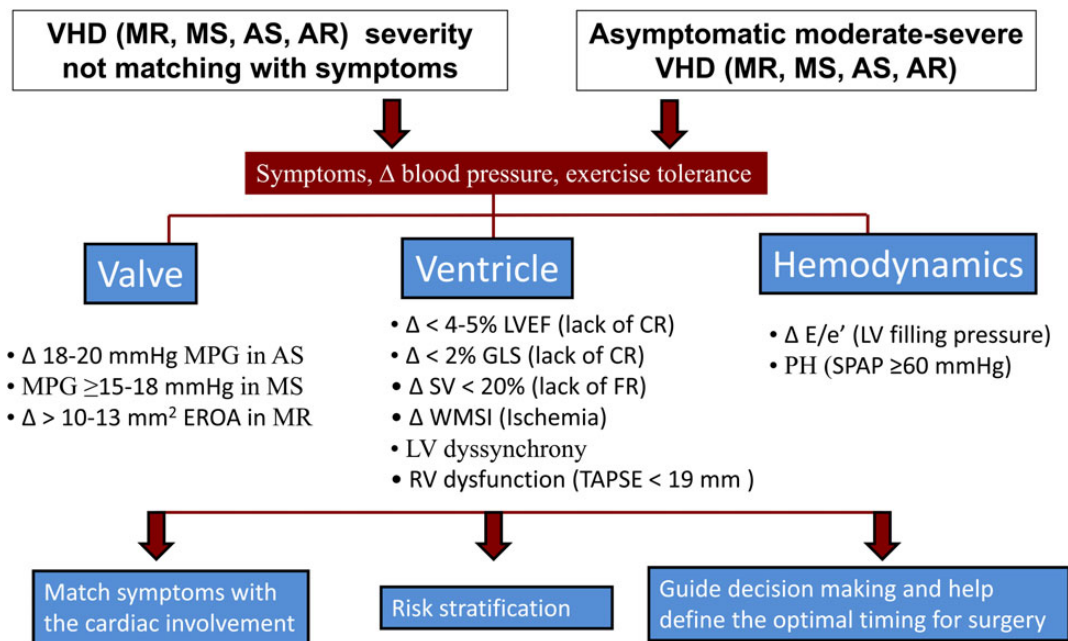


Figure 13 Usefulness of exercise SE in patients with valvular heart disease (VHD). The three components of VHD consequences are examined allowing individual risk stratification. Δ, changes from rest to peak exercise (*from rest to peak dobutamine); AR, aortic regurgitation; AS, aortic stenosis; EROA, Effective regurgitant orifice area; FR, flow reserve; GLS, global longitudinal strain; LVEF, left ventricular ejection fraction; MPG, mean pressure gradient; MR, mitral regurgitation; MS, mitral stenosis; RV, right ventricle; PH, systolic pulmonary hypertension; SPAP, systolic pulmonary artery pressure; SV, stroke volume; TAPSE, tricuspid annulus plane systolic excursion; WMSI, wall motion score index.

the severity based on stress-induced changes or a potential dynamic component. In valve disease with low flow, the aim of the test is to determine whether the valve disease is severe based on flow-dependent changes in severity parameters with stress.¹¹⁰

Mitral regurgitation

The severity of MR can have a dynamic nature, being load dependent or increasing with exercise.¹¹¹ Increase in severity during exertion has been reported regardless of etiology.^{112–116} Images should be acquired at baseline and immediately post-exercise when using a treadmill, and at baseline, low workload, and peak exercise when using a supine bicycle. Dobutamine should not be used instead of exercise to assess the dynamic behaviour of MR because its effects on MR severity are not physiologic. One exception to this is when inducible ischaemia is suspected in a patient who cannot complete an exercise test, as ischaemia may be the mechanism of MR.¹⁰⁵

Primary MR

In patients with primary MR, exercise echocardiography may provoke symptoms and be useful to assess the SPAP response and stratify risk.^{108,109} Although there is less evidence, the test is also reasonable in symptomatic patients with at least moderate MR. The increase in MR severity (≥ 1 grade),^{117,118} dynamic PH (SPAP ≥ 60 mmHg),^{119–123} the absence of contractile reserve ($< 5\%$ increase in EF or $< 2\%$ increment in global longitudinal strain) (Figure 14),^{124–129} and a limited RV contractile recruitment (quantified by tricuspid annular plane systolic excursion (TAPSE) < 19 mm)¹²³ are all parameters of poor prognosis. The lack of contractile reserve predicts decrease in LVEF and symptoms at follow-up in medically managed patients; it also predicts post-operative LV systolic dysfunction in surgically treated patients.^{124–129}

When MR is not severe at rest, the dataset should include colour flow Doppler (to allow off-line quantification of severity by PISA

method and vena contracta of the regurgitant jet), MR CW Doppler for quantification of severity by PISA method, TR CW Doppler for estimation of the SPAP, and LV views for global and regional systolic function assessment.^{107,112} Image acquisition should be performed in this order as MR severity and SPAP may decrease immediately on termination of the test. The assessment of MR severity parameters becomes more difficult at heart rates > 115 bpm.¹¹² It is important to scan for TR jet velocity by CW Doppler ideally early during exercise since early increase in SPAP is a marker for more significant disease.

When MR is severe at rest, there is no need to assess MR severity during stress.¹⁰⁷ Image acquisition should focus on SPAP and LV contractile reserve.

Secondary MR

SE may provide helpful information in patients with the following symptoms and circumstances: shortness of breath on exertion disproportionate to LV systolic dysfunction or MR severity at rest^{108,109}; recurrent and unexplained acute pulmonary edema¹⁰⁸; intermediate severity of MR who are scheduled for coronary artery bypass grafting¹⁰⁸ (to identify those who may benefit from combined revascularization and mitral valve repair), for individual risk stratification, or persistent PH after mitral valve repair.¹²⁰ Increase in MR severity (increase in ERO ≥ 13 mm²) (Figure 12)^{130–134} and dynamic PH (SPAP ≥ 60 mmHg)¹³⁵ are predictors of worse prognosis. Conversely, a decrease in MR severity, often related to recruited LV basal contractile reserve, is a marker of better outcome with medical treatment.¹³³

Impact on treatment

The current ESC/EACTS guidelines consider combined surgery as a class IIa, level of evidence C, indication in patients with moderate secondary MR, planned coronary artery bypass grafting, shortness of breath, and exercise PH in the setting of dynamic worsening of

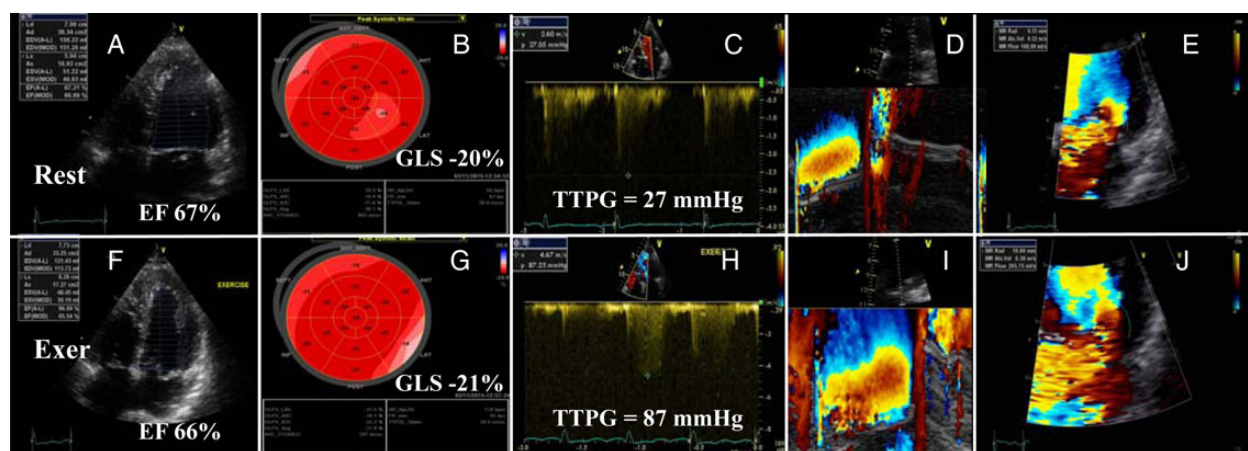


Figure 14 Patient with mitral valve prolapse and mitral regurgitation. (A–E) Rest evaluation; (F–J) exercise echocardiography results. At rest, left ventricular function was normal (EF 67% and global longitudinal strain [GLS] -21%). During exercise, EF and GLS did not change significantly, indicating no contractile reserve. Conversely, the systolic PAP (transtricuspid pressure gradient [TTPG]) (HC) and the severity of mitral regurgitation (DEI) increased severely. (D and I) The M-mode of the flow convergence zone and (E and J) the PISA radius at rest and at exercise using color flow imaging. It should be noted that the mitral regurgitation flow is very eccentric in this example; PISA is less reliable in this circumstance.

secondary MR. In severe primary MR, an SPAP ≥ 60 mmHg on exertion is a class IIb, level of evidence C, indication for surgery in case of high likelihood of durable repair and low surgical risk.¹⁰⁸ No specific recommendation has been provided in the AHA/ACC guidelines.¹⁰⁹

Key points

Exercise SE provides information about disease severity and individual outcome in MR. MR severity, SPAP, and left and right ventricular contractile reserve should be evaluated according to the clinical context. An increase by ≥ 1 grade in MR (from moderate-to-severe MR), a SPAP ≥ 60 mmHg, and a lack of contractile reserve ($<5\%$ increase in EF or $<2\%$ increase in global longitudinal strain) are markers of poor prognosis.

Aortic regurgitation

In severe aortic regurgitation (AR), the onset of symptoms heralds a dramatic change in prognosis,¹³⁶ with mortality being reported as high as 10–20% per year. Exercise testing is recommended to reveal symptoms in the patient with severe AR who reports being asymptomatic.¹⁰⁹ Neither exercise nor dobutamine SE can be used to re-grade AR severity in the patient with symptoms, because the test-induced increase in heart rate shortens diastole, limiting quantification of AR severity.

Severe aortic regurgitation without symptoms

Exercise testing is recommended to reveal symptoms.¹⁰⁸ Exercise echocardiography can serve this purpose, concomitantly providing LV contractile reserve assessment, but there is limited evidence to support this indication. The lack of contractile reserve ($<5\%$ increase in LVEF) was found to predict LV systolic dysfunction development at follow-up or post-operatively.^{136,137} Rest and exercise longitudinal function assessment (by TDI parameters) may reveal early signs of LV systolic dysfunction.¹³⁸

Non-severe aortic regurgitation with symptoms

Exercise testing is recommended to confirm equivocal symptoms.¹⁰⁹ Exercise SE can reveal another cause for symptoms (e.g. diastolic dysfunction, PH, or dynamic MR) but evidence in support of this indication is lacking.

Exercise SE rather than pharmacological SE is recommended for assessment of symptoms. Supine bicycle exercise is most appropriate for the assessment of contractile reserve, because images can be acquired at both low and high workloads.

Images should be acquired at baseline and immediately post-exercise when using a treadmill, and at baseline, low workload, and peak exercise when using a supine bicycle. For both indications, the minimum acquired dataset comprises LV views, TR CW Doppler for estimation of SPAP, and colour flow Doppler to detect MR, obtained in this order. The sequence of image acquisition always depends on the relative importance of the available information and the likelihood of the persistence of abnormalities into recovery.¹⁰⁵

Impact on treatment

ESC/EACTS and AHA/ACC guidelines consider aortic valve replacement (AVR) class I indication, level of evidence B, in patients with severe AR and symptoms revealed by exercise testing.^{129,130}

Key points

In AR, SE is used to assess symptoms, exercise tolerance, and the LV response to stress but not the valve disease severity. A lack of contractile reserve is associated with post-operative LV dysfunction.

Mitral stenosis

In mitral stenosis (MS), SE demonstrates the haemodynamic significance of the disease, which can contrast with its anatomically defined severity based on valve area.^{139,140} This could be explained by the indexed valve area being low for the patient or by valve non-compliance to the increase in flow during stress. SE is recommended for the assessment of patients with both severe asymptomatic disease and non-severe disease with symptoms^{108,109} based on extensive evidence.^{141–145}

Severe mitral stenosis without symptoms

MS is defined as severe when the valve area is <1 cm² in the ESC/EACTS guidelines¹⁰⁸ or <1.5 cm² in the ACC/AHA guidelines.¹⁰⁸ This difference has little implication for management because, when the valve area is <1.5 cm², the guidelines recommend consideration of the suitability of the valve for balloon valvotomy. Exercise testing is indicated to reveal symptoms when the valve area is <1 cm².^{108,109} If the valve area is <1.5 cm² and the mitral valve is suitable for balloon valvotomy, SE is indicated to reveal symptoms and assess haemodynamic consequences.^{109,145} Regardless of suitability for balloon valvotomy, when the valve area is <1.5 cm² but >1 cm², SE is indicated when planning pregnancy or major surgery.^{108,109}

Non-severe mitral stenosis with symptoms

SE is indicated to assess the haemodynamic significance of MS, which if severe, may account for symptoms.^{139,146} MS is diagnosed as severe if the mean gradient is >15 mmHg on exertion (Figure 15) or >18 mmHg during dobutamine infusion.^{141,142} A SPAP is >60 mmHg on exertion is another marker of haemodynamically significant MS.

Exercise echo provides concomitant mitral valve gradient and SPAP assessment. Early increase in SPAP, at low-level exercise, should be looked for since it is correlated with higher rate of exercise-induced symptoms in asymptomatic patients with mitral valve area ≤ 1.5 cm².¹⁴¹ Dobutamine SE can be used to assess mitral valve gradients during stress if the patient cannot exercise, but it is not recommended for assessment of SPAP.

Images should be acquired at baseline and immediately post-exercise when using a treadmill; at baseline, low dose and peak when using dobutamine; and at baseline, low workload and peak when using supine bicycle exercise. The minimum acquired dataset

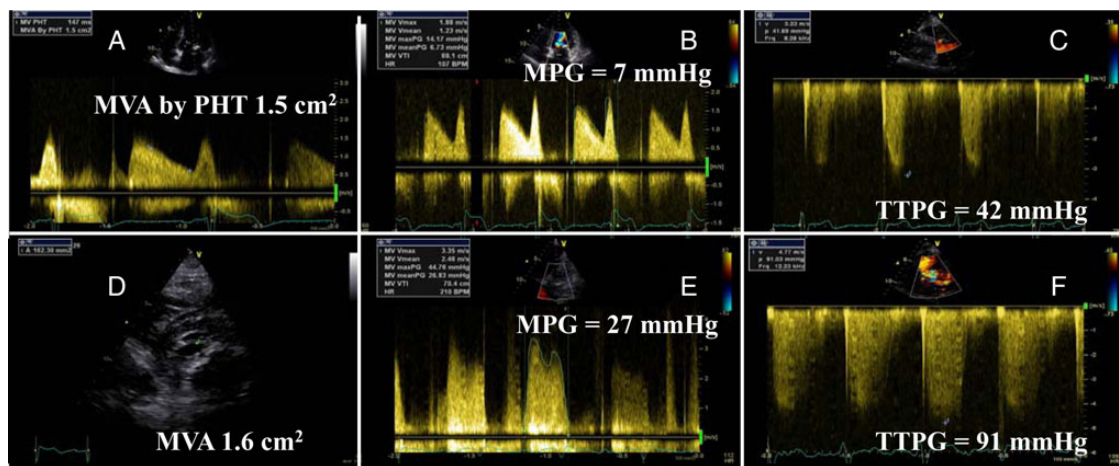


Figure 15 Patient with moderate mitral stenosis (mitral valve area (MVA) measured by pressure half time (PHT) (A) and planimetry methods (D)) and dyspnoea. With exercise, there was a significant increase in systolic PAP (transtricuspid pressure gradient (TTPG)) (D) and in transmitral pressure gradient (MPG) (E), indicating haemodynamically significant mitral stenosis. (A–D) Rest evaluation; (E and F) exercise echocardiography results.

comprises TR CW Doppler for estimation of SPAP and mitral valve CW Doppler for gradient measurement.

Maximal sweep speed and minimal velocity scale should be used for mitral valve continuous Doppler acquisition. In case of atrial fibrillation, SE is better performed during continuation of rate control medication to avoid early rise in heart rate during the test.

Impact on treatment

ESC/EACTS and AHA/ACC guidelines consider symptomatic MS as a class I indication for intervention, but suitability for percutaneous balloon valvotomy plays a central role in the final decision to treat.^{108,109}

Key points

SE is indicated to reveal symptoms and assess haemodynamic consequences of MS—based on the gradient and SPAP increase during stress—in patients with discordance between symptoms and stenosis severity. Exercise SE is preferred for SPAP assessment. MS should be considered severe if exertion results in a mean gradient > 15 mmHg and SPAP > 60 mmHg.

Aortic stenosis

Asymptomatic severe aortic stenosis

In patients with aortic stenosis (AS), the onset of symptoms and/or LV systolic dysfunction represents a clear indication (Class I, level of evidence B) for AVR. Exercise testing is contraindicated in patients with severe AS with definite or probable cardiac symptoms. However, exercise testing is recommended to unmask symptoms or abnormal blood pressure responses in patients with AS who claim to be asymptomatic.^{108,109} Approximately one-third of patients exhibit

exercise-limiting symptoms; these patients have worse outcomes.^{147,148} Exercise testing, with appropriate physician supervision and close monitoring of the ECG and blood pressure, is safe in AS patients without apparent symptoms. In patients with asymptomatic severe AS (Stage C1 in ACC/AHA guidelines),¹⁰⁹ exercise SE has been shown to provide incremental prognostic value beyond exercise testing alone.^{148,149}

Images should be acquired at baseline and immediately post-exercise when using a treadmill or at low and peak workload when using supine bicycle exercise. The minimum acquired dataset includes aortic valve CW Doppler for measurement of peak aortic velocity and mean gradient, acquisition of apical four- and two-chamber views for the assessment of LVEF by biplane Simpson, then TR CW Doppler for estimation of SPAP (Table 1). Continuous wave Doppler should ideally be performed from the window from which the maximum velocity was obtained at rest.

An increase in mean aortic pressure gradient by ≥ 18 –20 mmHg (Figure 16),^{148,149} the absence or limitation of LV contractile reserve (decrease or no change in LVEF suggesting subclinical LV dysfunction),^{147,150} and induced PH (SPAP > 60 mmHg)¹⁵¹ during exercise are markers of poor prognosis.

The increase in mean gradient may reflect either the presence of more severe AS or a non-compliant rigid aortic valve.^{148,149} The lack of LV contractile reserve with exercise may reflect more advanced disease with LV afterload mismatch and/or exhaustion of coronary flow reserve with exercise. LVEF lacks sensitivity to detect subclinical LV systolic dysfunction and assessment of longitudinal LV strain seems to be a more powerful parameter in predicting the occurrence of symptoms, exercise intolerance, and cardiac events in asymptomatic AS patients with preserved LVEF.¹⁵² Further studies are needed to determine the best cut-point value of exercise-induced change in LVEF or global longitudinal strain to identify patients at increased risk of developing symptoms, LV systolic dysfunction, or cardiac events.

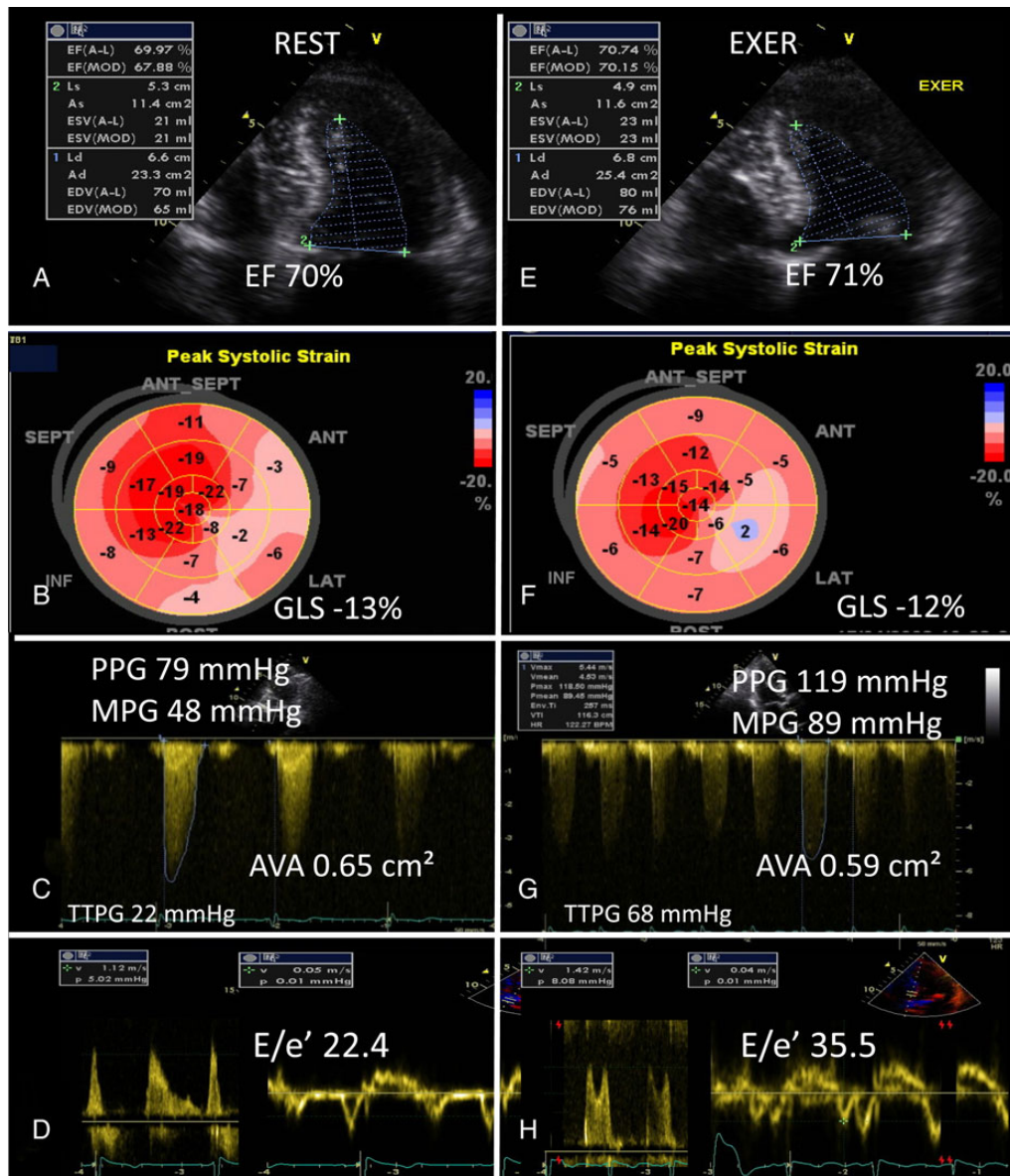


Figure 16 Asymptomatic patient with severe aortic stenosis and significant increase in transaortic pressure gradient, systolic PAP (transtricuspid pressure gradient [TTPG]), and E/e' during exercise echocardiography. Note that the left ventricular EF and the global longitudinal strain (GLS) remained unchanged, indicating the absence of contractile reserve. Also during test, blood pressure increased by >20 mmHg and neither symptoms nor significant ST segment changes were observed. (A–D) Rest evaluation; (E–H) exercise echocardiography results. AVA, aortic valve area; Exer, exercise; MPG, mean pressure gradient; PPG, peak pressure gradient.

Impact on treatment

The increase in mean gradient may be considered an indication for early elective AVR (Class IIb recommendation, level of evidence C in ESC/EACTS guidelines) in asymptomatic patients with severe AS.¹⁰⁸ Patients with severe AS developing PH or with limited contractile reserve and those with moderate AS having a marked increase in pressure gradient during exercise should probably have closer clinical and echocardiographic follow-up.^{148–152}

Key points

In patients with asymptomatic severe AS, exercise SE may uncover the development of symptoms, necessitating consideration for AVR. The main risk markers are a marked (>18–20 mmHg) increase in mean pressure gradient, a deterioration of LV systolic function, the lack of LV contractile reserve, and the development of PH (SPAP > 60 mmHg) during exercise. These markers can also be used to adjust the timing of follow-up in patients with moderate AS.

Low-flow, low-gradient AS

Low-flow, low-gradient (LF-LG) AS may occur with depressed (i.e. classical LF-LG) or preserved (i.e. paradoxical LF-LG) LVEF.¹⁵³ In both cases, the decrease in gradient relative to AS severity is due to a reduction in transvalvular flow. The main challenge in LF-LG AS is to distinguish between patients with true-severe AS and thus usually benefiting from surgical or transcatheter AVR, vs. patients with pseudo-severe AS who may not necessarily benefit from this intervention. Furthermore, patients with LF-LG severe AS have poor outcomes with conservative management but increased operative risk with surgical AVR.^{153–159}

Low-flow, low-gradient AS with reduced LV ejection fraction

Classical LF-LG AS is defined as an aortic valve area (AVA) $< 1.0 \text{ cm}^2$, a mean gradient $< 40 \text{ mmHg}$ and an LVEF $< 50\%$.^{129,130} Low-dose dobutamine SE is useful in these patients to assess stenosis severity and LV contractile reserve (Figures 17–20).^{110,154}

After acquisition at rest, Doppler tracings and LV images are obtained at each dobutamine infusion stage (Table 1); the dose increment is delayed until all recordings are considered optimal. The minimum acquired dataset comprises: aortic valve CW Doppler, LVOT PW Doppler (sample volume should be placed as much as possible at the same position in the LVOT during the test), views of LV cavity in parasternal long-axis, and apical two- and four-chamber. The imaging assessment includes LV function (changes in EF or global longitudinal strain) and flow reserve (increase in stroke volume $\geq 20\%$), changes in pressure gradients, and AVA. In contrast to the stroke volume, the mean transvalvular flow rate (i.e. stroke volume/LV ejection time), which is, besides the AVA, the main physiological determinant of the increase in gradient, continues to increase at higher doses of dobutamine due to increase in heart rate.^{110,154} For this reason, stopping the test when heart rate increases by $\geq 10 \text{ bpm}$, as proposed by some authors, may preclude significant increase in flow rate and thus limit the ability to distinguish true from pseudo-severe stenosis.¹⁶⁰

Absence of LV flow reserve during dobutamine SE is observed in approximately one-third of patients and is associated with high operative mortality (6–33%) with surgical AVR.^{154,155} However, this factor does not predict absence of LV function improvement in symptomatic status, and late survival after surgery.^{155,156} Thus, the absence of LV flow reserve should not preclude consideration for surgical or transcatheter AVR.¹⁵⁵ The lack of stroke volume increase during dobutamine SE can result from: (i) afterload mismatch due to an imbalance between the severity of the stenosis and myocardial reserve, (ii) inadequate increase of myocardial blood flow due to associated coronary artery disease, and/or (iii) irreversible myocardial damage due to previous myocardial infarction or extensive myocardial fibrosis.¹⁵⁴

The peak stress values of stroke volume index, LVEF, or longitudinal strain (LV contractile reserve) obtained during dobutamine SE may be better than the absolute or relative changes in these parameters because the peak stress values represent a composite measure accounting for both baseline resting LV function and LV contractile reserve.^{157–159}

Typically in true-severe AS, marked increases in gradients with small or no increases in AVA are observed during dobutamine SE, whereas in pseudo-severe AS, gradients increase only slightly or do not change and the AVA increases significantly with dobutamine SE.^{110,154} The most important parameters and criteria to identify true-severe AS during dobutamine SE are: a mean pressure gradient $\geq 40 \text{ mmHg}$ or peak aortic jet velocity $\geq 4 \text{ m/s}$ with an AVA $< 1.0 \text{ cm}^2$. Pseudo-severe AS is generally defined as a peak stress mean pressure gradient $< 40 \text{ mmHg}$ and a peak stress AVA $> 1.0 \text{ cm}^2$. Some studies suggest that the cut-point value of peak stress AVA should be raised from 1.0 to 1.2 cm^2 based on the concept that a moderate-to-severe AS may be well tolerated by a patient with preserved LVEF but may be detrimental for a patient with a depressed LVEF.^{159,160} When the AVA-gradient discordance and thus the uncertainty about actual stenosis severity persist with dobutamine SE (i.e. peak stress gradient $< 40 \text{ mmHg}$ and peak stress AVA $< 1.0 \text{ cm}^2$), it is helpful to calculate the projected AVA at normal flow rate (Q) (i.e. 250 mL/s) using the formula (Figure 21)^{160,161}:

$$\text{Projected AVA} = \text{AVA}_{\text{rest}} + (\Delta\text{AVA}/\Delta Q) \times (250 - Q_{\text{rest}}),$$

where AVA_{rest} and Q_{rest} are the AVA and mean transvalvular flow rate measured at rest and ΔAVA and ΔQ are the absolute changes in AVA and Q measured during dobutamine SE.

A projected AVA $< 1.0 \text{ cm}^2$ suggests true-severe stenosis.

Impact on treatment

Patients with pseudo-severe stenosis have no indication for AVR but require optimization of HF therapy and close echocardiographic follow-up.^{108,109,162} AVR should be considered in patients with evidence of true-severe AS on dobutamine SE. According to ESC/EACTS and ACC/AHA guidelines,^{108,109} symptomatic patients with classical LF-LG AS and evidence of severe AS on dobutamine SE (Stage D2) have a class IIa, level of evidence C, indication for AVR.^{108,109} However, patients with no LV flow reserve have high operative risk and therefore, the ESC/EACTS guidelines provided a weaker recommendation (IIb, level of evidence C) for AVR in these patients. Less invasive procedures such as transcatheter AVR could be considered in these patients with no LV flow/contractile reserve and evidence of severe AS.

Low-flow, low-gradient AS with preserved ejection fraction

Paradoxical LF-LG AS is defined as LVEF $\geq 50\%$, stroke volume index $< 35 \text{ mL/m}^2$, AVA $< 1.0 \text{ cm}^2$, indexed AVA $< 0.6 \text{ cm}^2/\text{m}^2$, and mean gradient $< 40 \text{ mmHg}$ at rest.^{108,109} Recent studies¹⁶³ suggest that exercise- (in patients with no/mild/ambiguous symptoms) or low-dose dobutamine- (in symptomatic patients) SE may be useful in patients with paradoxical LF-LG AS to corroborate stenosis severity. The same parameters and criteria as those described for classical LF-LG AS can be applied. About one-third of the patients with paradoxical LF-LG AS have pseudo-severe stenosis, which is similar to what has been reported in patients with classical LF-LG AS.¹⁶³ However, dobutamine SE is often not feasible or inconclusive in patients with paradoxical LF-LG AS due to the presence of LV restrictive physiology pattern. If such is the case, aortic valve calcium

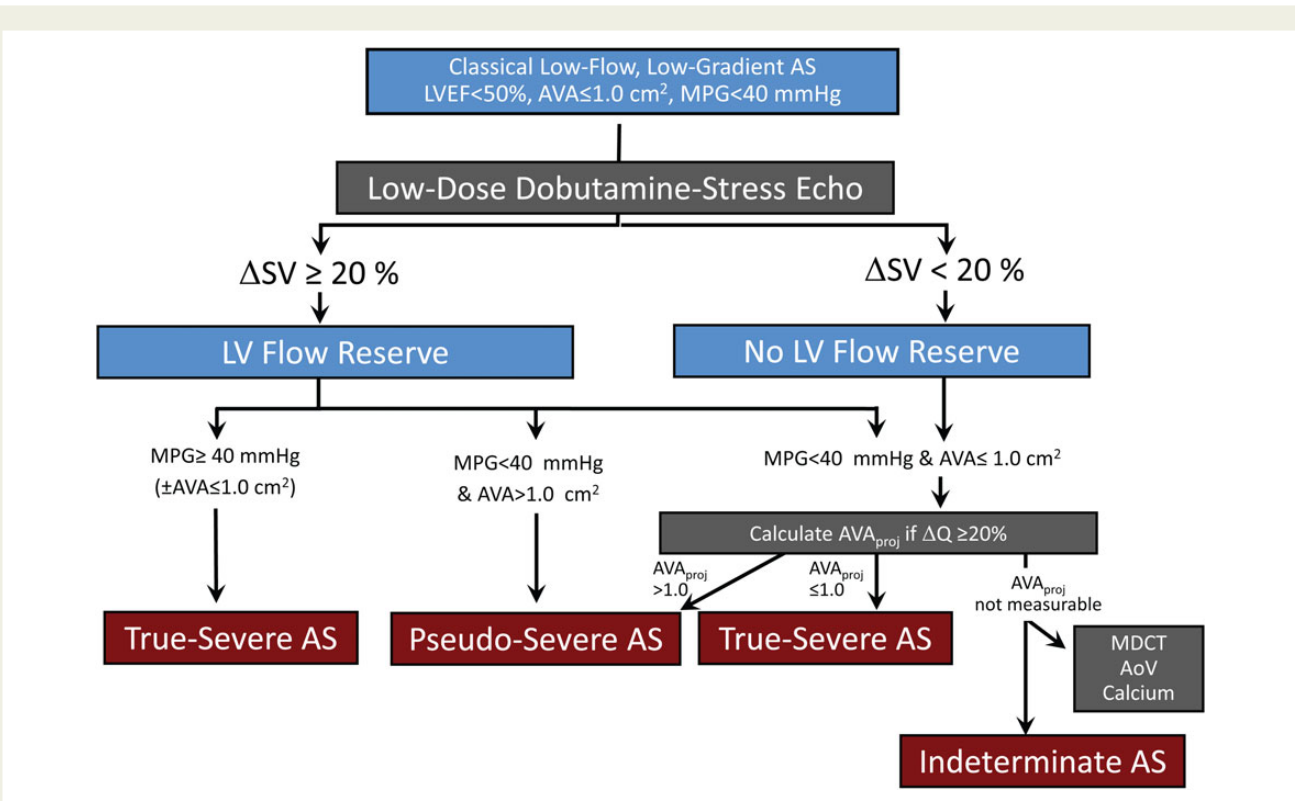


Figure 17 Interpretation of the dobutamine SE results in patients with low-flow, low-gradient AS, and reduced LVEF. The first step is to determine the presence of flow reserve, which is generally defined as a relative increase in stroke volume (SV) >20%. If there is flow reserve and if the mean pressure gradient (MPG) exceeds 40 mmHg and the effective aortic valve area (AVA) remains <1 cm², the stenosis is considered severe. If there is no flow reserve, it is difficult to get a definitive answer with regard to stenosis severity. In this case, the use of projected AVA or the evaluation of calcium score by computed tomography (MDCT) should be considered. The estimation of the projected AVA may not be reliable when the ΔQ is <20%. If the projected AVA is <1 cm², the stenosis is severe. MPG, mean pressure gradient; Q, flow rate; SV, stroke volume.

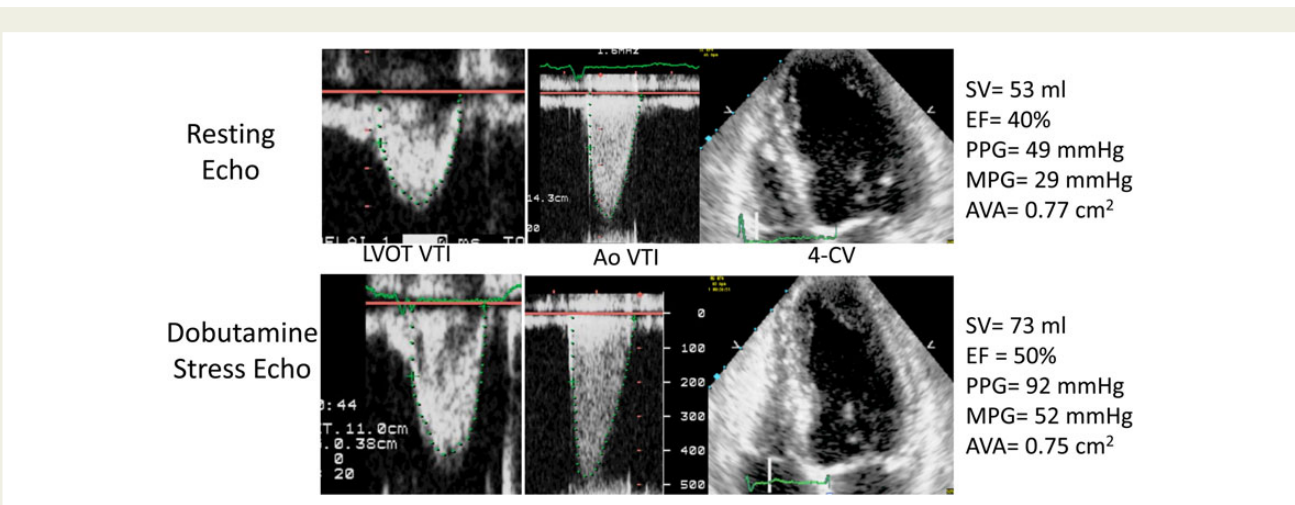


Figure 18 Example of low-flow, low-gradient - true-severe AS identified during dobutamine SE. During test, the increase in stroke volume (SV) (>20%, flow reserve) was accompanied by a significant rise in pressure gradients (mean pressure gradient (MPG) > 40 mmHg), while the aortic valve area (AVA) remained <1 cm². Note that the EF increased. PPG, peak pressure gradient.

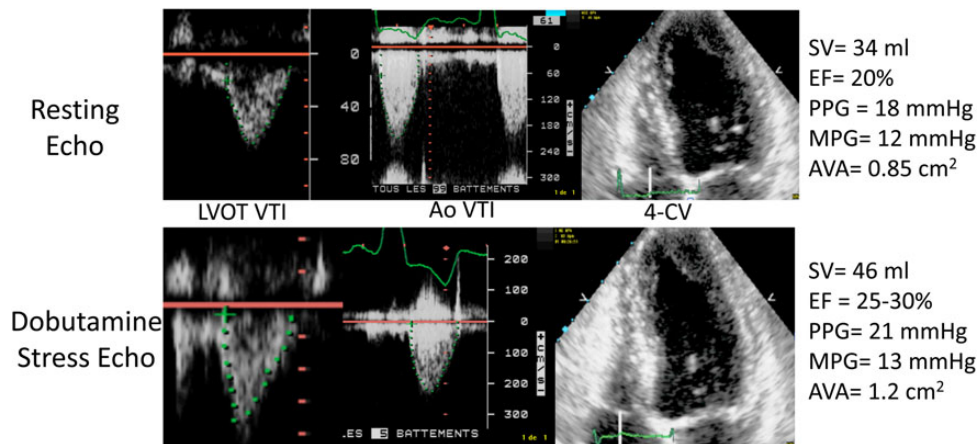


Figure 19 Example of low-flow, low-gradient—pseudo-severe AS. Example of pseudo-severe AS identified during dobutamine SE. During test, the increase in stroke volume (SV) (>20%, flow reserve) was not accompanied by a significant rise in pressure gradients (mean pressure gradient (MPG) <40 mmHg), while the aortic valve area (AVA) increased over 1 cm². Note that the EF increased significantly during test. PPG, peak pressure gradient.

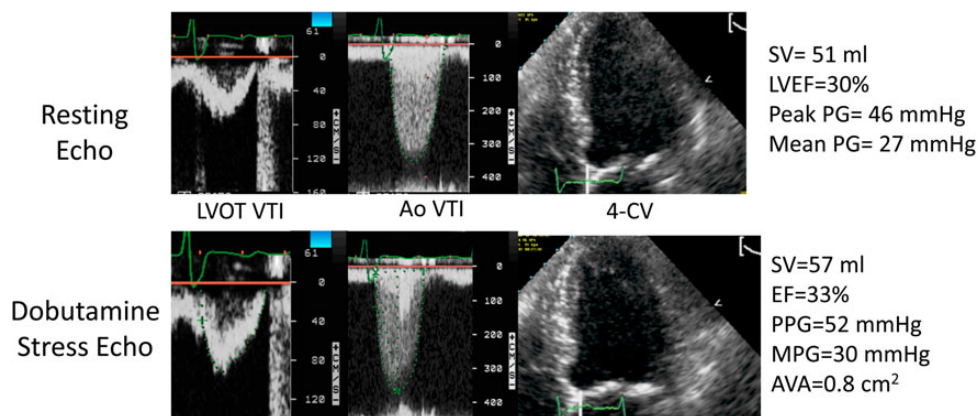


Figure 20 Example of low-flow, low-gradient AS with indeterminate stenosis severity. During dobutamine SE, the increase in stroke volume (SV) was <20%, indicating no flow reserve, and the peak (PPG) and mean (MPG) pressure gradients and aortic valve area (AVA) did not change significantly. Note that the EF changed slightly.

scoring by multidetector computed tomography may be used to confirm stenosis severity. According to ESC/EACTS and ACC/AHA guidelines,^{108,109} symptomatic patients with paradoxical LF-LG AS and evidence of severe AS (Stage D3) have a class IIa, level of evidence C, indication for AVR.

Key points

In classical low-flow, low-gradient AS with reduced LVEF, a low-dose dobutamine SE is recommended to: (i) assess LV flow reserve, which is helpful for surgical risk stratification and (ii) differentiate true- from pseudo-severe AS, which is key for guiding the decision to perform AVR. In paradoxical low-flow, low-gradient AS with preserved LVEF, exercise or dobutamine SE may also be used to differentiate true- from pseudo-severe AS.

Multivalvular heart disease

Although assessment of multivalvular disease is technically challenging clinically as well as with imaging, SE is well suited for this assessment. Mixed stenotic and regurgitant lesions can be assessed with a combination of colour flow imaging and Doppler, and multiple valves can be systematically assessed during exercise. Limited data, however, exist regarding the assessment and management of patients with multivalvular disease.^{108,164}

Evaluation of multivalvular disease with SE is indicated when the patient's symptoms are disproportionate to the resting haemodynamics.^{108,109} In this case, exercise testing can uncover an explanation for symptoms, e.g. the gradient or regurgitation increases or PH develops. When the valve disease is severe but

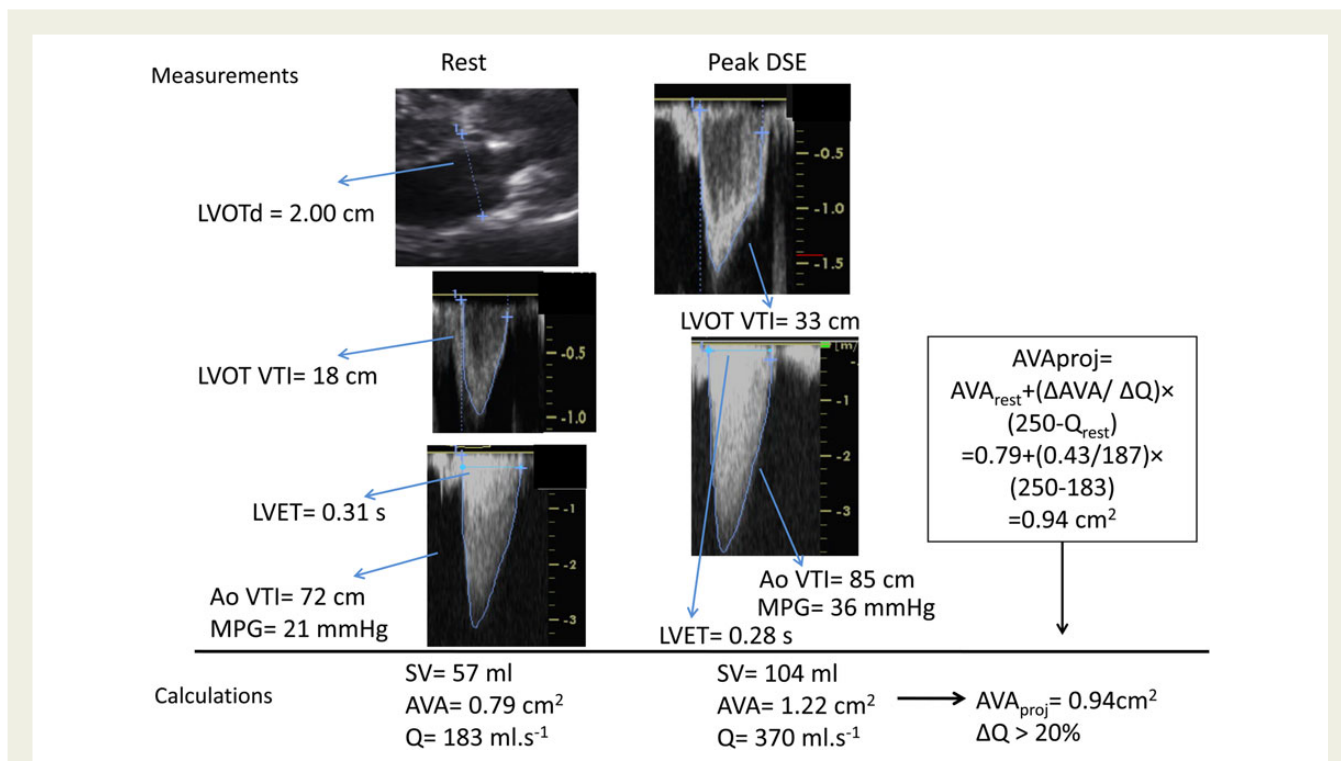


Figure 21 Example of the calculation of the projected aortic valve area (AVA_{proj}) during dobutamine stress echocardiography (DSE) in a patient with low-flow, low-gradient AS and reduced left ventricular EF. The projected AVA confirmed the presence of true-severe AS. Ao, aortic; LVET, left ventricular ejection time; LVOTd, LV outflow tract diameter; MPG, mean pressure gradient; Q, mean flow rate; SV, stroke volume; VTI, velocity time integral.

the patient is asymptomatic, exercise testing may uncover an abnormal haemodynamic response, arrhythmia, marked ST-segment shifts, or may demonstrate that the patient is indeed limited by symptoms.

Bicycle stress testing is best suited for the evaluation of multivalvular disease, as multiple valves can be assessed during exercise, rather than during recovery.

The strategy for assessment of the valves should be based on the rest echocardiographic images, including a sequence for interrogation of each valve of interest. There is usually one dominant lesion and the strategy of valve interrogation must take this into consideration. It may be necessary to prolong the stages of exercise from 2 or 3–5 min to complete the indicated colour flow and Doppler assessment. It is valuable to assess haemodynamic changes occurring during the early stages of exercise, especially in patients who are limited by exertional symptoms that may abruptly result in inability to exercise further.¹⁴¹ Exercise flow augmentation is known to differ for the mitral and aortic valves; the mean mitral orifice area increases with exercise, whereas increases in stroke volume at the level of the aortic valve are mediated by increases in the aortic time velocity integral.¹⁶⁵ Rheumatic mitral valve disease may include both stenosis and regurgitation and the relative importance of these lesions may vary during exercise; recognition of this is important for treatment.¹⁶⁶ Similarly, in aortic valve disease with combined stenosis and regurgitation, the consequences of the combination may be additive.

Post heart valve procedures

SE is a valuable tool for the evaluation of prosthetic valve haemodynamic function and may be useful when there is discordance between the patient's symptomatic status and the prosthetic valve haemodynamics. In patients with no, mild, or equivocal symptoms, the preferred modality is exercise SE using a protocol with graded bicycle exercise performed in the semi-supine position (Table 1).¹⁰⁵ Low-dose (up to 20 μg/kg/min) dobutamine SE is used in patients with moderate or severe symptoms.

Aortic and mitral prosthetic valves

Given that most prosthetic valves with normal function cause some degree of stenosis, the resting values of transprosthetic velocity and gradient overlap considerably between the normally and abnormally functioning prostheses.^{167–170} However, with the increase in flow achieved during exercise or dobutamine SE, patients with significant prosthetic valve stenosis or prosthesis–patient mismatch (PPM) will generally show a marked increase in transprosthetic gradient often accompanied by the development of pulmonary arterial hypertension (PH), symptoms, and subsequent impaired exercise capacity. On the other hand, patients with normal prosthetic valve function or with a bileaflet mechanical valve with a localized high gradient through the central valve orifice usually have minimal increase in gradient during SE.

Exercise or dobutamine SE may be helpful in confirming the presence of haemodynamically significant prosthetic valve stenosis or PPM in patients with mildly to moderately elevated transprosthetic gradients at rest: i.e. between 20 and 40 mmHg in the aortic position or 5–10 mmHg in the mitral position. A disproportionate increase in transvalvular gradient (>20 mmHg for aortic prostheses or >10 mmHg for mitral prostheses) generally indicates severe prosthesis stenosis (e.g. calcification, pannus overgrowth) or PPM, especially when there is a concomitant rise in SPAP (>60 mmHg) (Figure 22).^{171,172} A potential limitation of SE in this setting is the interference of the prosthetic material with the Doppler signal. This may lead to appearance of spectral Doppler artefacts, therefore, decreasing the accuracy of transprosthetic pressure gradient measurements, especially during exercise. High resting and stress gradients occur more often with smaller (≤ 21 mm for aortic and ≤ 25 for mitral) and mismatched prostheses.^{173–175}

Like LF-LG native AS, a low-dose dobutamine SE may be useful to differentiate true from pseudo-stenosis or mismatch in patients with prosthetic valves and low cardiac output (Figure 23) associated or not with reduced LVEF. In the situation of pseudo-stenosis/mismatch, the resting transprosthetic flow rate and thus the forces applied on the prosthetic valve leaflets are too low to completely open them. The measurement of a LG in concomitance with a small effective orifice area (EOA) (EOA < 1.0 cm² or EOA $<$ normal reference value -2 SD), a small indexed EOA (< 0.85 cm²/m² in aortic position and < 1.2 cm²/m² in the mitral position) and/or an abnormal Doppler velocity index (< 0.35 in the aortic position and > 2.2 in the mitral position) should alert the clinician and prompt further evaluation. On dobutamine SE, patients with pseudo-severe AS have a substantial increase in valve EOA and no or minimal elevation in

gradients with increasing flow rate. On the other hand, true stenosis or mismatch is associated with no or small increases in EOA, a marked increase in gradient, and most often the occurrence of indirect signs (LV dysfunction, marked elevation in SPAP, etc.) and symptoms.^{171,172} Patients with isolated mismatch (i.e. with no concomitant acquired stenosis) generally have a peak stress EOA that is close to the normal reference value of EOA for the implanted model and size of prosthesis.¹⁷⁰ Patients with stenosis have a stress EOA that is substantially smaller than the normal reference value.

Mitral valve annuloplasty

In patients with ischaemic MR, restrictive mitral valve annuloplasty may create some degree of functional MS.^{175–179} This abnormality may also occur in patients with degenerative MR following mitral valve repair, especially when complete ring annuloplasty is used.^{179,180} Some degree of functional MS (Figure 22) may occur in up to 50% of patients undergoing mitral valve annuloplasty and this haemodynamic sequel is associated with higher SPAP, worse functional capacity, and poorer quality of life.^{175–177,180}

Resting Doppler-echocardiographic assessment of mitral valve haemodynamics and SPAP may grossly underestimate the incidence and severity of functional MS following mitral valve annuloplasty because an important proportion of these patients have reduced transmitral flow rate.^{175,176,181,182} Indeed, the majority of patients with ischaemic MR have persistent LV systolic dysfunction and thus, LF state after surgery. β -Blocker therapy in these patients lengthens diastole and reduces transvalvular flow rate for a given stroke volume, mitigating the impact of significant functional MS.^{175,176,181,182}

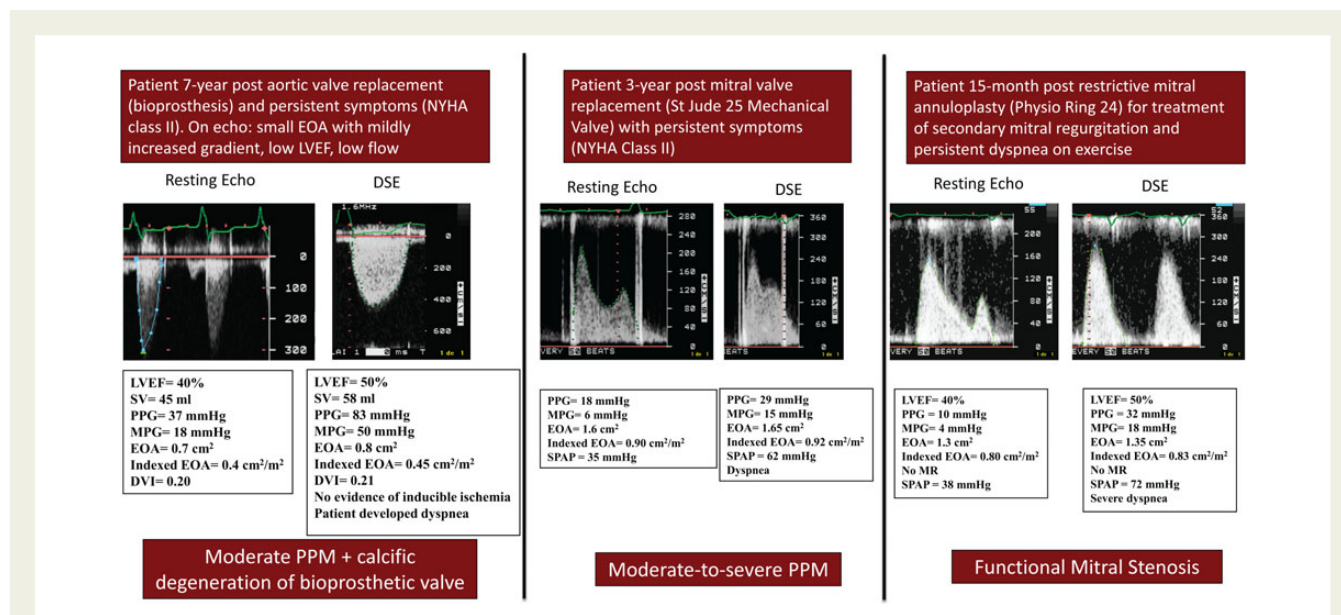


Figure 22 Examples of dobutamine stress test in patients with aortic and mitral valve prosthesis or repair. DVI, Doppler velocity index; EOA, effective orifice area; LVEF, left ventricular ejection fraction; MPG, mean pressure gradient; MR, mitral regurgitation; PPG, peak pressure gradient; SPAP, systolic pulmonary artery pressure; SV, stroke volume.

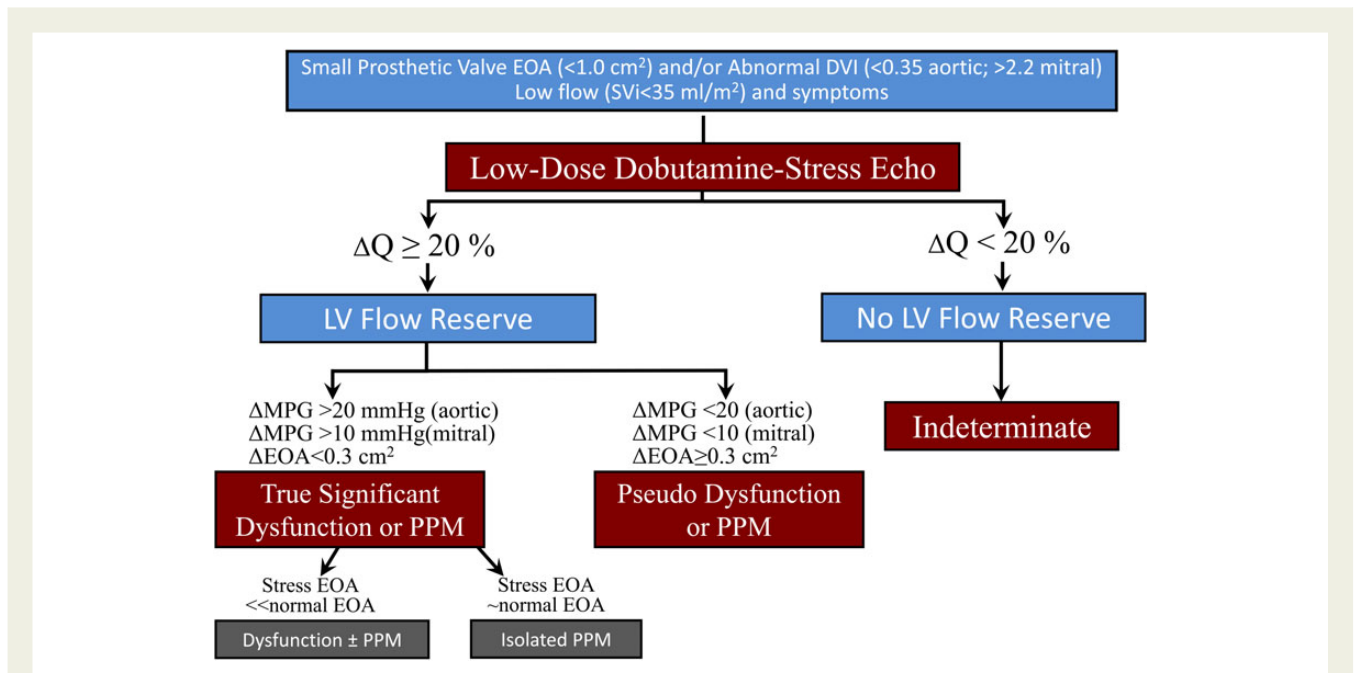


Figure 23 Evaluation of aortic/mitral prosthetic valve function in patients with low flow. Dobutamine SE is used to distinguish true significant dysfunction or patient–prosthesis mismatch (PPM) vs. pseudo-severe dysfunction or PPM vs. indeterminate valve function. Δ , difference peak-rest; EOA, effective orifice area; MPG, mean pressure gradient; Q, flow rate.

Exercise or dobutamine SE may be useful to unmask functional MS in patients who underwent mitral valve repair. This test should be considered in patients with resting mean gradient >3 mmHg who have persistent or recurrent symptoms following surgery. An absolute increase in mean transmitral gradient ≥ 7 mmHg with concomitant peak exercise SPAP ≥ 50 mmHg suggests the presence of functional MS.^{175,180–182}

Key points

In patients with aortic or mitral prosthetic valves and mild-to-moderate elevation of the resting transprosthetic gradients, exercise SE is useful to confirm: (i) the presence of significant prosthetic valve stenosis or PPM, (ii) the symptomatic status. In patients with aortic or mitral prosthetic valves and LF state with small resting EOA or abnormal Doppler velocity index, low-dose dobutamine SE is useful to differentiate true significant prosthesis dysfunction or PPM vs. pseudo-dysfunction. In symptomatic patients with mitral valve annuloplasty and mild increase in resting transmitral gradients, exercise or dobutamine SE is useful to confirm the presence of functional MS.

Pulmonary hypertension and pulmonary arterial pressure assessment

Pulmonary artery pressure is known to rise with exercise in patients with PH (mean PAP ≥ 25 mmHg at rest),¹⁸³ and in a variety of cardiac conditions (e.g. mitral and aortic valve disease, cardiomyopathy and the dyspnoeic patient referred for a diastolic SE) as previously discussed. An elevation in PAP and/or the development of RV

dysfunction with exercise has notable clinical significance generally denoting a poorer prognosis. Hence, SE has a role to play in evaluating patients with known or suspected PH.¹⁸⁴

Graded semi-supine exercise SE with imaging acquisition appropriate to the objectives of the test is the preferred approach. Post-exercise SE imaging is less reliable since SPAP is known to return to baseline quite quickly (declining by up to 25% within 3–5 min).^{184,185} Doppler recordings should be obtained within 1 min of test completion. The administration of a hypoxic challenge represents an alternative stress test in patients at risk for PH or high altitude pulmonary oedema (HAPE). Hypoxic challenge has the advantage that patients are stationary, and imaging is easier. While a variety of protocols may be used including assessment in a hypoxia chamber, the administration of a gas mixture of 12% oxygen and 88% nitrogen (corresponds to an altitude of 15 000 ft \sim 4500 m) by facemask is quite feasible.¹⁸⁶ Patients are exposed to this hypoxic challenge for 90–120 min, with periodic haemodynamic and oxygen saturation assessment and Doppler echocardiography performed before, midway through, and at the end of hypoxia.

During the stress test, images and Doppler recordings should be acquired at each stage of stress. Contrast may aid in imaging of the RV and may enhance the Doppler signal of TR; administration is safe in patients with PH.¹⁸ The minimum acquired dataset includes TR velocity, if possible pulmonary regurgitation (PR) velocity, and RV size and function (TAPSE), lateral annular tissue Doppler's, and free wall systolic strain; all are known to increase by 50% in normal subjects),¹⁸⁷ cardiac output, and depending on the referral indication, LV size and function. SPAP is calculated as the systolic transtricuspid pressure gradient plus right atrial pressure.^{183,184} Often an arbitrary value of 5 or 10 mmHg is assumed for right atrial (RA) pressure at exercise. However, this assumption may result in an

underestimation of SPAP with stress. An assessment of RA pressure by imaging of the size and collapsibility of the inferior vena cava as recommended for rest echocardiography³¹ has been used in the setting of SE, although validation studies are limited.¹⁸⁸ Total pulmonary vascular resistance (PVR) may be estimated by either the ratio of TR peak velocity to the time velocity integral of the RV outflow tract or the Doppler-derived mean PAP divided by cardiac output.¹⁸⁹ Since hypoxia may trigger PA vasoconstriction, oxygen saturation should be measured and reported when Doppler stress assessment of PAP is performed. Finally, as PAP is a flow-dependent variable, it will increase in the setting of anaemia, hyperthyroidism, and exercise.

A number of technical considerations are worth highlighting to optimize feasibility and diagnostic accuracy: (i) As Doppler-derived velocity measures are angle-dependent signals, a variety of windows should be interrogated to ensure the peak Doppler signals are obtained. This same window should be used to capture velocities during or following stress; (ii) If there is an insufficient TR Doppler envelope for measurement, the intravenous administration of agitated saline or contrast will frequently provide a more complete Doppler envelope, permitting measurement of the peak TR velocity (Figure 24)¹⁹⁰; (iii) As with all Doppler signals, particularly those obtained with agitated saline, the echocardiographer must be mindful to measure the true Doppler maximum rather than the faint or low-level noise on spectral Doppler signal, and hence avoid overestimation of a velocity that by being squared leads to a significantly overestimated pressure.

Pulmonary artery pressure with exercise in normal individuals

Evaluations in large cohorts of normal subjects have demonstrated that in response to exercise, the increase in PAP with exercise is

quite variable, and only in part relates to the intensity of exercise. Grünig et al. demonstrated that in normal subjects there is a bimodal distribution of peak TR velocities with exercise and hypoxia challenge with ~5–10% of normal subjects having a pulmonary hypertensive response.^{186,191} A TR velocity of >3.1 m/s (SPAP = 38 mmHg+ RAP) appears to serve as a threshold for determining an abnormal PAP with exercise.^{30,185,192,193} Exceptions to this might be older patients or athletes at high workloads (160 W) who may display higher PAP with exercise in the absence of disease.^{30,194}

Screening for susceptibility for high altitude pulmonary oedema and chronic mountain sickness

HAPE is a potentially life-threatening disorder that occurs in ~10% of individuals that climb to 15 000 ft (~4500 m). Hypoxia-induced PH appears to be a key pathophysiologic component. HAPE susceptible individuals may be identified by an abnormal rise in PAP in response to either low altitude hypoxia or exercise stress.¹⁸⁶ Exercise Doppler SE has also been found to identify individuals at risk for developing chronic mountain sickness with higher PAP and reduced RV function with exercise.^{195,196}

Screening for PH in patients at high risk for pulmonary arterial hypertension

While PAH is rare, with an estimated prevalence of 30–50 cases per million individuals, certain cohorts are at a significantly increased risk for PAH development.¹⁹⁷ Annual screening with rest transthoracic echocardiography has been proposed for patients with either known heritable mutations for PAH or a first-degree relative of familial PAH, patients with scleroderma, patients with portal

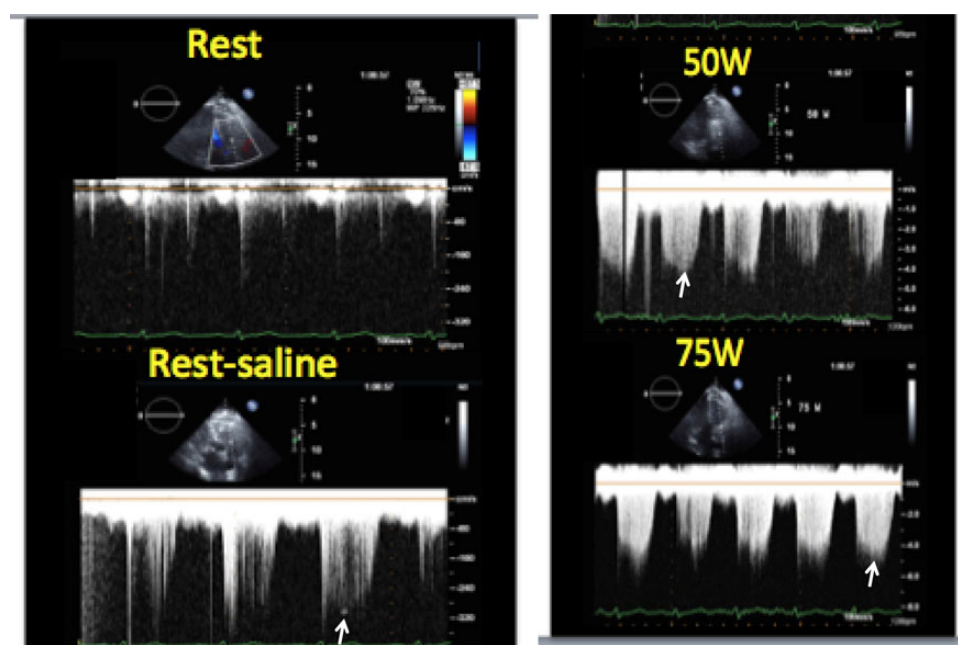


Figure 24 Example of intravenous agitated saline administration in Doppler SE. At rest, there is trivial tricuspid valve regurgitation leading to an incomplete, unmeasurable TR peak velocity. With agitated saline, a complete envelope is present thus allowing the measurement of the peak TR velocity at rest as well as during incremental stages of exercise.

hypertension, adults with sickle cell disease, or those with HIV infection.¹⁹⁷ While the role for SE in the screening evaluation should be considered on a case-by-case basis, there is emerging evidence that SE identifies patients at risk or early in development of disease.^{186,188,198–200} Rather than simply focusing on PAP with exercise, studies have suggested that an assessment of PVR is more sensitive.²⁰¹ Measures of SPAP and cardiac output are made at rest and with stress. A steeper slope of the dynamic PVR curve suggests a cohort at increased risk for the development of PAH.²⁰¹ Alternatively an assessment of PVR using the equation of Abbas *et al.* (PVR proportional to the TR velocity divided by RVOT TVI) as validated with rest echocardiography could be considered for the assessment of PVR with stress.^{202,203}

SE in patients with established PH

In patients with PH, PAP increases in response to even modest activity.^{182,204} However, the clinical value of exercise Doppler SE for the assessment of PAP in patients with known resting PH is unproven.²⁰⁵ The degree of elevation in PAP in patients with PH is not of clear prognostic benefit.²⁰⁶ Outcome in PH is invariably dictated by the RV response to loading.^{206,207} Therefore, there is growing interest in the echocardiographic assessment of RV function, particularly with enhanced techniques such as 2D speckle-tracking strain and 3D volumetrics.^{208,209} Yet, overt signs of right HF at rest typically exist only at late stages of disease, so there may be utility in assessing RV contractile reserve with stress. The inability to augment PAP with exercise, likely an indirect surrogate of impaired contractile reserve, is associated with worse outcome.²¹⁰ Others have shown that conventional RV contractility measures augment less in PAH compared with control.¹⁸ Sharma and colleagues recently evaluated low-dose dobutamine SE (at incremental doses of 5, 10, 15, and 20 µg/kg/min) in patients with PAH to assess contractile reserve. Patients with PAH had an impaired ability to augment RV contractility. Furthermore, RV contractile reserve correlated with exercise capacity.²¹¹

Key points

Doppler assessment of PAP with stress is feasible with exercise and is suggested as an adjunct in the assessment of patients with dyspnoea. In conjunction with PAP assessment, patients undergoing SE for suspected PH should have an assessment of RV function and oxygen saturation. Supine bike or hypoxic Doppler SE may be considered in the evaluation of patients at increased risk for PAH and to screen for HAPE and chronic mountain sickness. While the role of SE in patients with established PH is less proven, it may be useful in SE in the assessment of contractile reserve of the RV.

Athletes' hearts

SE using isotonic or isometric (i.e. handgrip) exercise in athletes can have three different clinically relevant targets besides assessment of ischaemia: (i) intraventricular gradients (detected by CW Doppler examination of the LVOT), (ii) pulmonary haemodynamics (i.e. SPAP, LV filling pressure) and evolution of MR (by colour Doppler echocardiography), (iii) lung sonography for detection of pulmonary congestion (as B-lines). These echocardiographic findings can underlie symptoms of chest pain, near syncope, and dyspnoea in symptomatic athletes.⁴

An exercise SE test in athletes can give valuable information about cardiac function, reserve, exercise capacity, and arrhythmias.²¹² A typical test can be performed in athletes with LV hypertrophy complaining of shortness of breath or tendency to syncope. One suggestive finding could be an LVOT gradient of >50 mmHg during or immediately after exercise in the presence of symptoms.³⁷ The occurrence of a gradient during exercise in symptomatic athletes is, however, a frequent finding,²¹³ and might help link the reported symptoms (post-exercise dizziness or syncope) to a potential cause (the development of an intraventricular gradient).

Some athletes, particularly those performing endurance activity, may have low resting LVEF, but can mobilize a very large volume with exercise.^{214,215} A considerable increase of EF during exercise suggests that the low rest LVEF is not related to significant LV systolic dysfunction.²¹²

B-lines detected by lung ultrasound, also called ultrasound lung comets, represent a useful and simple way to image directly the extravascular lung water.^{83,84} The anterior chest is scanned and the number of B-lines in each intercostal space is summed. Stress lung ultrasound (B-lines detection during or immediately post-exercise) is useful in two separate settings, HF and extreme physiology. In high altitude trekkers, healthy elite apnoea and scuba divers or underwater fishermen, and extreme athletes involved in sports such as triathlon or marathon, B-lines can be detected in the absence of symptoms of pulmonary oedema.^{216–218}

Key points

SE can be used in athletes if a dynamic obstruction is suspected or if they report symptoms that may be related to the development of an intraventricular systolic pressure gradient such as dizziness or syncope. A substantial increase in LVEF in athletes during SE suggests normal LV systolic function.

Congenital heart disease

SE has been applied to a variety of CHD, including atrial septal defect, coarctation of the aorta, univentricular heart, systemic RV, and post-operatively in tetralogy of Fallot.

Atrial septal defect

SE in atrial septal defect can be applied to evaluate myocardial performance and pulmonary haemodynamics.^{218,219} Although pharmacological stress may be used to evaluate the myocardial performance, exercise SE is preferred to evaluate the pulmonary haemodynamics in patients with CHD.²²⁰

Data on the effect of SE on the RV are scarce. In a bicycle SE study in patients with open and closed atrial septal defect, an increase in RV fractional area change (RVFAC) was inversely related to the SPAP at maximal exercise and positively related to peak oxygen consumption.²²¹ Both findings suggest a significant contribution of the SPAP on the RV workload.

Increased SPAP at rest is associated with a worse outcome in atrial septal defect.²²² Normal SPAP at rest seems to indicate normal pulmonary haemodynamics. However, in some atrial septal defect patients (open and closed) with normal SPAP at rest, a more pronounced pressure increase during bicycle SE can be observed.²¹⁶

Such a rise was more common when the atrial septal defect was closed at older age (≥ 34 years). The steeper slope of the corresponding pressure flow plots suggests increased dynamic PVR during exercise and minimal pulmonary vascular damage.^{220,223} The clinical importance of this increased dynamic PVR is not yet clearly understood but seems to correlate with maximal oxygen consumption. Abnormal dynamic response seems related to larger right atrial size and more significant degree of TR.^{201,224} The prognostic implication of an abnormal dynamic PVR response is still uncertain. Gabriels *et al.* failed to prove that increased dynamic PVR was related to the later development of PH in atrial septal defect patients.²⁰¹ Recent data have suggested that the dynamic PVR response could be modulated with the administration of pulmonary vascular dilatory therapy,²²⁵ suggesting that mild or early pulmonary vascular disease may be reversible.

Key points

SE may be useful in patients with an atrial septal defect. Bicycle SE testing is feasible to evaluate the RV performance in open and closed atrial septal defect patients. RV performance indirectly relates to SPAP at maximal exercise. Bicycle SE testing might be useful to detect increased dynamic PVR, which is hypothesized to be related to minimal pulmonary vascular disease.

Tetralogy of Fallot

Tetralogy of Fallot repair includes relief of RV outflow tract obstruction and closure of the ventricular septal defect. The most common residual problem is severe pulmonary regurgitation leading to progressive RV dilatation and dysfunction.²²⁶ SE could help with identification of early signs of RV and LV dysfunction. Exercise SE is the most commonly used technique as it is more physiological. Lamia Ait-Ali *et al.* studied in 128 young adults after tetralogy of Fallot repair the RV response to stress.²²⁷ In one group of 74 patients, RVFAC increased with exercise while in a second group of 49, no increase or even a decrease in RVFAC was observed. The clinical significance of these different functional responses is uncertain. Exercise SE was also used in children after tetralogy of Fallot repair; patients demonstrated a significant increase in markers of LV and RV dyssynchrony during exercise.²²⁸ The same group found a blunted response in RV isovolumetric acceleration with increased heart rate.^{229,230} This suggests a decreased RV and LV response to exercise. Hasan *et al.* utilized exercise SE to evaluate RV functional response during exercise in 20 patients with residual right outflow tract obstruction. The authors assessed changes in the exercise response before and after transcatheter pulmonary valve implantation²³¹ and showed a substantial increase in RVFAC and RV global strain at rest and at peak exercise after intervention. Further data are required regarding the clinical utilization of exercise echocardiography in tetralogy of Fallot patients.

Key points

Exercise echocardiography can be used in tetralogy of Fallot patients to study the RV and LV contractile reserve. RV function can be studied measuring RVFAC, TAPSE, and tissue Doppler velocities. Further data are required to demonstrate the clinical utility of this method.

Treated coarctation of the aorta

Patients after surgical or interventional repair of coarctation of the aorta can have residual coarctation of the aorta and are at risk of developing systemic arterial hypertension, which influences long-term outcomes.²³² Stress testing can be used to reveal subclinical hypertension. Exercise-induced systemic arterial hypertension (defined as a peak systolic blood pressure >200 mmHg) was predictive for chronic hypertension in adults after coarctation repair.²³³ Peak blood pressure during exercise correlated with LV mass index in children and young adults after coarctation stenting.²³⁴ Exercise testing can also be used to assess dynamic residual gradients (Figure 25). Recoarctation can be difficult to assess at rest and exercise SE can be used to study the response of the residual arch obstruction during exercise.²³⁵ The detection of a significant arch gradient during exercise (mean gradient ≥ 30 mmHg at any stage) together with systemic arterial hypertension proximal to the stenosis is a relevant clinical finding that may require further investigation and treatment.²³⁶ In adult patients with coarctation of the aorta, an abnormal contractile response has been demonstrated with a flattened increase in myocardial isovolumetric acceleration and s' with increase in heart rate.²³⁷ Interestingly, the isovolumic acceleration slope correlated with the exercise-induced increase in systolic and diastolic blood pressure. This may suggest that there is an effect of the increase in afterload during exercise on contractile function or alternatively isovolumetric acceleration could be afterload dependent.

Key points

In the context of coarctation of the aorta, exercise echocardiography can be used to assess blood pressure response and residual gradients across the aortic arch and distal aorta, as well as the myocardial response to exercise. An abnormal peak blood pressure response seems associated with chronic hypertension and increased LV mass index. A decreased contractile response to exercise has been described in patients after coarctation repair. The clinical significance remains to be demonstrated.

Univentricular hearts

Exercise stress testing in patients with univentricular cardiac physiology can be used to evaluate exercise and working capacities.^{238–240} However, minimal data are available on the SE assessment of exercise performance in these patients.

SE can be uniquely challenging due to the variability in cardiac anatomy, specifically the ventricular morphology. In patients with a single ventricle of RV morphology, the evaluation of systolic performance is particularly difficult since no standardized methods have been established. In hearts with a single LV, conventional functional assessment techniques can be employed (Figure 26), though the lack of a well-formed RV impacts the LV as well through the absence of normal ventricular interactions.

Exercise SE of the single ventricle may be helpful in collecting data in combination with the electrocardiographic and metabolic analysis routinely performed during exercise testing.²⁴¹ Staged imaging can be helpful in the visual assessment of myocardial contractility during incremental increases in afterload. Strain imaging during post-processing may allow for a more detailed analysis of myocardial mechanics.²⁴² Doppler assessment of regurgitant or obstructive valvar

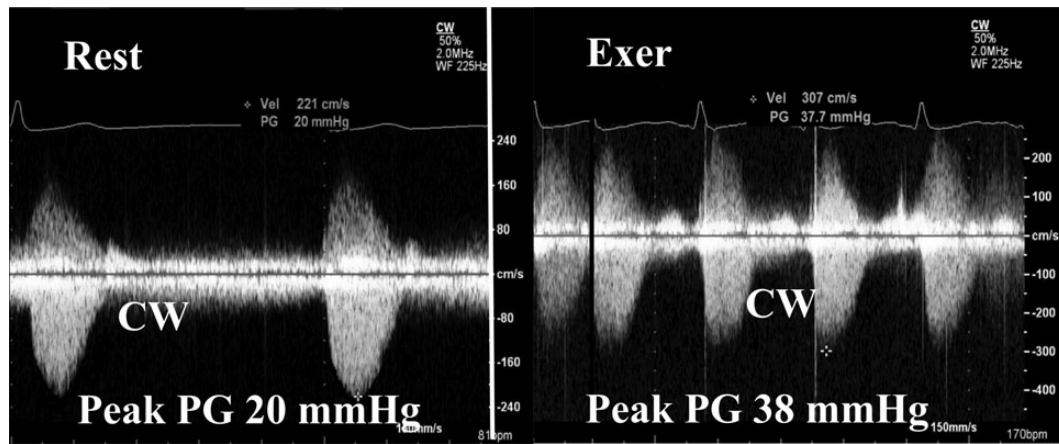


Figure 25 Stress continuous wave (CW) Doppler echocardiography in a 14-year-old patient with residual aortic coarctation post repair. A pre-exercise CW Doppler tracing obtained (left panel) displays a mildly increased resting velocity. At maximum exercise, the peak velocity obtained (right panel) increases slightly demonstrating no significant obstruction. PG, pressure gradient.

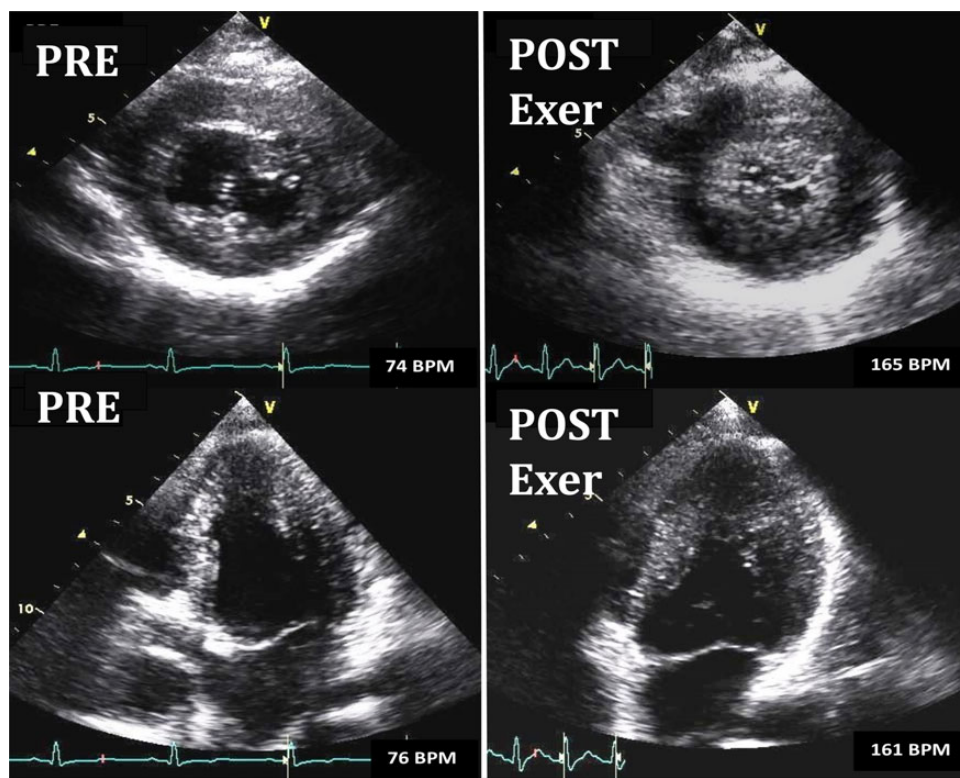


Figure 26 Exercise (Exer) SE in a 13-year-old patient with tricuspid atresia and single LV displaying end-systolic frames in the parasternal short axis (upper panels) and apical four-chamber (lower panels) views taken at rest (PRE) and peak exercise (POST). The displayed images showed the desired response of increased global myocardial thickening with a significant decrease in end-systolic volume.

and vascular lesions as exercise increases may be beneficial for surgical planning.²⁴³

Systemic right ventricle

In patients with a congenitally corrected transposition of the great arteries and in patients who underwent an atrial switch repair for

transposition of the great arteries, the morphological RV functions as systemic ventricle and the systemic atrio-ventricular valve is anatomically the tricuspid valve. Chronic systemic pressure load on the RV might lead to ventricular dysfunction, progressive TR, and HF.²⁴⁴ Theoretically, SE may provide more information about myocardial contractile reserve (Figure 27), and the behaviour of the TR during stress. In patients who underwent Mustard repair, systemic

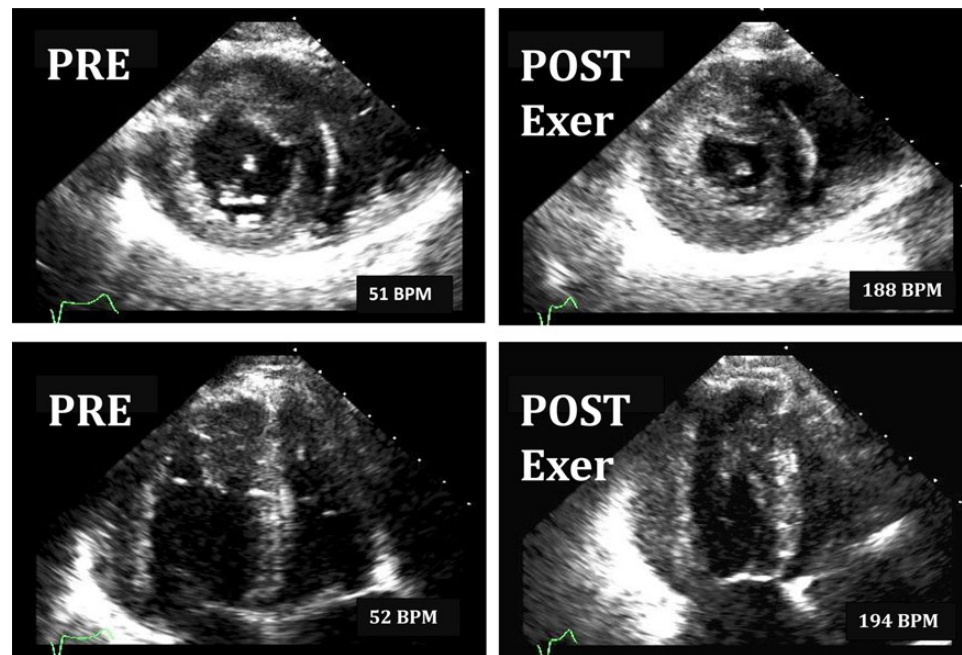


Figure 27 Exercise (Exer) SE in a patient with situs inversus and congenitally corrected transposition of the great arteries where the morphologic RV is the systemic ventricle. Resting and peak exercise image format are shown displaying end-systolic frames in the parasternal short axis and apical four-chamber views taken at rest (PRE) and peak exercise (POST). The desired response of increased global myocardial thickening and base-to-apex shortening with a significant decrease in right ventricular end-systolic volume is evident in the post-exercise images.

ventricular function, an independent predictor of the exercise capacity, is often depressed.²⁴⁵ Stroke volume did not increase during dobutamine SE whereas EF increased.²⁴⁶ The insufficient preload of the ventricle could explain the lack of increase in stroke volume during exercise due to the baffles used for the atrial switch repair. Finally, Vogt *et al.* found a correlation between increase in myocardial acceleration during isovolumic contraction under dobutamine and the brain natriuretic peptide levels.²⁴⁷ In congenitally corrected transposition of the great arteries dobutamine infusion increased the overall wall motion less than in a healthy control group. During dobutamine stress, patients showed significantly less regional wall thickening than controls, particularly in the septal and in the anterior segments. In patients with congenitally corrected transposition, ischaemia of the RV myocardium may contribute to the development of RV dysfunction.

Key points

Dobutamine SE might be useful to evaluate in the systemic RV ventricular function, wall thickening, and regional myocardial wall motion abnormalities. Dobutamine stress-induced echocardiographic findings might correlate with patient's functional capacity and levels of neurohormones.

Training and competencies

While currently SE is used by a limited number of cardiology departments and echocardiography laboratories, the increase in evidence

increases demand and the increase in demand requires training of more operators. The usual technology and training requirements needed for application of SE to coronary artery disease also apply for other indications. The additional skills needed for SE assessment of the many conditions described in this document can be more difficult to acquire but are easier to measure and more amenable to quantification than regional wall motion assessment. Therefore, these applications may be less dependent upon the subjectivity of interpretation.⁴ The checklist for starting and maintaining an SE laboratory includes training requirements recommended by the American Society of Echocardiography (including training with at least 100 stress echo studies with supervision and maintenance of skills with > 15 studies per month, with more experience and higher volumes recommended for the specialized studies described in this document),² the requirements suggested by the Task Force of the ACC/AHA (including competence in cardiopulmonary resuscitation and knowledge of the advantages and disadvantages of the different agents), and staff and organization/equipment requirements as proposed by the European Association of Cardiovascular Imaging (including resuscitation facilities readily available and performing a minimum of 100 studies/year per laboratory).^{248–250} As an additional requirement, the Council on Cardiovascular Sonography of the American Society of Echocardiography recommends for cardiac sonographers a dedicated training course in radiation safety, since echocardiography (and more frequently SE) is often performed in radiation-emitting ('hot') patients injected with radionuclides for myocardial perfusion studies.²⁵⁰ This leads to a significant exposure (up to 0.5 mSv, around 25 chest X-rays) per exam to the sonographer,

with potential for significant cumulative risk in case of protracted exposure, especially worrying in women, young people, during pregnancy, and in individuals who may require additional time scanning, such as novice sonographers including students and fellows.²⁵⁰ Training in SE entails exposure to a mix of exercise and pharmacological stress testing, including patient selection, stress modality choice, stress test supervision, and integration of all diagnostic information.²⁵¹

The increased demand for SE activity posed by recent recommendations, growing concern about radiation exposure and the cost of alternative imaging techniques,²⁵² and the expansion of indications and applications of SE well beyond coronary artery disease can only be met with optimization of training, cardiology staff, and resources.

Summary and future directions

The indications for the clinical use of SE in non-ischaemic heart disease are continuously evolving. The test can be used in a serial manner in the assessment of a certain patient for diagnosis, risk stratification, follow-up, and evaluation of treatment. Whereas guidelines recommend the use of SE in the evaluation of many patients with dyspnoea, valvular heart disease, and HCM, further information is needed about the role of testing in patients with other cardiomyopathies, CHD, and PH. Information regarding the impact of testing on improving patient outcomes is needed. Additionally, efficiencies may be gained in some cases by combining SE with comprehensive transthoracic echocardiography,²⁵³ or by combining assessment of ischaemia with evaluation of other conditions. Deformation imaging and multidimensional imaging may also enhance the utility of SE. The versatility of SE is great and expanded use is likely.

Reviewers

This document was reviewed by members of the 2014–2016 EACVI Scientific Documents Committee, and external reviewers.

EACVI reviewers included: associate professor Kristina Haugaa, professor Bernard Cosyns, associate professor Maurizio Galderisi, professor Philipp A. Kaufmann, professor Nuno Cardim, doctor Denisa Muraru, doctor Massimo Lombardi, doctor Victoria Delgado, professor Luc Pierard, doctor Rosa Sicari.

This document was reviewed by members of the 2015–2016 ASE Guidelines & Standards Committee, the 2015–2016 ASE Board of Directors, and 2016–2017 Executive Committee.

ASE reviewers included Deborah A. Agler, RCT, RDCS, FASE, Federico M. Asch, MD, FASE, Merri L. Bremer, EdD, RN, EDCS, ACS, FASE, Benjamin Byrd, MD, FASE, Hollie D. Carron, RDCS, FASE, Frederick C. Cobey, MD, FASE, Meryl Cohen, MD, FASE, Benjamin Eidem, MD, FASE, Fadia Makarem Ezzeddine, RT, RCS, FASE, Craig Fleishman, MD, FASE, Neal Gerstein, MD, FASE, Yvonne E. Gilliland, MD, FASE, Aasha S. Gopal, MD, FASE, Sandra Hagen-Ansert, RDCS, RDMS, MS, FASE, Stephen Heitner, MD, FASE, Lanqi Hua, RDCS, FASE, Soo H. Kim, MD, MPH, RPVI, FASE, Allan L. Klein, MD, FASE, Joe R. Kreeger, ACS, RCCS, RDCS, FASE, Jonathan R. Lindner, MD, FASE, Sunil Mankad, MD, FASE, Tasneem Naqvi, MD, FASE, Maryellen H. Orsinelli, RN, RDCS, FASE, Andy Pellett,

PhD, RCS, RDCS, FASE, Patricia A. Pellikka, MD, FASE, Sue D. Phillip, RCS, FASE, Juan Carlos Plana, MD, FASE, Vera H. Rigolin, MD, FASE, Brad J. Roberts, ACS, RCS, FASE, Lawrence G. Rudski, MD, FASE, Vandana Sachdev, MD, FASE, Anita Sadeghpour, MD, FASE, Fadi Shamoun, MD, FASE, Elaine Shea, ACS, RCS, RCCS, FASE, Roman M. Sniecinski, MD, FASE, Raymond F. Stainback, MD, FASE, Cynthia Taub, MD, FASE, Steven Walling, RCS, RDCS, FASE, Neil J. Weissman, MD, FASE, Susan E. Wiegers, MD, FASE.

Notice and disclaimer: this report is made available by EACVI and ASE as a courtesy reference source for members. This report contains recommendations only and should not be used as the sole basis to make medical practice decisions or for disciplinary action against any employee. The statements and recommendations contained in this report are primarily based on the opinions of experts, rather than on scientifically verified data. EACVI and ASE make no express or implied warranties regarding the completeness or accuracy of the information in this report, including the warranty of merchantability or fitness for a particular purpose. In no event shall EACVI or ASE be liable to you, your patients, or any other third parties for any decision made or action taken by you or such other parties in reliance on this information. Nor does your use of this information constitute the offering of medical advice by EACVI/ASE or create any physician–patient relationship between EACVI/ASE and your patients or anyone else.

Supplementary data

Supplementary data are available at *European Heart Journal – Cardiovascular Imaging* online.

Conflict of interest: The following authors reported no actual or potential conflicts of interest relative to this document: Patrizio Lancellotti, MD, PhD, FESC, Patricia A. Pellikka, MD, FASE, Raluca Dulgheru, MD, Thor Edvardsen, MD, PhD, FESC, Madalina Garbi, MD, MA, Jong Won Ha, MD, PhD, FESC, Joe Kreeger, ACS, RCCS, RDCS, FASE, Luc Mertens, MD, PhD, FASE, Eugenio Picano, MD, PhD, Thomas Ryan, MD, FASE, Jeane M. Tsutsui, MD, PhD, Albert Varga, MD, PhD, FESC

The following authors reported relationships with one or more commercial interests: Werner Budts, MD, PhD received research support from Occlutech, St. Jude Medical, Actelion, and Pfizer; Farooq A. Chaudhry, MD, FASE consulted for Lantheus and GE, received a restricted fellowship grant from Bracco, and research grants from Bracco and GE; Erwan Donal, MD, PhD, FESC received a research grant from GE; Garvan C. Kane, MD, PhD, FASE consulted for Philips Healthcare; Philippe Pibarot, DVM, PhD, FASE, FESC received research grants from Edwards Lifesciences, Cardiac Phoenix, and V-Wave Ltd.

References

1. Sicari R, Nihoyannopoulos P, Evangelista A, Kasprzak J, Lancellotti P, Poldermans D *et al.* Stress echocardiography expert consensus statement – executive summary. *Eur Heart J* 2009;**30**:278–89.

2. Pellikka PA, Nagueh SF, Elhendy AA, Kuehl CA, Sawada SG. American Society of Echocardiography recommendations for performance, interpretation, and application of stress echocardiography. *J Am Soc Echocardiogr* 2007;**20**:1021–41.
3. Cheitlin MD. Stress echocardiography in mitral stenosis: when is it useful? *J Am Coll Cardiol* 2004;**43**:402–4.
4. Picano E, Pellikka PA. Stress echo applications beyond coronary artery disease. *Eur Heart J* 2014;**35**:1033–40.
5. Picano E, Mathias W Jr, Pingitore A, Bigi R, Previtali M. Safety and tolerability of dobutamine-atropine stress echocardiography: a prospective, multicentre study. Echo Dobutamine International Cooperative Study Group. *Lancet* 1994;**344**:1190–2.
6. Lattanzi F, Picano E, Adamo E, Varga A. Dobutamine stress echocardiography: safety in diagnosing coronary artery disease. *Drug Saf* 2000;**22**:251–62.
7. Varga A, Garcia MA, Picano E. Safety of stress echocardiography (from the International Stress Echo Complication Registry). *Am J Cardiol* 2006;**98**:541–3.
8. Kane GC, Hepinstall MJ, Kidd GM, Kuehl CA, Murphy AT, Nelson JM et al. Safety of stress echocardiography supervised by registered nurses: results of a 2-year audit of 15,404 patients. *J Am Soc Echocardiogr* 2008;**21**:337–41.
9. Wuthiwaropas P, Wiste JA, McCully RB, Kane GC, Scott CG, Pellikka PA. Neuro-psychiatric symptoms during 24 hours after dobutamine-atropine stress testing: a prospective study in 1,006 patients. *J Am Soc Echocardiogr* 2011;**24**:367–73.
10. Varga A, Picano E, Lakatos F. Fatal ventricular fibrillation during a low-dose dobutamine stress test. *Am J Med* 2000;**108**:352–3.
11. Poliner LR, Dehmer GJ, Lewis SE, Parkey RW, Blomqvist CG, Willerson JT. Left ventricular performance in normal subjects: a comparison of the responses to exercise in the upright and supine positions. *Circulation* 1980;**62**:528–34.
12. Cortigiani L, Rigo F, Gherardi S, Galderisi M, Sicari R, Picano E. Prognostic implications of coronary flow reserve in left anterior descending coronary artery in hypertrophic cardiomyopathy. *Am J Cardiol* 2008;**102**:926–32.
13. Lowenstein JA, Canigga C, Rousse G, Amor M, Sánchez ME, Alasia D et al. Coronary flow velocity reserve during pharmacologic stress echocardiography with normal contractility adds important prognostic value in diabetic and nondiabetic patients. *J Am Soc Echocardiogr* 2014;**27**:1113–9.
14. Duncker DJ, Bache RJ. Regulation of coronary blood flow during exercise. *Physiol Rev* 2008;**88**:1009–86.
15. Bombardini T, Costantino MF, Sicari R, Ciampi Q, Pratali L, Picano E. End-systolic elastance and ventricular-arterial coupling reserve predict cardiac events in patients with negative stress echocardiography. *Biomed Res Int* 2013;**2013**:235194.
16. Ling LH, Christian TF, Mulvagh SL, Klarich KW, Hauser MF, Nishimura RA et al. Determining myocardial viability in chronic ischemic left ventricular dysfunction: A prospective comparison of rest-redistribution thallium 201 single-photon emission computed tomography, nitroglycerin-dobutamine echocardiography, and intracoronary myocardial contrast echocardiography. *Am Heart J* 2006;**151**:882–9.
17. Lin SS, Roger VL, Pascoe R, Seward JB, Pellikka PA. Dobutamine stress Doppler hemodynamics in patients with aortic stenosis: feasibility, safety, and surgical correlations. *Am Heart J* 1998;**136**:1010–6.
18. Abdelmoneim SS, Bernier M, Scott CG, Dhoble A, Ness SA, Hagen ME et al. Safety of contrast agent use during stress echocardiography in patients with elevated right ventricular systolic pressure: a cohort study. *Circ Cardiovasc Imaging* 2010;**3**:240–8.
19. Vasan RS, Larson MG, Benjamin EJ, Evans JC, Reiss C, Levy D. Congestive heart failure in subjects with normal versus reduced left ventricular ejection fraction: prevalence and mortality in a population-based cohort. *J Am Coll Cardiol* 1999;**33**:1948–55.
20. Senni M, Tribouilloy CM, Rodeheffer RJ, Jacobsen SJ, Evans JM, Bailey KR et al. Congestive heart failure in the community: a study of all incident cases in Olmsted County, Minnesota, in 1991. *Circulation* 1998;**98**:2282–9.
21. Ha JW, Oh JK, Pellikka PA, Ommen SR, Stussy VL, Bailey KR et al. Diastolic stress echocardiography: a novel noninvasive diagnostic test for diastolic dysfunction using supine bicycle exercise Doppler echocardiography. *J Am Soc Echocardiogr* 2005;**18**:63–8.
22. Burgess MI, Jenkins C, Sharman JE, Marwick TH. Diastolic stress echocardiography: hemodynamic validation and clinical significance of estimation of ventricular filling pressure with exercise. *J Am Coll Cardiol* 2006;**47**:1891–900.
23. Nagueh SF, Smiseth OA, Appleton CP, Byrd III BF, Dokainish H, Edvardsen T et al. Recommendations for the evaluation of left ventricular diastolic function by echocardiography: an update from the American Society of Echocardiography (ASE) and the European Association of Cardiovascular Imaging (EACVI). *Eur Heart J Cardiovasc Imaging* 2016, pii:ijew082.
24. Choi EY, Shim CY, Kim SA, Rhee SJ, Choi D, Rim SJ et al. Passive leg-raise is helpful to identify impaired diastolic functional reserve during exercise in patients with abnormal myocardial relaxation. *J Am Soc Echocardiogr* 2010;**23**:523–30.
25. Ha JW, Lulic F, Bailey KR, Pellikka PA, Seward JB, Tajik AJ et al. Effects of treadmill exercise on mitral inflow and annular velocities in healthy adults. *Am J Cardiol* 2003;**91**:114–5.
26. Oh JK, Kane GC. Diastolic stress echocardiography: the time has come for its integration into clinical practice. *J Am Soc Echocardiogr* 2014;**27**:1060–3.
27. Kane GC, Sachdev A, Villarraga HR, Ammash NM, Oh JK, McGoon MD et al. Impact of age on pulmonary artery systolic pressures at rest and with exercise. *Echo Res Pract* 2016;**3**:53–61.
28. Ha JW, Choi D, Park S, Shim CY, Kim JM, Moon SH et al. Determinants of exercise-induced pulmonary hypertension in patients with normal left ventricular ejection fraction. *Heart* 2009;**95**:490–4.
29. Caballero L, Kou S, Dulgheru R, Gonjilashvili N, Athanassopoulos GD, Barone D et al. Echocardiographic reference ranges for normal cardiac Doppler data: results from the NORRE Study. *Eur Heart J Cardiovasc Imaging* 2015;**16**:1031–41.
30. Bossone E, Rubenfire M, Bach DS, Ricciardi M, Armstrong WF. Range of tricuspid regurgitation velocity at rest and during exercise in normal adult men: implications for the diagnosis of pulmonary hypertension. *J Am Coll Cardiol* 1999;**33**:1662–3.
31. Rudski LG, Lai WW, Afialo J, Hua L, Handschumacher MD, Chandrasekaran K et al. Guidelines for the echocardiographic assessment of the right heart in adults: a report from the American Society of Echocardiography. *J Am Soc Echocardiogr* 2010;**23**:685–713.
32. Shim CY, Kim SA, Choi D, Yang WI, Kim JM, Moon SH et al. Clinical outcomes of exercise-induced pulmonary hypertension in subjects with preserved left ventricular ejection fraction: implication of an increase in left ventricular filling pressure during exercise. *Heart* 2011;**97**:1417–24.
33. Holland DJ, Prasad SB, Marwick TH. Prognostic implications of left ventricular filling pressure with exercise. *Circ Cardiovasc Imaging* 2010;**3**:149–56.
34. Gorcsan J III, Deswal A, Mankad S, Mandarino WA, Mahler CM, Yamazaki N, Katz WE. Quantification of the myocardial response to low-dose dobutamine using tissue Doppler echocardiographic measures of velocity and velocity gradient. *Am J Cardiol* 1998;**81**:615–23.
35. Duncan AM, Lim E, Gibson DG, Heinlein MY. Effect of dobutamine stress on left ventricular filling in ischemic dilated cardiomyopathy: pathophysiology and prognostic implications. *J Am Coll Cardiol* 2005;**46**:488–96.
36. Elliott PM, Anastasakis A, Borger MA, Borggrefe M, Cecchi F, Charron P et al. 2014 ESC Guidelines on diagnosis and management of hypertrophic cardiomyopathy: the task force for the diagnosis and management of hypertrophic cardiomyopathy of the European Society of Cardiology (ESC). *Eur Heart J* 2014;**35**:2733–79.
37. Cardim N, Galderisi M, Edvardsen T, Plein S, Popescu BA, D'Andrea A et al. Role of multimodality cardiac imaging in the management of patients with hypertrophic cardiomyopathy: an expert consensus of the European Association of Cardiovascular Imaging Endorsed by the Saudi Heart Association. *Eur Heart J Cardiovasc Imaging* 2015;**16**:280.
38. Argulian E, Chaudhry FA. Stress testing in patients with hypertrophic cardiomyopathy. *Prog Cardiovasc Dis* 2012;**54**:477–82.
39. Gersh BJ, Maron BJ, Bonow RO, Dearani JA, Fifer MA, Link MS et al. 2011 ACCF/AHA guideline for the diagnosis and treatment of hypertrophic cardiomyopathy: a report of the American College of Cardiology Foundation/American Heart Association Task Force on Practice Guidelines. *J Am Coll Cardiol* 2011;**58**:e212–60.
40. Nistri S, Olivetto I, Maron MS, Ferrantini C, Coppini R, Grifoni C et al. β Blockers for prevention of exercise-induced left ventricular outflow tract obstruction in patients with hypertrophic cardiomyopathy. *Am J Cardiol* 2012;**110**:715–9.
41. Maron BJ, Ommen SR, Semsarian C, Spirito P, Olivetto I, Maron MS. Hypertrophic cardiomyopathy: present and future, with translation into contemporary cardiovascular medicine. *J Am Coll Cardiol* 2014;**64**:83–99.
42. Maron BJ, Rowin EJ, Casey SA, Link M, Lesser JR, Chan RH et al. Hypertrophic cardiomyopathy in adulthood associated with low cardiovascular mortality with contemporary management strategies. *J Am Coll Cardiol* 2015;**65**:1915–28.
43. Spirito P. The dawn of a better day for patients with hypertrophic cardiomyopathy. *J Am Coll Cardiol* 2015;**65**:1929–30.
44. Pellikka PA, Oh JK, Bailey KR, Nichols BA, Monahan KH, Tajik AJ. Dynamic intraventricular obstruction during dobutamine stress echocardiography. A new observation. *Circulation* 1992;**86**:1429–32.
45. Marwick TH, Nakatani S, Haluska B, Thomas JD, Lever HM. Provocation of latent left ventricular outflow tract gradients with amyl nitrite and exercise in hypertrophic cardiomyopathy. *Am J Cardiol* 1995;**75**:805–9.
46. Feiner E, Arabadjian M, Winson G, Kim B, Chaudhry F, Sherrid MV. Post-prandial upright exercise echocardiography in hypertrophic cardiomyopathy. *J Am Coll Cardiol* 2013;**61**:2487–8.
47. Maron BJ, Maron MS, Wigle ED, Braunwald E. The 50-year history, controversies, and clinical implications of left ventricular outflow tract obstruction in hypertrophic cardiomyopathy from idiopathic hypertrophic subaortic stenosis to hypertrophic cardiomyopathy: from idiopathic hypertrophic subaortic stenosis to hypertrophic cardiomyopathy. *J Am Coll Cardiol* 2009;**54**:191–200.
48. Panza JA, Maris TJ, Maron BJ. Development and determinants of dynamic obstruction to left ventricular outflow in young patients with hypertrophic cardiomyopathy. *Circulation* 1992;**85**:1398–405.

49. Peteiro J, Fernandez X, Bouzas-Mosquera A, Monserrat L, Méndez C, Rodriguez-García E *et al*. Exercise echocardiography and cardiac magnetic resonance imaging to predict outcome in patients with hypertrophic cardiomyopathy. *Eur Heart J Cardiovasc Imaging* 2015;**16**:423–32.
50. Yu EH, Omran AS, Wigle ED, Williams WG, Siu SC, Rakowski H. Mitral regurgitation in hypertrophic obstructive cardiomyopathy: relationship to obstruction and relief with myectomy. *J Am Coll Cardiol* 2000;**36**:2219–25.
51. Desai MY, Bhonsale A, Patel P, Naji P, Smedira NG, Thamilarasan M *et al*. Exercise echocardiography in asymptomatic HCM: exercise capacity, and not LV outflow tract gradient predicts long-term outcomes. *JACC Cardiovascular imaging* 2014;**7**:26–36.
52. Donal E, Rozoy T, Kervio G, Schnell F, Mabo P, Carre F. Comparison of the heart function adaptation in trained and sedentary men after 50 and before 35 years of age. *Am J Cardiol* 2011;**108**:1029–37.
53. Schnell F, Donal E, Bernard-Brunet A, Reynaud A, Wilson MG, Thebault C *et al*. Strain analysis during exercise in patients with left ventricular hypertrophy: impact of etiology. *J Am Soc Echocardiogr* 2013;**26**:1163–9.
54. Barac I, Upadya S, Pilchik R, Winson G, Passick M, Chaudhry FA *et al*. Effect of obstruction on longitudinal left ventricular shortening in hypertrophic cardiomyopathy. *J Am Coll Cardiol* 2007;**49**:1203–11.
55. Butz T, van Buuren F, Mellwig KP, Langer C, Plehn G, Meissner A *et al*. Two-dimensional strain analysis of the global and regional myocardial function for the differentiation of pathologic and physiologic left ventricular hypertrophy: a study in athletes and in patients with hypertrophic cardiomyopathy. *Int J Cardiovasc Imaging* 2011;**27**:91–100.
56. Lafitte S, Reant P, Touche C, Pillois X, Dijos M, Arsac F *et al*. Paradoxical response to exercise in asymptomatic hypertrophic cardiomyopathy: a new description of outflow tract obstruction dynamics. *J Am Coll Cardiol* 2013;**62**:842–50.
57. Reant P, Reynaud A, Pillois X, Dijos M, Arsac F, Touche C *et al*. Comparison of resting and exercise echocardiographic parameters as indicators of outcomes in hypertrophic cardiomyopathy. *J Am Soc Echocardiogr* 2015;**28**:194–203.
58. Sugrue DD, Rodeheffer RJ, Codd MB, Ballard DJ, Fuster V, Gersh BJ. The clinical course of idiopathic dilated cardiomyopathy: a population based study. *Ann Intern Med* 1992;**117**:117–23.
59. Suwa M, Otake Y, Moriguchi A, Ito T, Hirota Y, Kawamura K *et al*. Iodine-123 metaiodobenzylguanidine myocardial scintigraphy for prediction of response to beta blocker therapy in patients with dilated cardiomyopathy. *Am Heart J* 1997;**133**:353–8.
60. Kawano S, Iida K, Fujieda K, Iida K, Fujieda K, Yukisada K *et al*. Response to isoproterenol as a prognostic indicator of evolution from hypertrophic cardiomyopathy to a phase resembling dilated cardiomyopathy. *J Am Coll Cardiol* 1995;**25**:687–92.
61. Ryerson AB, Border WL, Wasilewski-Masker K, Goodman M, Meacham L, Austin H *et al*. Assessing anthracycline-treated childhood cancer survivors with advanced stress echocardiography. *Pediatr Blood Cancer* 2015;**62**:502–8.
62. Civelli M, Cardinale D, Martinoni A, Lamantia G, Colombo N, Colombo A *et al*. Early reduction in left ventricular contractile reserve detected by dobutamine stress echo predicts high-dose chemotherapy-induced cardiac toxicity. *Int J Cardiol* 2006;**111**:120–6.
63. Cheung YF, Yu W, Li SN, Lam WW, Ho YC, Wong SJ *et al*. Dynamic dyssynchrony and impaired contractile reserve of the left ventricle in beta-thalassaemia major: an exercise echocardiographic study. *PLoS One* 2012;**7**:e45265.
64. Park S, Seo HS, Shim CY, Choi EY, Ko YG, Choi D *et al*. Effect of geometric remodeling on left ventricular longitudinal contractile reserve in patients with hypertension. *J Am Soc Echocardiogr* 2008;**21**:246–50.
65. Galderisi M, de Simone G, Innelli P, Turco A, Turco S, Capaldo B *et al*. Impaired inotropic response in type 2 diabetes mellitus: a strain rate imaging study. *Am J Hypertens* 2007;**20**:548–55.
66. Agricola E, Oppizzi M, Pisani M, Margonato A. Stress echocardiography in heart failure. *Cardiovasc Ultrasound* 2004;**2**:11.
67. Pratali L, Picano E, Otašević P, Vigna C, Palinkas A, Cortigiani L *et al*. Prognostic significance of the dobutamine echocardiography test in idiopathic dilated cardiomyopathy. *Am J Cardiol* 2001;**88**:1374–8.
68. Pratali L, Otasevic P, Neskovic A, Molinaro S, Picano E. Prognostic value of pharmacologic stress echocardiography in patients with idiopathic dilated cardiomyopathy: a prospective, head-to-head comparison between dipyridamole and dobutamine test. *J Cardiac Failure* 2007;**13**:836–42.
69. Zile MR, Kjellstrom B, Bennett T, Cho Y, Baicu CF, Aaron MF *et al*. Effects of exercise on left ventricular systolic and diastolic properties in patients with heart failure and a preserved ejection fraction versus heart failure and a reduced ejection fraction. *Circ Heart Fail* 2013;**6**:508–16.
70. Borlaug BA, Melenovsky V, Russell SD, Kessler K, Pacak K, Becker LC *et al*. Impaired chronotropic and vasodilator reserves limit exercise capacity in patients with heart failure and a preserved ejection fraction. *Circulation* 2006;**114**:2138–47.
71. Paraskevidis IA, Adamopoulos S, Kremastinos TH. Dobutamine echocardiographic study in patients with non-ischemic dilated cardiomyopathy and prognostical borderline values of peak exercise oxygen consumption: 18-month follow-up study. *J Am Coll Cardiol* 2001;**37**:1685–91.
72. Scrutinio D, Napoli V, Passantino A, Ricci A, Lajoià R, Rizzon P. Low-dose dobutamine responsiveness in idiopathic dilated cardiomyopathy: relation to exercise capacity and clinical outcome. *Eur Heart J* 2000;**21**:927–34.
73. Jourdain P, Funck F, Fulla Y, Hagege A, Bellorini M, Guillard N *et al*. Myocardial contractile reserve under low doses of dobutamine and improvement of left ventricular ejection fraction with treatment by carvedilol. *Eur J Heart Fail* 2002;**4**:269–76.
74. Drozd J, Krzeminska-Pakula M, Plewka M, Ciesielczyk M, Kasprzak JD. Prognostic value of low-dose dobutamine echocardiography in patients with dilated cardiomyopathy. *Chest* 2002;**121**:1216–22.
75. Cifra B, Dragulescu A, Brun H, Slorach C, Friedberg MK, Manlhiot C *et al*. Left ventricular myocardial response to exercise in children after heart transplant. *J Heart Lung Transplant* 2014;**33**:1241–7.
76. Sebbag L, Bergerot C, Jamal F, Roussoulières A, Boissonnat P, Bastien O *et al*. Alteration of the left ventricular contractile reserve in heart transplant patients: a dobutamine stress strain rate imaging study. *Transplant Proc* 2003;**35**:3072–4.
77. Nagueh SF, Mikati I, Weilbaeher D, Reardon MJ, Al-Zaghri GJ, Cacela D *et al*. Relation of the contractile reserve of hibernating myocardium to myocardial structure in humans. *Circulation* 1999;**100**:490–6.
78. Effect of metoprolol CR/XL in chronic heart failure: Metoprolol CR/XL Randomized Intervention Trial in Congestive Heart Failure (MERIT-HF). *Lancet* 1999;**353**:2001–7.
79. Rigo F, Gherardi S, Galderisi M, Sicari R, Picano E. The independent prognostic value of contractile and coronary flow reserve determined by dipyridamole stress echocardiography in patients with idiopathic dilated cardiomyopathy. *Am J Cardiol* 2007;**99**:1154–8.
80. Pratali L, Otasevic P, Rigo F, Gherardi S, Neskovic A, Picano E. The additive prognostic value of restrictive pattern and dipyridamole-induced contractile reserve in idiopathic dilated cardiomyopathy. *Eur J Heart Fail* 2005;**7**:844–51.
81. Anderson KL, Jenq KY, Fields JM, Panebianco NL, Dean AJ. Diagnosing heart failure among acutely dyspneic patients with cardiac, inferior vena cava, and lung ultrasonography. *Am J Emerg Med* 2013;**31**:1208–14.
82. Miglioranza MH, Gargani L, Sant'Anna RT, Rover MM, Martins VM, Mantovani A *et al*. Lung ultrasound for the evaluation of pulmonary congestion in outpatients: a comparison with clinical assessment, natriuretic peptides, and echocardiography. *JACC Cardiovasc Imaging* 2013;**6**:1141–51.
83. Picano E, Frassi F, Agricola E, Gligorova S, Gargani L, Mottola G. Ultrasound lung comets: a clinically useful sign of extravascular lung water. *J Am Soc Echocardiogr* 2006;**19**:356–63.
84. Agricola E, Picano E, Oppizzi M, Pisani M, Meris A, Fragasso G *et al*. Assessment of stress-induced pulmonary interstitial edema by chest ultrasound during exercise echocardiography and its correlation with left ventricular function. *J Am Soc Echocardiogr* 2006;**19**:457–63.
85. Amanullah AM, Chaudhry FA, Heo J, Galatro K, Dourdoufis P, Brozana S *et al*. Comparison of dobutamine echocardiography, dobutamine sestamibi, and rest-redistribution thallium-201 single-photon emission computed tomography for determining contractile reserve and myocardial ischemia in ischemic cardiomyopathy. *Am J Cardiol* 1999;**84**:626–31.
86. Franchini M, Traversi E, Cannizzaro G, Cobelli F, Pozzoli M. Dobutamine stress echocardiography and thallium-201 SPECT for detecting ischaemic dilated cardiomyopathy in patients with heart failure. *Eur J Echocardiogr* 2000;**1**:109–15.
87. Duncan AM, Francis DP, Gibson DG, Henein MY. Differentiation of ischemic from non-ischemic cardiomyopathy during dobutamine stress by left ventricular long-axis function: additional effect of left bundle branch block. *Circulation* 2003;**108**:1214–20.
88. Ypenburg C, Sieders A, Bleeker GB, Holman ER, van der Wall EE, Schalij MJ *et al*. Myocardial contractile reserve predicts improvement in left ventricular function after cardiac resynchronization therapy. *Am Heart J* 2007;**154**:1160–5.
89. Muñir P, Mitro P, Valocik G, Spurný P. Global myocardial contractile reserve assessed by high-dose dobutamine stress echocardiography predicts response to the cardiac resynchronization therapy. *Echocardiography* 2015;**32**:490–5.
90. Mizia-Stec K, Wita K, Mizia M, Szwed H, Nowalany-Kozielska E, Chrzanowski Ł *et al*. Preserved contractile reserve in a dobutamine test for the prediction of a response to resynchronization therapy in ischaemic and non-ischaemic cardiomyopathy – a multicenter ViaCRT study. *Int J Cardiol* 2014;**172**:476–7.
91. Gasparini M, Muto C, Iacopino S, Zanon F, Dicandia C, Distefano G *et al*. Low-dose dobutamine test associated with interventricular dyssynchrony: a useful tool to identify cardiac resynchronization therapy responders: data from the LOW dose DObutamine stress-echo test in Cardiac Resynchronization Therapy (LODO-CRT) phase 2 study. *Am Heart J* 2012;**163**:422–9.

92. Chaudhry FA, Shah A, Bangalore S, DeRose J, Steinberg JS. Inotropic contractile reserve and response to cardiac resynchronization therapy in patients with markedly remodeled left ventricle. *J Am Soc Echocardiogr* 2011;**24**:91–7.
93. Sénéchal M, Lancellotti P, Magne J, Garceau P, Champagne J, Blier L et al. Contractile reserve assessed using dobutamine echocardiography predicts left ventricular reverse remodeling after cardiac resynchronization therapy: prospective validation in patients with left ventricular dyssynchrony. *Echocardiography* 2010;**27**:668–76.
94. Sénéchal M, Lancellotti P, Garceau P, Champagne J, Dubois M, Magne J et al. Usefulness and limitation of dobutamine stress echocardiography to predict acute response to cardiac resynchronization therapy. *Echocardiography* 2010;**27**:50–7.
95. Ciampi Q, Pratali L, Citro R, Piacenti M, Villari B, Picano E. Identification of responders to cardiac resynchronization therapy by contractile reserve during stress echocardiography. *Eur J Heart Fail* 2009;**11**:489–96.
96. Lancellotti P, Sénéchal M, Moonen M, Donal E, Magne J, Nellessen E et al. Myocardial contractile reserve during exercise predicts left ventricular reverse remodeling after cardiac resynchronization therapy. *Eur J Echocardiogr* 2009;**10**:663–8.
97. Parsai C, Baltabaeva A, Anderson L, Chaparro M, Bijns B, Sutherland GR. Low-dose dobutamine stress echo to quantify the degree of remodeling after cardiac resynchronization therapy. *Eur Heart J* 2009;**30**:950–8.
98. Ghani A, Delnoy PP, Ottervanger JP, Ramdat Misier AR, Smit JJ, Adiyaman A et al. Association of apical rocking with long-term major adverse cardiac events in patients undergoing cardiac resynchronization therapy. *Eur Heart J Cardiovasc Imaging* 2015;**17**:146–53.
99. Ghani A, Delnoy PP, Ottervanger JP, Misier AR, Smit JJ, Adiyaman A et al. Apical rocking is predictive of response to cardiac resynchronization therapy. *Int J Cardiovasc Imaging* 2015;**31**:717–25.
100. Stankovic I, Aaronson M, Smith HJ, Vörös G, Kongsgaard E, Neskovic AN et al. Dynamic relationship of left-ventricular dyssynchrony and contractile reserve in patients undergoing cardiac resynchronization therapy. *Eur Heart J* 2014;**35**:48–55.
101. Tournoux F, Singh JP, Chan RC, Chen-Tournoux A, McCarty D, Manzke R et al. Absence of left ventricular apical rocking and atrial-ventricular dyssynchrony predicts non-response to cardiac resynchronization therapy. *Eur Heart J Cardiovasc Imaging* 2012;**13**:86–94.
102. Packer M, Fowler MB, Roecker EB, Coats AJ, Katus HA, Krum H et al. Carvedilol Prospective Randomized Cumulative Survival (COPERNICUS) Study Group. Effect of carvedilol on the morbidity of patients with severe chronic heart failure: results of the carvedilol prospective randomized cumulative survival (COPERNICUS) study. *Circulation* 2002;**106**:2194–9.
103. Seghato F, Shah DJ, Diluzio S, Bello D, Johnson MR, Cotts WG et al. Relation between contractile reserve and improvement in left ventricular function with beta-blocker therapy in patients with heart failure secondary to ischemic or idiopathic dilated cardiomyopathy. *Am J Cardiol* 2004;**93**:854–9.
104. Eichhorn EJ, Grayburn PA, Mayer SA, St John Sutton M, Appleton C, Plehn J et al. Myocardial contractile reserve by dobutamine stress echocardiography predicts improvement in ejection fraction with beta-blockade in patients with heart failure: the Beta-Blocker Evaluation of Survival Trial (BEST). *Circulation* 2003;**108**:2336–41.
105. Garbi M, Chambers J, Vannan MA, Lancellotti P. Valve stress echocardiography: a practical guide for referral, procedure, reporting, and clinical implementation of results from the HAVEC Group. *JACC Cardiovasc Imaging* 2015;**8**:724–36.
106. Picano E, Pibarot P, Lancellotti P, Monin JL, Bonow RO. The emerging role of exercise testing and stress echocardiography in valvular heart disease. *J Am Coll Cardiol* 2009;**54**:2251–60.
107. Pierard LA, Lancellotti P. Stress testing in valve disease. *Heart* 2007;**93**:766–72.
108. Vahanian A, Alfieri O, Andreotti F, Antunes MJ, Baron-Esquivias G, Baumgartner H et al. Guidelines on the management of valvular heart disease. *Eur Heart J* 2012;**33**:2451–96.
109. Nishimura RA, Otto CM, Bonow RO, Carabello BA, Erwin III JP, Guyton RA et al. 2014 AHA/ACC guideline for the management of patients with valvular heart disease. *J Am Coll Cardiol* 2014;**22**:e57–185.
110. deFilippi CR, Willett DL, Brickner ME, Appleton CP, Yancy CW, Eichhorn EJ et al. Usefulness of dobutamine echocardiography in distinguishing severe from nonsevere valvular aortic stenosis in patients with depressed left ventricular function and low transvalvular gradients. *Am J Cardiol* 1995;**75**:191–4.
111. Lancellotti P, Fattouch K, La Canna G. Therapeutic decision-making for patients with fluctuating mitral regurgitation. *Nat Rev Cardiol* 2015;**12**:212–9.
112. Lancellotti P, Magne J. Stress echocardiography in regurgitant valve disease. *Circ Cardiovasc Imaging* 2013;**6**:840–9.
113. Izumo M, Suzuki K, Moonen M, Kou S, Shimozato T, Hayashi A et al. Changes in mitral regurgitation and left ventricular geometry during exercise affect exercise capacity in patients with systolic heart failure. *Eur J Echocardiogr* 2011;**12**:54–60.
114. Yamano T, Nakatani S, Kanzaki H, Toh N, Amaki M, Tanaka J et al. Exercise-induced changes of functional mitral regurgitation in asymptomatic or mildly symptomatic patients with idiopathic dilated cardiomyopathy. *Am J Cardiol* 2008;**102**:481–5.
115. Giga V, Ostojic M, Vujisic-Tesic B, Djordjevic-Dikic A, Stepanovic J, Belesin B et al. Exercise-induced changes in mitral regurgitation in patients with prior myocardial infarction and left ventricular dysfunction: relation to mitral deformation and left ventricular function and shape. *Eur Heart J* 2005;**26**:1860–5.
116. Lebrun F, Lancellotti P, Piérard LA. Quantitation of functional mitral regurgitation during bicycle exercise in patients with heart failure. *J Am Coll Cardiol* 2001;**38**:1685–92.
117. Magne J, Lancellotti P, Pierard LA. Exercise-induced changes in degenerative mitral regurgitation. *J Am Coll Cardiol* 2010;**56**:300–9.
118. Coisne A, Levy F, Malaquin D, Richardson M, Quéré JP, Montaigne D et al. Feasibility of Doppler hemodynamic evaluation of primary and secondary mitral regurgitation during exercise echocardiography. *Int J Cardiovasc Imaging* 2015;**31**:291–9.
119. Magne J, Lancellotti P, Pierard LA. Exercise pulmonary hypertension in asymptomatic degenerative mitral regurgitation. *Circulation* 2010;**122**:33–41.
120. Magne J, Pibarot P, Sengupta PP, Donal E, Rosenhek R, Lancellotti P. Pulmonary hypertension in valvular disease: a comprehensive review on pathophysiology to therapy from the HAVEC Group. *JACC Cardiovasc Imaging* 2015;**8**:83–99.
121. Suzuki K, Izumo M, Yoneyama K, Mizukoshi K, Kamijima R, Kou S et al. Influence of exercise-induced pulmonary hypertension on exercise capacity in asymptomatic degenerative mitral regurgitation. *J Cardiol* 2015;**66**:246–52.
122. Magne J, Donal E, Mahjoub H, Miltner B, Dulgheru R, Thebault C et al. Impact of exercise pulmonary hypertension on postoperative outcome in primary mitral regurgitation. *Heart* 2015;**101**:391–6.
123. Kusunose K, Popović ZB, Motoki H, Marwick TH. Prognostic significance of exercise-induced right ventricular dysfunction in asymptomatic degenerative mitral regurgitation. *Circ Cardiovasc Imaging* 2013;**6**:167–76.
124. Lee R, Haluska B, Leung DY, Case C, Mundy J, Marwick TH. Functional and prognostic implications of left ventricular contractile reserve in patients with asymptomatic severe mitral regurgitation. *Heart* 2005;**91**:1407–12.
125. Haluska BA, Short L, Marwick TH. Relationship of ventricular longitudinal function to contractile reserve in patients with mitral regurgitation. *Am Heart J* 2003;**146**:183–8.
126. Magne J, Mahjoub H, Dulgheru R, Pibarot P, Pierard LA, Lancellotti P. Left ventricular contractile reserve in asymptomatic primary mitral regurgitation. *Eur Heart J* 2014;**35**:1608–16.
127. Donal E, Mascle S, Brunet A, Thebault C, Corbineau H, Laurent M et al. Prediction of left ventricular ejection fraction 6 months after surgical correction of organic mitral regurgitation: the value of exercise echocardiography and deformation imaging. *Eur Heart J Cardiovasc Imaging* 2012;**13**:922–30.
128. Lancellotti P, Cosyns B, Zacharakis D, Attena E, Van Camp G, Gach O et al. Importance of left ventricular longitudinal function and functional reserve in patients with degenerative mitral regurgitation: assessment by two-dimensional speckle tracking. *J Am Soc Echocardiogr* 2008;**21**:1331–6.
129. Paraskevidis IA, Kyrzopoulos S, Tsiapras D, Iliodromitis EK, Parissis J, Farmakis D et al. The role of left ventricular long-axis contraction in patients with asymptomatic non-ischemic mitral valve regurgitation and normal systolic function. *Int J Cardiol* 2008;**124**:64–71.
130. Piérard LA, Lancellotti P. The role of ischemic mitral regurgitation in the pathogenesis of acute pulmonary edema. *N Engl J Med* 2004;**351**:1627–34.
131. Lancellotti P, Lebrun F, Piérard LA. Determinants of exercise-induced changes in mitral regurgitation in patients with coronary artery disease and left ventricular dysfunction. *J Am Coll Cardiol* 2003;**42**:1921–8.
132. Lancellotti P, Troisfontaines P, Toussaint AC, Pierard LA. Prognostic importance of exercise-induced changes in mitral regurgitation in patients with chronic ischemic left ventricular dysfunction. *Circulation* 2003;**108**:1713–7.
133. Lancellotti P, Gérard PL, Piérard LA. Long-term outcome of patients with heart failure and dynamic functional mitral regurgitation. *Eur Heart J* 2005;**26**:1528–32.
134. Lapu-Bula R, Robert A, Van Craeynest D, D'Hondt AM, Gerber BL, Pasquet A et al. Contribution of exercise-induced mitral regurgitation to exercise stroke volume and exercise capacity in patients with left ventricular systolic dysfunction. *Circulation* 2002;**106**:1342–8.
135. Lancellotti P, Magne J, Dulgheru R, Ancion A, Martinez C, Piérard LA. Clinical significance of exercise pulmonary hypertension in secondary mitral regurgitation. *Am J Cardiol* 2015;**115**:1454–61.
136. Bonow RO, Lakatos E, Maron BJ, Epstein SE. Serial long-term assessment of the natural history of asymptomatic patients with chronic aortic regurgitation and normal left ventricular systolic function. *Circulation* 1991;**84**:1625–35.
137. Wahi S, Haluska B, Pasquet A, Case C, Rimmerman CM, Marwick TM. Exercise echocardiography predicts development of left ventricular dysfunction in medically and surgically treated patients with asymptomatic severe aortic regurgitation. *Heart* 2000;**84**:606–14.

138. Vinereanu D, Ionescu AA, Fraser AG. Assessment of left ventricular long-axis contraction can detect early myocardial dysfunction in asymptomatic patients with severe aortic regurgitation. *Heart* 2001;**85**:30–6.
139. Carabello BA. Modern management of mitral stenosis. *Circulation* 2005;**112**:432–7.
140. Schwammenthal E, Vered Z, Agranat O, Kaplinsky E, Rabinowitz B, Feinberg MS. Impact of atrioventricular compliance on pulmonary artery pressure in mitral stenosis: an exercise echocardiographic study. *Circulation* 2000;**102**:2378–84.
141. Brochet E, Détaint D, Fondard O, Tazi-Mezalek A, Messika-Zeitoun D, Lung B *et al*. Early hemodynamic changes versus peak values: what is more useful to predict occurrence of dyspnea during stress echocardiography in patients with asymptomatic mitral stenosis? *J Am Soc Echocardiogr* 2011;**24**:392–8.
142. Reis G, Motta MS, Barbosa MM, Esteves WA, Souza SF, Bocchi EA. Dobutamine stress echocardiography for noninvasive assessment and risk stratification of patients with rheumatic mitral stenosis. *J Am Coll Cardiol* 2004;**43**:393–401.
143. Cheriex EC, Pieters FA, Janssen JH, de Swart H, Palmans-Meulemans A. Value of exercise Doppler-echocardiography in patients with mitral stenosis. *Int J Cardiol* 1994;**45**:219–26.
144. Grimaldi A, Olivetto I, Figini F, Pappalardo F, Capritti E, Ammirati E *et al*. Dynamic assessment of 'valvular reserve capacity' in patients with rheumatic mitral stenosis. *Eur Heart J Cardiovasc Imaging* 2012;**13**:476–82.
145. Aviles RJ, Nishimura RA, Pellikka PA, Andreen KM, Holmes DR Jr. Utility of stress Doppler echocardiography in patients undergoing percutaneous mitral balloon valvotomy. *J Am Soc Echocardiogr* 2001;**14**:676–81.
146. Baumgartner H, Hung J, Bermejo J, Chambers JB, Evangelista A, Griffin BP *et al*. Echocardiographic assessment of valve stenosis: EAE/ASE recommendations for clinical practice. *J Am Soc Echocardiogr* 2009;**22**:1–23.
147. Lancellotti P, Karsera D, Tumminello G, Lebois F, Pierard LA. Determinants of an abnormal response to exercise in patients with asymptomatic valvular aortic stenosis. *Eur J Echocardiogr* 2008;**9**:338–43.
148. Lancellotti P, Lebois F, Simon M, Tombeux C, Chauvel C, Pierard LA. Prognostic importance of quantitative exercise Doppler echocardiography in asymptomatic valvular aortic stenosis. *Circulation* 2005;**112**:i377–82.
149. Marechaux S, Hachicha Z, Bellouin A, Dumesnil JG, Meimoun P, Pasquet A *et al*. Usefulness of exercise-stress echocardiography for risk stratification of true asymptomatic patients with aortic valve stenosis. *Eur Heart J* 2010;**31**:1390–7.
150. Marechaux S, Ennezat PV, Lejemtel TH, Polge AS, de Groote P, Asseman P *et al*. Left ventricular response to exercise in aortic stenosis: an exercise echocardiographic study. *Echocardiography* 2007;**24**:955–9.
151. Lancellotti P, Magne J, Donal E, Dulgheru R, Rosca M, Pierard LA. Determinants and prognostic significance of exercise pulmonary hypertension in asymptomatic severe aortic stenosis. *Circulation* 2012;**126**:851–9.
152. Donal E, Thebault C, O'Connor K, Veillard D, Rosca M, Pierard L *et al*. Impact of aortic stenosis on longitudinal myocardial deformation during exercise. *Eur J Echocardiogr* 2011;**12**:235–41.
153. Pibarot P, Dumesnil JG. Low-flow, low-gradient aortic stenosis with normal and depressed left ventricular ejection fraction. *J Am Coll Cardiol* 2012;**60**:1845–53.
154. Monin JL, Quere JP, Monchi M, Petit H, Baleynaud S, Chauvel C *et al*. Low-gradient aortic stenosis: operative risk stratification and predictors for long-term outcome: a multicenter study using dobutamine stress hemodynamics. *Circulation* 2003;**108**:319–24.
155. Tribouilloy C, Levy F, Rusinaru D, Guéret P, Petit-Eisenmann H, Baleynaud S *et al*. Outcome after aortic valve replacement for low-flow/low-gradient aortic stenosis without contractile reserve on dobutamine stress echocardiography. *J Am Coll Cardiol* 2009;**53**:1865–73.
156. Quere JP, Monin JL, Levy F, Petit H, Baleynaud S, Chauvel C *et al*. Influence of preoperative left ventricular contractile reserve on postoperative ejection fraction in low-gradient aortic stenosis. *Circulation* 2006;**113**:1738–44.
157. Bartko PE, Heinze G, Graf S, Clavel MA, Khorsand A, Bergler-Klein J *et al*. Two-dimensional strain for the assessment of left ventricular function in low flow-low gradient aortic stenosis, relationship to hemodynamics and outcome: A substudy of the multicenter TOPAS study. *Circ Cardiovasc Imaging* 2012;**6**:268–76.
158. Dahou A, Bartko PE, Capoulade R, Clavel MA, Mundigler G, Grondin SL *et al*. Usefulness of global left ventricular longitudinal strain for risk stratification in low ejection fraction, low-gradient aortic stenosis: results from the multicenter true or pseudo-severe aortic stenosis study. *Circ Cardiovasc Imaging* 2015;**8**:e002117.
159. Clavel MA, Fuchs C, Burwash IG, Mundigler G, Dumesnil JG, Baumgartner H *et al*. Predictors of outcomes in low-flow, low-gradient aortic stenosis: results of the multicenter TOPAS Study. *Circulation* 2008;**118**(14 Suppl):S234–42.
160. Clavel MA, Burwash IG, Mundigler G, Dumesnil JG, Baumgartner H, Bergler-Klein J *et al*. Validation of conventional and simplified methods to calculate projected valve area at normal flow rate in patients with low flow, low gradient aortic stenosis: the multicenter TOPAS (True or Pseudo Severe Aortic Stenosis) study. *J Am Soc Echocardiogr* 2010;**23**:380–6.
161. Blais C, Burwash IG, Mundigler G, Dumesnil JG, Loho N, Rader F *et al*. Projected valve area at normal flow rate improves the assessment of stenosis severity in patients with low flow, low-gradient aortic stenosis: The multicenter TOPAS (True or Pseudo Severe Aortic Stenosis) study. *Circulation* 2006;**113**:711–21.
162. Fougères É, Tribouilloy C, Monchi M, Petit-Eisenmann H, Baleynaud S, Pasquet A *et al*. Outcomes of pseudo-severe aortic stenosis under conservative treatment. *Eur Heart J* 2012;**33**:2426–33.
163. Clavel MA, Ennezat PV, Maréchaux S, Dumesnil JG, Capoulade R, Hachicha Z *et al*. Stress echocardiography to assess stenosis severity and predict outcome in patients with paradoxical low-flow, low-gradient aortic stenosis and preserved LVEF. *JACC Cardiovasc Imaging* 2013;**6**:175–83.
164. Unger P, Rosenhek R, Dedobbeleer C, Berrebi A, Lancellotti P. Management of multiple valve disease. *Heart* 2011;**97**:272–7.
165. Rassi A, Crawford MH, Richards KL, Miller JF. Differing mechanisms of exercise flow augmentation at the mitral and aortic valves. *Circulation* 1988;**77**:543–51.
166. Tischler MD, Battle RW, Saha M, Niggel J, LeWinter MM. Observations suggesting a high incidence of exercise-induced severe mitral regurgitation in patients with mild rheumatic mitral valve disease at rest. *J Am Coll Cardiol* 1994;**25**:128–33.
167. Pibarot P, Dumesnil JG. Prosthetic heart valves: selection of the optimal prosthesis and long-term management. *Circulation* 2009;**119**:1034–48.
168. Pibarot P, Dumesnil JG. Valve prosthesis-patient mismatch, 1978 to 2011: from original concept to compelling evidence. *J Am Coll Cardiol* 2012;**60**:1136–9.
169. Zoghbi WA, Chambers JB, Dumesnil JG, Foster E, Gottdiener JS, Grayburn PA *et al*. Recommendations for evaluation of prosthetic valves with echocardiography and Doppler ultrasound. *J Am Soc Echocardiogr* 2009;**22**:975–1014.
170. Lancellotti P, Pibarot P, Chambers JB, Edvardsen T, Delgado V, Dulgheru R *et al*. Recommendations for the imaging assessment of prosthetic heart valves. *Eur Heart J Cardiovasc Imag* 2016;**17**:589–90.
171. Pibarot P, Dumesnil JG, Jobin J, Cartier P, Honos G, Durand LG. Hemodynamic and physical performance during maximal exercise in patients with an aortic bioprosthetic valve. Comparison of stentless versus stented bioprostheses. *J Am Coll Cardiol* 1999;**34**:1609–17.
172. Pibarot P, Dumesnil JG, Jobin J, Lemieux M, Honos G, Durand LG. Usefulness of the indexed effective orifice area at rest in predicting an increase in gradient during maximum exercise in patients with a bioprosthesis in the aortic valve position. *Am J Cardiol* 1999;**83**:542–6.
173. Tatineni S, Barner HB, Pearson AC, Halbe D, Woodruff R, Labovitz AJ. Rest and exercise evaluation of St. Jude medical and Medtronic hall prostheses. Influence of primary lesion, valvular type, valvular size, and left ventricular function. *Circulation* 1989;**80**(Suppl. I):i16–23.
174. van den Brink RB, Verheul HA, Visser CA, Koelmeij MJW, Dunning AJ. Value of exercise Doppler echocardiography in patients with prosthetic or bioprosthetic cardiac valves. *Am J Cardiol* 1992;**69**:367–72.
175. Magne J, Sénéchal M, Mathieu P, Dumesnil JG, Dagenais F, Pibarot P. Restrictive annuloplasty for ischemic mitral regurgitation may induce functional mitral stenosis. *J Am Coll Cardiol* 2008;**51**:1692–701.
176. Kubota K, Otsuji Y, Ueno T, Koriyama C, Levine RA, Sakata R *et al*. Functional mitral stenosis after surgical annuloplasty for ischemic mitral regurgitation: importance of subvalvular tethering in the mechanism and dynamic deterioration during exertion. *J Thorac Cardiovasc Surg* 2010;**140**:617–23.
177. Kainuma S, Taniguchi K, Daimon T, Sakaguchi T, Funatsu T, Kondoh H *et al*. Does stringent restrictive annuloplasty for functional mitral regurgitation cause functional mitral stenosis and pulmonary hypertension? *Circulation* 2011;**124**(11 Suppl.):S97–106.
178. Rubino AS, Onorati F, Santarpia G, Achille F, Lorusso R, Santini F *et al*. Impact of increased transmitral gradients after undersized annuloplasty for chronic ischemic mitral regurgitation. *Int J Cardiol* 2012;**158**:71–7.
179. Nishida H, Takahara Y, Takeuchi S, Mogi K. Mitral stenosis after mitral valve repair using the duran flexible annuloplasty ring for degenerative mitral regurgitation. *J Heart Valve Dis* 2005;**14**:563–4.
180. Chan KL, Chen SY, Chan V, Hay K, Mesana T, Lam BK. Functional significance of elevated mitral gradients after repair for degenerative mitral regurgitation. *Circ Cardiovasc Imaging* 2013;**6**:1041–7.
181. Bertrand PB, Verbrugge FH, Verhaert D, Smeets CJ, Grieten L, Mullens W *et al*. Mitral valve area during exercise after restrictive mitral valve annuloplasty: importance of diastolic anterior leaflet tethering. *J Am Coll Cardiol* 2015;**65**:452–61.
182. Bertrand PB, Gutermann H, Smeets CJ, Van Kerrebroeck C, Verhaert D, Vandervoort P *et al*. Functional impact of transmitral gradients at rest and during exercise after restrictive annuloplasty for ischemic mitral regurgitation. *J Thorac Cardiovasc Surg* 2014;**148**:183–7.
183. Kjellström B, Frantz RP, Benza RL, Bennett T, Bourge RC, McGoon MD. Hemodynamic ranges during daily activities and exercise testing in patients with pulmonary arterial hypertension. *J Cardiac Fail* 2014;**20**:485–91.

184. Argiento P, Chester N, Mule M, D'Alto M, Bossone E, Unger P et al. Exercise stress echocardiography for the study of the pulmonary circulation. *Eur Respir J* 2010;**35**: 1273–8.
185. Lewis GD, Bossone E, Naeije R, Grünig E, Saggari R, Lancellotti P et al. Pulmonary vascular hemodynamic response to exercise in cardiopulmonary diseases. *Circulation* 2013;**128**:1470–9.
186. Grünig E, Mereles D, Hildebrandt W, Swenson ER, Kübler W, Kuecherer H et al. Stress Doppler echocardiography for identification of susceptibility to high altitude pulmonary edema. *J Am Coll Cardiol* 2000;**35**:980–7.
187. Almeida AR, Loureiro MJ, Lopes L, Cotrim C, Lopes L, Repolho D et al. Echocardiographic assessment of right ventricular contractile reserve in patients with pulmonary hypertension. *Rev Port Cardiol* 2014;**33**:155–63.
188. Kovacs G, Maier R, Aberer E, Brodmann M, Scheidl S, Hesse C et al. Assessment of pulmonary arterial pressure during exercise in collagen vascular disease: echocardiography versus right heart catheterization. *Chest* 2010;**133**:270–8.
189. Haddad F, Zamanian R, Beraud AS, Schnitter I, Feinstein J, Peterson T et al. A novel non-invasive method of estimating pulmonary vascular resistance in patients with pulmonary arterial hypertension. *J Am Soc Echocardiogr* 2009;**22**:523–9.
190. Himelman RB, Stulbarg M, Kircher B, Lee E, Kee L, Dean NC et al. Noninvasive evaluation of pulmonary artery pressure during exercise by saline-enhanced Doppler echocardiography in chronic pulmonary disease. *Circulation* 1989;**79**:863–71.
191. Grünig E, Weissmann S, Ehlen N, Fijalkowska A, Fischer C, Fourme T et al. Stress Doppler echocardiography in relatives of patients with idiopathic and familial pulmonary arterial hypertension: results of a multicenter European analysis of pulmonary artery pressure response to exercise and hypoxia. *Circulation* 2009;**119**: 1747–57.
192. Gurtner HP, Walsler P, Fässler B. Normal values for pulmonary hemodynamics at rest and during exercise in man. *Prog Resp Res* 1975;**9**:295–315.
193. Janosi A, Apor P, Hankoczy J, Kadar A. Pulmonary artery pressure and oxygen consumption measurement during supine bicycle exercise. *Chest* 1988;**93**: 419–21.
194. Mahjoub H, Levy F, Cassol M, Meimoun P, Peltier M, Rusinaru D et al. Effects of age on pulmonary artery systolic pressure at rest and during exercise in normal adults. *Eur J Echocardiogr* 2009;**10**:635–40.
195. Stuber T, Sartori C, Schwab M, Jayet PY, Rimoldi SF, Garcin S et al. Exaggerated pulmonary hypertension during mild exercise in chronic mountain sickness. *Chest* 2010;**137**:388–92.
196. Pratali L, Allemann Y, Rimoldi SF, Faïta F, Hutter D, Rexhaj E et al. RV contractility and exercise-induced pulmonary hypertension in chronic mountain sickness: a stress echocardiographic and tissue Doppler imaging study. *JACC Cardiovascular Imaging* 2013;**6**:1287–97.
197. Galie N, Humbert M, Vachiery JL, Gibbs S, Lang I, Torbicki A et al. 2015 ESC/ERS Guidelines for the diagnosis and treatment of pulmonary hypertension. *Eur Heart J* 2016;**37**:67–119.
198. Voilliot D, Magne J, Dulgheru R, Kou S, Henri C, Laaraibi S et al. Determinants of exercise-induced pulmonary arterial hypertension in systemic sclerosis. *Int J Cardiol* 2014;**173**:373–9.
199. Steen V, Chou M, Shanmugan V, Mathias M, Kuru T, Morrissey R. Exercise-induced pulmonary arterial hypertension in patients with systemic sclerosis. *Chest* 2008;**134**:146–51.
200. De Lima-Filho NN, Figueiredo MS, Vicari P, Cançado R, Carvalho AC, Bordin JO et al. Exercise-induced abnormal increase of systolic pulmonary artery pressure in adult patients with sickle cell anemia: an exercise stress echocardiography study. *Echocardiography* 2014. doi: 10.1111/echo.12853.
201. Gabriels C, Lancellotti P, Van De Bruaene A, Voilliot D, De Meester P, Buys R et al. Clinical significance of dynamic pulmonary vascular resistance in two populations at risk of pulmonary arterial hypertension. *Eur Heart J Cardiovasc Imaging* 2015;**16**: 564–70.
202. Abbas AE, Franey LM, Marwick T, Maeder MT, Kaye DM, Vlahos AP et al. Non-invasive assessment of pulmonary vascular resistance by Doppler echocardiography. *J Am Soc Echocardiogr* 2013;**26**:1170–7.
203. Choi EY, Shim J, Kim SA, Shim CY, Yoon SJ, Kang SM et al. Value of echo-Doppler derived pulmonary vascular resistance, net-atrioventricular compliance and tricuspid annular velocity in determining exercise capacity in patients with mitral stenosis. *Circ J* 2007;**71**:1721–7.
204. Suzuki K, Akashi YJ, Manabe M, Mizukoshi K, Kamijima R, Kou S et al. Simple exercise echocardiography using a Master's two-step test for early detection of pulmonary arterial hypertension. *J Cardiol* 2013;**62**:176–82.
205. Douglas PS, Garcia MJ, Haines DE, Lai WW, Manning WJ, Patel AR et al. ACCF/AHA/ASNC/HFSA/HRS/SCAI/SCCM/SCCT/SCMR 2011 Appropriate use criteria for echocardiography. *J Am Soc Echocardiogr* 2011;**24**:229–67.
206. Kane GC, Maradit-Kremers H, Slusser JP, Scott CG, Frantz RP, McGoon MD. Integration of clinical and hemodynamic parameters in the prediction of long-term survival in patients with pulmonary arterial hypertension. *Chest* 2011;**139**: 1285–93.
207. Vonk-Noordegraaf A, Haddad F, Chin KM, Forfia PR, Kawut SM, Lumens J et al. Right heart adaptation to pulmonary arterial hypertension: physiology and pathobiology. *J Am Coll Cardiol* 2013;**62**:D22–33.
208. Fine NM, Chen L, Bastiansen PM, Frantz RP, Pellikka PA, Oh JK et al. Outcome prediction by quantitative right ventricular function assessment in 575 subjects evaluated for pulmonary hypertension. *Circ Cardiovasc Imaging* 2013;**6**:711–21.
209. Vitarelli A, Mangieri E, Terzano C, Gaudio C, Salsano F, Rosato E et al. Three-dimensional echocardiography and 2D/3D speckle-tracking imaging in chronic pulmonary hypertension: diagnostic accuracy in detecting hemodynamic signs of right ventricular failure. *J Am Heart Assoc* 2015;**4**:e001584.
210. Grünig E, Tiede H, Enyimayew EO, Ehlen N, Seyfarth HJ, Bossone E et al. Assessment and prognostic relevance of right ventricular contractile reserve in patients with severe pulmonary hypertension. *Circulation* 2013;**128**:2005–15.
211. Sharma T, Lau EMT, Choudhary P, Torzillo PJ, Munoz PA, Simmons LR et al. Dobutamine stress for evaluation of right ventricular reserve in pulmonary arterial hypertension. *Eur Respir J* 2015;**45**:700–8.
212. Galderisi M, Cardim N, D'Andrea A, Bruder O, Cosyns B, Davin L et al. The multimodality cardiac imaging approach to the Athlete's heart: an expert consensus of the European Association of Cardiovascular Imaging. *Eur Heart J Cardiovasc Imaging* 2015;**16**:353.
213. Cotrim C, Almeida AR, Miranda R, Almeida AG, Cotrim H, Picano E et al. Stress-induced intraventricular gradients in symptomatic athletes during upright exercise continuous wave Doppler echocardiography. *Am J Cardiol* 2010;**106**: 1808–12.
214. Rubal BJ, Moody JM, Damore S, Bunker SR, Diaz NM. Left ventricular performance of the athletic heart during upright exercise: a heart rate-controlled study. *Med Sci Sports Exerc* 1986;**18**:134–40.
215. Dehnert C, Grünig E, Mereles D, von Lennep N, Bärtsch P. Identification of individuals susceptible to high-altitude pulmonary oedema at low altitude. *Eur Respir J* 2005;**25**:545–51.
216. Fagenholz PJ, Gutman JA, Murray AF, Noble VE, Thomas SH, Harris NS. Chest ultrasonography for the diagnosis and monitoring of high-altitude pulmonary edema. *Chest* 2007;**131**:1013–8.
217. Frassi F, Pingitore A, Cialoni D, Picano E. Chest sonography detects lung water accumulation in healthy elite apnea divers. *J Am Soc Echocardiogr* 2008;**21**:1150–5.
218. Pratali L, Cavana M, Sicari R, Picano E. Frequent subclinical high-altitude pulmonary edema detected by chest sonography as ultrasound lung comets in recreational climbers. *Crit Care Med* 2010;**38**:1818–23.
219. Oelberg DA, Marcotte F, Kreisman H, Wolkove N, Langleben D, Small D. Evaluation of right ventricular systolic pressure during incremental exercise by Doppler echocardiography in adults with atrial septal defect. *Chest* 1998;**113**:1459–65.
220. Van De Bruaene A, La Gerche A, Prior DL, Voigt JU, Delcroix M, Budts W. Pulmonary vascular resistance as assessed by bicycle stress echocardiography in patients with atrial septal defect type secundum. *Circ Cardiovasc Imaging* 2011;**4**: 237–45.
221. Van De Bruaene A, De Meester P, Buys R, Vanhees L, Delcroix M, Voigt JU et al. Right ventricular load and function during exercise in patients with open and closed atrial septal defect type secundum. *Eur J Prev Cardiol* 2013;**20**:597–604.
222. Van De Bruaene A, Moons P, Belmans A, Post MC, Luermans JG, Delcroix M et al. Predictive model for late atrial arrhythmia after closure of an atrial septal defect. *Int J Cardiol* 2013;**164**:318–22.
223. Lange SA, Braun MU, Schoen SP, Strasser RH. Latent pulmonary hypertension in atrial septal defect: dynamic stress echocardiography reveals unapparent pulmonary hypertension and confirms rapid normalisation after ASD closure. *Neth Heart J* 2013;**21**:333–43.
224. De Meester P, Thijs V, Van Deyk K, Budts W. Prevention of stroke by percutaneous left atrial appendage closure: short term follow-up. *Int J Cardiol* 2010;**142**: 195–6.
225. Van De Bruaene A, Jansen K, De Meester P, Delcroix M, Voigt JU, Gabriels C et al. Bosentan for mild pulmonary vascular disease in ASD patients (the BOMPA trial): a double-blind, randomized controlled, pilot trial. *Int J Cardiol* 2013;**168**:5081–2.
226. Lee C, Lee CH, Kwak JG, Kim SH, Shim WS, Lee SY et al. Factors associated with right ventricular dilatation and dysfunction in patients with chronic pulmonary regurgitation after repair of tetralogy of Fallot: analysis of magnetic resonance imaging data from 218 patients. *J Thorac Cardiovasc Surg* 2014;**148**:2589–95.
227. Ait-Ali L, Siciliano V, Passino C, Molinaro S, Pasanisi E, Sicari R et al. Role of stress echocardiography in operated fallot: feasibility and detection of right ventricular response. *J Am Soc Echocardiogr* 2014;**27**:1319–28.
228. Roche SL, Grosse-Wortmann L, Redington AN, Slorach C, Smith G, Kantor PF et al. Exercise induces biventricular mechanical dyssynchrony in children with repaired tetralogy of Fallot. *Heart* 2010;**96**:2010–5.
229. Cifra B, Ponderfer P, Dragulescu A, Friedberg MK, Slorach C, Mertens L. Right ventricular systolic and diastolic response to exercise in children after Tetralogy of Fallot repair – a bicycle exercise study. *Cardiol Young* 2014;**24**:S1–S165.

230. Cifra B, Dragulescu A, Friedberg MK, Slorach C, Mertens L. Isovolumic acceleration at rest and during exercise in children with repaired tetralogy of fallot. *Cardiol Young* 2014;**24**:S1–S165.
231. Hasan BS, Lunze FI, Chen MH, Brown DW, Boudreau MJ, Rhodes J *et al*. Effects of transcatheter pulmonary valve replacement on the hemodynamic and ventricular response to exercise in patients with obstructed right ventricle-to-pulmonary artery conduits. *JACC Cardiovasc Interv* 2014;**7**:530–42.
232. Chen SS, Dimopoulos K, Alonso-Gonzalez R, Liodakis E, Teixeira-Fernandez E, Alvarez-Barredo M *et al*. Prevalence and prognostic implication of restenosis or dilatation at the aortic coarctation repair site assessed by cardiovascular MRI in adult patients late after coarctation repair. *Int J Cardiol* 2014;**173**:209–15.
233. Luijendijk P, Bouma BJ, Vriend JW, Vliegen HW, Groenink M, Mulder BJ. Usefulness of exercise-induced hypertension as predictor of chronic hypertension in adults after operative therapy for aortic isthmus coarctation in childhood. *Am J Cardiol* 2011;**108**:435–9.
234. Morgan GJ, Lee KJ, Chaturvedi R, Bradley TJ, Mertens L, Benson L. Systemic blood pressure after stent management for arch coarctation: implications for clinical care. *JACC Cardiovasc Interv* 2013;**6**:192–201.
235. Guenthard J, Wyler F. Doppler echocardiography during exercise to predict residual narrowing of the aorta after coarctation resection. *Pediatric cardiology* 1996;**17**:370–4.
236. Chen CK, Cifra B, Morgan GJ, Sarkola T, Slorach C, Wei H *et al*. Left ventricular myocardial and hemodynamic response to exercise in young patients after endovascular stenting for aortic coarctation. *J Am Soc Echocardiogr* 2016;**29**:237–46.
237. Li VW, Chen RH, Wong WH, Cheung YF. Left ventricular contractile reserve in young adults long-term after repair of coarctation of the aorta. *Am J Cardiol* 2015;**115**:348–53.
238. Mahle WT, Wernovsky G, Bridges ND, Linton AB, Paridon SM. Impact of early ventricular unloading on exercise performance in preadolescents with single ventricle Fontan physiology. *J Am Coll Cardiol* 1999;**34**:1637–43.
239. Helbing WA, Luijnenburg SE, Moelker A, Robbers-Visser D. Cardiac stress testing after surgery for congenital heart disease. *Curr Opin Pediatr* 2010;**22**:579–86.
240. Bossers SS, Kapusta L, Kuipers IM, van Iperen G, Moelker A, Kroft LJ *et al*. Ventricular function and cardiac reserve in contemporary Fontan patients. *Int J Cardiol* 2015;**196**:73–80.
241. Brili SV, Alexopoulos NA, Barberis VI, Gatzoulis MA, Barbetseas J, Chrysohoou C *et al*. Dobutamine stress echocardiography for the evaluation of cardiac reserve late after Fontan operation. *Hellenic J Cardiol* 2007;**48**:252–7.
242. Schlangen J, Petko C, Hansen JH, Michel M, Hart C, Uebing A *et al*. Two-dimensional global longitudinal strain rate is a preload independent index of systemic right ventricular contractility in hypoplastic left heart syndrome patients after Fontan operation. *Circ Cardiovasc Imaging* 2014;**7**:880–6.
243. Lam YY, Kaya MG, Li W, Gatzoulis MA, Henein MY. Effect of chronic afterload increase on left ventricular myocardial function in patients with congenital left-sided obstructive lesions. *Am J Cardiol* 2007;**99**:1582–7.
244. Budts W, Scheurwegs C, Stevens A, Moons P, Van Deyk K, Vanhees L. The future of adult patients after mustard or senning repair for transposition of the great arteries. *Int J Cardiol* 2006;**113**:209–14.
245. Li W, Hornung TS, Francis DP, O'Sullivan C, Duncan A, Gatzoulis M *et al*. Relation of biventricular function quantified by stress echocardiography to cardiopulmonary exercise capacity in adults with mustard (atrial switch) procedure for transposition of the great arteries. *Circulation* 2004;**110**:1380–6.
246. Oosterhof T, Tulevski II, Roest AA, Steendijk P, Vliegen HW, van der Wall EE *et al*. Disparity between dobutamine stress and physical exercise magnetic resonance imaging in patients with an intra-atrial correction for transposition of the great arteries. *J Cardiovasc Magn Reson* 2005;**7**:383–9.
247. Vogt M, Kühn A, Wiese J, Eicken A, Hess J, Vogel M. Reduced contractile reserve of the systemic right ventricle under dobutamine stress is associated with increased brain natriuretic peptide levels in patients with complete transposition after atrial repair. *Eur J Echocardiogr* 2009;**10**:691–4.
248. Rodgers GP, Ayanian JZ, Balady G, Beasley JW, Brown KA, Gervino EV *et al*. American College of Cardiology/American Heart Association Clinical Competence statement on stress testing: a report of the American College of Cardiology/American Heart Association/American College of Physicians–American Society of Internal Medicine Task Force on Clinical Competence. *J Am Coll Cardiol* 2000;**36**:1441–53.
249. Popescu BA, Stefanidis A, Nihoyannopoulos P, Fox KF, Ray S, Cardim N *et al*. Updated standards and processes for accreditation of echocardiographic laboratories from The European Association of Cardiovascular Imaging. *Eur Heart J Cardiovasc Imaging* 2014;**15**:717–27.
250. Mc Ilwain EF, Coon PD, Einstein AJ, Mitchell CK, Natello GW, Palma RA *et al*. Radiation safety for the cardiac sonographer: Recommendations of the Radiation Safety Writing Group for the Council on Cardiovascular Sonography of the American Society of Echocardiography. *J Am Soc Echocardiogr* 2014;**27**:811–6.
251. Ryan T, Berlacher K, Lindner JR, Mankad SV, Rose GA, Wang A. Core Cardiovascular Training Statement (COCATS) 4 task force 5: training in echocardiography. *J Am Coll Cardiol* 2015;**65**:1786–99.
252. Picano E, Vañó E, Rehani MM, Cuocolo A, Mont L, Bodi V *et al*. The appropriate and justified use of medical radiation in cardiovascular imaging: a position document of the ESC Associations of Cardiovascular Imaging, Percutaneous Cardiovascular Interventions and Electrophysiology. *Eur Heart J* 2014;**35**:665–72.
253. Naji P, Griffin BP, Asfahan F, Barr T, Rodriguez LL, Grimm R *et al*. Predictors of long-term outcomes in patients with significant myxomatous mitral regurgitation undergoing exercise echocardiography. *Circulation* 2014;**129**:1310–9.