

The Cognitive Neuroscience of Human Memory Since H.M.

Larry R. Squire^{1,2,3,4} and John T. Wixted⁴

¹Veterans Affairs Healthcare System, San Diego, California 92161

²Department of Psychiatry, ³Department of Neurosciences, and ⁴Department of Psychology, University of California, San Diego, La Jolla, California 92093; email: lsquire@ucsd.edu, jwixted@ucsd.edu

Annu. Rev. Neurosci. 2011. 34:259–88

First published online as a Review in Advance on March 29, 2011

The *Annual Review of Neuroscience* is online at neuro.annualreviews.org

This article's doi:
10.1146/annurev-neuro-061010-113720

Copyright © 2011 by Annual Reviews.
All rights reserved

0147-006X/11/0721-0259\$20.00

Keywords

medial temporal lobe, hippocampus, neocortex, anterograde amnesia, retrograde amnesia

Abstract

Work with patient H.M., beginning in the 1950s, established key principles about the organization of memory that inspired decades of experimental work. Since H.M., the study of human memory and its disorders has continued to yield new insights and to improve understanding of the structure and organization of memory. Here we review this work with emphasis on the neuroanatomy of medial temporal lobe and diencephalic structures important for memory, multiple memory systems, visual perception, immediate memory, memory consolidation, the locus of long-term memory storage, the concepts of recollection and familiarity, and the question of how different medial temporal lobe structures may contribute differently to memory functions.

Contents

INTRODUCTION	260
ANATOMY OF MEMORY	261
PRINCIPLES OF ORGANIZATION SUGGESTED BY H.M.'S FINDINGS	265
MULTIPLE MEMORY SYSTEMS . .	266
VISUAL PERCEPTION	267
IMMEDIATE MEMORY AND WORKING MEMORY	268
REMOTE MEMORY AND MEMORY CONSOLIDATION	271
MEMORY IN THE NEOCORTEX . .	273
Achromatopsia	275
Prosopagnosia	275
Amusia	276
Knowledge Systems	277
RECOLLECTION AND FAMILIARITY	278
Recall versus Recognition	278
Remember/Know Procedure	279
Analysis of the Receiver Operating Characteristic	279
Newer (Model-Free) Methods	281
GROUP STUDIES AND MULTIPLE METHODS	281
CONCLUSIONS	282

INTRODUCTION

In the earliest systematic writings about human memory, it was already appreciated that the study of memory impairment can provide valuable insights into the structure and organization of normal function (Ribot 1881, Winslow 1861). This tradition of research has continued to prove fruitful and has yielded a broad range of fundamental information about the structure and organization of memory. What is memory? Is it one thing or many? What are the concepts and categories that guide our current understanding of how memory works and that underlie the classification of its disorders? It is sometimes not appreciated that the concepts and categories used in current discussions

of memory are not fixed and were not easily established. Even the question of which cognitive operations reflect memory and which depend on other faculties has a long history of empirical work and discussion.

One needs only to sample nineteenth-century writings to recognize how differently memory was viewed then and now. For example, in his classic treatment of memory disorders, Ribot (1881) considered amnesias due to neurological injury together with amnesias due to psychological trauma. And he viewed aphasia and agnosia as disorders of memory, wherein (in aphasia, for example) patients have lost their memory for words or memory for the movements needed to produce words. Today, aphasia is considered a deficit of language, and agnosia a deficit of visual perception. Memory is affected but only as part of a more fundamental defect in a specific kind of information processing.

The notion that the study of brain injury can elucidate the organization of memory was itself a matter for empirical inquiry. If brain regions were highly interconnected, and the brain's functions distributed and integrated one with another, then damage to any one area would produce a global impairment, blurred across multiple faculties and affecting all of mental life. But the fact of the matter is different. The brain is highly specialized and modular, with different regions dedicated to specific operations. As a result, localized damage can produce strikingly specific effects, including a selective and circumscribed impairment of memory.

The idea that functions of the nervous system can be localized was already well accepted by the end of the nineteenth century. This localizationist view had its roots in the writings of Gall (1825) and was supported by the experimental work of Broca (1861), Ferrier (1876), Fritsch & Hitzig (1870), and others (see Finger 1994). Yet, these ideas centered mainly around sensory functions, motor control, and language and did not usefully address the topic of memory. Then, in the early twentieth century, an influential program of experimental work in rodents investigated directly the localization of

memory with the conclusion that memory is distributed throughout the cortex and that the contribution to memory is equivalent across regions (Lashley 1929). This idea was strongly challenged (Hebb 1949, Hunter 1930) by the alternative, and more modern, interpretation that memory storage is indeed distributed but that different areas store different features of the whole. Still, as the midpoint of the twentieth century approached, memory functions, while distributed, were thought to be well integrated with perceptual and intellectual functions, and no region of the brain was believed to be disproportionately dedicated to memory. All that was about to change.

In 1957, Brenda Milner reported the profound effect on memory of bilateral medial temporal lobe resection, carried out to relieve epilepsy in a patient who became known as H.M. (1926–2008) (Scoville & Milner 1957, Squire 2009) (**Figure 1**). Remarkably, H.M. exhibited profound forgetfulness but in the absence of any general intellectual loss or perceptual disorders. He could not form new memories (anterograde amnesia) and also could not access some memories acquired before his surgery (retrograde amnesia). His impairment extended to both verbal and non-verbal material, and it involved information acquired through all sensory modalities. These findings established the fundamental principle that memory is a distinct cerebral function, separable from other perceptual and cognitive abilities, and also identified the medial aspect of the temporal lobe as important for memory. The early descriptions of H.M. can be said to have inaugurated the modern era of memory research, and the findings from H.M. enormously influenced the direction of subsequent work.

ANATOMY OF MEMORY

The work with H.M. is sometimes cited incorrectly as evidence of the importance of the hippocampus for memory, but this particular point could not of course be established by a large lesion that included not only the hippocampus but also the amygdala together with the adja-

cent parahippocampal gyrus. Which structures within H.M.'s lesion are important for memory became understood only gradually during the 1980s following the successful development of an animal model of human amnesia in the non-human primate (Mishkin 1978). Cumulative studies in the monkey (Murray 1992, Squire & Zola-Morgan 1991, Zola-Morgan et al. 1994) considerably clarified this issue. The important structures proved to be the hippocampus and the adjacent entorhinal, perirhinal, and parahippocampal cortices, which make up much of the parahippocampal gyrus (**Figure 2**).

One particularly instructive case of human memory impairment became available during this same time period (Zola-Morgan et al. 1986). R.B. developed a moderately severe, enduring impairment following an ischemic episode in 1978. During the five years until his death, his memory deficit was well documented with formal tests. Detailed histological examination of his brain revealed a circumscribed bilateral lesion involving the entire CA1 field of the hippocampus. Note that a lesion confined to the CA1 field must substantially disrupt hippocampal function because the CA1 field is a bottleneck in the unidirectional chain of processing that begins at the dentate gyrus and ends in the subiculum and entorhinal cortex. R.B. was the first case of memory impairment following a lesion limited to the hippocampus that was supported by extensive neuropsychological testing as well as neuropathological analysis.

The findings from R.B., considered together with the much more severe impairment in H.M., made two useful points. First, damage to the hippocampus itself is sufficient to produce a clinically significant and readily detectable memory impairment. Second, additional damage to the adjacent cortical regions along the parahippocampal gyrus (as in H.M.) greatly exacerbates the memory impairment. These same conclusions about the neuroanatomy of modest and severe memory impairment were also established in the monkey (Zola-Morgan et al. 1994).

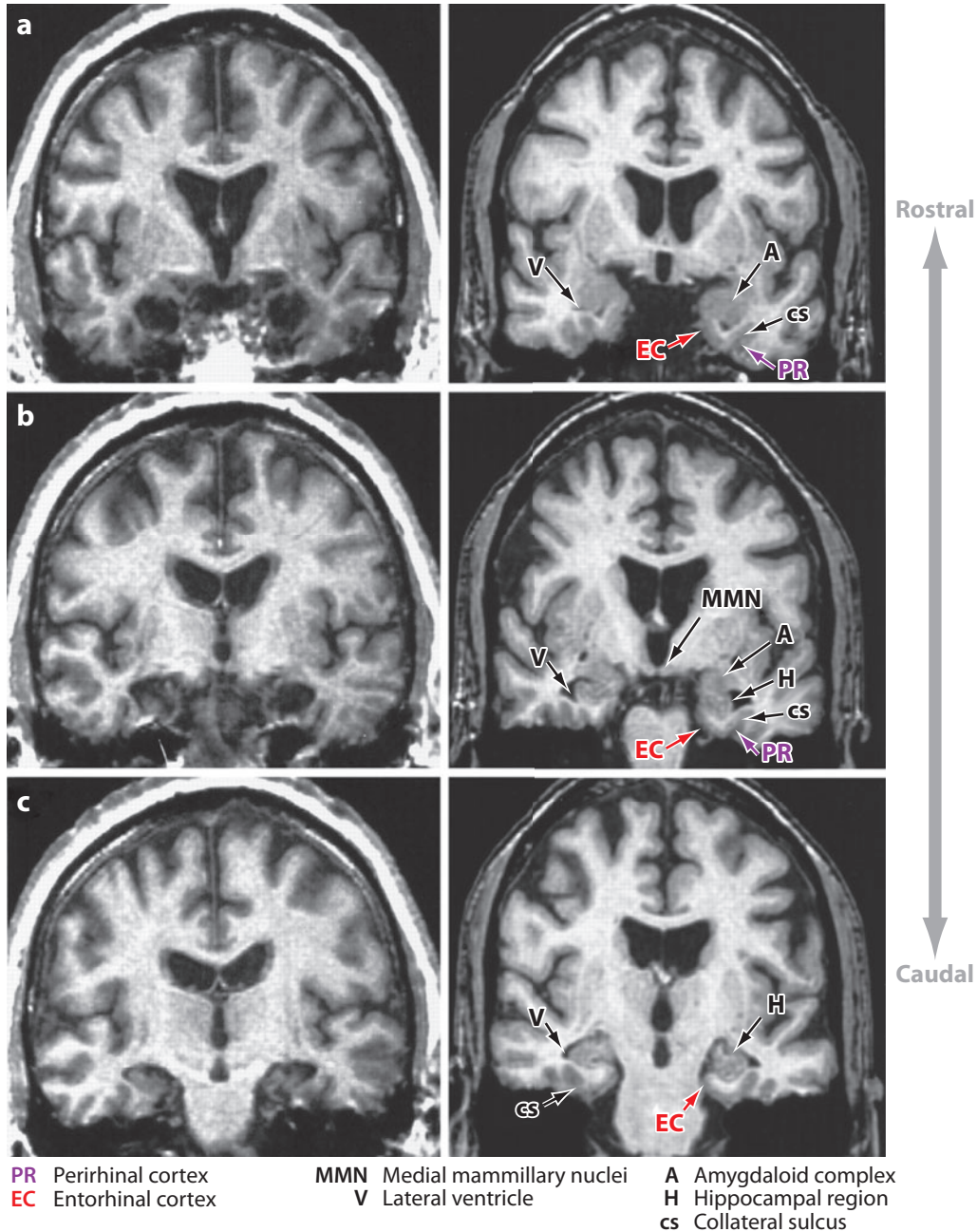
Another case was subsequently described (patient G.D.) with a histologically confirmed

bilateral lesion confined to the CA1 field and with a memory impairment very similar to R.B. (Rempel-Clower et al. 1996). Two other patients were also of interest. L.M. and W.H. had

somewhat more severe memory impairment than did R.B. and G.D., but the impairment was still moderate in comparison to H.M. (Rempel-Clower et al. 1996). Histological examination

Patient H.M.

Healthy 66-year-old male



revealed extensive bilateral lesions of the hippocampal region, involving all the CA fields and the dentate gyrus. There was also some cell loss in entorhinal cortex and, for W.H., cell loss in the subiculum, as well. The more severe memory impairment in these two cases, in comparison to R.B. and G.D., could be due to the additional damage within the hippocampus or to the cell loss in entorhinal cortex.

There are only a small number of cases where detailed neuropsychological testing and thorough neurohistological analysis have combined to demonstrate memory impairment after limited hippocampal damage or larger medial temporal lobe lesions (see also Victor & Agamanolis 1990). Yet, neuroanatomical information is essential because it lays the groundwork for classifying memory disorders, for understanding qualitative and quantitative differences between patients, and for addressing questions about how specific structures may contribute differently to memory functions. Nonetheless, in the absence of histological data, valuable information can be obtained from structural imaging. Methods for high-resolution imaging of hippocampal damage were developed some time ago (Press et al. 1989), and quantitative data can now be obtained that provide reliable estimates of tissue volume (Gold & Squire 2005). These estimates are based on guidelines defined histologically and use landmarks in the medial temporal lobe that are visible on MRI (Insausti et al. 1998a,b).

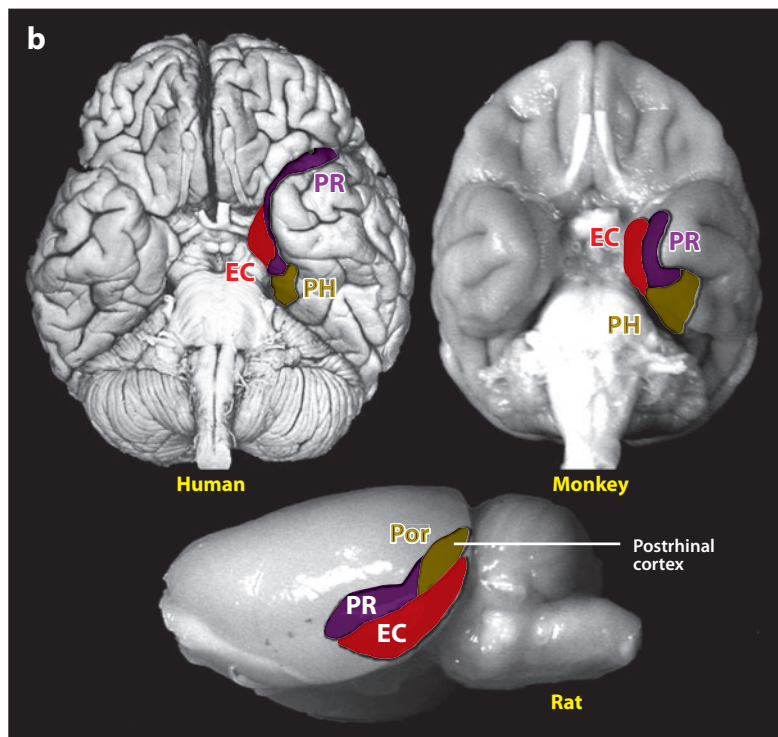
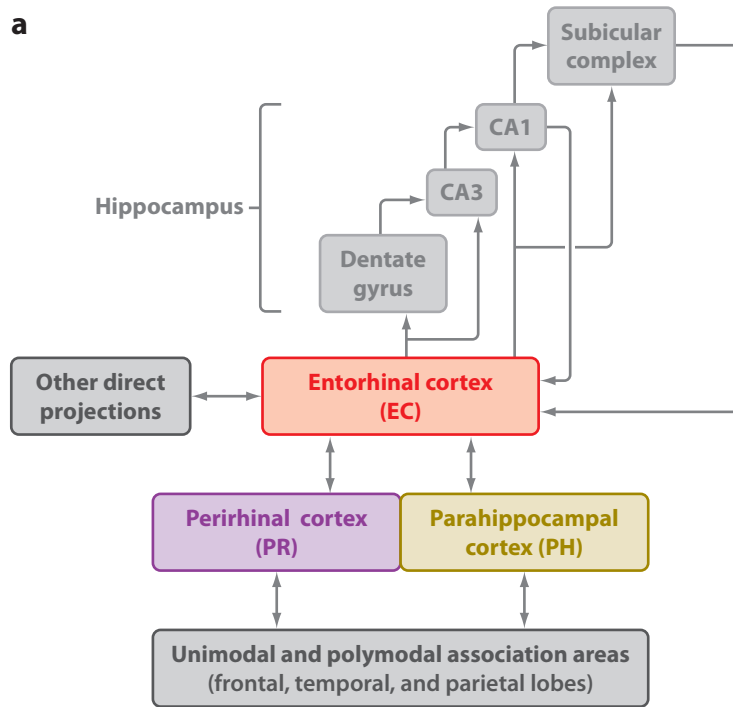
An interesting observation has emerged from calculations of hippocampal volume in memory-impaired patients, usually patients

who have sustained an anoxic episode. Across a number of reports, hippocampal volume (or area in the coronal plane) is typically reduced by ~40% [41%, $n = 10$ (Isaacs et al. 2003); 44%, $n = 5$ (Shrager et al. 2008); 43%, $n = 4$ (Squire et al. 1990); 45%, $n = 1$ (Cipolotti et al. 2001); 46%, $n = 1$ (Mayes et al. 2002)]. Neurohistological data from two of these patients (L.M. and W.H.) suggest an explanation for this striking consistency. As described above, these two patients had extensive cell loss in the hippocampus as well as in the dentate gyrus. Accordingly, a reduction in hippocampal volume of 40%, as estimated by MRI, may indicate a nearly complete loss of hippocampal neurons. The tissue collapses, but it does not disappear entirely. A volume loss in the hippocampus of ~40% may represent a maximum value for some etiologies of memory impairment.

While medial temporal lobe structures have received the most attention in studies of memory and memory impairment, it is notable that damage to the diencephalic midline also impairs memory. The deficit has essentially the same features as in medial temporal lobe amnesia. The best-known cause of diencephalic amnesia is alcoholic Korsakoff's syndrome. Here, damage to the medial dorsal thalamic nucleus (alone or perhaps in combination with damage to the mammillary nuclei) has been associated with memory impairment (Victor et al. 1989). Another survey of Korsakoff's syndrome documented damage to these two structures and, in addition, identified a role for the anterior thalamic nuclei (Harding et al. 2000). Six cases that were studied both neuropsychologically and neurohistologically (Gold & Squire 2006, Mair

Figure 1

Left column. Magnetic resonance images arranged from rostral (*a*) to caudal (*c*) through the temporal lobe of patient H.M. (in 1993 at age 67) and a 66-year-old healthy male (*right*). The comparison brain illustrates the structures that appear to have been removed during H.M.'s surgery in 1953. The lesion was bilaterally symmetrical, extending caudally 5.4 cm on the left side and 5.1 cm on the right. The full caudal extent of abnormal tissue is not illustrated. The damage included medial temporal polar cortex, most of the amygdaloid complex, virtually all the entorhinal cortex, and approximately the rostral half of the hippocampal region (dentate gyrus, hippocampus, and subicular complex). The perirhinal cortex was substantially damaged except for its ventrocaudal aspect. The more posterior parahippocampal cortex (areas TF and TH, not shown here) was largely intact. Adapted from Corkin et al. (1997) with permission from the Society for Neuroscience.



et al. 1979, Mayes et al. 1988) consistently identified damage in the medial thalamus (as well as in the mammillary nuclei for the five cases with Korsakoff's syndrome). Two regions of thalamus were implicated by these cases and by two neuroimaging studies of diencephalic amnesia (Squire et al. 1989, von Cramon et al. 1985): first, the medial dorsal nucleus and the adjacent internal medullary lamina; and second, the mammillothalamic tract and its target, the anterior thalamic nuclei. Damage to either of these regions can cause memory impairment. These diencephalic nuclei and tracts are anatomically related to the medial temporal lobe. The perirhinal cortex originates projections to the medial dorsal nucleus that enter through the internal medullary lamina, and the hippocampal formation projects both to the rostrally adjacent anterior nuclei and to the mammillary nuclei. These anatomical connections likely explain why patients with medial temporal or diencephalic lesions exhibit the same core deficit.

PRINCIPLES OF ORGANIZATION SUGGESTED BY H.M.'S FINDINGS

The early descriptions of H.M. suggested four principles about how memory is organized in the brain. First, despite his debilitating and pervasive memory impairment, H.M. successfully acquired a motor skill. This finding raised the possibility that memory is not a single thing. Second, because his memory impairment appeared to be well circumscribed, the structures damaged in memory-impaired patients were

thought not to be involved in intellectual and perceptual functions. Third, H.M. had a considerable capacity for sustained attention, including the ability to retain information for a period of time after it was first encountered. This finding suggested that medial temporal lobe structures are not needed for immediate memory or for the rehearsal and maintenance of material in what would now be termed working memory. Fourth, H.M. appeared to have good access to facts and events from time periods remote to his surgery. This observation suggested that the medial temporal lobe cannot be the ultimate storage site for long-term memory. Permanent memory must be stored elsewhere, presumably in neocortex. In the years since H.M. was described, each of these ideas has been the topic of extensive experimental work.

During the 1960s and 1970s, when human memory impairment began to be systematically studied, there was considerable debate about whether medial temporal and diencephalic structures were concerned more with storage or with retrieval. The findings from H.M. led to the view that these structures are needed for memory storage, that is, for the establishment of new representations in long-term memory. If these structures are unable to participate in forming long-term memory, then representations established in immediate memory are presumably lost or perhaps achieve some disorganized state. Consider the case of transient amnesic episodes (transient global amnesia or the memory impairment associated with electroconvulsive therapy). Here, the events that occur during the period of anterograde amnesia are not subsequently remembered

Figure 2

(a) Schematic view of the medial temporal lobe memory system for declarative memory, which is composed of the hippocampus and the perirhinal, entorhinal, and parahippocampal cortices. In addition to the connections shown here, there are also weak projections from the perirhinal and parahippocampal cortices to the CA1-subiculum border. (b) Ventral view of a human brain (*upper left*), monkey brain (*upper right*), and a lateral view of a rat brain (*lower center*). The major cortical components of the medial temporal lobe are highlighted and outlined. The hippocampus is not visible from the surface and in the human lies beneath the cortex of the medial temporal lobe. Its anterior extent lies below the posterior entorhinal (*red*) and perirhinal (*purple*) cortices, and the main body of the hippocampus lies beneath the parahippocampal cortex. In the rat, the parahippocampal cortex is termed postrhinal cortex. Abbreviations: EC, entorhinal cortex; PH, parahippocampal cortex (*dark yellow*); Por, postrhinal cortex; PR, perirhinal cortex.

after recovery from the amnesic condition. New learning again becomes possible, but events from the amnesic episode do not return to memory. Thus, if medial temporal lobe or diencephalic structures are not functional at the time of learning, memory is not established in a usable way and does not become available at a later time. More direct investigations of this issue using single-cell recording in monkeys have reached similar conclusions (Higuchi & Miyashita 1996; see Squire 2006). The idea is that the synaptic changes that would ordinarily represent acquired information in long-term memory either are lost altogether or fail to develop into a stable, coherent ensemble.

MULTIPLE MEMORY SYSTEMS

The memory impairment in H.M. and other patients is narrower than once thought in that not all kinds of learning and memory are affected. The first hint of this idea came when H.M. was found capable of learning a hand-eye coordination skill (mirror drawing) over a period of days, despite having no recollection of practicing the task before (Milner 1962). Although this finding showed that memory was not unitary, for some time it was thought that motor skill learning was a special case and that all the rest of memory is of one piece and is impaired in amnesia. Subsequently, it was discovered that motor-skill learning is but one example of a large domain of learning and memory abilities, all of which are intact in H.M. and other patients. H.M.'s motor skill learning marked the beginning of a body of experimental work that would eventually establish the biological reality of two major forms of memory.

An early insight was that perceptual skills and cognitive skills, not just motor skills, are preserved in amnesia. Specifically, amnesic patients acquired at a normal rate the perceptual skill of reading mirror-reversed words, despite poor memory for the task itself and for the words that were read (Cohen & Squire 1980). This finding was the basis for the formulation of a brain-based distinction between

two major forms of memory, which afford either declarative or procedural knowledge. Declarative knowledge referred to knowledge available as conscious recollections about facts and events. Procedural knowledge referred primarily to skill-based information, where what has been learned is embedded in acquired procedures.

Subsequently, memory-impaired patients were found to exhibit intact priming effects (see Tulving & Schacter 1990). For example, patients (like healthy volunteers) could name pictures of objects 100 ms faster when the pictures had been presented previously than when they were presented for the first time and independently of whether patients could recognize the pictures as familiar (Cave & Squire 1992).

Another important insight was the idea that the neostriatum (not the medial temporal lobe) is important for the sort of gradual, feedback-guided learning that results in habit memory (Mishkin et al. 1984). Thus, memory-impaired patients learned at a normal rate when explicit memorization was not useful (for example, when the outcome of each trial was determined probabilistically and performance needed to be based on a gut feeling) (Knowlton et al. 1996). Furthermore, tasks that healthy volunteers could learn rapidly by memorization (such as the concurrent learning of eight different, two-choice object discriminations) could also be learned successfully by profoundly amnesic patients, albeit very gradually (healthy volunteers required fewer than 80 trials; patients required more than 1000 trials). Although memory became robust in the patients after extended training (>90% accuracy), it differed from the memory acquired by healthy volunteers in that what was learned was outside of awareness and was rigidly organized (performance collapsed when the task format was modified) (Bayley et al. 2005a).

Given the wide variety of learning and memory phenomena that could be demonstrated in patients (for example, priming and habit learning), the perspective eventually shifted to a framework that accommodated multiple memory systems, not just two kinds of memory.

Indeed, one could ask what the various kinds of memory that were preserved in patients had in common aside from the fact that they were not declarative. Accordingly, the term non-declarative was introduced with the idea that declarative memory refers to one kind of memory system and that nondeclarative memory is an umbrella term referring to several additional memory systems (Squire & Zola-Morgan 1988). Nondeclarative memory includes skills and habits, simple forms of conditioning, emotional learning, priming, and perceptual learning, as well as phylogenetically early forms of behavioral plasticity such as habituation and sensitization.

Declarative memory is the kind of memory that is referred to when the term memory is used in everyday language. Declarative memory allows remembered material to be compared and contrasted. The stored representations are flexible, accessible to awareness, and can guide performance in a variety of contexts. Declarative memory is representational. It provides a way of modeling the external world, and it is either true or false. Nondeclarative memory is neither true nor false. It is dispositional and is expressed through performance rather than recollection. These forms of memory provide for myriad unconscious ways of responding to the world. In no small part, by virtue of the unconscious status of the nondeclarative forms of memory, they create some of the mystery of human experience. Here arise the dispositions, habits, and preferences that are inaccessible to conscious recollection but that nevertheless are shaped by past events, influence our behavior and mental life, and are an important part of who we are.

VISUAL PERCEPTION

Formal testing of patient H.M. over the years documented his good performance on intelligence tests and on other tests of perceptual function and lexical knowledge (Kensinger et al. 2001, Milner et al. 1968). He could detect the anomalous features of cartoon drawings, and he performed above the control mean on the Mooney “Closure” task, which requires

participants to find a face in a chaotic black and white pattern with incomplete contour (Milner et al. 1968). This perspective, that visual perception is intact after large medial temporal lobe lesions, was eventually challenged, first by work in monkeys (Eacott et al. 1994) and later by studies in humans (Lee et al. 2005a,b). These studies proposed that the perirhinal cortex, one of the structures damaged in H.M., is important for complex visual perceptual tasks involving stimuli with substantial feature overlap. It was also proposed that the hippocampus is needed when spatial processing is required, as in visual discriminations involving scenes.

Although some subsequent studies appeared to provide additional support for this perspective (Barens et al. 2007, Lee & Rudebeck 2010), attempts to replicate some of the key early work and to find impairments with new tests were unsuccessful (Shrager et al. 2006). Comprehensive reviews of this topic (Suzuki 2009, 2010) raised three important issues. First, a consideration of neuroanatomic and neurophysiological data emphasizes that the perirhinal cortex has unique characteristics that distinguish it from the laterally adjacent, unimodal visual area TE. The perirhinal cortex is a polymodal association area with strong connections to the hippocampus and entorhinal cortex, and it is difficult to view the perirhinal cortex as a visual area and as a continuation of the ventral visual pathway (Suzuki 2010).

Second, many of the studies designed to test visual perception, particularly studies in monkeys, involve a significant memory requirement. Thus, impaired associative learning or impaired long-term memory for the stimulus material could have contributed to many of the deficits reported after perirhinal lesions in monkeys. Even in studies of humans, impaired associative learning could result in deficient performance when different test stimuli need to be judged against the same two comparison stimuli on every trial (Graham et al. 2006). Indeed, in a new study that explored this issue, patients with hippocampal lesions were impaired when the same comparison stimuli were used on every trial but were fully intact when the

stimuli were unique to every trial (Kim et al. 2011). Using fixed comparison stimuli gives an advantage to those who can remember because one can learn what to look for in the test stimuli to decide which comparison stimulus it most closely resembles.

Third, patients who exhibit impaired performance on tasks of visual perception may have significant damage to lateral temporal cortex in addition to medial temporal lobe damage. This idea merits consideration, given that two of the three patients with medial temporal lobe damage who were impaired were reported to have damage lateral to the medial lobe (Barens et al. 2007; Lee et al. 2005a,b; Lee & Rudebeck 2010). Also, estimates of damage in most of the patients who were impaired were based on ratings of single sections through the lateral temporal cortex, not on quantitative measures of the entire region, thus leaving large amounts of tissue unexamined.

The importance of thorough neuroanatomical measurement in neuropsychological studies of memory cannot be overstated. Many current disagreements about the facts and ideas emerging from neuropsychological research on human memory can be traced to concerns about the locus and extent of lesions. If a deficit is expected but not found, perhaps the damage is less extensive than believed. If a deficit is not expected but is found, perhaps the damage is more extensive than has been detected. There is no substitute for thorough, quantitative descriptions of damage based on magnetic resonance imaging, as well as (where possible) detailed neurohistological description of the postmortem brain.

The possible role of perirhinal cortex in certain kinds of visual perception remains a topic of discussion and will benefit from detailed analysis of the lesions in the cases under study. At the present time, the weight of evidence from experimental lesion studies in monkeys, neurophysiological studies, and human neuropsychological studies continues to support the view that medial temporal lobe structures are important for declarative memory and not for perceptual functions (see also Clark et al. 2011).

IMMEDIATE MEMORY AND WORKING MEMORY

The early descriptions of H.M. emphasized how capable he was at focusing his attention and at retaining information for short periods of time (Milner et al. 1968). For example, he could retain a three-digit number for 15 minutes by continuous rehearsal, using what would now be termed working memory (Baddeley 2003). Yet when his attention was diverted, he forgot the whole event. In one dramatic demonstration, participants heard digit strings of increasing length (Drachman & Arbib 1966) (**Figure 3a**). Each string was presented as many times as needed until it was reported back correctly. Then, a new digit string was presented that was one digit longer than the previous one. Controls made their first errors with strings of eight digits and were eventually able to repeat strings as long as 20 digits (with no more than 25 repetitions at any one string length). In contrast, H.M. exhibited a marked discontinuity in performance as the string length increased. He repeated up to six digits correctly on his first try (six was his preoperative digit span), but he never succeeded at seven digits, even though he was given 25 repetitions of the same string. The interpretation was that at short string lengths H.M. could rely on his intact immediate memory and that he failed when the material to be remembered was more than could be held in mind. That is, he failed when the material exceeded his immediate memory capacity.

Time is not the key factor that determines how long information can be retained by patients like H.M. The relevant factors are immediate memory capacity and how successfully material can be maintained in working memory through rehearsal. Maintenance of information is difficult when material is difficult to rehearse (e.g., faces and designs). Moreover, working memory capacity can be quite limited, and typically only three or four simple visual objects can be maintained (Cowan 2001, Fukuda et al. 2010). With these considerations in mind, it is perhaps not surprising that impaired performance after medial temporal lobe

lesions has sometimes been reported at short retention intervals, usually when the task requires learning complex material or learning the relations between items (e.g., object-location associations) (Finke et al. 2008, Hannula et al. 2006, Kan et al. 2007, Olson et al. 2006). In these cases, the important question is whether working memory capacity has been exceeded and performance must rely on long-term memory, or whether working memory sometimes depends on the medial temporal lobe. Methods that are independent of the particular task that is used are needed to decide this question.

One approach to this issue seems promising in cases where the retention interval is long enough (about 8 seconds) to allow a manipulation to be introduced during the interval (Shrager et al. 2008). Controls (but not patients) were given either distraction or no distraction between study and test. Across experiments involving names, faces, or object-location associations, patient performance was related to how distraction affected controls. The patients were impaired when distraction had no effect on control performance, and the patients were intact when distraction disrupted control performance. These results suggested that the patients were impaired when the task

depended minimally on working memory (as indicated by the ineffectiveness of distraction on control performance), and they performed well when the task depended substantially on working memory (as indicated by the disruptive effect of distraction on controls). Thus, for the kinds of material studied here, including relational information for objects and locations, working memory appears to be intact after medial temporal lobe damage.

A possible approach in cases where the retention interval is very short (1–3 seconds) is based on the early study of digit span, described above. Participants saw different numbers of objects (1 to 7) arranged on a tabletop and then immediately tried to reproduce the array on an adjacent table (Jeneson et al. 2010) (**Figure 3b**). The same study-test sequence was repeated (up to a maximum of ten times) until participants correctly placed each object within a specified distance of its original location. The finding was that performance was intact when only a few object locations needed to be remembered. However, just as was found for digit strings, there was an abrupt discontinuity in performance with larger numbers of object locations. For example, patient G.P. (who has large medial temporal lobe lesions similar to H.M.'s lesions) learned 1, 2, or 3 object locations as quickly as

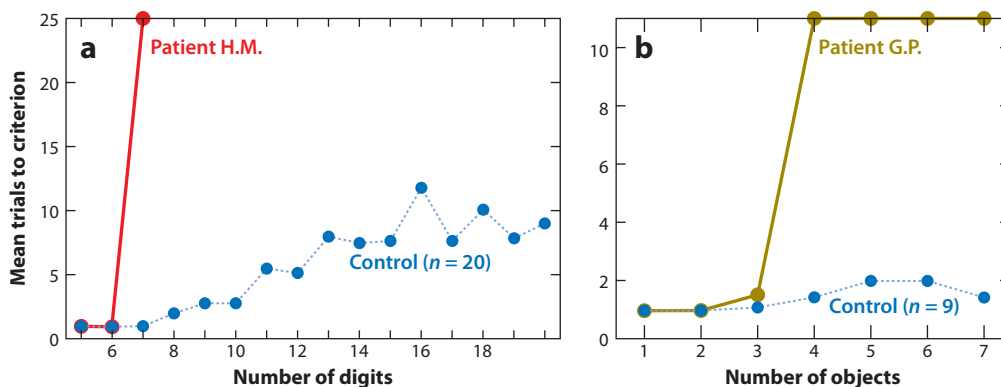


Figure 3

Intact working memory and impaired long-term memory. (a) The number of trials needed to succeed at each string length for patient H.M. and controls. H.M. could not succeed at repeating back 7 digits even after 25 attempts with the same string. (b) The number of trials needed to learn the locations of different numbers of objects for patient G.P. and controls. G.P. could not reproduce the locations of four objects, even after 10 attempts with the same display (panel a adapted from Drachman & Arbit 1966, with permission from the American Medical Association, and panel b adapted from Jeneson et al. 2010).

did controls, needing no more than one or two tries at each stage. However, when four object locations needed to be remembered, he could not succeed even in 10 attempts with the same array. These findings suggest that the maintenance of relational information (in this case, object-location associations) can proceed normally, even in patients with large medial temporal lobe lesions. An impairment is evident only when a capacity limit is reached, at which point performance must depend, at least in part, on long-term memory.

These observations support the view that patients with medial temporal lobe lesions can succeed at remembering whatever they have encountered, so long as the material to be remembered can be supported by a limited-capacity, short-term memory system (see also Jeneson et al. 2011). This formulation touches on a large and fundamental issue: whether there is any ability at all that depends on the hippocampus and related structures, even when a task can be managed within working memory. That is, do these structures perform any online computations for which the distinction between working memory and long-term memory is irrelevant?

This is a question of considerable current interest. It runs through discussions of perceptual functions and discussions of relational memory (as considered in this section and the preceding section). The issue is especially prominent in discussions of spatial cognition. For example, the ability to path integrate (i.e., the ability to use self-motion cues to keep track of a reference location as one moves through space) has been proposed to have a fundamental dependency on the hippocampus and entorhinal cortex. That is, these structures are proposed to carry out computations essential for path integration, regardless of the memory load or the retention interval (Whitlock et al. 2008). Furthermore, the hippocampus is proposed to be necessary for constructing a spatially correct mental image of either a remembered scene or an imagined scene (Bird et al. 2010, Bird & Burgess 2008), a task that need not involve recollection at all.

In the case of path integration, humans can succeed at simple paths in the absence

of hippocampus and entorhinal cortex so long as the task can be managed within 30–40 seconds (presumably supported by working memory) (Shrager et al. 2008). In the case of spatial imagining, patients with severe memory impairment can describe routes around their childhood neighborhoods, including when main routes are blocked and alternative routes must be found (Rosenbaum et al. 2000, Teng & Squire 1999). Furthermore, in one study, patients with hippocampal damage successfully imagined future events and provided a normal number of spatial referents (Squire et al. 2010; see Hassabis et al. 2007 for a deficit on a similar task). These demonstrations appear straightforward and would seem to raise doubts about the idea that the hippocampus performs online computations. Yet there is an alternate perspective. Specifically, it has been suggested that spatial representations can be established outside the hippocampus, and in parallel with hippocampal representations, but using somewhat different computations (Bird & Burgess 2008, Whitlock et al. 2008). By this account, some spatial tasks that are accomplished successfully after hippocampal damage are in fact being accomplished using different structures and different computations than are used by healthy individuals.

The idea is that, despite intact performance in patients, some tasks are still hippocampus-dependent and could be shown to be so if one could devise tasks that can only be done with computations unique to the hippocampus. This is an interesting perspective and one that, in principle, could be applied to any example of intact performance in patients. It will be difficult to resolve issues like these without understanding which strategies are used in any particular case and without gaining experimental control over them. In addition, tasks that can be solved by different structures and using different strategies may be associated with inconsistent deficits after hippocampal lesions. In contrast, there are some tasks that depend on the medial temporal lobe, where performance deficits are invariably pronounced, and where performance cannot be made to appear normal

by recruiting other brain structures or by using different strategies. These are tasks that assess the ability to form conscious long-term memory of facts and events, and the inability to carry out this function appears to be the central deficit in H.M. and other patients with medial temporal lobe lesions.

REMOTE MEMORY AND MEMORY CONSOLIDATION

A key insight about the organization of memory came with early observations of H.M.'s capacity to remember information that he acquired before his surgery in 1953. Initially, he was described as having a loss of memory (retrograde amnesia) covering the three years immediately preceding surgery and with earlier memories "seemingly normal" (Scoville & Milner 1957, p. 17). About ten years later, the impression was similar as there did not appear to have been any change in H.M.'s capacity to recall remote events antedating his operation, such as incidents from his early school years, a high school attachment, or jobs he had held in his late teens and early twenties (Milner et al. 1968, p. 216).

The first study of this issue with formal tests asked H.M. to recognize faces of persons who had become famous in the decades 1920–1970 (Marslen-Wilson & Teuber 1975). As expected, he performed poorly in the postmorbid period (the 1950s and 1960s) but did as well as or better than age-matched controls at recognizing faces from the premorbid period (the 1920s–1940s). This important finding implied that medial temporal lobe structures are not the ultimate storage sites for acquired memories. Memories that initially require the integrity of medial temporal lobe structures must be reorganized as time passes after learning so as to gradually become independent of these structures. The extent of retrograde amnesia provides an indication of how long this process takes.

Retrograde amnesia can be either temporally limited, covering a few years, or prolonged, depending on the locus and extent of the damage. Patients with damage thought to be restricted to the hippocampus had

retrograde amnesia for past news events that extended only a few years into the premorbid period (Manns et al. 2003b). By contrast, patients with large medial temporal lobe lesions (damage to hippocampus plus parahippocampal gyrus) exhibited extended retrograde amnesia that covered several decades, albeit sparing memories acquired in early life (patients E.P. and G.P.; Bayley et al. 2006, Bright et al. 2006). The possibility that some amount of more lateral damage (e.g., in the fusiform gyrus) contributed to the extended retrograde impairment in E.P. and G.P. cannot be excluded.

There has been particular interest in the status of autobiographical memories for unique events following medial temporal lobe damage, and in recent years methods have been developed to assess the detail with which such recollections can be reproduced. In the earliest formal assessments of H.M. (Sagar et al. 1985), he produced well-formed autobiographical memories from age 16 and younger (his surgery occurred at age 27). However, the situation seemed to change as H.M. aged. In a later update (Corkin 2002), H.M. (now 76 years old) was reported to have memories of childhood, but the memories appeared fact-like and lacked detail. It was stated that he could not reproduce a single event that was specific to time and place. In a formal study reported a few years later (Steinvorth et al. 2005), he was also impaired in recollecting events from his early life. It was concluded that autobiographical memories remain dependent on the medial temporal lobe so long as the memories persist.

This conclusion about H.M. is complicated by the findings from MRI scans obtained in 2002 and 2003 (Salat et al. 2006). These scans documented a number of significant changes since his first MRI scans from 1992–1993 (Corkin et al. 1997) (**Figure 1**). Specifically, the scans showed cortical thinning, subcortical atrophy, large amounts of abnormal white matter, and subcortical infarcts. All these features were thought to have developed during the past decade, and they complicate the interpretation of neuropsychological data collected during and after this period. Considering the

earlier reports that he could successfully retrieve past autobiographical memories (Milner et al. 1968, Scoville & Milner 1957), it is possible that remote autobiographical memories were in fact intact during the early years after surgery but were later compromised by neurological change. It is also possible that the available memories faded with time because they could not be strengthened through rehearsal and relearning.

Other work has supported the earlier descriptions of H.M. For example, methods similar to those used to assess H.M. have also been used to evaluate autobiographical memory in other patients with hippocampal damage or larger medial temporal lobe lesions (Bright et al. 2006, Kirwan et al. 2008). These patients had intact autobiographical memory from their early lives. The following example illustrates a well-formed autobiographical memory produced by E.P. about his early life, one of 18 that he produced. In this case, he was asked for a specific recollection in response to the cue word "fire." Like most recollections, his narrative contains both fact-based and event-specific information. Note the several repetitions in the narrative, which reflect his severe anterograde amnesia.

Dad had 3½ acres of property in Castro Valley and the back property would just grow and would be dry and for some reason, I didn't do it, but somehow or other the next thing we knew is that it was starting to burn. I told dad and he called the Castro Valley fire department. They came up and they got it out real quick. However it started I don't know. He had 3½ acres of property and he just let it grow. It would be grass or whatever. Who knows how it started, but it started to burn. Dad called the Castro Valley fire department and they came up and all the volunteers came in and they got it out in a matter of 10–15 minutes. They stamped it out. They don't know how it started. I was 16–17, in that bracket. Dad had 3½ acres of property. It was summer time, 1938. Those sort of things I think you remember. (Bayley et al. 2003, p. 139)

The same finding of intact early memories was reported in 10 patients with medial temporal lobe lesions in a study of emotional (and remote) autobiographical memories (Buchanan et al. 2005), and in two other patients (M.R. and P.D.), using a simpler assessment device (Eslinger 1998). In another study of four patients with medial temporal lobe damage and variable damage to anterior and posterior temporal neocortex (Rosenbaum et al. 2008), one patient (S.J.) was reported to have extended retrograde amnesia for autobiographical memory. The other three patients were less impaired, performing poorly in time periods closer to the onset of their amnesia. The impairment in S.J. was attributed to hippocampal damage. Alternatively, it is difficult to rule out a substantial contribution from the damage that was identified in neocortex.

It is noteworthy that, not infrequently, patients have been described as having extensive and ungraded retrograde amnesia (i.e., unrelated to how long ago the memory was formed) (for examples, see Bright et al. 2006, Cipolotti et al. 2001, Noulhiane et al. 2007, Rosenbaum et al. 2008, Sanders & Warrington 1971). This pattern of impairment has sometimes been taken to mean that the hippocampus (or related structures) is required as long as a memory persists. Yet, in many cases testing did not cover early adulthood and adolescence, so it is possible that the amnesia was not as ungraded as it appeared to be. In other cases, the damage was known to extend substantially into lateral temporal neocortex (see Bright et al. 2006 and Squire & Bayley 2007 for consideration of several cases). In one report of patients with unilateral temporal lobe resections, autobiographical memory was impaired across all past time periods (Noulhiane et al. 2007). In these patients, damage was recorded in the medial temporal lobe as well as in the temporal pole and in the anterior aspect of the superior, middle, and inferior temporal gyri. It is difficult to know to what extent this damage outside the medial temporal lobe might have contributed to the impairment. Significant damage to lateral temporal or frontal cortex can severely impair

performance on tests of remote memory, including tests of autobiographical memory about early life [7 cases, Bright et al. (2006); patients H.C., P.H., and G.T., Bayley et al. (2005b); patient E.K., Eslinger (1998)]. If lateral temporal cortex, for example, is a site of long-term memory storage (Mishkin 1982, Miyashita 1993), then lateral temporal damage would be expected to cause severe and extended retrograde amnesia. The difficulty is knowing in any particular case to what extent such damage is responsible for impaired remote memory.

Among several single-case studies reporting impaired memory for early-life events (see Squire & Bayley 2007 for discussion), patient V.C. has been the most carefully documented. The volume of his lateral temporal lobes was reported as normal. Yet, it is striking that V.C.'s 1/9 score on the childhood portion of the autobiographical memory interview differs sharply from the good scores (and sometimes maximum scores of 9) obtained on the same test by as many as 12 patients with MRI documentation of limited medial temporal lobe damage [$n = 8$, Bayley et al. (2006); $n = 2$, Eslinger (1998); $n = 1$, Kapur & Brooks (1999); $n = 1$, Schnider et al. (1995)]. With the possible exception of V.C., we are unaware of memory-impaired patients who have damage limited to the medial temporal lobe (as documented by neurohistology or thorough MRI) and who do so poorly at recollecting remote autobiographical memories (**Figure 4**).

The finding that retrograde amnesia is temporally limited after damage to the medial temporal lobe implies a process of reorganization whereby over time memories become less dependent on medial temporal lobe structures. As time passes after learning, the role of medial temporal lobe structures diminishes and a more permanent memory gradually develops, presumably in neocortex. According to a different perspective, only fact-based memories (not autobiographical memories) make this transition (Winocur et al. 2010). This view discounts the possible importance of neocortical damage in patients with impaired autobiographical remembering of remote events and attributes

the impairment specifically to hippocampal damage.

Some studies in experimental animals have directly tracked neural activity and structural changes in the hippocampus and neocortex after learning. Expression patterns of c-Fos described gradually decreasing activity in the mouse hippocampus after learning and parallel increases in a number of cortical regions (Frankland & Bontempi 2005). These findings and others (Restivo et al. 2009) reflect the increasing importance of distributed cortical regions for the representation of memory as time passes. The idea is not that memory is literally transferred from the hippocampus to neocortex but that gradual changes in the neocortex increase the complexity, distribution, and connectivity among multiple cortical regions. The next section considers what the study of patients has contributed to understanding the organization and storage of long-term memory.

MEMORY IN THE NEOCORTEX

The view that emerged from the study of H.M. and other patients is that medial temporal lobe structures are uniquely specialized to establish and maintain declarative memories. Other structures support the initial perception and processing of an experience, and these other structures are also critical for the long-term storage of the experience. A long-standing view is that the cortical processing of a multisensory experience leaves a distributed record in the same multiple regions that initially performed the processing. For example, neurons in visual areas store the visual aspect of a multisensory experience, neurons in auditory areas store the auditory aspect of the experience, other areas store the spatial aspects, and so on. According to this view, any act of remembering consists of the coordinated reactivation of the distributed neocortical regions that were engaged at the time of encoding (Damasio 1989, De Renzi 1982, Mishkin 1982, Squire 1987). When a memory is first formed, this reactivation depends on the hippocampus and related structures, but once

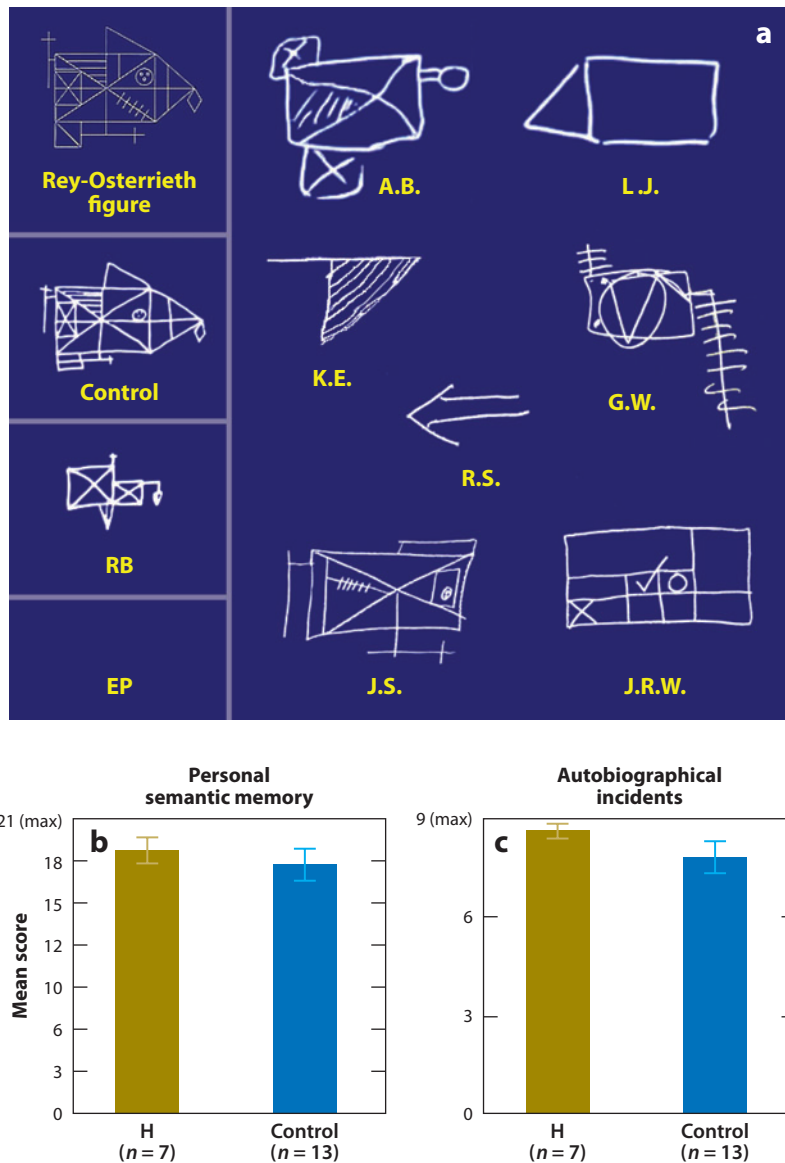


Figure 4

(a) Participants copied the Rey-Osterrieth figure illustrated in the small box in the upper left and 10–15 min later, without forewarning, tried to reproduce it from memory. The reproduction by a representative control is shown below the target figure. The left panel also shows the reproduction by patient R.B., who had histologically identified lesions of the CA1 field of the hippocampus (Zola-Morgan et al. 1986). Patient E.P., who had large medial temporal lobe lesions, did not recall copying a figure and declined to guess. The right section shows reproductions by seven patients with circumscribed damage to the hippocampus. Panels *b* and *c* show scores for the same seven patients (H) and 13 controls on the autobiographical memory interview, childhood portion (Kopelman et al. 1989). These findings suggest that patients who fail to produce any of the complex figure (like E.P.) or who are deficient at producing either remote semantic memories (A, maximum score, 21) or remote autobiographical events (B, maximum score, 9) will prove to have damage beyond the hippocampus. Indeed, even E.P. with his large lesions limited mainly to the medial temporal lobes, obtained maximal scores on these two tests (21/21 and 9/9).

memory is fully consolidated, reactivation can occur independently in neocortex.

A considerable body of evidence supporting the reactivation view has come from studies using fMRI (see Buckner & Wheeler 2001, Danker & Anderson 2010 for reviews). For example, several studies have found that the modality-specific or category-specific processes engaged at encoding tend to be re-engaged at retrieval (e.g., Polyn et al. 2005, Wheeler et al. 2000, Woodruff et al. 2005). This perspective of remembering implies that the dedicated processing areas of the neocortex can also be viewed as memory areas. However, rather than broadly encoding and consolidating memories, like the structures of the medial temporal lobe, each neocortical region operates within a very specific domain, and each region stores only specific features of an experience. It follows then that the same neocortical lesions that selectively impair processing in one particular domain should also cause correspondingly specific anterograde and retrograde memory impairments within the same domain. Although an extensive literature documents the selective information-processing deficits that are associated with different cortical lesions, the effects of those lesions on new learning and past remembering are only rarely considered. Here, we consider the cognitive effects of selective processing deficits with a view toward also identifying the effects on memory.

Achromatopsia

Finding selective anterograde memory impairment in association with a selective perceptual processing deficit would not be surprising. That is, if a perceptual deficit is present in one modality (e.g., visual perception), it should also be difficult to learn new material presented in the same modality. In addition, there should be consequences for remembering the past. Specifically, a selective deficit in processing particular features of visual material should selectively compromise the ability to recollect the same features in a previous memory, while leaving other aspects of the memory intact. This

idea is illustrated by “The Case of the Color-blind Painter” (Sacks 1995). An accomplished painter was involved in an automobile accident at the age of 65, which rendered him completely color blind. Although the anatomical basis of his disability was not identified, it was thought to have been caused by damage to regions dedicated to the perception of color (possibly including area V4). The disability itself was striking. The patient could discriminate between wavelengths of light, even though the different wavelengths no longer gave rise to the perception of different colors. Instead, different wavelengths gave rise to the perception of different shades of gray. Because this was a case of acquired cerebral achromatopsia (i.e., cortical color blindness), it was possible to ask about the status of previously established memories that had once included the subjective experience of color. If color in early memories depends on the same cortical structures that support the perception of color, then previously intact memories that were once retrieved in color should now be retrieved in black and white. Indeed, the case description leaves little doubt that the patient’s experience—both going forward and looking back—was now completely (and selectively) devoid of color. Although he retained abstract semantic knowledge of color, he could neither perceive nor later remember the color of objects presented to him (anterograde impairment). In addition, he could not subjectively experience color in his earlier (and once chromatic) memories (retrograde impairment). For example, he knew that his lawn was green, but he reported that he could no longer visualize it in green when he tried to remember what it once looked like.

Prosopagnosia

Similar effects have been documented by formal testing in cases of acquired prosopagnosia (impaired recognition of faces, or face blindness). The cardinal complaint of patients diagnosed with prosopagnosia is that they have a selective retrograde memory deficit. That is, once-recognizable faces no longer yield a

memory signal, even though other aspects of one's memory for the same individuals are preserved. For example, a patient who could not recognize his mother's face might continue to recognize the sound of her voice and still be able to recall his prior experiences with her.

Patient L.H., a 37-year-old man, sustained a severe closed-head injury in an automobile accident at the age of 18 (Farah et al. 1995a,b). His brain damage involved bilateral inferior temporo-occipital regions, as well as the right inferior frontal lobe and right anterior temporal lobe. Although general intellectual and elementary visual capabilities were preserved following the accident, L.H. became profoundly impaired at recognizing previously familiar faces. Along with this retrograde memory deficit, L.H. also exhibited a perceptual processing deficit that was selective for upright faces. For example, on a same/different face discrimination task, L.H. performed worse than controls at discriminating upright faces (consistent with a face perception deficit), but he performed unexpectedly better than controls at discriminating inverted faces (indicating that general perceptual abilities were preserved). Patient L.H. also exhibited anterograde amnesia for new faces. For example, L.H. and controls were presented with black and white photographs of both faces and common objects and asked to memorize them (Farah et al. 1995a). On a later recognition test, control subjects performed at the same level for faces and nonface objects. L.H.'s ability to remember faces was selectively impaired.

The retrograde memory deficit associated with acquired prosopagnosia is not confined to recognition memory but applies as well to recalling and imaging the past. In one study, (Barton & Cherkasova 2003), seven patients with adult-onset prosopagnosia performed comparative judgments about the configuration of famous faces that they tried to retrieve from memory (e.g., "Who has the more angular face: George Washington or Abraham Lincoln?"). The famous faces used in this test were presumably familiar before the onset of prosopagnosia. Even so, the patients were severely impaired on the face imagery task. Together, the

findings from acquired prosopagnosia—a modular perceptual processing deficit associated with selective anterograde and retrograde amnesia—suggest that the same areas that support the perception of faces also support the long-term memory of faces.

Amusia

This same set of findings, whereby an acquired and relatively modular processing deficit is associated with corresponding memory deficits (both anterograde and retrograde), has also been reported in a patient who lost the ability to recognize familiar music while retaining other perceptual and intellectual functions (amusia). Patient I.R. suffered bilateral brain damage at the age of 28 after undergoing a series of operations to clip aneurysms on the left and right middle cerebral arteries (Peretz et al. 1998, Peretz & Gagnon 1999). At the time she was tested (in her early 40s), CT scans indicated that the superior temporal gyrus was severely damaged bilaterally, and the lesion also extended to involve structures in the frontal cortex and anterior inferior parietal lobule.

I.R. was of normal intelligence, and her overall memory ability was normal as well. In addition, she exhibited no evidence of a hearing impairment according to standard audiometric tests, and except for music she had no difficulty recognizing familiar environmental sounds. However, tunes that were once familiar to her were now unrecognizable, and she could no longer sing music from memory (which she had previously been able to do). Her selective retrograde amnesia for previously familiar music was also accompanied by a selective perceptual deficit for music. Musical perception was tested using a same/different format in which two short excerpts were presented in succession (e.g., Mozart's piano concerto #27 followed by Mozart's piano concerto #23). Controls found this task so easy that they made no errors even when the interstimulus interval was long (20 s) and filled with conversation, but I.R.'s performance was no better than 80% correct even when the interstimulus interval was short (4 s).

She also exhibited anterograde amnesia for new music. A list of 15 briefly presented melodies was presented for study. On a subsequent old/new recognition test involving the 15 old melodies intermixed with 15 new ones, her memory performance was no better than chance (whereas control performance exceeded 85% correct). Thus, as with the cases of acquired achromatopsia and acquired prosopagnosia discussed earlier, impairments associated with acquired amusia imply a close connection between information processing and storage. The specificity of her anterograde and retrograde memory deficits corresponded directly to the specificity of her perceptual deficit.

Knowledge Systems

The findings considered here are consistent with the idea that memory storage in the neocortex reflects the outcome of the perceptual processing and analysis that occurred at the time of learning. A related literature concerns the status of stored semantic knowledge and its relation to information processing. These studies do not document a deficit in specific perceptual processing modules. Instead, they document the effects of cortical lesions (e.g., to posterior temporal cortex) on previously acquired knowledge within specific semantic categories, and they relate these deficits to the kinds of processing involved when the knowledge was first acquired.

The idea that knowledge systems may be organized by semantic categories was discussed by Warrington & Shallice (1984). They described four patients with widespread bilateral lesions (following herpes simplex encephalitis) that included the medial and lateral temporal lobes. In addition to having global amnesia, all four patients exhibited an asymmetry in their ability to identify animate and inanimate objects. They had a selective impairment in the ability to name or describe pictures of animate objects (e.g., animals and plants). By contrast, their ability to name or describe pictures of inanimate objects (e.g., broom, pencil, umbrella) appeared to be preserved. Assuming that all the objects were

previously familiar to the patients, the findings describe a category-specific retrograde memory impairment.

Other patients exhibited the opposite impairment. For example, patient Y.O.T., who had damage to the left temporoparietal region (thought to have resulted from a thromboembolism), showed relatively preserved knowledge of living things and poor knowledge of inanimate objects (Warrington & McCarthy 1987). However, her comprehension of body parts and fabrics was anomalous in that she exhibited knowledge about fabric names (non-living things) and poor knowledge about body parts (living things). In addition, Warrington & McCarthy (1987) noted that patient J.B.R. [one of the four patients previously described by Warrington & Shallice (1984)], who had exhibited a selective loss of knowledge about living things, nevertheless had preserved knowledge about body parts (living things) and poor knowledge about fabrics (nonliving things). These findings suggested that the principle by which knowledge is organized in the brain concerns whether objects are identified mainly by their physical features (form, color, texture, etc.) or by their function and how they are used. Generally, the animate/inanimate distinction fits this principle, but the exceptions are telling. Most animals are identified by their physical attributes, not by what can be done with them. By contrast, small inanimate objects are usually identified by their functions and how they are used (e.g., sweep with a broom, write with a pencil). However, some living things (such as body parts) are identified largely by their function, and some nonliving things (such as fabrics) are identified largely by their texture and shape. A recent comprehensive review of neuroimaging evidence strongly supports this account of stored semantic knowledge (Martin 2007).

If these category-specific retrograde memory deficits reflect the loss of knowledge that was initially acquired through category-specific processing, then a corresponding anterograde memory deficit would be expected, as well. Thus, for example, a patient who exhibits a selective deficit in naming or describing objects

that are defined by how they are used should also exhibit a selective deficit in learning novel objects that are defined by how they are used. To our knowledge, this prediction has not been tested.

RECOLLECTION AND FAMILIARITY

In recent years, there has been extended investigation of the idea that the different medial temporal lobe structures (hippocampus, entorhinal cortex, perirhinal cortex, and parahippocampal cortex) may support different memory functions. The study of H.M. could not address this issue because his bilateral lesions included most of these structures. However, other patients, especially patients with limited hippocampal lesions, have been useful in this regard.

One issue that has commanded considerable attention concerns the roles played by the hippocampus and perirhinal cortex in recognition memory. Recognition memory is thought to be supported by two processes, recollection and familiarity (Atkinson & Juola 1974,

Mandler 1980). Recollection involves remembering specific contextual details about a prior learning episode; familiarity involves simply knowing that an item was presented without having available any additional information about the learning episode. According to one view, both the hippocampus and the perirhinal cortex contribute to recollection and familiarity (Squire et al. 2007, Wixted & Squire 2010). According to a different view, the hippocampus and perirhinal cortex selectively support recollection and familiarity, respectively (Brown & Aggleton 2001, Eichenbaum et al. 2007).

Recall versus Recognition

One approach to investigating this issue has been to compare performance on an old/new recognition task, which is widely thought to be supported by both recollection and familiarity, with performance on a task of free recall, which is thought to depend mainly on recollection. (In a free recall task, subjects are presented with a list of items to memorize and are later asked to recall those items in any order they wish.) Because old/new recognition can be partially supported by familiarity, the question of interest is whether the performance of patients with hippocampal lesions is disproportionately better on an old/new recognition task in comparison to free recall.

Several case studies and group studies have asked this question of patients with adult-onset bilateral lesions that, according to quantitative MRI, are limited to the hippocampus. The case studies differ in their findings about the status of old/new recognition memory (Aggleton et al. 2005, Cipolotti et al. 2006, Mayes et al. 2002). Because the differing results may reflect individual differences, group studies are more informative. Two group studies have shown that the degree of impairment is similar when old/new recognition and free recall are compared (Kopelman et al. 2007, Manns et al. 2003a) (Figure 5). Another group study involved 56 hypoxic patients with damage believed to be limited to the hippocampus (no radiological information was available)

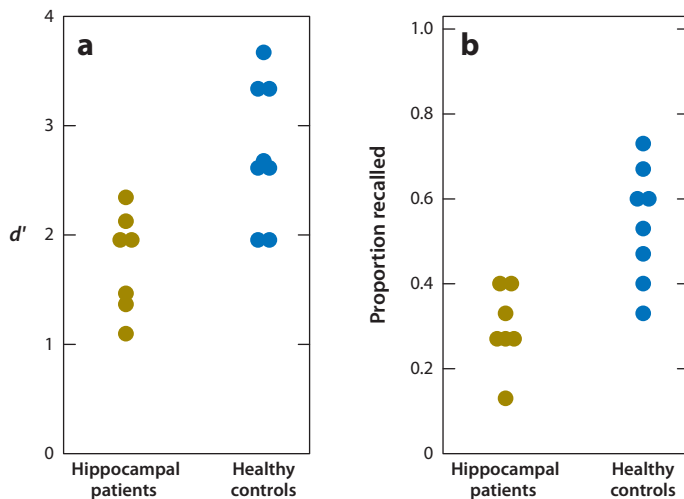


Figure 5

Individual recognition (*a*) and recall scores (*b*) for hippocampal patients ($n = 7$) and healthy controls ($n = 8$) from Manns et al. (2003a). When the patient scores for recognition and recall are converted to z-scores based on the mean and standard deviation of the corresponding control scores, the recognition deficit (-1.59) is statistically indistinguishable from the recall deficit (-1.81), $p > 0.60$. d' = discriminability.

(Yonelinas et al. 2002). The patients were less impaired on old/new recognition than on free recall. However, this conclusion was later shown to result from the remarkably aberrant recognition performance of a single 1 of the 55 control subjects (Wixted & Squire 2004). With that one outlier removed from the analysis, the patients and controls exhibited similar levels of impairment on recall and recognition. The recognition z-score for the patients was -0.59 (before removal of the outlier, $z = -0.39$), and the recall z-score was a statistically indistinguishable -0.68 . Thus, the available group studies are consistent in showing that the degree of memory impairment in patients with lesions limited to the hippocampus is similar for old/new recognition (which is substantially supported by familiarity) and for free recall (which is fully dependent on recollection). These findings suggest that the hippocampus is important for both recollection and familiarity.

Remember/Know Procedure

Another method that has been used to investigate the role of the medial temporal lobe in recollection and familiarity is the Remember/ Know procedure, which is based on subjective reports of whether recollection is available when an item is declared old. Participants report Remember when they can recollect something about the original encounter with the item (e.g., its context, what thoughts they had), and they report Know when they judge the item to be familiar but cannot recollect anything about its presentation. The Remember/Know judgments made by patients and controls are often converted into quantitative estimates of recollection and familiarity based on a widely used but controversial model of recognition memory (Yonelinas 1994). Using this method, some studies have reported that recollection is selectively impaired in patients with hippocampal lesions (Yonelinas et al. 2002), whereas other studies have found impairments in both recollection and familiarity (Manns et al. 2003a). A difficulty with deriving quantitative estimates of recollection and familiarity from

Remember/Know judgments is that the assumptions of the model that is used to derive estimates have generally not been supported by empirical test (e.g., Heathcote 2003, Rotello et al. 2005, Slotnick 2010, Slotnick & Dodson 2005). In particular, Know judgments reflect weaker memory than do Remember judgments, as measured by both confidence and accuracy (e.g., Dunn 2004, Squire et al. 2007). Thus, a supposed impairment in recollection (Remembering) after hippocampal lesions could simply mean that the patients have few strong memories (and that what would have been strong memories are now weak memories), not that recollection is selectively affected. The Remember/Know procedure could be used to study recollection and familiarity effectively if Remember and Know judgments were first equated for confidence and accuracy, but this approach has not been used in patient studies to date.

Analysis of the Receiver Operating Characteristic

Still another method that has been used to estimate recollection and familiarity has been to fit the Yonelinas (1994) dual-process model to receiver operating characteristic (ROC) data. This is the same model that has often been used to estimate recollection and familiarity using the Remember/Know procedure. An ROC is a plot of the hit rate versus the false alarm rate across different decision criteria. Typically, multiple pairs of hit and false alarm rates are obtained by asking subjects to provide confidence ratings for their old/new recognition decisions. A pair of hit and false alarm rates is then computed for each level of confidence, and the paired values are plotted across the confidence levels. The points of an ROC typically trace out a curvilinear path that can be characterized in terms of its symmetry relative to the negative diagonal (**Figure 6**). The dual-process model proposed by Yonelinas (1994) holds that the degree of asymmetry in an ROC directly reflects the degree to which the recollection process is involved in recognition decisions. Accordingly, a symmetrical ROC indicates that

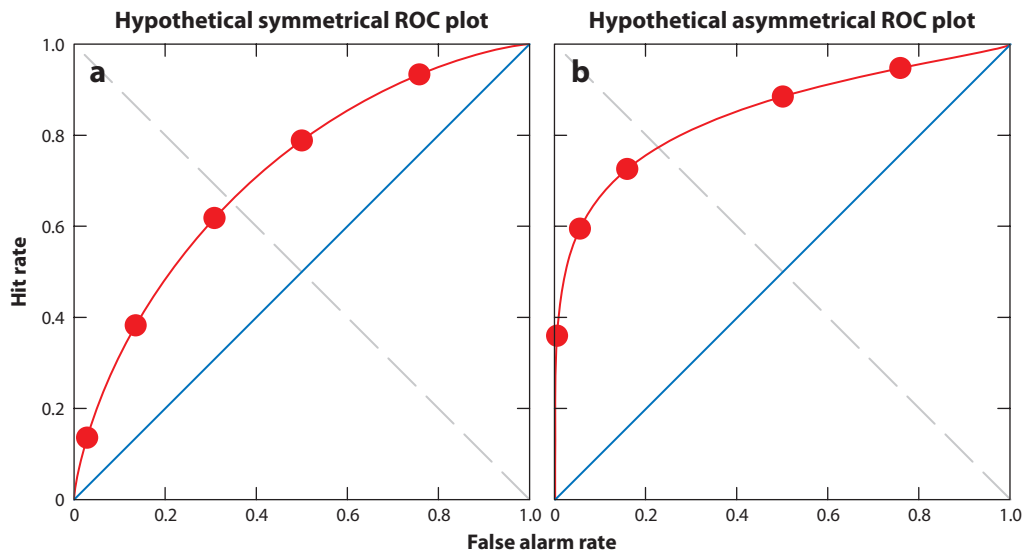


Figure 6

Symmetrical (*a*) and asymmetrical (*b*) receiver operating characteristic (ROC) plots with hypothetical data shown as filled red circles. The axis of symmetry is the negative diagonal (*dashed gray line*), and chance performance is indicated by the positive diagonal (*solid blue line*). The symmetrical ROC (*a*) reflects relatively weak memory (the data fall close to the positive diagonal), and the asymmetrical ROC (*b*) reflects stronger memory (the data fall farther from the positive diagonal).

recognition decisions were based solely on familiarity, and an asymmetrical ROC indicates that recollection occurred for some of the items, as well.

The finding that memory-impaired patients produce symmetrically curvilinear ROCs, whereas controls produce asymmetrical curvilinear ROCs, has been interpreted to mean that the recollection process is selectively impaired by hippocampal lesions (Yonelinas et al. 1998, 2000). However, once again, this is a model-dependent interpretation, and much evidence that has accumulated against this model in recent years instead supports an alternative signal-detection model (e.g., Dunn 2004, 2008; Wixted 2007; Wixted & Mickes 2010). According to the signal-detection model, a symmetrical ROC does not indicate familiarity-based responding but simply reflects weaker memory. Because patients have weaker memory than do controls, the fact that patients tend to exhibit symmetrical ROCs is not surprising.

The question is whether patients can exhibit asymmetrical ROCs (like controls) once

the strength of memory is equated. In one study, patients with lesions limited to the hippocampus were studied under two conditions (weak and strong memory) (Wais et al. 2006). In the weak condition, patients studied 50-item word lists, as did matched controls. As expected, the controls performed better than the patients did. In addition (again as expected), the control ROC was asymmetrical, and the patient ROC was symmetrical. To equate for overall memory strength, patients also studied lists of 10 items, which improved their memory performance to a level similar to that of the controls who had studied 50-item lists. In this condition, the patient ROC and the control ROC were similarly asymmetrical. These results show that patients can exhibit asymmetric ROCs, which have been taken to denote performance based on recollection. The results further suggest that the typical finding of asymmetrical ROCs for controls and symmetrical ROCs for patients does not necessarily indicate a selective deficit in recollection but can reflect a difference in overall memory strength.

Newer (Model-Free) Methods

The effects of hippocampal lesions on recollection and familiarity can also be studied in a way that does not depend on the assumptions of any specific psychological model. If hippocampal lesions selectively impair recollection, and preserve familiarity, then patients with hippocampal lesions should commonly experience strong, familiarity-based recognition that is unaccompanied by recollection. Furthermore, this experience should occur even more frequently in patients than controls because ordinarily when strong, familiarity-based recognition occurs (e.g., seeing a familiar face), details about prior encounters are remembered, as well.

In a formal test of this prediction, five patients with circumscribed hippocampal damage studied 25 words in one of two contexts (source A or source B) (Kirwan et al. 2010). Old/new recognition memory for the words was then tested using a six-point confidence scale (1 = sure new, 6 = sure old). For items endorsed as old, participants were also asked to make a source recollection decision (was the item learned in context A or B?). Old decisions made with high confidence but in the absence of successful source recollection would thus correspond to strong, familiarity-based recognition without recollection. The results were that there was no increased tendency for this experience to occur in patients relative to controls. If anything, the experience was less frequent in the patients. The simplest explanation for this result is that hippocampal damage impairs familiarity as well as recollection.

In summary, a large body of evidence based on the Remember/Know procedure and ROC analysis has been interpreted to mean that the hippocampus subserves recollection and plays no role in familiarity. It is often not appreciated that this interpretation is based on a specific model that equates weak memory with familiarity and strong memory with recollection [the model proposed by Yonelinas (1994)]. However, familiarity can sometimes be strong, and recollection can sometimes be weak (Wixted & Mickes 2010). In studies that do not depend on

this model, the results suggest that hippocampal lesions impair both recollection and familiarity (Kirwan et al. 2010, Wais et al. 2006).

The fact that a memory strength confound can explain why earlier studies have failed to detect impaired familiarity in hippocampal patients should not be taken to mean that “memory strength” is a concept that usefully informs the functional organization of medial temporal lobe structures. Consideration of how these structures contribute differently to memory properly begins with neuroanatomy. Information from neocortex enters the medial temporal lobe at different points (Suzuki & Amaral 1994). Perirhinal cortex receives strong input from unimodal visual areas, and the parahippocampal cortex receives prominent projections from areas important for spatial cognition, including posterior parietal cortex. This anatomical specialization suggests that perirhinal cortex may be especially important for visual memory (regardless whether a task requires recollection), and the parahippocampal cortex may be important for spatial memory. The finding of severe impairment in monkeys in visual associative tasks after perirhinal lesions (Murray et al. 1993) and in spatial tasks after parahippocampal cortex lesions (Malkova & Mishkin 2003) conforms to this suggestion. The hippocampus itself receives input from the adjacent cortex and is thus in a position to combine the operations of memory formation that are carried out by the more specialized structures that project to it. As expected, hippocampal lesions impair both visual memories and spatial memories. The impairment in memory formation is only modestly severe because many memory functions can be carried out by the adjacent cortex [for additional discussion of differences in the function of medial temporal lobe structures, see Squire et al. (2007), Wixted & Squire (2011)].

GROUP STUDIES AND MULTIPLE METHODS

The study of patients with medial temporal lobe lesions (especially the severely impaired patient H.M.) has led to dramatic advances in

understanding the structure and organization of memory. As work progressed, many studies came to focus on smaller lesions and less severe impairments. Furthermore, many of these studies were based on single cases and investigated specific questions about particular aspects of the impairment (for example, recall versus recognition or recollection versus familiarity). Such questions are difficult to settle from individual case studies because the expected effects are relatively small. Under such conditions, a deficit may reflect (unmeasured) premorbid individual differences rather than the effect of a focal brain lesion. Accordingly, for many questions single case studies are more suggestive than conclusive, and group studies are needed to answer experimental questions in a compelling way.

The advantage of group studies is that individual variability tends to be averaged out. However, group studies are useful only to the extent that the lesions can be documented and quantified with MRI. Some group studies have studied patients with assumed lesions, such as patients with modest memory impairments due to hypoxia who are studied on the untested assumption that their lesions are limited to the hippocampus. Given techniques currently available for quantifying the locus and extent of lesions, the use of such techniques in both single-case and group studies should become standard practice.

It is important to emphasize that studies of patients with lesions provide only one of many experimental approaches to investigating the organization of memory. The same issues have been usefully investigated in experimental animals with lesions (e.g., rats and monkeys), in single-unit recording studies of animals and humans, in studies using functional neuroimaging or transcranial magnetic stimulation (TMS), and in studies of genetically modified mice. Each approach has its own advantages and disadvantages, such that one can expect that their combined application will provide the best opportunity for further discovery.

CONCLUSIONS

The early descriptions of H.M. changed how human memory was understood. What became clear as a result of work with H.M.—and what remains clear today—is that the structures of the medial temporal lobe are essential for normal memory function. Specifically, these structures are thought to be important for the formation of memory and for the maintenance of memory for a period of time after learning. Although active lines of research investigate the possibility that these structures also contribute to other domains of cognitive function (e.g., visual perception, working memory, and online computations supporting spatial cognition), the half-century of research that began with H.M. has shown that profound impairment after medial temporal lobe damage occurs in only one domain, specifically, in what is now termed declarative memory.

The elements of long-term memory are stored in the neocortex (not in the medial temporal lobe) as products of the distributed, domain-specific processing that occurred in different regions of neocortex at the time of learning. Thus, long-term memory for whole events is widely represented, but the multiple areas that are involved each store distinct components of information. In addition, acts of remembering involve the reactivation of the same neocortical regions that initially processed and stored what was learned. The role of the medial temporal lobe is to consolidate the distributed elements of memory into a coherent and stable ensemble (a process that can take years). Many questions remain about how consolidation occurs, as well as about memory storage, memory retrieval, and the specific functions of the different medial temporal lobe structures and the different areas of neocortex. These topics encompass what has become a substantial and fruitful tradition of research within systems and cognitive neuroscience—a tradition that began with the study of H.M.

DISCLOSURE STATEMENT

The authors are not aware of any affiliations, memberships, funding, or financial holdings that might be perceived as affecting the objectivity of this review.

ACKNOWLEDGMENTS

This work was supported by the Medical Research Service of the Department of Veterans Affairs, NIMH grant MH24600 to L.R.S., and NIMH grant MH082892 to J.T.W.

LITERATURE CITED

- Aggleton JP, Vann SD, Denby C, Dix S, Mayes AR, et al. 2005. Sparing of the familiarity component of recognition memory in a patient with hippocampal pathology. *Neuropsychologia* 43:810–23
- Atkinson RC, Juola JF. 1974. Search and decision processes in recognition memory. In *Contemporary Developments in Mathematical Psychology*, ed. DH Krantz, RC Atkinson, P Suppes, pp. 243–90. San Francisco: Freeman
- Baddeley A. 2003. Working memory: looking back and looking forward. *Nat. Rev. Neurosci.* 4:829–39
- Barens MD, Gaffan D, Graham KS. 2007. The human medial temporal lobe processes online representations of complex objects. *Neuropsychologia* 45:2963–74
- Barton JJS, Cherkasova M. 2003. Face imagery and its relation to perception and covert recognition in prosopagnosia. *Neurology* 61:220–25
- Bayley PJ, Frascino JC, Squire LR. 2005a. Robust habit learning in the absence of awareness and independent of the medial temporal lobe. *Nature* 436:550–53
- Bayley PJ, Gold JJ, Hopkins RO, Squire LR. 2005b. The neuroanatomy of remote memory. *Neuron* 46:799–810
- Bayley PJ, Hopkins RO, Squire LR. 2003. Successful recollection of remote autobiographical memories by amnesic patients with medial temporal lobe lesions. *Neuron* 37:135–44
- Bayley PJ, Hopkins RO, Squire LR. 2006. The fate of old memories after medial temporal lobe damage. *J. Neurosci.* 26:13311–17
- Bird CM, Burgess N. 2008. The hippocampus and memory: insights from spatial processing. *Nat. Rev. Neurosci.* 9:182–94
- Bird CM, Capponi C, King JA, Doeller CF, Burgess N. 2010. Establishing the boundaries: the hippocampal contribution to imagining scenes. *J. Neurosci.* 30:11688–95
- Bright P, Buckman JR, Fradera A, Yoshimasu H, Colchester ACF, Kopelman MD. 2006. Retrograde amnesia in patients with hippocampal, medial temporal, temporal lobe, or frontal pathology. *Learn. Mem.* 13:545–57
- Broca PP. 1861. Remarks on the seat of the faculty of articulate language, followed by an observation of aphemia. In *Some Papers on the Cerebral Cortex*, transl. G von Bonin, pp. 199–220. Springfield, IL: Thomas
- Brown MW, Aggleton JP. 2001. Recognition memory: What are the roles of the perirhinal cortex and hippocampus? *Nat. Rev. Neurosci.* 2:51–61
- Buchanan TW, Tranel D, Adolphs R. 2005. Emotional autobiographical memories in amnesic patients with medial temporal lobe damage. *J. Neurosci.* 25:3151–60
- Buckner RL, Wheeler ME. 2001. The cognitive neuroscience of remembering. *Nat. Rev. Neurosci.* 2:624–34
- Cave C, Squire LR. 1992. Intact and long-lasting repetition priming in amnesia. *J. Exp. Psychol. Learn. Mem. Cog.* 18:509–20
- Cipolotti L, Bird C, Good T, Macmanus D, Rudge P, Shallice T. 2006. Recollection and familiarity in dense hippocampal amnesia: a case study. *Neuropsychologia* 44:489–506
- Cipolotti L, Shallice T, Chan D, Fox N, Scahill R, et al. 2001. Long-term retrograde amnesia. .the crucial role of the hippocampus. *Neuropsychologia* 2:151–72
- Clark RE, Reinagel P, Broadbent N, Flister E, Squire LR. 2011. Intact performance on feature ambiguous discriminations in rats with lesions of the perirhinal cortex. *Neuron*. In press

- Cohen NJ, Squire LR. 1980. Preserved learning and retention of pattern analyzing skill in amnesia: dissociation of knowing how and knowing that. *Science* 210:207–9
- Corkin S. 2002. What's new with the amnesic patient H.M.? *Nat. Rev. Neurosci.* 3:153–60
- Corkin S, Amaral DG, Gonzalez RG, Johnson KA, Hyman BT. 1997. H.M.'s medial temporal lobe lesion: findings from magnetic resonance imaging. *J. Neurosci.* 17:3964–80
- Cowan N. 2001. The magical number 4 in short-term memory: a reconsideration of mental storage capacity. *Behav. Brain Sci.* 24:87–185
- Damasio AR. 1989. Time-locked multiregional retroactivation: a systems-level proposal for the neural substrates of recall and recognition. *Cognition* 33:25–62
- Danker JF, Anderson JR. 2010. The ghosts of brain states past: remembering reactivates the brain regions engaged during encoding. *Psychol. Bull.* 136:87–102
- De Renzi E. 1982. Memory disorders following focal neocortical damage. *Philos. R. Soc. London [Biol.]* 298:73–83
- Drachman DA, Arbit J. 1966. Memory and the hippocampal complex. II. Is memory a multiple process? *Arch. Neurol.* 15:52–61
- Dunn JC. 2004. Remember-Know: a matter of confidence. *Psychol. Rev.* 111:524–42
- Dunn JC. 2008. The dimensionality of the remember-know task: a state-trace analysis. *Psychol. Rev.* 115:426–46t
- Eacott MJ, Gaffan D, Murray EA. 1994. Preserved recognition memory for small sets, and impaired stimulus identification for large sets, following rhinal cortex ablations in monkeys. *Euro. J. Neurosci.* 6:1466–78
- Eichenbaum H, Yonelinas AR, Ranganath C. 2007. The medial temporal lobe and recognition memory. *Annu. Rev. Neurosci.* 30:123–52
- Eslinger PJ. 1998. Autobiographical memory after temporal lobe lesions. *Neurocase* 4:481–95
- Farah MJ, Levinson KL, Klein KL. 1995a. Face perception and within-category discrimination in prosopagnosia. *Neuropsychologia* 33:661–74
- Farah MJ, Wilson KD, Drain HM, Tanaka J. 1995b. The inverted face inversion effect in prosopagnosia: evidence for mandatory, face-specific perceptual mechanisms. *Vision Res.* 35:2089–93
- Ferrier D. 1876. *The Functions of the Brain*. London: Smith, Elder and Company
- Finger S. 1994. *Origins of Neuroscience: A History of Explorations into Brain Function*. New York: Oxford Univ. Press
- Finke C, Braun M, Ostendorf F, Lehmann TN, Hoffmann KT, et al. 2008. The human hippocampal formation mediates short-term memory of colour-location associations. *Neuropsychologia* 46:614–23
- Frankland PW, Bontempi B. 2005. The organization of recent and remote memories. *Nat. Rev. Neurosci.* 6:119–30
- Fritsch G, Hitzig E. 1870. On the electrical excitability of the cerebrum. In *Some Papers on the Cerebral Cortex*, transl. G von Bonin. pp. 73–86. Springfield, IL: Thomas
- Fukuda K, Edward A, Vogel EK. 2010. Discrete capacity limits in visual working memory. *Curr. Opin. Neurobiol.* 20:177–82
- Gall FJ. 1825. *Sur les Fonctions du Cerveau et sur Celles de Chacune des Ses Parties*, 6 Vol. Paris: Bailliere
- Gold JJ, Squire LR. 2005. Quantifying medial temporal lobe damage in memory-impaired patients. *Hippocampus* 15:79–85
- Gold JJ, Squire LR. 2006. The anatomy of amnesia: neurohistological analysis of three new cases. *Learn. Mem.* 13:699–710
- Graham KS, Scahill VL, Hornberger M, Barense MD, Lee AC, et al. 2006. Abnormal categorization and perceptual learning in patients with hippocampal damage. *J. Neurosci.* 26:7547–54
- Hannula DE, Tranel D, Cohen NJ. 2006. The long and short of it: relational memory impairments in amnesia, even at short lags. *J. Neurosci.* 26:8352–59
- Harding A, Halliday G, Caine D, Kril J. 2000. Degeneration of anterior thalamic nuclei differentiates alcoholics with amnesia. *Brain* 123:141–54
- Hassabis D, Kumaran D, Vann SD, Maguire EA. 2007. Patients with hippocampal amnesia cannot imagine new experiences. *Proc. Natl. Acad. Sci. USA* 104:1726–31
- Heathcote A. 2003. Item recognition memory and the ROC. *J. Exp. Psych. Learn. Mem. Cogn.* 29:1210–30

- Hebb DO. 1949. *The Organization of Behavior*. New York: Wiley
- Higuchi S, Miyashita Y. 1996. Formation of mnemonic neuronal responses to visual paired associates in inferotemporal cortex is impaired by perirhinal and entorhinal lesions. *Proc. Natl. Acad. Sci. USA* 93:739–43
- Hunter WS. 1930. A consideration of Lashley's theory of equipotentiality of cerebral action. *J. Gen. Psych.* 3:444–68
- Insausti R, Insausti AM, Sobreviela M, Salinas A, Martinez-Penuela J. 1998a. Human medial temporal lobe in aging: anatomical basis of memory preservation. *Microsc. Res. Techn.* 43:8–15
- Insausti R, Juottonen K, Soininen H, Insausti AM, Partanen K, et al. 1998b. MR volumetric analysis of the human entorhinal, perirhinal, and temporopolar cortices. *Am. J. Neuroradiol.* 19:659–71
- Isaacs EB, Vargha-Khadem F, Watkins KE, Lucas A, Mishkin M, Gadian DG. 2003. Developmental amnesia and its relationship to degree of hippocampal atrophy. *Proc. Natl. Acad. Sci. USA* 100:13060–63
- Jeneson A, Mauldin KN, Hopkins RO, Squire LR. 2011. The role of the hippocampus in retaining relational information across short delays: the importance of memory load. *Learn. Mem.* In press
- Jeneson A, Mauldin KN, Squire LR. 2010. Intact working memory for relational information after medial temporal lobe damage. *J. Neurosci.* 30:13624–29
- Kan IP, Giovanello KS, Schnyer DM, Makris N, Verfaellie M. 2007. Role of the medial temporal lobes in relational memory: neuropsychological evidence from a cued recognition paradigm. *Neuropsychologia* 45:2589–97
- Kapur N, Brooks DJ. 1999. Temporally-specific retrograde amnesia in two cases of discrete bilateral hippocampal pathology. *Hippocampus* 9:247–54
- Kensinger E, Ullman MT, Corkin S. 2001. Bilateral medial temporal lobe damage does not affect lexical or grammatical processing: evidence from amnesic patient H.M. *Hippocampus* 11:347–60
- Kim S, Jeneson A, van der Horst AS, Frascino JC, Hopkins RO, Squire LR. 2011. Memory, visual discrimination performance, and the human hippocampus. *J. Neurosci.* 31:2624–29
- Kirwan CB, Bayley PJ, Galvan VV, Squire LR. 2008. Detailed recollection of remote autobiographical memory after damage to the medial temporal lobe. *Proc. Natl. Acad. Sci. USA* 105:2676–80
- Kirwan CB, Wixted JT, Squire LR. 2010. A demonstration that the hippocampus supports both recollection and familiarity. *Proc. Natl. Acad. Sci. USA* 107:344–48
- Knowlton BJ, Mangels JA, Squire LR. 1996. A neostriatal habit learning system in humans. *Science* 273:1399–402
- Kopelman MD, Bright P, Buckman J, Fradera A, Yoshimasu H, et al. 2007. Recall and recognition memory in amnesia: patients with hippocampal, medial temporal, temporal lobe or frontal pathology. *Neuropsychologia* 45:1232–46
- Kopelman MD, Wilson BA, Baddeley AD. 1989. The autobiographical memory interview: a new assessment of autobiographical and personal semantic memory in amnesic patients. *J. Clin. Exp. Neuropsych.* 5:724–44
- Lashley KS. 1929. *Brain Mechanisms and Intelligence: A Quantitative Study of Injuries to the Brain*. Chicago: Chicago Univ. Press
- Lee AC, Buckley MJ, Pegman SJ, Spiers H, Scahill VL, et al. 2005a. Specialization in the medial temporal lobe for processing of objects and scenes. *Hippocampus* 15:782–97
- Lee AC, Bussey TJ, Murray EA, Saksida LM, Epstein RA, et al. 2005b. Perceptual deficits in amnesia: challenging the medial temporal lobe 'mnemonic' view. *Neuropsychologia* 43:1–11
- Lee AC, Rudebeck SR. 2010. Human medial temporal lobe damage can disrupt the perception of single objects. *J. Neurosci.* 30:6588–94
- Mair WGP, Warrington EK, Weiskrantz L. 1979. Memory disorder in Korsakoff psychosis. A neuropathological and neuropsychological investigation of two cases. *Brain* 102:749–83
- Malkova L, Mishkin M. 2003. One-trial memory for object-place associations after separate lesions of hippocampus and posterior parahippocampal region in the monkey. *J. Neurosci.* 23:1956–65
- Mandler G. 1980. Recognizing: the judgment of previous occurrence. *Psychol. Rev.* 87:252–71
- Manns JR, Hopkins RO, Reed JM, Kitchener EG, Squire LR. 2003a. Recognition memory and the human hippocampus. *Neuron* 37:171–80
- Manns JR, Hopkins RO, Squire LR. 2003b. Semantic memory and the human hippocampus. *Neuron* 37:127–33

- Marslen-Wilson WD, Teuber HL. 1975. Memory for remote events in anterograde amnesia: recognition of public figures from news photographs. *Neuropsychologia* 13:353–64
- Martin A. 2007. The representation of object concepts in the brain. *Ann. Review. Psychol.* 58:25–45
- Mayes AR, Holdstock JS, Isaac CL, Hunkin NM, Roberts N. 2002. Relative sparing of item recognition memory in a patient with adult-onset damage limited to the hippocampus. *Hippocampus* 12:325–40
- Mayes AR, Meudell PR, Mann D, Pickering A. 1988. Location of lesions in Korsakoff's syndrome: neuropsychological and neuropathological data on two patients. *Cortex* 3:367–88
- Milner B. 1962. Les troubles de la memoire accompagnant des lesions hippocampiques bilaterales. In *Physiologie de l'hippocampe*, pp. 257–72. Paris: Cent. Natl. Rech. Sci.
- Milner B, Corkin S, Teuber HL. 1968. Further analysis of the hippocampal amnesic syndrome: 14 year follow-up study of H.M. *Neuropsychologia* 6:215–34
- Mishkin M. 1978. Memory in monkeys severely impaired by combined but not by separate removal of amygdala and hippocampus. *Nature* 273:297–98
- Mishkin M. 1982. A memory system in the monkey. *Philos. Trans. R. Soc. London Ser. B* 1089:83–95
- Mishkin M, Malamut B, Bachevalier J. 1984. Memories and habits: two neural systems. In *Neurobiology of Learning and Memory*, ed. G Lynch, JL McGaugh, NM Weinberger, pp. 65–77. New York: Guilford
- Miyashita Y. 1993. Inferior temporal cortex: where visual perception meets memory. *Annu. Rev. Neurosci.* 16:245–63
- Murray EA. 1992. Medial temporal lobe structures contributing to recognition memory: the amygdaloid complex versus rhinal cortex. In *The Amygdala: Neurobiological Aspects of Emotion, Memory, and Mental Dysfunction*, ed. JP Aggleton, pp. 453–70. London: Wiley-Liss
- Murray EA, Gaffan D, Mishkin M. 1993. Neural substrates of visual stimulus-stimulus association in rhesus monkeys. *J. Neurosci.* 13:4549–61
- Nouhiane M, Piolino P, Hasboun D, Clemenceau S, Baulac M, Samson S. 2007. Autobiographical memory after temporal lobe resection: neuropsychological and MRI volumetric findings. *Brain* 130:3184–99
- Olson IR, Page K, Moore KS, Chatterjee A, Verfaellie M. 2006. Working memory for conjunctions relies on the medial temporal lobe. *J. Neurosci.* 26:4596–601
- Peretz I, Gagnon L. 1999. Dissociation between recognition and emotional judgments for melodies. *Neurocase* 5:21–30
- Peretz I, Gagnon L, Bouchard B. 1998. Music and emotion: perceptual determinants, immediacy, and isolation after brain damage. *Cognition* 68:111–41
- Polyn SM, Natu VS, Cohen JD, Norman KA. 2005. Category-specific cortical activity precedes retrieval during memory search. *Science* 310:1963–66
- Press GA, Amaral DG, Squire LR. 1989. Hippocampal abnormalities in amnesic patients revealed by high-resolution magnetic resonance imaging. *Nature* 341:54–57
- Rempel-Clower N, Zola SM, Squire LR, Amaral DG. 1996. Three cases of enduring memory impairment following bilateral damage limited to the hippocampal formation. *J. Neurosci.* 16:5233–55
- Restivo L, Vetere G, Bontempi B, Ammassari-Teule M. 2009. The formation of recent and remote memory is associated with time-dependent formation of dendritic spines in the hippocampus and anterior cingulate cortex. *J. Neurosci.* 29:8206–14
- Ribot T. 1881. *Les Maladies de la Memoire* [English translation: Diseases of Memory]. New York: Appleton-Century-Crofts
- Rosenbaum RS, Moscovitch M, Foster JK, Schnyer DM, Gao F, et al. 2008. Patterns of autobiographical memory loss in medial-temporal lobe amnesic patients. *J. Cogn. Neurosci.* 20:1490–506
- Rosenbaum RS, Priselac S, Kohler S, Black SE, Gao F, et al. 2000. Remote spatial memory in an amnesic person with extensive bilateral hippocampal lesions. *Nat. Neurosci.* 3:1044–48
- Rotello CM, Macmillan NA, Reeder JA, Wong M. 2005. The remember response: subject to bias, graded, and not a process-pure indicator of recollection. *Psychon. Bull. Rev.* 12:865–73
- Sacks O. 1995. The case of the colorblind painter. In *An Anthropologist on Mars*, pp. 3–41. New York: Random House
- Sagar HH, Cohen NJ, Corkin S, Growdon JM. 1985. Dissociations among processes in remote memory. In *Memory Dysfunctions*, ed. DS Olton, E Gamzu, S Corkin, pp. 533–35. New York: Ann. NY Acad. Sci.

- Salat DH, van der Kouwe AJW, Tuch DS, Quinn BT, Fischl B, et al. 2006. Neuroimaging H.M.: a 10-year follow-up examination. *Hippocampus* 16:936–45
- Sanders HI, Warrington DK. 1971. Memory for remote events in amnesic patients. *Brain* 94:661–68
- Schnider A, Bassetti C, Schnider A, Gutbrod K, Ozdoba C. 1995. Very severe amnesia with acute onset after isolated hippocampal damage due to systemic lupus erythematosus. *J. Neurol. Neurosurg. Psychiatry* 59:644–46
- Scoville WB, Milner B. 1957. Loss of recent memory after bilateral hippocampal lesions. *J. Neurol. Neurosurg. Psychiatry* 20:11–21
- Shrager Y, Gold JJ, Hopkins RO, Squire LR. 2006. Intact visual perception in memory-impaired patients with medial temporal lobe lesions. *J. Neurosci.* 26:2235–40
- Shrager Y, Levy DA, Hopkins RO, Squire LR. 2008. Working memory and the organization of brain systems. *J. Neurosci.* 28:4818–22
- Slotnick SD. 2010. “Remember” source memory ROCs indicate recollection is a continuous process. *Memory* 18:27–39
- Slotnick SD, Dodson CS. 2005. Support for a continuous (single-process) model of recognition memory and source memory. *Mem. Cogn.* 33:151–70
- Squire LR. 1987. *Memory and Brain*. New York: Oxford Univ. Press
- Squire LR. 2006. Lost forever or temporarily misplaced? The long debate about the nature of memory impairment. *Learn. Mem.* 13:522–29
- Squire LR. 2009. The legacy of patient H.M. for neuroscience. *Neuron* 61:6–9
- Squire LR, Amaral DG, Press GA. 1990. Magnetic resonance imaging of the hippocampal formation and mammillary nuclei distinguish medial temporal lobe and diencephalic amnesia. *J. Neurosci.* 10:3106–17
- Squire LR, Amaral DG, Zola-Morgan S, Kritchevsky M, Press GA. 1989. Description of brain injury in the amnesic patient N.A. based on magnetic resonance imaging. *Exp. Neurol.* 105:23–25
- Squire LR, Bayley PJ. 2007. The neuroscience of remote memory. *Curr. Opin. Neurobiol.* 17:185–96
- Squire LR, van der Horst AS, McDuff SGR, Frascino JC, Hopkins RO, Mauldin KN. 2010. Role of the hippocampus in remembering the past and imagining the future. *Proc. Natl. Acad. Sci. USA* 107:19044–48
- Squire LR, Wixted JT, Clark RE. 2007. Recognition memory and the medial temporal lobe: a new perspective. *Nat. Rev. Neurosci.* 8:872–83
- Squire LR, Zola-Morgan S. 1988. Memory: brain systems and behavior. *Trends Neurosci.* 11:170–75
- Squire LR, Zola-Morgan S. 1991. The medial temporal lobe memory system. *Science* 253:1380–86
- Steinworth S, Levine B, Corkin S. 2005. Medial temporal lobe structures are needed to re-experience remote autobiographical memories: evidence from H.M. and W.R. *Neuropsychologia* 43:479–96
- Suzuki WA. 2009. Perception and the medial temporal lobe: evaluating the current evidence. *Neuron* 61:657–66
- Suzuki WA. 2010. Untangling memory from perception in the medial temporal lobe. *Trends Cogn. Sci.* 1:195–200
- Suzuki WA, Amaral DG. 1994. Topographic organization of the reciprocal connections between the monkey entorhinal cortex and the perirhinal and parahippocampal cortices. *J. Neurosci.* 14:1856–77
- Teng E, Squire LR. 1999. Memory for places learned long ago is intact after hippocampal damage. *Nature* 400:675–77
- Tulving E, Schacter DL. 1990. Priming and human memory systems. *Science* 247:301–6
- Victor M, Adams RD, Collins GH, eds. 1989. *The Wernicke-Korsakoff Syndrome and Related Neurological Disorders due to Alcoholism and Malnutrition*. Philadelphia: F.A. Davis
- Victor M, Agamanolis J. 1990. Amnesia due to lesions confined to the hippocampus: a clinical-pathological study. *J. Cogn. Neurosci.* 2:246–57
- von Cramon DY, Hebel N, Schuri U. 1985. A contribution to the anatomical basis of thalamic amnesia. *Brain* 108:993–1008
- Wais P, Wixted JT, Hopkins RO, Squire LR. 2006. The hippocampus supports both the recollection and the familiarity components of recognition memory. *Neuron* 49:459–68
- Warrington EK, McCarthy RA. 1987. Categories of knowledge. Further fractionations and an attempted integration. *Brain* 110:1273–96
- Warrington EK, Shallice T. 1984. Category specific semantic impairments. *Brain* 107:829–53

- Wheeler ME, Petersen SE, Buckner RL. 2000. Memory's echo: vivid remembering activates sensory-specific cortex. *Proc. Natl. Acad. Sci. USA* 97:11125–29
- Whitlock JR, Sutherland RJ, Witter MP, Moser MB, Moser EI. 2008. Navigating from hippocampus to parietal cortex. *Proc. Natl. Acad. Sci. USA* 105:14755–62
- Winocur G, Moscovitch M, Bontempi JB. 2010. Memory formation and long-term retention in humans and animals: convergence towards a transformation account of hippocampal-neocortical interactions. *Neuropsychologia* 48:2339–56
- Winslow F. 1861. *On Obscure Diseases of the Brain and Disorders of the Mind*. London: John W. Davies
- Wixted JT. 2007. Dual-process theory and signal-detection theory of recognition memory. *Psychol. Rev.* 114:152–76
- Wixted JT, Mickes L. 2010. A continuous dual-process model of remember/know judgments. *Psychol. Rev.* 117:1025–54
- Wixted JT, Squire LR. 2004. Recall and recognition are equally impaired in patients with selective hippocampal damage. *Cogn. Aff. Behav. Neurosci.* 4:58–66
- Wixted JT, Squire LR. 2010. The role of the human hippocampus in familiarity-based recognition memory. *Behav. Brain Res.* 215:197–208
- Wixted JT, Squire LR. 2011. The medial temporal lobe and the attributes of memory. *Trends Cogn. Sci.* In press
- Woodruff CC, Johnson JD, Uncapher MR, Rugg MD. 2005. Content-specificity of the neural correlates of recollection. *Neuropsychologia* 43:1022–32
- Yonelinas AP. 1994. Receiver-operating characteristics in recognition memory: evidence for a dual-process model. *J. Exp. Psychol. Learn. Mem. Cogn.* 20:1341–54
- Yonelinas AP, Kroll NEA, Dobbins IG, Lazzara MM, Knight RT. 1998. Recollection and familiarity deficits in amnesia: convergence of remember/know, process dissociation, and receiver operating characteristic data. *Neuropsychology* 12:1–17
- Yonelinas AP, Kroll NEA, Quamme JR, Lazzara MM, Sauve MJ, et al. 2002. Effects of extensive temporal lobe damage or mild hypoxia on recollection and familiarity. *Nat. Neurosci.* 5:1236–41
- Zola-Morgan S, Squire LR, Amaral DG. 1986. Human amnesia and the medial temporal region: enduring memory impairment following a bilateral lesion limited to field CA1 of the hippocampus. *J. Neurosci.* 6:2950–67
- Zola-Morgan S, Squire LR, Ramus SJ. 1994. Severity of memory impairment in monkeys as a function of locus and extent of damage within the medial temporal lobe memory system. *Hippocampus* 4:483–95