

The Cracked Tooth Syndrome

• Christopher D. Lynch, BDS, MFDRCSI •
• Robert J. McConnell, BDS, PhD, FFDRCSI •

A b s t r a c t

The purpose of this article is to review the clinical features, diagnosis and management of the cracked tooth syndrome (CTS). The condition refers to an incomplete fracture of a vital posterior tooth that occasionally extends into the pulp. A lack of awareness of the condition coupled with its varied clinical features can make diagnosis of CTS difficult. Common symptoms include an uncomfortable sensation or pain from a tooth that occurs while chewing hard foods and which ceases when the pressure is withdrawn. The patient is often unable to identify the offending tooth or quadrant involved, and may report a history of numerous dental procedures with unsatisfactory results. Successful diagnosis and management requires an awareness of the existence of CTS and the appropriate diagnostic tests. Management options depend on the nature of the symptoms and extent of the lesion. These options include routine monitoring, occlusal adjustments, placement of a cast restoration and endodontic treatment. A decision flowchart indicating the treatment options available to the dental practitioner is presented.

MeSH Key Words: cracked tooth syndrome/diagnosis; cracked tooth syndrome/therapy; dental restoration, permanent

© J Can Dent Assoc 2002; 68(8):470-5
This article has been peer reviewed.

The term cracked tooth syndrome (CTS) refers to an incomplete fracture of a vital posterior tooth that involves the dentine and occasionally extends into the pulp.¹⁻³ The term was first introduced by Cameron¹ in 1964, who noted a correlation between restoration size and the occurrence of CTS. Mention is made in the earlier literature of pulpal pain resulting from incomplete tooth fractures,^{4,5} and also of “greenstick fractures” of the crown.⁶ A more recent attempt to define the nature of this condition describes it as “a fracture plane of unknown depth and direction passing through tooth structure that, if not already involving, may progress to communicate with the pulp and/or periodontal ligament.”⁷

The condition presents mainly in patients aged between 30 years and 50 years.⁸⁻¹⁰ Men and women are equally affected.¹¹ Mandibular second molars, followed by mandibular first molars and maxillary premolars, are the most commonly affected teeth.^{2,12} While the crack tends to have a mesiodistal orientation in most teeth, it may run buccolingually in mandibular molars.¹¹

Two classic patterns of crack formation exist.¹ The first occurs when the crack is centrally located, and following the dentinal tubules may extend to the pulp; the second is where the crack is more peripherally directed and may

result in cuspal fracture. Pressure applied to the crown of a cracked tooth leads to separation of the tooth components along the line of the crack. Such separation in dentine results in the movement of fluid in the dentinal tubules, stimulating odontoblasts in the pulp as well as the stretching and rupturing odontoblastic processes lying in the tubules,³ thus stimulating pulpal nociceptors. Ingress of saliva along the crack line may further increase the sensitivity of dentine.¹³ Direct stimulation of pulpal tissues occurs if the crack extends into the pulp.

Symptoms and Diagnosis

Successful diagnosis of CTS requires awareness of its existence and of the appropriate diagnostic tests. The history elicited from the patient can give certain distinct clues. Pain on biting that ceases after the pressure has been withdrawn is a classical sign.^{1,3} Incidences usually occur while eating, or where objects such as a pencil or a pipe are placed between the teeth.³ The patient may have difficulty in identifying the affected tooth⁴ (there are no proprioceptive fibres in the pulp chamber). Vitality testing usually gives a positive response,^{1,2} and the tooth is not normally tender to percussion in an axial direction.⁴ Significantly, symptoms can be elicited when pressure is applied to an individual cusp.^{3,4,14} This is the



Figure 1a: The Tooth Slooth. The concave surface of the head is placed against the suspect cusp.

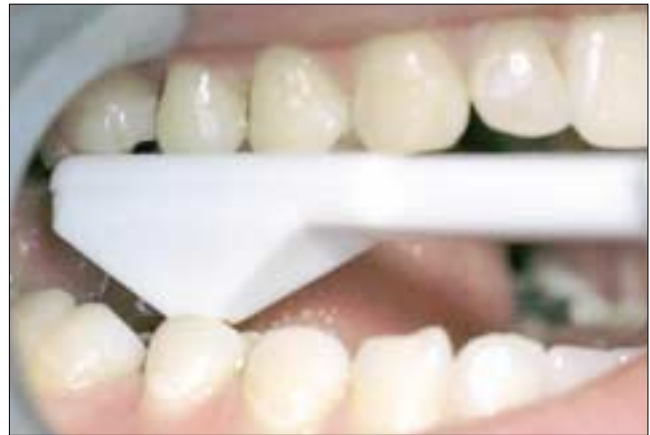

Figure 1b: Using the Tooth Slooth to identify damaged cusps.

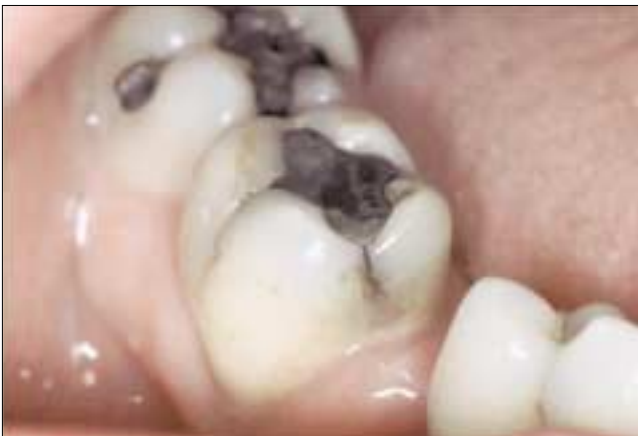

Figure 2: Stained crack lines on the mesial and buccal surfaces of a mandibular molar. If this tooth is asymptomatic, no treatment is required and the tooth should be monitored closely.

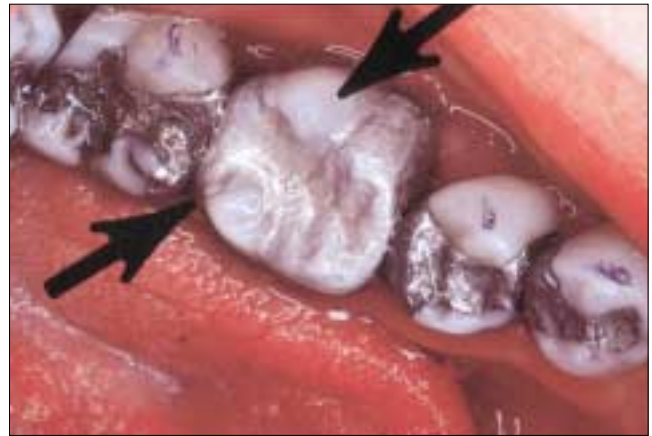

Figure 3: An extensively restored mandibular left first molar. The tooth has been weakened by the placement of an extensive intracoronal restoration. The arrows indicate the areas most prone to future crack formation.

principle of the so-called “bite tests” where the patient is instructed to bite on various items such as a toothpick, cotton roll, burlew wheel, wooden stick,^{2,13,14} or the commercially available Tooth Slooth (Professional Results, Inc., Laguna Niguel, Calif.) (Fig. 1a).² Pain increases as the occlusal force increases, and relief occurs once the pressure is withdrawn (though some patients may complain of symptoms after the force on the tooth has been released).^{2,3,11} The results of these “bite tests” are conclusive in forming a diagnosis (Fig. 1b).

The tooth often has an extensive intracoronal restoration.^{6,13,15} There may be a history of courses of extensive dental treatment, involving repeated occlusal adjustments¹ or replacement of restorations, which fail to eliminate the symptoms. The pain may sometimes occur following certain dental treatments, such as the cementation of an inlay, which may be erroneously diagnosed as interferences or “high spots” on the new restoration.^{1,16} Recurrent debonding of cemented intracoronal restorations such as

inlays may indicate the presence of underlying cracks.¹ Heavily restored teeth may also be tested by application of a sharp probe to the margins of the restoration. Pain evoked in this manner can indicate the presence of a crack in the underlying tooth,¹ which may be revealed upon removal of the restoration.¹⁷

Patients with a previous incidence of CTS can frequently self-diagnose their condition. Diagnosis should exclude pulpal, periodontal or periapical causes of pain.⁴ Galvanic pain associated with recent placement of amalgam restorations should also be considered in this differential diagnosis.³ Such pain occurs on closing the teeth together but decreases as full contact is made, unlike CTS where the pain increases as the teeth close further together, due to increasing occlusal force.³ The medical history should also be considered to exclude incidences of orofacial pain or psychiatric disorders.¹¹

Visual inspection of the tooth is useful, but cracks are not often visible without the aid of magnifying loupes, specialized

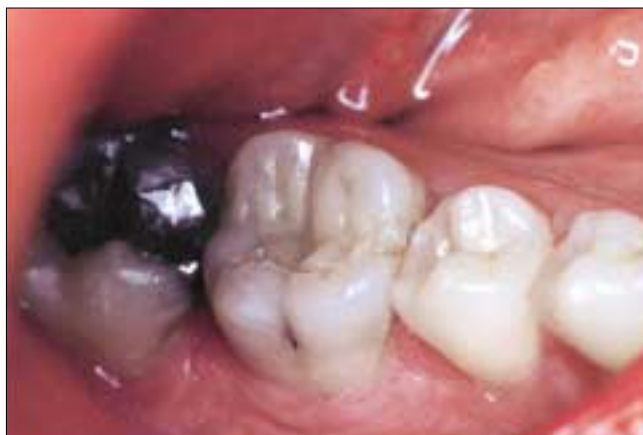

Figure 4: Fracture of a mandibular right first molar. This tooth was weakened by the placement of an extensive intracoronal restoration.

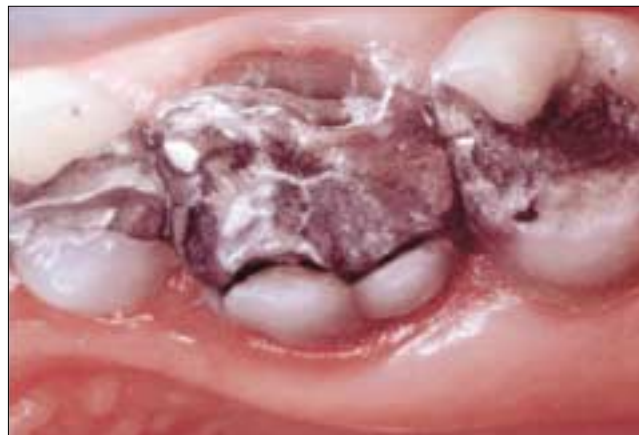


Figure 5: Fracture of the buccal and lingual walls of a maxillary left first molar restored with an extensive mesio-occlusal distal restoration.

Table 1 The etiology of cracked tooth syndrome

Classification	Factors	Examples
Restorative procedures	Inadequate design features	Over-preparation of cavities Insufficient cuspal protection in inlay/onlay design Deep cusp–fossa relationship
	Stress concentration	Pin placement Hydraulic pressure during seating of tightly fitting cast restorations Physical forces during placement of restoration, e.g., amalgam or soft gold inlays (historical) Non-incremental placement of composite restorations (tensile stress on cavity walls) Torque on abutments of long-span bridges
Occlusal	Masticatory accident	Sudden and excessive biting force on a piece of bone
	Damaging horizontal forces	Eccentric contacts and interferences (especially mandibular second molars)
	Functional forces	Large untreated carious lesions Cyclic forces
	Parafunction	Bruxism
Developmental	Incomplete fusion of areas of calcification	Occurrence of cracked tooth syndrome in unrestored teeth
Miscellaneous	Thermal cycling	Enamel cracks
	Foreign body	Lingual barbell
	Dental instruments	Cracking and crazing associated with high-speed handpieces

techniques such as transillumination^{11,14,16} or staining with dyes such as methylene blue.^{3,16,17} Particular attention should be paid to mesial and distal marginal ridges.^{14,17} Cracks are sometimes stained by caries or food and are visible to the unaided eye. Not all stained and visible crack lines lead to the development of CTS (**Fig. 2**). Other clues evident on examination include the presence of facets on the occlusal surfaces of teeth¹⁴ (identifies teeth involved in eccentric contact and at risk from damaging lateral forces), the presence of localized periodontal defects^{3,11} (found where cracks extend subgingivally), or the evocation of symptoms by sweet or thermal stimuli.^{2,3,14} Radiographic examination is usually inconclusive as cracks tend to run in a mesiodistal direction.^{2,4,11}

Etiology of CTS

Historically, CTS was associated with the placement of “soft gold” inlays (Class I Gold) that were physically adapted to the cavity using a mallet.⁵ Nowadays, common causes include masticatory accidents, such as biting on a hard, rigid object with unusually high force,^{3,4} or excessive removal of tooth structure during cavity preparation.¹⁴ Parafunctional habits such as bruxism are also associated with the development of this condition.^{1,14}

Commonly, the tooth has been structurally compromised by removal of tooth substance during restorative procedures¹⁴ (**Fig. 3**). Occlusal contact occurring on extensive occlusal or proximo-occlusal intracoronal restorations

(either cast metal or plastic restorations) subject the remaining weakened tooth structure to lateral masticatory forces, particularly during chewing^{3,4,11} (Figs. 4 and 5). Such cyclic forces result in the establishment and propagation of cracks.^{3,11,17} Deep cusp–fossa relationships due to over-carving of restorations,^{8,18,19} or cast restorations placed without proper consideration for cuspal protection,^{3,11,20} also render the tooth vulnerable. Cameron describes a case where he fitted a gold inlay on a molar tooth that subsequently developed symptoms of CTS. The patient complained of pain on application of pressure to the tooth. Having repeatedly performed occlusal adjustments over a one year period, complete relief of symptoms did not occur until a distal cusp fractured off the tooth.¹

Excessive condensation pressures, expansion of certain poorer quality amalgam alloys when contaminated with moisture, placement of retentive pins,³ and extensive composite restorations placed without due care for incremental technique³ (resulting in tensile forces in the tooth structure due to polymerization contraction) predispose to fracture formation. Other iatrogenic causes of CTS include

excessive hydraulic pressure in luting agents when cementing crowns¹¹ or bridge retainers.¹⁸ Long-span bridges exert excessive torque on the abutment teeth, leading to crack generation.³

The higher incidence of CTS in mandibular second molars may be associated with their proximity to the temporo-mandibular joint,^{1,2,8} based on the principle of the “lever” effect — the mechanical force on an object is increased at closer distances to the fulcrum.⁸ Eccentric contacts expose these teeth to significant occlusal trauma in this manner.²¹ Functional forces on teeth that have untreated carious lesions can also lead to crack formation.³

CTS has been reported in pristine (unrestored) teeth,^{3,13,14} or in those with minor restorations, which has led to the suggestion that there may be developmental weaknesses (arising within coalescence of the zones of calcification) within those teeth.⁸ This contrasts with the findings of Cameron, who claimed that the teeth involved were usually quite heavily restored.¹ Thermal cycling⁷ and damaging horizontal forces or parafunctional habits have also been implicated in the development of enamel cracks

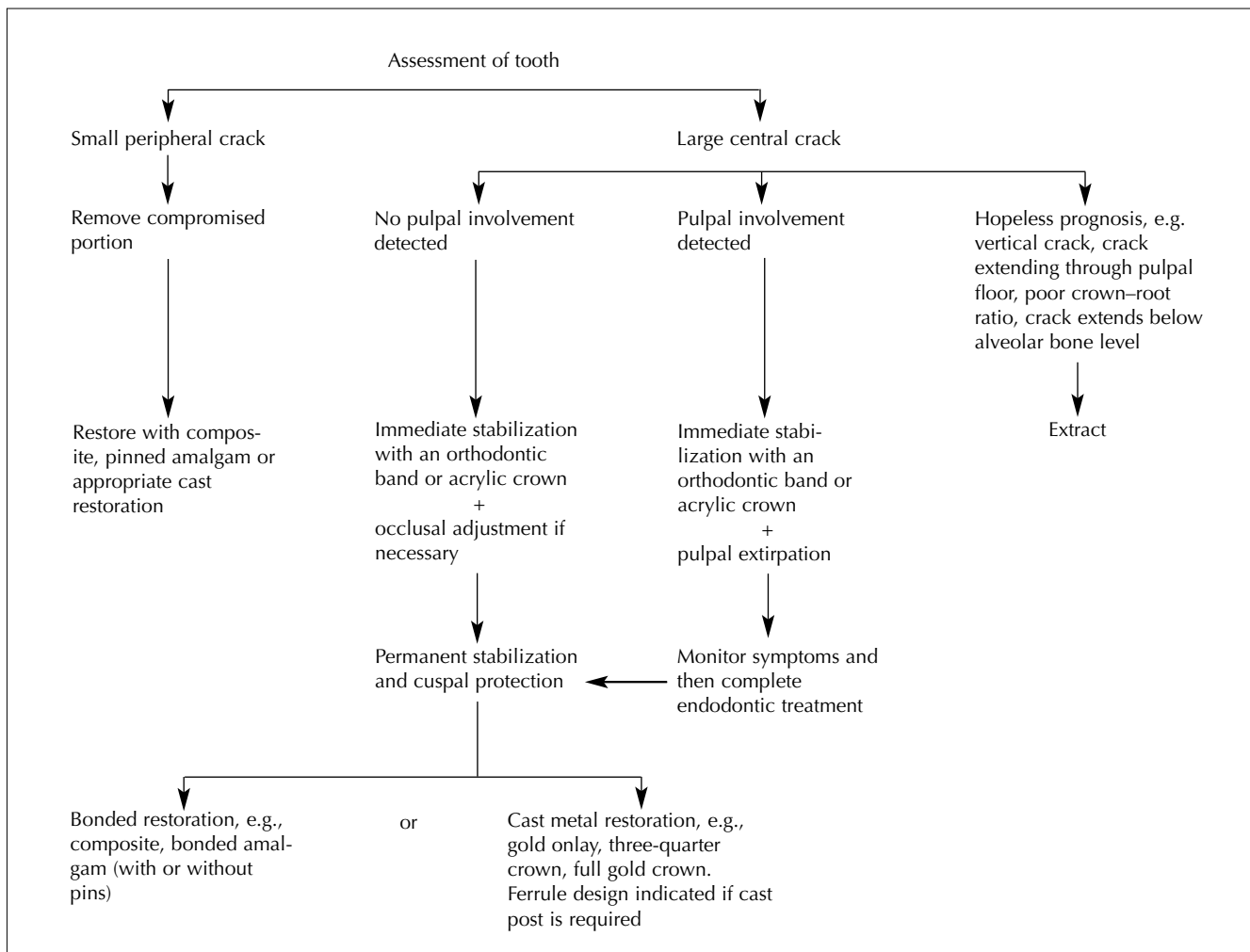


Figure 6: Treatment of cracked tooth syndrome

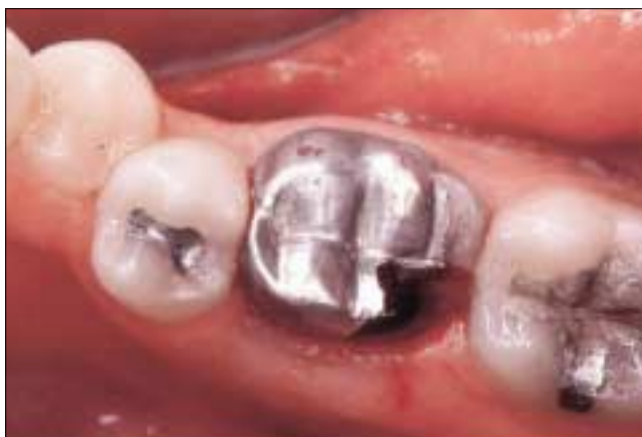

Figure 7: Fracture of the disto-lingual cusp of an extensively restored mandibular right first molar.

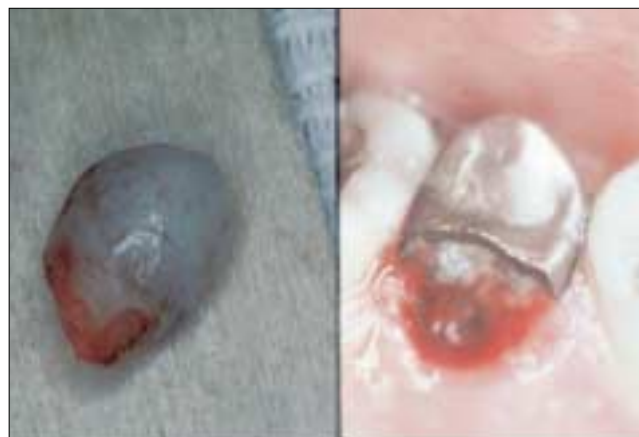

Figure 8: Fracture of the palatal cusp of an extensively restored maxillary right second premolar. The fractures in **Figs. 4, 5, 7 and 8** could have been prevented by incorporating appropriate cuspal reinforcement in each restoration.

in such unrestored teeth, with subsequent involvement of the underlying tooth.^{2,14} There are reports in the recent literature of the generation of such cracks associated with lingual barbells.²² A classification of the etiological factors of CTS is presented in **Table 1**.

Treatment of CTS

A decision flowchart of treatment options is presented in **Fig. 6**. Immediate treatment of the tooth depends on the size of the involved portion of the tooth. If the tooth portion is relatively small and avoids the pulp (Cameron's "peripherally located crack"), it may be fractured off and the tooth restored in the normal way^{2,14} (**Figs. 7 and 8**). If, however, the portion is very large or involves the pulp (Cameron's "centrally located crack"), the tooth should be stabilized immediately with an orthodontic stainless steel band.^{2,11} Stabilization, along with occlusal adjustment,¹⁴ can lead to immediate relief of symptoms. Care should be taken to prevent microleakage along the crack line, as this could result in pulpal necrosis.^{2,8,11} A high success rate has been reported when full-coverage acrylic provisional crowns were used to stabilize the compromised tooth.²³ The tooth should be examined after 2 to 4 weeks and if symptoms of irreversible pulpitis are evident, endodontic treatment should be performed.²

Ultimately the tooth needs to be restored with protection and permanent stabilization in mind.¹⁴ This can be achieved with an adhesive intracoronal restoration^{18,19} (e.g., bonded amalgam, adhesive composite restorations) or a cast extracoronal restoration^{1,2,4} (e.g., full-coverage crown, onlay or three-quarter crown with adequate cuspal protection) to bind the remaining tooth components together. While there has been a lot of interest in the benefits of such adhesive restorations, there is, as yet, little clinical evidence in the literature to support their use. As for extracoronal restorations, certain modifications of tooth preparation

have been suggested for cracked teeth, such as including additional bracing features in the area of the crack, i.e., extending the preparation in a more apical direction, beveling the cusps of the fractured segment more than usual to minimize damaging forces, using bases to prevent contact with the internal surface of the casting, and using boxes and grooves on the unfractured portion.²⁴ Cracks extending subgingivally often require a gingivectomy to expose the margin;³ however, an unfavourable crown-root ratio may render the tooth unrestorable.

Where vertical cracks occur or where the crack extends through the pulpal floor or below the level of the alveolar bone, the prognosis is hopeless and the tooth should be extracted.¹¹

It is worth remembering that it is possible for a crack to progress after placement of an extracoronal metal restoration or crown, when occlusal forces are particularly strong.

Prevention

Awareness of the existence and etiology of CTS is an essential component of its prevention.¹ Cavities should be prepared as conservatively as possible.⁹ Rounded internal line angles should be preferred to sharp line angles to avoid stress concentration. Adequate cuspal protection should be incorporated in the design of cast restorations.^{2,3,11} Cast restorations should fit passively to prevent generation of excess hydraulic pressure during placement.³ Pins should be placed in sound dentine, at an appropriate distance from the enamel to avoid unnecessary stress concentration.^{3,19} The prophylactic removal of eccentric contacts has been suggested for patients with a history of CTS to reduce the risk of crack formation, though there is little clinical evidence to support this practice.^{3,25}

Conclusion

Every practitioner should be aware of the existence of CTS, and the condition must always be considered when a patient complains of pain or discomfort on chewing or biting. A good history will provide vital assistance in the search for a diagnosis. Careful clinical examination and inspection, supplemented by specialized tests such as the non-axial application of pressure to cusps, will be conclusive. Treatment of CTS will depend on the position and extent of the crack. Management options vary according to clinical need, from replacement of the fractured cusp with a simple restoration to placement of an extracoronal restoration with adequate cuspal protection. Armed with the necessary awareness and conscientiousness, the dental practitioner should have no significant difficulty diagnosing and managing the CTS. ♦

Acknowledgments: We would like to acknowledge Dr. Don Gratton, chair, division of prosthodontics, faculty of medicine and dentistry, University of Western Ontario, for figures 3, 5, 7 and 8.

Dr. Lynch is registrar in restorative dentistry, department of restorative dentistry, National University of Ireland, Cork, Ireland.

Dr. McConnell is a professor of restorative dentistry, department of restorative dentistry, National University of Ireland, Cork, Ireland.

Correspondence to: Dr. Christopher D. Lynch, Department of Restorative Dentistry, University Dental School & Hospital, Wilton, Cork, Ireland. E-mail: clynch85@hotmail.com.

The authors have no declared financial interests in any company manufacturing the types of products mentioned in this article.

References

1. Cameron CE. Cracked-tooth syndrome. *J Am Dent Assoc* 1964; 68(March):405-11.
2. Ehrmann EH, Tyas MT. Cracked tooth syndrome: diagnosis, treatment and correlation between symptoms and post-extraction findings. *Aust Dent J* 1990; 35(2):105-12.
3. Rosen H. Cracked tooth syndrome. *J Prosthet Dent* 1982; 47(1):36-43.
4. Gibbs JW. Cuspal fracture odontalgia. *Dent Dig* 1954; 60(April):158-60.
5. Ritchey B, Mendenhall R, Orban B. Pulpitis resulting from incomplete tooth fracture. *Oral Med Oral Surg Oral Pathol* 1957; 10(June):665-70.
6. Sutton PRN. Greenstick fractures of the tooth crown. *Br Dent J* 1962; 112(May 1):362-3.
7. Ellis SG. Incomplete tooth fracture — proposal for a new definition. *Br Dent J* 2001; 190(8):424-8.
8. Hiatt WH. Incomplete crown-root fracture in pulpal-periodontal disease. *J Periodontol* 1973; 44(6):369-79.
9. Snyder DE. The cracked-tooth syndrome and fractured posterior cusp. *Oral Surg Oral Med Oral Pathol* 1976; 41(6):698-704.
10. Ellis SG, Macfarlane TV, McCord JF. Influence of patient age on the nature of tooth fracture. *J Prosthet Dent* 1999; 82(2):226-30.
11. Türp JC, Gobetti JP. The cracked tooth syndrome: an elusive diagnosis. *J Am Dent Assoc* 1996; 127(10):1502-7.
12. Braly RV, Maxwell EH. Potential for tooth fracture in restorative dentistry. *J Prosthet Dent* 1981; 45(4):411-4.
13. Stanley HR. The cracked tooth syndrome. *J Am Acad Gold Foil Oper* 1968; 11(2):36-47.
14. Bales DJ. Pain and the cracked tooth. *J Indiana Dent Assoc* 1975; 54(5):15-8.
15. Goose DH. Cracked tooth syndrome. *Br Dent J* 1981; 150(8):224-5.
16. Cameron CE. The cracked tooth syndrome: additional findings. *J Am Dent Assoc* 1976; 93(5):971-5.
17. Abou-Rass M. Crack lines: the precursors of tooth fractures — their diagnosis and treatment. *Quintessence Int* 1983; 14(4):437-47.
18. Trushkowsky R. Restoration of a cracked tooth with a bonded amalgam. *Quintessence Int* 1991; 22(5):397-400.
19. Bearn DR, Saunders EM, Saunders WP. The bonded amalgam restoration — a review of the literature and report of its use in the treatment of four cases of cracked-tooth syndrome. *Quintessence Int* 1994; 25(5):321-6.
20. Talim ST, Gohil KS. Management of coronal fractures of permanent posterior teeth. *J Prosthet Dent* 1974; 31(2):172-8.
21. Swepston JH, Miller AW. The incompletely fractured tooth. *J Prosthet Dent* 1986; 55(4):413-6.
22. DiAngelis AJ. The lingual barbell: a new etiology for the cracked-tooth syndrome. *J Am Dent Assoc* 1997; 128(10):1438-9.
23. Guthrie RG, DiFiore PM. Treating the cracked tooth with a full crown. *J Am Dent Assoc* 1991; 122(10):71-3.
24. Casciari BJ. Altered preparation design for cracked teeth. *J Am Dent Assoc* 1999; 130(4):571-2.
25. Agar JR, Weller RN. Occlusal adjustment for initial treatment and prevention of the cracked tooth syndrome. *J Prosthet Dent* 1988; 60(2):145-7.