

The Diagnosis and Medical Management of Advanced Neuroendocrine Tumors

GREGORY A. KALTSAS, G. MICHAEL BESSER, AND ASHLEY B. GROSSMAN

Department of Endocrinology, St. Bartholomew's Hospital, London EC1A 7BE, United Kingdom

Neuroendocrine tumors (NETs) constitute a heterogeneous group of neoplasms that originate from endocrine glands such as the pituitary, the parathyroids, and the (neuroendocrine) adrenal, as well as endocrine islets within glandular tissue (thyroid or pancreatic) and cells dispersed between exocrine cells, such as endocrine cells of the digestive (gastroenteropancreatic) and respiratory tracts. Conventionally, NETs may present with a wide variety of functional or nonfunctional endocrine syndromes and may be familial and have other associated tumors. Assessment of specific or general tumor markers offers high sensitivity in establishing the diagnosis and can also have prognostic significance. Imaging modalities include endoscopic ultrasonography, computed tomography and magnetic resonance imaging, and particularly, scintig-

raphy with somatostatin analogs and metaiodobenzylguanidine. Successful treatment of disseminated NETs requires a multimodal approach; radical tumor surgery may be curative but is rarely possible. Well-differentiated and slow-growing gastroenteropancreatic tumors should be treated with somatostatin analogs or α -interferon, with chemotherapy being reserved for poorly differentiated and progressive tumors. Therapy with radionuclides may be used for tumors exhibiting uptake to a diagnostic scan, either after surgery to eradicate microscopic residual disease or later if conventional treatment or biotherapy fails. Maintenance of the quality of life should be a priority, particularly because patients with disseminated disease may experience prolonged survival. (*Endocrine Reviews* 25: 458–511, 2004)

- I. Introduction
- II. Histopathological Classification and Variables Used to Predict Biological Behavior
- III. Tumor Biology
 - A. Genetic defects
 - B. Apoptosis
 - C. Growth factors
- IV. Tumor Markers in Neuroendocrine Tumors
 - A. Serum and immunohistochemical tumor markers
 - B. Amine and peptide receptor expression and visualization
 - C. Radionuclide imaging

Abbreviations: ADH, Antidiuretic hormone secretion; ASVS, arterial stimulation venous sampling; CAG, chronic atrophic gastritis; CCK, cholecystokinin; CEA, carcinoembryonic antigen; CgA, chromogranin A; CGRP, calcitonin gene-related peptide; CHD, carcinoid heart disease; CS, carcinoid syndrome; CT, computed tomography; CVD, cyclophosphamide, vincristine, and dacarbazine; DOTA, 1,4,7,10-tetraazacyclododecane-1,4,7,10-tetraacetic acid; DTPA, diethylene-triamine-penta acetic acid; ECL, enterochromaffin; EUS, endoscopic ultrasound; FDG, ^{18}F -labeled deoxyglucose; FMTC, familial MTC; 5-FU, 5-fluorouracil; GC, gastric carcinoid(s); GEP, gastroenteropancreatic; GI, gastrointestinal; GRP, gastrin-releasing peptide; hCG, human chorionic gonadotropin; 5-HIAA, 5-hydroxyindoleacetic acid; 5-HT, 5-hydroxytryptamine; 5-HTP, 5-hydroxytryptophan; INF, interferon; IOUS, intraoperative ultrasound; MEN, multiple endocrine neoplasia; MIBG, metaiodobenzylguanidine; MRI, magnetic resonance imaging; MTC, medullary thyroid carcinoma; NE, neuroendocrine; NET, NE tumor; NF, neurofibromatosis; NIPH, noninsulinoma pancreatogenous hypoglycemia; NME, necrolytic migratory erythema; NSE, neuron-specific enolase; PET, positron emission tomography; PP, pancreatic polypeptide; SCLC, small-cell lung carcinoma; SDH, succinate dehydrogenase; SPECT, single-photon emission CT; SS, somatostatin; STZ, streptozotocin; VEGF, vascular endothelial growth factor; VHL, von Hippel-Lindau; VIP, vasointestinal peptide; ZES, Zollinger-Ellison syndrome.

Endocrine Reviews is published bimonthly by The Endocrine Society (<http://www.endo-society.org>), the foremost professional society serving the endocrine community.

- V. Natural History of Neuroendocrine Tumors
- VI. Clinical Presentation, Biochemical Confirmation, and Imaging of NETs
 - A. Carcinoid tumors
 - B. Islet cell tumors
 - C. Chromaffin cell tumors (pheochromocytomas and paragangliomas)
 - D. Medullary thyroid carcinoma
- VII. Medical Management of Advanced Neuroendocrine Tumors
 - A. Pretreatment considerations
 - B. Symptomatic treatment of GEP tumors
 - C. Systemic treatment of GEP tumors
 - D. Multidisciplinary approach—quality of life
 - E. Symptomatic and systemic treatment of benign and malignant chromaffin cell tumors (pheochromocytoma and paraganglioma)
 - F. Treatment of medullary thyroid carcinoma
- VIII. Summary and Final Conclusions

I. Introduction

ENDOCRINE TUMORS CONSTITUTE a heterogeneous group of neoplasms that have been postulated to originate from a common precursor cell population (1). The system includes endocrine glands, such as the pituitary, the parathyroids, and the [neuroendocrine (NE)] adrenal, as well as endocrine islets within glandular tissue (thyroid or pancreatic) and cells dispersed between exocrine cells, such as endocrine cells of the digestive and respiratory tracts, the diffuse endocrine system (2–4). Because these cells share a number of antigens with nerve elements, the term “neuroendocrine” is also used to connote such cell types and will be adopted in this review (4). Traditionally, this classification

has tended to exclude pituitary and parathyroid tissue, and these will not be further discussed in this review. NE tumors (NETs) originating from the gastrointestinal (GI) tract, along with similar tumors originating from the lungs and thymus, have traditionally been defined as “carcinoid tumors”; this term will still be used in this review because most of the literature regarding the diagnosis, management, and prognosis of these tumors uses the previously established classification (5). Some NETs may occasionally show very aggressive behavior and become highly malignant (poorly differentiated NETs), but the great majority tend to be relatively slow growing (well-differentiated NETs) and retain many multipotent differentiation capacities (3). Such features include the ability to produce and secrete a variety of metabolically active substances (amines and peptides) and cause distinct clinical syndromes (6). In addition, NETs possess neuroamine uptake mechanisms and/or specific receptors at the cell membrane, such as somatostatin (SS) receptors, which can be of great value in identifying and localizing these tumors as well as being useful in their therapy (7). NETs may occur either sporadically or as part of familial syndromes; the latter are associated with particular genetic defects, a number of which have recently been delineated at the molecular level (8).

This review will focus on the gastroenteropancreatic (GEP) NETs, NETs originating from chromaffin cells, and NETs originating from C (parafollicular) cells of the thyroid. The particular features of NETs that have recently been incorporated into their classification will be covered in an attempt to combine accurate diagnosis with biological behavior and prognosis. Recent developments involving the pathogenesis, earlier diagnosis, and screening for NETs, particularly in familial forms, will also be discussed. Classical symptoms of specific syndromes related to humoral secretion or other clinical presentation of such tumors and recent advances in their biochemical confirmation and localization methods will be presented, and a diagnostic algorithm will be formulated. Finally, evidence-based current medical therapeutic approaches aiming at humoral control and prevention of further tumor growth will be reviewed, and a possible therapeutic algorithm for each of these tumors will be proposed.

II. Histopathological Classification and Variables Used to Predict Biological Behavior

The major function of NE cells is to elaborate, store, and secrete small peptides and biogenic amines (6, 9). Their histopathological examination aims at classifying the tumors according to their tissue origin, biochemical behavior, and prognosis (10). The assessment of endocrine differentiation in tumors has traditionally been obtained using light microscopy, silver impregnation methods (histochemistry), and electron microscopy (1, 4). Currently, the diagnosis of NETs mainly relies on the positive assessment of markers of NE differentiation by immunohistochemistry (3, 4, 11). The most commonly used markers are general NE markers (applicable to all NE cells), either in the cytosol such as neuron-specific enolase (NSE) and the protein gene product 9.5 (12, 13) or granular markers such as chromogranin A (CgA) and syn-

aptophysin (2, 4, 14). The cell-specific characterization of NETs requires hormone immunohistochemistry (4, 11). NETs associated with hyperfunctional syndromes are defined as functioning, whereas NETs exhibiting immunopositivity for endocrine markers and/or elevated serum markers but unassociated with a distinct clinical syndrome are called nonfunctioning tumors (3). Histological and hormonal features of specific cell types are integrated in a so-called “morphofunctional” classification, in an attempt to predict the natural history of the tumor (2, 3, 15). In the recent World Health Organization (WHO) classification, the following types of NETs have been recognized, at least for GEP tumors, but this is probably applicable to all NETs (1, 3, 4, 15–17): 1) well-differentiated endocrine tumor (benign or low grade malignant); 2) well-differentiated endocrine carcinoma; 3) poorly differentiated endocrine carcinoma (small cell carcinoma); and 4) mixed exocrine-endocrine carcinoma.

The differentiation is based on histomorphology, tumor size (in general larger tumors are more aggressive), and the presence or absence of gross local invasion and/or metastasis, thus reflecting biological behavior (2, 3). Most NETs are well-differentiated tumors that are characterized by a solid trabecular or glandular structure, tumor cell monomorphism with absent or low cytological atypia, and a low mitotic (<2 mitoses/mm²) and proliferative status (<2% Ki-67 positive cells) (3). Such tumors are slowly growing but can occasionally exhibit more aggressive behavior (>2 mitoses/mm² and/or proliferation index >2% Ki-67 positive cells); however, only in the presence of metastasis and/or invasiveness is the tumor defined as a well-differentiated NE carcinoma (2, 18). Poorly differentiated NETs are invariably malignant, are defined as poorly differentiated NE carcinomas, and are characterized by a predominantly solid structure with abundant necrosis, cellular atypia with a high mitotic index (≥10 mitoses/mm²) and proliferative status (>15% Ki-67 positive cells), diffuse reactivity for cytosolic markers, and scant or weak reactivity for granular markers or neurosecretory products (3). Mixed exocrine-endocrine carcinomas are epithelial tumors with a predominant exocrine component admixed with an endocrine component comprising at least one third of the entire tumor cell population. Their biological behavior is essentially dictated by the exocrine component, which may be acinar or ductal type (18). It is hoped that, in the future, other factors such as the angiogenic capacity of tumor cells and specific genetic changes may prove to be valuable tools in determining prognosis, biological behavior, and response to therapy (10).

III. Tumor Biology

A. Genetic defects

NETs can occur sporadically or in a familial context of autosomal dominant inherited syndromes such as multiple endocrine neoplasia (MEN) (8, 19). Four major MEN syndromes, MEN I, MEN II, von Hippel-Lindau (VHL) disease, and Carney complex, represent the most common forms of inherited predisposition to NETs with variable but high penetrance in various NE tissue; early screening can be used for presymptomatic diagnosis (8, 19). Less commonly, endocrine

tumors of the pancreas, parathyroids, and adrenal glands have been observed in phacomatoses, such as neurofibromatosis (NF) type 1 and tuberous sclerosis (19). In addition, familial occurrence of single endocrine lesions such as primary hyperparathyroidism, pituitary adenomas, medullary thyroid carcinoma (MTC), or pheochromocytomas have been identified as putative genetic diseases for most of which the genetic pathways remain to be identified (20).

Most NET-predisposing diseases have been related to inactivation of tumor growth suppressor genes, except in MEN II and the inherited form of MTC, which occur through dominant activation of the RET protooncogene (19, 21). The RET protooncogene encodes a transmembrane tyrosine-kinase receptor that causes cellular proliferation, differentiation, and increased cell motility (8, 21). MEN II comprises three clinical subtypes, MEN IIA, MEN IIB, and familial MTC (FMTC) (21); in MEN IIA, all patients develop MTC, about 50% pheochromocytoma, and about 15% primary hyperparathyroidism (21, 22). Patients with MEN IIB may have a marfanoid habitus and mucosal neuromas but not hyperparathyroidism; in these patients, MTC occurs at a younger age and behaves more aggressively compared with MEN IIA (19, 21). Approximately 95% of MEN II cases are accounted for by germline RET mutations (~98% of MEN IIA cases, 97% of MEN IIB cases, and 85% of FMTC cases) (21, 23). MEN I is an autosomal dominant syndrome characterized mainly by hyperplasia and/or multiple tumors of the parathyroid, endocrine pancreas, anterior pituitary, foregut-derived NET-tissues, and adrenocortical glands (24). Somatic mutations of the *MEN I* gene have been reported in sporadic forms of endocrine tumors with a variable incidence of 20–30% in parathyroid (25), endocrine pancreas (33% gastrinomas, 17% insulinomas) (26), 25% of lung carcinoids (27), but less than 1% in pituitary and adrenocortical tumors (4). In clinical practice, genetic analysis is useful to assess the syndromic diagnosis of MEN I, but the diagnosis cannot be excluded with certainty when a mutation is not found (8). Therefore, the clinical screening of patients remains a prerequisite for genetic analysis. The three major features of VHL disease are retinal angiomas, central nervous system hemangioblastomas, and clear cell renal cell carcinomas; the lifetime risk for each of these tumors has been estimated as greater than 70% (21, 28, 29). Other VHL-related lesions include pheochromocytomas, pancreatic islet cell tumors, and papillary cystadenomas of the pancreas, epididymis, the broad ligament, and the lymphatic sac of the middle ear (29). However, the incidence of specific tumors depends on the phenotypic class of VHL, of which four have been described (type 1 and types 2A, 2B, and 2C). The Carney complex is an autosomal dominant disease predisposing to various types of tumors, including cardiac and cutaneous myxomas, spotty pigmentation of the skin, and nonneoplastic hyperfunctioning endocrine states, such as nodular adrenocortical hyperplasia associated with Cushing's syndrome and pituitary and thyroid adenomas (30, 31). Approximately 1% of patients diagnosed with pheochromocytomas may have NF1, a dominantly inherited disorder with complete penetrance but highly variable expressivity (32). Diagnostic criteria for NF1 include cutaneous or sc neurofibromas, café-au-lait spots appearing early in life, optic glioma, benign iris hamartomas

(Lisch nodules), and specific dysplastic bone lesions (32). Digestive tract carcinoid tumors have rarely been described in patients with NF1 and tuberous sclerosis (8, 33). Knowledge of the particular genetic defects in these familial syndromes is essential for the early screening and counseling of other family members.

B. Apoptosis

The protein product of the bcl-2 oncogene is an important modulator of apoptosis because it blocks programmed cell death without affecting cell proliferation (34–36), whereas the c-myc protooncogene, which inactivates key tumor suppressors such as p53 and retinoblastoma gene product, also plays a central role in some forms of apoptosis (36, 37). Coexpression of bcl-2 and c-myc leads to a synergism that may result from the ability of bcl-2 to directly interfere with the apoptotic cell death resulting from the dysregulated expression of c-myc (34–36). Such an association has recently been described for a number of NETs including MTC, pheochromocytomas, carotid body tumors, and some carcinoids (34).

C. Growth factors

Malignant progression of NETs may also be triggered by overexpression of growth factors involved in endocrine and endothelial cell proliferation such as TGF α , endothelial growth factor, nerve growth factor, and vascular endothelial growth factor (VEGF)/VEGF-related factors (19). Among various growth factors promoting angiogenesis, VEGF was found to be overexpressed, mainly in midgut carcinoid and some pancreatic tumors, suggesting that it may be involved indirectly in the growth of these tumors (38).

The genetic markers so far identified in various sporadic types of NETs are not specific enough to be used for diagnostic purposes, but they provide some clues as to the genetic mechanism of tumor development.

IV. Tumor Markers in Neuroendocrine Tumors

A. Serum and immunohistochemical tumor markers

The various cell types of the NE cell system can secrete specific products, such as peptides and biogenic amines, that are tumor-specific and may serve as markers for the diagnosis and follow-up of treatment (see *Section IV.A.1*); it is also probable that some tumor markers may have prognostic implications (6, 39) (Table 1). A number of other components specific for all NE cells and associated with secretory granules or cytosolic proteins can also be used as tumor markers; among these, the chromogranin family is the one most commonly used (see *Section IV.A.2*) (6, 39).

1. Specific tumor markers. Peptide hormones are synthesized as precursors, which are cleaved in a sequence- and tissue-specific manner to yield the biologically active peptides; however, their fine processing is usually deficient in NET cells (6). Therefore, direct measurement of these peptides, and when necessary of their precursors, establishes the diagnosis and occasionally also provides information regarding the size of the tumor (39). In addition, there are cases in

TABLE 1. Common tumor markers and distribution of SS receptors in patients with GEP tumors, chromaffin cell tumors, and MTCs

Tumor types	Specific serum tumor markers	Nonspecific serum tumor markers	SS receptors (positive scintigraphy with ¹¹¹ In-octreotide)
Thymus	SS, serotonin	CgA, NSE	50–80%
C-thyroid cells	Calcitonin, CGRP, ACTH, SS, serotonin	CgA, CEA	70–75%
Lung	GRP, CT, SS, POMC, ACTH, ADH, serotonin, β -hCG	CgA, NSE	80%
GI tract	Gastrin, CCK, GIP, VIP, motilin, glucagon, GRP, PP, GHRH, POMC, ACTH, serotonin	CgA, NSE, hCG	80–90%
Pancreatic islet cells	Insulin, gastrin, VIP, glucagon, SS, serotonin	CgA, NSE, hCG	60–95%
Ovary	Serotonin, hCG, PTHrP, POMC, CGRP	CgA, NSE	
Chromaffin cells	Noradrenaline, adrenaline, dopamine, POMC, calcitonin, neuropeptide Y, neurotensin, SS	CgA, NSE	85–95%
Adenocarcinomas with NE differentiation	POMC, CGRP	CgA, NSE	20–35%

Derived from Krenning *et al.* (53); Olsen *et al.* (70); Lamberts *et al.* (6); Nobels *et al.* (40); Oberg (407); Norheim *et al.* (211); and Tomassetti *et al.* (213). POMC, Proopiomelanocortin; GIP, gastric inhibitory peptide.

which multiple hormone production is evident, which can also fluctuate throughout the course of the disease (39). The measurement of serum hormone concentrations can also be useful in the diagnosis of clinically nonfunctioning tumors in which the hormonal products may not be associated with clinical syndromes (6, 40). More recently, the α - and β -subunits of human chorionic gonadotropin (α - and β -hCG) have been shown to be markers of nonfunctioning GEP tumors, as well as MTC and small-cell lung carcinoma (SCLC) (6, 40).

2. Nonspecific tumor markers. In addition to specific hormones secreted by NE cells, other proteins that exert regulatory activities on the packaging, processing, and secretion of hormones are increasingly recognized as NET markers (6, 39, 41). CgA, CgB, and CgC form a group of acidic monomeric soluble proteins that are localized within secretory granules in which they are costored and cosecreted with the locally present peptides (39, 42). CgA is the granin mostly used in clinical practice, although the other chromogranins are relevant, particularly as CgA-negative, but CgB-positive tumors are increasingly being recognized (39, 43). Plasma CgA levels may be elevated in a variety of NETs, including pheochromocytomas (43–45), paragangliomas (40, 46), carcinoid and pancreatic islet cell tumors (43, 46, 47), MTC (43), parathyroid and pituitary adenomas (48), although much less (<60%) in SCLC (40, 44). The highest CgA levels have been found in metastatic carcinoids and GEP tumors (44, 45, 49, 50). Both tumor burden and secretory activity should be considered when interpreting CgA results, with a sensitivity and specificity varying between 10–100% and 68–100%, respectively (5, 43, 50). Renal insufficiency and hypergastrinemia are the main causes of false-positive CgA results (40, 43). Several assays for the measurement of intact CgA and the different cleavage products have been developed using either monoclonal or polyclonal antibodies, and thus exhibiting substantial differences in sensitivities and specificities (51). This must be taken into consideration until a recognized international standard for CgA is established (51). Comparative studies have shown that the sensitivity of CgA in relation to the reference biological specific markers is higher in foregut carcinoids, comprising bronchial, thymic, head and neck primaries (5, 40, 43), and comparable to specific tumor marker sensitivities in patients with ileal carcinoids and pheochromocytomas (43, 50). In addition, CgA has been

shown to be an independent prognostic factor for midgut carcinoids because it correlates not only with tumor burden but also with biological activity (46, 47).

Synaptophysin and NSE are present diffusely in the cytoplasm of NETs, so they are consistently positive in most NETs (6). NSE is only present in neurons and NE cells and can also serve as a circulating marker for NETs (6). NSE is most frequently elevated in patients with SCLC (74%) but has also been found to be elevated in 30–50% of patients with carcinoids, MTC, islet cell tumors, and pheochromocytomas (40). Elevated levels of NSE are also roughly correlated with tumor size, although the specificity is lower than that of CgA; however, the combination of both CgA and NSE has a higher sensitivity than either parameter separately (40). Some oncogenic proteins are not specific for NETs but are frequently synthesized in these tumors, *i.e.*, carcinoembryonic antigen (CEA) in MTC (6).

3. Tumor markers and stimulation tests. When patients present with a high clinical suspicion of a functional syndrome but with normal basal measurements of specific tumor markers, a dynamic test can be used to increase sensitivity (39). Although the rationale of employing such tests has recently been questioned, several dynamic tests have traditionally been used (52). The dynamic tests that are still in use will be discussed later with reference to individual tumor types.

B. Amine and peptide receptor expression and visualization

The demonstration of the presence of amine uptake mechanisms and a high density of peptide receptors on several NETs, as well as their metastases, has been used for both diagnosis and monitoring of these tumors using radionuclide techniques (6, 53).

Metaiodobenzylguanidine (MIBG) is a guanidine derivative that exploits the specific type 1 amine uptake mechanism at the cell membrane and the subsequent uptake from the cytoplasm and storage within the intracellular storage vesicles (54). It shows little binding to postsynaptic receptors and has minimal or no intrinsic pharmacological effect (54, 55). MIBG localizes to adrenomedullary tumors, hyperplastic adrenal medulla and, to a lesser degree, in the healthy adrenal medulla (54, 56). In addition, several other NETs including carcinoids and MTC exhibit this specific uptake mechanism and can thus accumulate MIBG (54).

SS is a 14-amino acid peptide that is widely expressed throughout the central nervous system as well as in peripheral tissues including the endocrine pancreas, gut, thyroid, adrenals, and kidneys (57, 58). SS acts mostly as an inhibitory factor on neurotransmission, intestinal motility, absorption of nutrients and ions, vascular contractility, and cell proliferation (57). Owing to its short half-life (1–2 min), many SS long-acting analogs have been synthesized, among which octreotide and lanreotide are the ones most commonly used in clinical practice (59, 60). These analogs are cyclic octapeptides that have a more prolonged half-life (1.5–2 h), and thus, biological activity (6, 59–61). The biological effects of SS are mediated by five specific SS receptors (1–5) that all bind the native peptide but show major differences in their affinities for SS analogs; the currently used analogs exhibit a very low affinity for SS receptors 1 and 4 but bind with high affinity to SS receptors 2 (predominantly) and 5 and with moderate affinity to SS receptor 3 (6, 57, 62, 63). Each receptor subtype is coupled to multiple intracellular transduction pathways, but all five are functionally coupled to inhibition of adenylate cyclase and decreased calcium influx, and thus generally inhibit hormonal secretion and intestinal motility (57). SS also inhibits the proliferation of both normal and tumoral cells as a result of hypophosphorylation of the retinoblastoma gene product and G₁ cell cycle arrest (64). The anti-proliferative effects of SS can also result from apoptosis through SS receptor 3 induced by p53 and Bax (39). The SS effect on tumor growth may also be the result of indirect effects through the inhibition of growth factors (65) and angiogenesis (66, 67).

SS receptors are found mainly in well-differentiated rather than poorly differentiated tumors and thus may exert prognostic significance as markers of differentiation (Table 1) (67–69). The high frequency of SS receptor 2 mRNA in NETs allows the localization of various human tumors and metastases using ¹¹¹In-labeled octreotide (57, 66); there is a close correlation between the presence of SS receptor 2 mRNA, tracer uptake using SS receptor autoradiography, and the therapeutic response to SS analog treatment (6, 39, 70). In addition, specific polyclonal antibodies against SS receptor 2 have been developed that correlate with ¹¹¹In-labeled octreotide uptake (71). Tumors and metastases that harbor uptake mechanisms and/or peptidic receptors can be visualized *in vivo* using a γ -camera after the injection of ¹²³I-MIBG and/or ¹¹¹In-pentetreotide (72, 73). In addition, other small peptidic receptors that are expressed in cell membranes of NE tissues include vasointestinal peptide (VIP), bombesin, cholecystokinin (CCK), gastrin and/or substance P (6, 67–69). Labeled analogs/peptides can also be used as markers for putative receptors for *in vivo* tumor visualization (69, 74).

C. Radionuclide imaging

Radionuclides provide a diagnostic modality in which radiolabeled amines or peptide analogs, based on their ability to bind to suitable ligands, are used for the identification and localization of NETs (7, 62, 63, 75).

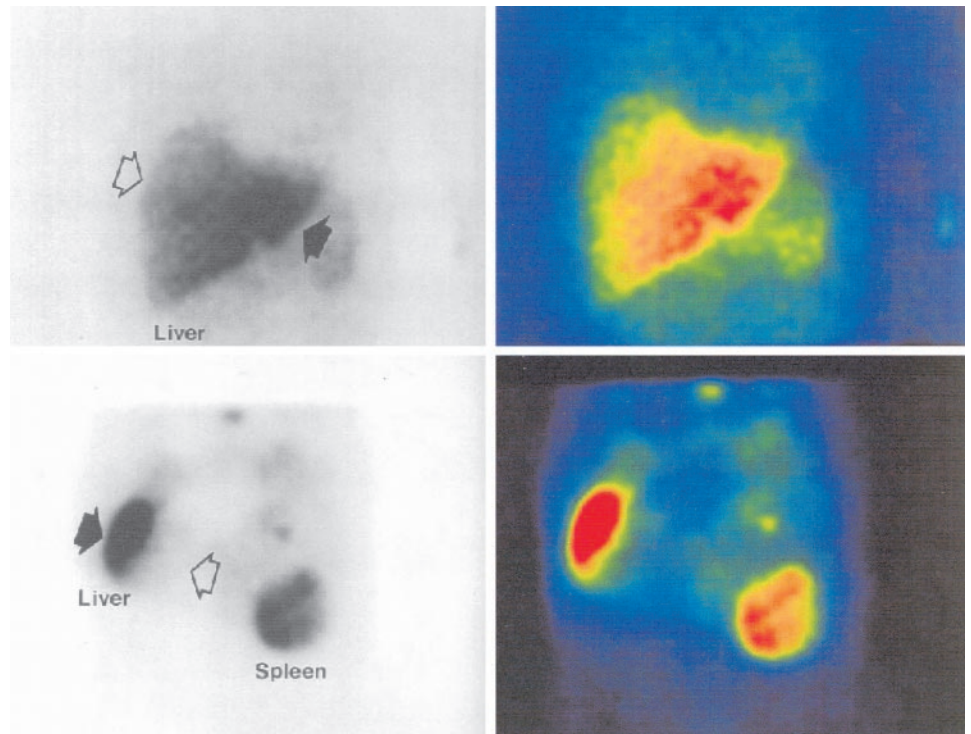
1. Scintigraphy with MIBG (¹²³I-MIBG). The prolonged storage of MIBG within secretory vesicles permits high specific uptake and imaging after labeling with both ¹³¹I- and ¹²³I-MIBG; however, imaging quality with ¹²³I-MIBG is superior, and it

is currently the radiopharmaceutical of choice (76–79). The efficiency of ¹²³I-MIBG is excellent for the visualization of intraadrenal and extraadrenal sites of benign and malignant pheochromocytomas, showing a diagnostic sensitivity and specificity above 80 and 90%, respectively (80). Radiolabeled MIBG facilitates in the diagnosis of multiple tumors and paragangliomas, in the detection of suspected malignant chromaffin tumors, for the screening of individuals at risk in familial forms of the disease, and for the selection of patients for therapeutic MIBG based on a positive diagnostic scan (72, 78). It also has a complementary role in the diagnosis of other NETs such as carcinoids and MTC (78–80) (Fig. 1); its sensitivity is said to be enhanced with the preimaging administration of MIBG, but this remains controversial (81).

2. Scintigraphy with SS analogs (¹¹¹In-octreotide). Octreotide (Sandostatin, Novartis, Basel, Switzerland) was the first SS analog to be used in clinical practice, although considerable experience has also been obtained with lanreotide (Somatuline/Ipstyl, Ipsen, Paris, France) (73). These compounds have been conjugated with DTPA (diethylene-triamine-pentaacetic acid) (63, 64, 82), but more recently with DOTA (1,4,7,10-tetraazacyclododecane-1,4,7,10-tetraacetic acid) as a way of coupling SS analogs with various radionuclides (83, 84). There is a predominance of renal clearance of the analog (73, 85, 86), although the uptake of ¹¹¹In-DTPA octreotide (pentetreotide) shows a bell-shaped function of the injected mass, explaining the increased uptake that follows prior administration of the unlabeled peptide (73, 87). Planar and single-photon emission CT (SPECT) lesions are performed 24 and 48 h after the injection of the radiopharmaceutical; normal visualization includes the thyroid, spleen, liver, kidneys, and part of the pituitary (73, 86) (Fig. 2). Scintigraphy with ¹¹¹In-octreotide has been shown to have a detection rate of 67–91% for all NETs and is used both for diagnosis and staging, and also in the follow-up of patients (7, 53, 59, 70, 83). In addition, it also exhibits high specificity (88–92), although occasional false-positive localizations may occur because uptake is also demonstrable in many other tumors, granulomas, and autoimmune diseases (7, 53, 54, 83, 86). A recent systematic study prospectively assessing the specificity of scintigraphy with ¹¹¹In-octreotide in patients with gastrinomas revealed an overall specificity of 86% (93, 94). Evidence from *in vitro* studies has shown increased uptake of radiolabeled octreotide in the presence of low concentrations of unlabeled octreotide (95, 96). During octreotide treatment, the uptake of ¹¹¹In-octreotide in SS receptor-positive tumors and the spleen is diminished (95). In general, NETs remain visible during treatment with octreotide, although tumor uptake may be less than without octreotide treatment (95).

The detection of an unsuspected lesion in a patient with a single known lesion is important in that it may affect the selection of curative surgery, which remains the treatment of choice in patients with NETs (83, 97–99); however, there are no clinical or biochemical predictors of a positive scan (7, 99). False-positive results have been reported, although this may be a misnomer because they may actually represent micrometastases (73). ¹¹¹In-DTPA-Tyr³-octreotate, a newly synthesized SS analog, demonstrated higher tumor uptake than ¹¹¹In-DTPA-Tyr³-octreotide, whereas kidney uptake was similar (73). More

FIG. 1. Qualitative difference in the pattern of uptake with ^{123}I -MIBG (top panels) and ^{111}In -pentetreotide (bottom panels) scintigraphy in the same patient with hepatic metastases from an ileal carcinoid. [Adapted with permission from Kaltsas *et al.*: *J Clin Endocrinol Metab* 86:895–902, 2001 (99). © The Endocrine Society.]



recently, ^{68}Ga coupled to octreotide and ^{64}Cu -TETA-octreotide have been used as tracers for positron emission tomography (PET) imaging (58, 100), because they exhibit better tumor-to-background ratios than ^{111}In -octreotide, and in a few cases ^{64}Cu -TETA-octreotide demonstrated more lesions than ^{111}In -octreotide in patients with NETs (58, 100). Alternatively, scanning with radiolabeled VIP has been shown to be equally sensitive to ^{111}In -octreotide in a direct comparison of 14 GEP tumors, indicating that these tumors may either coexpress both SS and VIP receptors or demonstrate cross-reactivity, most probably to SS receptor subtype 3 (67, 68, 78, 101). Other small peptide receptors that are also expressed on the cell membranes of NE cells, such as bombesin, CCK, gastrin, and/or substance P (6, 67, 69, 102), can also be used for *in vivo* tumor visualization (69). At present, despite efforts aimed at developing more specific radioligands, ^{111}In -octreotide remains the radiopharmaceutical of first choice for the imaging of NETs (Refs. 73 and 78; also see Ref. 103).

3. *PET imaging.* PET utilizes the ability of radiolabeled tracers to be taken up by certain tumors and can thus selectively measure the function of different metabolic pathways of the specific tissue (104). The first tracer used in oncology was ^{18}F -labeled deoxyglucose (FDG); however, because NETs are mostly well-differentiated and slow-growing tumors, they have a low metabolic rate and cannot be visualized efficiently with this tracer, which is more useful in less-differentiated NETs without SS receptors (78, 105, 106). The metabolic pathway synthesizing 5-hydroxytryptamine (5-HT) from 5-hydroxytryptophan (5-HTP) occurs in carcinoid and other NETs and can thus also be used for PET imaging (105, 106). ^{11}C -5-HTP is specifically trapped by serotonin-producing tumors, and this can be further enhanced by the concomitant administration of carbidopa (107). PET imaging using ^{11}C -

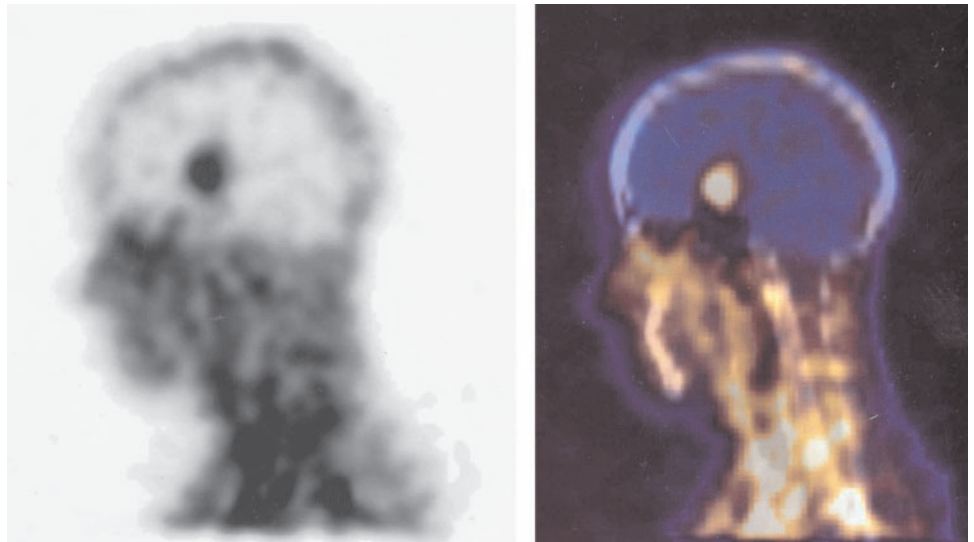
5-HTP as a tracer is overall more sensitive compared with the other NE tracer ^{11}C -labeled-L-DOPA, and can be used as a universal tracer for these tumors (104, 108). PET imaging using ^{11}C -5-HTP has been shown to be superior to computed tomography (CT) scanning in diagnosing GEP tumors and monitoring their response to therapy; for poorly differentiated tumors, FDG-PET can be used instead (106, 107). Because scintigraphy with ^{111}In -octreotide fails to visualize 10–20% of GEP tumors, PET may prove to be superior, although this needs to be formally assessed by a prospective trial (78).

V. Natural History of Neuroendocrine Tumors

Natural history is defined as the spontaneous course of a disease (109). For many NETs, this is not well known due to the relative rarity of NETs, particularly GEP tumors, and the lack of controlled prospective trials (59, 60). The behavior of GEP NETs is rather heterogeneous, with the majority exhibiting long periods of relatively small growth, spontaneous standstill, or even tumor regression, although a subset can show explosive growth and behave in a highly malignant manner (59). The majority of patients with MITC may retain localized disease for years, but some develop early metastases that are associated with a poor outcome (110). Chromaffin-cell tumors can also develop late recurrences after successful treatment or develop an early aggressive course (111). In addition, a considerable proportion of these tumors may occur as part of familial syndromes with involvement of multiple organs in the index patient and other members of the patient's family (4, 5, 21, 112).

Once an NET has been diagnosed, three main factors have to be considered: recognition of the possibility of a familial syndrome, "disease spread" assessment, and the tumor's biological behavior (109, 112). Screening for MEN and other related fa-

FIG. 2. ^{111}In -octreotide scan (Octreoscan) in a young female patient with a midline intracerebral NET. There was no significant pathological uptake elsewhere in the body, and the patient was referred for external beam radiotherapy as the safest therapeutic option (patient of Dr. P. N. Plowman, Dr. M. Powell, and Dr. A. B. Grossman).



mial syndromes is a fundamental step in the management of NETs, because prognosis and treatment may differ from the sporadic cases and there is the issue of familial screening in patients with familial syndromes (109, 113). The diagnosis of MEN is based on the presence of other MEN-related endocrinopathies in a patient or relatives. Occasionally, when the clinical suspicion is high without unequivocal biochemical confirmation, dynamic endocrine tests and more recently genetic screening may be needed (109). The association of MEN with NETs renders treatment more difficult, because MEN-related tumors may be multiple and diffusely spread (113). Hepatic and bony metastases are the major causes of death, with a less than 50% probability of 5-yr survival in patients with metastatic GEP tumors (109). Similarly, the liver is the most frequently involved organ in the metastatic process in MTC and malignant chromaffin cell tumors (114–116). The usually small difference between the 5- and 10-yr survival rates indicates that there are probably two subsets of patients with liver metastases (109, 117): 1) patients in whom there is a rapid tumoral evolution, who die relatively early, the median interval between progression of liver metastases (>25% growth within 6–12 months) and death being relatively short, 6 months (range, 1–24 months); and 2) patients with slow tumoral evolution who usually have prolonged survival (109, 114, 116). The routine use of the previously described variables to predict the biological behavior of the tumor probably discriminates well-differentiated from poorly differentiated NETs and the subset of well-differentiated tumors that may follow a more aggressive course. Among these variables, tumoral staining for Ki-67 and vascular and/or perineural invasion exhibit the highest sensitivity and specificity (112).

VI. Clinical Presentation, Biochemical Confirmation, and Imaging of NETs

A. Carcinoid tumors

Carcinoid tumors are derived from neoplastic proliferation of enterochromaffin (ECL) or Kulchitsky cells (118). These cells are ubiquitous but predominate in the GI and

urogenital tracts and bronchial epithelium (2, 119). One of their main characteristics is the synthesis, storage, and secretion of serotonin (11). Serotonin is synthesized from tryptophan through its precursor, 5-HTP, and subsequently metabolized to 5-hydroxyindoleacetic acid (5-HIAA), which is excreted in the urine (52, 119). In addition to serotonin, carcinoid tumors may also secrete other hormones such as corticotropin (ACTH), histamine, dopamine, substance P, neurotensin, prostaglandins, kallikrein, and tachykinins (52, 119, 120). In normal subjects, approximately 99% of tryptophan is used for the synthesis of nicotinic acid, and 1% or less is made into 5-HT. In patients with carcinoid tumors, there is a shift toward the production of 5-HT and eventually 5-HIAA (52, 121). When 5-HT and other products are secreted into the portal circulation, they are efficiently metabolized by the liver and do not usually cause any systemic signs or symptoms. However, when liver metastases are present or when the primary lesions are found in the bronchus and/or ovaries, the systemic features of the carcinoid syndrome (CS) become more evident (52, 119, 121).

The exact etiology of carcinoid tumorigenesis is unknown, although experimental studies have shown that in contrast to a number of nonendocrine tumors, neither common oncogenes (ras, myc, fos, jun, src) nor common tumor suppressor genes (p53, retinoblastoma) are generally important in the molecular pathogenesis of most, except possibly the more atypical forms (122). Recently, the amine handling of carcinoid tumors was highlighted with the finding of vesicular monoamine transporter in endocrine gut cells and carcinoid tumors (123, 124).

1. Clinical presentation

a. Classification. Carcinoid tumors have traditionally been classified further according to the anatomic site of origin (52, 118, 121): foregut (including respiratory tract, thymus, stomach, duodenum, and pancreas), midgut (including small intestine, appendix, right colon), and hindgut (including transverse colon, sigmoid, and rectum). Within these subgroups, the biological and clinical characteristics of the tumors vary considerably (2, 5, 119). Foregut carcinoids have a low con-

tent of serotonin (5-HT) and often secrete the serotonin precursor 5-HTP, histamine, and a multitude of polypeptide hormones causing characteristic clinical syndromes (121). Foregut carcinoids are associated with an atypical CS and have the potential to metastasize to bone (118, 121). Midgut carcinoids have a high 5-HT content (118, 121), rarely secrete 5-HTP or peptide hormones, but do release 5-HT and other vasoactive compounds such as kinins, prostaglandins, and substance P (52, 119, 121); they are more likely to cause the classic CS with the development of hepatic metastases and rarely metastasize to bone (109, 118). Hindgut carcinoid tumors rarely contain 5-HT, secrete 5-HTP, and/or cause the CS; however, they can contain numerous GI hormones and very infrequently metastasize to bone (118).

b. Incidence, epidemiology, and prognosis. Carcinoids are relatively rare tumors with an annual incidence of 0.8–2.1 cases per 100,000 per year (125–127), although autopsy series have found an incidence of 8.4 cases per 100,000 population per year (128). Analysis from Cancer Registries of several countries has recently highlighted the distribution of carcinoid tumors in the gut and other areas throughout the body (125, 129, 130). Carcinoid tumors, mainly foregut carcinoids, are associated with MEN I in about 10% of cases (20, 52), but can also occur in MEN II or NF1 and occasionally in familial polyposis coli; however, the great majority are sporadic (33, 52, 131–134). Non-MEN familial carcinoid tumors are rare, most being GI in five families and pulmonary in the other family described to date (132, 135). Recent epidemiological studies have shown a small increased familial risk for midgut and hindgut carcinoids in offspring of parents affected with carcinoids, bladder cancer, or other endocrine gland tumors (129, 136). Overall, approximately 1% of patients with carcinoid tumors appear to have a positive family history in first-degree relatives, which is therefore associated with a relative risk of 3.6; this is much higher if both parents are affected (129, 136).

A cumulative analysis of all types of carcinoid tumors showed that in 45% of cases metastases were already evident at the time of diagnosis and that the 5-yr survival rate of all carcinoid tumors regardless of site was approximately 50% (126). The highest metastatic percentages were noticed for pancreatic (76%), colonic (71%), and small bowel carcinoids (71%), corresponding to their poor 5-yr survival rates (34, 42, and 55%, respectively) (126, 137). Among patients with distant metastases, those with midgut primary tumors have improved survival compared with patients with tumors arising from other primary sites (126, 137). Synchronous or metachronous adenocarcinomas, particularly of the large bowel, are found in 13% of patients, particularly males, with mainly midgut tumors (52, 130, 131). Occasionally, carcinoid tumors may secrete one hormone, whereas at other times the peptide or amine secreted may differ and yield an entirely different clinical syndrome or, more rarely, metastases may secrete different hormones from the original tumor (121).

c. CS. The CS is usually a consequence of a synergistic interaction of tumor factors (5-HT, kinins, kallikrein, prostaglandins) gaining access to the systemic circulation, thus circumventing metabolism in the portal or pulmonary arterial circulation (52, 118, 121, 138, 139). Patients with the more

common (95%) classic (typical) CS usually present with flushing (90%), diarrhea (70%), abdominal pain (40%), valvular heart disease (40–45%), telangiectasia (25%), wheezing (15%), and pellagra (5%) (52, 118, 121, 138, 139).

The principal features of CS are diarrhea and flushing (139). In the early phases of the disease, the major mechanisms of diarrhea are secretory and GI dysmotility factors, whereas the later phases are also associated with gut lymphangiectasia and bacterial overgrowth (60, 121, 139). The flush found in patients with the classic CS (midgut carcinoids) is usually of a pink to red color and involves the face and upper trunk, lasting for a few minutes and occurring many times per day without leaving a permanent discoloration (121). This type of flush is triggered by alcohol or tyramine-containing foods, chocolate, walnuts, and bananas (121, 138, 139). The atypical syndrome, which is much less common (5%), consists in a flush that tends to be of protracted duration lasting for hours, of a purplish rather than the usual pink-red color. It frequently leaves telangiectasia and hypertrophy of the skin of the face and upper neck but also involves the limbs, which may become acrocyanotic; this type of flush occurs in the absence of triggering foods (10, 52, 121, 139). In addition, headache, lacrimation, hypotension, cutaneous edema, and bronchoconstriction may occur (10, 139). It is usually found in patients with foregut carcinoid tumors, and it is thought to be mediated by 5-HTP, histamine, and other biogenic amines (121, 139). In a recent analysis of 8876 patients with carcinoid tumors, 8.4% of patients developed the CS; these patients were older, had higher serotonin activity, and a higher incidence of hepatic metastases compared with patients without CS (138).

Carcinoid crisis is the most immediate life-threatening complication of the syndrome; it is mostly observed in patients with foregut and midgut carcinoid tumors (139). Hypotension, very rarely hypertension, tachycardia predisposing to arrhythmias, bronchial wheezing, flushing, and central nervous system dysfunction are the main features (52, 118, 121). It can occur spontaneously or, more commonly, can be precipitated after anesthesia, interventional procedures, or medication (chemotherapy, or radiopharmaceuticals causing tumor lysis and releasing large amounts of amines into the systemic circulation) (139).

d. Pulmonary carcinoids. Pulmonary carcinoids account for approximately 1–2% of primary lung tumors (140, 141) and are classified along a spectrum of pulmonary NETs with different biological characteristics such as typical carcinoid tumor, atypical carcinoid tumor, large-cell NE carcinoma, and SCLC (142, 143). Typical bronchial carcinoids are generally more benign than atypical carcinoid tumors, but both types can metastasize to regional lymph nodes or to the liver, bones, and brain (143, 144). Typical carcinoid tumors (well-differentiated NETs) are mostly located centrally close to the hilum, are associated with symptoms suggestive of a mass effect (119, 145), and often develop clinical syndromes secondary to secretion of other hormones that are nontypical to the tissue of origin, such as Cushing's syndrome from ectopic secretion of ACTH (120), acromegaly due to ectopic secretion of GHRH, or the syndrome of inappropriate antidiuretic hormone secretion (ADH) due to ectopic ADH secretion (52,

119). The CS occurs in less than 5% of cases, although it may be found in up to 50% of patients with disseminated disease (144, 145). Some tumors produce histamine, and these patients may experience an atypical CS (146). Well-differentiated pulmonary tumors are usually indolent, associated with metastases in less than 15% of cases (119, 147, 148). The presence of lymph node metastases and symptoms at the time of diagnosis are considered adverse prognostic factors (140, 144, 145); most studies have shown 5- and 10-yr survival rates of around 90% (140, 144, 145, 147, 148).

Approximately 20–30% of pulmonary carcinoid tumors have atypical histological features and are more accurately classified as well-differentiated pulmonary NE carcinomas (119, 140, 144, 145). The combination of carcinoid morphology and the presence of two or more mitoses per square millimeter or necrosis is diagnostic of atypical carcinoids (143). Atypical carcinoids have a more aggressive clinical course, metastasize to lymph nodes in 30–50% of cases, and have a 5- and 10-yr survival rate of 40–60% and 35–49%, respectively (140, 141, 143, 144, 148, 149). Large-cell NE carcinoma are closely related to smoking and, although less aggressive, have a similar clinical course and prognosis to SCLC (Refs. 143 and 149; also see Ref. 150).

e. Thymic carcinoids. Thymic carcinoids are a rare type of tumor with approximately 150 cases reported (151). MEN I-related thymic carcinoids constitute approximately 25% of all cases of thymic carcinoids, although rarely these tumors may be encountered in MEN IIA (151, 152). Thymic carcinoids frequently develop metastases and have a poor outcome; there is commonly an association with ectopic ACTH production, but not with the CS (152–154). In patients with MEN I, this is an insidious tumor associated with neither Cushing's syndrome nor the CS, typically developing in males (>95%), aged over 40 yr (>70%), with a history of tobacco smoking (>70%) (151, 152, 155). Local invasion, recurrence, and distant metastasis are common; there is no effective treatment available (152, 153). Its male predominance, the absence of loss of heterozygosity in the MEN I region, clustering in some MEN I families, and the presence of different MEN I mutations in these families, suggest either haploid insufficiency or the involvement of other etiological factors, probably a putative tumor suppressor gene on 1p (151, 152).

f. Gastric carcinoids (GC). GC are separated into three distinct groups: GC associated with chronic atrophic gastritis (CAG) type A, GC associated with the Zollinger-Ellison syndrome (ZES), and sporadic GC (119, 156, 157). The prevalence of CS is 4% (158), whereas the majority of cases ($\leq 75\%$) are associated with CAG (119, 156–159); these latter patients have hypochlorhydria and hypergastrinemia that results in ECL cell hyperplasia (119, 156, 157), and approximately 50% have associated pernicious anemia (119, 156, 159). Most of these tumors are less than 1 cm in diameter, and approximately 60% are multifocal (160). CAG type A-associated carcinoids are usually indolent, metastasizing in 8–23%, with distant metastases in 3–5%, and although a few deaths have been described, the overall mortality is minimal (156, 158, 159, 161). Between 5 and 10% of GC are associated with the ZES and occur almost exclusively in the context of the MEN

I syndrome (119, 156, 162). These tumors are thought to arise from hyperplastic ECL cells, they are not associated with the CS, and their prognosis is similar to CAG type A-associated carcinoid tumors (119, 156, 157). Sporadic GC tumors account for 15–25% of GC tumors, are usually solitary and greater than 1 cm in diameter, and in approximately 30% are associated with an atypical CS mediated via histamine release (119, 156, 157, 159, 160). These tumors are highly aggressive, the great majority being metastatic at diagnosis, and are associated with a high mortality rate particularly in the presence of atypical histology (156, 158, 160). Regional lymph node metastases have been described in 20–50% of patients, and liver metastases ultimately develop in two thirds of patients (160). Occasionally, poorly differentiated cases of NE carcinomas, particularly in elderly patients, have been described with an overall mean survival of 7 months (Refs. 156 and 163; also see Refs. 164–167).

g. Duodenal carcinoids. Duodenal carcinoids are relatively uncommon tumors (18) that are usually of small size (2 cm) and are found during endoscopic procedures; such small tumors are not associated with metastases and appear to have a good prognosis (168). Duodenal carcinoids exhibit significantly lower serotonergic hormone levels than other foregut carcinoids, but up to 20% stain for SS, and rarely for calcitonin and pancreatic polypeptide (PP) (160, 168). When these tumors are of larger size (>2 cm), they may develop metastases to regional lymph nodes or the liver in 45% of patients (160). Approximately 30% may be associated with neurofibromatosis, occasionally MEN I and/or pheochromocytomas, and may display reactivity for other hormones (160). These various tumor entities are important to recognize because of possible associations with hormonal or hereditary syndromes and a distinctly variable aggressive behavior (160, 168). Overall survival is similar to GC (including sporadic cases) (168). Such tumors should be distinguished from duodenal gastrinomas, particularly in MEN I patients. A recent analysis has revealed a high typical/atypical ratio, a relatively low metastatic rate of 27%, and a 3% incidence of CS (169).

h. Pancreatic carcinoids. Primary pancreatic carcinoids (serotonin-producing tumors of the pancreas) are a rare subtype of pancreatic tumors with approximately 100 cases reported (160, 170). These tumors are relatively large with a high rate of metastasis (69–88.4%) at the time of diagnosis (168, 170, 171). Pancreatic carcinoid tumors produce higher levels of serotonergic hormones and are commonly associated with the CS (65%), which may be atypical because the most common symptoms are pain, diarrhea, and weight loss, whereas flushing is encountered in only approximately one third of such patients (168, 171). The diagnosis is based on a demonstrable pancreatic NET plus elevation of plasma serotonin and/or elevation of 5-HIAA (86%) in the urine; however, not all tumors result in recognizable hyperserotoninemia (170). These tumors have a poor prognosis due to delayed diagnosis, which precludes extensive resection, and a poor response to other therapeutic modalities; a single reported patient has been associated with MEN I (168, 170–172).

i. Small intestine carcinoids. The small intestine is the most common site for carcinoid tumors, which are thought to arise

from serotonin-producing intraepithelial endocrine cells; they make up approximately one third of small bowel tumors, are mostly located in the distal ileum, and are often multicentric (119, 126, 173). The majority of patients present with abdominal pain, small bowel obstruction, and metastases to the lymph nodes and the liver; 7–28.6% of them may present with the CS (119, 173). In this group of patients, tumor size is an unreliable predictor of metastatic disease, although tumors larger than 2 cm are more likely to metastasize (119, 174, 175). However, metastases have been reported even from tumors measuring less than 0.5 cm in diameter; approximately 65% of small gut carcinoids (<1 cm) show microscopic spread to lymph nodes and almost half have liver metastases (10, 173). These tumors are frequently associated with an extensive mesenteric reaction fibrosis leading to bulking of the intestine and mesenteric ischemia (10). Long-term survival correlates closely with the stage of the disease, 5-yr survival being 65–73% among patients with localized or regional disease and 36–79% among patients with liver metastases; the lowest survival is found in patients with more than four distinct liver metastases and the presence of the CS (47, 126, 173, 176). Synchronous and metachronous malignancies were found in approximately 14–16.6% of patients in recent series (126, 173, 177). The diagnosis of the primary site of these tumors may occasionally be quite difficult, and thus many cases of small bowel carcinoids may present as disseminated carcinoid tumors of unknown primary (177, 178).

j. Appendiceal carcinoids. Carcinoid tumors are the most common tumors of the appendix and are thought to arise from subepithelial endocrine cells of the lamina propria and submucosa of the appendix wall (119, 179). They are more common in women than in men and may be found in 0.3% of patients undergoing appendectomy (52, 119, 129, 180). The majority are located in the distal third of the appendix and are unlikely to cause obstruction (181, 182). Besides location, the size of the tumor is the best predictor of prognosis, particularly because more than 95% of appendiceal carcinoids are less than 2 cm in diameter (119). Patients with such small tumors only rarely metastasize, in contrast to approximately 30% of patients with larger tumors who may have either nodal or distant metastases (119, 182). The 5-yr survival rate is 94% for patients with local disease and 85% for patients with regional metastases (119, 126). In the presence of hepatic metastases, which can be associated with the CS, the 5-yr survival rate is 34% (119, 126). Goblet cell carcinoids of the appendix possess morphological features suggestive of both carcinoid and glandular differentiation (183). Recent studies have suggested an aggressive behavior with a 20–56% incidence of metastases, whereas tumor size is not an accurate guide to further management (5, 183). However, survival rates can show wide variation, indicating unpredictable malignant behavior (5, 184).

k. Carcinoids of the colon. Carcinoid tumors of the colon are thought to arise from serotonin-producing epithelial endocrine cells and account for less than 1% of colonic malignancies; however, only 60–70% of these tumors show positive serotonin immunohistochemistry (119, 126, 185). These tu-

mors are mainly located in the cecum, followed by the ileocecal region (185). Most patients present with symptoms of pain, anorexia, and weight loss (119, 186) and have clinically palpable tumors (185), whereas less than 5%, mainly with tumors of the proximal colon, present with the CS (119, 186, 187). In more than 90% of patients, tumor size is greater than 2 cm, and over two thirds of patients have either nodal or distant metastases at presentation; even lesions of less than 1 cm are associated with metastases in 22% (119, 185, 188). The 5-yr survival rates are 70% for patients with local disease, 44% for patients with regional metastases, and 20% for those with distant metastases (126).

l. Rectal carcinoids. Rectal carcinoids account for 1–2% of all rectal tumors (119, 126, 189), although most contain glucagon, PP, and glicentin-like peptides rather than serotonin (189, 190). The CS is very rare, and although patients can present with rectal bleeding, pain, or constipation, approximately 50% of tumors are asymptomatic and are found on routine endoscopy (119, 189, 191). The size of the primary lesion correlates closely with the probability of metastases that occur in less than 5% of patients with tumors less than 1 cm in diameter, but in most patients with tumors more than 2 cm in diameter; other important prognostic features are infiltration of muscularis propria and atypical histology (119, 189–191). However, the majority of patients with tumors between 1 and 2 cm and atypical histology may have developed metastases at diagnosis (191). Approximately 10% of rectal carcinoids may be associated with another colonic neoplasm (126). The 5-yr survival rates are 81% for patients with local disease, 47% for patients with regional disease, and 18% for patients with distant metastases (119, 126).

m. Ovarian carcinoids. These tumors are rare, ranging from 0.52–1.7% in different series (126, 192), and usually present with either pain in the pelvic area or pain with defecation (193). They can be divided into cystic teratoma/dermoid and those without such lesions (192). The former tumors follow a more benign course with less incidence of regional and hepatic metastases and a 5-yr survival of almost 100%, compared with 84% for the latter; for patients with disseminated disease (30%), the overall 5-yr survival is 33% (192, 193). The CS is present in approximately 30% of patients (192, 193).

n. Carcinoids of unknown primary. Carcinoids of unknown primary site have not been defined in detail, even in studies including a large number of patients with carcinoid tumors (126, 177). A recent analysis of 434 carcinoid tumors revealed an unexpectedly high number of carcinoids of unknown primary that were clinically and biochemically similar to midgut metastatic carcinoids (177). In addition, their survival rate was shorter than carcinoids with identified primaries and similar to that of patients with midgut carcinoids with distant metastases (22 *vs.* 28%) (177).

o. Less common primaries and metastatic locations. After the publication of studies including large numbers of patients, it became obvious that carcinoid tumors may develop in virtually any organ; however, relatively few have been reported arising from the esophagus, liver or gall bladder, middle ear, testis, and the heart (98, 126, 129, 194–198). More recently, the

application of more sensitive techniques including radionuclide imaging with MIBG and octreotide has demonstrated unusual areas of metastases and remote primaries in patients with carcinoid tumors, such as the breast and orbit (98, 194).

p. Carcinoid heart disease (CHD). CHD occurs in 57–77% of patients with the CS but is hemodynamically significant in a much smaller percentage (199, 200). Carcinoid heart lesions are characterized by plaque-like, fibrous endocardial thickening that classically involves the right and, in approximately 10% of patients, the left side of the heart, the most common valvular lesion being tricuspid regurgitation (119, 199, 201, 202). Patients with the CS and CHD have significantly higher levels of 5-HIAA and other vasoactive substances, suggesting that higher serotonin levels may be responsible (118, 126), although the great majority of them have previously received chemotherapy (200). This view is also supported by the finding that anorectic drugs that interfere with serotonin metabolism can produce valvular lesions similar to those seen in CHD (118, 119, 203, 204). Patients with CHD also exhibit high levels of plasma vasopressin (205, 206). Right-sided heart disease is associated with substantial morbidity and mortality in such patients, and nearly half of the patients who die of CS succumb to heart failure (118, 119); a recent analysis revealed that at least in some patients SS analogs did not prevent progression of cardiac lesions (207). Although valvular replacement in patients with symptoms of CHD has been associated with high perioperative morbidity and mortality in elderly patients, surviving patients appear to have substantial improvement of symptoms and quality of life and probably an improvement in survival (199, 201, 208). It should therefore be seriously considered in all patients with otherwise controllable disease, but significant cardiac impairment due to the valvular disease, who present reasonable operative risks.

q. Carcinoid fibrosis. In midgut carcinoid tumors, mesenteric metastases are common even with the smallest primary tumors (174). A larger size primary tumor may occasionally coalesce with lymph gland metastases in the mesentery that can grow further and are characterized by marked mesenteric fibrosis (174, 182, 208). This fibrosis, which can occasionally be extensive, probably results from the effects of growth factors and other substances released from the carcinoid metastases (209). The fibrosis causes shrinkage and fixation of the mesentery and mesenteric root to the retroperitoneum, such that fibrous bands may obstruct the duodenum and, occasionally, parts of the colon (174). This may cause partial or complete small bowel obstruction, although the primary tumor is not large enough to obstruct the intestinal lumen (174, 209). The mesenteric vessels may also become entrapped or occluded, with resulting venous stasis and ischemia and occasionally impairment of the arterial circulation (174). In terms of therapy, in such cases extensive surgical intervention and debulking of the tumor mass from the mesenteric root with preservation of the main intestinal vascular supply and important collaterals are required (174). This approach will generally allow more limited small intestinal resection, minimize the risk of further intestinal complications, and probably avoid a bypass procedure (174).

2. Biochemical diagnosis. In all three tumor subgroups, high levels of CgA, PP, and α/β -hCG subunit may be found (5, 6, 131, 178). High levels of α -subunit are often found in patients with hindgut and midgut carcinoid tumors, whereas both α - and β -subunits may be increased in midgut carcinoid patients (146). Patients with midgut carcinoid tumors have increased rates of serotonin production; elevated serotonin levels can be measured either in the plasma or as the serotonin metabolite 5-HIAA (52, 146). Determination of serotonin is associated with a poor specificity, due to significant variations over time, and thus 5-HIAA levels are usually measured instead (178). Measurement of urinary 5-HIAA levels is used for confirming the diagnosis and monitoring patients with metastatic disease; in such patients, elevated 24-h urinary 5-HIAA levels were associated with a 73% sensitivity and a 100% specificity in predicting the presence of a tumor (210). Patients with midgut carcinoids also exhibit increased tachykinin levels (neurokinin A and K) that can also be used for diagnosis and evaluation of responsiveness during treatment (211). Patients with foregut carcinoid tumors rarely secrete serotonin, and only the rare existence of CS justifies measurement of 5-HIAA (178). Patients with hindgut tumors rarely present with elevated levels of tumor markers, even in the presence of metastatic disease, and thus measurement of 5-HIAA or other hormones and peptides is mainly indicated in the presence of a hypersecretory syndrome (178).

Levels of serum CgA are raised in 80% of patients and also seem to correlate with tumor load and predict prognosis, particularly in patients with midgut carcinoids, because elevation of CgA levels can precede radiographic evidence of recurrence (52, 118, 146). Although the routine measurement of CgA has not been established as yet, it has been suggested that it should also be used in foregut carcinoids because CgA may be elevated in 93% of patients with metastatic pulmonary carcinoids and patients with gastric and thymic carcinoids (5, 161, 178). However, its low specificity makes it unreliable for the differential diagnosis of a lung tumor found on chest radiology (161). Using patients with metastatic carcinoid tumors and patients in remission, a cut-off discriminatory level of CgA has been suggested with a 92% sensitivity and a 96% specificity (212), whereas CgA was found to be more sensitive than either NSE or α -hCG when directly compared in the same group of patients (40). Although a recent study failed to confirm the same results of CgA measurement, this has been attributed to the methodology used (6, 51, 213). Increased CEA levels are a poor prognostic factor and raise the possibility of a tumor with adenocarcinoma differentiation (119). Determination of other hormones is recommended in the presence of a functional syndrome (178). In patients with the atypical CS, the diagnosis can be established by analysis of the main metabolite of histamine, methylimidazole acetic acid in the urine (10). Our current policy is to routinely measure CgA in all patients with carcinoid tumors and 5-HIAA levels in patients with midgut carcinoids, the CS, and/or liver metastases; measurement of other markers is performed in the presence of a relevant hypersecretory syndrome. The differential diagnosis of the CS is considerable and will include various types of inflammatory bowel disease, gut neoplasia, and

diverticular disease in older patients, and irritable bowel syndrome in younger patients. It should be emphasized that normal barium contrast studies of the bowel do not confirm the diagnosis of irritable bowel syndrome, and plasma CgA and/or urinary 5-HIAA levels are simple screening techniques.

3. Imaging carcinoid tumors and diagnostic workup. The determination of tumor extent (localization and metastases) as well as primary tumor location is an essential aspect of the management of carcinoid tumors because it facilitates possible resection, which remains the only treatment that can actually cure the patient, *i.e.*, remove all evidence of tumor with no recurrence (214, 215). Currently, ^{111}In -pentetate is used by many in the routine staging of GEP tumors to demonstrate diagnostic uptake and in the follow-up of such patients to detect regrowth or newly occurring metastases at an early stage, and we believe it should be used in all such cases; a negative scan in the presence of proven disease should alert the physician to the possibility of a poorly differentiated tumor (62, 69).

a. Foregut carcinoid tumors. Chest radiography may occasionally detect bronchial carcinoids, mainly as opacities with notched margins (62). However, thin-section CT and magnetic resonance imaging (MRI) allows greater resolution of bronchial carcinoids, identifies lymph node involvement, and can also facilitate tissue diagnosis with fine-needle aspiration cytology (178). Scintigraphy with ^{111}In -octreotide may identify previously unrecognized lesions, particularly in patients with the possibility of ACTH-dependent Cushing's syndrome, but may be negative in up to 30%, although a recent study suggested that the majority of such patients will eventually develop a positive scan (216–219). Although PET with FDG is usually of limited value in the diagnosis of bronchial carcinoids, PET with radiolabeled-5-HTP may be more useful in detecting occult bronchial carcinoid tumors (104, 105). Similarly, although chest radiography may demonstrate a thymic mass, CT and/or MRI is further required to evaluate the presence of metastases and plan surgery and may be more sensitive than scintigraphy with ^{111}In -octreotide (151, 152, 155, 220). Most GC are usually diagnosed on endoscopy or endosonography, because upper GI contrast studies are often nonspecific or fail to visualize the lesion (221). The investigation should be concluded by performing CT of the abdomen (178).

b. Midgut carcinoid tumors. In general, midgut carcinoid tumors, regardless of their functional state, are diagnosed when they have already metastasized (178, 222). Scintigraphy with ^{111}In -octreotide is extremely helpful and is used for staging and identification of the primary lesion (178, 222). SS scintigraphy has an 83% diagnostic accuracy and a positive predictive value of 100%, and can also identify lesions that are not seen by other imaging modalities; it is also very sensitive in identifying bone deposits from carcinoids (53, 118). The superiority of SS scintigraphy to other diagnostic modalities has been demonstrated by several recent studies (92, 223–225). Transabdominal ultrasound identifies approximately one third of small bowel carcinoids and two thirds of liver metastases (226), and may also be used to guide

percutaneous biopsies of liver tumors (227). CT and MRI are less sensitive than scintigraphy with ^{111}In -octreotide because they identify only approximately 50% of the primary tumors, although they are reliable methods for monitoring responsiveness to treatment (99, 118) (Figs. 3–6). For identification of the primary tumor, classic double-contrast barium GI studies (enteroclysis) are generally used, although recently CT-enteroclysis may offer diagnostic advantages (228, 229). Probably the most important reason to use this technique is to assess the possibility of imminent small bowel obstruction. However, approximately 40% of primary and metastatic tumors may not be visualized by the usual techniques (118).

c. Hindgut carcinoid tumors. Scintigraphy with ^{111}In -octreotide demonstrates the highest sensitivity, although hindgut carcinoids are more likely to have a negative scan than those arising from other sites (118, 178); in these cases, additional imaging with ^{123}I -MIBG has been suggested as an alternative (99, 222). Lower GI contrast studies have poor sensitivity and specificity for hindgut carcinoid tumors (118), but are more successful in localizing those in the cecum and ascending colon (230). Endoscopic ultrasound (EUS) has a 90% accuracy for localization and staging of colorectal carcinoids and can also identify local nodal involvement (231); MRI may be used as an alternative (118).

d. Carcinoids of unknown origin. In cases where the metastases are detected first, it may be of prognostic significance to try and identify the primary origin of the tumor in either the abdomen or chest or in unusual locations such as testes, ovaries, and breast (98, 194). Using radiological and/or nuclear imaging methods, the primary tumor was localized in 96 and 81% of cases of nonfunctioning and functioning NETs, respectively, in one series (232).

We currently perform scintigraphy with ^{111}In -octreotide in all of our patients with carcinoid tumors and use conventional imaging to clarify the exact morphology of the tumor and follow the response to treatment; in cases of a negative scan (particularly foregut carcinoid tumors), we use ^{123}I -MIBG. The latter radionuclide is also used as a guide to therapy (see Section VII.C). SPECT/CT hybrid imaging with

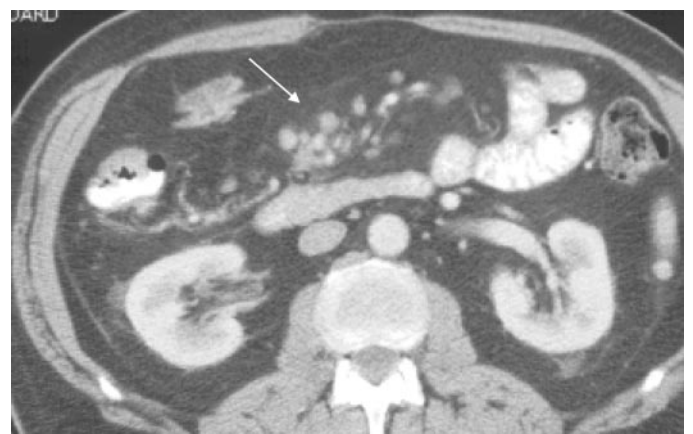


FIG. 3. CT scan of metastatic midgut NET demonstrating scattered malignant lymph nodes (*white arrow*). (Courtesy of Dr. A. G. Rockall and Dr. R. Reznek, Department of Radiology, St. Bartholomew's Hospital, London, UK.)

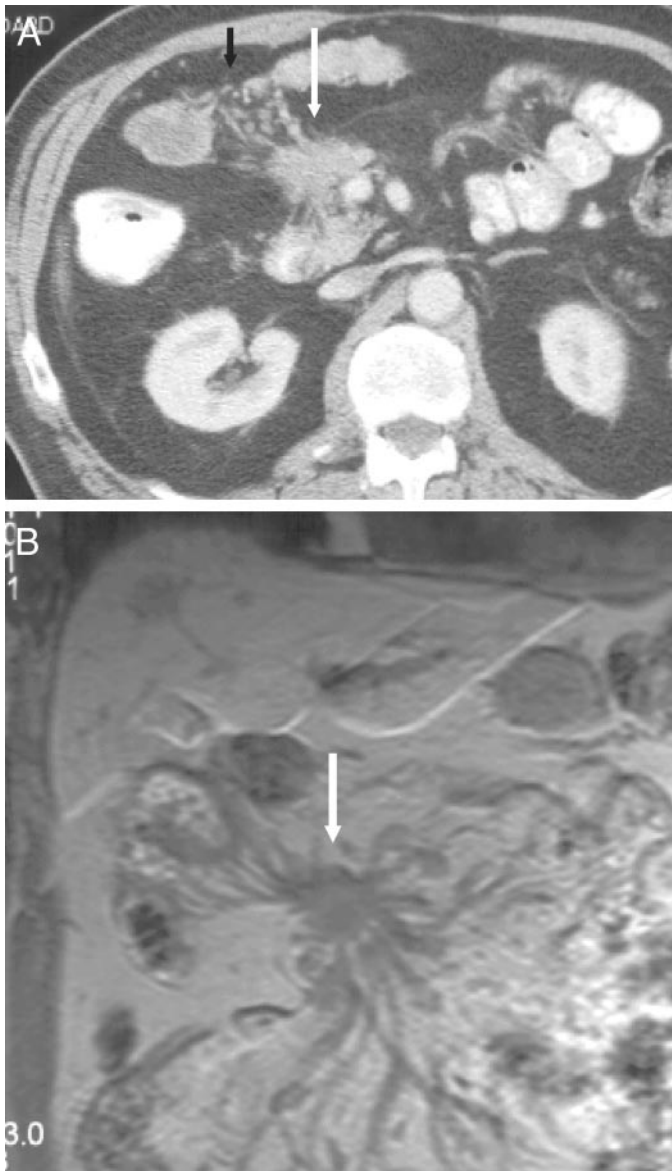

FIG. 4. CT (A) and MRI (B) scans of a metastatic NET arising from the midgut, demonstrating an extensive desmoplastic response binding the mesentery (*white arrows*). (Courtesy of Dr. A. G. Rockall and Dr. R. Reznick, Department of Radiology, St. Bartholomew's Hospital, London, UK.)

¹¹¹In-octreotide is used by some in the assessment of NETs (233). PET imaging is not routinely performed and is reserved only for patients in which all other imaging modalities are negative; however, we and others are currently evaluating the routine use of this form of imaging in all patients with carcinoid tumors.

4. Screening. Clinical examination to exclude NF1 and an extended family history should be taken in all patients with carcinoid tumors. Patients with sporadic or familial bronchial or GC should be evaluated for germline MEN I mutations; in the presence of a mutation, these cases should be treated as MEN I families. Management of MEN I families includes screening for parathyroid and enteropancreatic tumors from late childhood, with predictive testing of first-

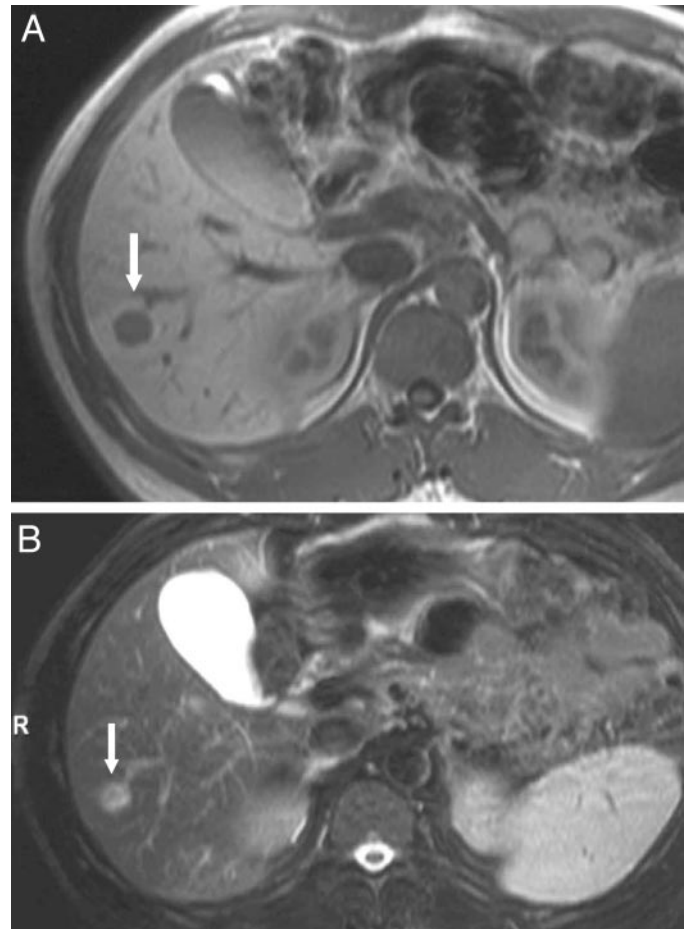


FIG. 5. A, T₁-weighted MRI of a hepatic metastasis (*white arrow*) in a patient with a metastatic NET. The lesion is hypodense compared to the surrounding liver parenchyma. B, T₂-weighted MRI in the same patient. Note that the lesion (*white arrow*) is now hyperintense (courtesy of Dr. A. G. Rockall and Dr. R. Reznick, Department of Radiology, St. Bartholomew's Hospital, London, UK).

degree relatives of known mutations. Patients with mid- and hindgut carcinoid tumors should be screened for another neoplasm (usually within the GI tract), particularly if they are males, in the presence of relevant family history and during the first year after initial diagnosis (129, 136). Counseling should be readily available in case of positive findings.

B. Islet cell tumors

A variety of clinical syndromes are found in patients with islet cell tumors, reflecting the potential of endocrine cells to secrete both peptides and amines (1, 234). However, about 20% of islet tumors secrete no detectable hormones and may remain clinically silent until detected at an unresectable stage with symptoms due to the mass effect of the tumor or metastatic disease (1, 234). The initial concern with islet cell tumors is an awareness of the multitude of clinical syndromes that they may cause (Table 2).

1. Clinical presentation and biochemical diagnosis

a. Insulinoma. Insulinomas account for 60% of islet cell tumors and are typically hypervascular, solitary small tu-

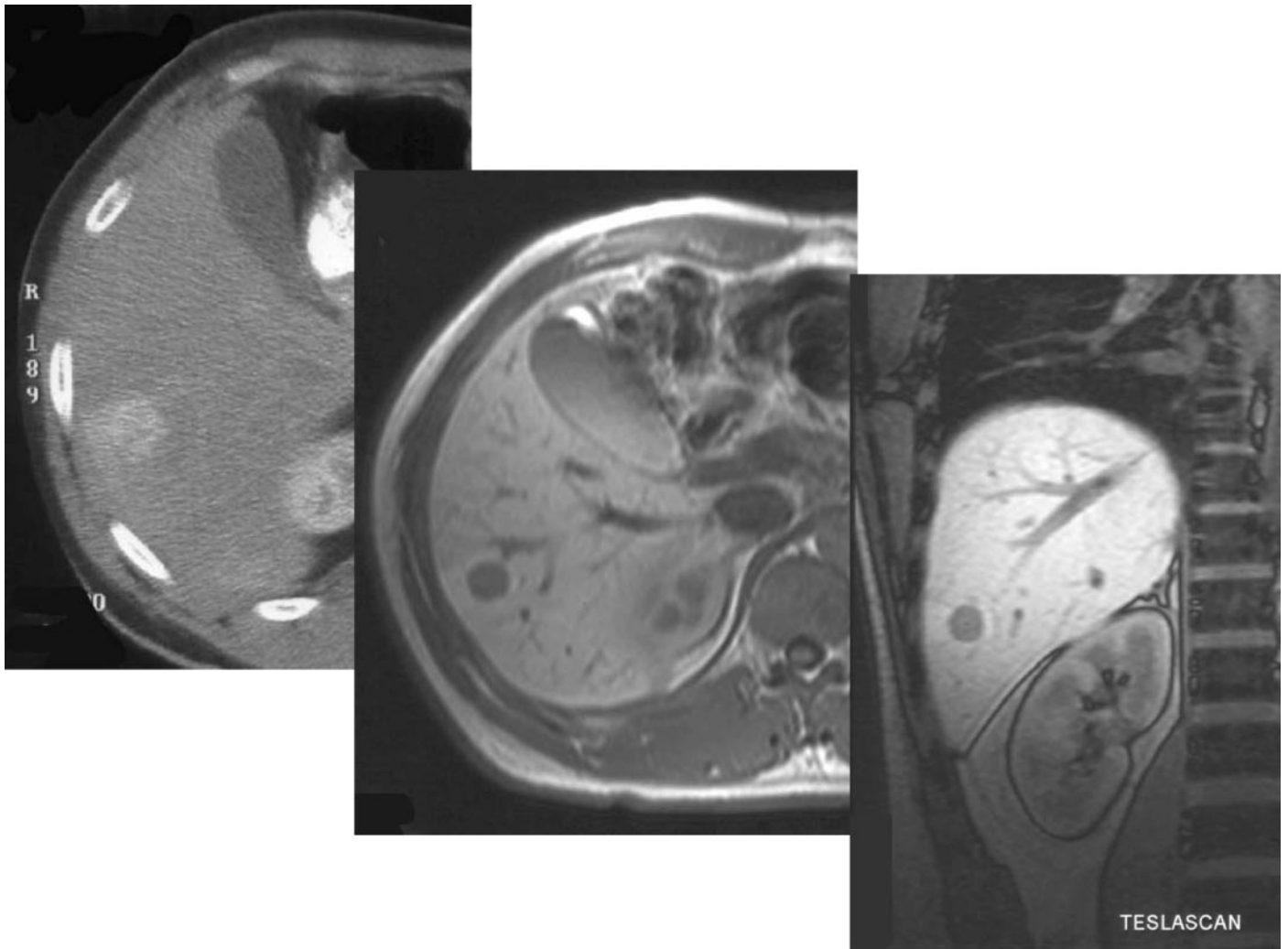


FIG. 6. A comparison of CT (axial; *left*), conventional (axial; *middle*), and post-mangafodipir (Teslascan) (coronal; *right*) MRI scans in a patient with hepatic metastases from a midgut NET. The hepatic metastasis shows enhancement after contrast enhancement in the CT scan and is slightly more evident as a hypointense lesion on the T₁-weighted MRI. However, after iv mangafodipir, note how the surrounding parenchymal tissue selectively concentrates the contrast medium, demarcating the metastasis with greater clarity (courtesy of Dr. A. G. Rockall and Dr. R. Reznek, Department of Radiology, St. Bartholomew's Hospital, London, UK).

mors, with 90% measuring less than 2 cm and 30% measuring less than 1 cm in diameter (1, 234–237). Approximately 10% are multiple, 10% are malignant, and 4–7% are associated with MEN I (236, 238, 239); these tumors are usually multiple and can be malignant in up to 25% of cases (240, 241). Almost all insulinomas are located within the pancreas, although aberrant cases have been described in the duodenum, ileum, lung, and cervix (139, 237, 242, 243).

The tumor is characterized by hypersecretion of insulin and the subsequent development of symptoms of neuroglycopenia and symptoms resulting from the catecholaminergic response, which may not always be present (236, 243, 244). Patients with neuroglycopenia may complain of headache, lethargy, dizziness, diplopia, blurred vision, and amnesia; rarely, hypoglycemia may result in seizures, coma, or permanent neurological deficit (236, 244). The catecholaminergic response is associated with tremor, anxiety, palpitations, nausea, hunger, and sweating (236, 245, 246). Hypoglycemic episodes occur early in the morning and may be triggered by

exercise (244). Because occasionally symptoms are not specific and insulinoma can mimic several pathological conditions, a broad differential diagnosis should be considered. More importantly, the diagnosis should be considered in any patients presenting with unexplained paroxysmal episodes, including those associated with abnormalities in behavior and/or seizures (242, 247).

The diagnosis of insulinoma is based on demonstrating Whipple's triad [symptoms of hypoglycemia, concomitant plasma glucose of <45 mg/dl (<2.2 mmol/liter), and relief of symptoms with sugar intake] (236, 245, 246). Fasting therefore is the major maneuver used in the diagnosis of insulinoma and has two important purposes: the first is to document hypoglycemia (glucose levels < 45 mg/dl), and the second is to demonstrate hypoglycemia-associated, inappropriate insulin (>6 μ U/ml or 30 pmol/liter) and C-peptide (>300 pmol/liter) concentrations. The absence of sulfonylurea or related drug in the plasma or urine should be sought in relevant cases (236, 244, 248). Exogenously administered

TABLE 2. GEP tumors: anatomical, clinical, and biochemical features

Site	Incidence (cases/10 ⁶)	Pathology	Peptide/amines	Clinical features	Metastases (%)	MEN I (%)
Foregut Bronchi, thymus, stomach, first part of duodenum, pancreas	2–5	Mixed growth pattern, argyrophilic (+)	5-HTP, histamine, ACTH, CRH, GH, gastrin, 5- HIAA (30%)	Pulmonary obstruction, atypical flush, and hormone syndromes	Liver, LMN, bone	10
Midgut Second duodenum, jejunum, ileum, right colon	4–10	Insular growth, argentaffin and argyrophilic (+)	5-HT, tachykinins, prostaglandins, bradykinins and others (70%), 5-HIAA (75%)	Bowel obstruction, typical pink/red flush, wheeze/ diarrhea (CS)	Liver (60–80), LMN metastases	
Hindgut Transverse colon to rectum	1.5–2.5	Trabecular/solid growth, argyrophilic (+)	Local production SS, peptide YY, ghrelin, neurotensin, 5-HTP, and other hormones Insulin, proinsulin	Incidental finding, local symptoms	Bone metastases (5–40)	
Insulinoma	1–2		Insulin, proinsulin	Neuroglucopenia, Whipple's triad	10	5–10
Gastrinoma	1–1.5		Gastrin	ZES (peptic ulcer, diarrhea, epigastric pain)	60–90	25
VIPoma	0.1		VIP	Watery diarrhea, hypokalemia, achlorhydria	50–80	10
Glucagonoma Somatostatinoma	0.01–0.1 <0.1		Glucagon SS	NME, DM, cachexia Gallstones, DM, steatorrhea, achlorhydria	80–90 60–70	5–17 5–10
Nonfunctioning tumors	1–2		PP	Symptoms related to mass effect	60–80	20–30
GRFoma ACTHoma	<0.1 <0.1		GRF ACTH	Acromegaly Cushing's syndrome	60–70 95	20 Rare

Argentaffin (+), Precipitation of silver salts in the absence of reducing agent; argyrophilic (+), precipitation of silver salts only in the presence of reducing agent; LMN, lymph node; DM, diabetes mellitus; GRF, GH-releasing factor (equivalent to GHRH). [Derived from Arnold *et al.* (59); Mignon (109); Soga and colleagues (138, 285, 290); Wermers *et al.* (277); Modlin and Sandor (126).]

insulin is associated with raised insulin plasma but low plasma C-peptide levels (236, 247, 249). Proinsulin levels have been shown to be of diagnostic value because more than 90% of patients with insulinomas have a plasma proinsulin component of at least 25% of the total immunoreactive insulin (247–250). When an insulinoma seems highly likely, the 72-h fast is considered as the investigation of choice (240, 248, 249). In most series, 30% of patients develop symptoms by 12 h into the fast, 80% within 24 h, and almost 100% at 72 h (240, 246). Normal subjects may lower their glucose levels below 45 mg/dl in 48 h, but the corresponding insulin levels should be very low or undetectable (240). More recently, it has been suggested that a 48-h fast may be as sensitive as the 72-h fast in demonstrating the presence of an insulinoma (248). Not all patients with insulinoma will develop diagnostically reduced glucose levels; in these cases, measuring insulin surrogates (β -hydroxybutyrate and the response of plasma glucose to iv glucagon at the end of the prolonged fast) can be valuable (240, 246, 247). Rarely, patients with insulinomas may suppress their insulin levels below 10 μ U/ml because their glucose levels fall at the end of the fast; however, these patients still have elevated proinsulin concentrations (240, 248, 251). Because of the reliability of the 72-h fast, provocative tests are only rarely used, and shorter fasts (such as three sets of 15-h fasts) are of lower reliability (242). Occasionally, it may be helpful to provide the patient or their partner with home glucose monitoring to assess blood glucose levels during an attack. When serum chromogranins are used as tumor markers, CgB should be measured instead of CgA because these tumors preferentially secrete CgB (39, 252). Selective intraarterial calcium gluconate injection into the various arteries supplying the pancreas and hepatic venous sampling [arterial stimulation venous sampling (ASVS)], with calcium acting as an insulin secretagogue, may be extremely helpful in the diagnosis and localization of these tumors (253, 254). The differential diagnosis of an insulinoma is large and will include a variety of cerebral and cardiac dysrhythmias (249). We generally include a 24-h electrocardiogram and an electroencephalogram in the diagnostic workup of such patients, except where the diagnosis of hypoglycemia is quickly confirmed. With confirmation of hypoglycemia as the cause of the attacks, certain rare metabolic syndromes may need to be considered, as well as factitious hypoglycemia and ectopic secretion of pro-IGF-II by certain tumors (Ref. 255; also see Ref. 256).

Only approximately 5–10% of insulinomas are truly malignant, presenting with similar clinical symptoms to patients with benign disease, namely symptoms of hypoglycemia (236, 242, 257). These tumors are usually single and large, averaging 6 cm in diameter with a median survival of 4 yr (240). Recently, patients with mainly postprandial hypoglycemia, noninsulinoma pancreatogenous hypoglycemia (NIPH), have been reported (258). These patients characteristically present with neuroglycopenic symptoms within 4 h of meal ingestion, have negative 72-h fasts, and harbor islet hypertrophy or nesidioblastosis rather than insulinomas (258). In contrast to NIPH, patients with nesidioblastosis develop fasting hypoglycemia within 8–14 h; however, nesidioblastosis *per se* constituted only 0.7% of the causes of endogenous hyperinsulinism in one big series (259). In both

of these entities, ASVS can be extremely helpful to differentiate this condition from the presence of an islet cell tumor (258), although the diagnosis usually requires histopathological verification. Successful excision of a benign lesion is associated with normal life expectancy (240), whereas a 10-yr survival of 29% has been described for malignant insulinomas (249).

b. Gastrinomas. Gastrinomas are gastrin-secreting tumors derived from either the duodenum or the pancreas, causing the ZES by producing hypergastrinemia, which results in hyperchlorhydria and gastric mucosal thickening (139). The majority occur in or near the head of the pancreas; less frequent sites are the small intestine and the stomach (162, 260). Gastrinomas, after insulinomas, are the second most frequent endocrine tumors of the pancreas that occur in either the sporadic form or in up to 25% in association with MEN I (139, 162). A duodenal localization is mainly associated with the MEN I syndrome when gastrinomas are usually small and frequently multifocal, and may therefore be difficult to detect either by traditional imaging methods or at surgery (139, 162). Although the majority of gastrinomas run a malignant course (162, 260, 261), neither their size nor their histological appearance accurately reflects their biological behavior (260, 262). Lymph node and liver metastasis is present in 70–80% at diagnosis, and bone metastases in 12% (139, 162). Previous studies have shown that after the excision of lymphoid tissue containing gastrinoma there was cure of the disease, implicating the presence of primary gastrinoma in lymph nodes; even more rarely, ovarian and heart tumors that release gastrin have been described (94, 162, 260, 261, 263).

Except for the symptoms due to the effects of widespread metastases, the clinical manifestations of the ZES are due almost entirely to the effects of elevated gastrin levels and hypersecretion of gastric acid (162, 260). In a recent review of 261 patients, the mean age at presentation was 41 yr, and there was a 5.2-yr delay between the onset of the symptoms and the time of diagnosis (264). Ulceration of the upper GI mucosa develops in more than 90% of patients; less frequent sites are the distal duodenum or the jejunum (139, 162, 260, 264). Esophageal involvement is increasingly recognized, occurring in 10–60% of patients, and includes heartburn and dysphagia due to gastroesophageal reflux and its complications (162, 264). Diarrhea is the second most common symptom, developing in 50–65% of patients, and it can precede, accompany, or follow the ulcerous disease; in 7–35%, it may be the only initial symptom (162, 260). Cushing's syndrome occurs with an incidence of 6% in sporadic gastrinomas, mainly due to ectopic ACTH production, and is usually severe and associated with a worse prognosis (265). Coexisting pheochromocytomas have also been described rarely in patients with the ZES (266). Duodenal gastrinomas comprise 60% of all duodenal NETs and are located in the first and second portion of the duodenum (160). They are frequently small (<1 cm) and thus difficult to detect, but can metastasize to regional lymph nodes in 30–70% of patients (160, 162). Approximately 40% of gastrinomas are located within the duodenal submucosa, and in MEN I patients with ZES this prevalence may reach 90% (160). Patients with ZES

and MEN I are clinically different from patients with the sporadic form of the disease in that they characteristically present at an earlier age, and although the gastrinoma can be the presenting lesion, most patients have hyperparathyroidism or pituitary disease at the time of presentation of the ZES (162, 267). Duodenal and pancreatic gastrinomas differ both in biological behavior and their cells of origin (268). Approximately 25% of gastrinomas are associated with MEN-I, and 19% of them can also have mild Cushing's syndrome secondary to a pituitary tumor secreting ACTH (162, 260, 265). In patients associated with MEN I, the trophic effects of prolonged hypergastrinemia on ECL cells lead to the formation of GC, mainly involving the body and fundus of the stomach; these cases demonstrate loss of heterozygosity on chromosome 11q13 (162). Patients with MEN I have a 20–30 fold higher chance of developing an ECLoma than patients with the sporadic form (269).

One should always consider the presence of ZES in cases of an unusual ulcer location or ulcers refractory to treatment, unexplained diarrhea and weight loss, and prominent gastric folds at endoscopy. The basic investigations for establishing the diagnosis of ZES are a fasting serum gastrin concentration, the secretin stimulation test, and gastric secretion studies. Measurement of serum gastrin is not interpretable in the presence of drugs that inhibit gastric acid output. Although an occasional patient with the ZES may have normal serum gastrin levels, the great majority (>90%) do have fasting hypergastrinemia and a gastric fluid pH lower than 2.5 (162, 260). A serum gastrin level of 1000 pg/ml or greater is diagnostic of ZES as long as the patient is normocalcemic and free of pyloric obstruction, has normal renal function, and secretes gastric acid (270). However, many patients with gastrinomas may have nondiagnostic serum gastrin levels (260, 270). In such cases, a gastric analysis and a secretin provocative test may be performed to establish the correct diagnosis (162, 260). Two units per kilogram of secretin are given iv, and serum gastrin is measured before and 2, 5, 10, and 20 min afterward; a positive response is considered an increase of at least 200 pg/ml in serum gastrin and is found in 87% of patients (271, 272). Approximately 30% of those with an equivocal secretin test will have a positive calcium infusion test (272). Gastric acid perfusion studies are rarely used (273). α - and β -Subunits of hCG are elevated in 30–40% of patients; however, their association with malignancy is not fully established (40, 50). Prominent gastric folds are apparent in 94% of patients at endoscopy (264). When measuring serum gastrin, we stop H₂-antagonists for a minimum of 1 wk and proton pump inhibitors for at least 3 wk. The presence of liver metastases at the time of diagnosis is the most important determinant of survival, mostly found in patients with pancreatic rather than duodenal lesions; the incidence of lymph node metastases is similar in patients with duodenal and pancreatic gastrinomas but does not exert a significant influence on survival (268, 274). Approximately 25% of patients with ZES follow an aggressive course with development of liver metastases and an overall 10-yr survival of 30% (268). The overall survival of MEN I-related gastrinomas is similar to the sporadic form and is largely determined by the presence of liver metastases (20, 275).

c. Glucagonoma. Glucagonomas are rare slow-growing tumors arising from the pancreatic α -cells, commonly associated with a characteristic syndrome as the result of excessive secretion of glucagon and other peptides (276). The majority of cases are sporadic, but between 5 and 17% are associated with MEN I or, rarely, familial adenomatous polyposis (276–278). However, glucagonomas may be more common because autopsy series have demonstrated 0.8% occurrence rates of microglucagonomas in adult-onset diabetics (278, 279). Patients with the sporadic disease present in their fifth decade of life with lesions mainly located in the tail of the pancreas, whereas patients with MEN I present at the younger age of 33 yr (277, 280). Glucagonomas can be as large as 6 cm, are highly malignant, and over 80% of the sporadic tumors have documented mainly hepatic metastases at diagnosis (277–279, 281).

The most common symptoms are weight loss (70–80%), rash (65–80%), diabetes (75%), cheilosis or stomatitis (30–40%), and diarrhea (15–30%), the most characteristic being the rash, necrolytic migratory erythema (NME) (277–279, 281). This dermatitis-looking lesion typically evolves over 7–14 d, beginning as small erythematous lesions in the groin and extending to the perineum, lower extremities, and perioral regions (276, 277). These areas then blister, and central erosions develop in the epidermis, followed by secondary infection with *Candida albicans* and *Staphylococcus aureus* (278, 282). There are only a few sporadic reports of patients with glucagonomas who never develop NME (277, 278). Other dermatological manifestations of glucagonoma are dystrophic nails, angular cheilitis, atrophic glossitis, and buccal mucosal inflammation (277, 282). Fatty acid, zinc, and amino acid deficiency and hepatic impairment have been implicated as causes of NME, but the exact etiology is unknown; serum glucagon levels do not correlate with the presence or the severity of the rash (276–278). Diabetes may precede the NME by several years, but NME can occur alone (283). Once the combination of NME and diabetes develops, the diagnosis of glucagonoma is usually made rapidly (276–278). Other common manifestations are psychiatric disorders and an increased incidence of thromboembolism (\leq 30%), manifest as deep venous thrombosis and pulmonary embolism (276–278).

Patients with glucagonomas often develop a normochromic normocytic anemia and hypoalbuminemia, hypocholesterolemia, and hypoaminoacidemia (277). The diagnosis is based on clinical suspicion and the demonstration of raised fasting plasma glucagon levels (>50 pmol/liter) in the presence of a pancreatic tumor (278). Fasting plasma glucagon levels may be elevated to between 1.5 and 150 times the upper limit of normal (276, 278). It is therefore important to maintain a high index of suspicion in patients with clinical features suggestive of a glucagonoma, but in whom only marginally elevated glucagon levels are found, especially when a glucagonoma is suspected in a patient with MEN I at an earlier stage as a result of screening (276). Approximately 20–40% of patients with glucagonomas may also have raised fasting gastrin levels and VIP levels; these may be associated with secondary endocrine syndromes, particularly ZES, and warrant further follow-up (276–278). Patients without established metastases have a good outcome

after surgery alone, with an over 85% survival rate at a mean follow-up of 4.7 yr, whereas this rate falls to 60% in patients with malignant disease (276–278). Thromboembolic events may account for over 50% of all deaths directly attributed to the glucagonoma syndrome (Ref. 280; also see Ref. 284).

d. VIPoma. Most VIPomas are sporadic, and approximately 70–80% originate from the pancreas, mostly from the pancreatic tail (139, 285). Other, less common sites of origin are the adrenal, retroperitoneum, mediastinum, lung, and jejunum (285, 286). Primary tumors are usually large, greater than 2 cm, and 50–60% of pancreatic VIPomas have already developed metastases, mainly to the liver and lymph nodes, at the time of diagnosis (285). VIPomas can also be of neural origin (10–12%), mostly in children as ganglioneuromas, ganglioblastomas, or neuroblastomas (139, 287). In contrast to pancreatic VIPomas, in neurogenic VIPomas the presence of metastases is much less common (29%) and mainly involves the lymph nodes (285). Occasionally carcinoid tumors, pheochromocytomas, and bronchogenic carcinomas may be associated with VIP secretion (287). VIPomas can be multifocal in 4%, and in 8.7% there is an association with MEN I (285).

Severe watery diarrhea is a universal symptom of the syndrome (285, 286). The diarrhea is secretory in nature, typically unremitting with fasting, intermittent in 53%, and continuous in 47% of cases (139). When the diarrhea is intermittent, there is usually a delay in making the diagnosis (286). Patients typically produce more than 3 liters of watery stool per day with a range up to 30 liters/d. Chronic diarrhea is associated with severe fluid and electrolyte (mainly potassium and bicarbonate) loss with subsequent marked asthenia, cramps leading to tetany and cardiac alterations, and even sudden death (139). Hypokalemia is often severe ($K^+ < 2.5$ mEq/liter, losses > 400 mEq/d), paradoxically associated with low bicarbonate levels due to severe intestinal loss; this results in severe hyperchloremic acidosis (286). Hypophosphatemia and hypomagnesemia are also apparent, although a number of patients have associated hypercalcemia (285). Other symptoms include carbohydrate intolerance (50%) and facial flushing in up to 20% of patients, secondary to a direct vasodilatory action of VIP (285, 287). Achlorhydria or hypochlorhydria is present in over two thirds of the patients (285). The diagnosis is based on the presence of secretory diarrhea in association with raised fasting VIP levels in the presence of a pancreatic or other lesion associated with VIP production (285). In the early stages of the disease or in the presence of intermittent symptoms, random VIP levels may be normal (288). In these instances the diagnosis is obtained when VIP measurements are performed in the presence of diarrhea; in addition, other endocrine causes of secretory diarrhea, such as the CS, gastrinoma and MTC, or laxative abuse, should be considered (Ref. 286; also see Ref. 289).

e. Somatostatinoma. Somatostatinomas are rare tumors of either the pancreas or the small intestine, mainly the duodenum, with an estimated incidence of one in 40 million per year; approximately 200 cases have been reported according to a recent review (290). SS exerts a general inhibitory function on exocrine and endocrine secretions and bowel motility,

which is shown as suppression of hormonal secretion and bowel-related functions (transit, motility, and absorption), a so-called inhibitory syndrome (139, 290). In contrast to other functional pancreatic tumors, somatostatinomas are characterized by a relatively low incidence of a hypersecretory syndrome and association with the MEN I syndrome, whereas they are more commonly associated with NF1 and pheochromocytomas, suggestive of an inherited endocrinopathy (139, 290).

Pancreatic somatostatinomas are usually large (85.5% greater than 2 cm; average diameter, 5.1 cm) and associated with local symptoms and/or symptoms of excessive SS secretion; commonly, these tumors may demonstrate features of multisecretory activity (33.3%) (290). Symptoms related to SS hypersecretion are found in approximately 11% of patients with somatostatinomas: hyperglycemia (95%), cholelithiasis (68%), diarrhea (60%), steatorrhea (47%), and hypochlorhydria (26%) (290). Abdominal pain, weight loss, and anemia are nonspecific symptoms most probably related to the size of the tumor and its malignant potential (290, 291). These tumors, when not specifically looked for, are usually found late between the fifth and sixth decades of life, either at the time of exploratory laparotomy or during various imaging studies (290, 291).

The majority of extrapancreatic somatostatinomas are found in the duodenum but can also occur in the jejunum, cystic duct, colon, and rectum (290–292). Their presenting features are mostly related to local effects of the mass rather than the systemic effects of SS, whereas the majority are diagnosed serendipitously during endoscopic procedures (290, 292). Most duodenal tumors are located near the ampulla of Vater and may be associated with obstruction of the bile duct (39%), pancreatitis, and GI bleeding (292). These tumors usually are not associated with a secretory syndrome (2.5% compared with 18.5% of pancreatic tumors), although diabetes and cholelithiasis have occasionally been described (292, 293). Duodenal somatostatinomas tend to be smaller (58.6% smaller than 2 cm), with psammoma bodies and multisecretory activity when they are associated with von Recklinghausen disease in 43.2% (290). The diagnosis is established by demonstrating elevated SS levels in a patient with a relevant history and the presence of a pancreatic mass; duodenal somatostatinomas may not be associated with abnormal SS levels or secrete abnormally high molecular weight forms of SS (294). In a review of 173 cases reported in the literature (290), no statistically significant difference in the rate of metastases and malignancy was detected between pancreatic and extrapancreatic tumors. The overall 5-yr survival rate is 75%, or 60% when metastases are present (Ref. 290; also see Ref. 295).

f. Rare forms of islet cell tumors. Other rare tumors have also been reported (109). Most prevalent among them are ACTHomas (~110 cases reported), GRFomas that can be associated with acromegaly (~50 cases), neurotensinomas (~50 cases), and parathyrimomas (~35 cases) (109). Very rarely, pancreatic tumors secreting calcitonin, enteroglucagon, CCK, gastric inhibitory peptide, LH, gastrin-releasing peptide (GRP), and ghrelin have also been described (109, 296, 297). Rare forms of islet cell tumors may raise diagnostic

difficulties due to their multiple and occasionally fluctuating hormonal production and release (109).

g. Nonfunctioning tumors and PPomas. These tumors account for about 20% of all endocrine pancreatic tumors and are not associated with clinical syndromes caused by hormonal hypersecretion (298). They are most often diagnosed in the fifth to sixth decades of life and are mainly situated in the pancreas rather than the duodenum (139, 298–300). Their clinical silence may be related to inactive hormonal production, cosecretion of peptide inhibitors, or down-regulation of peripheral receptors (139, 301). These tumors are usually large and are diagnosed either as incidental findings or by symptoms caused by an expanding mass or metastases because approximately two thirds are truly malignant; except when associated with MEN I in approximately 20–30% of cases, nonfunctioning pancreatic tumors are generally unifocal (178, 299, 300, 302). Histologically, they demonstrate positive immunohistochemistry for insulin (50%), PP (40%), glucagon (30%), or SS (13%) (139, 301). Recently, it has been shown that two subgroups of nonfunctioning tumors exist, each accounting for 50% of cases; one shows a large number of chromosomal derangements, which are a strong independent adverse prognostic factor, whereas the other lacks any (188, 303). Overall 5- and 10-yr survival rates of 65 and 49%, respectively, have been described (299, 300, 302). Although tumors derived from PP cells are clinically silent, there are rare exceptions of PPomas associated with diarrhea, diabetes mellitus, and weight loss; 55 of such cases have been described (109). Because the majority of these tumors are clinically silent, differentiation from the more aggressive pancreatic adenocarcinomas should always be considered. Lack of tumor hypervascularization with resulting contrast enhancement on CT scanning and negative scintigraphy with ¹¹¹In-octreotide are more in favor of adenocarcinomas (304). Histopathology is usually diagnostic, but in cases of doubt specialist pathological advice should be sought. It should be noted that pancreatic adenocarcinomas may occasionally have NE elements intermingled with more typical adenocarcinoma cells (see *Section II*).

h. Pancreatic islet cell tumors in MEN I. The prevalence of enteropancreatic tumors in MEN I varies from 30–75% and approaches 80% in necropsy series (20, 275). These tumors can be found in any part of the pancreas or at the duodenum; they are multicentric, benign or malignant, micro- or macroadenomas, and less often present as hyperplastic lesions (20, 305). Although patients usually present with hormonal symptoms by the age of 40 yr, they can be diagnosed earlier during screening of individuals at risk; however, malignancy (although it may be present in an occult form) rarely presents before the age of 30 yr (20, 275). These tumors display a variety of elevated tumor markers that can change with time (275) but cannot reliably identify the patients at risk for the development or progression of malignant disease (20). Gastrinomas, followed by insulinomas, are the most common functioning pancreatic islet cell tumors related to MEN I, and approximately 50% may have metastasized before diagnosis (20, 305, 306). However, in younger patients, an insulinoma may be more frequently seen. Pancreatic primary lesions, the

presence of metastases or ectopic Cushing's syndrome, and the height of gastrin level are correlates of a poor prognosis (20, 305, 306). Nonfunctioning tumors occur in virtually all patients who have had adequate screening; at the time of the onset of symptoms, half of the patients have malignant disease (307). Early tumor recognition depends on biochemical screening; however, there is a wide variation of investigations that may be performed (20). Measurement of gastrin, insulin/proinsulin, PP, glucagon, and CgA is associated with a sensitivity of approximately 70%; this can be further increased with α - and β -hCG subunits and VIP and measurement of gastrin and PP after a meal stimulation test (20, 275, 308, 309). It has been shown that lesion size is not a useful indicator of malignant transformation, although patients with larger tumors are more likely to harbor liver metastases; furthermore, survival in ZES patients with MEN-I is closely similar to survival in sporadic cases, suggesting that the malignant potential is the most important cause of death-related disease (113, 275). Therefore, it has been suggested that early surgical resection may reduce the risk for malignant progression and future dissemination (307, 310). Patients with MEN I should always be investigated for the presence of a thymic carcinoid (155).

2. Imaging islet cell tumors. Recently, several prospective studies have investigated the relative utility of currently available techniques and helped to establish a diagnostic work-up on evidence-based information (93, 105, 178, 222, 224, 311–314). Because of its high sensitivity and its ability to obtain whole body images, we consider that scintigraphy with ¹¹¹In-octreotide is the initial imaging procedure of choice for GEP tumors; however, conventional noninvasive and occasionally invasive diagnostic modalities may still be required (6, 118, 162).

a. Radionuclear imaging. Several studies, including some prospective ones, have shown that ¹¹¹In-octreotide is more sensitive than any other single conventional method used to localize a gastrinoma or identify hepatic metastases (93, 223, 224, 315–318), although even this may still miss up to 30% of gastrinomas ultimately detected on surgical exploration (53, 93, 162, 316). In another prospective study, ¹¹¹In-octreotide altered the management in many patients with gastrinomas by successfully locating the primary tumor and clarifying equivocal localization results obtained by other imaging modalities (224). The ability of all conventional imaging modalities to visualize primary lesions is limited when the tumor size is less than 1 cm, and they will thus miss many duodenal gastrinomas (162, 268). Scintigraphy with ¹¹¹In-octreotide detects 30–75% of gastrinomas measuring less than 1.1 cm, primarily small duodenal gastrinomas, and almost all that are larger than 2 cm (316, 317). A negative scan in the presence of a visible tumor suggests either a poorly differentiated NET or a pancreatic adenocarcinoma (304). Imaging with ¹²³I-MIBG has a poor sensitivity in identifying islet cell tumors and should not generally be used in cases with negative ¹¹¹In-octreotide scintigraphy (99). PET using ¹¹C-5-HTP, due to selective uptake in tumor tissue compared with surrounding tissue, produces very good tumor visibility; it can be used for the examination of both the thorax and abdomen and has been shown on several occasions to be

superior to scintigraphy with ^{111}In -octreotide (104). However, the lack of general availability and the high cost limit its extensive use (104, 319). Intraoperative radionuclear imaging can be used to help define the exact location of a biochemically proven NET and aid in its complete resection (319).

b. Ultrasonography. Transabdominal ultrasound exhibits a detection rate for insulinomas and gastrinomas between 25–70% and 30%, respectively (240, 313, 320, 321). Detection rates are better for lesions greater than 3 cm in diameter and are relatively poor for lesions smaller than 1 cm; however, these rates may improve considerably with the application of modern high-resolution real-time ultrasound (313, 321).

EUS allows the positioning of a high-frequency (7.5–10 MHz) transducer in close proximity to the pancreas (313). Lesions as small as 5 mm and gastrinomas located in the bowel can be detected with this technique (322). Although there is a potential “blind-spot” at the splenic hilum, sensitivities as high as 79–82% have been obtained (235, 239, 240, 322, 323). A recent single-center prospective study revealed a sensitivity of 93% and a specificity of 95% in the localization of intrapancreatic lesions (324); EUS detected all tumors visualized by any other conventional technique (excluding scintigraphy with ^{111}In -octreotide), calling into question the necessity for these other imaging modalities (162, 325). EUS can identify approximately half of these tumors and, in combination with ^{111}In -octreotide, up to 69%, although it may still miss up to 50% of duodenal gastrinomas (162, 326). Particularly for gastrinomas, a negative EUS of the pancreas invariably predicted an extrapancreatic location (324).

Intraoperative ultrasound (IOUS) also allows direct high-resolution examination of the pancreas (313); the combination of IOUS and surgical palpation has led to 97% cure rates in patients with benign insulinomas (240). The overall sensitivity for gastrinomas is 83%, with 100% of intrapancreatic and 58% of extrapancreatic lesions detected in a large series (162). Although IOUS does not substitute for preoperative localization of islet cell tumors, it facilitates surgical resection and, in patients with MEN I, can help define the appropriate plane of resection by identifying multiple small tumors (313).

c. CT and MRI. The majority of islet cell tumors are isodense on unenhanced CT and will not be seen without iv contrast enhancement, appearing then as hypervascular lesions (93, 235, 313). Dual-face helical CT scan allows multiphase imaging during a single bolus of contrast administration and can achieve sensitivities in the range 82–92% (320, 327, 328). Reviewing most recently published series using T_1 -weighted fat suppression images, MRI identified 71 of 78 lesions, a 91% sensitivity in 57 islet cell tumors (311, 312, 329, 330). A comparative study showed that the sensitivity of T_1 -weighted MRI is equivalent to delayed dynamic CT (311). MRI is considered the most sensitive technique for demonstrating liver and bone metastases in patients with NETs and is recommended for precise monitoring of response to therapy (331).

d. Invasive imaging techniques. In cases of small insulinomas not detected with the previously mentioned imaging modalities, invasive procedures may still be necessary to achieve preoperative localization (332). Sensitivities between

77 and 100% have been described for transhepatic portal venous sampling, but this technique is associated with a not inconsiderable morbidity (332, 333). Selective arterial calcium stimulation and hepatic venous sampling (ASVS) using calcium as the insulin secretagogue is a powerful tool for the preoperative localization of occult insulinomas and can also help distinguish the rare forms of NIPHS (240, 247, 249, 254, 257). In particular, it allows for correlation of anatomical imaging abnormalities with functional changes and is particularly helpful in MEN I when several anatomical changes may be identified and it is vital to know which are functionally relevant. After successful catheterization of gastroduodenal (supplying the head of the pancreas and uncinate process), superior mesenteric (supplying the body and tail), splenic (tail of pancreas), and hepatic (supplying the liver) arteries, a greater than 2-fold rise in insulin is required to localize an insulin-secreting tumor in the portion of the pancreas supplied by the artery studied (253). In a recent series of 11 patients, a sensitivity of 100% was obtained with this technique, which may also identify rare extrapancreatic insulin-secreting NETs, mainly of the liver (93, 332). Hepatic venous sampling after selective injection of secretin is a more sensitive study than portal venous sampling in localizing extrapancreatic and duodenal gastrinomas (334), but will probably now be replaced by calcium stimulation.

3. Diagnostic protocols. Because of its sensitivity and high specificity, its ability to alter management and image all areas of the body at once, we consider that the initial investigation of choice for the diagnosis of functional (except insulinomas) and nonfunctional endocrine pancreatic tumors should be scintigraphy with ^{111}In -octreotide (53, 89, 99, 178, 222–224). When a gastrinoma is suspected, endoscopy or EUS should also be performed to identify duodenal as well as pancreatic gastrinomas, especially when multiple lesions are suspected as in MEN I (139, 162). In patients with positive ^{111}In -octreotide scintigraphy, further imaging may be applied to delineate the exact anatomic margins of the tumor and local spread of the disease (178, 222). CT and MRI are also very sensitive and specific methods in demonstrating hepatic metastases and pancreatic tumors, and they show specific advantages in routine tumor staging and monitoring of therapy (178, 222, 223). EUS is the most sensitive method for the precise delineation of pancreatic lesions (317, 326). For MEN I patients with positive scintigraphy with ^{111}In -octreotide, further investigation for other associated lesions is warranted (222, 335). Because fewer than 60% of insulinomas express SS receptors and the great majority are located in the pancreas, endoscopic ultrasonography is regarded as the most sensitive method for tumor (324, 336) localization; helical CT and MRI may also be helpful (325). However, scintigraphy with ^{111}In -octreotide may also be needed in cases of malignant insulinomas because these tumors more often demonstrate SS receptors (222). When scintigraphy with ^{111}In octreotide is negative, areas within a high prevalence of metastases should be investigated (222). Currently, the intraarterial calcium stimulation test remains the only invasive functional study in frequent use: it may help recognize sporadic or MEN I-related occult tumors, it aids in the correlation of anatomic abnormalities with functionality, and it

facilitates the differential diagnosis from NIPH (247, 333, 337).

C. Chromaffin cell tumors (pheochromocytomas and paragangliomas)

Pheochromocytomas and paragangliomas are NETs arising from chromaffin cells that can occur in either sporadic or familial forms. Pheochromocytomas are chromaffin cell tumors arising from the adrenal medulla (338, 339). Paragangliomas are chromaffin cell tumors derived from the paraganglia that can be of either sympathetic (localized mainly in the retroperitoneum and thorax) or parasympathetic origin (occurring adjacent to the aortic arch, neck, and skull base); approximately 5% of head and neck paragangliomas and 50% of abdominal paragangliomas are hormone-producing (340). Pheochromocytomas occur with an estimated incidence of one to eight cases per million per year; they represent 0.5% of patients tested for hypertension and suggestive symptoms and 4% of patients presenting with adrenal incidentalomas (115, 341–343). However, the incidence of pheochromocytomas increases continuously with advancing age, although a significant number (>50%) are first diagnosed at autopsy, a prevalence of pheochromocytoma of about 0.1%, having escaped diagnosis in life (342, 344).

Chromaffin cell tumors generally obey the rough rule of 10: about 10% are malignant, 10% are familial, 10% are not associated with hypertension, 10% are extraadrenal, 10% are bilateral, and 10% occur in children (344–346). However, with more extended follow-up, the application of sensitive biochemical tests, and scintigraphy with MIBG, it has been established that the number of malignant chromaffin cell tumors is probably higher, ranging from 13–26% (347–350). In addition, using genetic analysis, it has been suggested that the incidence of patients with familial disease may also be higher than previously considered (21). Bilateral or multifocal chromaffin cell tumors are found most frequently in familial syndromes, either as an isolated trait with an autosomal mode of inheritance or in association with other tumors in the autosomal dominant MEN syndromes (351). In the MEN IIA and MEN IIB syndromes, there is a roughly 30–50% prevalence of pheochromocytomas and chromaffin cell tumors (352, 353). There is also an association of pheochromocytomas with the VHL syndrome (15–20%), NF1 (1–5%), and possibly also with Carney's syndrome (344, 354). The catecholamines (epinephrine, norepinephrine, and dopamine), widely distributed biogenic amines, are the main secretory products of chromaffin cells (115). Patients with chromaffin cell tumors present with a diversity of symptoms that have been attributed to the catecholamine release as well as to a variety of cosecreted active metabolic substances (115, 342). Pheochromocytomas primarily secrete norepinephrine and sometimes epinephrine; however, dopamine-secreting and nonfunctioning pheochromocytomas have also been described (355). The only definite criterion to ascertain malignancy is the presence of metastases at sites where chromaffin tissue is normally absent; the most common metastatic sites are the skeleton (>50%), liver (50%), and lung (30%) (Refs. 111, 115, 344, and 355; also see Refs. 342, 343, and 356).

1. Clinical presentation and biochemical diagnosis. Many patients with a functioning chromaffin-secreting tumor present with the classic triad of episodic headache, palpitations, and profuse sweating (111, 357). Hypertension is the foremost clinical manifestation and presents either as sustained, with or without paroxysms, or paroxysmal hypertension with intervening normotension (111, 357). The presence of hypertension with the classic triad of symptoms should suggest the diagnosis of a catecholamine-secreting tumor (115, 355). Other common but less characteristic clinical symptoms and signs include tremor, nervousness and anxiety, weakness, nausea, vomiting, flushing, paresthesia, constipation, weight loss, fever, and chest or abdominal pain (357). However, a considerable number of chromaffin cell tumors may be asymptomatic with a normal blood pressure and may be diagnosed either at autopsy or while investigating an incidentally discovered adrenal mass (358). Attacks can occur spontaneously or be precipitated by exercise, increases of intraabdominal pressure, medication, or general anesthesia (115, 355). The pressor crises are associated with a significant morbidity and occasionally mortality (359). In a proportion of patients, cardiac manifestations predominate, with chest pain, angina pectoris, myocardial infarction, and myocarditis (Ref. 344; also see Ref. 342).

The diagnosis is usually established with the documentation of high catecholamine levels. In the past, this was sought through the measurement of elevated urinary catecholamine metabolites, vanillyl mandelic acid, and metanephrines. Vanillyl mandelic acid measurement has a sensitivity of only 63% but can be useful in detecting large tumors with abnormal catecholamine metabolism such as neuroblastomas or malignant chromaffin cell tumors (360, 361). Urinary metanephrine excretion has a higher sensitivity and specificity (76 and 94%, respectively), but measurement of urinary free catecholamines offers more than 90% sensitivity, although with some loss in specificity, and is currently widely used (360). Adjustments have to be made with respect to renal function; multiple urine collections have to be undertaken, particularly if the patient is suffering from intermittent symptoms (344, 360). Elevated plasma catecholamines have a sensitivity of 85% and a specificity ranging from 80–95%, according to the threshold taken, whereas CgA has been reported to exert a sensitivity of 83% with an acceptable specificity for the diagnosis of a chromaffin cell tumor (344, 360, 361). The combination of urinary free catecholamines and metanephrines usually suffices to diagnose most patients (355, 357), although the combination of resting plasma catecholamines and total urinary metanephrines gives a false negative rate of 2.7% (115). Recently, measurement of plasma metanephrines was claimed to offer a 99% sensitivity in detecting a secretory chromaffin cell tumor, and it is also associated with the highest sensitivity at 100% specificity in reaching such a diagnosis (360), although this is not universally accepted (342, 343). The catecholamine response to the combination of glucagon stimulation and clonidine suppression tests that have been used to increase the sensitivity in the presence of equivocal results are currently used very seldom (115, 342, 360). A number of hormones have been described in patients with functioning catecholamine-secreting tumors. Secretion of ACTH is associated with

Cushing's syndrome; substance P, tachykinins, and histamine with hypotension; VIP and calcitonin gene-related peptide (CGRP) with flushing; and opioids with constipation (Ref. 344; also see Refs. 342 and 361).

Malignant chromaffin cell tumors are larger than benign ones (average diameter, 8.8 cm *vs.* 4.2 cm, respectively) (355), and although traditionally the extraadrenal forms were considered more malignant than adrenal tumors, this has recently been questioned (351, 355). Chromaffin cell tumors are less likely to be malignant in patients with familial syndromes, whereas they are more likely to be malignant in patients with a family history of a malignant tumor (20, 355). However, the clinical behavior of malignant chromaffin cell tumors may be highly variable, with 5-yr survival rates ranging from 36–74% (353, 362). The 3-yr survival rate was found to be 73%, with the majority of cases diagnosed at first presentation (363). Markedly elevated CgA levels point toward malignant chromaffin cell tumors (Ref. 364; also see Refs. 365 and 366).

2. Localization studies: screening in familial forms

a. Imaging of pheochromocytomas and paragangliomas. Having established the diagnosis of a chromaffin cell tumor, the next step is to document the extent of the disease and whether the tumor occurs as part of a familial or a sporadic form of the disease, and then to determine tumor biology and extent. Because more than 90% of chromaffin cell tumors are intra-abdominal, approximately 90% are located in the adrenals, and the great majority are larger than 2 cm, CT imaging demonstrates a 93–100% sensitivity for detecting adrenal tumors and 90% sensitivity for detecting extraadrenal tumors (351, 357, 360). Most tumors enhance markedly after iv contrast medium; nonionic contrast medium does not usually require previous α -adrenoceptor blockade (367). MRI exerts equal sensitivity to CT in detecting adrenal tumors but is superior in detecting extraadrenal tumors (351, 368). Most pheochromocytomas are hypointense on T₁-weighted images and markedly hyperintense on T₂-weighted images; although typical, these appearances on T₂-weighted images are not specific (368). However, both techniques have inferior specificity, which is particularly important due the high frequency of non-pheochromocytoma-related adrenal masses (369). Scintigraphy with ¹²³I-labeled MIBG offers superior specificity, especially for familial and malignant lesions (95–100%), and a sensitivity approximating 90%; however, more than 10% of tumors can still be nondemonstrable with this technique (360). Because chromaffin cell tumors often express SS receptors, scintigraphy with ¹¹¹In-octreotide can be used to increase sensitivity, particularly in cases of ¹²³I-MIBG negative lesions (99). In cases where clinical and biochemical suspicion is high and all imaging studies have failed to demonstrate a lesion, venous catheterization of the adrenal or other suspected sites is performed with sampling for measurement of both epinephrine and norepinephrine, and their ratio is calculated; high epinephrine/norepinephrine levels suggest a normal adrenal (344, 370). PET, originally with FDG and ¹¹C-hydroxyephedrine and more recently with 6-[¹⁸F]-fluorodopamine, has been shown to be highly sensitive, and on several occasions better than other established methods, demonstrating almost 100% sensitivity and spec-

ificity; when widely available, it has been claimed that PET will become the imaging modality of choice (22, 371).

b. Familial chromaffin cell tumors and genetic screening. Recent advances in genetics have contributed to early diagnosis and screening in cases of familial chromaffin cell tumor manifestation in MEN types IIA and IIB by early screening of the relatives; VHL kindreds are absent in the type I phenotype but are the sole manifestation in type 2C families (21, 28). Recently, it was shown that germline mutations in three of the succinate dehydrogenase (SDH) mitochondrial complex II subunits (SDHD, SDHB, and SDHC) cause susceptibility to chromaffin cell tumors (372). It has been reported that 84% of all multifocal tumors (including bilateral tumors) and 59% of tumors with onset at the age of 18 yr or younger, particularly extraadrenal pheochromocytomas, may be associated with hereditary disease (21); in such cases counseling should be readily available. Somatic RET mutations have been described in 10% of sporadic pheochromocytomas and VHL mutations in approximately 3% (28, 373, 374). Although it has recently been suggested that RET, VHL, and SDHD mutations together may account for 15–24% of nonfamilial presentation of pheochromocytoma (21, 352), this is not widely accepted (28, 373), and we therefore cannot recommend their routine screening in apparently sporadic chromaffin cell tumors. When uncertainty regarding the malignant nature of the tumor remains, elevated telomerase and/or c-myc and decreased or absent neuropeptide Y activity and inhibin/activin β -subunit have been suggested to be indicative of malignant pheochromocytoma (355, 375–378).

D. Medullary thyroid carcinoma

MTC is a rare calcitonin-secreting tumor of the parafollicular or C cells of the thyroid (110). MTC occurs in both sporadic and hereditary forms; although it accounts for only 3–10% of all thyroid carcinomas, it is responsible for up to 13.4% of all deaths (110, 379–381). The familial (hereditary) variety of MTC is inherited as an autosomal dominant trait with a high degree of penetrance (379). There are three distinct hereditary varieties of MTC: 1) MEN IIA syndrome (90% of the cases of MEN II syndromes), characterized by MTC in combination with pheochromocytoma and tumors of the parathyroids; 2) MEN IIB syndrome, characterized by MTC, pheochromocytoma, ganglioneuromatosis, and a marfanoid habitus; and 3) FMTC, without any other endocrinopathies.

A germline mutation in the RET protooncogene predisposes individuals to develop MEN II and FMTC (381). These varieties of FMTC are clinically distinct from each other with respect to incidence, genetics, age of onset, association with other disease, histopathology, and prognosis. The majority of patients (75%) have sporadic MTC (379), which usually occurs in the fifth decade of life, whereas hereditary disease is usually diagnosed earlier, depending on biochemical or genetic screening (379, 381). MTC synthesizes and secretes large amounts of calcitonin as well as a number of other substances such as CGRP, CEA, NSE, CgA, and ACTH (382, 383); however, none of these tumor markers has the sensitivity and specificity comparable to calcitonin. Calcitonin is secreted in all cases of clinically palpable MTC, whereas

normal basal calcitonin levels are usually found in very small tumors and cases of C cell hyperplasia (382). Pentagastrin has been used extensively as a provocative agent for calcitonin secretion for the identification of both subclinical MTC and gene carriers in families at risk (379, 381); in addition, the combined calcium and pentagastrin infusion test has been proposed to potentiate the secretagogue stimulus for calcitonin (384). Recently, however, genetic screening has been progressively replacing biochemical tests (Refs. 379 and 381; also see Refs. 385 and 386).

1. Clinical presentation and biochemical diagnosis. The majority of patients with sporadic MTC (70%) initially present with a thyroid nodule or mass, occasionally accompanied by cervical lymphadenopathy; when a thyroid nodule is palpable, cervical lymph node metastases are present in at least 50% of patients (355, 387). Occasionally, there may be symptoms of ectopic hormone production such as diarrhea, facial flushing, and (rarely) Cushing's syndrome (379, 381). The correct diagnosis is usually obtained from cytological diagnosis or by plasma calcitonin measurements (383). Preoperative calcitonin levels correlate with tumor size (388) and are usually above 100 pg/ml in the presence of clinically significant disease; a stimulation test may be used in suspicious cases with normal calcitonin levels (388, 389). Although routine measurement of serum calcitonin has been advocated in all patients presenting with thyroid nodules, it is not yet clear whether this represents a cost-effective method (390). Variable loss of calcitonin synthesis and secretion with or without an increase in CEA may indicate a dedifferentiation and a more aggressive form of MTC (6, 40). The discovery of a MTC in a patient has several diagnostic implications involving a specific strategy: these include preoperative evaluation of the extent of the disease, classification of MTC as sporadic or hereditary by DNA testing, and screening for associated endocrinopathies in hereditary MTC.

2. Screening of familial forms and localization studies

a. Screening. Traditionally, first-degree relatives of patients with MTC were tested with the pentagastrin stimulation test to identify asymptomatic members necessitating prophylactic thyroidectomy; however, calcitonin results were occasionally borderline and difficult to interpret (383). The preferred current method is genetic screening; if a RET mutation is identified, then all family members should be offered testing for the same mutation (20, 391). Family members without the RET mutation are reassured and informed that no further tests are necessary for either them or their offspring (20, 383). When FMTC is suspected and no mutation is detected in a given patient, genetic linkage analysis may be performed to evaluate family members at risk (391). Once gene carriers are identified, prophylactic thyroidectomy can be offered, which, in these patients, is curative if carried out at a young enough age.

b. Disease localization after initial diagnosis. Before surgery, ultrasound of the neck or MRI of the neck and mediastinum should be performed (381). A CT scan of the liver and the lung is also needed before surgery to identify any evidence of metastases, although these may be miliary (381). MTC is

characterized by its early lymph node metastatic spread, in approximately 50%, and even micro-MTC (<10 mm) may cause clinically detectable cervical lymph node metastasis in 10% of cases (388).

c. Localization of residual or recurrent disease. After thyroidectomy, patients are initiated on T₄ replacement therapy and have their calcitonin levels assessed within the next few months. Ideally, patients who have been treated with total thyroidectomy with neck dissection should have low or undetectable calcitonin levels (392, 393), using the more sensitive immunoradiometric assay methods (392). Patients with postoperative normalization of calcitonin and/or CEA levels are commonly considered surgically cured (110, 382). However, stimulated peak plasma calcitonin levels are more useful than basal levels in detecting occult disease after thyroidectomy (379, 381). Using molecular detection of disseminated tumor cells in cervical lymph nodes with cytokeratin 20 RT-PCR, a higher percentage of involved lymph nodes was detected compared with immunohistochemistry, suggesting more extensive residual disease (394). However, the prognostic value of minimal residual disease in MTC has yet to be confirmed in prospective studies.

In patients with residual or recurrent disease, further evaluation should be performed by means of high-resolution ultrasonography with or without fine-needle aspiration, CT, and/or MRI; however, their sensitivity in detecting minimal residual disease is substantially reduced (383). Scintigraphy with ¹³¹I-MIBG and ¹¹¹In-octreotide has shown a sensitivity of 35–50% and 50–75%, respectively (54, 72, 99); ¹¹¹In-octreotide has been shown to be more sensitive than MRI scanning in detecting occult MTC recurrence (395), and scintigraphy with these radionuclides will also visualize chromaffin cell tumors in MEN patients (396). Although it was originally suggested that scintigraphy with ^{99m}Tc-dimercaptosuccinic acid is sensitive in identifying both bone and soft tissue metastases, these results have not been consistently reproduced (382). Similarly, immunoscintigraphic procedures using radiolabeled monoclonal antibodies, with either calcitonin or CEA, have been reported to show considerable sensitivity but are still considered experimental investigations (382, 397). Selective venous sampling catheterization with or without pentagastrin stimulation has shown encouraging results for the localization of occult disease in individual patients (398). Diagnostic laparoscopy of the liver may demonstrate small deposits of metastatic MTC in a number of patients with negative imaging studies, but this procedure is not widely used (399). More recently, FDG PET has been shown to be promising, although comparisons with other imaging techniques are still lacking (400).

VII. Medical Management of Advanced Neuroendocrine Tumors

A. Pretreatment considerations

Surgery remains the treatment of choice and the only approach that can achieve a cure in patients with NETs (60, 401–403). Medical treatment should always be considered as an adjuvant to surgery unless either the general condition of

the patient or other contraindications preclude surgery (227, 382, 404, 405). In cases of metastatic disease, surgery has been used to improve hormone-mediated symptoms and the quality of life (406), to reduce tumor bulk and prevent further local and systemic effects (10, 406), and even to improve survival in certain groups of tumors, particularly in midgut carcinoids (406, 407). In addition, surgery can also be used after medical treatment has achieved substantial tumor reduction in an attempt to maximize changes for a longer disease-free interval and even cure (5, 113), although a recent study suggested that the great majority of such patients eventually relapse (408).

Before applying any kind of therapy, the possibility of an MEN I syndrome should always be considered in patients with GEP, particularly pancreatic tumors, whereas the possibility of MEN II syndrome should be entertained in patients with chromaffin cell tumors and MTC (113, 344, 383). Such an approach is important because there is considerable difference in the management of these tumors when they occur as part of the MEN syndromes (20, 109, 113, 383). In addition, tumor biology is currently becoming a powerful determinant of the form of medical treatment because it may correlate with the natural history of the disease (109). Uniform criteria to assess responses to treatment are also necessary to establish specific management guidelines (5, 404).

Patients' responses to therapy should be divided into symptomatic, hormonal, and tumor responses (59, 409, 410). Tumor responses are classified according to WHO criteria as: 1) complete response, complete regression of all clinical and hormonal evidence of tumor, including radiological abnormalities; 2) partial response, a 50% or greater reduction of all measurable tumor and no appearance of new lesions, including hormonal and symptomatic improvement; 3) stable disease, a less than 50% reduction or no greater than 25% increase of tumor size, hormonal measurements, and symptoms; and 4) progression, appearance of new lesions or an increase of 25% or more of tumor size, and hormonal and symptomatic deterioration. Patients are reviewed at 3- to 6-month intervals; review assessment comprises clinical, biochemical, and radiological evaluation. The rationale of applying further treatment at these time intervals is contingent upon the relative prolonged replication period of these tumors (79, 116).

B. Symptomatic treatment of GEP tumors

GEP tumors associated with clinical syndromes related to specific hormonal production are currently best managed with SS analogs (61, 411, 412). Before the availability of SS analogs, several therapies directed to specific hormonal production were used, with the goal of improving symptoms and the quality of life (413). Some of these therapies may still be necessary either when symptoms become refractory to SS analogs or in combination with them (61, 401, 405, 414).

1. *CS*. Because flushing and diarrhea may be associated with particular precipitants, lifestyle adjustments may be required; patients should avoid known precipitants such as alcohol, spicy foods, and strenuous exercise (52). Diarrhea in patients with CS is not always the consequence of excessive

hormonal secretion because occasionally it may deteriorate or even start after surgical resection of the primary tumor, mainly in the terminal ileum (59, 405). In such cases, the diarrhea is secondary to bile acid loss and/or increased bacterial contamination of the small intestine with subsequent deconjugation of bile acids; cholestyramine is the treatment of choice for the former case, and antibiotics for the latter (405, 411). Patients with histamine-producing tumors and the atypical CS should avoid histamine-liberating drugs and optimally be pretreated with SS analogs, blockade of histamine receptors, and possibly corticosteroids (405, 411). A number of other agents active in the CS were used in the pre-SS analog era; their mode of action has been extensively reviewed in the past (60, 402, 413). Among them, loperamide, mainly in combination with SS analogs, may still be of great value (59). Combination vitamin B replacement should be administered in patients with severe disease and suspicion of pellagra, and indeed we use compound vitamin B replacement in all patients with CS.

2. Pancreatic tumors

a. *Insulinoma*. These tumors are the least sensitive to treatment with SS analogs (61). Diazoxide at doses of 50–300 mg/d (but up to 600 mg/d) usually diminishes insulin secretion and is the most effective drug for controlling hypoglycemia; it can cause marked edema, renal impairment, and hirsutism (59, 405). Verapamil (a Ca^{+2} blocker), glucocorticoids, and phenytoin have also been used, although less effectively (60, 246, 250). In refractory cases, glucocorticoids such as prednisolone or high doses of synthetic GH can be effective (255).

b. *Gastrinoma*. The introduction of H_2 -receptor antagonists and, later, $\text{H}^+ - \text{K}^+ - \text{ATPase}$ (proton pump) inhibitors has replaced surgery in many cases and has markedly improved the therapeutic strategies for the management of gastric acid secretion and its sequel in patients with ZES (59, 60, 405). Proton pump inhibitors are currently the therapeutic agents of choice for short- and long-term control of gastric acid secretion (59, 61, 405, 415). Gastric acid secretion is best controlled by a mean morning dose of 40–80 mg of omeprazole or an equivalent dose of other similar compounds; if higher doses are required, they should be given every 12 h (415), and patients should be on these medications indefinitely (59, 61, 405, 411). Although H_2 -blockers are also capable of controlling gastric acid hypersecretion effectively, they have for the most part been superseded by proton pump inhibitors (59, 61, 405).

c. *Glucagonoma*. NME responds to SS infusion irrespective of alterations in glucagon levels or normalization of previously low amino acid levels (416). Because surgical resection may be considered even if the tumor is metastatic, it is important to correct hypoaminoacidemia and mineral deficiency, control diabetes, and administer low-dose heparin to decrease the risk of thrombosis; SS analogs preoperatively have also been advocated (277).

d. *VIPoma*. Several antidiarrheal drugs, indomethacin, and lithium can be used, but they seldom control the diarrhea effectively. Glucocorticoids are usually highly effective,

however, and can produce a 40–50% reduction in VIP levels (286, 405). They may best be used for acute exacerbations, with SS analogs being the mainstay for chronic control (286, 405).

e. Somatostatinomas. There is no specific treatment for somatostatinomas besides administration of SS analogs that inhibit SS secretion from the tumor.

C. Systemic treatment of GEP tumors

Systemic medical treatment of GEP tumors includes treatment with biological agents [SS analogs, interferon (INF)- α], chemotherapy, and variations of these forms of therapy (5, 417–419). However, the results of published trials are often obscured by the rarity of GEP tumors, a lack of precise knowledge of the natural history, a paucity of prospective studies with large numbers of patients, and the lack of uniform criteria for assessing response to treatment (59, 113, 420, 421). GEP tumors can exhibit long phases of spontaneous tumor standstill, spontaneous regression even without treatment, or explosive growth (405). Once progression of disease becomes clinically detectable, however, the pace of clinical deterioration appears to increase (420). It is hoped that the incorporation of markers of tumor biology in the diagnostic workout of these tumors will successfully identify the more aggressive subset of tumors and direct treatment accordingly.

1. Biotherapy: SS analogs and/or INF- α

a. SS analogs in GEP tumors. SS analogs can reliably control hormone-mediated symptoms, may exert an antiproliferative effect and thus control tumor growth, and can also have vascular and immune system modulatory effects (59, 404, 405). SS analogs are poor tumoricidal agents (59, 122, 404, 405, 422) but may show tumorigenic effects and retard further NET growth, resulting in tumor stabilization (59, 122, 404, 405, 422). Regular octreotide at a daily dose of 200–450 μg is associated with a median 60% symptomatic, 70% biochemical, and 5–11% tumoral response (59, 404, 405, 423). The highest response rates are obtained using octreotide in daily doses greater than 30,000 μg or lanreotide in doses greater than 5 mg/d (and up to 15 mg) (421); such high doses may also induce tumor cell apoptosis (421, 423, 424). More than 30 patients with partial tumor regression to SS analogs have been reported, the majority of whom had also received other treatment modalities; very few cases have shown complete tumor regression with octreotide monotherapy, and some of these were in the context of an MEN I syndrome (421, 425–429). However, a great number of patients achieve disease stabilization (59, 404, 405, 417, 420, 421, 424, 429–438) (Table 3). This has also been clearly demonstrated in prospective studies, in which only patients with substantial tumor progression (>25%) were treated with 450–750 μg of octreotide daily; 36.5–50% of these patients obtained radiographically proven disease stabilization with a median duration of 5–18 months (405, 420, 431). Slow-release formulations of octreotide (Sandostatin LAR, Novartis) administered at doses of 20–30 mg/month or lanreotide at 30 mg every 10–14 d are now available and have achieved better or similar response

rates with a more convenient administration scheme (5, 59, 439–441). Lanreotide Autogel (Ipsen, Paris, France) appears to be at least as effective as conventional lanreotide at a monthly dosage of 60–120 mg, given by deep sc injection (74, 116). Although most data are derived from retrospective studies, there seems to be no major difference between octreotide and lanreotide in terms of receptor affinity or biological activity (59, 432, 434), as also shown by a prospective study (437). In a recent as yet unpublished study, Lanreotide Autogel appeared to be highly effective in controlling CS-associated flushing but was apparently less effective against diarrhea; however, it is probable that this relates to patient selection criteria, and it seems unlikely that there will be major differences in symptomatic control between the currently available long-acting SS analogs. The quality of life was substantially improved after treatment with long-acting SS analogs (435, 437). When octreotide LAR is prescribed, concomitant treatment with short-acting octreotide should be initiated for the first 2–3 wk (59, 423).

In patients with the CS, both diarrhea and flushing improve or even disappear after treatment with SS analogs, usually within the first week; flushing appears to be more sensitive to SS analogs than the diarrhea (61, 429, 432, 442, 443). The effect of SS analogs on the course of CHD and overall prognosis of the CS has not been assessed in any prospective study; recent data have shown an overall increase in survival after the introduction of octreotide, suggesting a direct effect on prognosis in some studies (130, 207, 444), but no control groups are available for formal comparison (207). However, with active medical and surgical therapy of tumor disease and with careful selection of patients, valve replacement may reduce mortality from CHD substantially (199, 208, 445, 446). In life-threatening situations, such as carcinoid crisis, iv infusion of octreotide at doses of 50–100 $\mu\text{g}/\text{h}$ is usually effective (60). Only around 50% of patients with insulinomas respond to treatment with SS analogs, which may relate to the lack of SS receptor subtype 2 in 50% of these tumors or to the presence of tumors with no or atypical β -granules (59). In patients not responding to SS analogs, hypoglycemia may even be aggravated through suppression of counterregulatory hormones such as glucagon (59, 405). Long-acting SS analogs suppress gastric secretion by a direct effect on the parietal cell and by inhibiting gastrin release from the tumor cell, but they do not uniformly lower gastric acid as effectively as omeprazole, which is also not associated with tachyphylaxis (59, 447). However, omeprazole is not known to exert any effect on tumor growth, and therefore the theoretical possibility of an antitumoral effect exerted by SS analogs affecting growth should always be considered. This is currently being formally assessed (412). Symptomatic and biochemical responses have been noted in more than 80% of patients with VIPomas; symptomatic improvement was not always related to the reduction in plasma VIP levels, suggesting a direct effect on the gut (277, 412). Patients with glucagonomas demonstrate an approximate 90% symptomatic improvement, particularly in the skin rash, and a 60% biochemical improvement, although SS analogs are less effective in the management of diabetes and weight loss (276). Although only a small number of patients with somatostatinomas have been treated with SS

TABLE 3. Treatment of GEP tumors with SS analogs

First author, year (Ref.)	<i>n</i>	Tumor	Agent	Previous therapy	Symptomatic response (%)	Hormonal response (%)	Tumor response
Saltz, 1993 (420) ^{a,b}	34	20 ct, 13 IST, 1 unknown	Octreotide	13 CH	71	33	PR 0%, SD 50% (duration, 5 months median) ^c SD 58%
Scherubl, 1994 (prospective, WHO criteria) (429) ^c	12		Lanreotide 30 mg/14 d	Octreotide	40–90		
Arnold, 1996 (60) ^{a,b}	103	64 ct, 39 IST	Octreotide 200–500 µg 3×/d	21 CH, 9 INF	85	33.3	PR 0%, SD 36.5%, duration 18 months
Di Bartolomeo, 1996 (431) ^{a,b}	43	31 ct, 12 IST	Octreotide 1500–3000 µg/d	9 CH, 7 RT	73 ^d	77	PR 7%, SD 27%
Ruszniewski, 1996 (432) ^c	39	ct	Lanreotide 30 mg/14 d	16 CH, 16 octreotide	55	42	PR 0%
Eriksson, 1997 (433) ^{a,c,e}	19	13 ct, 6 IST	Lanreotide high dose (up 12,000 mg/d)	9 Octreotide, 10 INF		54 (12 months)	PR 0%, SD 90%
Tomassetti, 1998 (434)	18	10 ct, 8 IST	Lanreotide 30 mg/10 d	15 Octreotide	90	33	SD 78%
Faiss, 1999 (421) ^{a,e}	30	20 ct, 10 unknown	Lanreotide 15 mg/d	10 SS analogs, 3 INF, 7 combination, 3 CH	70	43–52	CR 3.4%, PR 3.4%, SD 37%
Wymenga, 1999 (435) ^a	55 (progressive disease)	48 ct, 7 IST	Lanreotide 30 mg/14 d	16 Octreotide, 10 INF, 2 CH, 1 RT	45	47	PR 6%, SD 81%
Ricci, 2000 (436) ^{a,b}	25 (progressive disease)	12 ct, 13 IST	Lanreotide 30 mg/2 wk	13 Octreotide, CH	70	42	PR 8%, SD 40%, duration 8.5 months
O'Toole, 2000 (437) ^{a,f}	33	ct	Octreotide 400–600 µg/d, lanreotide 30 mg/10 d	20 Octreotide, 2 lanreotide	61	54 (>25% reduction)	
Ducreux, 2000 (438) ^a	39 (symptoms or progressive disease)	ct	Lanreotide 30 mg/10–14 d		64	50	PR 5%, SD 49%
Aparicio, 2001 (424)	35 (progressive disease)	22 ct, 12 IST	Octreotide 300 µg/d, lanreotide 30 mg/14 d				PR 3%, SD 57%

Assessment was performed using WHO criteria. ct, Carcinoid tumors; IST, islet cell tumors; CH, chemotherapy; RT, radiotherapy; CR, complete response; PR, partial response; SD, stable disease.

^a Prospective study.

^b Patients with progressive disease or severe noncontrolled symptoms.

^c Improvement in the quality of life.

^d Response restricted to patients with ct.

^e Ultra-high dose used.

^f Direct prospective comparison between octreotide and lanreotide.

analogs, there has been considerable symptomatic and biochemical improvement correlating with the presence of SS receptors as shown by octreotide scintigraphy (412, 423, 448).

b. High-dose treatment/continuous infusion treatment. A number of studies have examined the effect of treatment with high doses of SS analogs (octreotide, 6 mg/d, and lanreotide, 9–15 mg/d) in patients with progressive GEP tumors on conventional doses of octreotide, showing a further tumoral response (421, 449). One study using high doses of lanreotide was unique in that patients who obtained disease stabilization underwent serial tumor biopsies over a period of 12 months, showing an increased number of apoptotic cells; it was postulated that this was achieved through induction of apoptosis via SS receptor subtype 3 (449). This extra antiproliferative effect of ultra-high doses has also been demonstrated in studies in which only progressive tumors were included (421). It is possible that high-dose octreotide/lanreotide can produce additional antiproliferative effects in patients failing on standard doses of octreotide (412). More recently, the administration of 1.5 mg/d of octreotide was associated with substantial tumor responses in two patients with disseminated atypical carcinoid lung tumors (450). Although the continuous infusion of SS analogs was not associated with any side effects, there was no improvement in the tumoral response; however, this form of treatment can be considered in acute and life-threatening crises (449). Currently, our own position is to use doses of Sandostatin LAR up to 30–60 mg every 3–4 wk, and Lanreotide Autogel up to 120 mg monthly. However, it is reasonable to consider additional “top-up” doses of sc octreotide, using 50 or 100 μ g from time to time if required. Alone, sc octreotide can be used up to 1000 μ g daily, either as regular intermittent doses or by continuous sc infusion, for short times during acute exacerbations. We do not at present recommend the regular use of doses above these levels outside of controlled clinical trials.

c. Tachyphylaxis. Eventually, the great majority of patients escape from SS analog therapy; the median duration of response is around 12 months with regard to both hormonal production and tumor growth; increased doses may be required initially to maintain symptomatic control, but eventually dose escalation can no longer control the clinical symptoms (61, 412, 451, 452). Although the majority of these data are derived from studies that have used octreotide and fewer are from studies that have used lanreotide, this phenomenon probably reflects a drug class rather than a specific compound effect (432). The mechanism behind this tachyphylaxis is not yet known, although early down-regulation of SS receptors (restorable transiently by a drug-free interval or dose increment) and development of receptor-negative clones has been considered (132, 452); this issue has recently been extensively reviewed (452). However, tachyphylaxis does not occur when patients with acromegaly are treated with octreotide, and it is more likely to be caused by changes in tissue-specific regulation of cellular SS receptors rather than simply differential patterns of SS receptor subtype expression (62, 63, 452). Tachyphylaxis may also be related to the frequency and form of SS analog administration (453). In recent studies using long-acting formulations of SS analogs,

tachyphylaxis has not been so commonly described (424, 435, 436, 438, 441). We would generally increase the dose of long-acting SS analog as required for symptom control, adding top-up doses of short-acting drugs to the long-acting analogs where these provide additional clinical benefit. Experience with drug-free “holidays” is limited, and we tend not to use this technique. As noted above, we would not normally go above a Sandostatin LAR dosage of 30–60 mg every 3–4 wk or Lanreotide Autogel dosage of 120 mg monthly.

d. Adverse effects of treatment with SS analogs. Adverse effects to treatment with SS analogs do occur but are usually mild and very rarely require discontinuation of the treatment (59, 60, 412, 431, 432, 437, 438). Approximately half of the patients on long-term SS analog treatment develop gallbladder dysfunction and a predisposition to biliary sludge or gallstone formation, although this is rarely clinically significant (454). Other side effects are discomfort at the injection sites, nausea, flatulence, diarrhea, steatorrhea and fat malabsorption, abdominal pain, and (rarely) hyperglycemia and a rash (59, 60, 412, 431, 432, 437, 438).

Currently, slow-release SS analogs are regarded as the gold standard treatment for the management of hormone-related symptoms in patients with GEP tumors, because they improve patient compliance and satisfaction (5, 419). Of interest, some preliminary data have shown a significant efficacy of Sandostatin LAR in terms of objective response rate and biochemical and symptomatic control in patients with progressive metastatic disease after therapy with lanreotide (440, 455). This possible lack of cross-resistance between different SS analogs might be due to different pharmacokinetic and pharmacodynamic properties of the compounds leading to different receptor desensitization mechanisms, and this may lead to the development of new therapeutic strategies in the management of NETs (440, 455, 456). There is no direct evidence that treatment with SS analogs prolongs survival in patients with GEP tumors (122). However, retrospective comparison with a cohort of patients treated with chemotherapy has shown that octreotide was associated with around 3-fold improved survival, whereas the overall survival of patients with GEP tumors has probably increased after the introduction of SS analogs (130, 444). This awaits confirmation from prospective studies.

e. Newer SS analogs. SOM-230 (Novartis) is a new SS analog that has a more prolonged half-life (≤ 23 –24 h) and exerts a more potent inhibitory effect than current available compounds, because it binds with much higher affinity to several subtypes of SS receptors (457). SOM-230 binds with high affinity to SS receptors 1, 2, 3, and 5, but hardly at all to subtype 4, but in this sense represents a near-universal ligand (457, 458). Initial studies have revealed no desensitization of the suppressing effect of SOM-230, in contrast to octreotide, due to the different intracellular dynamics of SS receptor subtypes 2 and 5 (459). The introduction of SOM-230 into clinical practice will also address the long-standing question as to whether SS receptor subtypes 1 and 3, which mediate antitumor effects (cell cycle inhibition, induction of apoptosis), exert a clinical beneficial effect in inoperable carcinoid

and islet cell tumors (457, 460). Early phase I clinical trials using SOM-230 have been initiated recently (457, 458).

f. Future prospects. The potential value of high-dose SS analog therapy and novel SS subtype specific analogs is currently under extensive investigation. There may be certain types of tumors that preferentially express subtypes of SS receptors that have little or no affinity for current SS analogs, and agents such as SOM-230 may increase the proportion of NETs able to respond to SS therapy. This is also currently being explored with the availability of the slow-release formulations that allow the administration of even higher doses. The SS receptor status, tumor biology, and growth pattern of each patient are included in the prior-to-treatment analysis to optimize treatment and provide new insights into the mechanisms of action of SS analogs (412). In addition, the incorporation of SS analogs with other therapeutic modalities is currently under investigation.

g. INF- α therapy in GEP tumors. INFs are compounds known to exert a combination of effects directed to several groups of tumors and are considered as biological response modifiers because they interact with other soluble or cell-associated regulatory factors (172, 404, 461). INF has been used either alone or in combination with chemotherapy and SS analogs in various, but mainly carcinoid, endocrine tumors (172, 404, 461). The antitumor action of INF- α , produced by leukocytes, includes direct effects on proliferation, apoptosis, differentiation, and angiogenesis (461). INF- α also exerts an immunomodulatory effect and induces fibrosis in metastatic, particularly hepatic lesions (461, 462).

Initial studies used human leukocyte INF, but currently recombinant INF is the major agent in use (63, 64). The recommended doses are 3–9 MU daily or every other day, with a median dose of 5 MU every other day sc, but treatment should be titrated individually according to sex, weight, and age (463, 464). The leukocyte count can also be used to determine INF dose titration, aiming at reducing the number of leukocytes to below 3.0×10^9 /liter (463, 464). From data derived from studies summarized in Table 4 (including carcinoid and pancreatic tumors separately), the median symptomatic and biochemical response rates to INF are 40–70% and 44%, respectively, and the median tumoral response is 11% (422, 463, 465–470). Disease stabilization is noticed in a

further 35% of patients, and tumor progression in approximately 15–20%; the median duration of response was 32 months (463). It has been postulated that INF induces apoptosis and that tumor cells are replaced by fibrotic tissue, which could explain the increased intratumoral fibrosis observed in carcinoid metastases without a significant change in tumor size; this could theoretically account for the discrepancy between biochemical and tumoral results (5, 227, 423, 461, 464, 471, 472). In patients with low proliferative endocrine pancreatic tumors, a response rate of approximately 50%, lasting for more than 2 yr, has been observed (5, 227, 423, 461, 464, 471, 472). Both retrospective and prospective studies have shown that INFs, with or without SS analogs, should be the medical treatment of choice, particularly in patients with midgut carcinoids (5, 227, 423, 461, 464, 471, 472). There seems to be no clear dose-response relationship, and higher doses were not associated with an improved response (465). Oberg and co-workers (5, 47, 172, 461) have treated more than 300 patients with GEP tumors with INF- α and have suggested that a limited tumor burden may be associated with a better therapeutic response. Although retrospective data suggest a prolongation of survival, there are only a few randomized control studies demonstrating a better outcome of patients treated with INF compared with patients treated with chemotherapy or SS analogs (172, 404, 461). In another randomized study, discontinuation of successful INF therapy was associated with shortening of life expectancy (468).

Treatment with INF has shown a 77% response rate (with a median duration of 8.5 months) as second-line therapy after failure of chemotherapy, with a 51% response rate (median duration, 20 months) in patients where half received the treatment as first-line and the rest as second-line (172, 404, 461). The combination of INF and SS analogs may minimize the problem of tachyphylaxis of analog treatment alone. However, what remains unclear at present is whether SS analogs and INF exert an additive effect or not. This has been suggested by some retrospective studies, but the results of a randomized study were not very encouraging (473, 474) (see Section VII.C.1.j). In contrast, the combination of recombinant INF and chemotherapy with streptozotocin (STZ) and doxorubicin or 5-fluorouracil in randomized controlled trials was not associated with a synergistic effect, although consider-

TABLE 4. Treatment of GEP tumors with INF- α

First author, year (Ref.)	<i>n</i>	Dose	Biochemical response (%)	Tumor response (%)
Carcinoid tumors				
Moertel, 1989 (465)	27	INF _{2a} 24 MU/m ² × 3/wk	39	20
Hanssen, 1989 (466)	19	INF α 2b 5 MU × 8/wk ± chemoembolization	40 (±86)	10 (±86)
Bartsch, 1990 (467)	18	r-INF2c 2 MU/m ² × 12/wk	44	0
Valimaki, 1991 (478)	8	INF α 3 MU/m ² × 7/wk	50	12.5
Oberg, 2000 (461)	111	INF α × 7/wk r-INF _{2b} 5 MU/m ² × 3/wk	42	15
Tiensuu Janson, 1992 (485)	22	r-INF _{2a} 3 MU/m ² × 3/wk	25	17
		r-INF- α ₂ × 3 MU/wk + STZ + adriamycin	0	0
Joensuu, 1992 (469)	14	INF α 6–30 MU/m ² /wk	50	0
Bajetta, 1993 (470)	34	INF α -2a 5 MU × 3–7/wk	57	11.8
Pancreatic tumors				
Bajetta, 1993 (470)	4	INF α -2a 5 MU × 3–7/wk		0
Eriksson 1993 (464)	57	r-INF- α _{2b} 5–6 MU/m ² × 3–5/wk	51	12

Data represent the most important trials of INF- α therapy in patients with GEP therapy.

able toxicity was encountered (175, 422, 475). Similarly, in patients failing treatment with INF- α , second line (salvage) therapy with ^{131}I -MIBG or STZ-based chemotherapy was not proven to be effective, although the number of patients treated was small (476). Recently, intralesional INF administration was associated with tumor necrosis and significant clinical improvement in a patient with metastatic carcinoid tumor (477).

In contrast to the above findings, a small number of studies have suggested that the effects of INF are often suppressed as a result of adverse effects that limit continuous treatment and can affect its efficiency (465, 478, 479). Similarly, in bronchial carcinoids neither SS analogs, INF, or their combination was found to be effective (480). The development of neutralizing antibodies to recombinant INF may also limit its clinical efficiency, although change to human INF may restore some of these effects (481). Recently, it has been speculated that the activation of phospholipase A₂, which may provide some of the antitumor effects of INF, might also contribute to the clinical side effects (481).

h. Adverse effects. Flu-like symptoms are almost universal but short-lived, lasting approximately 1 wk (404, 461, 471). Chronic fatigue and mild depression may develop in up to 50% of patients, occasionally leading to discontinuation of the treatment. Autoimmune reactions (thyroid dysfunction, a systemic lupus erythematosus syndrome, and polymyalgia) appear in approximately 30% of patients. The presence of these reactions does not, however, appear to influence tumor responsiveness (482).

i. Future prospects. It is expected that newer INFs, particularly the longer-acting polyethylene glycosylated recombinant formulations, will soon be available, leading to better patient compliance and less side effects. In addition, the induction of INF regulatory factors might be used to indicate the response of carcinoid tumors to treatment with INF (483). Pegylated INF- α has come into clinical use at doses of 50–100 μg sc once a week (461, 471).

j. Combination of SS analogs and INF- α . After a dramatic response was obtained following treatment with the combination of INF- α and SS analogs, it was hypothesized that patients resistant to either medication alone might respond to that combination (473, 484), and the problem of tachyphylaxis of analog treatment alone could be postponed with-

out any additional cross-resistance between the two biotherapies (146, 473, 484, 485). This original observation was reinforced further when the application of INF- α and SS analogs in patients with malignant midgut carcinoid tumors was shown to improve prognosis and offer good symptomatic relief (146, 485). In a further study, the addition of INF to patients with progressive carcinoid and pancreatic islet cell tumors, besides treatment with octreotide alone, was associated with significant symptomatic and biochemical improvement, inhibition of tumor growth, and probably prolongation of survival in the responder group (473) (Table 5; Refs. 473, 484–486). Although the objective tumor responses obtained from that study are difficult to compare to other studies, because a greater than 30% reduction of tumor size was accepted as indicative of a radiological tumor response, similar findings were obtained in a recent study in which the combination of INF and SS analogs was used in patients with pancreatic islet cell tumors who developed progression of their disease after becoming refractory to the administration of each drug alone; however, the value of sequential treatment was not considered in that study (486). Similarly, this combination has been shown to be effective in liver metastases from pernicious anemia-related ECL-GC tumors (161, 487), but not in patients with pulmonary carcinoids suffering from CS (although there was some symptomatic relief) (161). However, the results of a prospective study evaluating the effect of this combination *vs.* each drug alone in 80 therapy-naive patients with verified metastatic NETs showed that SS analogs (lanreotide), INF, or the combination of the two had comparable antiproliferative effects (474). Response rates were relatively lower than those of nonrandomized studies, similar for functional and nonfunctional NETs, whereas side effects leading to discontinuation of the therapy were more frequent in the group that received the combination treatment (474). Currently, we rarely find an occasion to add INF when treatment with SS analogs is no longer effective.

2. Chemotherapy for NETs. In general, NETs are not highly chemosensitive, and if they do respond, any improvements may be slow to appear; this may be due to NETs' generally low rate of mitosis, the target of many cytotoxic drugs, and also to their biological properties (116). NETs show high expression of the multidrug resistance (MDR-1) gene, which is capable of extruding a variety of anticancer drugs (116, 141), and high levels of expression of the antiapoptotic gene

TABLE 5. Treatment of GEP tumors with the combination of SS analogs and INF- α

First author, year (Ref.)	<i>n</i>	Tumor	Previous treatment	Dose	Symptomatic response	Biochemical response
Joensuu, 1992 (469)	1	ct	INF	5–10 MU INF \times 3/wk, 200 μg octreotide/d	100%	100%
Tiensuu Janson, 1992 (485) ^a	24	ct	Octreotide, 14 CH \pm INF	9 MU INF/wk, octreotide 300 μg /d	46%	77%
Frank, 1999 (473) ^{a,b}	21	9 ct, 12 IST	19 Octreotide, 2 lanreotide	5 MU INF \times 3/wk, 600 μg octreotide		69%
Fjallskog, 2002 (486)	16	IST	8 INF, 6 SS, 11 CH	9 MU INF/wk, 450 μg octreotide/d		62.5% (22 months)

All patients had progressive disease. ct, Carcinoid tumor; IST, islet cell tumor; CH, chemotherapy; CR, complete response; PR, partial response; SD, stable disease.

^a Prolongation of survival in responders.

^b Not WHO radiological criteria of response.

Bcl-2, which may contribute further to the intrinsic resistance to chemotherapy agents (34).

a. Chemotherapy for GEP tumors. Chemotherapy has been used extensively in the past for the management of disseminated GEP tumors; however, it was only after each group of tumors was separately analyzed that its efficacy was shown to depend on primary site and histological differentiation (404, 488). Currently, the indications for chemotherapy need to be very carefully reconsidered, because biotherapy with SS analogs and/or INF can control the symptoms of humoral syndromes and may also affect tumor growth (5, 116, 488). However, chemotherapy may be beneficial for selected cases of advanced, especially pancreatic, tumors that do not respond to other forms of therapy, and for poorly differentiated GEP tumors (5, 52, 116, 423, 488). One of the most commonly used drugs is STZ (182, 412, 489). STZ and its related compound chlorozotocin are glucose molecules with a nitrosurea substitute in the C2 position; this is likely to be the actual toxic part of the molecule (481).

b. Chemotherapy for well-differentiated pancreatic tumors. Chemotherapy is currently considered for progressive tumors (>25% increase in size of main tumor mass over 6–12 months) and is not usually appropriate in the early management of the disease when application of biotherapy is more advisable (116, 488, 490). Several chemotherapy regimens, initially with single drugs and later on with combinations of drugs, have been used and extensively reviewed in the past (172, 182, 404, 412, 423, 443); however, there are very few prospective studies confirming their efficacy (491). The combination of STZ and doxorubicin has been superior to other regimens, mainly STZ and 5-fluorouracil (5-FU), and has been associated with a 69% objective response lasting for

18 months and an overall median survival of 2.2 yr (491) (Table 6; Refs. 489, 491–498). In cases where the use of doxorubicin is limited due to its potential cardiotoxicity, the traditional combination of STZ and 5-FU can be used as an alternative (116, 464, 488, 498). Patients with functioning tumors respond better than those with nonfunctioning tumors (423, 443, 489). Patients who respond may also be good candidates for secondary surgical excision (113).

c. Chemotherapy for well-differentiated carcinoid tumors. The majority of information regarding the therapeutic response of carcinoid, particularly midgut, tumors to chemotherapy is derived from observational studies and indicates an overall poor response to either single or multiple agent chemotherapy (182, 443, 492, 499–502) (Table 6). In two randomized studies, the combination of 5-FU and STZ produced 33 and 22% response rates, respectively, while using non-WHO criteria (182, 492). The response duration is unpredictable and often short lasting, in the region of 3–8 months (182, 413, 499–501); although individual cases of much longer responses have also been described (116, 503, 504), there is no unequivocal evidence that chemotherapy improves survival, and it can certainly induce unpleasant adverse effects and be associated with a poor quality of life (172, 423, 443). In patients with typical pulmonary carcinoids, the combination of etoposide and cis-platinum, particularly if used as first-line chemotherapy, may be of value, in contrast to previous findings in patients with typical pancreatic carcinoid tumors (144, 307, 505). In this group of patients with lung tumors, conventional chemotherapy using STZ and 5-FU failed to control the disease (144, 480).

We consider the use of systemic chemotherapy for well-differentiated GEP tumors when the general condition of the

TABLE 6. Treatment of well-differentiated GEP tumors with combination chemotherapy

First author, year (Ref.)	Regimen	n	Tumor response
Pancreatic tumors			
Broder, 1973 (494)	STZ	52	42% (42 months survival)
Moertel, 1980 (493)	Randomized study		
	STZ	42	36%
	STZ and 5-FU	42	63%
Bukowski, 1992 (495)	Chlorozotocin and adriamycin	44	36% (11 months)
Moertel, 1992 (491)	Randomized study		
	STZ and adriamycin	36	69% (18 months) 2.2-yr survival
	STZ and 5-FU	33	45% (14 months) 1.4-yr survival
	Chlorozotocin	33	30% (17 months) 1.5-yr survival
Eriksson, 1993 (464)	STZ and 5-FU	31	35% (23 months duration response)
Bajetta, 1998 (496)	5-FU and dacarbazine and epirubicin	15	26.7% (10 months duration)
Rivera, 1998 (497)	Doxorubicin, STZ, 5-FU	11	54.5% (15 months) 1.8-yr survival ^a
Kaltsas, 2002 (498)	Lomustine and 5-FU	5	40% (2-yr survival)
Carcinoids			
Moertel, 1979 (499)	5-FU and cyclophosphamide	47	26%
Engstrom, 1984 (492)	STZ and 5-FU vs. adriamycin	80	22% (15 months median survival)
		81	21% (11 months median survival)
Moertel, 1987 (181)	STZ and 5-FU	43	33% (7 months survival)
	Methotrexate and cyclophosphamide	16	
	STZ and cyclophosphamide	14	
Bukowski, 1987 (501)	STZ and 5-FU and adriamycin and cyclophosphamide	56	30%
Oberg, 1987 (500)	STZ and 5-FU	24	8%
Rougier, 1991 (502)	5-FU and adriamycin and cisplatin	15	14% (27 months)
Kaltsas, 2002 (498)	Lomustine and 5-FU	18	25% (duration response 36.5 months)

^a Median patient survival, 21 months for responders vs. 14.5 months for nonresponders.

patient is good enough and after an observational period to appreciate the rate of tumor growth. Similarly, because these tumors are relatively slow-growing, antitumor efficacy should be evaluated after 6 months unless further tumor progression has occurred (5, 488, 490, 506). In cases of substantial tumor regression, the possibility of surgical resection of the main residual disease should be considered; this can occasionally be associated with prolonged tumor control (488, 490). Chemotherapy has to be weighed against potential side effects but may be the only alternative, particularly in poorly differentiated tumors.

d. Chemotherapy for poorly differentiated GEP tumors. A high (overall 67% regression rate with a 17% complete regression rate) but short-lasting response, similar to the one described in SCLC, has been obtained in poorly differentiated GEP tumors using the combination of etoposide and cis-platinum (491, 507). In addition, there was a tendency for more prolonged survival compared with the 6-month survival reported in a small group of poorly differentiated carcinoid tumors (508). Although the activity of this regimen for poorly differentiated GEP tumors has subsequently been confirmed in phase II studies (505, 507, 509), results concerning the response rate in well-differentiated GEP tumors have been contradictory, with some studies demonstrating a poor response (505, 507, 509) while others have achieved significant responses in heavily pretreated patients (505) (Table 7; Refs. 505, 507, 509). However, the response to treatment may be limited due to potential nephrotoxicity, particularly in previous heavily pretreated patients; currently, coadministration of amifostine as a means to reduce chemotoxicity is being evaluated (505).

e. Side effects. Even in patients responding to combination chemotherapy, toxic reactions including severe bone marrow suppression, nephrotoxicity (20–75% in patients treated with STZ), and heart failure have been reported in substantial numbers of patients (491). This is more evident in previously heavily pretreated patients and especially with the use of etoposide.

f. Future prospects. To improve response rate and find novel chemotherapeutic regimens, new agents with antitumor activity in NETs are being tried. Phase II trials have shown that high-dose paclitaxel in patients with advanced NETs was associated with minimal antitumor activity with considerable hematological toxicity (510). More recently, a novel specific cytotoxic treatment for serotonin-producing tumors has appeared (511). This treatment is based on the inherent ability of serotonin-secreting cells to take up the inactive compound 5-hydroxy-tryptophan, which is then metabolized via tryptophan hydroxylase to the toxic compound 5,7-dihydroxy-tryptophan (511). In addition, a cytotoxic hybrid between the SS analog vapreotide and doxorubicin has been shown, at least in animal studies, to increase the dose and effect of doxorubicin without increasing the toxicity because it is directed to the tumor cells (512, 513). There are also anecdotal reports of the use of thalidomide, as an antiangiogenic agent, and antagonists of the epidermal growth factor in the therapy of NETs (514). The results of controlled trials with the use of newer antiangiogenic agents will be of considerable interest.

3. Treatment of hepatic metastases. Liver metastases in GEP and other NETs carry a poor prognosis, with a 5-yr survival rate of less than 50%, and are associated with deterioration in the patient's quality of life (126, 515–517). In one small study of untreated patients, progression of tumor was observed in all, with almost a doubling of tumor mass after 1 yr, although there were individuals with disseminated disease who experienced prolonged survival (10, 518). Treatment directed against the hepatic metastases is either surgical (selective segmental liver resection, liver transplantation, and ablative therapy) or medical (vascular intervention leading to ischemia of the area occupied by the tumor) (10, 517, 518). The medical-ischemic treatment of NETs relies on the exclusive blood supply of tumoral tissue from the hepatic artery, in contrast to normal liver parenchyma that mainly relies on portal venous perfusion (10, 518). Ischemia can be achieved by several techniques directed to the hepatic

TABLE 7. Treatment of GEP (well- and poorly differentiated) tumors with etoposide (VP 16) and cis-platinum (CDDP)

First author, year (Ref.)	Protocol	n	Tumor type	Tumor response	Survival (months)
Poorly differentiated GEP					
Moertel, 1991 (507)	VP 16 130 mg/m ² D1–3, CDDP 45 mg/m ² D2–3	18	9 ct, 6 IST, 3 unknown	67% (CR 17%, PR 50%, SD 33%) (8 months) ^a	19 ^{b,c}
Mitry, 1999 (retrospective) (509)	VP 16 100 mg/m ² D1–3, CDDP 100 mg/m ² D1	41		41.5% (CR 10%, PR 31.5%) (9.2 months) SD 34.1%	15 ^{b,c}
Fjallskog, 2001 (505)	VP 16 100 mg/m ² D1–3, CDDP 45 mg/m ² D2–3	9	5 ct, 4 IST	44.4% PR (2 ct, 2 IST) 44.4% SD (3 ct, 1 IST)	
Well-differentiated GEP					
Moertel, 1991 (507)	VP 16 130 mg/m ² D1–3, CDDP 45 mg/m ² D2–3	27	13 ct, 14 IST	ct (PR 0%, SD 84.5%) IST (PR 14%, SD 64%)	
Mitry, 1999 (509)	VP 16 100 mg/m ² D1–3, CDDP 100 mg/m ² D1	11	11 ct	9.5% PR (8.5 months), SD (36.4%)	17.6
Fjallskog, 2001 (505) ^d	VP 16 100 mg/m ² D1–3, CDDP 45 mg/m ² D2–3	27 ^d	13 ct, 11 IST	54% PR (ct 61.5%, IST 45.5%)	

D1, D1-2, and D1-3 refer to day of chemotherapy treatment. ct, Carcinoid tumors; IST, islet cell tumors; CR, complete response; PR, partial response; SD, stable disease.

^a Responses not influenced by tumor function.

^b Not confirmed from a prospective study.

^c Probable increase in survival.

^d Progressive disease.

artery, such as ligation, selective embolization, or temporary occlusion (10).

a. Surgical therapy of hepatic metastases. This form of treatment relies on the predilection of most NETs for developing liver metastases that rarely progress to liver dysfunction and failure despite gross tumor load (516, 517, 519). Because of their slow tumor growth and often incapacitating symptoms related to tumor bulk and hormone production, solitary metastases or multiple lesions confined to one lobe can be surgically resected, aiming either at cure or at removal of at least 90% of tumor burden (516, 517, 519, 520). In patients with GEP tumors, surgical resection was associated with significant prolongation of survival and symptomatic improvement, although it was rarely curative; patients with bilobar disease or more than 75% liver involvement were the least likely to benefit (516, 517, 519, 521). The location and removal of the primary tumor before hepatic resection also contributed to improved survival (517). The introduction of more specific local ablation techniques, which achieve tumor destruction *in situ*, has widened the possibilities for treating liver metastases and has potentially extended the indications for surgery (*e.g.*, by resecting a tumor in one lobe and local ablation in the other, with or without chemoembolization) (520). Several ablative techniques are currently used, including ethanol injections (520); cryosurgery, where tumor cells are killed after injection of liquid nitrogen (-196 C) (522); or radiofrequency ablation, a slow wave diathermy technique that destroys tumor cells by protein coagulation caused by heat (520). Hepatic radioembolization has also been tried, although in a limited number of patients (523). All of these techniques, while promising, still need to be tested prospectively in a large group of patients. Currently, only a small number of retrospective reviews provide some indirect evidence suggesting that surgical resection of hepatic metastases may prolong survival in selected cases, although this is rarely curative (406, 516, 517).

b. Invasive medical therapy of hepatic metastases (hepatic artery embolization-chemoembolization). Selective embolization of the hepatic arteries causes a temporary but complete ischemia (10, 524), with objective symptomatic and hormonal responses of 65 and 81%, respectively (525). Chemoembolization is embolization combined with liver-targeted intraarterial administration of chemotherapy; initially, small particles of iodized oil containing a chemotherapeutic agent are injected and, to obliterate peripheral arterial branches, are followed by sponge particles to embolize larger proximal feeding tumor arteries (10, 515). Contraindications include complete portal vein obstruction and hepatic insufficiency (515, 526). Initial studies showed a symptomatic improvement and significant tumor reduction in response to 5-FU in carcinoid tumors, with a mean duration of 2 yr (527). Similar results were obtained from both prospective and retrospective studies for several types of NETs using other chemotherapeutic agents; in such studies, it has been reported that more than 35% of patients showed objective tumor responses (525, 527–533) (Table 8). During these procedures, SS analogs may be coadministered to avoid life-threatening crises (10). Chemoembolization is more efficient if the bulk of tumor

mass, and particularly the primary tumor, has been resected (532). Therefore, chemoembolization is an alternative to chemotherapy for progressive hepatic metastases in patients with NETs, although it is not clear whether this treatment should be used early or late in the course of the disease (506). However, as other therapies for GEP and other NETs become available, its role needs to be reevaluated (506). The side effects of the procedure are usually mild and transient and mainly constitute the postembolization syndrome (nausea, vomiting, abdominal pain, fever up to 37.5 C , and raised transaminases); major complications (acute renal failure and bleeding peptic ulcers) are extremely rare (515). However, when they do occur they can be life threatening, and we would advise that the procedure is only carried out in major centers with the relevant experience and expertise (534).

c. Other forms of treatment. External radiotherapy has occasionally been attempted for locally unresectable carcinoid and pancreatic islet cell carcinomas. Although a few cases showing substantial tumor regression have been described (464, 535), there is no evidence of the effect of such therapy, which is mainly used for palliation of metastatic disease. Treatment with the injection of murine monoclonal antibodies was associated with substantial biochemical and objective improvement in patients with VIPomas (536).

4. Treatment of NETs with radiopharmaceuticals (endoradiotherapy). Radioiodine for the treatment of thyroid disorders has been the best example of a radionuclide-targeting agent; with the introduction of ^{131}I -labeled MIBG, the field of radionuclide treatment has been extended to a wide range of NETs because more than 90% of chromaffin cell tumors, 70% of carcinoids, and around of 35% of MTC concentrate MIBG (87, 99, 319, 425, 537). The use of this therapy can be considered either early in an adjuvant setting, after surgery to eradicate occult disease, or later for treatment of disseminated disease (538).

a. ^{131}I -MIBG therapy for malignant NETs. Potential advantages of ^{131}I -MIBG therapy are that it is a treatment targeting both primary tumors and distant metastases, it has a preferential radiation delivery to tumoral lesions with relative sparing of normal tissues (mainly β -emission with only a 10% γ -emission contribution), and it has little pharmacological toxicity (55). Most of the patients treated so far had no other therapeutic options or were refractory to conventional treatment strategies, with only a few prospective trials incorporating treatment-naïve patients. Usually, patients had multiple sites of disease as evidenced by scintigraphic ^{123}I -MIBG appearance, a prerequisite for the initiation of treatment (79) (Fig. 7). ^{131}I -MIBG is administered as a slow iv infusion over a period of 60–90 min, and patients are kept in an isotope treatment unit for 4–6 d; to minimize thyroidal ^{131}I uptake, potassium iodide 120–150 mg/d is given starting 2 d before therapy and continued for 8–21 d after therapy (76, 79, 347, 539, 540).

Most centers have used between 100 and 300 mCi (3.7 and 11.1 GBq) of ^{131}I -MIBG per treatment; ^{131}I -MIBG therapy is repeated, usually at 6-month intervals (55, 79, 80, 347, 537). The worldwide cumulative experience using ^{131}I -MIBG treatment in 52 patients with metastatic carcinoid disease

TABLE 8. Response to chemoembolization (CE) in patients with GEP tumors and hepatic metastases

First author, year (Ref.)	<i>n</i>	Tumors	Adjuvant therapy	CE	Symptomatic response	Biochemical	Tumoral response (duration)	Status of disease before CE
Hajarizadeh, 1992 (527)	8	8 ct	Octreotide	5-FU ^a	100%		OR 50%, SD 50% (10.6 months)	
Therasse, 1993 (528)	23	23 ct	Some on octreotide	Doxo ^a	100% (22 months)	91% (18 months)	OR 35%, SD 29.5%	All progressive disease
Ruszniewski, 1993/2000 (515) ^b	24	18 ct, 6 IST	Octreotide	Doxo ^a	73%	57%	OR 33%, SD 22% IST, SD, (80%) (14 months)	All progressive disease/symptoms
Diaco, 1995 (529)	10	10 ct	Octreotide intraarterial 5-FU	Doxo/cisplatin/mitocin C ^a	100%		OR 60% (42.5 months), SD 30% (>6 months)	All patients symptomatic
Mavligit, 1993 (530)	5	5 IST		Cisplatin-vinblastin ^a	NF	NF	80% (18.5 months)	1 progressive disease
Clouse, 1994 (531)	20	11 ct, 9 IST	Octreotide	Doxo	100%	90%	84% (8.5 months)	15 progressive disease
Perry, 1994 (532)	30	15 ct, 15 IST	Octreotide	Doxo ^a		69%	OR 78%	Symptoms, no candidates for surgery
Drougas, 1998 (533)	15	15 ct	Octreotide	5-FU ^a	75% ^c	100%	OR 77%	All progressive disease

ct, Carcinoid tumors; IST, islet cell tumors; OR, objective response; SD, stable disease; Doxo, doxorubicin.

^a WHO response criteria.

^b Prospective trial.

^c Assessment of quality of life.

was reported in 1994; an objective tumor response was recorded in 15%, with a symptomatic response in 65% of the patients (97). Since then, the results of treatment in another 30 patients were reported demonstrating a 60% symptomatic response, but a hormonal response of only 12.5% and no reduction in tumor mass (79, 347, 537, 541). Very few cases of malignant islet cell tumors with ¹³¹I-MIBG treatment have been described, reflecting the relatively poor ¹²³I-MIBG uptake of these tumors (79). Scintigraphy with ¹¹¹In-pentetreotide is more sensitive than scintigraphy with ¹²³I-MIBG (99), and it is expected that treatment with ⁹⁰Y-labeled SS analogs will be applicable to a larger population of patients with NETs, particularly islet cell tumors, and will also locate the same lesions identified by ¹³¹I-MIBG; the results of phase II trials are now becoming available (99, 542, 543). In occasional tumors that show complementary uptake with ¹¹¹In-pentetreotide to non-¹²³I-MIBG avid lesions, concomitant use of ¹³¹I-MIBG and ⁹⁰Y-labeled SS analogs may be another therapeutic option (99, 544).

Hematological toxicity is the main significant side effect of ¹³¹I-MIBG therapy (mainly leucopenia and thrombocytopenia (339, 545). Severe myelosuppression is mainly seen in patients with widespread bone metastases and diffuse bone marrow involvement, and in patients heavily pretreated with chemotherapy (347, 546). Transient hepatic failure, presumably secondary to widespread hepatic lesion necrosis, has also been described (79, 547). We have also reported premature ovarian failure (Ref. 79; also see Ref. 548).

b. Radiopharmaceutical therapy with ¹¹¹In octreotide. ¹¹¹In emits mainly γ -radiation, Auger and conversion electrons, and exerts an antiproliferative effect in malignant tumors if their principal target, cellular DNA, is within the particle range (54, 83, 549). Thirty end-stage patients with NETs, including 20 patients with GEP tumors, were treated with [¹¹¹In-DTPA] octreotide; 21 of these patients, all with pro-

gressive disease, received a cumulative dose of 20 GBq (83). Of these 21 patients, six showed an antiproliferative effect demonstrated as shrinkage of the tumor, whereas in another eight patients there was stabilization of disease; there was a tendency toward better results in patients with high tumor uptake (83). In 27 additional patients treated with two doses of ¹¹¹In pentetreotide, an objective partial response occurred in two (8%), whereas significant tumor necrosis occurred in seven (27%) patients without any major side effect; the median survival was 18 months, compared with 6 months expected (550). However, in recent studies it was shown that the response may not be sustained in time, probably due to the preferential survival of resistant clones (551, 552), and that its efficacy in large tumors and end-stage patients is limited (551, 552). Therefore, it was suggested that ¹¹¹In-pentetreotide should be given either in combination with β -emitters or to eradicate micrometastases (553). Toxicity of the treatment was generally low, with 100 GBq being the maximum tolerable dose (553).

c. Radiopharmaceutical therapy with ⁹⁰Y octreotide/DOTA-TOC. Radionuclides emitting β -radiation have greater therapeutic potential because the particles they emit have sufficient energy to cause cell damage, and they deliver higher radiation doses in a larger part of the tumor without penetrating very far into surrounding tissue (54, 83, 554). The same SS analog (Tyr³-octreotide) used for diagnosis has been coupled to a bifunctional chelating agent (DOTA) for the complexing of ⁹⁰Y, a pure energetic β -emitter well suited for internal radiotherapy, ⁹⁰Y-DOTA-D-Phe¹-Tyr³-octreotide (⁹⁰Y-SMT487, OctreoTher, Novartis, Basel, Switzerland) (83, 99, 555). Concomitant iv administration of amino acids reduces renal radioactivity uptake without altering tumor uptake (73, 554, 555). Thirty-nine patients with a variety of tumors received OctreoTher in an escalating dosage with minor toxicity, whereas the objective response rate (complete

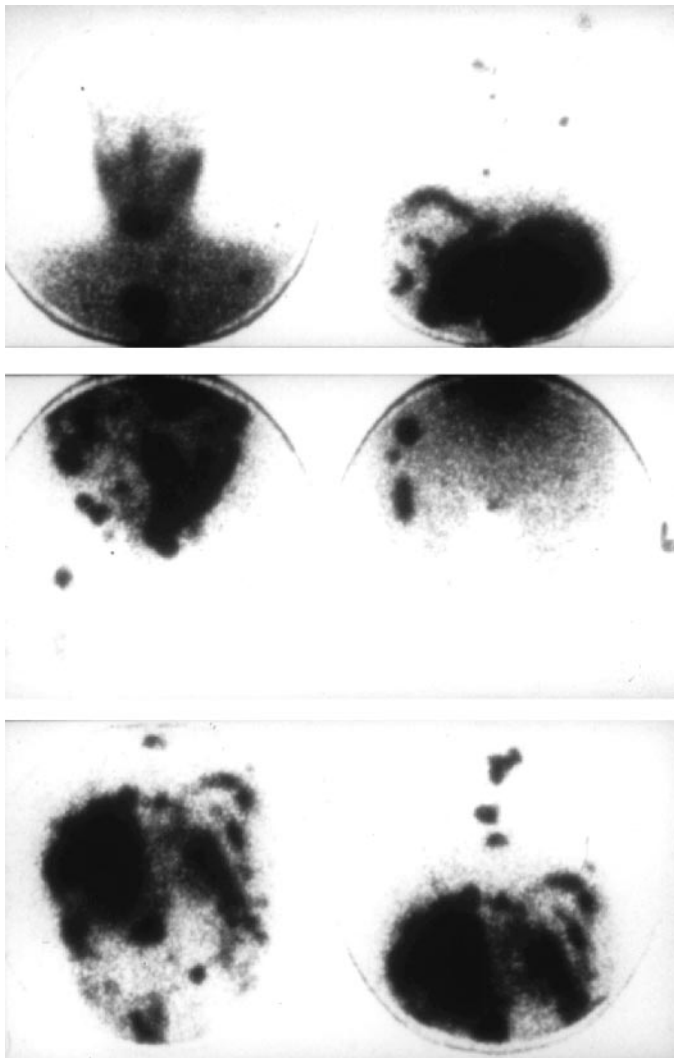


FIG. 7. Posttherapy scan after ^{131}I -MIBG in a patient with a metastatic pheochromocytoma. The *top panel* shows uptake in the mediastinum and left shoulder; the *middle and lower panels* show metastases in the pelvis, femur, spine, and ribs. [Adapted with permission from Mukherjee *et al.*: *Clin Endocrinol (Oxf)* 55:47–60, 2001 (79) © Blackwell Publishing.]

and partial responses) was 23% and disease stabilization 64% (80, 556). A Novartis-sponsored phase II study is currently ongoing to test the efficacy of OctreoTher in patients with a variety of disseminated NETs (also see Refs. 73, 554, 555) (Fig. 8). There is also experience using ^{90}Y -DOTATOC, a compound similar to OctreoTher (554, 557); of 10 patients with metastatic NETs treated with ^{90}Y -DOTATOC, six reported improvement in tumor growth, hormonal secretion, and symptoms, with minimal side effects, whereas the others showed stable disease (84, 554, 557). Another 29 patients were treated with ^{90}Y -DOTATOC, six of whom obtained a remission, whereas 20 had disease stabilization (543, 557). In a more recent phase II nonrandomized study involving 37 patients with progressive GEP tumors, an objective tumor response of 24% (36% for pancreatic tumors) was noted, without serious toxicity; there was also a suggestion of a more favorable long-term outcome (542).

d. Radiopharmaceutical therapy with ^{90}Y -lanreotide. Lanreotide shows a slightly different affinity to octreotide for SS receptors (558). After a 25% regression of liver metastases and substantial symptomatic improvement in a patient with a malignant gastrinoma after four infusions of 1 GBq of ^{90}Y -lanreotide (559), a phase IIa Multicenter Analysis of a Universal Receptor Imaging and Treatment Initiative (MAURITIUS) European study was organized (558). ^{90}Y -DOTA-lanreotide (1 GBq) was given iv over 30 min without kidney protection in 39 patients with GEP tumors, including 34 carcinoid tumors. After two cycles of ^{90}Y -DOTA-lanreotide, the treatment was discontinued in the case of progressive disease; otherwise, another two cycles were given. Over a 3-yr follow-up period, 20.5% of patients achieved regression, whereas 43.6% demonstrated stable disease (558). However, because OctreoTher shows higher tumor uptake in patients with NET lesions compared with lanreotide, the former should be considered as the treatment of first choice, where available (558).

e. Radionuclear therapy with [^{177}Lu -DOTA Tyr 3]-octreotate. To overcome the limitations of administering tumoricidal doses of radiotherapy to nonoctreotide avid lesions and the lack of uptake to certain areas due to tumor heterogeneity, several β -emitters, in addition to ^{90}Y , such as ^{153}Sm , ^{177}Lu , and ^{186}Re are also being considered, along with the newest SS analog Tyr 3 -octreotate, which exhibits the highest affinity for SS receptor type 2 (553). ^{177}Lu -DOTA-Tyr 3 -octreotate shows a very high tumor uptake with a very good ratio of tumor-to-kidney uptake, thus suggesting an ideal compound for radionuclide therapy (553). Radiotherapy with ^{177}Lu -DOTA-Tyr 3 -octreotate has recently been used in 18 patients with a variety of progressive NETs, with 39% of patients showing a partial remission (560). It has also been suggested

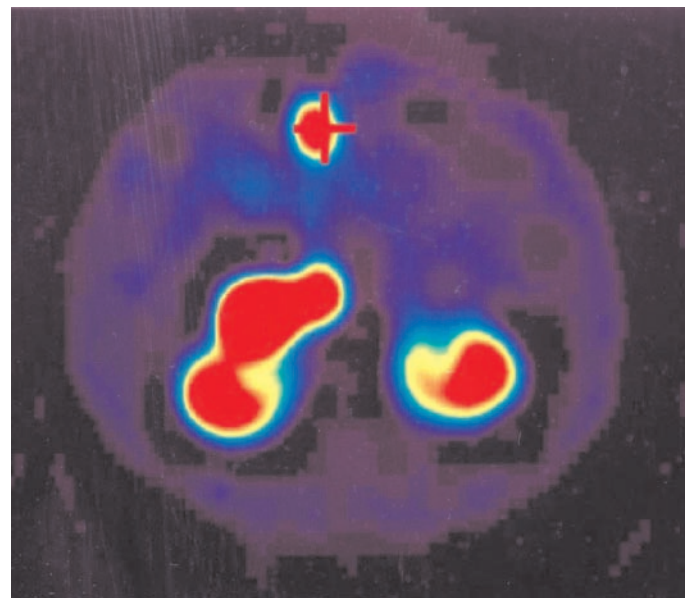


FIG. 8. Imaging of a patient with a malignant insulinoma who received a therapeutic dose of ^{90}Y -trium-octreotide (OctreoTher); the primary lesion in the head of the pancreas is clearly demonstrated in the SPECT reconstruction (marked with a *cross*) (courtesy of Dr. K. E. Britton, Department of Nuclear Medicine, St. Bartholomew's Hospital, London, UK).

that in patients with tumors of different sizes, including small metastases, the administration of combinations of different radionuclides, *e.g.*, ^{90}Y , which is optimal for larger tumors, and ^{177}Lu , which is optimal for smaller tumors, coupled to octreotide and/or octreotate may be particularly useful (553).

f. Future prospects. It is likely that “endoradiotherapy” for the treatment of NETs will develop considerably within the next few years. Until now, indications for ^{131}I -MIBG have been limited to palliative treatment of malignant chromaffin cell and occasionally carcinoid tumors, most often at an advanced disease stage. The recent application of ^{90}Y -labeled SS analogs represents a major advantage, because these radionuclides can be taken up by a wider number of NETs (99). Ideally, these radionuclides should be used in patients with small tumor targets (not more than 1–2 cm in diameter) (561). Combination therapy with both ^{131}I -MIBG and OctreoTher or $^{111}\text{In}/^{90}\text{Y}/^{177}\text{Lu}$ -octreotide remains an attractive theoretical option, after as complete a surgical resection as possible to ensure good uptake of the radiopharmaceutical by the remaining tumor target. If treatments are repeated regularly, it is likely that the disease can be at least stabilized for a period of several years, if not cured. In addition, newer SS analogs in combination with different emitters are in development that might show superior imaging and therapeutic properties. Finally, it may be hoped that the efficacy of endoradiotherapy will be improved by coadministration of chemotherapeutic drugs whose radiosensitizing properties may be synergistic with those of irradiation (80). Immune system activation for the control of micrometastatic disease may also be required to achieve complete control and eventual cure. Compounds antagonizing tumor angiogenesis by binding to $\alpha_v\beta_3$ receptors on newly formed blood vessels could be combined with DTPA-Tyr³-octreotate from hybrid peptides that can bind to both SS receptor 2 and $\alpha_v\beta_3$ receptors and can thus be used for both scintigraphy and radionuclide therapy (562). In addition, transfer of genes encoding for the expression of SS receptors 2 and 5 to receptor-negative tumors may render them responsive to treatment with these agents (563).

D. Multidisciplinary approach—quality of life

The increasing number of investigative procedures and therapeutic options for both the diagnosis and treatment of NETs is best dealt with by a multidisciplinary team. Such a team should include physicians with a special interest in NETs, pathologists, endocrinologists, gastroenterologists, interventional radiologists, surgeons, oncologists, and a nuclear medicine expert (52, 131). Diagnostic procedures should be critically reviewed to help establish a consensus on the best evidence-based management, including invasive procedures such as chemoembolization or repeated surgical procedures. Due to the relative rarity of such tumors, optimum management should be undertaken in centers with relevant experience and expertise (52, 131). Because the majority of these tumors are slowly growing and even patients with disseminated disease may have prolonged survival, early involvement in palliative team programs may be help-

ful. To evaluate the results of current management, establish guidelines, and develop new therapeutic trials, multicenter collaborations are particularly helpful. However, this does not always occur; a recent retrospective analysis from Italy reviewing all GEP tumors treated over the last 20 yr found that a such multidisciplinary approach was practiced in only a small proportion of patients (232). In addition, attempts to improve the quality of life should be sought because patients with metastatic disease may still experience prolonged survival, and this should be weighed against the potential side effects of any systemic treatment (116).

E. Symptomatic and systemic treatment of benign and malignant chromaffin cell tumors (pheochromocytoma and paraganglioma)

Surgery with complete resection, when possible, or debulking of the primary tumor should be as radical as possible to obtain disease-free, long-term survival (111). Antihypertensive drugs that block the effects of catecholamine and α -methyl tyrosine, which inhibits catecholamine synthesis, are used for control of the symptoms, but these therapies do not inhibit the growth of these tumors (111, 344, 347).

1. Symptomatic therapy. Surgical resection is the treatment of choice for isolated unilateral pheochromocytomas, and even cases of localized metastases should always be carried out as an elective procedure after careful preoperative preparation (115, 344). The resection of these tumors has great potential for intra- and postoperative complications, which are substantially minimized by adequate blood pressure control and close monitoring of fluid balance (115, 357). Blood pressure control is achieved preoperatively with the mixed α_1/α_2 noncompetitive adrenoreceptor antagonist phenoxybenzamine, starting at a dose of 10 mg orally up to 10–20 mg four times daily (115, 357). After dose stabilization, the β_1/β_2 antagonist propranolol, at a dose of 40 mg three times a day, is given to avoid reflex tachycardia, although much higher doses may be required (344). Newer selective α_1 -antagonists such as terazosin, prazosin, and doxazosin can also be used, particularly because they may be less likely to produce reflex tachycardia (564). In addition, calcium-channel blockers can be used either alone or as an adjunct to α -blockade in high-risk patients or where these drugs are contraindicated (115, 565). However, despite adequate α -blockade, significant elevations of blood pressure and rarely hypertensive crises may still occur, particularly during manipulation of the tumor, followed by severe hypotension on tumor removal (115, 344). Although hypertensive episodes can be treated with intermittent iv injections of phentolamine, this drug can cause repeated cycles of hyper- or hypotension (344). Sodium nitroprusside should be used to obtain a gradual and controlled reduction of arterial blood pressure through continuous iv infusion. Nifedipine capsules taken sublingually have also been used with success (115). For patients with inoperable, malignant, recurrent, or multicentric tumors, long-term medical therapy using α - and β -adrenergic blockade is the treatment of choice (115). Another approach is to decrease catecholamine production from the tumor by using α -methyl-p-tyrosine, which inhibits the rate-limiting enzyme

tyrosine hydroxylase (566). Circulating catecholamine can be reduced up to 80%, but its use is occasionally associated with side effects (115). A case of an objective tumor response has been described with the use of metyrosine but has not been substantiated in other studies; however, metyrosine can be used as an adjuvant to chemotherapy (567–569). The combination of α/β blockers with metyrosine has been shown to exert a synergistic effect (Ref. 115; also see Ref. 342).

2. Systemic therapy. The principal therapy for malignant chromaffin cell tumors is resection and catecholamine blockade (355). However, additional treatment will be required for inoperable symptomatic tumors or tumors with extensive disease after resection (355). This is particularly important because survival analysis in malignant pheochromocytomas has shown two subsets of patients; approximately 50% of patients have a more aggressive course and die within 4–5 yr, whereas the others show a more indolent course and survive for many years even without treatment (114, 116, 346). It has therefore been suggested that early mortality probably results from progression of the malignancy, rather than hormonal hypersecretion, thus necessitating further aggressive treatment (114). Tumor biology may be a powerful tool directing further management; however, there are not enough studies applying currently established or other markers of disease aggressiveness in chromaffin cell tumors.

Short-term or long-term administration of SS analogs has not shown any clinical benefit, although occasional biochemical responses have been obtained (570–573). However, SS analogs may still be of value in individual patients (570, 574). INF has very rarely been used as the sole treatment in patients with pheochromocytomas with some success (575). Chemotherapy with either single agents or a combination of agents has also been tried as the last option in patients with malignant chromaffin cell tumors (345). Individual cases have been treated with a variety of chemotherapeutic agents that occasionally have shown clinically useful responses (345, 576). Due to the resemblance of these tumors to neuroblastomas, which have shown an overall response rate of 80% to the regimen of cyclophosphamide, vincristine, and dacarbazine (CVD), this regimen has been used more extensively in patients with malignant chromaffin cell tumors. The largest series of 14 patients showed a 79% hormonal and 57% tumor response with minimal side effects, mainly bone marrow toxicity and hypotension (114). This was not a randomized study, and there was no evidence of any prolongation of survival with this form of treatment (114). Several other reports have confirmed the efficacy of this regimen, including a large number of patients treated in Japan (364, 577). Although most responses are transient without any clear effect on long-term survival (114), occasional individual long-term survivors have also been described (578) (Table 9; see Refs. 114, 345, 568, 569, and 577–586). Chemotherapy with CVD should be performed under adequate α -blockade, because life-threatening hypertensive crises from excessive catecholamine release have been described, even in asymptomatic patients (584). The combination of CVD chemotherapy with α -methyl-p-tyrosine has been shown to exert a synergistic effect in the control of excessive catecholamine release in individual cases (569). CgA and catecholamine measure-

ments are the best biochemical markers, not only suggesting the diagnosis of malignant chromaffin cell tumors but also in gauging the response to treatment (364).

External radiotherapy has a mainly palliative role in relieving pain, especially in patients with localized bony metastases; its effectiveness is limited in a minority of cases and is temporary, requiring repeated courses of irradiation (346, 348). There have been, however, occasional reports in which external radiotherapy, in addition to local control, combined either with chemotherapy or therapy with ^{131}I -MIBG, also exhibited some hormonal and tumoral response (580, 587–589). Chromaffin cell tumors were the first tumors to be treated with ^{131}I -MIBG, and the results of 106 evaluable patients with malignant pheochromocytomas were originally presented at the International Workshop in Rome in 1991 (539). The vast majority of patients had disseminated disease and had failed to respond to, or relapsed after, all previous treatment including chemotherapy (539, 590). Symptomatic improvement related to catecholamine hypersecretion was obtained in almost all cases (reduction in blood pressure, pain relief, reduction of daily doses of antihypertensive drugs), whereas an overall tumor response (partial tumor response or stabilization of the disease) was obtained in 58% of the patients (590). Soft tissue deposits generally responded better than bone metastases, and small tumor sites showed a better response than large ones (55, 76). Therefore, surgical debulking is strongly recommended before radionuclide therapy with MIBG (55, 79). More recently, Loh *et al.* (347) in 1997 reviewed the results of ^{131}I -MIBG therapy in patients with malignant chromaffin cell tumors (77% of these patients had pheochromocytomas, 21% had paragangliomas, and 2% had both types of tumors). Initial symptomatic improvement was achieved in 76% of patients, hormonal responses in 45%, and tumor responses in 30%; very few patients had complete tumor and hormonal responses (347). The overall number of patients with metastatic paragangliomas treated with ^{131}I -MIBG is smaller than those with pheochromocytomas; however, in general it appears that these tumors behave similarly to metastatic pheochromocytomas in their response to ^{131}I -MIBG therapy (79, 537). The cumulative reported therapeutic response of ^{131}I -MIBG therapy in patients with pheochromocytomas and paragangliomas is shown in Table 10 (Refs. 590–596); see also Ref. 597). Although controlled studies are lacking, these data do suggest that ^{131}I -MIBG treatment may be associated with increased survival with occasional sustained complete remissions or cures (79, 347). Occasionally, malignant pheochromocytomas may be octreotide but not MIBG avid; in such cases therapy with octreotide may be of value (544). A few patients with malignant chromaffin cell tumors have already been treated with ^{111}In -octreotide and ^{90}Y -octreotide (DOTATOC), with some obtaining disease stabilization (542, 598). In cases of malignant chromaffin cell tumors with liver metastases that are resistant to chemotherapy, transarterial embolization may be useful in achieving transient symptomatic and hormonal improvement in patients under close peri- and postoperative monitoring of blood pressure (569, 577, 599). Radiofrequency ablation of metastases may also be helpful in selected patients (600). The majority of pheochromocytomas with MEN II, NF1, and VHL disease are benign; in cases with a strong family history

TABLE 9. Combination chemotherapy in malignant chromaffin cell tumors

First author, year (Ref.)	Scheme	n	Tumor	Symptomatic	Hormonal	Tumoral
Keiser, 1985 (579)	Cyclophosphamide 750 mg/m ² D1 Vincristine 1.4 mg/m ² D1 Dacarbazine 600 mg/m ² D1–2	3	Pheo	3/3	2/3	2/3 PR
Averbuch, 1988 (114)	Cyclophosphamide 750 mg/m ² D1 Dacarbazine 600 mg/m ² D1–2	14	Pheo	80%	79% (CR 3, PR 8) 22 months duration	57% (CR 2, PR 6) 21 months duration
Siddiqui, 1988 (580)	CVD	1	Pheo	1	1 (transient)	NR
Proye, 1992 (581)	CVD	3	Pheo		50% transient	NR
Senan, 1992 (582)	CVD	2	Pheo	2/2	100%	NR (SD)
Schlumberger, 1992 (345)	Etoposide, cisplatin Cyclophosphamide 5-FU/STZ CVD	4 1 1 1	Pheo		1/7 PR	NR
Ein, 1994 (586) ^a	Dacarbazine/adriamycin/ novantrone, cyclophosphamide, adriamycin	2	1 Para/1 Pheo			1/2 ^b
Sasaki, 1994 (583)	CVD	1	Pheo (MEN II)		PR	PR
Wu, 1994 (584)	CVD	2	2 Pheo (INFI)	1/2		NR
Noshiro, 1996 (585)	CVD	1	1 Pheo/1 Para	1/1	2/2	1 PR
Tada, 1998 (569)	CVD	3	Pheo		3 (PR)	NR
Arai, 1998 (568)	CVD	1	Pheo	1	1	NR
Takahashi, 1999 (577)	CVD	1	Pheo			PR
Iwabuchi, 1999 (578)	Vindesine 6 mg/m ² D1 Dacarbazine 600 mg/m ² D1–2	1	Pheo	1/1	1/1	NR (survived 7 yr)
Rao, 2000 (364)	CVD Cyclophosphamide 750 mg/m ² D1 Vincristine 1.4 mg/m ² D1 Dacarbazine 600 mg/m ² D1–2	1 9	Pheo Pheo	0/1	0/1 ↓ CgA 5/9	NR 5/9 ^b

D1–2, Days of chemotherapy; CR, complete response; PR, partial response; NR, no response; Pheo, pheochromocytoma; Para, paraganglioma; ↓, reduced; SD, stable disease.

^a Pediatric cases.

^b No WHO criteria so cannot comment.

of malignant pheochromocytoma, earlier surgical intervention should be considered (Ref. 355; also see Ref. 548).

3. Future prospects. Although treatment with ¹³¹I-MIBG may initially be effective, uptake in the various lesions decreases with time due to an acquired resistance by the tumoral tissue or an anaplastic transformation of the tumor (55, 76). Thus, the integration of ¹³¹I-MIBG therapy with chemotherapy can be applied to avoid the emergence of resistant clones that do not take up MIBG (55, 76, 539). However, a recent prospective trial combining ¹³¹I-MIBG with CVD chemotherapy was not particularly encouraging for malignant pheochromocytomas, although an additive antitumor effect was demonstrated; pretreatment with ¹³¹I-MIBG increased toxicity, which curtailed the proposed chemotherapy protocol (601). More recently, the issue of administering chemotherapy before treatment with ¹³¹I-MIBG was raised, although these data were derived from a retrospective analysis (602). Based on initial studies on carcinoid tumors, it was suggested that pre dosing with nonradiolabeled MIBG can improve ¹³¹I-MIBG tumor targeting and enhance its therapeutic effect in patients with NETs that accumulate MIBG (81, 603).

F. Treatment of medullary thyroid carcinoma

Total thyroidectomy with central lymph node dissection with or without an ipsilateral modified neck dissection is the initial treatment of choice (383). Once gene carriers have been identified, prophylactic thyroidectomy at an early age should be offered: this may be curative and has significantly improved the prognosis of FMTC (20, 382).

1. Treatment of residual or recurrent disease. In patients with postoperative persistent disease and positive imaging studies, there is increasing evidence that they should undergo a second operation (110, 380, 383). In patients with evidence of noncurable and inoperable disease or occult disease, close clinical observation and monitoring of changes in the serum calcitonin concentration are required. It appears that there are two subsets of patients; the great majority will remain stable for many years and will require no additional treatment, except for long-term follow-up (381). Persistent hypercalcitoninemia postoperatively in patients with sporadic and FMTC is associated with overall 90% and 86% 5- and 10-yr survival rates (362). The frequent long survival without symptoms or evidence of progression, even after the diagnosis of distant metastases, and the poor results of chemo-

TABLE 10. Response to ¹³¹I-MIBG therapy in patients with malignant chromaffin cell tumors

First author, year (Ref.)	No. of patients	Dose (mCi)	Tumor response					Biochemical response				
			CR	PR	SD	DP	NR	CR	PR	SD	DP	NR
Shapiro, 1991 (539)	28	479	0	2	16	9	1	0	12	6	10	0
Lewington, 1991 (546)	13	632	0	2	11	0	0	0	8	0	0	5
Lumbroso, 1991 (591)	9	245	0	1	1	4	3	0	1	1	4	3
Krempf, 1991 (409)	15	651	0	5	7	3	0	4	3	6	2	0
Fischer, 1991 (592)	13	652	0	2	7	4	0	NR	NR	NR	NR	NR
Bestagno, 1991 (593)	6	599	0	2	3	1	0	0	4	1	1	0
Troncone, 1991 (590)	5	408	1	1	1	2	0	0	2	3	0	0
Colombo, 1991 (594)	4	281	0	0	3	1	0	0	1	3	0	0
Hoefnagel, 1991 (607)	4	700	0	1	3	0	0	0	3	0	0	1
Loh, 1997 (347)	3	505	1	0	1	1	0	1	0	2	0	0
Nakabeppu, 1994 (595)	3	295	0	1	1	1	0	0	2	0	1	0
Castellani, 2000 (537)	12	378	1	4	6	1	0	1	6	1	0	3
Sakahara, 1994 (596)	5	206	0	2	2	1	0	0	1	4	0	0
Bomanji, 1993 (540), Mukherjee, 2001 (79)	15	638	0	6	3	5	1	2	6	1	0	6
Sisson, 1994 (545)	6	206	0	2	2	1	NR	0	2	2	2	0

Only studies with more than three patients are included. CR, Complete response; PR, partial response; SD, stable disease; DP, disease progression; NR, not recorded.

therapy in patients with proven metastases (389) suggest that the option of no treatment is entirely reasonable if the disease does not progress while the patient is under careful observation (389). The presence of more than three metastatic lymph nodes at the time of the first operation is a major predictor of disease recurrence (389). However, for the minority of patients who have active hormonal secretion or in whom the disease progresses rapidly, further treatment will be required (110, 380, 381).

External beam radiotherapy was originally reported to be useful in selected groups with MTC, particularly in patients with large tumor load and worst prognostic factors (382, 604), although earlier studies considered that patients with MTC were relatively radioresistant (605). A recent retrospective analysis of patients with a high risk of recurrence (microscopic residual disease, extraglandular invasion, or lymph node involvement) who received external irradiation besides surgery showed that they developed less local/regional relapse compared with patients who were treated with surgery alone; however, no effect on survival was documented (382). Currently, there are no clear indications for the role of external radiotherapy in patients with postoperative high risks for recurrence or residual disease, mainly due to the lack of a randomized control trial. We therefore suggest that external radiotherapy can be used in patients with inoperable tumors and expanding postoperative lesions for palliation, whereas its application for local control in patients with residual disease should be decided individually, considering the presence of other risk factors (383, 605). Currently, there is no role of ¹³¹I for eradicating residual thyroid tissue in the treatment of MTC, because there was no difference in respect to recurrence, alterations in calcitonin levels, or 5- and 10-yr survival rates along patients who were treated with surgery alone and those who received adjunctive ¹³¹I therapy (606).

Because ¹³¹I-MIBG is taken up by a number of MTC tumors, its administration has been proposed as a radiometabolic treatment for those patients who present a significant scintigraphic uptake (10, 79, 99, 116). The worldwide cumulative experience was reported in 1991 and 1994 for 18 and 22 patients, respectively (10, 72, 590, 607). An objective tumor

response was documented in approximately 30% of patients, with a symptomatic response in 50%. Since then, four additional reports including 17 patients have appeared demonstrating a complete response in one patient plus two partial responses, whereas no response was obtained in the rest of the patients (55, 79, 537). On several occasions, symptomatic and hormonal responses have been obtained irrespective of objective tumor responses (55, 79). Thus, although tumor disappearance is exceptional, there is considerable improvement in symptoms and beneficial effects on hormonal and tumor control in a substantial number of patients (79, 80). ¹³¹I-MIBG is an expensive and complex therapy, and the response is unpredictable, although occasional patients may show a therapeutic response. Radionuclide therapy with SS analogs has also been used occasionally. A few patients with MTC have also received ¹¹¹In-octreotide or ⁹⁰Y-lanreotide in the MAURITIUS trial (552, 558); although this was not a homogeneous group of patients, the initial results were encouraging, supporting further prospective studies for the use of this form of therapy in patients with advanced MTC disease.

Although a few studies have shown some hormonal improvement after treatment with SS analogs (608), biological or morphological parameters were not significantly improved in larger series (609). In occasional patients, continuous treatment with high-dose SS analogs can offer some improvement (69). Only a few series have formally assessed the effect of therapy with INF, and no major effect was found (470, 473). The combination of octreotide (0.3 mg/d) with INF, although well tolerated, was not associated with any tumor response and only a selective biochemical response; however, the combination of lanreotide with INF was associated with substantial biochemical response and stabilization of the disease in the majority of patients reported (382, 610, 611). The results of this treatment combination need to be assessed in a prospective study. Chemotherapy is usually restricted to a minority, less than 20%, of patients with MTC with rapidly progressive disease (382, 383). The most effective agent is doxorubicin, which has produced partial response rates up to 30% either alone or in combination (382).

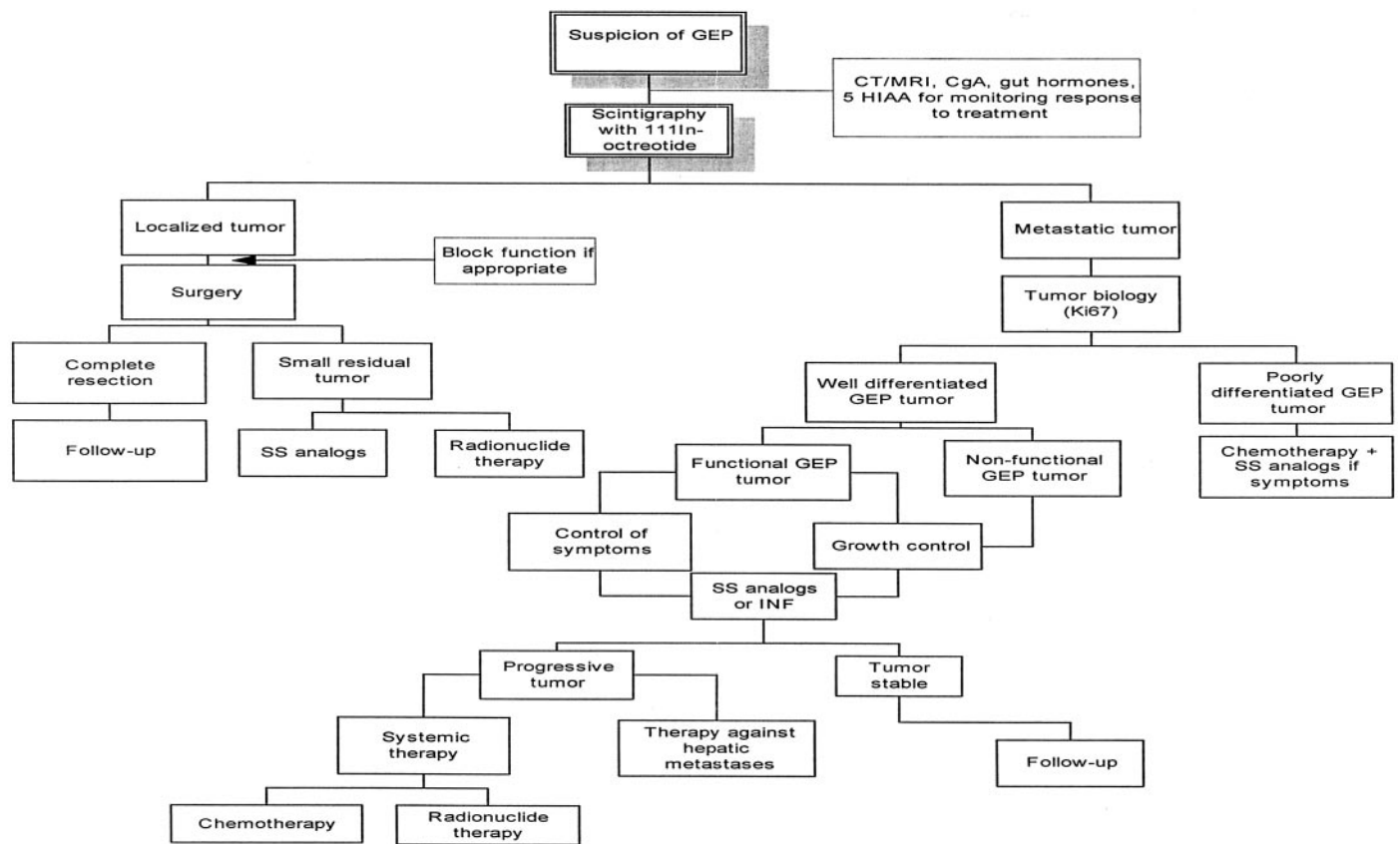


FIG. 9. Suggested flow-plan for the assessment and general therapeutic approach to gastroenteropancreatic tumors. Specific modalities of treatment, their sequential use, and the order of their use will be determined to some extent by local availability and expertise. It should be emphasized that a true evidence base for many of these recommendations is lacking.

Responses have also been less than impressive in other small series using combination chemotherapy with agents including 5-FU and dacarbazine, cyclophosphamide, methotrexate, and cis-platinum (110, 116, 382, 612). In a recent review of the literature, Orlandi *et al.* (382) analyzed 144 patients treated with a variety of chemotherapeutic schemes and showed a 3% complete and a 27% partial tumor response; however, no clear benefit was demonstrated on survival. Comparing the results from different chemotherapeutic treatments, it seems that doxorubicin and the combination of doxorubicin and cis-platinum, or 5-FU and dacarbazine, produce similar response rates (382). Chemotherapeutic agents have also been used to enhance the tumoricidal activity of ionizing agents, but it is still difficult to reach firm conclusions regarding their efficacy because most series included only a limited number of patients (110, 613). However, mainly due to the low toxicity, regimens containing 5-FU and dacarbazine might be indicated as the first-line treatment of advanced MTC, although clearly controlled studies are indicated (498). Radiometabolic therapy with anti-CEA-labeled monoclonal antibodies has also been proposed. A few phase I/II trials have shown initially promising results but await confirmation from further studies (614, 615). Recent studies have shown that vaccination with calcitonin and/or CEA peptide-pulsed dendritic cells results in the induction of a cellular, antigen-specific immune response in patients with MTC, leading to

beneficial responses in patients with residual or recurrent disease (Refs. 616 and 617; also see Refs. 618 and 619).

2. *Future prospects.* Recently, in patients with RET gene-activated mutations and subsequent increased tyrosine kinase activity, treatment with specific RET oncoprotein inhibitors is undergoing clinical trial, offering an alternative treatment strategy for tumors sustaining oncogenic activation of RET (620).

VIII. Summary and Final Conclusions

Clinical suspicion based on the presence of characteristic symptoms and/or syndromes may suggest the presence of an NET, which then requires assessment of specific or general tumor markers that currently offer high sensitivity in establishing the diagnosis and can also have prognostic significance. Measurement of specific amines or hormones establishes the biochemical confirmation of a GEP tumor, whereas measurement of CgA appears to be a universal marker. Similarly, both urinary catecholamines and plasma metanephrine estimations are highly sensitive and specific for a chromaffin cell tumor, whereas basal or stimulated plasma calcitonin offers the highest diagnostic accuracy for the presence of MTC. Current histopathological and molecular techniques not only provide the diagnosis but can also,

to some extent, predict the biological behavior of the tumor. Molecular screening is gradually replacing other biochemical tests when a familial syndrome is suspected; in such cases, counseling is essential. The detection rate of all imaging modalities has greatly improved due to advantages in methods such as endoscopic ultrasonography, CT, and MRI. The introduction of nuclear techniques such as scintigraphy with SS analogs and PET imaging have greatly helped in the identification of occult lesions and in the staging of NETs. Successful treatment of disseminated NETs requires a multimodal approach aimed at symptomatic control, prevention of further tumor growth, and hopefully ultimate cure, although the latter is rarely possible. SS analogs can very frequently control the symptoms attributed to functional GEP tumors and facilitate the preparation of such patients for surgical intervention. Similarly, optimal preoperative control of symptoms attributed to excessive catecholamine secretion or other metabolically active substances derived from chromaffin cell tumors allows these patients to undergo potentially curative surgical procedures safely. Radical tumor surgery is a prerequisite because it is the only available curative approach; recently, the surgical approach has become more aggressive, including wide resections of metastases together with enucleation of liver metastases and/or hepatic artery embolization with adjuvant chemotherapy or focal hepatic ablation techniques. If surgical intervention is not possible, treatment should be guided according to currently established classification systems and prognostic factors. Well-differentiated and slow-growing GEP tumors should be treated with SS analogs or INF- α alone or in combination, although our preference is to exhibit SS analogs at an early stage, and we rarely add INF. Chemotherapy should be considered for poorly differentiated and progressive GEP tumors. Therapy with radionuclides, ^{131}I -MIBG for chromaffin cell tumors and treatment with radiolabeled SS analogs for other NETs, may be used for tumors exhibiting uptake to a diagnostic scan either after surgery to eradicate microscopic residual disease or later if conventional treatment or biotherapy fails. Alternatively, chemotherapy can be used in patients with GEP tumors and progressive disease, despite biotherapy or treatment with radiolabeled SS analogs, and in patients with disseminated chromaffin cell tumors and MTC. However, such an approach should always consider the patient's performance and comfort status, the growth rate of the tumor, and the side effect profile. The possibility that these tumors may occur in the context of endocrine syndromes with the involvement of other tissues and other family members should always be considered, and treatment should be directed accordingly. Maintenance of the quality of life should be a priority, particularly because patients with disseminated disease may experience prolonged survival, and the expected efficacy of treatment should be weighed against possible adverse effects. Finally, a suggested flow-plan for the assessment and general therapeutic approach to these tumors, particularly in GEP tumors, is included in Fig. 9.

Acknowledgments

Address all correspondence and requests for reprints to: Prof. A. B. Grossman, Endocrine Oncology, Department of Endocrinology, St. Bar-

tholomew's Hospital, London EC1A 7BE, United Kingdom. E-mail: a.b.grossman@qmul.ac.uk

G.M.B. and A.B.G. have received payments for services from Novartis (Basel, Switzerland) and Ipsen (Paris, France). G.A.K. received payments for services from Novartis.

References

- Rindi G, Villanacci V, Ubiali A, Scarpa A 2001 Endocrine tumors of the digestive tract and pancreas: histogenesis, diagnosis and molecular basis. *Expert Rev Mol Diagn* 1:323–333
- Solcia E, Rindi G, Paolotti D, La Rosa S, Capella C, Fiocca R 1999 Clinicopathological profile as a basis for classification of the endocrine tumours of the gastroenteropancreatic tract. *Ann Oncol* 10(Suppl 2):S9–S15
- Solcia E, Kloppel G, Sobin LH 2000 Histological typing of endocrine tumours. 2nd ed. Heidelberg: World Health Organization
- Rindi G, Villanacci V, Ubiali A 2000 Biological and molecular aspects of gastroenteropancreatic neuroendocrine tumors. *Digestion* 62(Suppl 1):19–26
- Oberg K 2002 Carcinoid tumors: molecular genetics, tumor biology, and update of diagnosis and treatment. *Curr Opin Oncol* 14:38–45
- Lamberts SW, Hofland LJ, Nobels FR 2001 Neuroendocrine tumor markers. *Front Neuroendocrinol* 22:309–339
- Kaltsas GA, Mukherjee JJ, Grossman AB 2001 The value of radiolabelled MIBG and octreotide in the diagnosis and management of neuroendocrine tumours. *Ann Oncol* 12(Suppl 2):S47–S50
- Calender A 2000 Molecular genetics of neuroendocrine tumors. *Digestion* 62(Suppl 1):3–18
- Vuitch F, Sekido Y, Fong K, Mackay B, Minna JD, Gazdar AF 1997 Neuroendocrine tumors of the lung. Pathology and molecular biology. *Chest Surg Clin N Am* 7:21–47
- Ahlman H, Wangberg B, Jansson S, Friman S, Olausson M, Tylen U, Nilsson O 2000 Interventional treatment of gastrointestinal neuroendocrine tumours. *Digestion* 62(Suppl 1):59–68
- Bishop AE, Polak JM 1996 Gastrointestinal endocrine tumours. Pathology. *Baillieres Clin Gastroenterol* 10:555–569
- Lloyd RV, Wilson BS 1983 Specific endocrine tissue marker defined by a monoclonal antibody. *Science* 222:628–630
- Rode J, Dhillon AP, Doran JF, Jackson P, Thompson RJ 1985 PGP 9.5, a new marker for human neuroendocrine tumours. *Histopathology* 9:147–158
- Wiedenmann B, Franke WW, Kuhn C, Moll R, Gould VE 1986 Synaptophysin: a marker protein for neuroendocrine cells and neoplasms. *Proc Natl Acad Sci USA* 83:3500–3504
- Capella C, Heitz PU, Hofler H, Solcia E, Kloppel G 1995 Revised classification of neuroendocrine tumours of the lung, pancreas and gut. *Virchows Arch* 425:547–560
- Clarke MR, Weyant RJ, Watson CG, Carty SE 1998 Prognostic markers in pheochromocytoma. *Hum Pathol* 29:522–526
- Tisell LE, Oden A, Muth A, Altiparmar G, Molne J, Ahlman H, Nilsson O 2003 The Ki67 index a prognostic marker in medullary thyroid carcinoma. *Br J Cancer* 89:2093–2097
- Kloppel G, Heitz PU, Capella C, Solcia E 1996 Pathology and nomenclature of human gastrointestinal neuroendocrine (carcinoid) tumors and related lesions. *World J Surg* 20:132–141
- Calender A, Vercherat C, Gaudray P, Chayvialle JA 2001 Deregulation of genetic pathways in neuroendocrine tumors. *Ann Oncol* 12(Suppl 2):S3–S11
- Brandi ML, Gagel RF, Angeli A, Bilezikian JP, Beck-Peccoz P, Bordi C, Conte-Devolx B, Falchetti A, Gheri RG, Libroia A, Lips CJ, Lombardi G, Mannelli M, Pacini F, Ponder BA, Raue F, Skogseid B, Tamburrano G, Thakker RV, Thompson NW, Tomassetti P, Tonelli F, Wells Jr SA, Marx SJ 2001 Guidelines for diagnosis and therapy of MEN type 1 and type 2. *J Clin Endocrinol Metab* 86:5658–5671
- Neumann HP, Hoegerle S, Manz T, Brenner K, Iliopoulos O 2002 How many pathways to pheochromocytoma? *Semin Nephrol* 22: 89–99
- Neumann HP, Berger DP, Sigmund G, Blum U, Schmidt D, Parmer RJ, Volk B, Kirste G 1993 Pheochromocytomas, multiple

- endocrine neoplasia type 2, and von Hippel-Lindau disease. *N Engl J Med* 329:1531–1538
23. Mulligan LM, Kwok JB, Healey CS, Elsdon MJ, Eng C, Gardner E, Love DR, Mole SE, Moore JK, Papi L 1993 Germ-line mutations of the RET proto-oncogene in multiple endocrine neoplasia type 2A. *Nature* 363:458–460
 24. Shepherd JJ 1991 The natural history of multiple endocrine neoplasia type 1. Highly uncommon or highly unrecognized? *Arch Surg* 126:935–952
 25. Heppner C, Kester MB, Agarwal SK, Debelenko LV, Emmert-Buck MR, Guru SC, Manickam P, Olufemi SE, Skarulis MC, Doppman JL, Alexander RH, Kim YS, Saggat SK, Lubensky IA, Zhuang Z, Liotta LA, Chandrasekharappa SC, Collins FS, Spiegel AM, Burns AL, Marx SJ 1997 Somatic mutation of the MEN1 gene in parathyroid tumours. *Nat Genet* 16:375–378
 26. Zhuang Z, Vortmeyer AO, Pack S, Huang S, Pham TA, Wang C, Park WS, Agarwal SK, Debelenko LV, Kester M, Guru SC, Manickam P, Olufemi SE, Yu F, Heppner C, Crabtree JS, Skarulis MC, Venzon DJ, Emmert-Buck MR, Spiegel AM, Chandrasekharappa SC, Collins FS, Burns AL, Marx SJ, Lubensky IA 1997 Somatic mutations of the MEN1 tumor suppressor gene in sporadic gastrinomas and insulinomas. *Cancer Res* 57:4682–4686
 27. Debelenko LV, Brambilla E, Agarwal SK, Swallowell JJ, Kester MB, Lubensky IA, Zhuang Z, Guru SC, Manickam P, Olufemi SE, Chandrasekharappa SC, Crabtree JS, Kim YS, Heppner C, Burns AL, Spiegel AM, Marx SJ, Liotta LA, Collins FS, Travis WD, Emmert-Buck MR 1997 Identification of MEN1 gene mutations in sporadic carcinoid tumors of the lung. *Hum Mol Genet* 6:2285–2290
 28. Maher ER, Eng C 2002 The pressure rises: update on the genetics of pheochromocytoma. *Hum Mol Genet* 11:2347–2354
 29. Iliopoulos O 2001 von Hippel-Lindau disease: genetic and clinical observations. *Front Horm Res* 28:131–166
 30. Carney JA, Gordon H, Carpenter PC, Shenoy BV, Go VL 1985 The complex of myxomas, spotty pigmentation, and endocrine overactivity. *Medicine (Baltimore)* 64:270–283
 31. Stratakis CA, Carney JA, Lin JP, Papanicolaou DA, Karl M, Kastner DL, Pras E, Chrousos GP 1996 Carney complex, a familial multiple neoplasia and lentiginosis syndrome. Analysis of 11 kindreds and linkage to the short arm of chromosome 2. *J Clin Invest* 97:699–705
 32. Gutmann DH, Aylsworth A, Carey JC, Korf B, Marks J, Pyeritz RE, Rubenstein A, Viskochil D 1997 The diagnostic evaluation and multidisciplinary management of neurofibromatosis 1 and neurofibromatosis 2. *JAMA* 278:51–57
 33. Griffiths DF, Williams GT, Williams ED 1987 Duodenal carcinoid tumours, pheochromocytoma and neurofibromatosis: islet cell tumour, pheochromocytoma and the von Hippel-Lindau complex: two distinctive neuroendocrine syndromes. *Q J Med* 64:769–782
 34. Wang DG 1999 Apoptosis in neuroendocrine tumours. *Clin Endocrinol (Oxf)* 51:1–9
 35. Hockenbery D, Nunez G, Millman C, Schreiber RD, Korsmeyer SJ 1990 Bcl-2 is an inner mitochondrial membrane protein that blocks programmed cell death. *Nature* 348:334–336
 36. Pelengaris S, Khan M 2001 Oncogenic co-operation in β -cell tumorigenesis. *Endocr Relat Cancer* 8:307–314
 37. Evan GI, Wyllie AH, Gilbert CS, Littlewood TD, Land H, Brooks M, Waters CM, Penn LZ, Hancock DC 1992 Induction of apoptosis in fibroblasts by c-myc protein. *Cell* 69:119–128
 38. Terris B, Scazecz JY, Rubbia L, Bregeaud L, Pepper MS, Ruzsiewicz P, Belghiti J, Flejou J, Degott C 1998 Expression of vascular endothelial growth factor in digestive neuroendocrine tumours. *Histopathology* 32:133–138
 39. Eriksson B, Oberg K, Stridsberg M 2000 Tumor markers in neuroendocrine tumors. *Digestion* 62(Suppl 1):33–38
 40. Nobels FR, Kwekkeboom DJ, Coopmans W, Schoenmakers CH, Lindemans J, De Herder WW, Krenning EP, Bouillon R, Lamberts SW 1997 Chromogranin A as serum marker for neuroendocrine neoplasia: comparison with neuron-specific enolase and the α -subunit of glycoprotein hormones. *J Clin Endocrinol Metab* 82:2622–2628
 41. Iacangelo AL, Eiden LE 1995 Chromogranin A: current status as a precursor for bioactive peptides and a granulogenic/sorting factor in the regulated secretory pathway. *Regul Pept* 58:65–88
 42. Taupenot L, Harper KL, O'Connor DT 2003 The chromogranin-secretogranin family. *N Engl J Med* 348:1134–1149
 43. Baudin E, Bidart JM, Bachelot A, Ducreux M, Elias D, Ruffie P, Schlumberger M 2001 Impact of chromogranin A measurement in the work-up of neuroendocrine tumors. *Ann Oncol* 12(Suppl 2):S79–S82
 44. O'Connor DT, Deftos LJ 1986 Secretion of chromogranin A by peptide-producing endocrine neoplasms. *N Engl J Med* 314:1145–1151
 45. Hsiao RJ, Parmer RJ, Takiyuddin MA, O'Connor DT 1991 Chromogranin A storage and secretion: sensitivity and specificity for the diagnosis of pheochromocytoma. *Medicine (Baltimore)* 70:33–45
 46. Baudin E, Gigliotti A, Ducreux M, Ropers J, Comoy E, Sabourin JC, Bidart JM, Cailleux AF, Bonacci R, Ruffie P, Schlumberger M 1998 Neuron-specific enolase and chromogranin A as markers of neuroendocrine tumours. *Br J Cancer* 78:1102–1107
 47. Janson ET, Holmberg L, Stridsberg M, Eriksson B, Theodorsson E, Wilander E, Oberg K 1997 Carcinoid tumors: analysis of prognostic factors and survival in 301 patients from a referral center. *Ann Oncol* 8:685–690
 48. Kimura N, Miura W, Noshiro T, Mizunashi K, Hanew K, Shimizu K, Watanabe T, Shibukawa S, Sohn HE, Abe K, Miura Y, Nagura H 1997 Plasma chromogranin A in pheochromocytoma, primary hyperparathyroidism and pituitary adenoma in comparison with catecholamine, parathyroid hormone and pituitary hormones. *Endocr J* 44:319–327
 49. Drivsholm L, Paloheimo LI, Osterlind K 1999 Chromogranin A, a significant prognostic factor in small cell lung cancer. *Br J Cancer* 81:667–671
 50. Nobels FR, Kwekkeboom DJ, Bouillon R, Lamberts SW 1998 Chromogranin A: its clinical value as marker of neuroendocrine tumours. *Eur J Clin Invest* 28:431–440
 51. Stridsberg M, Eriksson B, Oberg K, Janson ET 2003 A comparison between three commercial kits for chromogranin A measurements. *J Endocrinol* 177:337–341
 52. Caplin ME, Buscombe JR, Hilson AJ, Jones AL, Watkinson AF, Burroughs AK 1998 Carcinoid tumour. *Lancet* 352:799–805
 53. Krenning EP, Kwekkeboom DJ, Bakker WH, Breeman WA, Kooij PP, Oei HY, van Hagen M, Postema PT, de Jong M, Reubi JC 1993 Somatostatin receptor scintigraphy with [¹¹¹In-DTPA-D-Phe¹] and [¹²³I-Tyr³] octreotide: the Rotterdam experience with more than 1000 patients. *Eur J Nucl Med* 20:716–731
 54. Wiseman GA, Kvols LK 1995 Therapy of neuroendocrine tumors with radiolabeled MIBG and somatostatin analogues. *Semin Nucl Med* 25:272–278
 55. Troncione L, Rufini V 1999 Nuclear medicine therapy of pheochromocytoma and paraganglioma. *Q J Nucl Med* 43:344–355
 56. Sisson JC 2002 Radiopharmaceutical treatment of pheochromocytomas. *Ann NY Acad Sci* 970:54–60
 57. Benali N, Ferjoux G, Puente E, Buscail L, Susini C 2000 Somatostatin receptors. *Digestion* 62(Suppl 1):27–32
 58. Hofland LJ, Lamberts SW 2001 Somatostatin receptor subtype expression in human tumors. *Ann Oncol* 12(Suppl 2):S31–S36
 59. Arnold R, Simon B, Wied M 2000 Treatment of neuroendocrine GEP tumours with somatostatin analogues: a review. *Digestion* 62(Suppl 1):84–91
 60. Arnold R 1996 Medical treatment of metastasizing carcinoid tumors. *World J Surg* 20:203–207
 61. Maton PN 1993 Use of octreotide acetate for control of symptoms in patients with islet cell tumors. *World J Surg* 17:504–510
 62. Lamberts SW, van der Lely AJ, de Herder WW, Hofland LJ 1996 Somatostatin analogs: future directions. *Metabolism* 45:104–106
 63. Lamberts SW, van der Lely AJ, de Herder WW, Hofland LJ 1996 Octreotide. *N Engl J Med* 334:246–254
 64. Sharma K, Patel YC, Srikant CB 1999 C-terminal region of human somatostatin receptor 5 is required for induction of Rb and G1 cell cycle arrest. *Mol Endocrinol* 13:82–90
 65. Macaulay VM 1992 Insulin-like growth factors and cancer. *Br J Cancer* 65:311–320
 66. Garcia de la Torre N, Wass JA, Turner HE 2002 Antiangiogenic effects of somatostatin analogues. *Clin Endocrinol (Oxf)* 57:425–441

67. Reubi JC, Laissue J, Waser B, Horisberger U, Schaer JC 1994 Expression of somatostatin receptors in normal, inflamed, and neoplastic human gastrointestinal tissues. *Ann NY Acad Sci* 733:122–137
68. Reubi JC 1995 Neuropeptide receptors in health and disease: the molecular basis for in vivo imaging. *J Nucl Med* 36:1825–1835
69. de Herder WW, van der Lely AJ, Lamberts SW 1996 Somatostatin analogue treatment of neuroendocrine tumours. *Postgrad Med J* 72:403–408
70. Olsen JO, Pozderac RV, Hinkle G, Hill T, O'Dorisio TM, Schirmer WJ, Ellison EC, O'Dorisio MS 1995 Somatostatin receptor imaging of neuroendocrine tumors with indium-111 pentetreotide (Octreoscan). *Semin Nucl Med* 25:251–261
71. Janson ET, Stridsberg M, Gobl A, Westlin JE, Oberg K 1998 Determination of somatostatin receptor subtype 2 in carcinoid tumors by immunohistochemical investigation with somatostatin receptor subtype 2 antibodies. *Cancer Res* 58:2375–2378
72. Hoefnagel CA 1994 Metaiodobenzylguanidine and somatostatin in oncology: role in the management of neural crest tumours. *Eur J Nucl Med* 21:561–581
73. Kwekkeboom D, Krenning EP, de Jong M 2000 Peptide receptor imaging and therapy. *J Nucl Med* 41:1704–1713
74. de Herder WW, Lamberts SW 2002 Somatostatin and somatostatin analogues: diagnostic and therapeutic uses. *Curr Opin Oncol* 14:53–57
75. Lamberts SW, Krenning EP, Reubi JC 1991 The role of somatostatin and its analogs in the diagnosis and treatment of tumors. *Endocr Rev* 12:450–482
76. Shapiro B 1995 Ten years of experience with MIBG applications and the potential of new radiolabeled peptides: a personal overview and concluding remarks. *Q J Nucl Med* 39:150–155
77. Shapiro B, Sisson JC, Shulkin BL, Gross MD, Zempel S 1995 The current status of meta-iodobenzylguanidine and related agents for the diagnosis of neuro-endocrine tumors. *Q J Nucl Med* 39:3–8
78. Bombardieri E, Maccauro M, Castellani MR, Chiti A, Procopio G, Bajetta E, Seregni E 2001 [Radioisotopic imaging of neuroendocrine tumours. Which radiopharmaceutical and which diagnostic procedure?]. *Minerva Endocrinol* 26:197–213
79. Mukherjee JJ, Kaltsas GA, Islam N, Plowman PN, Foley R, Hikmat J, Britton KE, Jenkins PJ, Chew SL, Monson JP, Besser GM, Grossman AB 2001 Treatment of metastatic carcinoid tumours, pheochromocytoma, paraganglioma and medullary carcinoma of the thyroid with (131I)-meta-iodobenzylguanidine [(131I)-mIBG]. *Clin Endocrinol (Oxf)* 55:47–60
80. Chatal JF, Le Bodic MF, Kraeber-Bodere F, Rousseau C, Resche I 2000 Nuclear medicine applications for neuroendocrine tumors. *World J Surg* 24:1285–1289
81. Taal BG, Hoefnagel C, Boot H, Valdes OR, Rutgers M 2000 Improved effect of 131I-MIBG treatment by predosing with non-radiolabeled MIBG in carcinoid patients, and studies in xenografted mice. *Ann Oncol* 11:1437–1443
82. Krenning EP, Bakker WH, Breeman WA, Koper JW, Kooij PP, Ausema L, Lameris JS, Reubi JC, Lamberts SW 1989 Localisation of endocrine-related tumours with radioiodinated analogue of somatostatin. *Lancet* 1:242–244
83. Krenning EP, de Jong M, Kooij PP, Breeman WA, Bakker WH, de Herder WW, van Eijck CH, Kwekkeboom DJ, Jamar F, Pauwels S, Valkema R 1999 Radiolabelled somatostatin analogue(s) for peptide receptor scintigraphy and radionuclide therapy. *Ann Oncol* 10(Suppl 2):S23–S29
84. Otte A, Mueller-Brand J, Dellas S, Nitzsche EU, Herrmann R, Maecke HR 1998 Yttrium-90-labelled somatostatin-analogue for cancer treatment. *Lancet* 351:417–418
85. Breeman WA, Kwekkeboom DJ, Kooij PP, Bakker WH, Hofland LJ, Visser TJ, Ensing GJ, Lamberts SW, Krenning EP 1995 Effect of dose and specific activity on tissue distribution of indium-111-pentetreotide in rats. *J Nucl Med* 36:623–627
86. Balon HR, Goldsmith SJ, Siegel BA, Silberstein EB, Krenning EP, Lang O, Donohoe KJ 2001 Procedure guideline for somatostatin receptor scintigraphy with (111In)-pentetreotide. *J Nucl Med* 42:1134–1138
87. Dorr U, Rath U, Sautter-Bihl ML, Guzman G, Bach D, Adrian HJ, Bihl H 1993 Improved visualization of carcinoid liver metastases by indium-111 pentetreotide scintigraphy following treatment with cold somatostatin analogue. *Eur J Nucl Med* 20:431–433
88. Krenning EP, Kwekkeboom DJ, de Jong M, Visser TJ, Reubi JC, Bakker WH, Kooij PP, Lamberts SW 1994 Essentials of peptide receptor scintigraphy with emphasis on the somatostatin analog octreotide. *Semin Oncol* 21:6–14
89. Krenning EP, Kwekkeboom DJ, Oei HY, de Jong RJ, Dop FJ, Reubi JC, Lamberts SW 1994 Somatostatin-receptor scintigraphy in gastroenteropancreatic tumors. An overview of European results. *Ann NY Acad Sci* 733:416–424
90. Krenning EP, Kwekkeboom DJ, Oei Y, Reubi JC, Lamberts SW 1993 Octreotide agent shows peptide imaging potential. *Diagn Imaging (San Franc)* 15:88–91, 117
91. Krenning EP, Kwekkeboom DJ, Reubi JC, van Hagen PM, van Eijck CH, Oei HY, Lamberts SW 1993 111In-octreotide scintigraphy in oncology. *Digestion* 54(Suppl 1):84–87
92. Chiti A, Fanti S, Savelli G, Romeo A, Bellanova B, Rodari M, van Graafeiland BJ, Monetti N, Bombardieri E 1998 Comparison of somatostatin receptor imaging, computed tomography and ultrasound in the clinical management of neuroendocrine gastro-enteropancreatic tumours. *Eur J Nucl Med* 25:1396–1403
93. Gibril F, Reynolds JC, Doppman JL, Chen CC, Venzon DJ, Termanini B, Weber HC, Stewart CA, Jensen RT 1996 Somatostatin receptor scintigraphy: its sensitivity compared with that of other imaging methods in detecting primary and metastatic gastrinomas. A prospective study. *Ann Intern Med* 125:26–34
94. Gibril F, Reynolds JC, Chen CC, Yu F, Goebel SU, Serrano J, Doppman JL, Jensen RT 1999 Specificity of somatostatin receptor scintigraphy: a prospective study and effects of false-positive localizations on management in patients with gastrinomas. *J Nucl Med* 40:539–553
95. Kwekkeboom DJ, Krenning EP 2002 Somatostatin receptor imaging. In: Lamberts SWJ, Dogliotti L, eds. *The expanding role of octreotide I: advances in oncology*. 1st ed. Bristol, UK: BioScientifica; 17–30
96. Hofland LJ, van Koetsveld PM, Waaijers M, Zuyderwijk J, Breeman WA, Lamberts SW 1995 Internalization of the radioiodinated somatostatin analog [125I-Tyr3]octreotide by mouse and human pituitary tumor cells: increase by unlabeled octreotide. *Endocrinology* 136:3698–3706
97. Hoefnagel CA, Schornagel J, Valdes Olmos RA 1991 [131I]metaiodobenzylguanidine therapy of malignant pheochromocytoma: interference of medication. *J Nucl Biol Med* 35:308–312
98. Kaltsas GA, Putignano P, Mukherjee JJ, Satta MA, Lowe DG, Britton KE, Monson JP, Grossman AB, Besser GM 1998 Carcinoid tumours presenting as breast cancer: the utility of radionuclide imaging with 123I-MIBG and 111In-DTPA pentetreotide. *Clin Endocrinol (Oxf)* 49:685–689
99. Kaltsas G, Korbonits M, Heintz E, Mukherjee JJ, Jenkins PJ, Chew SL, Reznik R, Monson JP, Besser GM, Foley R, Britton KE, Grossman AB 2001 Comparison of somatostatin analog and meta-iodobenzylguanidine radionuclides in the diagnosis and localization of advanced neuroendocrine tumors. *J Clin Endocrinol Metab* 86:895–902
100. Anderson CJ, Dehdashti F, Cutler PD, Schwarz SW, Laforest R, Bass LA, Lewis JS, McCarthy DW 2001 64Cu-TETA-octreotide as a PET imaging agent for patients with neuroendocrine tumors. *J Nucl Med* 42:213–221
101. Virgolini I, Raderer M, Kurtaran A, Angelberger P, Banyai S, Yang Q, Li S, Banyai M, Pidlich J, Niederle B 1994 Vasoactive intestinal peptide-receptor imaging for the localization of intestinal adenocarcinomas and endocrine tumors. *N Engl J Med* 331:1116–1121
102. Aloj L, Panico MR, Caraco C, Zannetti A, Del Vecchio S, Di Nuzzo C, Arra C, Morelli G, Tesauro D, De Luca S, Pedone C, Salvatore M 2002 Radiolabeling approaches for cholecystokinin B receptor imaging. *Biopolymers* 66:370–380
103. de Jong M, Kwekkeboom D, Valkema R, Krenning EP 2003 Radiolabelled peptides for tumour therapy: current status and future directions. Plenary lecture at the EANM 2002. *Eur J Nucl Med Mol Imaging* 30:463–469
104. Eriksson B, Bergstrom M, Sundin A, Juhlin C, Orlefors H, Oberg

- K, Langstrom B** 2002 The role of PET in localization of neuroendocrine and adrenocortical tumors. *Ann NY Acad Sci* 970:159–169
105. **Erasmus JJ, McAdams HP, Patz Jr EF, Coleman RE, Ahuja V, Goodman PC** 1998 Evaluation of primary pulmonary carcinoid tumors using FDG PET. *AJR Am J Roentgenol* 170:1369–1373
 106. **Adams S, Baum R, Rink T, Schumm-Drager PM, Usadel KH, Hor G** 1998 Limited value of fluorine-18 fluorodeoxyglucose positron emission tomography for the imaging of neuroendocrine tumours. *Eur J Nucl Med* 25:79–83
 107. **Orlefors H, Sundin A, Ahlstrom H, Bjurling P, Bergstrom M, Lilja A, Langstrom B, Oberg K, Eriksson B** 1998 Positron emission tomography with 5-hydroxytryptophan in neuroendocrine tumors. *J Clin Oncol* 16:2534–2541
 108. **Sundin A, Eriksson B, Bergstrom M, Bjurling P, Lindner KJ, Oberg K, Langstrom B** 2000 Demonstration of [¹¹C] 5-hydroxy-L-tryptophan uptake and decarboxylation in carcinoid tumors by specific positioning labeling in positron emission tomography. *Nucl Med Biol* 27:33–41
 109. **Mignon M** 2000 Natural history of neuroendocrine enteropancreatic tumors. *Digestion* 62(Suppl 1):51–58
 110. **Marsh DJ, Learoyd DL, Robinson BG** 1995 Medullary thyroid carcinoma: recent advances and management update. *Thyroid* 5:407–424
 111. **Bravo EL** 2002 Pheochromocytoma. *Cardiol Rev* 10:44–50
 112. **Rindi G, Villanacci V, Ubiali A** 2002 Classification of neuroendocrine phenotype in cancer. In: Lamberts SWJ, Dogliotti L, eds. *Advances in oncology*. Bristol, UK: BioScientifica; 31–42
 113. **Skogseid B** 2001 Nonsurgical treatment of advanced malignant neuroendocrine pancreatic tumors and midgut carcinoids. *World J Surg* 25:700–703
 114. **Averbuch SD, Steakley CS, Young RC, Gelmann EP, Goldstein DS, Stull R, Keiser HR** 1988 Malignant pheochromocytoma: effective treatment with a combination of cyclophosphamide, vincristine, and dacarbazine. *Ann Intern Med* 109:267–273
 115. **Bravo EL** 1994 Evolving concepts in the pathophysiology, diagnosis, and treatment of pheochromocytoma. *Endocr Rev* 15:356–368
 116. **Kaltsas G, Mukherjee JJ, Plowman PN, Grossman AB** 2001 The role of chemotherapy in the nonsurgical management of malignant neuroendocrine tumours. *Clin Endocrinol (Oxf)* 55:575–587
 117. **Sutliff VE, Doppman JL, Gibril F, Venzon DJ, Yu F, Serrano J, Jensen RT** 1997 Growth of newly diagnosed, untreated metastatic gastrinomas and predictors of growth patterns. *J Clin Oncol* 15:2420–2431
 118. **Ganim RB, Norton JA** 2000 Recent advances in carcinoid pathogenesis, diagnosis and management. *Surg Oncol* 9:173–179
 119. **Kulke MH, Mayer RJ** 1999 Carcinoid tumors. *N Engl J Med* 340:858–868
 120. **Limper AH, Carpenter PC, Scheithauer B, Staats BA** 1992 The Cushing syndrome induced by bronchial carcinoid tumors. *Ann Intern Med* 117:209–214
 121. **Vinik AI, McLeod MK, Fig LM, Shapiro B, Lloyd RV, Cho K** 1989 Clinical features, diagnosis, and localization of carcinoid tumors and their management. *Gastroenterol Clin North Am* 18:865–896
 122. **Jensen RT** 2000 Carcinoid and pancreatic endocrine tumors: recent advances in molecular pathogenesis, localization, and treatment. *Curr Opin Oncol* 12:368–377
 123. **Erickson JD, Schafer MK, Bonner TI, Eiden LE, Weihe E** 1996 Distinct pharmacological properties and distribution in neurons and endocrine cells of two isoforms of the human vesicular monoamine transporter. *Proc Natl Acad Sci USA* 93:5166–5171
 124. **Ahlman H, Nilsson O** 2001 The gut as the largest endocrine organ in the body. *Ann Oncol* 12(Suppl 2):S63–S68
 125. **Newton JN, Swerdlow AJ, dos Santos Silva IM, Vessey MP, Grahame-Smith DG, Primates P, Reynolds DJ** 1994 The epidemiology of carcinoid tumours in England and Scotland. *Br J Cancer* 70:939–942
 126. **Modlin IM, Sandor A** 1997 An analysis of 8305 cases of carcinoid tumors. *Cancer* 79:813–829
 127. **Modlin IM, Tang LH** 1997 Approaches to the diagnosis of gut neuroendocrine tumors: the last word (today). *Gastroenterology* 112:583–590
 128. **Berge T, Linell F** 1976 Carcinoid tumours. Frequency in a defined population during a 12-year period. *Acta Pathol Microbiol Scand [A]* 84:322–330
 129. **Hemminki K, Li X** 2001 Incidence trends and risk factors of carcinoid tumors: a nationwide epidemiologic study from Sweden. *Cancer* 92:2204–2210
 130. **Quaedvlieg PF, Visser O, Lamers CB, Janssen-Heijnen ML, Taal BG** 2001 Epidemiology and survival in patients with carcinoid disease in The Netherlands. An epidemiological study with 2391 patients. *Ann Oncol* 12:1295–1300
 131. **McStay MK, Caplin ME** 2002 Carcinoid tumour. *Minerva Med* 93:389–401
 132. **Janmohamed S, Bloom SR** 1997 Carcinoid tumours. *Postgrad Med J* 73:207–214
 133. **Duh QY, Hybarger CP, Geist R, Gamsu G, Goodman PC, Gooding GA, Clark OH** 1987 Carcinoids associated with multiple endocrine neoplasia syndromes. *Am J Surg* 154:142–148
 134. **Hough DR, Chan A, Davidson H** 1983 Von Recklinghausen's disease associated with gastrointestinal carcinoid tumors. *Cancer* 51:2206–2208
 135. **Yeatman TJ, Sharp JV, Kimura AK** 1989 Can susceptibility to carcinoid tumors be inherited? *Cancer* 63:390–393
 136. **Hemminki K, Li X** 2001 Familial carcinoid tumors and subsequent cancers: a nation-wide epidemiologic study from Sweden. *Int J Cancer* 94:444–448
 137. **Onaitis MW, Kirshbom PM, Hayward TZ, Quayle FJ, Feldman JM, Seigler HF, Tyler DS** 2000 Gastrointestinal carcinoids: characterization by site of origin and hormone production. *Ann Surg* 232:549–556
 138. **Soga J, Yakuwa Y, Osaka M** 1999 Carcinoid syndrome: a statistical evaluation of 748 reported cases. *J Exp Clin Cancer Res* 18:133–141
 139. **Tomassetti P, Migliori M, Lalli S, Campana D, Tomassetti V, Corinaldesi R** 2001 Epidemiology, clinical features and diagnosis of gastroenteropancreatic endocrine tumours. *Ann Oncol* 12(Suppl 2):S95–S99
 140. **Harpole Jr DH, Feldman JM, Buchanan S, Young WG, Wolfe WG** 1992 Bronchial carcinoid tumors: a retrospective analysis of 126 patients. *Ann Thorac Surg* 54:50–54
 141. **Marty-Ane CH, Costes V, Pujol JL, Alauzen M, Baldet P, Mary H** 1995 Carcinoid tumors of the lung: do atypical features require aggressive management? *Ann Thorac Surg* 59:78–83
 142. **Warren WH, Gould VE, Faber LP, Kittle CF, Memoli VA** 1985 Neuroendocrine neoplasms of the bronchopulmonary tract. A classification of the spectrum of carcinoid to small cell carcinoma and intervening variants. *J Thorac Cardiovasc Surg* 89:819–825
 143. **Travis WD, Rush W, Flieder DB, Falk R, Fleming MV, Gal AA, Koss MN** 1998 Survival analysis of 200 pulmonary neuroendocrine tumors with clarification of criteria for atypical carcinoid and its separation from typical carcinoid. *Am J Surg Pathol* 22:934–944
 144. **Granberg D, Wilander E, Oberg K, Skogseid B** 2000 Prognostic markers in patients with typical bronchial carcinoid tumors. *J Clin Endocrinol Metab* 85:3425–3430
 145. **Fink G, Krelbaum T, Yellin A, Bendayan D, Saute M, Glazer M, Kramer MR** 2001 Pulmonary carcinoid: presentation, diagnosis, and outcome in 142 cases in Israel and review of 640 cases from the literature. *Chest* 119:1647–1651
 146. **Tiensuu Janson EM, Oberg KE** 1996 Carcinoid tumours. *Baillieres Clin Gastroenterol* 10:589–601
 147. **Torre M, Barberis M, Barbieri B, Bonacina E, Belloni P** 1989 Typical and atypical bronchial carcinoids. *Respir Med* 83:305–308
 148. **Schreurs AJ, Westermann CJ, van den Bosch JM, Vanderschueren RG, Brutel de la Riviere A, Knaepen PJ** 1992 A twenty-five-year follow-up of ninety-three resected typical carcinoid tumors of the lung. *J Thorac Cardiovasc Surg* 104:1470–1475
 149. **Dusmet ME, McKneally MF** 1996 Pulmonary and thymic carcinoid tumors. *World J Surg* 20:189–195
 150. **Hage R, de la Riviere AB, Seldenrijk CA, van den Bosch JM** 2003 Update in pulmonary carcinoid tumors: a review article. *Ann Surg Oncol* 10:697–704
 151. **Teh BT** 1998 Thymic carcinoids in multiple endocrine neoplasia type 1. *J Intern Med* 243:501–504
 152. **Teh BT, McArdle J, Chan SP, Menon J, Hartley L, Pullan P, Ho J, Khir A, Wilkinson S, Larsson C, Cameron D, Shepherd J** 1997

- Clinicopathologic studies of thymic carcinoids in multiple endocrine neoplasia type 1. *Medicine (Baltimore)* 76:21–29
153. Soga J, Yakuwa Y, Osaka M 1999 Evaluation of 342 cases of mediastinal/thymic carcinoids collected from literature: a comparative study between typical carcinoids and atypical varieties. *Ann Thorac Cardiovasc Surg* 5:285–292
 154. Moran CA, Suster S 2000 Neuroendocrine carcinomas (carcinoid tumor) of the thymus. A clinicopathologic analysis of 80 cases. *Am J Clin Pathol* 114:100–110
 155. Gibril F, Chen YJ, Schrupp DS, Vortmeyer A, Zhuang Z, Lubensky IA, Reynolds JC, Louie A, Entsuaeh LK, Huang K, Asgharian B, Jensen RT 2003 Prospective study of thymic carcinoids in patients with multiple endocrine neoplasia type 1. *J Clin Endocrinol Metab* 88:1066–1081
 156. Rindi G, Bordi C, Rappel S, La Rosa S, Stolte M, Solcia E 1996 Gastric carcinoids and neuroendocrine carcinomas: pathogenesis, pathology, and behavior. *World J Surg* 20:168–172
 157. Soga J 1997 Gastric carcinoids: a statistical evaluation of 1,094 cases collected from the literature. *Surg Today* 27:892–901
 158. Gough DB, Thompson GB, Crotty TB, Donohue JH, Kvols LK, Carney JA, Grant CS, Nagorney DM 1994 Diverse clinical and pathologic features of gastric carcinoid and the relevance of hypergastrinemia. *World J Surg* 18:473–479
 159. Rindi G, Luinetti O, Cornaggia M, Capella C, Solcia E 1993 Three subtypes of gastric argyrophil carcinoid and the gastric neuroendocrine carcinoma: a clinicopathologic study. *Gastroenterology* 104:994–1006
 160. Akerstrom G 1996 Management of carcinoid tumors of the stomach, duodenum, and pancreas. *World J Surg* 20:173–182
 161. Granberg D, Wilander E, Stridsberg M, Granerus G, Skogseid B, Oberg K 1998 Clinical symptoms, hormone profiles, treatment, and prognosis in patients with gastric carcinoids. *Gut* 43:223–228
 162. Jensen RT 1996 Gastrointestinal endocrine tumours. *Gastrinoma*. *Baillieres Clin Gastroenterol* 10:603–643
 163. Rindi G, Azzoni C, La Rosa S, Klersy C, Paolotti D, Rappel S, Stolte M, Capella C, Bordi C, Solcia E 1999 ECL cell tumor and poorly differentiated endocrine carcinoma of the stomach: prognostic evaluation by pathological analysis. *Gastroenterology* 116:532–542
 164. Modlin IM, Lye KD, Kidd M 2003 Carcinoid tumors of the stomach. *Surg Oncol* 12:153–172
 165. Modlin IM, Kidd M, Lye KD, Wright NA 2003 Gastric stem cells: an update. *Keio J Med* 52:134–137
 166. Modlin IM, Lye KD, Kidd M 2004 Multiple gastric carcinoids. *J Am Coll Surg* 198:174
 167. Modlin IM, Lye KD, Kidd M 2004 A 50-year analysis of 562 gastric carcinoids: small tumor or larger problem? *Am J Gastroenterol* 99:23–32
 168. Kirshbom PM, Kherani AR, Onaitis MW, Hata A, Kehoe TE, Feldman C, Feldman JM, Tyler DS 1999 Foregut carcinoids: a clinical and biochemical analysis. *Surgery* 126:1105–1110
 169. Soga J 2003 Endocrinocarcinomas (carcinoids and their variants) of the duodenum. An evaluation of 927 cases. *J Exp Clin Cancer Res* 22:349–363
 170. Mao C, el Attar A, Domenico DR, Kim K, Howard JM 1998 Carcinoid tumors of the pancreas. Status report based on two cases and review of the world's literature. *Int J Pancreatol* 23:153–164
 171. Maurer CA, Baer HU, Dyong TH, Mueller-Garamvoelgyi E, Friess H, Ruchti C, Reubi JC, Buchler MW 1996 Carcinoid of the pancreas: clinical characteristics and morphological features. *Eur J Cancer* 32A:1109–1116
 172. Oberg K 1998 Advances in chemotherapy and biotherapy of endocrine tumors. *Curr Opin Oncol* 10:58–65
 173. Burke AP, Thomas RM, Elsayed AM, Sobin LH 1997 Carcinoids of the jejunum and ileum: an immunohistochemical and clinicopathologic study of 167 cases. *Cancer* 79:1086–1093
 174. Makridis C, Oberg K, Juhlin C, Rastad J, Johansson H, Lorelius LE, Akerstrom G 1990 Surgical treatment of mid-gut carcinoid tumors. *World J Surg* 14:377–383
 175. Janson ET, Oberg K 1993 Long-term management of the carcinoid syndrome. Treatment with octreotide alone and in combination with α -interferon. *Acta Oncol* 32:225–229
 176. Modlin IM, Lye KD, Kidd M 2003 A 5-decade analysis of 13,715 carcinoid tumors. *Cancer* 97:934–959
 177. Kirshbom PM, Kherani AR, Onaitis MW, Feldman JM, Tyler DS 1998 Carcinoids of unknown origin: comparative analysis with foregut, midgut, and hindgut carcinoids. *Surgery* 124:1063–1070
 178. Wiedenmann B, Jensen RT, Mignon M, Modlin CI, Skogseid B, Doherty G, Oberg K 1998 Preoperative diagnosis and surgical management of neuroendocrine gastroenteropancreatic tumors: general recommendations by a consensus workshop. *World J Surg* 22:309–318
 179. Shaw PA 1990 Carcinoid tumours of the appendix are different. *J Pathol* 162:189–190
 180. Roggo A, Wood WC, Ottinger LW 1993 Carcinoid tumors of the appendix. *Ann Surg* 217:385–390
 181. Moertel CG, Weiland LH, Nagorney DM, Dockerty MB 1987 Carcinoid tumor of the appendix: treatment and prognosis. *N Engl J Med* 317:1699–1701
 182. Moertel CG 1987 Karnofsky memorial lecture. An odyssey in the land of small tumors. *J Clin Oncol* 5:1502–1522
 183. Butler JA, Houshiar A, Lin F, Wilson SE 1994 Goblet cell carcinoid of the appendix. *Am J Surg* 168:685–687
 184. Kanthan R, Saxena A, Kanthan SC 2001 Goblet cell carcinoids of the appendix: immunophenotype and ultrastructural study. *Arch Pathol Lab Med* 125:386–390
 185. Soga J 1998 Carcinoids of the colon and ileocecal region: a statistical evaluation of 363 cases collected from the literature. *J Exp Clin Cancer Res* 17:139–148
 186. Rosenberg JM, Welch JP 1985 Carcinoid tumors of the colon. A study of 72 patients. *Am J Surg* 149:775–779
 187. Ballantyne GH, Savoca PE, Flannery JT, Ahlman MH, Modlin IM 1992 Incidence and mortality of carcinoids of the colon. Data from the Connecticut Tumor Registry. *Cancer* 69:2400–2405
 188. Falconi M, Bettini R, Scarpa A, Capelli P, Pederzoli P 2001 Surgical strategy in the treatment of gastrointestinal neuroendocrine tumours. *Ann Oncol* 12(Suppl 2):S101–S103
 189. Soga J 1997 Carcinoids of the rectum: an evaluation of 1271 reported cases. *Surg Today* 27:112–119
 190. Federspiel BH, Burke AP, Sobin LH, Shekitka KM 1990 Rectal and colonic carcinoids. A clinicopathologic study of 84 cases. *Cancer* 65:135–140
 191. Koura AN, Giacco GG, Curley SA, Skibber JM, Feig BW, Ellis LM 1997 Carcinoid tumors of the rectum: effect of size, histopathology, and surgical treatment on metastasis free survival. *Cancer* 79:1294–1298
 192. Soga J, Osaka M, Yakuwa Y 2000 Carcinoids of the ovary: an analysis of 329 reported cases. *J Exp Clin Cancer Res* 19:271–280
 193. Davis KP, Hartmann LK, Keeney GL, Shapiro H 1996 Primary ovarian carcinoid tumors. *Gynecol Oncol* 61:259–265
 194. Isidori AM, Kaltsas G, Frajese V, Kola B, Whitelocke RA, Plowman PN, Britton KE, Monson JP, Grossman AB, Besser GM 2002 Ocular metastases secondary to carcinoid tumors: the utility of imaging with [(123)I]meta-iodobenzylguanidine and [(111)In-DTPA pentetreotide. *J Clin Endocrinol Metab* 87:1627–1633
 195. Riddell DA, LeBoldus GM, Joseph MG, Hearn SA 1994 Carcinoid tumour of the middle ear: case report and review of the literature. *J Otolaryngol* 23:276–280
 196. Pandya UH, Pellikka PA, Enriquez-Sarano M, Edwards WD, Schaff HV, Connolly HM 2002 Metastatic carcinoid tumor to the heart: echocardiographic-pathologic study of 11 patients. *J Am Coll Cardiol* 40:1328–1332
 197. Torske KR, Thompson LD 2002 Adenoma versus carcinoid tumor of the middle ear: a study of 48 cases and review of the literature. *Mod Pathol* 15:543–555
 198. Frank RG, Gerard PS, Anselmo MT, Bennett L, Preminger BI, Wise GJ 1991 Primary carcinoid tumor of the testis. *Urol Radiol* 12:203–205
 199. Robiolio PA, Rigolin VH, Harrison JK, Lowe JE, Moore JO, Bashore TM, Feldman JM 1995 Predictors of outcome of tricuspid valve replacement in carcinoid heart disease. *Am J Cardiol* 75:485–488
 200. van der Horst-Schrivers AN, Wymenga AN, de Vries EG 2003 Carcinoid heart disease. *N Engl J Med* 348:2359–2361
 201. Robiolio PA, Rigolin VH, Wilson JS, Harrison JK, Sanders LL,

- Bashore TM, Feldman JM** 1995 Carcinoid heart disease. Correlation of high serotonin levels with valvular abnormalities detected by cardiac catheterization and echocardiography. *Circulation* 92:790–795
202. **Pelikka PA, Tajik AJ, Khandheria BK, Seward JB, Callahan JA, Pitot HC, Kvols LK** 1993 Carcinoid heart disease. Clinical and echocardiographic spectrum in 74 patients. *Circulation* 87:1188–1196
203. **Khan MA, Herzog CA, St Peter JV, Hartley GG, Madlon-Kay R, Dick CD, Asinger RW, Vessey JT** 1998 The prevalence of cardiac valvular insufficiency assessed by transthoracic echocardiography in obese patients treated with appetite-suppressant drugs. *N Engl J Med* 339:713–718
204. **Jick H, Vasilakis C, Weinrauch LA, Meier CR, Jick SS, Derby LE** 1998 A population-based study of appetite-suppressant drugs and the risk of cardiac-valve regurgitation. *N Engl J Med* 339:719–724
205. **Zuetenhorst JM, Taal BG** 2003 Carcinoid heart disease. *N Engl J Med* 348:2359–2361
206. **Zuetenhorst JM, Bonfrer JM, Korse CM, Bakker R, van Tinteren H, Taal BG** 2003 Carcinoid heart disease: the role of urinary 5-hydroxyindoleacetic acid excretion and plasma levels of atrial natriuretic peptide, transforming growth factor- β and fibroblast growth factor. *Cancer* 97:1609–1615
207. **Moller JE, Connolly HM, Rubin J, Seward JB, Modesto K, Pelikka PA** 2003 Factors associated with progression of carcinoid heart disease. *N Engl J Med* 348:1005–1015
208. **Westberg G, Wangberg B, Ahlman H, Bergh CH, Beckman-Suurkula M, Caidahl K** 2001 Prediction of prognosis by echocardiography in patients with midgut carcinoid syndrome. *Br J Surg* 88:865–872
209. **Funa K, Papanicolaou V, Juhlin C, Rastad J, Akerstrom G, Heldin CH, Oberg K** 1990 Expression of platelet-derived growth factor β -receptors on stromal tissue cells in human carcinoid tumors. *Cancer Res* 50:748–753
210. **Feldman JM, O'Dorisio TM** 1986 Role of neuropeptides and serotonin in the diagnosis of carcinoid tumors. *Am J Med* 81:41–48
211. **Norheim I, Theodorsson-Norheim E, Brodin E, Oberg K** 1986 Tachykinins in carcinoid tumors: their use as a tumor marker and possible role in the carcinoid flush. *J Clin Endocrinol Metab* 63:605–612
212. **Pirker RA, Pont J, Pohnl R, Schutz W, Griesmacher A, Muller MM** 1998 Usefulness of chromogranin A as a marker for detection of relapses of carcinoid tumours. *Clin Chem Lab Med* 36:837–840
213. **Tomassetti P, Migliori M, Simoni P, Casadei R, De Iasio R, Corinaldesi R, Gullo L** 2001 Diagnostic value of plasma chromogranin A in neuroendocrine tumours. *Eur J Gastroenterol Hepatol* 13:55–58
214. **de Herder WW** 2002 An algorithm for the treatment of gastroenteropancreatic neuroendocrine tumors: when to treat, how to treat. In: Lamberts SJ, Dogliotti L, eds. *Advances in oncology*. Bristol, UK: BioScientifica; 143–154
215. **Wallace S, Ajani JA, Charnsangavej C, DuBrow R, Yang DJ, Chuang VP, Carrasco CH, Dodd Jr GD** 1996 Carcinoid tumors: imaging procedures and interventional radiology. *World J Surg* 20:147–156
216. **Reubi JC, Kvols L, Krenning E, Lamberts SW** 1990 Distribution of somatostatin receptors in normal and tumor tissue. *Metabolism* 39:78–81
217. **Janson ET, Westlin JE, Ohrvall U, Oberg K, Lukinius A** 2000 Nuclear localization of ^{111}In after intravenous injection of [^{111}In -DTPA-D-Phe1]-octreotide in patients with neuroendocrine tumors. *J Nucl Med* 41:1514–1518
218. **Kalkner KM, Janson ET, Nilsson S, Carlsson S, Oberg K, Westlin JE** 1995 Somatostatin receptor scintigraphy in patients with carcinoid tumors: comparison between radioligand uptake and tumor markers. *Cancer Res* 55:5801s–5804s
219. **Tsagarakis S, Christoforaki M, Giannopoulou H, Rondogianni F, Housianakou I, Malagari C, Rontogianni D, Bellenis I, Thalassinou N** 2003 A reappraisal of the utility of somatostatin receptor scintigraphy in patients with ectopic adrenocorticotropin Cushing's syndrome. *J Clin Endocrinol Metab* 88:4754–4758
220. **Lastoria S, Vergara E, Palmieri G, Acampa W, Varrella P, Caraco C, Bianco RA, Muto P, Salvatore M** 1998 In vivo detection of malignant thymic masses by indium-111-DTPA-D-Phe1-octreotide scintigraphy. *J Nucl Med* 39:634–639
221. **Davies MG, O'Dowd G, McEntee GP, Hennessy TP** 1990 Primary gastric carcinoids: a view on management. *Br J Surg* 77:1013–1014
222. **Ricke J, Klose KJ, Mignon M, Oberg K, Wiedenmann B** 2001 Standardisation of imaging in neuroendocrine tumours: results of a European delphi process. *Eur J Radiol* 37:8–17
223. **Lebtahi R, Cadiot G, Sarda L, Daou D, Faraggi M, Petegnief Y, Mignon M, le Guludec D** 1997 Clinical impact of somatostatin receptor scintigraphy in the management of patients with neuroendocrine gastroenteropancreatic tumors. *J Nucl Med* 38:853–858
224. **Termanini B, Gibril F, Reynolds JC, Doppman JL, Chen CC, Stewart CA, Sutliff VE, Jensen RT** 1997 Value of somatostatin receptor scintigraphy: a prospective study in gastrinoma of its effect on clinical management. *Gastroenterology* 112:335–347
225. **Cadiot G, Bonnaud G, Lebtahi R, Sarda L, Ruzsniwski P, Le Guludec D, Mignon M** 1997 Usefulness of somatostatin receptor scintigraphy in the management of patients with Zollinger-Ellison syndrome. Groupe de Recherche et d'Etude du Syndrome de Zollinger-Ellison (GRESZE). *Gut* 41:107–114
226. **Rioux M, Langis P, Naud F** 1995 Sonographic appearance of primary small bowel carcinoid tumor. *Abdom Imaging* 20:37–43
227. **Andersson T, Eriksson B, Lindgren PG, Wilander E, Oberg K** 1987 Percutaneous ultrasonography-guided cutting biopsy from liver metastases of endocrine gastrointestinal tumors. *Ann Surg* 206:728–732
228. **Semelka RC, John G, Kelekis NL, Burdeny DA, Ascher SM** 1996 Small bowel neoplastic disease: demonstration by MRI. *J Magn Reson Imaging* 6:855–860
229. **Sugimoto E, Lorelius LE, Eriksson B, Oberg K** 1995 Midgut carcinoid tumours. CT appearance. *Acta Radiol* 36:367–371
230. **Thompson GB, van Heerden JA, Martin Jr JK, Schutt AJ, Ilstrup DM, Carney JA** 1985 Carcinoid tumors of the gastrointestinal tract: presentation, management, and prognosis. *Surgery* 98:1054–1063
231. **Yoshida M, Tsukamoto Y, Niwa Y, Goto H, Hase S, Hayakawa T, Okamura S** 1995 Endoscopic assessment of invasion of colorectal tumors with a new high-frequency ultrasound probe. *Gastrointest Endosc* 41:587–592
232. **Corleto VD, Panzuto F, Falconi M, Cannizzaro R, Angeletti S, Moretti A, Delle FG, Farinati F** 2001 Digestive neuroendocrine tumours: diagnosis and treatment in Italy. A survey by the Oncology Study Section of the Italian Society of Gastroenterology (SIGE). *Dig Liver Dis* 33:217–221
233. **Krausz Y, Keidar Z, Kogan I, Even-Sapir E, Bar-Shalom R, Engel A, Rubinstein R, Sachs J, Bocher M, Agranovicz S, Chisin R, Israel O** 2003 SPECT/CT hybrid imaging with ^{111}In -pentetreotide in assessment of neuroendocrine tumours. *Clin Endocrinol (Oxf)* 59:565–573
234. **Vinik AI, Moattari AR** 1989 Treatment of endocrine tumors of the pancreas. *Endocrinol Metab Clin North Am* 18:483–518
235. **Scott BA, Gatenby RA** 1998 Imaging advances in the diagnosis of endocrine neoplasia. *Curr Opin Oncol* 10:37–42
236. **Service FJ, McMahon MM, O'Brien PC, Ballard DJ** 1991 Functioning insulinoma—incidence, recurrence, and long-term survival of patients: a 60-year study. *Mayo Clin Proc* 66:711–719
237. **Outwater EK, Siegelman ES** 1996 MR imaging of pancreatic disorders. *Top Magn Reson Imaging* 8:265–289
238. **Service FJ** 1999 Diagnostic approach to adults with hypoglycemic disorders. *Endocrinol Metab Clin North Am* 28:519–532
239. **Perry RR, Vinik AI** 1996 Endocrine tumors of the gastrointestinal tract. *Annu Rev Med* 47:57–68
240. **Grant CS** 1996 Gastrointestinal endocrine tumours. *Insulinoma*. *Baillieres Clin Gastroenterol* 10:645–671
241. **Taheri S, Meeran K** 2000 Islet cell tumours: diagnosis and medical management. *Hosp Med* 61:824–829
242. **Fajans SS, Vinik AI** 1989 Insulin-producing islet cell tumors. *Endocrinol Metab Clin North Am* 18:45–74
243. **Seckl MJ, Mulholland PJ, Bishop AE, Teale JD, Hales CN, Glaser M, Watkins S, Seckl JR** 1999 Hypoglycemia due to an insulin-secreting small-cell carcinoma of the cervix. *N Engl J Med* 341:733–736
244. **Dizon AM, Kowalyk S, Hoogwerf BJ** 1999 Neuroglycopenic and

- other symptoms in patients with insulinomas. *Am J Med* 106:307–310
245. Service FJ 1991 Hypoglycemias. *West J Med* 154:442–454
 246. Service FJ 1995 Hypoglycemia. *Med Clin North Am* 79:1–8
 247. Service FJ 1995 Hypoglycemic disorders. *N Engl J Med* 332:1144–1152
 248. Hirshberg B, Livi A, Bartlett DL, Libutti SK, Alexander HR, Doppman JL, Skarulis MC, Gorden P 2000 Forty-eight-hour fast: the diagnostic test for insulinoma. *J Clin Endocrinol Metab* 85:3222–3226
 249. Service FJ 1999 Classification of hypoglycemic disorders. *Endocrinol Metab Clin North Am* 28:501–517
 250. Kao PC, Taylor RL, Service FJ 1994 Proinsulin by immunochromatometric assay for the diagnosis of insulinoma. *J Clin Endocrinol Metab* 78:1048–1051
 251. Dons RF, Hodge J, Ginsberg BH, Brennan MF, Cryer PE, Kourides IA, Gorden P 1985 Anomalous glucose and insulin responses in patients with insulinoma. Caveats for diagnosis. *Arch Intern Med* 145:1861–1863
 252. Eriksson B, Oberg K 2000 Neuroendocrine tumours of the pancreas. *Br J Surg* 87:129–131
 253. Doppman JL, Chang R, Fraker DL, Norton JA, Alexander HR, Miller DL, Collier E, Skarulis MC, Gorden P 1995 Localization of insulinomas to regions of the pancreas by intra-arterial stimulation with calcium. *Ann Intern Med* 123:269–273
 254. O'Shea D, Rohrer-Theurs AW, Lynn JA, Jackson JE, Bloom SR 1996 Localization of insulinomas by selective intraarterial calcium injection. *J Clin Endocrinol Metab* 81:1623–1627
 255. Drake WM, Miraki F, Siddiqi A, Yateman M, Barnes NC, Camacho-Hubner C, Monson JP 1998 Dose-related effects of growth hormone on IGF-I and IGF-binding protein-3 levels in non-islet cell tumour hypoglycaemia. *Eur J Endocrinol* 139:532–536
 256. Burns AR, Dackiw AP 2003 Insulinoma. *Curr Treat Options Oncol* 4:309–317
 257. Danforth Jr DN, Gorden P, Brennan MF 1984 Metastatic insulin-secreting carcinoma of the pancreas: clinical course and the role of surgery. *Surgery* 96:1027–1037
 258. Service FJ, Natt N, Thompson GB, Grant CS, van Heerden JA, Andrews JC, Lorenz E, Terzic A, Lloyd RV 1999 Noninsulinoma pancreatogenous hypoglycemia: a novel syndrome of hyperinsulinemic hypoglycemia in adults independent of mutations in Kir6.2 and SUR1 genes. *J Clin Endocrinol Metab* 84:1582–1589
 259. Kaczirek K, Soleiman A, Schindl M, Passler C, Scheuba C, Prager G, Kaserer K, Niederle B 2003 Nesidioblastosis in adults: a challenging cause of organic hyperinsulinism. *Eur J Clin Invest* 33:488–492
 260. Wolfe MM, Jensen RT 1987 Zollinger-Ellison syndrome. Current concepts in diagnosis and management. *N Engl J Med* 317:1200–1209
 261. Wolfe MM, Alexander RW, McGuigan JE 1982 Extraprostatic, extraintestinal gastrinoma: effective treatment by surgery. *N Engl J Med* 306:1533–1536
 262. Maton PN, Gardner JD, Jensen RT 1989 Diagnosis and management of Zollinger-Ellison syndrome. *Endocrinol Metab Clin North Am* 18:519–543
 263. Noda S, Norton JA, Jensen RT, Gay Jr WA 1999 Surgical resection of intracardiac gastrinoma. *Ann Thorac Surg* 67:532–533
 264. Roy PK, Venzon DJ, Shojamanesh H, Abou-Saif A, Peghini P, Doppman JL, Gibril F, Jensen RT 2000 Zollinger-Ellison syndrome. Clinical presentation in 261 patients. *Medicine (Baltimore)* 79:379–411
 265. Maton PN, Gardner JD, Jensen RT 1986 Cushing's syndrome in patients with the Zollinger-Ellison syndrome. *N Engl J Med* 315:1–5
 266. Zollinger RM, Ellison EC, O'Dorisio TM, Sparks J 1984 Thirty years' experience with gastrinoma. *World J Surg* 8:427–435
 267. Benya RV, Metz DC, Venzon DJ, Fishbeyn VA, Strader DB, Orbuch M, Jensen RT 1994 Zollinger-Ellison syndrome can be the initial endocrine manifestation in patients with multiple endocrine neoplasia-type I. *Am J Med* 97:436–444
 268. Weber HC, Venzon DJ, Lin JT, Fishbeyn VA, Orbuch M, Strader DB, Gibril F, Metz DC, Fraker DL, Norton JA 1995 Determinants of metastatic rate and survival in patients with Zollinger-Ellison syndrome: a prospective long-term study. *Gastroenterology* 108:1637–1649
 269. Jensen RT, Fraker DL 1994 Zollinger-Ellison syndrome. Advances in treatment of gastric hypersecretion and the gastrinoma. *JAMA* 271:1429–1435
 270. Orloff SL, Debas HT 1995 Advances in the management of patients with Zollinger-Ellison syndrome. *Surg Clin North Am* 75:511–524
 271. McGuigan JE, Wolfe MM 1980 Secretin injection test in the diagnosis of gastrinoma. *Gastroenterology* 79:1324–1331
 272. Frucht H, Howard JM, Slaff JI, Wank SA, McCarthy DM, Maton PN, Vinayek R, Gardner JD, Jensen RT 1989 Secretin and calcium provocative tests in the Zollinger-Ellison syndrome. A prospective study. *Ann Intern Med* 111:713–722
 273. Roy PK, Venzon DJ, Feigenbaum KM, Koviack PD, Bashir S, Ojeaburu JV, Gibril F, Jensen RT 2001 Gastric secretion in Zollinger-Ellison syndrome. Correlation with clinical expression, tumor extent and role in diagnosis—a prospective NIH study of 235 patients and a review of 984 cases in the literature. *Medicine (Baltimore)* 80:189–222
 274. Kisker O, Bastian D, Bartsch D, Nies C, Rothmund M 1998 Localization, malignant potential, and surgical management of gastrinomas. *World J Surg* 22:651–657
 275. Skogseid B, Eriksson B, Lundqvist G, Lorelius LE, Rastad J, Wide L, Akerstrom G, Oberg K 1991 Multiple endocrine neoplasia type 1: a 10-year prospective screening study in four kindreds. *J Clin Endocrinol Metab* 73:281–287
 276. Frankton S, Bloom SR 1996 Gastrointestinal endocrine tumours. *Glucagonomas*. *Baillieres Clin Gastroenterol* 10:697–705
 277. Wermers RA, Fatourechhi V, Wynne AG, Kvols LK, Lloyd RV 1996 The glucagonoma syndrome. Clinical and pathologic features in 21 patients. *Medicine (Baltimore)* 75:53–63
 278. Chastain MA 2001 The glucagonoma syndrome: a review of its features and discussion of new perspectives. *Am J Med Sci* 321:306–320
 279. Edney JA, Hofmann S, Thompson JS, Kessinger A 1990 Glucagonoma syndrome is an underdiagnosed clinical entity. *Am J Surg* 160:625–628
 280. Stacpoole PW 1981 The glucagonoma syndrome: clinical features, diagnosis, and treatment. *Endocr Rev* 2:347–361
 281. Stacpoole PW, Jaspan J, Kasselberg AG, Halter SA, Polonsky K, Gluck FW, Liljenquist JE, Rabin D 1981 A familial glucagonoma syndrome: genetic, clinical and biochemical features. *Am J Med* 70:1017–1026
 282. Prinz RA, Dorsch TR, Lawrence AM 1981 Clinical aspects of glucagon-producing islet cell tumors. *Am J Gastroenterol* 76:125–131
 283. Domen RE, Shaffer Jr MB, Finke J, Sterin WK, Hurst CB 1980 The glucagonoma syndrome. Report of a case. *Arch Intern Med* 140:262–263
 284. Pujol RM, Wang CY, El Azhary RA, Su WP, Gibson LE, Schroeter AL 2004 Necrolytic migratory erythema: clinicopathologic study of 13 cases. *Int J Dermatol* 43:12–18
 285. Soga J, Yakuwa Y 1998 Vipoma/diarrheogenic syndrome: a statistical evaluation of 241 reported cases. *J Exp Clin Cancer Res* 17:389–400
 286. Park SK, O'Dorisio MS, O'Dorisio TM 1996 Vasoactive intestinal polypeptide-secreting tumours: biology and therapy. *Baillieres Clin Gastroenterol* 10:673–696
 287. Friesen SR 1987 Update on the diagnosis and treatment of rare neuroendocrine tumors. *Surg Clin North Am* 67:379–393
 288. O'Dorisio TM, Mekhjian HS, Gaginella TS 1989 Medical therapy of VIPomas. *Endocrinol Metab Clin North Am* 18:545–556
 289. Peng SY, Li JT, Liu YB, Fang HQ, Wu YL, Peng CH, Wang XB, Qian HR 2004 Diagnosis and treatment of VIPoma in China (case report and 31 cases review): diagnosis and treatment of VIPoma. *Pancreas* 28:93–97
 290. Soga J, Yakuwa Y 1999 Somatostatinoma/inhibitory syndrome: a statistical evaluation of 173 reported cases as compared to other pancreatic endocrinomas. *J Exp Clin Cancer Res* 18:13–22
 291. Harris GJ, Tio F, Cruz Jr AB 1987 Somatostatinoma: a case report and review of the literature. *J Surg Oncol* 36:8–16
 292. Mao C, Shah A, Hanson DJ, Howard JM 1995 Von Recklinghausen's disease associated with duodenal somatostatinoma: contrast of

- duodenal versus pancreatic somatostatinomas. *J Surg Oncol* 59:67–73
293. Dayal Y, Tallberg KA, Nunnemacher G, DeLellis RA, Wolfe HJ 1986 Duodenal carcinoids in patients with and without neurofibromatosis. A comparative study. *Am J Surg Pathol* 10:348–357
 294. Axelrod L, Bush MA, Hirsch HJ, Loo SW 1981 Malignant somatostatinoma: clinical features and metabolic studies. *J Clin Endocrinol Metab* 52:886–896
 295. Tanaka S, Yamasaki S, Matsushita H, Ozawa Y, Kurosaki A, Takeuchi K, Hoshihara Y, Doi T, Watanabe G, Kawaminami K 2000 Duodenal somatostatinoma: a case report and review of 31 cases with special reference to the relationship between tumor size and metastasis. *Pathol Int* 50:146–152
 296. Hirshberg B, Conn PM, Uwaifo GI, Blauer KL, Clark BD, Nieman LK 2003 Ectopic luteinizing hormone secretion and anovulation. *N Engl J Med* 348:312–317
 297. Corbetta S, Peracchi M, Cappiello V, Lania A, Lauri E, Vago L, Beck-Peccoz P, Spada A 2003 Circulating ghrelin levels in patients with pancreatic and gastrointestinal neuroendocrine tumors: identification of one pancreatic ghrelinoma. *J Clin Endocrinol Metab* 88:3117–3120
 298. Venkatesh S, Ordonez NG, Ajani J, Schultz PN, Hickey RC, Johnston DA, Samaan NA 1990 Islet cell carcinoma of the pancreas. A study of 98 patients. *Cancer* 65:354–357
 299. Lo CY, van Heerden JA, Thompson GB, Grant CS, Soreide JA, Harnsen WS 1996 Islet cell carcinoma of the pancreas. *World J Surg* 20:878–883
 300. Bartsch DK, Schilling T, Ramaswamy A, Gerdes B, Celik I, Wagner HJ, Simon B, Rothmund M 2000 Management of nonfunctioning islet cell carcinomas. *World J Surg* 24:1418–1424
 301. Norton JA 1994 Neuroendocrine tumors of the pancreas and duodenum. *Curr Probl Surg* 31:77–156
 302. Evans DB, Skibber JM, Lee JE, Cleary KR, Ajani JA, Gagel RF, Sellin RV, Fenoglio CJ, Merrell RC, Hickey RC 1993 Nonfunctioning islet cell carcinoma of the pancreas. *Surgery* 114:1175–1181
 303. Rigaud G, Missiaglia E, Moore PS, Zamboni G, Falconi M, Talamini G, Pesci A, Baron A, Lissandrini D, Rindi G, Grigolato P, Pederzoli P, Scarpa A 2001 High resolution allelotype of nonfunctional pancreatic endocrine tumors: identification of two molecular subgroups with clinical implications. *Cancer Res* 61:285–292
 304. van Eijck CH, Lamberts SW, Lemaire LC, Jeekel H, Bosman FT, Reubi JC, Bruining HA, Krenning EP 1996 The use of somatostatin receptor scintigraphy in the differential diagnosis of pancreatic duct cancers and islet cell tumors. *Ann Surg* 224:119–124
 305. Pipeleers-Marichal M, Somers G, Willems G, Foulis A, Imrie C, Bishop AE, Polak JM, Hacki WH, Stamm B, Heitz PU 1990 Gastrinomas in the duodenum of patients with multiple endocrine neoplasia type 1 and the Zollinger-Ellison syndrome. *N Engl J Med* 322:723–727
 306. Norton JA 1999 Intra-operative procedures to localize endocrine tumours of the pancreas and duodenum. *Ital J Gastroenterol Hepatol* 31(Suppl 2):S195–S197
 307. Skogseid B, Oberg K, Eriksson B, Juhlin C, Granberg D, Akerstrom G, Rastad J 1996 Surgery for asymptomatic pancreatic lesion in multiple endocrine neoplasia type I. *World J Surg* 20:872–876
 308. Skogseid B, Larsson C, Oberg K 1991 Genetic and clinical characteristics of multiple endocrine neoplasia type 1. *Acta Oncol* 30:485–488
 309. Skogseid B, Oberg K, Benson L, Lindgren PG, Lorelius LE, Lundquist G, Wide L, Wilander E 1987 A standardized meal stimulation test of the endocrine pancreas for early detection of pancreatic endocrine tumors in multiple endocrine neoplasia type 1 syndrome: five years experience. *J Clin Endocrinol Metab* 64:1233–1240
 310. Yu F, Venzon DJ, Serrano J, Goebel SU, Doppman JL, Gibril F, Jensen RT 1999 Prospective study of the clinical course, prognostic factors, causes of death, and survival in patients with long-standing Zollinger-Ellison syndrome. *J Clin Oncol* 17:615–630
 311. Ichikawa T, Peterson MS, Federle MP, Baron RL, Haradome H, Kawamori Y, Nawano S, Araki T 2000 Islet cell tumor of the pancreas: biphasic CT versus MR imaging in tumor detection. *Radiology* 216:163–171
 312. Buetow PC, Miller DL, Parrino TV, Buck JL 1997 Islet cell tumors of the pancreas: clinical, radiologic, and pathologic correlation in diagnosis and localization. *Radiographics* 17:453–472
 313. King CM, Reznick RH, Dacie JE, Wass JA 1994 Imaging islet cell tumours. *Clin Radiol* 49:295–303
 314. Zimmer T, Stolzel U, Bader M, Koppenhagen K, Hamm B, Buhr H, Riecken EO, Wiedenmann B 1996 Endoscopic ultrasonography and somatostatin receptor scintigraphy in the preoperative localisation of insulinomas and gastrinomas. *Gut* 39:562–568
 315. Scherubl H, Bredeek U, Zimmer T, Riecken EO 1996 [Screening for hereditary neuroendocrine tumors of the gastrointestinal-pancreatic system]. *Z Gastroenterol* 34:XX
 316. Alexander HR, Fraker DL, Norton JA, Bartlett DL, Tio L, Benjamin SB, Doppman JL, Goebel SU, Serrano J, Gibril F, Jensen RT 1998 Prospective study of somatostatin receptor scintigraphy and its effect on operative outcome in patients with Zollinger-Ellison syndrome. *Ann Surg* 228:228–238
 317. Cadiot G, Lebtahi R, Sarda L, Bonnaud G, Marmuse JP, Vissuzaine C, Ruzsniwski P, Le Guludec D, Mignon M 1996 Preoperative detection of duodenal gastrinomas and peripancreatic lymph nodes by somatostatin receptor scintigraphy. *Groupe D'etude Du Syndrome De Zollinger-Ellison. Gastroenterology* 111:845–854
 318. Schirmer WJ, Melvin WS, Rush RM, O'Dorisio TM, Pozderac RV, Olsen JO, Ellison EC 1995 Indium-111-pentetreotide scanning versus conventional imaging techniques for the localization of gastrinoma. *Surgery* 118:1105–1113
 319. Bombardieri E, Maccauro M, De Deckere E, Savelli G, Chiti A 2001 Nuclear medicine imaging of neuroendocrine tumours. *Ann Oncol* 12(Suppl 2):S51–S61
 320. Thoeni RF, Mueller-Lisse UG, Chan R, Do NK, Shyn PB 2000 Detection of small, functional islet cell tumors in the pancreas: selection of MR imaging sequences for optimal sensitivity. *Radiology* 214:483–490
 321. London JF, Shawker TH, Doppman JL, Frucht HH, Vinayek R, Stark HA, Miller LS, Miller DL, Norton JA, Jensen RT 1991 Zollinger-Ellison syndrome: prospective assessment of abdominal US in the localization of gastrinomas. *Radiology* 178:763–767
 322. Rosch T, Lightdale CJ, Botet JF, Boyce GA, Sivak Jr MV, Yasuda K, Heyder N, Palazzo L, Dancygier H, Schusdziarra V 1992 Localization of pancreatic endocrine tumors by endoscopic ultrasonography. *N Engl J Med* 326:1721–1726
 323. Glover JR, Shorvon PJ, Lees WR 1992 Endoscopic ultrasound for localisation of islet cell tumours. *Gut* 33:108–110
 324. Anderson MA, Carpenter S, Thompson NW, Nostrant TT, Elta GH, Scheiman JM 2000 Endoscopic ultrasound is highly accurate and directs management in patients with neuroendocrine tumors of the pancreas. *Am J Gastroenterol* 95:2271–2277
 325. Bansal R, Tierney W, Carpenter S, Thompson N, Scheiman JM 1999 Cost effectiveness of EUS for preoperative localization of pancreatic endocrine tumors. *Gastrointest Endosc* 49:19–25
 326. Ruzsniwski P, Amouyal P, Amouyal G, Grange JD, Mignon M, Bouche O, Bernades P 1995 Localization of gastrinomas by endoscopic ultrasonography in patients with Zollinger-Ellison syndrome. *Surgery* 117:629–635
 327. Van Hoe L, Gryspeerdt S, Marchal G, Baert AL, Mertens L 1995 Helical CT for the preoperative localization of islet cell tumors of the pancreas: value of arterial and parenchymal phase images. *AJR Am J Roentgenol* 165:1437–1439
 328. Legmann P, Vignaux O, Dousse B, Baraza AJ, Palazzo L, Dumontier I, Coste J, Louvel A, Roseau G, Couturier D, Bonnin A 1998 Pancreatic tumors: comparison of dual-phase helical CT and endoscopic sonography. *AJR Am J Roentgenol* 170:1315–1322
 329. Owen NJ, Sohaib SA, Peppercorn PD, Monson JP, Grossman AB, Besser GM, Reznick RH 2001 MRI of pancreatic neuroendocrine tumours. *Br J Radiol* 74:968–973
 330. Semelka RC, Cumming MJ, Shoenuit JP, Magro CM, Yaffe CS, Kroeker MA, Greenberg HM 1993 Islet cell tumors: comparison of dynamic contrast-enhanced CT and MR imaging with dynamic gadolinium enhancement and fat suppression. *Radiology* 186:799–802
 331. Debray MP, Geoffroy O, Laissy JP, Lebtahi R, Silbermann-Hoffman O, Henry-Feugeas MC, Cadiot G, Mignon M, Schouman-

- Clayes E 2001 Imaging appearances of metastases from neuroendocrine tumours of the pancreas. *Br J Radiol* 74:1065–1070
332. **Brandle M, Pfammatter T, Spinass GA, Lehmann R, Schmid C** 2001 Assessment of selective arterial calcium stimulation and hepatic venous sampling to localize insulin-secreting tumours. *Clin Endocrinol (Oxf)* 55:357–362
333. **Pasieka JL, McLeod MK, Thompson NW, Burney RE** 1992 Surgical approach to insulinomas. Assessing the need for preoperative localization. *Arch Surg* 127:442–447
334. **Thom AK, Norton JA, Axiotis CA, Jensen RT** 1991 Location, incidence, and malignant potential of duodenal gastrinomas. *Surgery* 110:1086–1091
335. **Lamberts SW, Hofland LJ, Lely AJ, de Herder WW** 1998 Somatostatin receptor expression in multiple endocrine neoplasia and in von Hippel-Lindau disease. *J Intern Med* 243:569–571
336. **Jais P, Terris B, Ruzsiewicz P, LeRomancer M, Reyl-Desmars F, Vissuzaine C, Cadiot G, Mignon M, Lewin MJ** 1997 Somatostatin receptor subtype gene expression in human endocrine gastroenteropancreatic tumours. *Eur J Clin Invest* 27:639–644
337. **Grams D, Skogseid B, Wilander E, Eriksson B, Martensson H, Cedermark B, Ahren B, Kristofferson A, Oberg K, Rastad J** 1992 Pancreatic tumors in multiple endocrine neoplasia type 1: clinical presentation and surgical treatment. *World J Surg* 16:611–618
338. **Shapiro B, Fig LM** 1989 Management of pheochromocytoma. *Endocrinol Metab Clin North Am* 18:443–481
339. **Troncione L, Rufini V** 1997 131I-MIBG therapy of neural crest tumours (review). *Anticancer Res* 17:1823–1831
340. **Erickson D, Kudva YC, Ebersold MJ, Thompson GB, Grant CS, van Heerden JA, Young Jr WF** 2001 Benign paragangliomas: clinical presentation and treatment outcomes in 236 patients. *J Clin Endocrinol Metab* 86:5210–5216
341. **Mantero F, Terzolo M, Arnaldi G, Osella G, Masini AM, Ali A, Giovagnetti M, Opocher G, Angeli A** 2000 A survey on adrenal incidentaloma in Italy. Study Group on Adrenal Tumors of the Italian Society of Endocrinology. *J Clin Endocrinol Metab* 85:637–644
342. **Bravo EL, Tagle R** 2003 Pheochromocytoma: state-of-the-art and future prospects. *Endocr Rev* 24:539–553
343. **Kudva YC, Sawka AM, Young Jr WF** 2003 Clinical review 164: the laboratory diagnosis of adrenal pheochromocytoma: the Mayo Clinic experience. *J Clin Endocrinol Metab* 88:4533–4539
344. **Grossman AB, Kaltsas GA** 2003 Adrenal medulla. Physiology and pathology. In: Besser GM, Thorner MO, eds. *Comprehensive clinical endocrinology*. Edinburgh: Blackwell; 223–237
345. **Schlumberger M, Gicquel C, Lumbroso J, Tenenbaum F, Comoy E, Bosq J, Fonseca E, Ghillani PP, Aubert B, Travagli JP** 1992 Malignant pheochromocytoma: clinical, biological, histologic and therapeutic data in a series of 20 patients with distant metastases. *J Endocrinol Invest* 15:631–642
346. **Lewi HJ, Reid R, Mucci B, Davidson JK, Kyle KF, Macpherson SG, Semple P, Kaye S** 1985 Malignant phaeochromocytoma. *Br J Urol* 57:394–398
347. **Loh KC, Fitzgerald PA, Matthey KK, Yeo PP, Price DC** 1997 The treatment of malignant pheochromocytoma with iodine-131 metaiodobenzylguanidine (131I-MIBG): a comprehensive review of 116 reported patients. *J Endocrinol Invest* 20:648–658
348. **Shapiro B, Sisson JC, Lloyd R, Nakajo M, Satterlee W, Beierwaltes WH** 1984 Malignant phaeochromocytoma: clinical, biochemical and scintigraphic characterization. *Clin Endocrinol (Oxf)* 20:189–203
349. **Shapiro B, Copp JE, Sisson JC, Eyre PL, Wallis J, Beierwaltes WH** 1985 Iodine-131 metaiodobenzylguanidine for the locating of suspected pheochromocytoma: experience in 400 cases. *J Nucl Med* 26:576–585
350. **Mundschenk J, Lehnert H** 1998 Malignant pheochromocytoma. *Exp Clin Endocrinol Diabetes* 106:373–376
351. **Goldstein RE, O'Neill Jr JA, Holcomb III GW, Morgan III WM, Neblett III WW, Oates JA, Brown N, Nadeau J, Smith B, Page DL, Abumrad NN, Scott Jr HW** 1999 Clinical experience over 48 years with pheochromocytoma. *Ann Surg* 229:755–764
352. **Eng C** 1996 Seminars in medicine of the Beth Israel Hospital, Boston. The RET proto-oncogene in multiple endocrine neoplasia type 2 and Hirschsprung's disease. *N Engl J Med* 335:943–951
353. **Ponder BA** 1999 The phenotypes associated with ret mutations in the multiple endocrine neoplasia type 2 syndrome. *Cancer Res* 59:1736s–1741s
354. **Walther MM, Herring J, Enquist E, Keiser HR, Linehan WM** 1999 von Recklinghausen's disease and pheochromocytomas. *J Urol* 162:1582–1586
355. **Kebebew E, Duh QY** 1998 Benign and malignant pheochromocytoma: diagnosis, treatment, and follow-up. *Surg Oncol Clin N Am* 7:765–789
356. **Roman S** 2004 Pheochromocytoma and functional paraganglioma. *Curr Opin Oncol* 16:8–12
357. **Eigelberger MS, Duh QY** 2001 Pheochromocytoma. *Curr Treat Options Oncol* 2:321–329
358. **Orchard T, Grant CS, van Heerden JA, Weaver A** 1993 Pheochromocytoma—continuing evolution of surgical therapy. *Surgery* 114:1153–1158
359. **Cohen CD, Dent DM** 1984 Phaeochromocytoma and acute cardiovascular death (with special reference to myocardial infarction). *Postgrad Med J* 60:111–115
360. **Pacak K, Linehan WM, Eisenhofer G, Walther MM, Goldstein DS** 2001 Recent advances in genetics, diagnosis, localization, and treatment of pheochromocytoma. *Ann Intern Med* 134:315–329
361. **Eisenhofer G, Lenders JW, Pacak K** 2004 Biochemical diagnosis of pheochromocytoma. *Front Horm Res* 31:76–106
362. **van Heerden JA, Roland CF, Carney JA, Sheps SG, Grant CS** 1990 Long-term evaluation following resection of apparently benign pheochromocytoma(s)/paraganglioma(s). *World J Surg* 14:325–329
363. **Coutant R, Pein F, Adamsbaum C, Oberlin O, Dubouset J, Guinebretiere JM, Teinturier C, Bougneres PF** 1999 Prognosis of children with malignant pheochromocytoma. Report of 2 cases and review of the literature. *Horm Res* 52:145–149
364. **Rao F, Keiser HR, O'Connor DT** 2000 Malignant pheochromocytoma. Chromaffin granule transmitters and response to treatment. *Hypertension* 36:1045–1052
365. **Lehnert H, Mundschenk J, Hahn K** 2004 Malignant pheochromocytoma. *Front Horm Res* 31:155–162
366. **Kaltsas GA, Papadogias D, Grossman AB** 2004 The clinical presentation (symptoms and signs) of sporadic and familial chromaffin cell tumours (phaeochromocytomas and paragangliomas). *Front Horm Res* 31:61–75
367. **Mukherjee JJ, Peppercorn PD, Reznick RH, Patel V, Kaltsas G, Besser M, Grossman AB** 1997 Pheochromocytoma: effect of non-ionic contrast medium in CT on circulating catecholamine levels. *Radiology* 202:227–231
368. **Peppercorn PD, Grossman AB, Reznick RH** 1998 Imaging of incidentally discovered adrenal masses. *Clin Endocrinol (Oxf)* 48:379–388
369. **Maurea S, Cuocolo A, Reynolds JC, Neumann RD, Salvatore M** 1996 Diagnostic imaging in patients with paragangliomas. Computed tomography, magnetic resonance and MIBG scintigraphy comparison. *Q J Nucl Med* 40:365–371
370. **Newbould EC, Ross GA, Dacie JE, Bouloux PM, Besser GM, Grossman A** 1991 The use of venous catheterization in the diagnosis and localization of bilateral phaeochromocytomas. *Clin Endocrinol (Oxf)* 35:55–59
371. **Pacak K, Goldstein DS, Doppman JL, Shulkin BL, Udelsman R, Eisenhofer G** 2001 A "phea" lurks: novel approaches for locating occult pheochromocytoma. *J Clin Endocrinol Metab* 86:3641–3646
372. **Baysal BE, Ferrell RE, Willett-Brozick JE, Lawrence EC, Myssiorek D, Bosch A, van der Mey A, Taschner PE, Rubinstein WS, Myers EN, Richard III CW, Cornilisse CJ, Devilee P, Devlin B** 2000 Mutations in SDHD, a mitochondrial complex II gene, in hereditary paraganglioma. *Science* 287:848–851
373. **Brauch H, Hoepfner W, Jahnig H, Wohl T, Engelhardt D, Spelsberg F, Ritter MM** 1997 Sporadic pheochromocytomas are rarely associated with germline mutations in the vhl tumor suppressor gene or the ret protooncogene. *J Clin Endocrinol Metab* 82:4101–4104
374. **Chew SL, Lavender P, Jain A, Weber A, Ross RJ, Wass JA, Besser GM, Clark AJ** 1995 Absence of mutations in the MEN2A region of the ret proto-oncogene in non-MEN 2A phaeochromocytomas. *Clin Endocrinol (Oxf)* 42:17–21
375. **Kubota Y, Nakada T, Sasagawa I, Yanai H, Itoh K** 1998 Elevated

- levels of telomerase activity in malignant pheochromocytoma. *Cancer* 82:176–179
376. Kumaki N, Kajiwara H, Kameyama K, DeLellis RA, Asa SL, Osamura RY, Takami H 2002 Prediction of malignant behavior of pheochromocytomas and paragangliomas using immunohistochemical techniques. *Endocr Pathol* 13:149–156
 377. Salmenkivi K, Haglund C, Ristimaki A, Arola J, Heikkila P 2001 Increased expression of cyclooxygenase-2 in malignant pheochromocytomas. *J Clin Endocrinol Metab* 86:5615–5619
 378. Salmenkivi K, Arola J, Voutilainen R, Ilvesmaki V, Haglund C, Kahri AI, Heikkila P, Liu J 2001 Inhibin/activin β B-subunit expression in pheochromocytomas favors benign diagnosis. *J Clin Endocrinol Metab* 86:2231–2235
 379. Raue F 1998 German medullary thyroid carcinoma/multiple endocrine neoplasia registry. German MTC/MEN Study Group. Medullary Thyroid Carcinoma/Multiple Endocrine Neoplasia Type 2. *Langenbecks Arch Surg* 383:334–336
 380. Kebebew E, Clark OH 2000 Medullary thyroid cancer. *Curr Treat Options Oncol* 1:359–367
 381. Kebebew E, Ituarte PH, Siperstein AE, Duh QY, Clark OH 2000 Medullary thyroid carcinoma: clinical characteristics, treatment, prognostic factors, and a comparison of staging systems. *Cancer* 88:1139–1148
 382. Orlandi F, Caraci P, Mussa A, Saggiorato E, Pancani G, Angeli A 2001 Treatment of medullary thyroid carcinoma: an update. *Endocr Relat Cancer* 8:135–147
 383. Giuffrida D, Gharib H 1998 Current diagnosis and management of medullary thyroid carcinoma. *Ann Oncol* 9:695–701
 384. Hennessy JF, Wells Jr SA, Ontjes DA, Cooper CW 1974 A comparison of pentagastrin injection and calcium infusion as provocative agents for the detection of medullary carcinoma of the thyroid. *J Clin Endocrinol Metab* 39:487–495
 385. Machens A, Niccoli-Sire P, Hoegel J, Frank-Raue K, van Vroonhoven TJ, Roehrer HD, Wahl RA, Lamesch P, Raue F, Conte-Devolx B, Dralle H 2003 Early malignant progression of hereditary medullary thyroid cancer. *N Engl J Med* 349:1517–1525
 386. Machens A, Holzhausen HJ, Thanh PN, Dralle H 2003 Malignant progression from C-cell hyperplasia to medullary thyroid carcinoma in 167 carriers of RET germline mutations. *Surgery* 134:425–431
 387. Soh EY, Clark OH 1996 Surgical considerations and approach to thyroid cancer. *Endocrinol Metab Clin North Am* 25:115–139
 388. Cohen R, Campos JM, Salaun C, Heshmati HM, Kraimps JL, Proye C, Sarfati E, Henry JF, Niccoli-Sire P, Modigliani E 2000 Preoperative calcitonin levels are predictive of tumor size and postoperative calcitonin normalization in medullary thyroid carcinoma. Groupe d'Etudes des Tumeurs a Calcitonine (GETC). *J Clin Endocrinol Metab* 85:919–922
 389. Dottorini ME, Assi A, Sironi M, Sangalli G, Spreafico G, Colombo L 1996 Multivariate analysis of patients with medullary thyroid carcinoma. Prognostic significance and impact on treatment of clinical and pathologic variables. *Cancer* 77:1556–1565
 390. Vierhapper H, Raber W, Bieglmayer C, Kaserer K, Weinhausl A, Niederle B 1997 Routine measurement of plasma calcitonin in nodular thyroid diseases. *J Clin Endocrinol Metab* 82:1589–1593
 391. Ledger GA, Khosla S, Lindor NM, Thibodeau SN, Gharib H 1995 Genetic testing in the diagnosis and management of multiple endocrine neoplasia type II. *Ann Intern Med* 122:118–124
 392. Engelbach M, Gorges R, Forst T, Pftzner A, Dawood R, Heerdt S, Kunt T, Bockisch A, Beyer J 2000 Improved diagnostic methods in the follow-up of medullary thyroid carcinoma by highly specific calcitonin measurements. *J Clin Endocrinol Metab* 85:1890–1894
 393. Kebebew E, Kikuchi S, Duh QY, Clark OH 2000 Long-term results of reoperation and localizing studies in patients with persistent or recurrent medullary thyroid cancer. *Arch Surg* 135:895–901
 394. Weber T, Klar E 2001 Minimal residual disease in thyroid carcinoma. *Semin Surg Oncol* 20:272–277
 395. Dorr U, Frank-Raue K, Raue F, Sautter-Bihl ML, Guzman G, Buhr HJ, Bihl H 1993 The potential value of somatostatin receptor scintigraphy in medullary thyroid carcinoma. *Nucl Med Commun* 14:439–445
 396. Rufini V, Salvatori M, Garganese MC, Di Giuda D, Lodovica Maussier M, Troncone L 2000 Role of nuclear medicine in the diagnosis and therapy of medullary thyroid carcinoma. *Rays* 25:273–282
 397. Behr TM, Gratz S, Markus PM, Dunn RM, Hufner M, Schauer A, Fischer M, Munz DL, Becker H, Becker W 1997 Anti-carcinoembryonic antigen antibodies versus somatostatin analogs in the detection of metastatic medullary thyroid carcinoma: are carcinoembryonic antigen and somatostatin receptor expression prognostic factors? *Cancer* 80:2436–2457
 398. Abdelmoumene N, Schlumberger M, Gardet P, Roche A, Travagli JP, Francesc C, Parmentier C 1994 Selective venous sampling catheterisation for localisation of persisting medullary thyroid carcinoma. *Br J Cancer* 69:1141–1144
 399. Moley JF, Dilley WG, DeBenedetti MK 1997 Improved results of cervical reoperation for medullary thyroid carcinoma. *Ann Surg* 225:734–740
 400. Gasparoni P, Rubello D, Ferlin G 1997 Potential role of fluorine-18-deoxyglucose (FDG) positron emission tomography (PET) in the staging of primitive and recurrent medullary thyroid carcinoma. *J Endocrinol Invest* 20:527–530
 401. Arnold R, Frank M 1996 Control of growth in neuroendocrine gastro-enteropancreatic tumours. *Digestion* 57(Suppl 1):69–71
 402. Arnold R, Hiddemann W 1996 [Therapy of metastatic endocrine tumors of the gastrointestinal tract]. *Dtsch Med Wochenschr* 121:1346–1347
 403. Norton JA, Fraker DL, Alexander HR, Venzon DJ, Doppman JL, Serrano J, Goebel SU, Peghini PL, Roy PK, Gibril F, Jensen RT 1999 Surgery to cure the Zollinger-Ellison syndrome. *N Engl J Med* 341:635–644
 404. Oberg K 1999 Neuroendocrine gastrointestinal tumors—a condensed overview of diagnosis and treatment. *Ann Oncol* 10(Suppl 2):S3–S8
 405. Arnold R, Frank M 1996 Gastrointestinal endocrine tumours: medical management. *Baillieres Clin Gastroenterol* 10:737–759
 406. Hellman P, Lundstrom T, Ohrvall U, Eriksson B, Skogseid B, Oberg K, Tiensuu JE, Akerstrom G 2002 Effect of surgery on the outcome of midgut carcinoid disease with lymph node and liver metastases. *World J Surg* 26:991–997
 407. Oberg K 1999 [Therapeutic alternative in metastasizing neuroendocrine tumors. In carefully selected cases liver transplantation is possible]. *Lakartidningen* 96:3745–3747
 408. Norton JA, Warren RS, Kelly MG, Zuraek MB, Jensen RT 2003 Aggressive surgery for metastatic liver neuroendocrine tumors. *Surgery* 134:1057–1063
 409. Krempf M, Lumbroso J, Mornex R, Brendel AJ, Wemeau JL, Delisle MJ, Aubert B, Carpentier P, Fleury-Goyon MC, Gibold C 1991 Treatment of malignant pheochromocytoma with [131I]metaiodobenzylguanidine: a French multicenter study. *J Nucl Biol Med* 35:284–287
 410. Krempf M, Lumbroso J, Mornex R, Brendel AJ, Wemeau JL, Delisle MJ, Aubert B, Carpentier P, Fleury-Goyon MC, Gibold C 1991 Use of m-[131I]iodobenzylguanidine in the treatment of malignant pheochromocytoma. *J Clin Endocrinol Metab* 72:455–461
 411. Degen L, Beglinger C 1999 The role of octreotide in the treatment of gastroenteropancreatic endocrine tumors. *Digestion* 60(Suppl 2):9–14
 412. Eriksson B, Oberg K 1999 Summing up 15 years of somatostatin analog therapy in neuroendocrine tumors: future outlook. *Ann Oncol* 10(Suppl 2):S31–S38
 413. Moertel CG 1983 Treatment of the carcinoid tumor and the malignant carcinoid syndrome. *J Clin Oncol* 1:727–740
 414. Maton PN 1993 Review article: the management of Zollinger-Ellison syndrome. *Aliment Pharmacol Ther* 7:467–475
 415. Metz DC, Strader DB, Orbuch M, Koviack PD, Feigenbaum KM, Jensen RT 1993 Use of omeprazole in Zollinger-Ellison syndrome: a prospective nine-year study of efficacy and safety. *Aliment Pharmacol Ther* 7:597–610
 416. Schmid R, Allescher HD, Schepp W, Holscher A, Siewert R, Schusdziarra V, Classen M 1988 Effect of somatostatin on skin lesions and concentrations of plasma amino acids in a patient with glucagonoma-syndrome. *Hepatogastroenterology* 35:34–37
 417. Faiss S, Scherubl H, Riecken EO, Wiedenmann B 1996 Drug therapy in metastatic neuroendocrine tumors of the gastroenteropancreatic system. *Recent Results Cancer Res* 142:193–207

418. **Faiss S, Scherubl H, Riecken EO, Wiedenmann B** 1996 Interferon- α versus somatostatin or the combination of both in metastatic neuroendocrine gut and pancreatic tumours. *Digestion* 57(Suppl 1):84–85
419. **Oberg K** 2001 Established clinical use of octreotide and lanreotide in oncology. *Chemotherapy* 47(Suppl 2):40–53
420. **Saltz L, Trochanowski B, Buckley M, Heffernan B, Niedzwiecki D, Tao Y, Kelsen D** 1993 Octreotide as an antineoplastic agent in the treatment of functional and nonfunctional neuroendocrine tumors. *Cancer* 72:244–248
421. **Faiss S, Rath U, Mansmann U, Caird D, Clemens N, Riecken EO, Wiedenmann B** 1999 Ultra-high-dose lanreotide treatment in patients with metastatic neuroendocrine gastroenteropancreatic tumors. *Digestion* 60:469–476
422. **Pelley RJ, Bukowski RM** 1999 Recent advances in systemic therapy for gastrointestinal neuroendocrine tumors. *Curr Opin Oncol* 11:32–37
423. **Oberg K** 2001 Chemotherapy and biotherapy in the treatment of neuroendocrine tumours. *Ann Oncol* 12(Suppl 2):S111–S114
424. **Aparicio T, Ducreux M, Baudin E, Sabourin JC, De Baere T, Mitry E, Schlumberger M, Rougier P** 2001 Antitumour activity of somatostatin analogues in progressive metastatic neuroendocrine tumours. *Eur J Cancer* 37:1014–1019
425. **Lokich J** 1998 Carcinoid tumor regression with high-dose octreotide acetate: a patient report. *Am J Clin Oncol* 21:246–247
426. **Leong WL, Pasiaka JL** 2002 Regression of metastatic carcinoid tumors with octreotide therapy: two case reports and a review of the literature. *J Surg Oncol* 79:180–187
427. **Imtiaz KE, Monteith P, Khaleeli A** 2000 Complete histological regression of metastatic carcinoid tumour after treatment with octreotide. *Clin Endocrinol (Oxf)* 53:755–758
428. **Tomassetti P, Migliori M, Caletti GC, Fusaroli P, Corinaldesi R, Gullo L** 2000 Treatment of type II gastric carcinoid tumors with somatostatin analogues. *N Engl J Med* 343:551–554
429. **Scherubl H, Wiedenmann B, Riecken EO, Thomas F, Bohme E, Rath U** 1994 Treatment of the carcinoid syndrome with a depot formulation of the somatostatin analogue lanreotide. *Eur J Cancer* 30A:1590–1591
430. **Bajetta E, Di Bartolomeo M, Zilembo N, Bochicchio AM** 1993 Medical treatment of neuroendocrine tumors. *Tumori* 79:380–388
431. **Di Bartolomeo M, Bajetta E, Buzzoni R, Mariani L, Carnaghi C, Somma L, Zilembo N, Di Leo A** 1996 Clinical efficacy of octreotide in the treatment of metastatic neuroendocrine tumors. A study by the Italian Trials in Medical Oncology Group. *Cancer* 77:402–408
432. **Ruszniewski P, Ducreux M, Chayvialle JA, Blumberg J, Cloarec D, Michel H, Raymond JM, Dupas JL, Gouerou H, Jian R, Genestin E, Bernades P, Rougier P** 1996 Treatment of the carcinoid syndrome with the long-acting somatostatin analogue lanreotide: a prospective study in 39 patients. *Gut* 39:279–283
433. **Eriksson B, Renstrup J, Imam H, Oberg K** 1997 High-dose treatment with lanreotide of patients with advanced neuroendocrine gastrointestinal tumors: clinical and biological effects. *Ann Oncol* 8:1041–1044
434. **Tomassetti P, Migliori M, Gullo L** 1998 Slow-release lanreotide treatment in endocrine gastrointestinal tumors. *Am J Gastroenterol* 93:1468–1471
435. **Wymenga AN, Eriksson B, Salmela PI, Jacobsen MB, Van Cutsem EJ, Fiasse RH, Valimaki MJ, Renstrup J, de Vries EG, Oberg KE** 1999 Efficacy and safety of prolonged-release lanreotide in patients with gastrointestinal neuroendocrine tumors and hormone-related symptoms. *J Clin Oncol* 17:1111
436. **Ricci S, Antonuzzo A, Galli L, Orlandini C, Ferdeghini M, Boni G, Roncella M, Mosca F, Conte PF** 2000 Long-acting depot lanreotide in the treatment of patients with advanced neuroendocrine tumors. *Am J Clin Oncol* 23:412–415
437. **O'Toole D, Ducreux M, Bommelaer G, Wemeau JL, Bouche O, Catus F, Blumberg J, Ruszniewski P** 2000 Treatment of carcinoid syndrome: a prospective crossover evaluation of lanreotide versus octreotide in terms of efficacy, patient acceptability, and tolerance. *Cancer* 88:770–776
438. **Ducreux M, Ruszniewski P, Chayvialle JA, Blumberg J, Cloarec D, Michel H, Raymond JM, Dupas JL, Gouerou H, Jian R, Genestin E, Hammel P, Rougier P** 2000 The antitumoral effect of the long-acting somatostatin analog lanreotide in neuroendocrine tumors. *Am J Gastroenterol* 95:3276–3281
439. **Rubin J, Ajani J, Schirmer W, Venook AP, Bukowski R, Pommier R, Saltz L, Dandona P, Anthony L** 1999 Octreotide acetate long-acting formulation versus open-label subcutaneous octreotide acetate in malignant carcinoid syndrome. *J Clin Oncol* 17:600–606
440. **Ricci S, Antonuzzo A, Galli L, Ferdeghini M, Bodei L, Orlandini C, Conte PF** 2000 Octreotide acetate long-acting release in patients with metastatic neuroendocrine tumors pretreated with lanreotide. *Ann Oncol* 11:1127–1130
441. **Garland J, Buscombe JR, Bouvier C, Bouloux P, Chapman MH, Chow AC, Reynolds N, Caplin ME** 2003 Sandostatin LAR (long-acting octreotide acetate) for malignant carcinoid syndrome: a 3-year experience. *Aliment Pharmacol Ther* 17:437–444
442. **Kvols LK, Moertel CG, O'Connell MJ, Schutt AJ, Rubin J, Hahn RG** 1986 Treatment of the malignant carcinoid syndrome. Evaluation of a long-acting somatostatin analogue. *N Engl J Med* 315:663–666
443. **Oberg K** 1993 The use of chemotherapy in the management of neuroendocrine tumors. *Endocrinol Metab Clin North Am* 22:941–952
444. **Anthony LB, Martin W, Delbeke D, Sandler M** 1996 Somatostatin receptor imaging: predictive and prognostic considerations. *Digestion* 57(Suppl 1):50–53
445. **Connolly HM, Schaff HV, Mullany CJ, Rubin J, Abel MD, Pellikka PA** 2001 Surgical management of left-sided carcinoid heart disease. *Circulation* 104:136–140
446. **Connolly HM, Schaff HV, Mullany CJ, Abel MD, Pellikka PA** 2002 Carcinoid heart disease: impact of pulmonary valve replacement in right ventricular function and remodeling. *Circulation* 106:151–156
447. **Vinik AI, Tsai S, Moattari AR, Cheung P** 1988 Somatostatin analogue (SMS 201–995) in patients with gastrinomas. *Surgery* 104:834–842
448. **Angeletti S, Corleto VD, Schillaci O, Marignani M, Annibale B, Moretti A, Silecchia G, Scopinaro F, Basso N, Bordi C, Delle FG** 1998 Use of the somatostatin analogue octreotide to localise and manage somatostatin-producing tumours. *Gut* 42:792–794
449. **Eriksson B, Janson ET, Bax ND, Mignon M, Morant R, Opolon P, Rougier P, Oberg KE** 1996 The use of new somatostatin analogues, lanreotide and octastatin, in neuroendocrine gastro-intestinal tumors. *Digestion* 57(Suppl 1):77–80
450. **Filosso PL, Ruffini E, Oliaro A, Papalia E, Donati G, Rena O** 2002 Long-term survival of atypical bronchial carcinoids with liver metastases, treated with octreotide. *Eur J Cardiothorac Surg* 21:913–917
451. **Wynick D, Anderson JV, Williams SJ, Bloom SR** 1989 Resistance of metastatic pancreatic endocrine tumours after long-term treatment with the somatostatin analogue octreotide (SMS 201–995). *Clin Endocrinol (Oxf)* 30:385–388
452. **Hofland LJ, Lamberts SW** 2003 The pathophysiological consequences of somatostatin receptor internalization and resistance. *Endocr Rev* 24:28–47
453. **Corleto VD, Angeletti S, Schillaci O, Marignani M, Caratozzolo M, Panzuto F, Annibale B, Delle FG** 2000 Long-term octreotide treatment of metastatic carcinoid tumor. *Ann Oncol* 11:491–493
454. **Trendle MC, Moertel CG, Kvols LK** 1997 Incidence and morbidity of cholelithiasis in patients receiving chronic octreotide for metastatic carcinoid and malignant islet cell tumors. *Cancer* 79:830–834
455. **Raderer M, Kurtaran A, Scheithauer W, Fiebiger W, Weinlaender G, Oberhuber G** 2001 Different response to the long-acting somatostatin analogues lanreotide and octreotide in a patient with a malignant carcinoid. *Oncology* 60:141–145
456. **Dogliotti L, Tampellini M, Stivanello M, Gorzegno G, Fabiani L** 2001 The clinical management of neuroendocrine tumors with long-acting repeatable (LAR) octreotide: comparison with standard subcutaneous octreotide therapy. *Ann Oncol* 12(Suppl 2):S105–S109
457. **Lamberts SW, van der Lely AJ, Hofland LJ** 2002 New somatostatin analogs: will they fulfil old promises? *Eur J Endocrinol* 146:701–705
458. **Bruns C, Lewis I, Briner U, Meno-Tetang G, Weckbecker G** 2002 SOM230: a novel somatostatin peptidomimetic with broad somatotropin release inhibiting factor (SRIF) receptor binding and a unique antisecretory profile. *Eur J Endocrinol* 146:707–716
459. **Stroh T, Jackson AC, Sarret P, Dal Farra C, Vincent JP, Kreienkamp HJ, Mazella J, Beaudet A** 2000 Intracellular dynamics of sst5 receptors in transfected COS-7 cells: maintenance of cell surface

- receptors during ligand-induced endocytosis. *Endocrinology* 141:354–365
460. **Weckbecker G, Briner U, Lewis I, Bruns C** 2002 SOM230: a new somatostatin peptidomimetic with potent inhibitory effects on the growth hormone/insulin-like growth factor-I axis in rats, primates, and dogs. *Endocrinology* 143:4123–4130
 461. **Oberg K** 2000 Interferon in the management of neuroendocrine GEP-tumors: a review. *Digestion* 62(Suppl 1):92–97
 462. **Grander D, Sangfelt O, Erickson S** 1997 How does interferon exert its cell growth inhibitory effect? *Eur J Haematol* 59:129–135
 463. **Oberg K, Eriksson B** 1991 The role of interferons in the management of carcinoid tumours. *Br J Haematol* 79(Suppl 1):74–77
 464. **Eriksson B, Oberg K** 1993 An update of the medical treatment of malignant endocrine pancreatic tumors. *Acta Oncol* 32:203–208
 465. **Moertel CG, Rubin J, Kvols LK** 1989 Therapy of metastatic carcinoid tumor and the malignant carcinoid syndrome with recombinant leukocyte A interferon. *J Clin Oncol* 7:865–868
 466. **Hanssen LE, Schrupf E, Kolbenstedt AN, Tausjo J, Dolva LO** 1989 Treatment of malignant metastatic midgut carcinoid tumours with recombinant human α 2b interferon with or without prior hepatic artery embolization. *Scand J Gastroenterol* 24:787–795
 467. **Bartsch HH, Stockmann F, Arnold R** 1990 Treatment of metastatic carcinoid tumors by recombinant human interferon- α . Results from a phase II study. *J Cancer Res Clin Oncol* 116:305 (Abstract)
 468. **Jacobsen MB, Hanssen LE, Kolmannskog F, Schrupf E, Vatn MH, Bergan A** 1995 Interferon- α 2b, with or without prior hepatic artery embolization: clinical response and survival in mid-gut carcinoid patients. The Norwegian carcinoid study. *Scand J Gastroenterol* 30:789–796
 469. **Joensuu H, Kumpulainen E, Grohn P** 1992 Treatment of metastatic carcinoid tumour with recombinant interferon α . *Eur J Cancer* 28A:1650–1653
 470. **Bajetta E, Zilembo N, Di Bartolomeo M, Di Leo A, Pilotti S, Bochicchio AM, Castellani R, Buzzoni R, Celio L, Dogliotti L** 1993 Treatment of metastatic carcinoids and other neuroendocrine tumors with recombinant interferon- α 2a. A study by the Italian Trials in Medical Oncology Group. *Cancer* 72:3099–3105
 471. **Oberg K, Eriksson B, Janson ET** 1994 The clinical use of interferons in the management of neuroendocrine gastroenteropancreatic tumors. *Ann NY Acad Sci* 733:471–478
 472. **Oberg K** 2000 State of the art and future prospects in the management of neuroendocrine tumors. *Q J Nucl Med* 44:3–12
 473. **Frank M, Klose KJ, Wied M, Ishaque N, Schade-Brittinger C, Arnold R** 1999 Combination therapy with octreotide and α -interferon: effect on tumor growth in metastatic endocrine gastroenteropancreatic tumors. *Am J Gastroenterol* 94:1381–1387
 474. **Faiss S, Pape UF, Bohmig M, Dorffel Y, Mansmann U, Golder W, Riecken EO, Wiedenmann B** 2003 Prospective, randomized, multicenter trial on the antiproliferative effect of lanreotide, interferon α , and their combination for therapy of metastatic neuroendocrine gastroenteropancreatic tumors—the International Lanreotide and Interferon Alfa Study Group. *J Clin Oncol* 21:2689–2696
 475. **Hughes MJ, Kerr DJ, Cassidy J, Soukop M, McGregor K, Blackburn N, Yosef H, Kaye SB** 1996 A pilot study of combination therapy with interferon- α 2a and 5-fluorouracil in metastatic carcinoid and malignant endocrine pancreatic tumours. *Ann Oncol* 7:208–210
 476. **Zilembo N, Buzzoni R, Bajetta E, Di Bartolomeo M, de Braud F, Castellani R, Maffioli L, Celio L, Villa E, Lorusso V** 1993 Salvage treatment after r-interferon α 2a in advanced neuroendocrine tumors. *Acta Oncol* 32:245–250
 477. **Schneider HJ, Heddle RM, Downes MO, Wan KM, Smedley HM** 1998 Intralesional interferon for the treatment of metastatic carcinoid tumours. *Clin Oncol (R Coll Radiol)* 10:129–130
 478. **Valimaki M, Jarvinen H, Salmela P, Sane T, Sjoblom SM, Pelkonen R** 1991 Is the treatment of metastatic carcinoid tumor with interferon not as successful as suggested? *Cancer* 67:547–549
 479. **Papamichael D, Seymour MT, Penson RT, Wilson P, Gallagher CJ, Besser GM, Slevin ML** 1998 Double modulation of 5-fluorouracil with interferon α 2a and high-dose leucovorin in advanced neuroendocrine tumours. *Eur J Cancer* 34:2133–2134
 480. **Granberg D, Eriksson B, Wilander E, Grimfjard P, Fjallskog ML, Oberg K, Skogseid B** 2001 Experience in treatment of metastatic pulmonary carcinoid tumors. *Ann Oncol* 12:1383–1391
 481. **Pape UF, Hocker M, Seuss U, Wiedenmann B** 2000 New molecular aspects in the diagnosis and therapy of neuroendocrine tumors of the gastroenteropancreatic system. *Recent Results Cancer Res* 153:45–60
 482. **Ronnbom LE, Alm GV, Oberg KE** 1991 Autoimmunity after α -interferon therapy for malignant carcinoid tumors. *Ann Intern Med* 115:178–183
 483. **Zhou Y, Wang S, Gobl A, Oberg K** 2000 The interferon- α regulation of interferon regulatory factor 1 (IRF-1) and IRF-2 has therapeutic implications in carcinoid tumors. *Ann Oncol* 11:707–714
 484. **Joensuu H, Katka K, Kujari H** 1992 Dramatic response of a metastatic carcinoid tumour to a combination of interferon and octreotide. *Acta Endocrinol (Copenh)* 126:184–185
 485. **Tiensuu Janson EM, Ahlstrom H, Andersson T, Oberg KE** 1992 Octreotide and interferon α : a new combination for the treatment of malignant carcinoid tumours. *Eur J Cancer* 28A:1647–1650.
 486. **Fjallskog ML, Sundin A, Westlin JE, Oberg K, Janson ET, Eriksson B** 2002 Treatment of malignant endocrine pancreatic tumors with a combination of α -interferon and somatostatin analogs. *Med Oncol* 19:35–42
 487. **Kouraklis G, Misiakos E, Glinavou A, Raftopoulos J, Karatzas G** 2002 Management of enterochromaffin-like gastric carcinoid tumor metastasized to the liver. *Scand J Gastroenterol* 37:246–248
 488. **Rougier P, Mitry E** 2000 Chemotherapy in the treatment of neuroendocrine malignant tumors. *Digestion* 62(Suppl 1):73–78
 489. **Eriksson B, Skogseid B, Lundqvist G, Wide L, Wilander E, Oberg K** 1990 Medical treatment and long-term survival in a prospective study of 84 patients with endocrine pancreatic tumors. *Cancer* 65:1883–1890
 490. **Oberg K** 1994 Treatment of neuroendocrine tumors. *Cancer Treat Rev* 20:331–355
 491. **Moertel CG, Lefkopoulo M, Lipsitz S, Hahn RG, Klaassen D** 1992 Streptozocin-doxorubicin, streptozocin-fluorouracil or chlorozotocin in the treatment of advanced islet-cell carcinoma. *N Engl J Med* 326:519–523
 492. **Engstrom PF, Lavin PT, Moertel CG, Folsch E, Douglass Jr HO** 1984 Streptozocin plus fluorouracil versus doxorubicin therapy for metastatic carcinoid tumor. *J Clin Oncol* 2:1255–1259
 493. **Moertel CG, Hanley JA, Johnson LA** 1980 Streptozocin alone compared with streptozocin plus fluorouracil in the treatment of advanced islet-cell carcinoma. *N Engl J Med* 303:1189–1194
 494. **Broder LE, Carter SK** 1973 Pancreatic islet cell carcinoma. II. Results of therapy with streptozotocin in 52 patients. *Ann Intern Med* 79:108–118
 495. **Bukowski RM, Tangen C, Lee R, Macdonald JS, Einstein Jr AB, Peterson R, Fleming TR** 1992 Phase II trial of chlorozotocin and fluorouracil in islet cell carcinoma: a Southwest Oncology Group study. *J Clin Oncol* 10:1914–1918
 496. **Bajetta E, Rimassa L, Carnaghi C, Seregini E, Ferrari L, Di Bartolomeo M, Regalia E, Cassata A, Procopio G, Mariani L** 1998 5-Fluorouracil, dacarbazine, and epirubicin in the treatment of patients with neuroendocrine tumors. *Cancer* 83:372–378
 497. **Rivera E, Ajani JA** 1998 Doxorubicin, streptozocin, and 5-fluorouracil chemotherapy for patients with metastatic islet-cell carcinoma. *Am J Clin Oncol* 21:36–38
 498. **Kaltsas GA, Mukherjee JJ, Isidori A, Kola B, Plowman PN, Monson JP, Grossman AB, Besser GM** 2002 Treatment of advanced neuroendocrine tumours using combination chemotherapy with lomustine and 5-fluorouracil. *Clin Endocrinol (Oxf)* 57:169–183
 499. **Moertel CG, Hanley JA** 1979 Combination chemotherapy trials in metastatic carcinoid tumor and the malignant carcinoid syndrome. *Cancer Clin Trials* 2:327–334
 500. **Oberg K, Norheim I, Lundqvist G, Wide L** 1987 Cytotoxic treatment in patients with malignant carcinoid tumors. Response to streptozocin—alone or in combination with 5-FU. *Acta Oncol* 26:429–432
 501. **Bukowski RM, Johnson KG, Peterson RF, Stephens RL, Rivkin SE, Neilan B, Costanzi JH** 1987 A phase II trial of combination chemotherapy in patients with metastatic carcinoid tumors. A Southwest Oncology Group Study. *Cancer* 60:2891–2895
 502. **Rougier P, Oliveira J, Ducreux M, Theodore C, Kac J, Droz JP** 1991 Metastatic carcinoid and islet cell tumours of the pancreas: a phase

- II trial of the efficacy of combination chemotherapy with 5-fluorouracil, doxorubicin and cisplatin. *Eur J Cancer* 27:1380–1382
503. **Harris PE, Bouloux PM, Wass JA, Besser GM** 1990 Successful treatment by chemotherapy for acromegaly associated with ectopic growth hormone releasing hormone secretion from a carcinoid tumour. *Clin Endocrinol (Oxf)* 32:315–321
 504. **Hatton MQ, Reed NS** 1997 Chemotherapy for neuroendocrine tumors: the Beatson Oncology Centre experience. *Clin Oncol (R Coll Radiol)* 9:385–389
 505. **Fjallskog ML, Granberg DP, Welin SL, Eriksson C, Oberg KE, Jansson ET, Eriksson BK** 2001 Treatment with cisplatin and etoposide in patients with neuroendocrine tumors. *Cancer* 92:1101–1107
 506. **Veenhof CH** 1999 Pancreatic endocrine tumours, immunotherapy and gene therapy: chemotherapy and interferon therapy of endocrine tumours. *Ann Oncol* 10(Suppl 4):185–187
 507. **Moertel CG, Kvols LK, O'Connell MJ, Rubin J** 1991 Treatment of neuroendocrine carcinomas with combined etoposide and cisplatin. Evidence of major therapeutic activity in the anaplastic variants of these neoplasms. *Cancer* 68:227–232
 508. **Johnson LA, Lavin P, Moertel CG, Weiland L, Dayal Y, Doos WG, Geller SA, Cooper HS, Nime F, Masse S, Simson IW, Sumner H, Folsch E, Engstrom P** 1983 Carcinoids: the association of histologic growth pattern and survival. *Cancer* 51:882–889
 509. **Mitry E, Baudin E, Ducreux M, Sabourin JC, Rufie P, Aparicio T, Aparicio T, Lasser P, Elias D, Duvillard P, Schlumberger M, Rougier P** 1999 Treatment of poorly differentiated neuroendocrine tumours with etoposide and cisplatin. *Br J Cancer* 81:1351–1355
 510. **Ansell SM, Pitot HC, Burch PA, Kvols LK, Mahoney MR, Rubin J** 2001 A phase II study of high-dose paclitaxel in patients with advanced neuroendocrine tumors. *Cancer* 91:1543–1548
 511. **Walther DJ, Peter JU, Bader M** 2002 7-Hydroxytryptophan, a novel, specific, cytotoxic agent for carcinoids and other serotonin-producing tumors. *Cancer* 94:3135–3140
 512. **Nagy A, Schally AV, Halmos G, Armatas P, Cai RZ, Csernus V, Kovacs M, Koppán M, Szepeshazi K, Kahan Z** 1998 Synthesis and biological evaluation of cytotoxic analogs of somatostatin containing doxorubicin or its intensely potent derivative, 2-pyrrolinodoxorubicin. *Proc Natl Acad Sci USA* 95:1794–1799
 513. **Schally AV, Nagy A** 1999 Cancer chemotherapy based on targeting of cytotoxic peptide conjugates to their receptors on tumors. *Eur J Endocrinol* 141:1–14
 514. **Hopfner M, Sutter AP, Gerst B, Zeitz M, Scherubl H** 2003 A novel approach in the treatment of neuroendocrine gastrointestinal tumors. Targeting the epidermal growth factor receptor by gefitinib (ZD1839). *Br J Cancer* 89:1766–1775
 515. **Ruszniewski P, Malka D** 2000 Hepatic arterial chemoembolization in the management of advanced digestive endocrine tumors. *Digestion* 62(Suppl 1):79–83
 516. **Chen H, Hardacre JM, Uzar A, Cameron JL, Choti MA** 1998 Isolated liver metastases from neuroendocrine tumors: does resection prolong survival? *J Am Coll Surg* 187:88–92
 517. **Chamberlain RS, Canes D, Brown KT, Saltz L, Jarnagin W, Fong Y, Blumgart LH** 2000 Hepatic neuroendocrine metastases: does intervention alter outcomes? *J Am Coll Surg* 190:432–445
 518. **Skinazi F, Zins M, Menu Y, Bernades P, Ruszniewski P** 1996 Liver metastases of digestive endocrine tumours: natural history and response to medical treatment. *Eur J Gastroenterol Hepatol* 8:673–678
 519. **Siperstein AE, Rogers SJ, Hansen PD, Gitomirsky A** 1997 Laparoscopic thermal ablation of hepatic neuroendocrine tumor metastases. *Surgery* 122:1147–1154
 520. **Hellman P, Ladjevardi S, Skogseid B, Akerstrom G, Elvin A** 2002 Radiofrequency tissue ablation using cooled tip for liver metastases of endocrine tumors. *World J Surg* 26:1052–1056
 521. **Que FG, Nagorney DM, Batts KP, Linz LJ, Kvols LK** 1995 Hepatic resection for metastatic neuroendocrine carcinomas. *Am J Surg* 169:36–42
 522. **Dale PS, Souza JW, Brewer DA** 1998 Cryosurgical ablation of unresectable hepatic metastases. *J Surg Oncol* 68:242–245
 523. **Andrews JC, Walker SC, Ackermann RJ, Cotton LA, Ensminger WD, Shapiro B** 1994 Hepatic radioembolization with yttrium-90 containing glass microspheres: preliminary results and clinical follow-up. *J Nucl Med* 35:1637–1644
 524. **Ajani JA, Carrasco CH, Wallace S** 1994 Neuroendocrine tumors metastatic to the liver. Vascular occlusion therapy. *Ann NY Acad Sci* 733:479–487
 525. **Moertel CG, Johnson CM, McKusick MA, Martin Jr JK, Nagorney DM, Kvols LK, Rubin J, Kunselman S** 1994 The management of patients with advanced carcinoid tumors and islet cell carcinomas. *Ann Intern Med* 120:302–309
 526. **Taourel P, Dazat M, Lafortune M, Pradel J, Rossi M, Bruel JM** 1994 Hemodynamic changes after transcatheter arterial embolization of hepatocellular carcinomas. *Radiology* 191:189–192
 527. **Hajarizadeh H, Ivancev K, Mueller CR, Fletcher WS, Woltering EA** 1992 Effective palliative treatment of metastatic carcinoid tumors with intra-arterial chemotherapy/chemoembolization combined with octreotide acetate. *Am J Surg* 163:479–483
 528. **Therasse E, Breitmayer F, Roche A, De Baere T, Indushekar S, Ducreux M, Lasser P, Elias D, Rougier P** 1993 Transcatheter chemoembolization of progressive carcinoid liver metastasis. *Radiology* 189:541–547
 529. **Diaco DS, Hajarizadeh H, Mueller CR, Fletcher WS, Pommier RF, Woltering EA** 1995 Treatment of metastatic carcinoid tumors using multimodality therapy of octreotide acetate, intra-arterial chemotherapy, and hepatic arterial chemoembolization. *Am J Surg* 169:523–528
 530. **Mavligit GM, Pollock RE, Evans HL, Wallace S** 1993 Durable hepatic tumor regression after arterial chemoembolization-infusion in patients with islet cell carcinoma of the pancreas metastatic to the liver. *Cancer* 72:375–380
 531. **Clouse ME, Perry L, Stuart K, Stokes KR** 1994 Hepatic arterial chemoembolization for metastatic neuroendocrine tumors. *Digestion* 55(Suppl 3):92–97
 532. **Perry LJ, Stuart K, Stokes KR, Clouse ME** 1994 Hepatic arterial chemoembolization for metastatic neuroendocrine tumors. *Surgery* 116:1111–1116
 533. **Drougas JG, Anthony LB, Blair TK, Lopez RR, Wright Jr JK, Chapman WC, Webb L, Mazer M, Meranze S, Pinson CW** 1998 Hepatic artery chemoembolization for management of patients with advanced metastatic carcinoid tumors. *Am J Surg* 175:408–412
 534. **Kress O, Wagner HJ, Wied M, Klose KJ, Arnold R, Alfke H** 2003 Transarterial chemoembolization of advanced liver metastases of neuroendocrine tumors: a retrospective single-center analysis. *Digestion* 68:94–101
 535. **Tennvall J, Ljungberg O, Ahren B, Gustavsson A, Nillson LO** 1992 Radiotherapy for unresectable endocrine pancreatic carcinomas. *Eur J Surg Oncol* 18:73–76
 536. **Juhlin C, Papanicolaou V, Arnborg H, Klareskog L, Lorelius LE, Rastad J, Oberg K, Akerstrom G** 1994 Clinical and biochemical effects in vivo of monoclonal antitumor antibody in Verner-Morrison's syndrome. *Cancer* 73:1346–1352
 537. **Castellani MR, Chiti A, Seregini E, Bombardieri E** 2000 Role of 131I-metaiodobenzylguanidine (MIBG) in the treatment of neuroendocrine tumours. Experience of the National Cancer Institute of Milan. *Q J Nucl Med* 44:77–87
 538. **Buhl T, Mortensen J, Kjaer A** 2002 I-123 MIBG imaging and intraoperative localization of metastatic pheochromocytoma: a case report. *Clin Nucl Med* 27:183–185
 539. **Shapiro B, Sisson JC, Wieland DM, Mangner TJ, Zempel SM, Mudgett E, Gross MD, Carey JE, Zasadny KR, Beierwaltes WH** 1991 Radiopharmaceutical therapy of malignant pheochromocytoma with [131I]metaiodobenzylguanidine: results from ten years of experience. *J Nucl Biol Med* 35:269–276
 540. **Bomanji J, Britton KE, Ur E, Hawkins L, Grossman AB, Besser GM** 1993 Treatment of malignant pheochromocytoma, paraganglioma and carcinoid tumours with 131I-metaiodobenzylguanidine. *Nucl Med Commun* 14:856–861
 541. **Taal BG, Hoefnagel CA, Valdes Olmos RA, Boot H, Beijnen JH** 1996 Palliative effect of metaiodobenzylguanidine in metastatic carcinoid tumors. *J Clin Oncol* 14:1829–1838
 542. **Waldherr C, Pless M, Maecke HR, Haldemann A, Mueller-Brand J** 2001 The clinical value of [90Y-DOTA]-D-Phe1-Tyr3-octreotide (90Y-DOTATOC) in the treatment of neuroendocrine tumours: a clinical phase II study. *Ann Oncol* 12:941–945
 543. **Otte A, Herrmann R, Macke HR, Muller-Brand J** 1999 [Yttrium 90 DOTATOC: a new somatostatin analog for cancer therapy of neuroendocrine tumors]. *Schweiz Rundsch Med Prax* 88:1263–1268
 544. **van der Harst E, de Herder WW, Bruining HA, Bonjer HJ, de**

- Krijger RR, Lamberts SW, van de Meiracker AH, Boomsma F, Stijnen T, Krenning EP, Bosman FT, Kwekkeboom DJ 2001 [(123)I]metaiodobenzylguanidine and [(111)In]octreotide uptake in benign and malignant pheochromocytomas. *J Clin Endocrinol Metab* 86:685–693
545. **Sisson JC, Shapiro B, Hutchinson RJ, Carey JE, Zasadny KR, Zempel SA, Normolle DP** 1994 Predictors of toxicity in treating patients with neuroblastoma by radiolabeled metaiodobenzylguanidine. *Eur J Nucl Med* 21:46–52
546. **Lewington VJ, Zivanovic MA, Tristram M, McEwan AJ, Ackery DM** 1991 Radiolabelled metaiodobenzylguanidine targeted radiotherapy for malignant pheochromocytoma. *J Nucl Biol Med* 35:280–283
547. **Bongers V, de Klerk JM, Zonnenberg BA, de Kort G, Lips CJ, van Rijk PP** 1997 Acute liver necrosis induced by iodine-131-MIBG in the treatment of metastatic carcinoid tumors. *J Nucl Med* 38:1024–1026
548. **Bomanji JB, Wong W, Gaze MN, Cassoni A, Waddington W, Solano J, Ell PJ** 2003 Treatment of neuroendocrine tumours in adults with 131I-MIBG therapy. *Clin Oncol (R Coll Radiol)* 15:193–198
549. **Fjalling M, Andersson P, Forssell-Aronsson E, Gretarsdottir J, Johansson V, Tisell LE, Wangberg B, Nilsson O, Berg G, Michanek A, Lindstedt G, Ahlman H** 1996 Systemic radionuclide therapy using indium-111-DTPA-D-Phe1-octreotide in midgut carcinoid syndrome. *J Nucl Med* 37:1519–1521
550. **Anthony LB, Woltering EA, Espenan GD, Cronin MD, Maloney TJ, McCarthy KE** 2002 Indium-111-pentetreotide prolongs survival in gastroenteropancreatic malignancies. *Semin Nucl Med* 32:123–132
551. **Breeman WA, de Jong M, Kwekkeboom DJ, Valkema R, Bakker WH, Kooij PP, Visser TJ, Krenning EP** 2001 Somatostatin receptor-mediated imaging and therapy: basic science, current knowledge, limitations and future perspectives. *Eur J Nucl Med* 28:1421–1429
552. **Buscombe JR, Caplin ME, Hilson AJ** 2003 Long-term efficacy of high-activity 111In-pentetreotide therapy in patients with disseminated neuroendocrine tumors. *J Nucl Med* 44:1–6
553. **de Jong M, Valkema R, Jamar F, Kvols LK, Kwekkeboom DJ, Breeman WA, Bakker WH, Smith C, Pauwels S, Krenning EP** 2002 Somatostatin receptor-targeted radionuclide therapy of tumors: preclinical and clinical findings. *Semin Nucl Med* 32:133–140
554. **Smith MC, Liu J, Chen T, Schran H, Yeh CM, Jamar F, Valkema R, Bakker W, Kvols L, Krenning E, Pauwels S** 2000 OctreoTher: ongoing early clinical development of a somatostatin-receptor-targeted radionuclide antineoplastic therapy. *Digestion* 62(Suppl 1):69–72
555. **de Jong M, Bakker WH, Krenning EP, Breeman WA, van der Pluijm ME, Bernard BF, Visser TJ, Jermann E, Behe M, Powell P, Macke HR** 1997 Yttrium-90 and indium-111 labelling, receptor binding and biodistribution of [DOTA0,d-Phe1,Tyr3]octreotide, a promising somatostatin analogue for radionuclide therapy. *Eur J Nucl Med* 24:368–371
556. **Paganelli G, Zoboli S, Cremonesi M, Bodei L, Ferrari M, Grana C, Bartolomei M, Orsi F, De Cicco C, Macke HR, Chinol M, de Braud F** 2001 Receptor-mediated radiotherapy with 90Y-DOTA-D-Phe1-Tyr3-octreotide. *Eur J Nucl Med* 28:426–434
557. **Otte A, Herrmann R, Heppeler A, Behe M, Jermann E, Powell P, Maecke HR, Muller J** 1999 Yttrium-90 DOTATOC: first clinical results. *Eur J Nucl Med* 26:1439–1447
558. **Virgolini I, Britton K, Buscombe J, Moncayo R, Paganelli G, Riva P** 2002 In- and Y-DOTA-Ianreotide: results and implications of the MAURITIUS trial. *Semin Nucl Med* 32:148–155
559. **Leimer M, Kurtaran A, Smith-Jones P, Raderer M, Havlik E, Angelberger P, Vorbeck F, Niederle B, Herold C, Virgolini I** 1998 Response to treatment with yttrium 90-DOTA-Ianreotide of a patient with metastatic gastrinoma. *J Nucl Med* 39:2090–2094
560. **Kwekkeboom DJ, Bakker WH, Kooij PP, Konijnenberg MW, Srinivasan A, Erion JL, Schmidt MA, Bugaj JL, de Jong M, Krenning EP** 2001 [177Lu-DOTAOTyr3]octreotate: comparison with [111In-DTPA]octreotide in patients. *Eur J Nucl Med* 28:1319–1325
561. **de Jong M, Krenning E** 2002 New advances in peptide receptor radionuclide therapy. *J Nucl Med* 43:617–620
562. **van Hagen PM, Breeman WA, Bernard HF, Schaar M, Mooij CM, Srinivasan A, Schmidt MA, Krenning EP, de Jong M** 2000 Evaluation of a radiolabelled cyclic DTPA-RGD analogue for tumour imaging and radionuclide therapy. *Int J Cancer* 90:186–198
563. **Jenkins SA, Kynaston HG, Davies ND, Baxter JN, Nott DM** 2001 Somatostatin analogs in oncology: a look to the future. *Chemotherapy* 47(Suppl 2):162–196
564. **Nicholson Jr JP, Vaughn Jr ED, Pickering TG, Resnick LM, Artusio J, Kleinert HD, Lopez-Overjero JA, Laragh JH** 1983 Pheochromocytoma and prazosin. *Ann Intern Med* 99:477–479
565. **Proye C, Thevenin D, Cecat P, Petitlot P, Carnaille B, Verin P, Sautier M, Racadot N** 1989 Exclusive use of calcium channel blockers in preoperative and intraoperative control of pheochromocytomas: hemodynamics and free catecholamine assays in ten consecutive patients. *Surgery* 106:1149–1154
566. **Jones NF, Walker G, Ruthven CR, Sandler M** 1968 α -methyl-tyrosine in the management of pheochromocytoma. *Lancet* 2:1105–1109
567. **Serri O, Comtois R, Bettez P, Dubuc G, Buu NT, Kuchel O** 1984 Reduction in the size of a pheochromocytoma pulmonary metastasis by metyrosine therapy. *N Engl J Med* 310:1264–1265
568. **Arai A, Naruse M, Naruse K, Tanabe A, Yoshimoto T, Iwama T, Kusakabe K, Obara T, Demura R, Demura H** 1998 Cardiac malignant pheochromocytoma with bone metastases. *Intern Med* 37:940–944
569. **Tada K, Okuda Y, Yamashita K** 1998 Three cases of malignant pheochromocytoma treated with cyclophosphamide, vincristine, and dacarbazine combination chemotherapy and α -methyl-p-tyrosine to control hypercatecholaminemia. *Horm Res* 49:295–297
570. **Kopf D, Bockisch A, Steinert H, Hahn K, Beyer J, Neumann HP, Hensen J, Lehnert H** 1997 Octreotide scintigraphy and catecholamine response to an octreotide challenge in malignant pheochromocytoma. *Clin Endocrinol (Oxf)* 46:39–44
571. **Plouin PF, Bertherat J, Chatellier G, Billaud E, Azizi M, Grouzmann E, Epelbaum J** 1995 Short-term effects of octreotide on blood pressure and plasma catecholamines and neuropeptide Y levels in patients with pheochromocytoma: a placebo-controlled trial. *Clin Endocrinol (Oxf)* 42:289–294
572. **Invitti C, De Martin I, Bolla GB, Pecori GF, Maestri E, Leonetti G, Cavagnini F** 1993 Effect of octreotide on catecholamine plasma levels in patients with chromaffin cell tumors. *Horm Res* 40:156–160
573. **Lamarre-Cliche M, Gimenez-Roqueplo AP, Billaud E, Baudin E, Luton JP, Plouin PF** 2002 Effects of slow-release octreotide on urinary metanephrine excretion and plasma chromogranin A and catecholamine levels in patients with malignant or recurrent pheochromocytoma. *Clin Endocrinol (Oxf)* 57:629–634
574. **Koriyama N, Kakei M, Yaekura K, Okui H, Yamashita T, Nishimura H, Matsushita S, Tei C** 2000 Control of catecholamine release and blood pressure with octreotide in a patient with pheochromocytoma: a case report with in vitro studies. *Horm Res* 53:46–50
575. **Schuppert F, Scheumann GF, Schober C, Overbeck J, Schurmeyer TH, Schmoll HJ, Dralle H, von zur Muhlen A** 1991 [Therapy of a malignant sympathetic paraganglioma of the organ of Zuckerkandl—a case report]. *Klin Wochenschr* 69:937–942
576. **Mornex R, Badet C, Peyrin L** 1992 Malignant pheochromocytoma: a series of 14 cases observed between 1966 and 1990. *J Endocrinol Invest* 15:643–649
577. **Takahashi K, Ashizawa N, Minami T, Suzuki S, Sakamoto I, Hayashi K, Tomiyasu S, Sumikawa K, Kitamura K, Eto T, Yano K** 1999 Malignant pheochromocytoma with multiple hepatic metastases treated by chemotherapy and transcatheter arterial embolization. *Intern Med* 38:349–354
578. **Iwabuchi M, Oki Y, Nakamura H** 1999 Palliative chemotherapy for malignant pheochromocytoma: symptomatic palliation of two cases. *Intern Med* 38:433–435
579. **Keiser HR, Goldstein DS, Wade JL, Douglas FL, Averbuch SD** 1985 Treatment of malignant pheochromocytoma with combination chemotherapy. *Hypertension* 7:118–124
580. **Siddiqui MZ, Von Eyben FE, Spanos G** 1988 High-voltage irradiation and combination chemotherapy for malignant pheochromocytoma. *Cancer* 62:686–690
581. **Proye C, Vix M, Goropoulos A, Kerlo P, Lecomte-Houcke M** 1992 High incidence of malignant pheochromocytoma in a surgical unit. 26 cases out of 100 patients operated from 1971 to 1991. *J Endocrinol Invest* 15:651–663
582. **Senan S, Reed N, Connell J** 1992 Palliation of malignant pheochromocytoma with combination chemotherapy. *Eur J Cancer* 28A:1006–1007
583. **Sasaki M, Iwaoka T, Yamauchi J, Tokunaga H, Naomi S, Inoue**

- J, Oishi S, Umeda T, Sato T 1994 A case of Sipple's syndrome with malignant pheochromocytoma treated with ¹³¹I-metaiodobenzylguanidine and a combined chemotherapy with cyclophosphamide, vincristine and dacarbazine. *Endocr J* 41:155–160
584. Wu LT, Dicipinigaitis P, Bruckner H, Manger W, Averbuch S 1994 Hypertensive crises induced by treatment of malignant pheochromocytoma with a combination of cyclophosphamide, vincristine, and dacarbazine. *Med Pediatr Oncol* 22:389–392
585. Noshiro T, Honma H, Shimizu K, Kusakari T, Watanabe T, Akama H, Shibukawa S, Miura W, Abe K, Miura Y 1996 Two cases of malignant pheochromocytoma treated with cyclophosphamide, vincristine and dacarbazine in a combined chemotherapy. *Endocr J* 43:279–284
586. Ein SH, Weitzman S, Thorner P, Seagram CG, Filler RM 1994 Pediatric malignant pheochromocytoma. *J Pediatr Surg* 29:1197–1201
587. Scott Jr HW, Reynolds V, Green N, Page D, Oates JA, Robertson D, Roberts S 1982 Clinical experience with malignant pheochromocytomas. *Surg Gynecol Obstet* 154:801–818
588. Ball AB, Tait DM, Fisher C, Sinnott HD, Harmer CL 1991 Treatment of metastatic para-aortic paraganglioma by surgery, radiotherapy and I-¹³¹ MIBG. *Eur J Surg Oncol* 17:543–546
589. Naguib M, Caceres M, Thomas Jr CR, Herman TS, Eng TY 2002 Radiation treatment of recurrent pheochromocytoma of the bladder: case report and review of literature. *Am J Clin Oncol* 25:42–44
590. Troncone L, Rufini V, Maussier ML, Valenza V, Daidone MS, Luzzi S, De Santis M 1991 The role of [¹³¹I]metaiodobenzylguanidine in the treatment of medullary thyroid carcinoma: results in five cases. *J Nucl Biol Med* 35:327–331
591. Lumbroso J, Schlumberger M, Tenenbaum F, Aubert B, Travagli JP, Parmentier C 1991 [¹³¹I]metaiodobenzylguanidine therapy in 20 patients with malignant pheochromocytoma. *J Nucl Biol Med* 35:288–291
592. Fischer M 1991 Therapy of pheochromocytoma with [¹³¹I]metaiodobenzylguanidine. *J Nucl Biol Med* 35:292–294
593. Bestagno M, Pizzocaro C, Maira G, Terzi A, Panarotto MB, Guerra P 1991 Results of [¹³¹I]metaiodobenzylguanidine treatment in metastatic malignant pheochromocytoma. *J Nucl Biol Med* 35:277–279
594. Colombo L, Lomuscio G, Vignati A, Dottorini ME 1991 Preliminary results of [¹³¹I]metaiodobenzylguanidine treatment in metastatic malignant pheochromocytoma. *J Nucl Biol Med* 35:300–304
595. Nakabeppu Y, Nakajo M 1994 Radionuclide therapy of malignant pheochromocytoma with ¹³¹I-MIBG. *Ann Nucl Med* 8:259–268
596. Sakahara H, Endo K, Saga T, Hosono M, Kobayashi H, Konishi J 1994 ¹³¹I-metaiodobenzylguanidine therapy for malignant pheochromocytoma. *Ann Nucl Med* 8:133–137
597. Kaltsas G, Mukherjee JJ, Foley R, Britton K, Grossman A 2003 Treatment of metastatic pheochromocytoma and paraganglioma with ¹³¹I-meta-iodobenzylguanidine (MIBG). *The Endocrinologist* 13:1–13
598. Valkema R, De Jong M, Bakker WH, Breeman WA, Kooij PP, Lugtenburg PJ, De Jong FH, Christiansen A, Kam BL, De Herder WW, Stridsberg M, Lindemans J, Ensing G, Krenning EP 2002 Phase I study of peptide receptor radionuclide therapy with [In-DTPA]octreotide: the Rotterdam experience. *Semin Nucl Med* 32:110–122
599. Tanaka S, Ito T, Tomoda J, Higashi T, Yamada G, Tsuji T 1993 Malignant pheochromocytoma with hepatic metastasis diagnosed 20 years after resection of the primary adrenal lesion. *Intern Med* 32:789–794
600. Pacak K, Fojo T, Goldstein DS, Eisenhofer G, Walther MM, Linehan WM, Bachenheimer L, Abraham J, Wood BJ 2001 Radiofrequency ablation: a novel approach for treatment of metastatic pheochromocytoma. *J Natl Cancer Inst* 93:648–649
601. Sisson JC, Shapiro B, Shulkin BL, Urba S, Zempel S, Spaulding S 1999 Treatment of malignant pheochromocytomas with ¹³¹I metaiodobenzylguanidine and chemotherapy. *Am J Clin Oncol* 22:364–370
602. Hartley A, Spooner D, Brunt AM 2001 Management of malignant pheochromocytoma: a retrospective review of the use of MIBG and chemotherapy in the West Midlands. *Clin Oncol (R Coll Radiol)* 13:361–366
603. Zuetenhorst H, Taal BG, Boot H, Valdes OR, Hoefnagel C 1999 Long-term palliation in metastatic carcinoid tumours with various applications of meta-iodobenzylguanidin (MIBG): pharmacological MIBG, ¹³¹I-labelled MIBG and the combination. *Eur J Gastroenterol Hepatol* 11:1157–1164
604. Steinfeld AD 1977 The role of radiation therapy in medullary carcinoma of the thyroid. *Radiology* 123:745–746
605. Schlumberger M, Abdelmoumene N, Delisle MJ, Couette JE 1995 Treatment of advanced medullary thyroid cancer with an alternating combination of 5 FU-streptozocin and 5 FU-dacarbazine. The Groupe d'Etude des Tumeurs a Calcitonine (GETC). *Br J Cancer* 71:363–365
606. Saad MF, Guido JJ, Samaan NA 1983 Radioactive iodine in the treatment of medullary carcinoma of the thyroid. *J Clin Endocrinol Metab* 57:124–128
607. Hoefnagel CA, Delprat CC, Valdes Olmos RA 1991 Role of [¹³¹I]metaiodobenzylguanidine therapy in medullary thyroid carcinoma. *J Nucl Biol Med* 35:334–336
608. Mahler C, Verhelst J, de Longueville M, Harris A 1990 Long-term treatment of metastatic medullary thyroid carcinoma with the somatostatin analogue octreotide. *Clin Endocrinol (Oxf)* 33:261–269
609. Modigliani E, Cohen R, Joannidis S, Siame-Mourrot C, Guliana JM, Charpentier G, Cassuto D, Bentata PM, Tabarin A, Roger P 1992 Results of long-term continuous subcutaneous octreotide administration in 14 patients with medullary thyroid carcinoma. *Clin Endocrinol (Oxf)* 36:183–186
610. Vitale G, Tagliaferri P, Caraglia M, Rampone E, Ciccarelli A, Bianco AR, Abbruzzese A, Lupoli G 2000 Slow release lanreotide in combination with interferon- α 2b in the treatment of symptomatic advanced medullary thyroid carcinoma. *J Clin Endocrinol Metab* 85:983–988
611. Lupoli G, Cascone E, Arlotta F, Vitale G, Celentano L, Salvatore M, Lombardi G 1996 Treatment of advanced medullary thyroid carcinoma with a combination of recombinant interferon α -2b and octreotide. *Cancer* 78:1114–1118
612. Petursson SR 1988 Metastatic medullary thyroid carcinoma. Complete response to combination chemotherapy with dacarbazine and 5-fluorouracil. *Cancer* 62:1899–1903
613. Heshmati HM, Gharib H, van Heerden JA, Sizemore GW 1997 Advances and controversies in the diagnosis and management of medullary thyroid carcinoma. *Am J Med* 103:60–69
614. Kraeber-Bodere F, Bardet S, Hoefnagel CA, Vieira MR, Vuillez JP, Murat A, Ferreira TC, Bardies M, Ferrer L, Resche I, Gautherot E, Rouvier E, Barbet J, Chatal JF 1999 Radioimmunotherapy in medullary thyroid cancer using bispecific antibody and iodine ¹³¹-labeled bivalent hapten: preliminary results of a phase I/II clinical trial. *Clin Cancer Res* 5:3190s–3198s
615. Juweid ME, Hajjar G, Swayne LC, Sharkey RM, Suleiman S, Herskovic T, Pereira M, Rubin AD, Goldenberg DM 1999 Phase I/II trial of (¹³¹I)-MN-14F(ab)₂ anti-carcinoembryonic antigen monoclonal antibody in the treatment of patients with metastatic medullary thyroid carcinoma. *Cancer* 85:1828–1842
616. Schott M, Seissler J, Lettmann M, Fouxon V, Scherbaum WA, Feldkamp J 2001 Immunotherapy for medullary thyroid carcinoma by dendritic cell vaccination. *J Clin Endocrinol Metab* 86:4965–4969
617. Bachleitner-Hofmann T, Stift A, Friedl J, Pfragner R, Radelbauer K, Dubsky P, Schuller G, Benko T, Niederle B, Brostjan C, Jakesz R, Gnant M 2002 Stimulation of autologous antitumor T-cell responses against medullary thyroid carcinoma using tumor lysate-pulsed dendritic cells. *J Clin Endocrinol Metab* 87:1098–1104
618. Clayman GL, el Baradie TS 2003 Medullary thyroid cancer. *Otolaryngol Clin North Am* 36:91–105
619. Moley JF 2003 Medullary thyroid carcinoma. *Curr Treat Options Oncol* 4:339–347
620. Carlomagno F, Vitagliano D, Guida T, Ciardiello F, Tortora G, Vecchio G, Ryan AJ, Fontanini G, Fusco A, Santoro M 2002 ZD6474, an orally available inhibitor of KDR tyrosine kinase activity, efficiently blocks oncogenic RET kinases. *Cancer Res* 62:7284–7290