

Retraction

Retracted: The Effect of Synthetic Osteoconductive Bone Graft Material for Augmentation of Internally Fixed Unstable Trochanteric Fractures

BioMed Research International

Received 7 August 2020; Accepted 12 August 2020; Published 30 August 2020

Copyright © 2020 BioMed Research International. This is an open access article distributed under the Creative Commons Attribution License, which permits unrestricted use, distribution, and reproduction in any medium, provided the original work is properly cited.

BioMed Research International has retracted the article titled “The Effect of Synthetic Osteoconductive Bone Graft Material for Augmentation of Internally Fixed Unstable Trochanteric Fractures” [1] due to concerns with the study design raised by the authors. The authors explained that the study was not a randomized trial as described in the article, but a retrospective observational study in which patient assignment to the CaP and control groups was not randomized.

References

- [1] J. Park, J. M. Shin, D. K. Lee, S.-S. Lee, S. H. Paik, and B. H. Lee, “The Effect of Synthetic Osteoconductive Bone Graft Material for Augmentation of Internally Fixed Unstable Trochanteric Fractures,” *BioMed Research International*, vol. 2019, Article ID 5879089, 8 pages, 2019.

Clinical Study

The Effect of Synthetic Osteoconductive Bone Graft Material for Augmentation of Internally Fixed Unstable Trochanteric Fractures

Jin Park,¹ Jung Min Shin,² Do Kyung Lee,³ Sung-Sahn Lee,⁴ Seung Ha Paik,⁵ and Byung Hoon Lee ⁶

¹Hip Service, Department of Orthopedic Surgery, Kangdong Sacred Heart Hospital, Hallym University College of Medicine, 150 Sung-an-ro, Kangdonggu, Seoul 05355, Republic of Korea

²Rheumatology, Department of Internal Medicine, Hanyang Medical Center, Hanyang University College of Medicine, Seoul, Republic of Korea

³Department of Orthopedic Surgery, Konyang University Hospital, Konyang University School of Medicine, Daejeon, Republic of Korea

⁴Department of Orthopedic Surgery, Inje University Ilsan Paik Hospital, 170 Juhwa-ro, Ilsanseo-gu, Goyang 10380, Republic of Korea

⁵Department of Orthopedic Surgery, Kang-Dong Sacred Heart Hospital, Hallym University Medical School, Seoul, Republic of Korea

⁶Department of Orthopedic Surgery, Gachon University, Gil Medical Center, Incheon, Republic of Korea

Correspondence should be addressed to Byung Hoon Lee; oselite@naver.com

Jin Park and Jung Min Shin contributed equally to this work.

Received 2 October 2018; Accepted 16 January 2019; Published 19 March 2019

Academic Editor: Vance W Berger

Copyright © 2019 Jin Park et al. This is an open access article distributed under the Creative Commons Attribution License, which permits unrestricted use, distribution, and reproduction in any medium, provided the original work is properly cited.

This study aimed to evaluate whether the augmentation of CaP into the femoral head around the lag screw results in superior clinical and radiological outcomes of treatment of unstable trochanteric fractures using an intramedullary (IM) implant. Fifty-six consecutive patients with unstable trochanteric fractures who had been surgically treated with IM devices between 2014 and 2016 were prospectively reviewed and randomly divided into two groups based on the use of CaP degradable cements: 28 patients were assigned to the CaP group, while the other 28 patients were assigned to the control group (no use of CaP). Clinical evaluations and radiological analyses were conducted during a minimum of 2-year follow-up. No significant differences in the mean visual analogue scale for the hip pain scores and modified Harris Hip Scores were found between the CaP group and the controls at postoperative 2 months and 2 years. However, earlier walker ambulation was possible in the CaP group (10 ± 9 days) compared to the control group (13 ± 12 days) ($P = 0.02$). In radiological analysis, the CaP group showed significantly lower difference between tip-apex distance measured immediately after surgery and that measured at one-year follow-up compared to the control group ($P = 0.012$). No screw cut-out occurred in the CaP group, while one patient in the control group was reoperated for screw cut-out. The CaP augmentation into the femoral head around lag screw can reduce lag screw penetration, prevent screw cut-out beyond the femoral head, and facilitate early ambulation in elderly patients with unstable trochanteric fractures.

1. Introduction

Osteoporotic trochanteric fractures (TFs) are the second leading cause of elderly patients hospitalization [1]. Stable two-part TFs usually heal well, irrespective of the fixation device, while unstable TFs, defined as fractures with three fragments or more, are more often associated with complications, such as screw cut-out or excessive sliding [2].

The complication rate of conventional sliding hip screws for unstable fractures with osteoporosis can be increased in patients with osteoporosis and unstable fractures [2]. Screw cut-out is the most common complication.

Management of patients with unstable TFs is a continuing challenge, in part because of the frequently encountered osteoporosis in these individuals, which may make stable fixation with conventional metal implants difficult to achieve.

In elderly patients, who may not be able to take weight through their upper limbs, successful rehabilitation often depends upon immediate weight bearing being allowed after surgery.

Augmentation of calcium phosphate (CaP) degradable cements has been suggested for treatment of TFs by using sliding screw devices [3, 4]. CaP hardens in situ and was found to be replaced by host bone over time; moreover, it can provide structural support to bone union by adding a compressive strength, which is higher than that of cancellous bone. Therefore, CaP augmentation for providing better structural support to comminuted fracture site was suggested to prevent the femoral neck shortening [5]. To our best knowledge, only two studies evaluated CaP augmentation using degradable cements in unstable TFs [6, 7].

Intramedullary implants showed better functional recovery and biomechanical stability compared to sliding screw devices and thus have been suggested for treatment of unstable fractures [8]. However, the use of intramedullary nails has been linked to another concern of implant failure due to varus angulation or the screw cut-out.

We hypothesized that the augmentation of CaP degradable cements would be useful to prevent screw cut-out of intramedullary nails, in contrast to the use of CaP degradable cements to reduce the shortening of the femoral neck in sliding screw devices. Between April 2014 and December 2016, 56 patients with unstable TFs were surgically treated with intramedullary (IM) devices and were randomly divided into two groups based on the use of augmentation into femoral head with bone graft substitute containing tricalcium phosphate and calcium sulphate [9] (geneX®, Biocomposites Ltd., Staffordshire, UK). The purpose of this study was to evaluate whether the use of CaP degradable cements for CaP augmentation around the lag screw inserted into the femoral head resulted in superior clinical and radiological outcomes (especially, the preventive effect on screw cut-out during bone union) in treatment of unstable TFs by using intramedullary implants.

2. Methods

2.1. Patients and Methods. Between April 2014 and December 2016, 100 patients with TFs were enrolled in this study. The trial included patients with unstable trochanteric (three or four parts fractures, AO type A2, and Evans unstable type 1). Additional inclusion criteria were as follows: age being more than 65 years; walking with or without support, having less than 72 hours between the fracture and surgery, and signing informed consent. Exclusion criteria were as follows: (1) stable two parts of fractures (AO type A1, Evans stable type 1); (2) transtrochanteric fractures with a transverse of reversed/oblique fracture line at the level of the lesser trochanter (AO type A3, Evans type 2) [10]; (3) pathological fractures related to tumors and subtrochanteric fractures; (4) tip-apex distance (TAD) > 18 mm [11]; (5) limited ability to perform objective functional tests (dementia, serious concomitant illness or mental instability, or neurosensory, or neuromuscular or musculoskeletal deficiency); (6) soft-tissue

infection at the operation site; (7) concurrent fractures that would affect the postoperative functional outcome.

After exclusion, 61 patients that underwent fracture fixation with an intramedullary nail were randomly either to the augmentation into femoral head with CaP group or to controls without CaP augmentation [12]. A total of 56 patients underwent hip computed tomography (CT) immediately and at one-year follow-up after the operation (Figure 1). Patients with a follow-up period < 2 years and those who were lost to follow-up were excluded. Thus, the final cohort included 28 patients assigned to the use of CaP cement and 28 patients in whom CaP cement was not used (control group). One patient from the CaP group was lost to the follow-up and two had a follow-up period < 2 years, while two patients from the control group were lost to follow-up and one had a follow-up period < 2 years.

The mean age of patients from the CaP and control groups was 78.6 years and 78.0 years, respectively. The mean body mass index (BMI) was 22.5 kg/m² in the CaP group and 21.2 kg/m² in the control group. The mean bone mineral density (BMD) was -3.9 in the CaP group and -3.9 in the control group. According to Evan's classification, CaP group included 3 patients with class 3 fractures, 16 patients with class 4 fractures, and 4 patients with class 5 fractures, while the control group included 4 patients with class 3 fractures, 15 patients with class 4 fractures, and 6 patients with class 5 fractures (Table 1). Appropriate reduction was achieved in all enrolled patients.

Informed consent was obtained from all participants. Patients gave informed consent for the study participation, while for patients with dementia consent was obtained from their legal guardians. The Institutional Review Board of the Kangdong Sacred Hospital approved the current study (ID number: KDF 2015-06-021).

All operations were performed by a single specialized hip fracture surgeon. All nail fixations were with performed a 130° nail with static distal locking and no supplementary fixation with Zimmer Natural Nail® (ZNN; Zimmer, Winterthur, Switzerland) was applied. All surviving patients were followed-up for a minimum of two years with functional assessment undertaken by an independent investigator blinded to the treatment allocation. All patients were followed-up at postoperative 2 weeks, and then at 2 months, 6 months, 12 months, and yearly, thereafter. Every follow-up included a clinical examination and a radiographic control. In addition, CT scans were scheduled at 12 months postoperatively for radiological assessment. Any fracture healing complications identified beyond one year from injury was also included in the outcomes.

Clinical outcomes (visual analogue scale for the hip pain [pVAS] and modified Harris Hip Score [mHHS]) and complications were assessed preoperatively and 2 years postoperatively in an outpatient clinic. Pain was evaluated at each follow-up visit using a 100-mm linear visual analogue scale (VAS), with 0 indicating no pain and 100 the most severe pain possible. mHHS score was evaluated at each follow-up visit by using a questionnaire with eight parameters and four physical examinations. The total score ranged between

TABLE 1: Patients' demographics.

	CaP group (n = 22)	Control group (n = 23)	P value
Age	78.6 ± 12.8	78.0 ± 17.9	0.925
BMI (kg/m ²)	22.5 ± 5.4	21.2 ± 3.4	0.758
BMD	-3.9 ± 1.0	-3.9 ± 0.7	0.937
Evan's classification	4.1 ± 0.6	4 ± 0.8	0.475
3 (n)	3	4	
4 (n)	14	13	
5 (n)	3	6	

CaP: calcium phosphate; BMI: body mass index; BMD: bone mineral density.

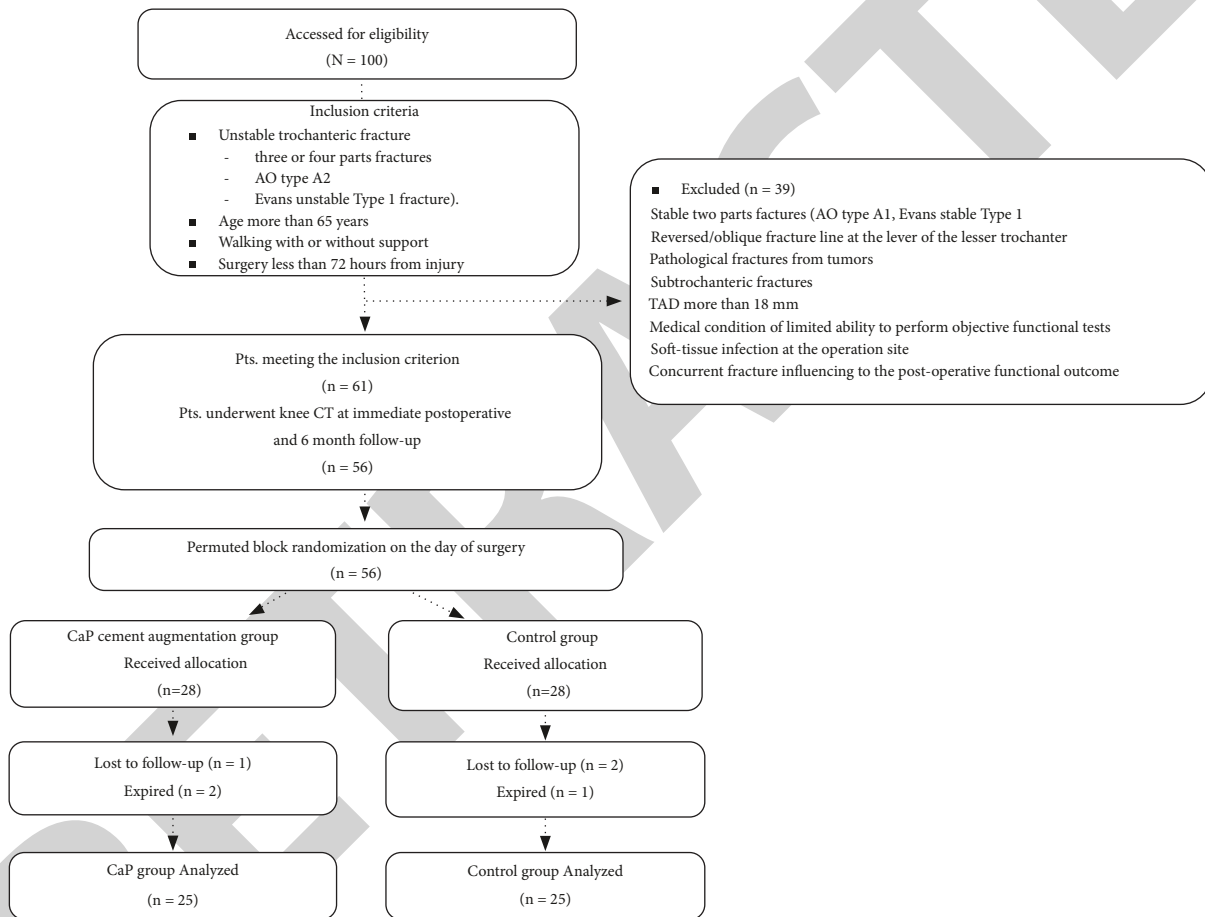


FIGURE 1: Patient flowchart. TAD: tip-apex distance and CT: computed tomography.

0 and 100. A higher score indicated better physical function. The parameters of questionnaire reflect the activities of daily living (ADL) and include (1) pain, (2) support, (3) distance walked, (4) limp, activities, (5) shoes, socks, (6) stairs, (7) public transportation, and (8) sitting.

Fracture healing was determined when the trabecula bone was observed across the fracture line on performed X-ray. Nonunion was defined as the absence of bridging bone at the line of the fracture at 6 months of follow-up. The signs of avascular necrosis were assessed according to the classification of Ficat [13]. TAD (tip-apex distance) was measured using CT data at immediate postoperative

and postoperative 1-year of follow-up. Using the RadiAnt digital imaging and communications in medicine (DICOM) Viewer (version 32-bit; Medixant, Poznan, Poland), a type of picture archiving and communication system, the images were exported and used for measurement. The DICOM (digital imaging and communications in medicine) data were extracted from the picture archiving and communication system and C-GET protocol support for retrieving studies from PACS locations. A widely used open-source application in both clinical and research settings and comparable in performance to commercially available software was used for configurable units and precision for length measurements

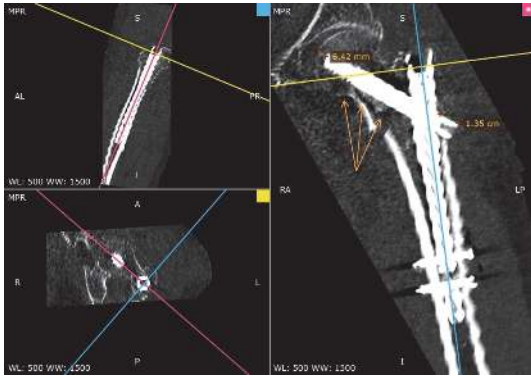


FIGURE 2: To calculate true tip-apex distance (TAD), curved multiplanar reconstruction (MPR) view was generated using axis lines (cross lines) in sagittal and coronal views as shown above, which shows whole lag screw and proximal nail. TAD was measured on this MPR view and the distance from lateral margin of proximal nail to lag screw tip was measured for assessment of lateral protrusion distance of lag screw (orange arrows: CaP around lag screw tip augmented through the screw tract).

[14]. Using the software, we acquired one view to reflect the real distance from the femoral head to the screw tip (Figure 2).

2.2. Surgical Procedure and Postoperative Rehabilitation. All surgical operations were performed by an experienced hip surgeon using IM devices. Before surgical draping, fractures were reduced using an orthopedic traction bed. Otherwise, reduction was easily obtained with gentle traction and rotational adjustment on a fracture table. Accurate reduction was checked by measuring the neck shaft angle or Garden's alignment index under the C-arm fluoroscopy, and any amount of varus alignments was not accepted. After the fracture reduction, the straight guide was positioned manually with a 2-cm skin incision proximally at the tip of greater trochanter. Reaming was performed at the entry site, with proper or slight overreaming for prevention of varus tilt of the head and neck fragment. The ideal position of a guide pin for the lag screw is in the center of the femoral head and neck on both AP and lateral views. Positioning the lag screw at the superior and anterior quadrant [15] and the tip of the lag screw getting away from the subchondral bone more than 5 mm will increase the risk of the screw cut-out. The acceptable distance from the subchondral cortex to the tip of the lag screw was located at 5 mm area of the subchondral bone on both AP and lateral postoperative radiographs. We inserted the nail a little deeper down to the canal and positioned the lag screw at the inferior to the center on AP view in order to avoid postoperative impingement of the nail tip. We tried to avoid the blade positioning at the superior quadrant. Finally, the fixation was performed using a distal interlocking screw and locked.

CaP degradable cement was injected just after reaming for lag screw insertion into the screw tract gently. The trocar was advanced through the screw tract to the proximal margin of the femoral head under the fluoroscopic monitoring.

Afterwards, the stylet pushed CaP into the tract slowly. CaP was penetrated to the surrounding bone simultaneously with the lag screw positioning (Figure 3). Full weight bearing during the early healing period was allowed in all patients.

Reduction was considered adequate if (1) the femoral neck angle was $< 10^\circ$ of varus or $< 15^\circ$ of valgus when compared with the uninjured, contralateral hip; (2) displacement was < 5 mm on both AP and lateral postoperative radiographs; (3) the position of the lag screw was assessed from the mapping of the femoral head described by Kyle et al. [16].

2.3. Statistical Analysis. Binary outcomes for the two groups were analyzed using Fisher's exact test and continuous outcomes were analyzed with the unpaired t-test. For the length of hospital stay, the data were not parametric, and the Mann-Whitney U test was used. A P-value < 0.05 was considered statistically significant. All results were analyzed on an intention-to-treat basis. The measurement methods were developed and agreed together by two orthopedic surgeons (independent observers). However, these surgeons were blinded to each other's measurements and their own prior measurements. They measured the parameters twice, with an interval of 2 weeks. The intraclass correlation coefficient was examined to assess the reliability of the measurements. All measured intraclass correlation coefficients were almost perfect, ranging from 0.831 to 0.991. All statistical analyses were performed using SAS ver. 9.3 (SAS Institute, Cary, NC, USA).

3. Results

The final 25 patients in CaP group and 25 patients to controls were analyzed in this study (Figure 1). Table 2 lists the operative details for the two groups. The total hospital stay was not different between the two groups, but inward ambulation was possible earlier in CaP group (10 ± 9 days) compared to the control group (13 ± 12 days) ($P = 0.02$). One patient with lag screw cut-out from the control group was reoperated on by hemiarthroplasty. No surgical site infection and adverse reaction occurred in either group. Table 3 lists the mean pain scores and mHHS scores. Improved clinical outcomes were observed with the use of CaP augmentation compared to controls, but the difference was not statistically significant.

Table 4 presents the radiological assessments on the immediate postoperative radiographs and at postoperative one-year follow-up. CaP group showed significantly lower change between TAD measured immediately after surgery and that measured at one-year follow-up ($P = 0.012$). Mean TAD was 5.6 mm (range: 3.0–8.2 mm) postoperatively and 3.7 mm (range: 0.5–6.9 mm) at one-year follow-up. The delta value was 1.3 mm (range: -1.3–3.9). In the control group, the mean TAD was 4.1 mm (range: 2.6–5.6 mm) postoperatively and 3.5 mm (range, 3.2–3.8 mm) at one-year follow-up; thus, the delta value was 2.0 mm (range: 1.3–2.7 mm). Mean lateral protrusion distance was 2.6 mm (range: 0.4–4.8 mm) postoperatively and 5.0 mm (range: 1.3–8.7 mm) at one-year follow-up; thus, the delta value was 2.5 mm (range:

TABLE 2: Operative details and hospital stay.

	CaP group (n = 22)	Control group (n = 23)	P value
Operation time (min)	37.0 ± 15.7	36.0 ± 17.9	0.856
Mean hospitalization (day)	28.5 ± 7.4	29.0 ± 9.4	0.985
Mean days for walker ambulation	10 ± 9	13 ± 12	0.02
Complication			
Wound infection, n	0	0	
Cut-out, n	0	1	

CaP: calcium phosphate.

TABLE 3: Mean (standard deviation) pain score as assessed by VAS during walking, and mHHS for the functional assessment in the two groups at two six months and two years after surgery (a score of 0 indicates no pain and 100 indicates the worst possible pain).

At postoperative	2 months			2 years		
	CaP	Control	P value	CaP	Control	P value
Pain VAS	30	45	0.121	15 (12)	16 (11)	0.816
mHHS	46 (18)	51 (15)	0.568	90 (7)	89 (9)	0.415

VAS: visual analogue scale; mHHS: modified Harris Hip score; CaP: calcium phosphate.

TABLE 4: Radiological assessments.

	TAD			Lateral protrusion of lag screw		
	Immediate postoperative	1 year follow-up	delta	Immediate postoperative	1 year follow-up	delta
CaP group	5.6 ± 2.6	3.7 ± 3.2	1.3 ± 2.6	2.6 ± 2.2	5.0 ± 3.7	2.5 ± 1.9
Control group	4.1 ± 1.5	3.5 ± 0.3	2.0 ± 0.7	2.4 ± 0.2	4.4 ± 0.6	2.2 ± 0.3
P value			0.012			0.243

TAD: tip-apex distance and CaP: calcium phosphate.

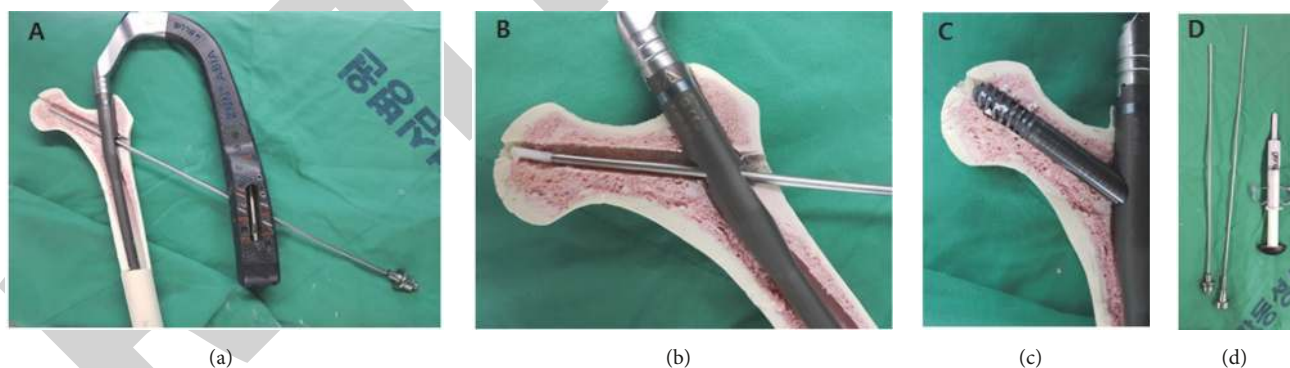


FIGURE 3: (a) CaP degradable cement (geneX®) was injected just after reaming for lag screw insertion into the screw tract gently. The trocar was advanced through the screw tract to the proximal margin of the femoral head under fluoroscopy monitoring. (b) Afterwards, the stylet was used to push CaP into the tract slowly. (c) CaP was penetrated into surrounding bone simultaneous with positioning of the lag screw. (d) Long trocar and stylet with enough length to femoral head manufactured and used.

0.6–4.4 mm) in CaP group. In the control group, the mean lateral protrusion distance was 2.4 mm (range: 2.2–2.6 mm) postoperatively and 4.4 mm (range: 3.8–5.0 mm) at the one-year follow-up; thus, the delta value was 2.2 mm (range: 1.9–2.5 mm). However, delta values were not significantly different between the two groups.

4. Discussion

The principal finding of this study was that (1) the augmentation into femoral head using CaP degradable cements significantly decreased the amount of the penetration of lag screw tip in elderly patients with unstable TFs; concomitantly,

lateral protrusion distance of the lag screw was increased by sliding laterally, even though the difference was not statistically significant; (2) significantly earlier ambulation was possible in patients from CaP augmented group compared to the control group.

In sliding hip screw, the augmentation into fracture site of CaP degradable cements might be useful for enhancing the osteoconduction and providing the mechanical stability by bone union, while both these parameters would be concomitantly affected by patient's factors, such as bone density and the fracture gap size. Therefore, it might be less predictable how to decrease the shortening of the femoral neck. Structural support against mechanical loading to fracture site was provided from adjacent osteoporotic bony trabeculae. Meanwhile, recent intramedullary nail systems with locking mechanisms between lag screw and intramedullary nail can withstand mechanical compressive loading. The power holding the reduction state is transferred to the femoral head around the lag screw tip. Therefore, the augmentation of CaP degradable cements would have to be sought to be applied on reducing complication rate, such as lag screw failure in intramedullary device.

Conventional bone cement injected into femoral head has several disadvantages, even though it can provide prompt mechanical supportive property. First, the thermal necrosis can happen [17]. Second, the nonunion problem can occur. Nonabsorbable cement can make the proximal portion of an unstable TF to be bulky, to hinder appropriate reduction [17]. In this study, there was no case of nonunion with augmentation of biodegradable cement into femoral head and all cases achieved appropriate reduction.

In recent years new types of cement which are susceptible to remodeling and replacement by host bone have been introduced and may be used for the augmentation of fractures in order to improve stability and outcome [3, 4, 18]. It is injectable, biocompatible, and nonexothermic and hardens in situ and is claimed to be replaced by host bone over time. After injection, an osteoconductive, carbonated apatite is formed with chemical and physical characteristics similar to those of the mineral phase of bone. It has a compressive strength of 55 MPa, which is higher than that of cancellous bone. CaP hardens without generating heat and, based upon preclinical studies and human biopsies, will resorb over time, although the timetable for this resorption in man is not known. With these advantages superior to the bone cement, biodegradable CaP can be applied with compensation of its limitations. However, CaP of injectable type used in this study is recommended to inject through screw tract as soon as possible just after mixing because hardened state over time of CaP can hinder screw entrance.

Another principal finding was that earlier ambulation was enabled in patients with augmentation of CaP. Increased and localized load to subchondral bone of femoral head through lag screw tip during weight bearing can make pain and induce the subchondral bone marrow lesion, which is closely correlated with pain and rapid joint deterioration [19–21]. Pain relief by the augmentation of CaP can be explained as for subchondroplasty, a procedure involving the injection of the bone substitute into the bone marrow lesion, introduced

for pain relief [22, 23]. Faster ambulation can decrease the duration of hospitalization and also prevent postoperative complications such as deep vein thrombosis and pulmonary embolism.

This study has several limitations. First, patients were enrolled under the exclusion criteria of TAD more than 18 mm [11]. Geller et al. [11] reported that patients with the average TAD < 18 mm did not experience screw cut-out when using IM devices in the treatment of trochanteric hip fractures, since there was only one case with screw cut-out regardless of the CaP augmentation. Second, the sample size was relatively small to provide conclusive data regarding whether the augmentation of CaP into femoral head significantly prevents the screw cut-out. Therefore, this study was performed to evaluate the amount of lag screw penetration by bone union by exact measurement of TAD on MPR view using software. Our results provide clues for further investigation to prevent lag screw cut-out, even though the small differences reported here might be unlikely to have clinical significance. Third, other confounding factors can be suggested related lag screw cut-out or penetration including fracture type, surgical technique related screw position, and bone density. However, there is no significant difference between the two groups in terms of patients' demographics, such as age, sex, BMI, and BMD. Moreover, this study included only patients of unstable TF. Our findings have clinical relevance because to the best of our knowledge, this is the first study about clinical effectiveness of the augmentation of CaP into femoral head of internally fixed unstable TFs.

5. Conclusion

The CaP augmentation into femoral head around lag screw can decrease the amount of lag screw penetration in elderly patients with unstable TFs and be helpful to prevent screw cut-out beyond femoral head and to facilitate early ambulation.

Abbreviations

BMD:	Bone mineral density
BMI:	Body mass index
CaP:	Calcium phosphate
CT:	Computed tomography
DICOM:	Digital imaging and communications in medicine
HHS:	Harris Hip Score
IM:	Intramedullary
TF:	Trochanteric fracture
TAD:	Tip-apex distance
VAS:	Visual analogue scale.

Data Availability

The datasets used and/or analyzed during the current study are available from the corresponding author on reasonable request.

Ethical Approval

All procedures performed in studies involving human participants were in accordance with the ethical standards of the institutional and/or national research committee and with the 1964 Helsinki declaration and its later amendments or comparable ethical standards. The current study obtained Institutional Review Board approval from the authors' institution (ID number: KDF 2015-06-021) before study onset, and their protocol was also approved.

Consent

Informed consent was obtained from all participants.

Disclosure

The funding sources were not involved in the study design, collection, data analysis or interpretation, writing of the manuscript, or the decision to submit the manuscript for publication. *Level of Evidence II* is prospective comparative study.

Conflicts of Interest

The authors declare that they have no conflicts of interest.

Authors' Contributions

(1) Byung Hoon Lee and Jin Park handled conception and design of the study, Byung Hoon Lee, Do Kyung Lee, and Seung Ha Paik collected data, Byung Hoon Lee conducted data analysis and managed interpretation, (2) Jung Min Shin drafted the manuscript, Byung Hoon Lee and Sung-Sahn Lee critically revised the manuscript for important intellectual content, and (3) final approval of the version to be submitted was given by all authors. Byung Hoon Lee (oselite@naver.com) takes responsibility for the integrity of this work. These authors (Jin Park and Jung Min Shin) contributed equally to this work.

Acknowledgments

The authors thank all members of the Joint Reconstruction Center, Kangdong Sacred Heart Hospital, for their great scientific debates. This research was supported by a grant no. 2015-09 from the Kangdong Sacred Heart Hospital Fund.

References

- [1] D. G. Lorich, D. S. Geller, and J. H. Nielson, "Osteoporotic peritrochanteric hip fractures: management and current controversies," *Instructional Course Lectures*, vol. 53, pp. 441–454, 2004.
- [2] W.-Y. Kim, C.-H. Han, J.-I. Park, and J.-Y. Kim, "Failure of intertrochanteric fracture fixation with a dynamic hip screw in relation to pre-operative fracture stability and osteoporosis," *International Orthopaedics*, vol. 25, no. 6, pp. 360–362, 2001.
- [3] M. Bohner, "Calcium orthophosphates in medicine: from ceramics to calcium phosphate cements," *Injury*, vol. 31, no. 4, pp. D37–D47, 2000.
- [4] L. Eschbach, "Nonresorbable polymers in bone surgery," *Injury*, vol. 31, supplement 4, pp. D22–D27, 2000.
- [5] B. Barnes and K. Dunovan, "Functional outcomes after hip fracture," *Physical Therapy in Sport*, vol. 67, no. 11, pp. 1675–1679, 1987.
- [6] P. Mattsson and S. Larsson, "Unstable trochanteric fractures augmented with calcium phosphate cement. A prospective randomized study using radiostereometry to measure fracture stability," *Scandinavian Journal of Surgery*, vol. 93, no. 3, pp. 223–228, 2004.
- [7] P. Mattsson, A. Alberts, G. Dahlberg, M. Sohlman, H. C. Hyldahl, and S. Larsson, "Resorbable cement for the augmentation of internally-fixed unstable trochanteric fractures. A prospective, randomized multicentre study," *The Journal of Bone & Joint Surgery (British Volume)*, vol. 87, no. 9, pp. 1203–1209, 2005.
- [8] W. Yu, X. Zhang, R. Wu et al., "The visible and hidden blood loss of Asia proximal femoral nail anti-rotation and dynamic hip screw in the treatment of intertrochanteric fractures of elderly high-risk patients: A retrospective comparative study with a minimum 3 years of follow-up," *BMC Musculoskeletal Disorders*, vol. 17, no. 1, 2016.
- [9] H. L. Yang, X. S. Zhu, L. Chen et al., "Bone healing response to a synthetic calcium sulfate/ β -tricalcium phosphate graft material in a sheep vertebral body defect model," *Journal of Biomedical Materials Research Part B: Applied Biomaterials*, vol. 100B, no. 7, pp. 1911–1921, 2012.
- [10] H. Pervez, M. J. Parker, G. A. Pryor, L. Lutchman, and N. Chirodian, "Classification of trochanteric fracture of the proximal femur: a study of the reliability of current systems," *Injury*, vol. 33, no. 8, pp. 713–715, 2002.
- [11] J. A. Geller, C. Saifi, T. A. Morrison, and W. Macaulay, "Tip-apex distance of intramedullary devices as a predictor of cut-out failure in the treatment of peritrochanteric elderly hip fractures," *International Orthopaedics*, vol. 34, no. 5, pp. 719–722, 2010.
- [12] G. S. Doig and F. Simpson, "Randomization and allocation concealment: a practical guide for researchers," *Journal of Critical Care*, vol. 20, no. 2, pp. 187–191, 2005.
- [13] R. P. Ficat, "Idiopathic bone necrosis of the femoral head. Early diagnosis and treatment," *The Journal of Bone & Joint Surgery (British Volume)*, vol. 67, no. 1, pp. 3–9, 1985.
- [14] T. Yamauchi, M. Yamazaki, A. Okawa et al., "Efficacy and reliability of highly functional open source DICOM software (OsiriX) in spine surgery," *Journal of Clinical Neuroscience*, vol. 17, no. 6, pp. 756–759, 2010.
- [15] R. F. Kyle, M. E. Cabanela, T. A. Russell et al., "Fractures of the proximal part of the femur," *Instr Course Lect*, pp. 44–227, 1995.
- [16] R. F. Kyle, R. B. Gustilo, and R. F. Premer, "Analysis of six hundred and twenty-two intertrochanteric hip fractures. A retrospective and prospective study," *The Journal of Bone & Joint Surgery*, vol. 61, no. 2, pp. 216–221, 1979.
- [17] P. Lee, K. Peng, C. Wu, T. Huang, R. Hsu, and M. Wu, "Complications of cement-augmented dynamic hip screws in unstable type intertrochanteric fractures—a case series study," *Biomedical Journal*, vol. 35, no. 4, p. 345, 2012.
- [18] F. R. DiMaio, "The science of bone cement: A historical review," *Orthopedics*, vol. 25, no. 12, pp. 1399–1407, 2002.

- [19] F. W. Roemer, T. Neogi, M. C. Nevitt et al., "Subchondral bone marrow lesions are highly associated with, and predict subchondral bone attrition longitudinally: the MOST study," *Osteoarthritis and Cartilage*, vol. 18, no. 1, pp. 47–53, 2010.
- [20] M. D. Crema, F. W. Roemer, D. Hayashi, and A. Guermazi, "Comment on: Bone marrow lesions in people with knee osteoarthritis predict progression of disease and joint replacement: A longitudinal study," *Rheumatology*, vol. 50, no. 5, Article ID ker006, pp. 996–997, 2011.
- [21] D. T. Felson, C. E. Chaisson, C. L. Hill et al., "The association of bone marrow lesions with pain in knee osteoarthritis," *Annals of Internal Medicine*, vol. 134, no. 7, pp. 541–549, 2001.
- [22] S. B. Cohen and P. F. Sharkey, "Subchondroplasty for Treating Bone Marrow Lesions," *Journal of Knee Surgery*, vol. 29, no. 7, pp. 555–563, 2016.
- [23] P. F. Sharkey, S. B. Cohen, C. F. Leinberry, and J. Parvizi, "Subchondral bone marrow lesions associated with knee osteoarthritis," *American journal of orthopedics (Belle Mead, N.J.)*, vol. 41, no. 9, pp. 413–417, 2012.