

**The effects of oral administration of monosodium glutamate (msg) on the testicular morphology and cauda epididymal sperm reserves of young and adult male rats**

**Udensi M. Igwebuike<sup>1\*</sup>, Izuchukwu S. Ochiogu<sup>2</sup>, Blessing C. Ihedinihu<sup>1</sup>, Joseph E. Ikokide<sup>2</sup>, and Idika K. Idika<sup>3</sup>**

<sup>1</sup>*Department of Veterinary Anatomy, Faculty of Veterinary Medicine, University of Nigeria Nsukka, Nigeria*

<sup>2</sup>*Department of Veterinary Obstetrics and Reproductive Diseases, Faculty of Veterinary Medicine, University of Nigeria Nsukka, Nigeria*

<sup>3</sup>*Department of Veterinary Parasitology and Entomology, Faculty of Veterinary Medicine, University of Nigeria Nsukka, Nigeria*

---

**IGWEBUIKE, U. M., I. S. OCHIUGU, B. C. IHEDINIHU, J. E. IKOKIDE, I. K. IDIKA: The effects of oral administration of monosodium glutamate (msg) on the testicular morphology and cauda epididymal sperm reserves of young and adult male rats. Vet. arhiv 81, 525-534, 2011.**

**ABSTRACT**

The effects of oral administration of varied doses of monosodium glutamate (MSG) on the morphology of the testes and cauda epididymal sperm reserves of rats were studied using 28 four-week-old (young) male Sprague-Dawley rats and 28 twelve-week-old (adult) male Sprague-Dawley rats. Increasing doses (1 mg/g body mass, 2 mg/g body mass, and 4 mg/g body mass) of a 40% aqueous solution of monosodium glutamate were administered to the male Sprague-Dawley rats every 48 hours for 6 weeks, using a rat gavage needle. The results showed that age variation did not influence the effect of MSG on the parameters studied in male rats. There was a significant reduction in the cauda epididymal sperm reserves ( $P < 0.05$ ) and the serum testosterone levels ( $P < 0.05$ ) of the rats that received monosodium glutamate relative to the control rats. The histomorphology of the testes of the rats that were given monosodium glutamate did not differ from those of the rats in the control group. No overt pathological lesions were seen in the testicular sections. These observations suggest that monosodium glutamate may have adversely affected spermatogenesis by disrupting the hypothalamic-pituitary-testis regulatory axis, and not through any direct toxic effect on the testis.

**Key words:** monosodium glutamate, serum testosterone level, cauda epididymal sperm, testicular morphology

---

\*Corresponding author:

Dr. U. M. Igwebuike, Department of Veterinary Anatomy, Faculty of Veterinary Medicine, University of Nigeria Nsukka, Nigeria, Phone: +234 803 872 6150; Fax: +234 42770 644; E-mail: abuchi2002@yahoo.com; udensi.igwebuike@unn.edu.ng

## Introduction

Monosodium glutamate (MSG), a white crystalline powder, is the sodium salt of a naturally occurring non-essential amino acid, glutamic acid (FURST and STEHLE, 2004). MSG is commonly marketed as a flavour enhancer and is used as a food additive particularly in West African and Asian dishes (FAROMBI and ONYEMA, 2006). Generally, monosodium glutamate is accepted as a safe food additive that needs no specified average daily intake or an upper limit intake (SAMUELS, 1999). However, inadvertent abuse of this food additive may occur because of its abundance, mostly without labelling, in many food ingredients (EGBUONU et al., 2009). An experimental study (BURDE et al., 1971) demonstrated that both subcutaneous injection and oral administration of MSG to immature rats and mice resulted in neuronal losses in the hypothalamus.

The ability of monosodium glutamate to damage nerve cells of the hypothalamus is a pointer to the fact that it may alter the neural control of reproductive hormone secretion via the hypothalamic-pituitary-gonadal regulatory axis. Such alterations in reproductive hormone secretion may adversely affect the reproductive capacity of the affected animals. Indeed, there is unpublished evidence that high doses of monosodium glutamate have been used in some parts of Nigeria as folk medicine to counteract libido in male goats. The effects of such toxicants on male reproduction may be anatomical or only functional, depending on whether they produce structural changes in the reproductive system, or merely affect the functions of the reproductive organs (WITORSCH, 1995). The present study was designed to investigate the effects of monosodium glutamate on the testes and cauda epididymal sperm reserves of both young and adult male rats.

## Materials and methods

*Experimental animals.* Two experiments were carried out in this study. The 28 four-week-old male Sprague-Dawley rats used for Experiment I weighed between 40 and 60 grams at the commencement of the experiment and these constituted the young male rats of the study. The 28 twelve-week-old male Sprague-Dawley rats used for Experiment II weighed between 160 and 180 grams at the commencement of the experiment and these constituted the adult male rats of the study. All the rats were housed in fly-proof metal aluminum cages and fed commercially prepared feed *ad libitum*. Drinking water was provided. The rats were kept for a two-week acclimatization period before the commencement of the experiments.

*Experiment I.* The 28 young male rats were randomly assigned to 4 groups of 7 rats per group. The control group received no monosodium glutamate, while rats in the three treatment groups were given oral doses of a 40% aqueous solution of monosodium glutamate every 48 hours for 6 weeks, using a rat gavage needle. On each treatment day, rats in the low dose group received 1 mg/g body mass of MSG per rat, those in the

medium dose group received 2mg/g body mass of MSG per rat, and rats in the high dose group received 4mg/g body mass of MSG per rat. At the end of the 6 weeks of treatment with monosodium glutamate, the rats were euthanatized using diethyl ether chamber.

*Experiment II.* The 28 adult male rats were randomly assigned to 4 groups of 7 rats per group. The treatment procedures described above for the young rats were repeated for these adult rats.

*Quantitative measurements.* Prior to sacrificing each rat, 2 mL of blood was collected from the medial canthus of the eye into a test tube, and allowed to clot. The serum was harvested and used for testosterone assay. The assay was carried out using ELISA technique. Following death, the epididymides of each male rat were dissected and extraneous tissues trimmed. These epididymides were weighed and put in bijour bottles containing phosphate-buffered saline, pH 6.8. The cauda epididymal sperm reserves were determined using the standard hemocytometric method of AMANN and ALMQUIST (1961).

*Histological preparations.* The testes were dissected from each male rat. The testes were fixed by immersion in Bouin's fluid for 48 hours. Later, they were dehydrated in graded concentrations of ethanol, cleared in xylene, and embedded in paraffin wax. The 5 µm thick sections were cut, mounted on glass slides, and stained with hematoxylin and eosin for light microscopy. Photomicrographs were captured using a Moticam Images Plus 2.0 digital camera (Motic China Group Ltd. 1999-2004).

*Statistical analyses.* Means and standard errors were calculated for each group of observations. The data obtained were statistically analyzed using ANOVA (SPSS 9.0 Statistical Package of SPSS Inc. USA).

## Results

*Serum testosterone levels.* The mean serum testosterone levels of both the young and adult male rats are presented in Table 1.

Table 1. The mean serum testosterone levels of male rats that received varied doses of monosodium glutamate

Animal group	Parameter	Control	Low dose (1 mg/g b.m.)	Medium dose (2 mg/g bm.)	High dose (4 mg/g bm.)	P levels
Young male rats	Serum testosterone level (ng/mL)	4.45 ± 0.35 <sup>a</sup>	1.11 ± 0.27 <sup>b</sup>	0.71 ± 0.16 <sup>b</sup>	1.38 ± 0.63 <sup>b</sup>	ab: P<0.05
Adult male rats	Serum testosterone level (ng/mL)	3.40 ± 0.17 <sup>a</sup>	1.18 ± 0.09 <sup>b</sup>	1.24 ± 0.39 <sup>b</sup>	0.33 ± 0.09 <sup>c</sup>	ab: P<0.05 ac: P<0.05 bc: P<0.05

Values are presented as mean ± SE. Different superscripts in a row indicate significant variation at the specified level of probability

The mean serum testosterone levels of the young rats that received the low dose, medium dose and high dose of monosodium glutamate in this study were significantly lower ( $P < 0.05$ ) than that of the control rats. The serum testosterone levels did not differ significantly ( $P > 0.05$ ) between the three MSG-treat groups. The mean serum testosterone levels of the adult rats that received the low dose, medium dose and high dose of monosodium glutamate in this study were significantly lower ( $P < 0.05$ ) than that of the control rats. Furthermore, the mean serum testosterone level of adult rats in the high dose group was significantly lower ( $P < 0.05$ ) than those of the low and medium dose groups.

*Cauda epididymal sperm reserves.* Table 2 shows the data on the mean cauda epididymal sperm reserves of both the young and adult male rats. There was no significant difference ( $P > 0.05$ ) between the mean cauda epididymal sperm reserve of the young rats that received the low dose of monosodium glutamate and that of the control rats. However, the mean cauda epididymal sperm reserves of the young rats that were given the medium and high doses of monosodium glutamate were significantly reduced ( $P < 0.05$ ) relative to the control group and the low dose group. Comparison of the mean cauda epididymal sperm reserves of the adult male rats showed that the value obtained for each of the three treatment groups was significantly lower ( $P < 0.05$ ) than that of the control group. Further comparison of the treatment groups revealed a dose-related significant reduction ( $P < 0.05$ ) in the mean cauda epididymal sperm reserves.

Table 2. The mean cauda epididymal sperm reserves of male rats that received varied doses of monosodium glutamate.

Animal group	Parameter	Control	Low dose (1 mg/g bm.)	Medium dose (2 mg/g bm.)	High dose (4 mg/g bm.)	P levels
Young male rats	Cauda epididymal sperm reserve ( $10^6$ )	139.34 ± 14.14 <sup>a</sup>	113.82 ± 15.82 <sup>a</sup>	37.57 ± 5.88 <sup>b</sup>	12.79 ± 1.68 <sup>b</sup>	ab: $P < 0.05$
Adult male rats	Cauda epididymal sperm reserve ( $10^6$ )	216.31 ± 8.54 <sup>a</sup>	137.53 ± 5.44 <sup>b</sup>	96.05 ± 3.53 <sup>c</sup>	47.61 ± 2.67 <sup>d</sup>	ab: $P < 0.05$ ac: P < 0.05ad: P < 0.05bc: P < 0.05bd: P < 0.05cd: P < 0.05

Values are presented as mean ± SE. Different superscripts in a row indicate significant variation at the specified level of probability

*Histology.* Sections of the testes of the young rats (Fig. 1) and the adult rats (Fig. 2) in the control group showed normal seminiferous tubules and interstices. The morphology of the testes of the male rats that were given monosodium glutamate did not appear different from those of the control rats. No overt pathological lesions were apparent in the seminiferous epithelia or the interstitial spaces of the testes (Figs. 3, 4) of the male rats that received the different doses of monosodium glutamate.

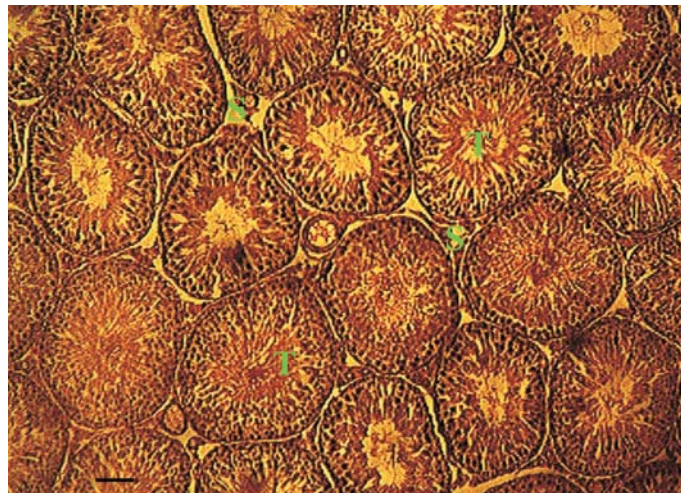


Fig. 1. Histology of the testis of a young male rat of the control group showing normal testicular histology. Note the active seminiferous tubules (T) and interstitial spaces (S). H&E stain; objective  $\times 10$ ; scale bar = 60  $\mu\text{m}$ .

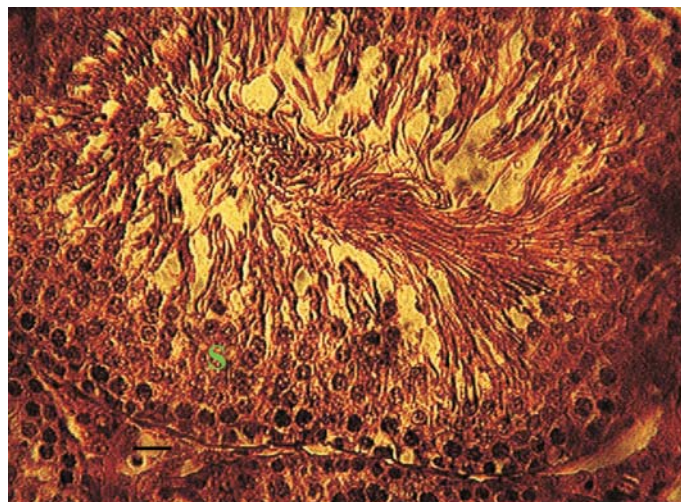


Fig. 2. Histology of the seminiferous tubule of an adult male rat of the control group showing normal histology. The seminiferous epithelium (S) is active in spermatogenesis. H&E stain objective  $\times 40$ , scale bar = 15  $\mu\text{m}$ .

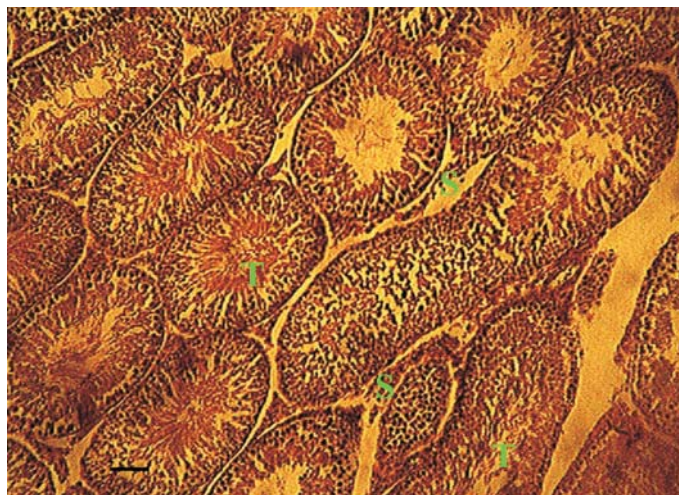

Fig. 3. Histology of the testis of a young male rat that received 4 mg/g b.m. of monosodium glutamate showing no overt pathological lesions. Note the seminiferous tubules (T) and interstitial spaces (S). H&E stain, objective  $\times 10$ ; scale bar = 60  $\mu\text{m}$ .

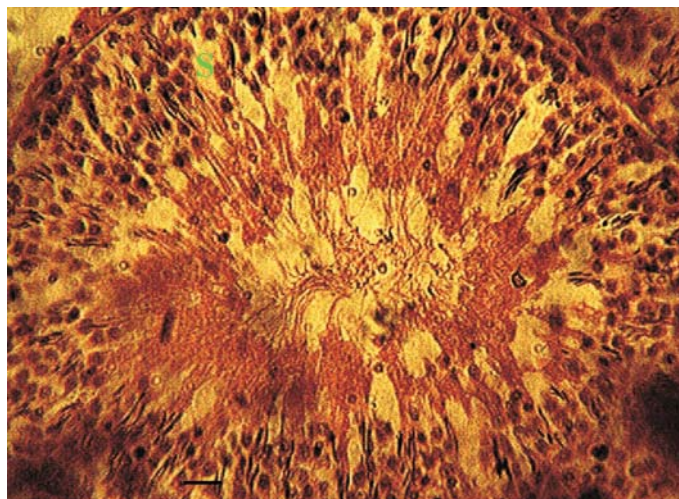


Fig. 4. Histology of the seminiferous tubule of an adult male rat that received 4mg/g b. m. of monosodium glutamate showing no overt pathological lesions. The seminiferous epithelium (S) is apparently active in spermatogenesis. H&E stain; objective  $\times 40$ ; scale bar = 15  $\mu\text{m}$ .

### Discussion

The activity of neuroendocrine regulatory processes may be very susceptible to changes in certain external factors such as nutrition or administration of hormones and drugs. Our study demonstrated that serum testosterone levels were markedly reduced in both young and adult rats treated with monosodium glutamate. Administration of monosodium glutamate destroyed neurons of the hypothalamus in rats and mice (BURDE et al., 1971), and such neuronal losses in the hypothalamus can result in disruption of the hypothalamic-pituitary-testis regulatory axis (NEMEROFF et al., 1981) that controls the steroidogenesis of testicular Leydig cells (McLACHLAN et al., 1996). This will ultimately impact serum testosterone levels, because 95% of the androgen is produced by Leydig cells of the testes, while cells in the cortex of the adrenal gland produce about 5% (URBAN, 1999).

The dose-dependent reduction in cauda epididymal sperm counts following oral administration of monosodium glutamate to both young and adult male rats may be an indication that the normal process of spermatogenesis was adversely affected in the rats that consumed monosodium glutamate. Spermatogenesis is a complex cyclic process in which germ cells undergo series of mitotic and meiotic cell divisions, followed by morphological differentiation in a delicately regulated spatiotemporal fashion in the seminiferous epithelium. In mammals, spermatogenesis is totally dependent upon testosterone (PAKARAINEN et al., 2005; WANG et al., 2009); however, only total abolition of testicular androgen action resulted in consistent azoospermia (ZHANG et al., 2003). Androgens act to stimulate spermatogenesis through androgen receptors (ARs) located on Sertoli cells and peritubular myoid cells of the testis (DE GENDT et al., 2004). It has been demonstrated that androgen stimulation of spermatogenesis requires direct androgen action on the Sertoli cells (O'SHAUGHNESSY et al., 2010), and this was necessary for postmeiotic spermiogenesis (ZHANG et al., 2003). Thus, appropriate regulation of androgen activity via the hypothalamic-pituitary-testis axis is necessary for initiation and maintenance of spermatogenesis. The indication is that the reduced cauda epididymal sperm counts observed in the MSG-treated rats in the present study may be the end result of a considerable decline in the influence of testosterone on spermatogenesis in these rats. This proposition agrees with the report of ZIRKIN et al. (1989) who showed that there was a dose-response relationship between seminiferous tubule fluid (STF) testosterone concentration and the number of advanced spermatids produced by the testis.

The absence of any overt pathological lesions in the histology of the testes of the young and adult rats that received varied doses of monosodium glutamate suggests that MSG did not have any direct toxic effect on the testes. This observation differs from what has been reported in rats following the administration of some testicular toxicants such as crude oil (OBIDIKE et al., 2007; IGWEBUIKE et al., 2009) and metronidazole

(SOHRABI et al., 2007). The inference is that monosodium glutamate may have impacted spermatogenesis through its disruption of the hypothalamic-pituitary-testis regulatory axis, and not through any direct toxic effect on the testis.

In conclusion, our study has demonstrated that oral administration of monosodium glutamate resulted in lowered serum testosterone levels and reduction in the cauda epididymal sperm reserves of male rats, but did not cause any overt pathological lesions in their testes. These effects were similar in both the young and adult male rats that received monosodium glutamate, and may have arisen through disruption of the hypothalamic-pituitary-testis axis regulation by monosodium glutamate.

#### **Formal statement**

The authors wish to state that the rats used in the course of this study were handled in accordance with the guidelines for the protection of animal welfare in the University of Nigeria Nsukka.

#### **References**

- AMANN, R. P., J. O. ALMQUIST (1961): Reproductive capacity of dairy bulls. 1. Techniques for direct measurement of gonadal and extra-gonadal sperm reserves. *J. Dairy sci.* 44, 1537-1545.
- BURDE, R. M., B. SCHAINKER, J. KAYES (1971): Acute effect of oral and subcutaneous administration of monosodium glutamate on the arcuate nucleus of the hypothalamus in mice and rats. *Nature* 233, 58-60.
- DE GENDT K., J. V. SWINNEN, P. T. SAUNDERS, L. SCHOONJANS, M. DEWERCHIN, A. DEVOS, K. TAN, N. ATANASSOVA, F. CLAESSENS, C. LÉCUREUIL, W. HEYNS, P. CARMELIET, F. GUILLOU, R. M. SHARPE, G. VERHOEVEN (2004): A Sertoli cell-selective knockout of the androgen receptor causes spermatogenic arrest in meiosis. *Proc. Natl. Acad. Sci. USA* 101, 1327-1332.
- EGBUONU, A. C., O. OBIDOA, C. A. EZEOKONKWO, L. U. EZEANYIKA, P. M. EJKEME (2009): Hepatotoxic effects of low dose oral administration of monosodium glutamate in male albino rats. *African J. Biotechnol.* 8, 3031-3035.
- FAROMBI, E. O., O. O. ONYEMA (2006): Monosodium glutamate-induced oxidative damage and genotoxicity in the rat: modulatory role of vitamin C, vitamin E and guercetin. *Human Experimental Toxicol.* 125, 251-259.
- FURST, P., P. STEHLE (2004): What are the essential elements needed for the determination of amino acid requirements in humans? *J. Nutri.* 34, 1558S-1565S.
- IGWEBUIKE, U. M., R. I. OBIDIKE, N. U. NJOKU, S. V. O. SHOYINKA (2009): Testicular morphology and epididymal sperm reserves of male rats following the withdrawal of Nigerian Qua Iboe Brent crude oil. *Vet. Arhiv* 80, 121-128.



- McLACHLAN, R. I., N. G. WREFORD, L. O'DONNELL, D. M. DE KRETZER, D. M. ROBERTSON (1996): The endocrine regulation of spermatogenesis: independent roles for testosterone and FSH. *J. Endocrinol.* 148, 1-9.
- NEMEROFF, C. B., C. A. LAMARTINIERE, G. A. MASON, R. E. SQUIBB, J. S. HONG, S. C. BONDY (1981): Marked reduction in gonadal steroid hormone levels in rats treated neonatally with monosodium-L-glutamate: Further evidence for disruption of hypothalamic-pituitary-gonadal axis regulation. *Neuroendocrinol.* 33, 265-267.
- OBIDIKE, I. R., U. M. IGWEBUIKE, S. V. O. SHOYINKA (2007): Testicular morphology and cauda epididymal sperm reserves of male rats exposed to Nigerian Qua Iboe Brent crude oil. *J. Vet. Sci.* 8, 1-5.
- O'SHAUGHNESSY, P. J., G. VERHOEVEN, K. DE GENDT, A. MONTEIRO, M. H. ABEL (2010): Direct action through the Sertoli cells is essential for androgen stimulation of spermatogenesis. *Endocrinol.* 151, 2343-2348.
- PAKARAINEN, T., F. ZHANG, S. MÄKELÄ, M. POUTANEN I. HUHTANIEMI (2005): Testosterone replacement therapy induces spermatogenesis and partially restores fertility in luteinizing hormone receptor knockout mice. *Endocrinol.* 146, 596-606.
- SAMUELS, A. (1999): The toxicity/safety of MSG: A study in suppression of information. *Accountability Res.* 6, 259-310.
- SOHRABI, D., M. ALIPOURB, A. AWSATMELLATIC (2007): Effect of metronidazole on spermatogenesis, plasma gonadotrophins and testosterone in male rats. *Iranian J. Pharmaceutical Res.* 6, 279-283.
- URBAN, R. J. (1999): Effects of testosterone and growth hormone on muscle function. *J. Lab. Clin. Med.* 134, 7-10.
- WANG, R., S. YEH, C. TZENG, C. CHANG (2009): Androgen receptor roles in spermatogenesis and fertility: Lessons from testicular cell-specific androgen receptor knockout mice. *Endocrinol. Rev.* 30, 119-132.
- WITORSCH, R. J. (1995): *Reproductive Toxicology*, 2<sup>nd</sup> ed. Raven Press, New York.
- ZHANG, F., T. PAKARAINEN, M. POUTANEN, J. TOPPARI, I. HUHTANIEMI (2003): The low gonadotropin-independent constitutive production of testicular testosterone is sufficient to maintain spermatogenesis. *Proc. Natl. Acad. Sci. USA.* 100, 13692-13697.
- ZIRKIN, B. R., R. SANTULLI, C. A. AWONIYI, L. L. EWING (1989): Maintenance of advanced spermatogenic cells in the adult rat testis: quantitative relationship to testosterone concentration within the testis. *Endocrinol.* 124, 3043-3049.

Received: 28 June 2010

Accepted: 17 March 2011

---

**IGWEBUIKE, U. M., I. S. OCHIOGU, B. C. IHEDINIHU, J. E. IKOKIDE, I. K. IDIKA: Učinci oralnog davanja mononatrijeva glutamata na morfologiju jaja i rezervu spermija u nuzjajčanom repu mladih i odraslih štakora. Vet. arhiv 81, 525-534, 2011.**

**SAŽETAK**

Učinci oralnog davanja različitih doza mononatrijeva glutamata na morfologiju jaja i rezervu spermija u nuzjajčanom repu bili su istraživani u pokusima na 28 štakora Sprague-Dawley u dobi od četiri tjedna (mladi) i na 28 štakora Sprague-Dawley u dobi od 12 tjedana (odrasli). Štakorima su bile primijenjene povećavajuće doze (1 mg/g tjelesne mase, 2 mg/g tjelesne mase i 4 mg/g tjelesne mase) 40%-tne vodene otopine mononatrijeva glutamata svakih 48 sati kroz šest tjedana iglom prilagođenom za štakore. Rezultati su pokazali da razlika u dobi nije utjecala na učinak mononatrijeva glutamata na pretraživane pokazatelje. Ustanovljeno je značajno smanjenje rezervi spermija u nuzjajčanom repu ( $P < 0,05$ ) kao i razina serumskog testosterona ( $P < 0,05$ ) u štakora kojima je primijenjen mononatrijev glutamat u odnosu na kontrolnu skupinu. Histološki nalaz tkiva jaja štakora kojima je bio primijenjen mononatrijev glutamat nije se razlikovao od onog u štakora kontrolne skupine. Nisu bili uočeni patološki poremećaji u histološkim rezovima tkiva. Ovi nalazi upućuju na zaključak da mononatrijev glutamat može imati nepovoljan utjecaj na spermatogenezu prekidanjem regulacijske osi hipotalamus-hipofiza-testis, a ne putem ikakvoga izravnoga toksičnoga učinka na testese.

**Ključne riječi:** mononatrijev glutamat, razina serumskog testosterona, nuzjajčana sperma, morfologija testesa

---