

## The Effects of Sericin Cream on Wound Healing in Rats

Pornanong ARAMWIT<sup>1,†</sup> and Areeporn SANGCAKUL<sup>2</sup>

<sup>1</sup>Department of Pharmacy, Faculty of Pharmaceutical Sciences, Chulalongkorn University, Bangkok, 10330, Thailand

<sup>2</sup>Research Center, Ramathibodi Hospital, Faculty of Medicine, Mahidol University, Bangkok, 10400, Thailand

Received April 24, 2007; Accepted July 4, 2007; Online Publication, October 7, 2007

[doi:10.1271/bbb.70243]

**Sericin has good hydrophilic properties, compatibility, and biodegradation, it can be used as a wound-healing agent. We evaluated the effects of sericin on wound healing and wound size reduction using rats by generating two full-thickness skin wounds on the dorsum. Group 1 animals were treated with Betadine® on left-side (control) wounds and, with 8% sericin cream on right-side (treated) wounds. Group 2, cream base (formula control) and 8% sericin cream (treated) were topically applied to left-, and right-side wounds respectively. Sericin-treated wounds had much smaller inflammatory reactions, and wound-size reduction was much greater than in the control throughout the inspection period. Mean time in days for 90% healing from sericin-treated wounds was also much less than for cream base-treated wounds. Histological examination after 15 d of treatment with 8% sericin cream revealed complete healing, no ulceration, and an increase in collagen as compared to cream base-treated wounds, which showed some ulceration and acute inflammatory exudative materials.**

**Key words:** wound healing; sericin; histopathological inspection; wound-size reduction

Silkworms, *Bombyx mori*, produce two natural macromolecule proteins. These are sericin and fibroin proteins. Sericin, comprising granular and high molecular proteins that have adhesive and gelatin-like characteristics, is specially synthesized in the middle silk gland of the silkworm, and constitutes 25–30% of silk protein.<sup>1)</sup> Its molecular weight ranges widely, from about 10 to over 400 kDa.<sup>1,2)</sup> Lower molecular weight sericin peptides ( $\leq 20$  kDa) are soluble in cold water and can be recovered during early stages of raw silk production, while high-molecular weight sericin peptides ( $\geq 20$  kDa) are soluble in hot water and can be obtained in the later stages of silk processing or during process of silk degumming.<sup>1)</sup> Sericin consists of about 30% serine, which is the main amino acid of natural moisture factor (NMF) in human skin.<sup>3,4)</sup> This amino acid makes sericin an excellent moisturizing

agent.<sup>1,3,5)</sup> Besides this property, sericin also has antibacterial, antioxidant, anticancer, and UV-light protecting activity.<sup>1,2,6–8)</sup>

In 2005, Tsubouchu *et al.* showed that sericin enhances the attachment of primary cultured human skin fibroblasts.<sup>9)</sup> Silk fibroin, as a component of spongy sheets, can also accelerate wound healing in rats by facilitating collagenization, as demonstrated by Yeo *et al.*<sup>10)</sup> Moreover, fibroin membrane used as a wound dressing shows no toxicity or irritation.<sup>11)</sup> However, since sericin has more hydrophilic properties due to the presence of several hydroxyl groups, as compared to fibroin,<sup>12)</sup> as well as good compatibility and biodegradation,<sup>7)</sup> it may be a better candidate for wound-healing agent. Besides, smaller molecular weight peptides in sericin might enhance absorption through the wound and, more strongly facilitate than does fibroin.

In the present study, we evaluated the effects of sericin on wound healing and wound-size reduction in rats. Sericin cream was formulated using a petrolatum ointment base. We postulated that topical application of sericin cream would enhance wound healing and wound-size reduction in rats.

### Materials and Methods

**Materials.** Sericin powder was kindly supplied by Institute of Agricultural Technology, Suranaree University of Technology, Nakhon Ratchasima, Thailand. Petrolatum, mineral oil, lanolin, glycerin, bisabolol, propylparaben, and methylparaben were purchased from Sigma (Singapore), and were used without further purification. Betadine® (a 10% povidone-iodine solution) was purchased from a local drug store in Bangkok. All other chemicals were of extra-pure reagent grade and were used as received.

**Animals.** Eight week-old male Sprague-Dawley rats purchased from National Laboratory Animal Center of Mahidol University, Thailand, weighing  $250 \pm 5$  g, were used in the experiments. Each rat was caged alone at  $25 \pm 2$  °C and subjected to a 12:12 h light–dark cycle

<sup>†</sup> To whom correspondence should be addressed. Fax: +66-02-218-8403; E-mail: aramwit@gmail.com

(standard fluorescent light), and allowed chow and water *ad libitum*. The rats were acclimatized for 1 week before use. They were maintained according to the "Guide for the Care and Use of Laboratory Animals" established by National Laboratory Animal Center of Mahidol University, Thailand.

**Sericin cream preparation.** White petrolatum, mineral oil, lanolin, glycerin, bisabolol, propylparaben, and methylparaben were used to formulate a sericin cream base. For 8% sericin cream, sericin powder was dissolved in warm water and then mixed with other ingredients during cream-forming process.

**In vivo animal tests.** There were 18 rats in total, which were divided into two groups of nine each. Two full-thickness skin wounds in each rat were prepared by excision (1.5 × 1.5 cm) on the dorsum of each rat under aseptic surgery. In group 1, Betadine® was topically applied on left-side wounds (control wounds) and 8% sericin cream was topically applied on right-side wounds (treated wounds). Group 2, cream base (formula control wounds) and 8% sericin cream (treated wounds) were topically applied to left-side and right-side wounds respectively. Surgery was performed with the animal anesthetized with 30 mg/kg intramuscular injection of Zoletel, and Baytril® (enrofloxacin, Bayer, Germany), an anti-bacterial agent, at 10 mg/kg was also injected subcutaneously. The skin over the dorsal area was shaved completely and application fields were outlined with a marking pen just prior to skin excision. Rimadyle® (carprofen, Pfizer, USA) at 5 mg/kg was injected subcutaneously every 24 h for 5 d as pain reducer. All wounds were cleaned daily with sterile normal saline solution. Betadine®, cream base or sericin cream was applied to wounds daily after cleaning. All creams were applied evenly in sufficient amounts to cover all wound areas. The rats of each group were scrutinized for 15 d after application, during which the wound surfaces were observed. Body weights and skin irritations were observed daily. This protocol has been approved by Mahidol University Animal Care and Use Committee (MU-ACUC).

**Wound-size measurements.** All wounds were measured for area with a stereomicroscope (Carl Zeiss, Germany, Primo Star model, 0.3 × 0.65 objective lens), and photographed to Moticcamm 2300® at 1,024 × 768 pixels. Motic Images Plus 2.0 ML was used to analyze the data.

**Histological evaluations.** After 5, 10, and 15 d, three rats in each group were terminated and skin samples were taken. The central portion of underlying tissue was taken and fixed in 10% buffered formalin. Each specimen was embedded in a paraffin block and thin sections (3 μm) were prepared, and stained with hematoxylin-eosin, and Masson's trichrome method. Wound-healing

effects were examined histologically under a light microscope, an Olympus BX 50, using low-power magnification, at 200X and 100X.


**Statistical analysis.** All data were expressed as the mean ± SD. Evaluation of statistical significance was determined by paired and unpaired Student's *t*-test. A *p* < 0.01 was considered significant.

## Results and Discussion

The molecular weight of sericin powder was determined using prestained SDS-PAGE standards broad range and Bio-Rad® as markers. The results indicate that sericin powder contains peptides with molecular weights ranging from 90 to 125 kDa, as shown in Fig. 1. A study by Gamo *et al.* found that sericin is a complex mixture of 5–6 polypeptides differing widely in size (40–400 kDa).<sup>13)</sup> Normally, sericin solution without heat treatment exhibits distinct bands of three main sericin components at > 250, 180, and 100 kDa under SDS-PAGE,<sup>14)</sup> but sericin extracted by autoclaving method may show broader bands due to the mixture of different molecular weights peptides.

Regarding toxicity, 8% sericin cream, as well as cream base, showed no any of the toxicity in rats. All rats gained weight during the period of observation. The average weight during the period of observation in both groups did not differ significantly at the end of the study. No rats showed signs of anorexia, phlegmatic or titubant. Table 1 shows the average weight, body-weight gain, food consumption, and food efficiency ratio of rats in both groups during the experimental period. There was no statistically significant difference between body weights of rats in either group. Moreover, there was no rash or redness of the skin in sericin-treated wounds as compared to control wounds. These results indicate that sericin cream is safe and biocompatible. Besides, sericin-treated wounds healed almost completely without any allergic rash while wounds not treated with sericin still showed some inflammation.

The inflammatory reactions of the skin in sericin-treated wounds tended to be much smaller than those in the control throughout the inspection period. Figures 2 and 3 (A–D) show wound sizes from a group-2 rat treated with cream base and sericin cream on days 0, 5, 10, 15. During the first few days after operation, there was inflammation of wounds in all cases, but the wounds improved substantially from day 10 after treatment. All wound-area measurements were expressed as percentages of initial wound size. Table 2 data represent the percent of wound-size reduction of wounds in rats in both groups, recorded from post-wounding on days 5, 10, and 15. These results indicate that sericin-treated wounds in group-2 rats showed a statistically significant difference in percent of wound-size reduction as compared to cream base-treated wounds (*p* < 0.01), especially at 90% healing/d, but there was no statisti-

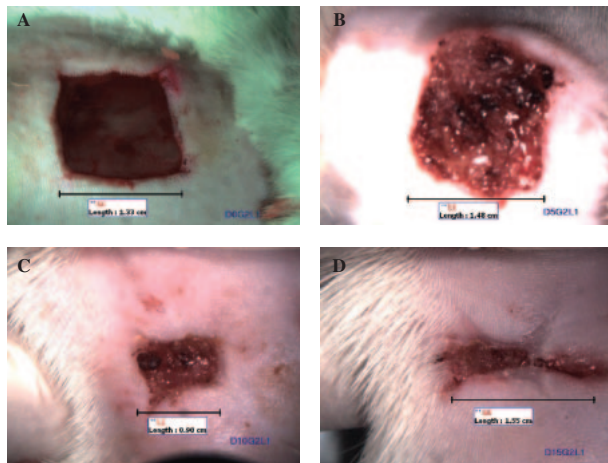


**Fig. 1.** Molecular Weight of Sericin by SDS-PAGE.

**Table 1.** Average Body Weight, Body Weight Gain, Food Consumption, and Food Efficiency Ratios of Rats of the Two Groups

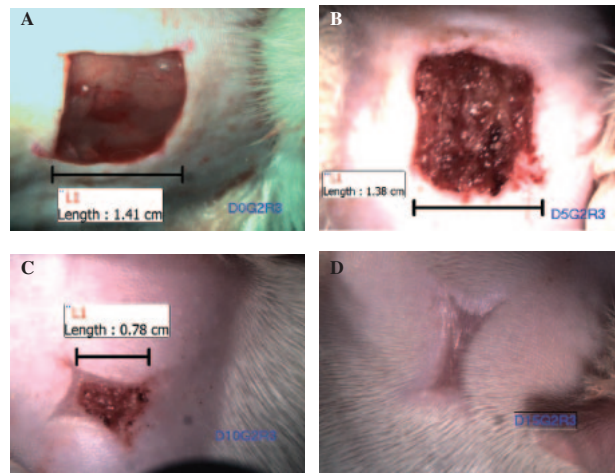
Parameters	Group 1	Group 2
Average initial body weight, g (n = 18)	249.60 ± 3.63	245.00 ± 5.54
Average body weight gain/d, g/d	5.42 ± 0.58	5.20 ± 0.33
Average food consumption, g/d	22.53 ± 1.74	24.09 ± 1.81
Average food efficiency ratio*	0.231 ± 0.02	0.225 ± 0.03

\*Food efficiency ratio = body weight gain/food consumption



**Fig. 2.** Wound Size, on Day 0 (A), 5 (B), 10 (C), 15 (D) from a Group-2 Rat, Treated with Cream Base.

cally significant difference in percent of wound-size reduction in control and sericin-treated wounds in group-1 rats. This might have been due to the antiseptic properties of Betadine®, which help to promote healing;<sup>15)</sup> these properties are not strongly present in sericin cream. Besides, the sample size of rats in each group was quite small. Further experiment will be performed with larger numbers of rats to eliminate individual variables.

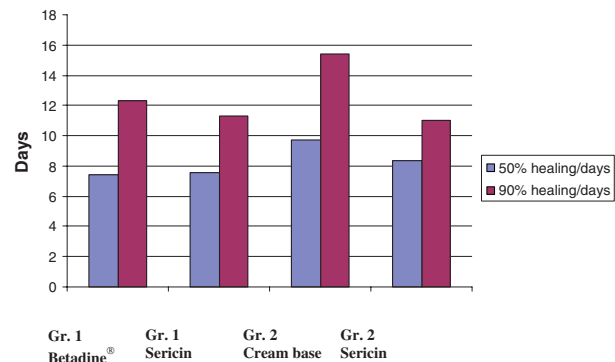


**Fig. 3.** Wound Size, on Day 0 (A), 5 (B), 10 (C), 15 (D) from a Group-2 Rat, Treated with Sericin Cream.

**Table 2.** Percent Wound Size Reduction in Rats of the Two Groups, Post-Wounding on Day 5, 10, and 15

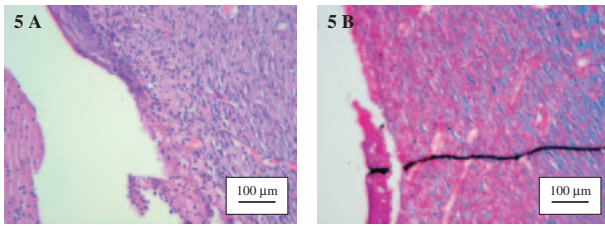
Day of observation	Wound-size reduction (%)			
	Group 1		Group 2	
	Control	Sericin	Cream base	Sericin
5 (n = 3)	—	—	—	3.85 ± 15.50
10 (n = 3)	88.96 ± 1.84	79.72 ± 4.67	66.63 ± 16.41	67.03 ± 15.10
15 (n = 4)	95.37 ± 3.88	99.26 ± 1.48	91.70 ± 10.14	100.00 ± 0.00*

\*Significant difference at p = 0.01 by the Mann-Whitney U Nonparametric Test



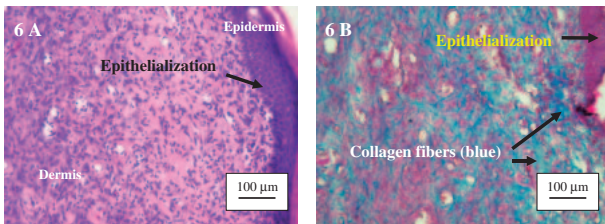
**Fig. 4.** Effect of Sericin Cream on Time to Achieve 50% and 90% Wound Healing in Rats.

The time taken for each animal's wound to be reduced by 50% and 90% of its initial size was also calculated. Ninety percent healing was chosen as our end-point, since healing of the remainder of the wound to completion is generally variable and dependent upon other factors such as animal interference. Time to achieve 50% and 90% wound healing is shown in Fig. 4. Mean time in days for 90% healing from sericin-treated wounds was much less than from cream base-treated wounds (11 vs 15 days).



**Fig. 5.** Histological Appearance of Left-Side Wound from a Group-1 Rat, Treated with Betadine<sup>®</sup>, 15 d after Treatment.

The skin sample was stained with hematoxylin-eosin (A) and Masson's trichrome (B); 200X.



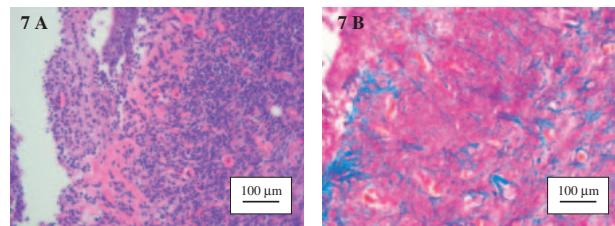
**Fig. 6.** Histological Appearance of Right-Side Wound from a Group-1 Rat, Treated with 8% Sericin Cream, 15 d after Treatment.

The skin sample was stained with hematoxylin-eosin (A) and Masson's trichrome (B); 200X.

Histological examinations of a wound from a group-1 rat on day 15 after treatment are shown in Figs. 5 and 6. As illustrated in Fig. 5, the left-side wound (control, treated with Betadine<sup>®</sup>) was not fully epithelialized, and some ulcers were present. Unevenness of epidermis near the ulcer was observed, collagen decreased, and there was greater inflammation than in the right-side wound or sericin-treated. Masson's trichrome stains collagen and yields a blue color, while the red color represents cytoplasm, red blood cells, and muscle. The pattern of staining intensity corresponds to the relative quantity of collagen-fiber deposit, which reflexes the process of synthesis and degradation and remodeling as well as the timing of the lesion. Persistent injury causing inflammation is another factor that interferes with collagen formation and deposition. More than 70% of wounds treated with sericin cream showed complete healing from day 10 of treatment. Figure 6 represents histological results from a right-side wound treated with sericin cream. The surface of epidermis became even. These results show complete healing, no ulceration, and an increase in collagen.

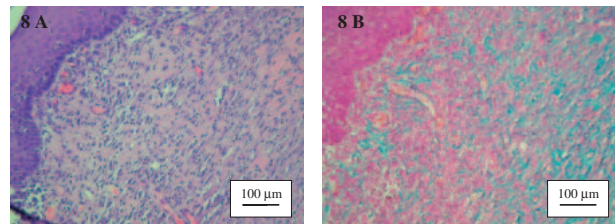
Masson's trichrome stain of healed scars, which stains blue on collagen fibers as a major component of connective tissue, shows dense collagen in sericin-treated wounds. Collagen is the most common protein in animals and ultimately provides the tensile strength of healing in wounds.<sup>10,16</sup> Also, sericin promotes epidermis growth, as shown by full recovery of the epidermis to its normal thickness in all sericin-treated wounds.

To see the effects of cream base on wound healing, cream base and 8% sericin cream were applied on left



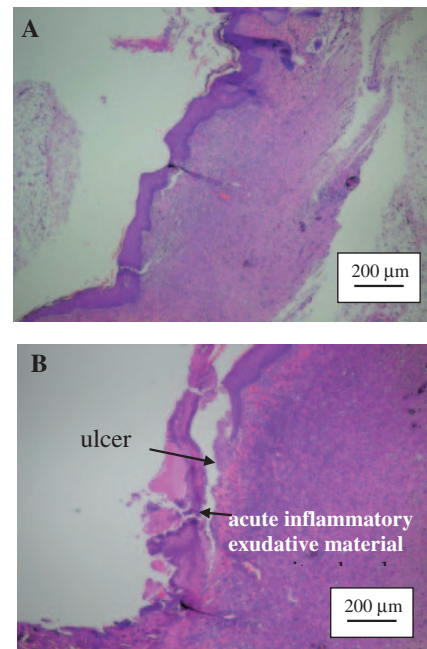
**Fig. 7.** Histological Appearance of Left-Side Wound from a Group-2 Rat, Treated with Cream Base, 15 d after Treatment.

The skin sample was stained with hematoxylin-eosin (A) and Masson's trichrome (B); 200X.



**Fig. 8.** Histological Appearance of Right-Side Wound from a Group-2 Rat, Treated with 8% Sericin Cream, 15 d after Treatment.

The skin sample was stained with hematoxylin-eosin (A) and Masson's trichrome (B); 200X.



**Fig. 9.** Histological Appearance of Right-Side Wound from a Group-2 Rat, Treated with 8% Sericin Cream (A) and Left-Side Wound Treated with Cream Base (B), 15 d after Treatment; 100X.

and right-side wounds respectively. Figures 7 and 8 show histological results for skin samples of a group-2 rat after 15 d of treatment with cream base and 8% sericin cream, on left and right-side wounds respectively. Left-side wounds (Fig. 7) showed some ulceration and more inflammation than did right-side wounds

(Fig. 8). Unevenness of the epidermis near ulcers was also observed on the cream base-treated side. Sericin-treated wounds, on the other hand, showed an increase in collagen.

The histology at 100X of left and right-side wounds of a group-2 rat is shown in Fig. 9. The sericin-treated wound showed complete healing (Fig. 9A), while the cream base-treated wound displayed some ulceration and acute inflammatory exudative material covering the ulcers (Fig. 9B).

## Conclusion

All these results suggest that sericin has wound-healing effects without causing allergic reactions, but the molecular weight of this protein fraction might affect its healing property. Further investigation should be done of the absorption and wound-healing effects from different molecular weights of sericin.

## Acknowledgments

We would like to thank Dr. Phaibul Punyarit of the Department of Pathology, Phramongkutkloa College of Medicine, Bangkok for histological analysis, and Professor Titinun Auamnoy of the Department of Pharmacy Administration for his assistance with statistical analysis.

## References

- Zhang, Y. Q., Applications of natural silk protein sericin in biomaterials. *Biotechnol. Adv.*, **20**, 91–100 (2002).
- Kato, N., Sato, S., Yamanaka, A., Yamada, H., Fuwa, N., and Nomura, M., Silk protein, sericin, inhibits lipid peroxidation and tyrosinase activity. *Biosci. Biotechnol. Biochem.*, **62**, 145–147 (1998).
- Nagura, M., Ohnishi, R., Gitoh, Y., and Ohkoshi, Y., Structures and physical properties of cross-linked sericin membranes. *J. Insect Biotechnol. Sericol.*, **70**, 149–153 (2001).
- Kurioka, A., Kurioka, F., and Yamazaki, M., Characterization of sericin powder prepared from citric acid-degraded sericin polypeptides of the Silkworm, *Bombyx Mori. Biosci. Biotechnol. Biochem.*, **68**, 774–780 (2004).
- Cho, K. Y., Moon, J. Y., Lee, Y. W., Lee, K. G., Yeo, J. H., Kweon, H. Y., Kim, K. H., and Cho, C. S., Preparation of self-assembled silk sericin nanoparticles. *Int. J. Biol. Macromol.*, **32**, 36–42 (2003).
- Zhaorigetu, S., Yanaka, N., Sasaki, M., Watanabe, H., and Kato, N., Inhibitory effects of silk protein, sericin, on UVB-induced acute damage and tumor promotion by reducing oxidative stress in the skin of hairless mouse. *J. Photochem. Photobiol. B: Biol.*, **71**, 11–17 (2003).
- Tao, W., Li, M., and Xie, R., Preparation and structure of porous silk sericin materials. *Macromol. Mater. Eng.*, **290**, 188–194 (2005).
- Tamada, Y., Sano, M., Niwa, K., Imai, T., and Yoshino, G., Sulfation of silk sericin and anticoagulant activity of sulfated sericin. *J. Biomater. Sci. Polym. Ed.*, **15**, 971–980 (2004).
- Tsubouchi, K., Igarashi, Y., Takasu, Y., and Yamada, H., Sericin enhances attachment of cultured human skin fibroblasts. *Biosci. Biotechnol. Biochem.*, **69**, 403–405 (2005).
- Yeo, J. H., Lee, K. G., Kim, H. C., Oh, Y. L., Kim, A. J., and Kim, S. Y., The effects of PVA/chitosan/fibroin (PCF)-blended spongy sheets on wound healing in rats. *Biol. Pharm. Bull.*, **23**, 1220–1223 (2000).
- Wu, C., and Tian, B., Properties and applications of wound-protective membrane made from fibroin. Proceedings of the Third International Silk Conference, China, Suzhou (1996).
- Kweon, H. Y., and Cho, C. S., Biomedical applications of silk protein. *Int. J. Indust. Entomol.*, **3**, 1–6 (2001).
- Gamo, T., Inokuchi, T., and Laufer, H., Polypeptides of fibroin and sericin secreted from different sections of the silk gland in *Bombyx mori*. *Insect Biochem.*, **7**, 285–295 (1977).
- Takasu, Y., Yamada, H., and Tsubouchi, K., Isolation of three main sericin components from the cocoon of the silkworm, *Bombyx mori*. *Biosci. Biotechnol. Biochem.*, **66**, 2715–2718 (2002).
- Muller, M., Hollyoak, M., Moaveni, Z., Brown, T. L., Herndon, D., and Heggers, J., Retardation of wound healing by silver sulfadiazine is reversed by aloe vera and nystatin. *Burns*, **29**, 834–836 (2003).
- Tabata, Y., Lonikar, S., Horii, F., and Ikada, Y., Immobilization of collagen onto polymer surfaces having hydroxyl groups. *Biomaterials*, **7**, 234–238 (1986).