

The effects of swimming exercise and supraphysiological doses of nandrolone decanoate on the testis in adult male rats: a transmission electron microscope study

M.A. Naraghi¹, F. Abolhasani¹, I. Kashani¹, I.J. Anarkooli², M. Hemadi³,
A. Azami¹, M. Barbarestani¹, R.J. Aitken⁴, S. Shokri²

¹Anatomy Department, School of Medicine, Tehran University of Medical Sciences, Tehran, Iran

²Anatomy Department, School of Medicine, Zanjan University of Medical Sciences, Zanjan, Iran

³Anatomy Department, School of Medicine, Ahvaz University of Medical Sciences, Ahvaz, Iran

⁴ARC Centre of Excellence in Biotechnology and Development, Discipline of Biological Sciences, University of Newcastle, NSW, Australia

[Received 4 April 2010; Accepted 14 May 2010]

Anabolic-androgenic steroids (AAS) are used in high doses by athletes to improve athletic ability, physical appearance, and muscle mass. Unfortunately, the abuse of these agents has significantly increased. It has been established that exercise and high doses of AAS may influence the hypothalamic-pituitary gonadal (H-P-G) axis, which can in turn affect the ultrastructure of the testes. However, the effect of the combination of exercise and high doses of AAS on the ultrastructure of the testes is not known. This study was undertaken in order to examine the combination effects of swimming exercise and supra-physiological doses of nandrolone decanoate on the ultrastructural changes in rat testes. Five groups of male Wistar strain albino rats were treated as follows for 8 weeks: solvent of nandrolone decanoate (peanut oil) as a vehicle (sham); nandrolone decanoate (ND) (10 mg/kg/week) — ND; exercise (1 h/day, 5 days a week) — exercise; ND (10 mg/kg/week) and exercise (1 h/day, 5 days a week) — ND-EX; and sedentary control without any injection or exercise — control. Ultrastructural changes in the rat testes were characterised by transmission electron microscopy. The number and size of Leydig cells were considerably decreased in the interstitial space in the experimental rats. The increased thickness and irregular wavy multilaminar appearance of basement membrane in the treated animals, especially in the ND-EX group, are associated with well developed myoid cells. Cytoplasm vacuolisation, vesicular-like crista of the mitochondria, numerous lipid droplets, and lysosome and phagolysosome in Sertoli cells were significantly observed in the experimental groups. Several apoptotic germ cells were considerably observed in the experimental rats ($p \leq 0.05$). Exercise training seems to increase the extent of ultrastructural changes caused by supra-physiological doses of ND in rats, which in turn may affect fertility. (Folia Morphol 2010; 69, 3: 138–146)

Key words: exercise, nandrolone decanoate, testis, transmission electron microscope

INTRODUCTION

Anabolic-androgenic steroids (AASs) are synthetic derivatives of testosterone and are important pharmacologically for their use in the treatment of various medical conditions such as growth deficiency, some blood disorders, osteoporosis, hypogonadal dysfunction and the commencement of delayed puberty in men, and growth promotion [4, 7, 23]. However, AASs have not always been used purely for medical purposes [23]. Due to their anabolic effects, AASs became vastly popular among bodybuilders, power lifters and both male and female professional athletes, recreational athletes, prepubescent, and adolescents [7, 23]. Most recently, AAS use has filtered through to “recreational street drug” users and is the fastest growing drug group in this subdivision [9]. These people use such compounds in excess of therapeutic doses (10- to 100-fold) by administration of a single type or a mixture of several AASs, with little or no regard for the consequences [4]. AASs seem to be appealing to abusers because when taken in conjunction with exercise, they increase muscle mass and strength, and increase libido [7, 23]. Abuse of AASs may be an aetiological factor in male infertility among recreational power athletes. In men the effects of intensive exercise training combined with high doses of AAS on reproductive function have not been thoroughly investigated. In fact, most authors have focused only on hormonal indices of male reproductive function and less attention has been directed toward ultrastructural changes in testis. AASs and endurance exercise might induce some subclinical alterations in the hypothalamic-pituitary gonadal (H-P-G) axis. Such changes include primarily a reduction in circulating levels of total and free testosterone as well as luteinising hormone (LH) [7]. These effects result from negative feedback of androgens on the H-P-G axis. However, the combined effects of exercise training and supraphysiological doses of exogenous androgens on the ultrastructure of testes have not been investigated. This study was undertaken in order to examine the combination effects of swimming exercise and supraphysiological doses of nandrolone decanoate on the ultrastructural changes in rat testes.

MATERIAL AND METHODS

Chemicals

Nandrolone decanoate (ND) (25 mg/mL) was purchased from the Iran Hormone Company (Tehran,

Iran). Epoxy resin araldite CY212 was purchased from TAAB Laboratories, Berks, UK.

Animals

The animals were maintained according national guidelines and protocols as approved by the National Institute of Health Guide (National Institute of Health Publications No. 80-23, Revised 1978). Healthy adult male albino rats of Wistar strain from an in-house breeding colony, weighing 170–200 g (90 days old), were randomly selected from the Laboratory Animal Centre of Tehran University of Medical Sciences. The animals were housed in a specific pathogen-free environment and well-ventilated animal house. After 1-week acclimatisation they were placed in clean polycarbonate cages under a 12 h: 12 h Light: Dark cycle with a room temperature of $22 \pm 2^\circ\text{C}$. The rats were fed a standard laboratory diet (Pars dam factory; Tehran, Iran) and clean drinking water was made available ad libitum.

Exercise procedure

In this study, swimming was considered a suitable model of endurance exercise training, since swimming is a natural behaviour among rodents and it is a widely used exercise model [22]. The swim training included two phases: adaptation and training. The adaptation phase consisted of the first 6 days of training. On the first day, the animals exercised in the pool for ten minutes. The exercise period was extended by ten minutes each day until the rats were swimming for sixty minutes. The training phase consisted of five sixty-minute sessions per week for eight weeks (between 11:00–13:00 h on each training day). All the animals were able to swim for the whole sixty minutes [17]. Exercise was performed by swimming in glass tanks (length 100 cm, width 50 cm, depth 50 cm) containing tap water maintained at $32\text{--}34^\circ\text{C}$. A maximum of six rats were allowed to swim together. ND injection and exercise periods were selected according to the spermatogenesis period in rats. The period of spermatogenesis in rats is approximately 48–56 days [14]; therefore, 8-week ND injection (56 days) seemed to be a reasonable period for assaying of spermatogenesis.

Treatment

The rats were randomly divided into five different groups of 7 animals each. Group A (sham) rats received the solvent of ND (peanut oil) as a vehicle; group B (ND) received 10 mg/kg/week of nandrolone-

ne decanoate for 8 weeks; in group C (exercise) the exercise protocol was employed for 1 hour of continuous swimming per day, 5 days a week for 8 weeks [10, 17, 22]; group D (ND-EX) received 10 mg/kg/week of ND and the exercise protocol was employed for 1 hour of continuous swimming per day, 5 days a week for 8 weeks; and group E (control) were without any injection or exercise protocol. The vehicle and ND were injected intramuscularly to the gluteal region once every week.

Laboratory studies

The rats were anaesthetised with a mixture of ketamine (45 mg/kg) and xylazine (35 mg/kg) intraperitoneally. Both testes were quickly removed and cut.

TEM procedure

A 1–2 mm cube of testicular tissue was fixed in a mixture of 1% paraformaldehyde and 2.5% glutaraldehyde buffered with 0.1 mol/L sodium cacodylate containing 3 mmol/L calcium chloride, pH 7.4. (EM fluid) for 24 h, washed with sodium cacodylate-buffered saline, and post-fixed in 1% osmium tetroxide and again washed with sodium cacodylate-buffered saline. After en block staining, the tissue was dehydrated in graded ethanol solutions and was embedded in a mixture of equal amounts of epoxy resin araldite CY212 and dodecyl succinic anhydride in 0.2% DMP 30 (TAAB Laboratories, Berks, UK), and incubated at 60°C overnight to make the resin blocks. Sections 1 μ m thick were cut and placed on glass slides and stained with toluidine blue to select the representative areas (seminiferous tubules). Ultrathin sections around 60–90 nanometer were cut and taken on a copper grid and stained with a mixture of uranyl acetate and lead citrate, then viewed by transmission electron microscopy (TEM) (Philips CM10, Holland). The sections were photographed and the prints assessed in a single sitting.

To distinguish different testicular cell types, the following ultrastructural morphological characteristics were used. Spermatogonia are located on the basal lamina of the seminiferous tubules. Type A spermatogonia were identified as cells with an ovoid nucleus with the nucleoli close to the nuclear membrane. The electron-dense cytoplasm contained a small Golgi apparatus, few mitochondria, and many free ribosomes. Type B spermatogonia were identified by having a more rounded nucleus and heavily stained chromatin masses attached to the nuclear membrane or to the nucleoli, located at the centre of the nucleus. Sertoli cells were recognised by their

location on the basal laminae of the tubuli, by their extension to the lumen of the tubule, and by their large, deeply indented nucleus with a homogeneous nucleoplasm and a prominent nucleolus. The cytoplasm contained oval mitochondria, a small Golgi apparatus, an agranular endoplasmic reticulum, lipid droplets, and primary and secondary lysosomes. Leydig cells were found in the stroma between the tubules. The cytoplasm of the Leydig cells contained a high number of mitochondria, an agranular endoplasmic reticulum, varying numbers of lipid droplets, and occasionally some protein crystals.

The ultrathin sections were studied in the following categories: (1) Seminiferous tubules: basement membrane (BM); Spermatogenic series: various stages of maturation, sperm count, and sperm morphology; Sertoli cells: number, size, and organelles; (2) Extracellular matrix (ECM); and Leydig cells. Features of degeneration were fragmentation of the cell membrane, disorganisation of the organelle, intracellular oedema, disruption of the endoplasmic reticulum (ER), and rarefaction of mitochondria. The vacuolar and degenerative changes were graded according to the percentage of cells involved as follows: grade 0: < 1% of cells; grade 1: 1–25%; grade 2: 25–50%; grade 3: > 50% of cells affected. Apoptosis was similarly graded as follows: grade 0: < 1%; grade 1: 1–5%; grade 2: 6–10%; grade 3: > 10% of cells. Cell numbers were graded as follows: grade 0: normal; grade \pm 1: 25–50% increase or decrease; grade \pm 2: 50–75% increase or decrease; grade \pm 3: > 75% increase or decrease. Thickening of the BM was graded as 0: BM thickness in control rats (taken as normal range); 1: 25–50%; 2: 50–75%; 3: > 75% increase.

Statistical analysis

Kruskal-Wallis and Wilcoxon rank-sum tests were used to analyse the statistical significance of differences in parameters between the control testes and the experimental groups separately. A p-value less than 0.05 was taken to be statistically significant.

RESULTS

Testicular interstitium

Light microscopy of the interstitial tissue in the control and sham rats showed normal appearance and contained Leydig cells, blood vessels, and fibroblasts. The Leydig cells had spherical and oval nuclei. In the experimental groups, especially in the ND-EX group, less Leydig cells, blood vessels, and

fibroblasts were observed and the interstitial spaces were wider. The study of interstitium using an electron microscope revealed a great abundance of lipid droplets in Leydig cells in the sham and control animals, as well as a great number of mitochondria with well-developed cristae. Tubular and vesicular smooth ER was distributed throughout the cytoplasm in both the control and sham groups (Fig. 1F). Contrary to control and sham animals, more pyknotic and apoptotic Leydig cells associated with vacuolated cytoplasm were seen in the treated animals, especially in the ND-EX group (Fig. 1E).

Testicular epithelium

At the light microscopic level, the seminiferous tubules showed a normal arrangement and population of cellular components of germ cells and Sertoli cells in the control and sham animals (Fig. 1A). In comparison with the control and sham groups, the seminiferous epithelium of the treated animals was disrupted with broad spaces between the cellular components showing the presence of copious vacuoles frequently associated with degenerating germ cells (Fig. 1B and Table 1). Ultrastructural analysis of the seminiferous epithelium revealed that the thickness of the BM in the ND and ND-EX rats were increased with irregular wavy multilaminar appearance, compared with the control and sham groups (Fig. 1C, D and Table 1). Collagen fibres were increased in both the ND and ND-EX groups (Fig. 1C, D). Well developed myoid cells covered the BM of seminiferous tubule in all groups; however, pyknotic nuclei were observed in few myoid cells in the ND-EX rats. Sertoli cells with triangular nuclei and apical invaginations were observed in all the animals, and basolateral invaginations were observed in the treated rats. In contrast to the control and sham animals, lysosome and phagolysosome and more abundant lipid droplets were present in the cytoplasm of Sertoli cells in the treated groups (Fig. 1G, H and Table 1). The mitochondria of Sertoli cells were distinct and possessed vesicular and vacuolar cristae (Fig. 2C, D). Fine structural features of seminiferous epithelium revealed no morphological alterations in spermatogonia, spermatocytes, and spermatids in the control and sham animals. In addition, the spermatogonia were in contact with the BM (Fig. 1A and Table 2).

Compared with the control and sham animals, degenerated and small flat spermatogonia were seen in the treated animals (Fig. 2G and Table 2). Clumps of apoptotic spermatocytes were seen in the

treated animals, especially in the ND and ND-EX groups (Fig. 2A, B and Table 2). The nucleus of some spermatocytes had more prominent clumps of chromatin (Fig. 2H). The spermatids in the ND-EX group contained more vesicles and vacuoles and some dense bodies (Fig. 2E, F and Table 1).

DISCUSSION

The results of the present study show a remarkable decrease in the number and size of Leydig cells and a depletion of intact cells in treated animals, especially in the ND and ND-EX groups. These results were consistent with Feinberg et al. [7], who found pyknotic and severe depletion of Leydig cells following treatment by AASs. The close relationship between Leydig cells and blood vessels suggests that these cells are at high risk of exogenous toxicants, and multivacuolated Leydig cells are probably a form of cell involution. Leydig cells are known to have receptors for LH that stimulate these cells to produce testosterone. Both LH and testosterone are responsible for normal spermatogenesis in male rats [26]. Therefore, depletion of LH receptors and a decrease in peripheral LH by exogenous testosterone administration result in a reduction of testosterone secretion [13].

The BM plays an important role in maintaining the structural and functional integrity of tissues [18]. It provides structural stability of organs and sends signals to cells through cell surface receptors [15]. Altered BM structure has been associated with severe functional impairment of the testis [18]. The BM contains several proteins including laminin, type IV collagen, various heparin sulphate proteoglycans, and ectatin/nidogen [6]. Type IV collagen is a major constituent of mammalian BM that has been localised in both the inner and the outer ECM layers of the BM of seminiferous tubules [15]. This collagen is secreted by myofibroblasts and Sertoli cells [21]. In the present study, the increased thickness and irregular wavy multilaminar appearance of BM in the treated animals, especially in the ND-EX group, are associated with well developed myoid cells. Some reports have demonstrated that exogenous stimulants, such as AASs, affect myoid cells to produce more type IV collagen, fibronectin, and ECM, which is responsible for basal lamina thickness [20]. Interactions between Sertoli cells, peritubular myoid cells, Leydig cells, and germ cells are thought to be essential for spermatogenesis. Each of these interactions must be communicated through the ECM of the BM. Many reports have demonstrated that over-

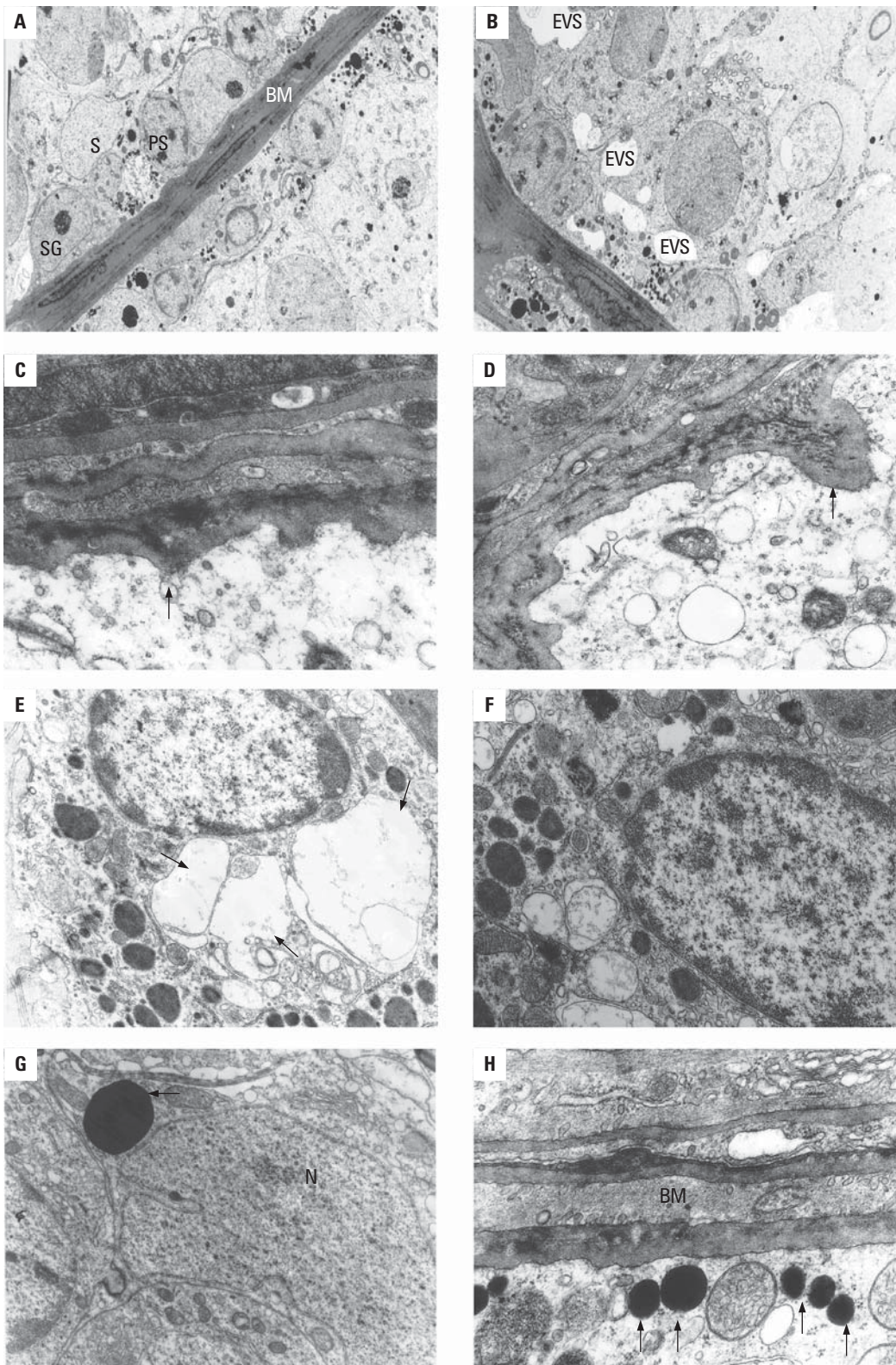


Figure 1. Electron micrograph image (TEM) of rat testes from: **A.** ($\times 4000$) the control group showing normal basement membrane (BA), primary spermatocytes (PS), spermatogonia (SG), and Sertoli cell (S); **B.** ($\times 5000$) animals in the ND-EX group, showing empty vacuolar spaces (EVS) in the Sertoli and spermatocyte cells. Signs of inflammatory damage of testicular tissue in the form of irregular and thickened basal lamina (\rightarrow) in the ND — **C.** ($\times 11000$) and ND-EX groups — **D.** ($\times 13000$), cytoplasmic vacuolation (\rightarrow) in the Leydig cells in the ND-EX group — **E.** ($\times 12000$) in comparison with normal Leydig cells in the control group — **F.** ($\times 15000$), lipid droplets (\rightarrow) in Sertoli cells (N — Sertoli nucleus) in the ND — **G.** ($\times 22000$) and ND-EX groups — **H.** ($\times 23000$); BM — basement membrane.

Table 1. Changes observed in rat testes by transmission electron microscopy

Groups	Control	ND	EX	ND + EX
Seminiferous tubules				
Basement membrane thickening	Normal	Diffuse 2+ rarefaction	Mild, focal, 1 + rarefaction	Diffuse, 2+ to 3+
Spermatogenesis	Normal	Focal degeneration single cell apoptosis sperm count mildly decreased	Focal degeneration single cell apoptosis sperm count mildly decreased	Marked degeneration Clumped apoptosis cells All counts reduced
Sertoli cells	Normal	Increased size Increased lipid droplets	Mild increase in size Mild increased lipid droplets	Increased size Increased lipid droplets
Extracellular matrix	Normal	Increased deposit	Mild increase	Increased protein deposit
Leydig cells	Normal	Normal	Normal	Single cell apoptosis
Inflammatory cells	Absent	Absent	Absent	Absent

ND — nandrolone decanoate, EX — exercise

Table 2. Ultrastructural changes in testes

Groups	Control rats	Sham rats	ND rats	EX rats	ND + EX rats
Seminiferous tubules					
1. Basement membrane thickening	0	0	2 (Gr. 2)	1 (Gr. 2)	7 (Gr. 2) ^a
2. Spermatogonia					
Decreased numbers	0	0	1 (Gr. 1)	1 (Gr. 1)	5 (Gr. 2) ^a
Degeneration	0	0	2 (Gr. 1)	1	3 (Gr. 2) ^a
Vacuolation	0	0	1 (Gr. 1)	0	3 (Gr. 2) ^a
Apoptosis	4 (occasional)	3 (occasional)	6 (single) ^a	3 (single)	7 (single) ^a
3. Spermatocytes					
Decreased numbers	0	0	1 (Gr. 1)	1 (Gr. 1)	3 (Gr. 1) ^a
Degeneration	0	0	2 (Gr. 1) ^a	1	5 (Gr. 3) ^a
Vacuolation	0	0	1 (Gr. 1)	0	1 (Gr. 2)
Apoptosis	4 (occasional)	3(occasional)	6 (clumps) ^a	5 (single)	7 (clumps) ^a
4. Spermatids					
Decreased numbers	2 (mild)	2 (mild)	4 (moderate) ^a	1 (mild)	2 (mild), 5 (moderate) ^a
Abnormal morphology	0	0	2 (tail/head) ^a	0	4 (head) ^a
5. Sertoli cells					
Increased cell number	2	1	1	2	2
Increased cell size	0	0	5 ^a	0	7 ^a
Increased lipid droplets	2	2	5 ^a	1	7 ^a
Leydig cell number increase	0	0	0	0	2
Extracellular matrix thickness	0	0	5 ^a	0	7 ^a

^aWilkinson rank-sum test; $p < 0.05$ statistically significant; ND — nandrolone decanoate, EX — exercise

expression of the subtypes of type IV collagen correlates with abnormally thickened BM and is related to spermatogenic dysfunction in humans and

other mammals [6, 11, 20, 25]. Among the testicular epithelium two major changes were noticed in the Sertoli cells and in their vicinity. One was the pre-

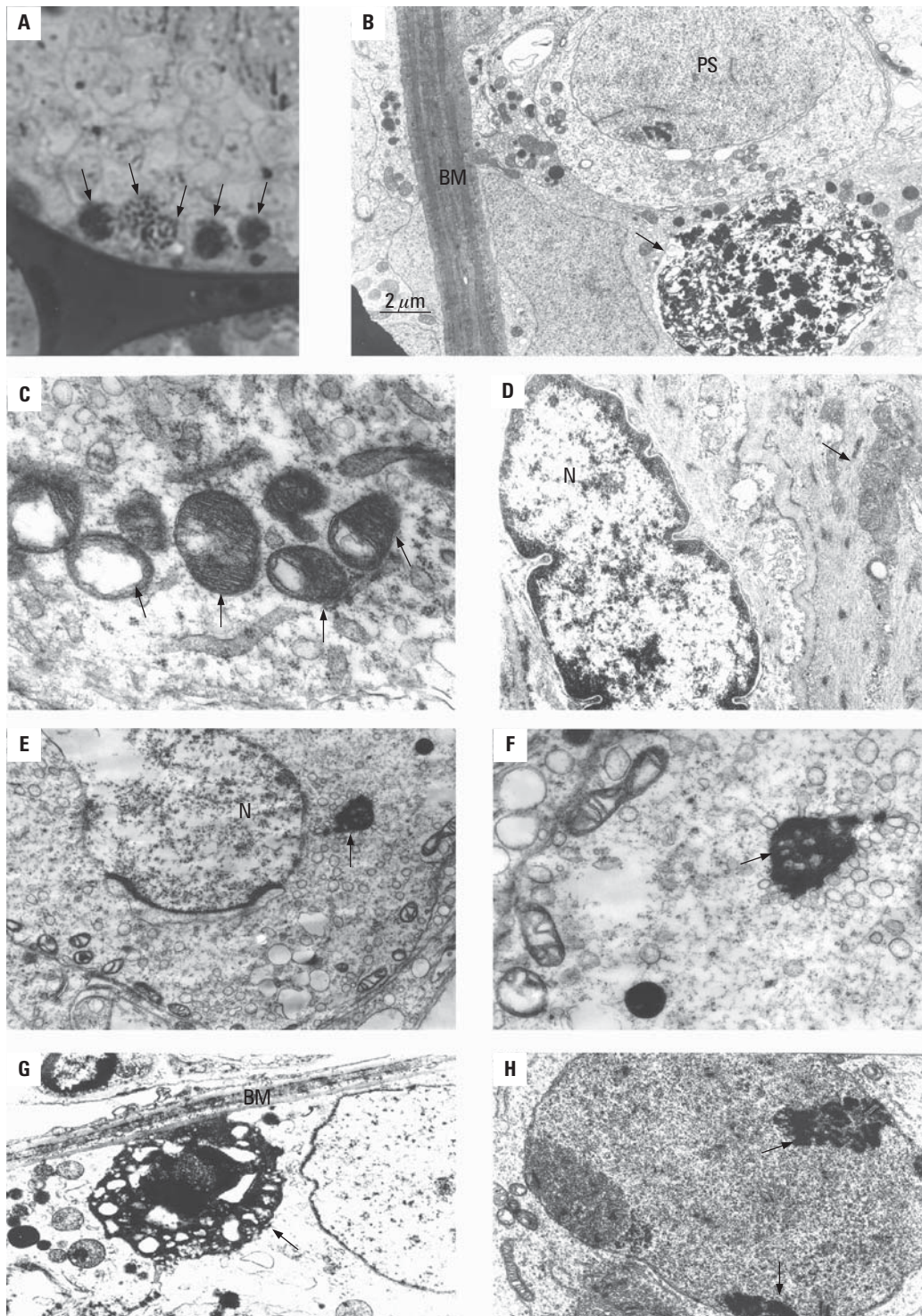


Figure 2. Spermatogenic cell apoptosis (TEM) analyses of testis cross-sections from the ND-EX group, 400 × magnification: The representatives TEM semithin (A) and TEM ultrathin (B) sections demonstrate increased germ cell apoptosis (arrows) in sections from the ND-EX rats; BM — basement membrane, PS — primary spermatocyte. Vacuoles in the mitochondria of Sertoli cells (→) in the ND-EX group — C. (×30000) in comparison with normal mitochondria of Sertoli cells (N — Sertoli nucleus) in the control group — D. (×17000), dense body in the cytoplasm of spermatid cells (N — spermatid nucleolus) in the ND-EX group — E. (×25000), F. (×45000), degenerated cell (→) near the basement membrane (BM) in the ND-EX group — G. (×30000), dense clumped marginal chromatin (→) in primary spermatocytes in the ND-EX group — H. (×35000).

sence of cytoplasm vacuolisation: vesicular-like crista of the mitochondria, numerous lipid droplets, and lysosome and phagolysosome in the Sertoli cells of ND and ND-EX rats. These are in agreement with the reports showing that exogenous stimulants may cause progressive apoptosis of the Sertoli cells, which affect spermatogenesis and sperm parameters [8]. The second major change was the empty vacuolar spaces between the Sertoli cells that are thought to be the place where spermatogonia and spermatocytes should be located.

In addition, the results of the present study show that apoptosis occurred in all germline cells, especially in spermatogonia and spermatocytes. The presence of apoptotic germ cells in this study is supported by Blanco et al. [2], who described apoptosis in hamster testis following treatment with AASs. However, Feinberg et al. [7] showed apoptosis only in the Leydig cells following testosterone propionate treatment in rats. Spermatogenesis is a complex and dynamic process that results in the continual production of spermatozoa in mammals. The Sertoli cells are largely responsible for orchestrating the germ cells through sequential phases of mitosis, meiosis, and differentiation. The Sertoli cells accomplish this task by providing hormonal, nutritional, and physical support. The apoptosis of germ cells that occurs in the testicular epithelium serves as a mechanism to reduce the germ cell population to the level that the Sertoli cells can support. Drugs such as AASs that injure or disrupt the function of Sertoli cells can effectively reduce their supportive roles and result in an increase in the elimination of the germ cell numbers via apoptosis [19]. Also, it has been shown that apoptosis in the germ cells is related to the Fas signalling system, which is activated by exogenous toxicants [19]. Observation of detached germ cells, amorphous head sperm, and missed location of spermatids and spermatozoa that are closely related to the BM in this study may be due to the rapid disruption of the Sertoli germ cell interaction. This physical interaction ultimately leads to the sloughing of the germ cells from the seminiferous epithelium [19]. It seems that the spermatogenesis cycle is reduced due to the presence of high levels of androgens. On the other hand, some researchers believe that exercise increases the oxygen consumption rate by 10- to 20-fold, resulting in an enhanced production of reactive oxygen species (ROS) in the cells/tissues, and exerts oxidative stress (OS), which increases the rate of cellular damage [5]. Pey et al. [16] showed that prolonged stanozolol treatment as an AAS can cause an oxidative stress situation in rat liver. Chaves et al. [3]

indicated that chronic treatment with ND causes an impairment of exercise induction of antioxidant enzyme activities, leading to reduced cardioprotection upon ischaemic events. Therefore, it seems logical that the physical/chemical-induced oxidative stress may affect the testicular antioxidant system and lipid peroxidation in rats [12]. OS has been shown to be a major cause of male infertility; a large proportion of infertile men have elevated levels of seminal ROS. Several forms of sperm DNA damage are caused by ROS, e.g. chromatin cross-linking, chromosome deletion, and DNA strand breaks (Apoptosis). Under physiological conditions, apoptosis maintains the number of germ cells within the supportive capacity of Sertoli cells. However, disturbances in this pathway can interrupt the spermatogenic cascade. High levels of apoptosis were detected at spermatogenic stages where major developmental blocks occur, and frequencies of DNA damage were higher in less mature germ cells [24]. The present study showed that exercise training seems to increase the extent of apoptotic changes caused by supraphysiological doses of ND treatment on the testis of rat (Fig. 2, Table 1, 2). Recent studies have shown that exercise training enhances antioxidant enzyme activity and reduces lipid peroxidation in vital tissues of animals [1]. However, the testes contain a low amount of antioxidant enzymes in comparison with other organs such as the liver and kidneys. The mitochondrial membrane of the testis is rich in polyunsaturated lipids [1] and the testes may actually be more vulnerable to peroxidative injury. Therefore, further experiments are needed to clarify the mechanisms of the effects of ND-EX treatment on germ cell apoptosis, and we suggest that other researchers measure the ROS and antioxidant enzymes of the testes after treatment with a combination of ND and exercise.

CONCLUSIONS

In conclusion, exercise training seems to increase the extent of apoptotic and ultrastructural changes caused by supraphysiological doses of ND treatment on the testis of the rat. All these findings indicate that there is a high degree of infertility risk associated with the use of a combination of ND and exercise.

ACKNOWLEDGEMENTS

The authors would like to thank Mr. Safavi for his assistance in the TEM histological process. This work was supported by a grant from the Vice-chancellor of Research, Tehran University of Medical Sciences.

REFERENCES

- Agarwal A, Said TM (2005) Oxidative stress, DNA damage and apoptosis in male infertility: a clinical approach. *BJU Int*, 95: 503–507.
- Blanco A, Flores-Acuna F, Roldan-Villalobos R, Montere JG (2002) Testicular damage from anabolic treatments with the beta(2)-adrenergic agonist clenbuterol in pigs: a light and electron microscope study. *Vet J*, 163: 292–298.
- Chaves EA, Pereira-Junior PP, Fortunato RS, Masuda MO, de Carvalho AC, de Carvalho FP (2006) Nandrolone decanoate impairs exercise-induced cardioprotection: role of antioxidant enzymes. *J Steroid Biochem Mol Biol*, 99: 223–230.
- Clark AS, Harrold AV, Fast AS (1997) Anabolic-androgenic steroid effects on the sexual behavior of intact male rats. *Horm Behav*, 31: 35–46.
- Davies KJ, Quintanilha AT, Brooks GA, Packer L (1982) Free radicals and tissue damage produced by exercise. *Biochem Biophys Res Commun*, 107: 1198–1205.
- Dobashi M, Fujisawa M, Naito I, Yamazaki T, Okada H, Kamidono S (2003) Distribution of type IV collagen subtypes in human testes and their association with spermatogenesis. *Fertil Steril*, 80: 755–760.
- Feinberg MJ, Lumia AR, McGinnis MY (1997) The effect of anabolic-androgenic steroids on sexual behavior and reproductive tissues in male rats. *Physiol Behav*, 62: 23–30.
- Gopalkrishnan K, Gill-Sharma MK, Balasinar N, Padwal V, D'Souza S, Parte P (1998) Tamoxifen-induced light and electron microscopic changes in the rat testicular morphology and serum hormonal profile of reproductive hormones. *Contraception*, 57: 261–269.
- Graham MR, Davies B, Grace FM, Kicman A, Baker JS (2008) Anabolic steroid use: patterns of use and detection of doping. *Sports Med*, 38: 505–525.
- Gündüz F, Sentürk UK, Kuru O, Aktekin B, Aktekin MR (2004) The effect of one year's swimming exercise on oxidant stress and antioxidant capacity in aged rats. *Physiol Res*, 53: 171–176.
- Häger M, Gawlik K, Nyström A, Sasaki T, Durbeej M (2005) Laminin $\alpha 1$ chain corrects male infertility caused by absence of laminin $\alpha 2$ chain. *Am J Pathol*, 167: 823–833.
- Husain K, Somani SM (1998) Interaction of exercise training and chronic ethanol ingestion on testicular antioxidant system in rat. *J Appl Toxicol*, 18: 421–429.
- Ichihara I, Kawamura H, Nakano T, Pelliniemi LJ (2001) Ultrastructural, morphometric and hormonal analysis of the effects of testosterone treatment on Leydig cells and other interstitial cells in young adult rats. *Ann Anat*, 183: 413–426.
- Kolasa A, Marchlewicz M, Wenda-Rozewicka L, Wiszniewska B (2004) Morphology of the testis and the epididymis in rats with dihydrotestosterone (DHT) deficiency. *Rocz Akad Med Białymst*, 49: 117–119.
- Martin GR, Timpl R (1987) Laminin and other basement membrane components. *Annu Rev Cell Biol*, 3: 57–85.
- Pey A, Saborido A, Blázquez I, Delgado J, Megías A (2003) Effects of prolonged stanozolol treatment on antioxidant enzyme activities, oxidative stress markers, and heat shock protein HSP72 levels in rat liver. *J Steroid Biochem Mol Biol*, 87: 269–277.
- Portes LA, Tucci PJ (2006) [Swim training attenuates myocardial remodeling and the pulmonary congestion in Wistar rats with secondary heart failure to myocardial infarction. *Arq Bras Cardiol*, 87: 54–59.
- Richardson LL, Kleinman HK, Dym M (1998) Altered basement membrane synthesis in the testis after tissue injury. *J Androl*, 19: 145–155.
- Richburg JH (2000) The relevance of spontaneous- and chemically-induced alterations in testicular germ cell apoptosis to toxicology. *Toxicol Lett*, 15: 79–86.
- Santoro G, Romeo C, Impellizzeri P, Arco A, Rizzo G, Gentile C (1999) A morphometric and ultrastructural study of the changes in the lamina propria in adolescents with varicocele. *BJU Int*, 83: 828–832.
- Skinner MK, Tung PS, Fritz IB (1985) Cooperativity between Sertoli cells and testicular peritubular cells in the production and deposition of extracellular matrix components. *J Cell Biol*, 100: 1941–1947.
- Sugizaki MM, Dal Pai-Silva M, Carvalho RF, Padovani CR, Bruno A, Nascimento AF (2006) Exercise training increases myocardial inotropic response in food restricted rats. *Int J Cardiol*, 112: 191–201.
- Tan RS, Scally MC (2009) Anabolic steroid-induced hypogonadism: towards a unified hypothesis of anabolic steroid action. *Med Hypotheses*, 72: 723–728.
- Tesarik J, Greco E, Cohen-Bacrie P, Mendoza C (1998) Germ cell apoptosis in men with complete and incomplete spermiogenesis failure. *Mol Hum Reprod*, 4: 757–762.
- Timpl R (1996) Macromolecular organization of basement membranes. *Curr Opin, Cell Biol*, 8: 618–624.
- Zirkin BR (1998) Spermatogenesis: its regulation by testosterone and FSH. *Semin Cell Dev Biol*, 9: 417–421.