

## Concise report

# The fast-track ultrasound clinic for early diagnosis of giant cell arteritis significantly reduces permanent visual impairment: towards a more effective strategy to improve clinical outcome in giant cell arteritis?

Andreas P. Diamantopoulos<sup>1</sup>, Glenn Haugeberg<sup>1,2</sup>, Are Lindland<sup>3</sup>  
and Geirmund Myklebust<sup>1</sup>

## Abstract

**Objective.** Permanent visual impairment has been reported to occur in up to 19% of GCA patients. The aim of this study was to examine whether implementation of a fast-track approach could reduce the rate of permanent visual impairment and inpatient days of care in GCA patients.

**Methods.** A fast-track outpatient GCA clinic (FTC) was implemented in the Department of Rheumatology, Hospital of Southern Norway Trust Kristiansand, Norway in 2012. The patients included in this study were subsequently recruited between March 2010 and October 2014. Routine clinical and laboratory data and number of inpatient days of care were collected.

**Results.** During the observation period, 75 patients were diagnosed with GCA. Among the 75 GCA patients, 32 were evaluated conventionally and 43 in the FTC. In the conventionally approached group, six patients suffered from permanent visual impairment, while in the FTC group only one patient suffered from permanent visual impairment. The relative risk of permanent visual impairment in the GCA patients examined in the FTC was 88% lower compared with the conventionally evaluated group (relative risk 0.12, 95% CI: 0.01, 0.97,  $P=0.01$ ). The mean difference in inpatient days of care between patients evaluated conventionally and patients evaluated in the FTC was 3 days (3.6 vs 0.6 days,  $P < 0.0005$ ).

**Conclusion.** The implementation of the FTC in GCA care appears to significantly reduce the risk of permanent visual impairment and is more cost effective by reducing the need for inpatient care.

**Key words:** temporal arteritis, vasculitis, ultrasonography, outcome measures, health economics

## Rheumatology key messages

- The fast-track outpatient GCA clinic may reduce permanent visual impairment in GCA patients.
- The fast-track outpatient GCA clinic reduces inpatient days of care in GCA patients.

<sup>1</sup>Department of Rheumatology, Hospital of Southern Norway Trust Kristiansand, <sup>2</sup>Department of Neuroscience, Division of Rheumatology, Norwegian University of Science and Technology, Trondheim and <sup>3</sup>Department of Ophthalmology, Hospital of Southern Norway Trust Arendal, Norway

Submitted 18 December 2014; revised version accepted 9 July 2015

Correspondence to: Andreas P. Diamantopoulos, Department of Rheumatology, Hospital of Southern Norway Trust Kristiansand, Service box 416, 4604 Kristiansand, Norway.  
E-mail: andreas.diamantopoulos@sshf.no

## Introduction

GCA is the most common form of primary systemic vasculitis, mainly affecting elderly individuals aged  $\geq 50$  years [1], with its highest incidence worldwide reported from Norway [2]. Permanent visual loss is one of the most feared complications in GCA, and visual manifestations have been reported in up to 31% and permanent visual loss in 19% of GCA patients [3, 4]. Early diagnosis and

treatment with glucocorticosteroids seems to protect against visual loss [5]. However, if the visual loss has already occurred treatment with high doses of glucocorticosteroids seems ineffective with respect to improving vision [6, 7]. The immense threat for visual loss lies in the first 6 days after diagnosis [6]. Another challenge is that ~20% of GCA patients with visual loss have occult GCA and absence of systemic manifestations [8]. Thus, early diagnosis and initiation of treatment appears to be the most crucial factor to prevent visual loss or impairment in GCA patients.

Biopsy of the temporal artery is considered to be the gold standard for diagnosing GCA [9]. However, the waiting time for a biopsy can be long, and uncertainty about the diagnosis in ambivalent cases where additional investigations are performed, in addition to the fear of treating older patients with high glucocorticosteroid doses, can lead to unnecessary hospital admissions. Hence, this practice may increase inpatient care expenses.

The fast-track approach has been introduced in several fields in medicine with remarkable success in reducing mortality, morbidity and inpatient days of care [10–13]. Rapid initiation of treatment improves outcomes in RA cases through the utilization of the window of opportunity [14]. The fast-track outpatient GCA clinic (FTC), based on quick clinical and ultrasonographic evaluation of the patients suspected to have GCA and initiation of treatment if appropriate, is an implementation of the above models in the diagnostic procedures of GCA patients.

The primary aim of this study was to examine whether the rate of transient and permanent visual loss in GCA patients was lower in the period with the FTC approach compared with the period before the introduction of the FTC in our rheumatology clinic. Furthermore, our second aim was to explore whether this approach was also more cost effective.

## Methods

Patients aged  $\geq 50$  years with new-onset GCA examined in our department between April 2010 and October 2014 were included in this quality study. The FTC approach for GCA [quick evaluation by colour Doppler ultrasound (CDUS) during 24 h, and immediate initiation of treatment if appropriate] was implemented in our outpatient clinic in March 2012 (Fig. 1). The implementation of the FTC was performed at the same time as our participation in the Temporal Artery Biopsy vs Ultrasound in diagnosis of GCA (TABUL) study [15]. The study has been approved by the Institutional Review Board, Hospital of Southern Norway Trust. Owing to the retrospective design of the study, informed consent has not been obtained.

The diagnosis of GCA was based on the positive US examination of temporal arteries and/or large vessels and/or a positive biopsy of the temporal artery and the clinical signs of GCA. Clinical and laboratory data were systematically registered as part of ordinary clinical care and practice. All patients were examined clinically by the same rheumatologist who performed the US examination (A.P.D.). All the patients with visual disturbances (e.g.

amaurosis fugax, diplopia, blurred vision) were examined by an ophthalmologist. In the group of patients with visual disturbances, the number of referrals from ophthalmologists was the same between the two groups (FTC and conventionally evaluated). In patients without visual disturbances, no referrals from ophthalmologists were registered. Permanent visual impairment was defined as total visual loss in one or both eyes (for counting fingers or less). Inpatient days of care for all groups were also registered. The cost of an inpatient day was calculated according to the cost reported by the Norwegian Ministry of Finance in 2013 [16].

All the patients with visual disturbances and permanent visual impairment received the same treatment (1 g methylprednisolone i.v. for 3 days consecutively).

## Ultrasonographic evaluation of the arteries

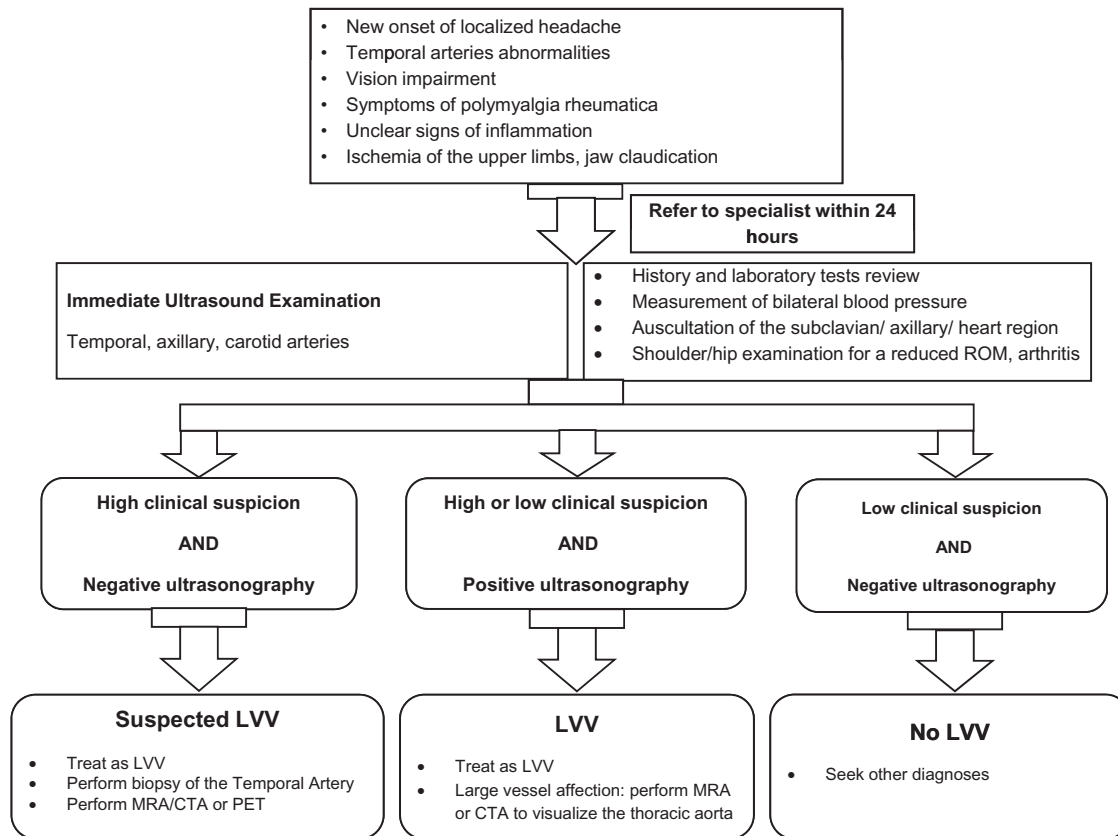
CDUS was performed by a rheumatologist experienced in vascular US (A.P.D.). During the period 2010–13, the patients were assessed using a Siemens Acuson Antares US system with a multilinear high frequency transducer up to 12 MHz (Siemens Medical Systems, Ultrasound Group, Erlangen, Germany) and from January 2014 by using a Siemens Acuson S2000 US system with a multilinear high frequency transducer up to 17 MHz (Siemens Medical Systems). A Doppler frequency of 7.5 MHz was used in both sets of US equipment. Examination of common superficial temporal arteries, the frontal and parietal branches, the axillary and common carotid arteries in longitudinal and transverse planes was performed in all patients. The presence of a hypoechoic ring (eccentric or circumferential) around the vessel wall (halo sign) in any part of the temporal, axillary or common carotid arteries in both transverse and longitudinal views was considered as a positive CDUS finding. The cut-off limit for vasculitis for the axillary artery was 1 mm and for the carotid artery 1.5 mm [17]. Large-vessel vasculitis was defined as the presence of US findings as described above in the axillary and/or carotid arteries with or without temporal artery involvement.

## Statistical analysis

Continuous variables were presented as means with 95% CIs if normally distributed and as medians with interquartile range (IQR) for non-normal distribution of variables. Categorical variables were presented as numbers and percentages. Relative risk (RR) was reported as measure of association with 95% CI as measure of statistical stability.

For comparisons between groups, the independent-samples *t*-test for continuous variables and  $\chi^2$  test or Fisher's exact test (where appropriate) for categorical variables were applied. For non-parametric numerical variables, the Wilcoxon signed-rank test was applied. The statistical analyses were performed with STATA 13 (College Station, TX, USA).  $P < 0.05$  was considered significant.

**Fig. 1** The fast-track US GCA outpatient clinic algorithm



**Results**

During the evaluation period, 75 patients (mean age 73 years, 95% CI 71, 76) were diagnosed to have GCA; 49 females (mean age 73.5 years, 95% CI 71, 80) and 26 males (mean age 72 years, 95% CI 69, 76). Among the 75 GCA patients, 32 were evaluated conventionally (mean age 74.6 years, 95% CI 71, 77) and 43 in the FTC (mean age 72.0 years, 95% CI 69, 74;  $P=0.30$ ). The baseline characteristics of the two groups are presented in supplementary Table S1, available at *Rheumatology* Online.

In the conventional care group, visual disturbances were observed in nine patients; six of them suffered from permanent (21.5%) visual impairment in one (five patients) or both eyes (one patient). All the patients suffered from visual disturbances before the introduction of the treatment with CSs. Among the 43 patients evaluated in the FTC group, nine had transient visual manifestations and one (2.4%) suffered from permanent visual impairment in one eye. Among the patients with disturbances of vision, four patients had amaurosis fugax (22%), two patients had diplopia (12%), seven patients (38%) suffered from anterior ischaemic optic neuropathy, three from blurred vision (16%) and in two the changes were not defined (12%). The RR of permanent visual

impairment in the GCA patients examined in the FTC was 88% lower compared with the conventionally evaluated group (Table 1). The mean number of inpatient days of care was 3.6 days (IQR 7) in patients who were evaluated conventionally and 0.6 day (IQR 1) in patients evaluated in the FTC (mean difference 3 days,  $P < 0.0005$ ), and significantly more patients were examined in the outpatient clinic in the FTC group than in the conventional group (supplementary Table S1, available at *Rheumatology* Online). The daily inpatient cost in the Norwegian Hospitals was calculated to be 12 433 Norwegian Krone (NOK) according to the Norwegian Ministry of Finance [16]. Thus, implementation of the FTC reduced the cost of inpatient care by ~37 300 NOK per patient, a total reduction for all the 42 GCA patients assessed in the FTC of 1 566 558 NOK (~185 000 Euros).

**Discussion**

Our data indicate that the FTC including a rapid assessment by ultrasonography may significantly reduce the risk of permanent visual impairment in GCA patients. The implementation of an innovative technique combined with quick evaluation can lead to a significant decrease of one of the most feared complications of the GCA disease

**TABLE 1** Comparison of the visual outcomes between the FTC and the conventionally evaluated group

| Outcome                     | Fast-track group | Conventionally evaluated group | RR (95% CI)       | P-values |
|-----------------------------|------------------|--------------------------------|-------------------|----------|
| Visual disturbances         | 9                | 9                              | 0.74 (0.33, 1.66) | 0.40     |
| Permanent visual impairment | 1                | 6                              | 0.12 (0.01, 0.97) | 0.01     |
| Inpatient days of care      | 0.60             | 3.60                           | NA                | <0.0005  |

FTC: fast-track outpatient GCA clinic; NA: not applicable; RR: relative risk.

[18, 19]. Furthermore, FTC seems to be more cost effective by reducing the need for inpatient days of care used in diagnosing GCA. Interestingly, lower rates of permanent visual impairment after the introduction of a quick clinical evaluation programme of the GCA patients were also observed in a previous study from our region, in which of 54 GCA patients only one (1.9%) suffered permanent visual impairment [20]. It appears that the major factor in visual loss is the delayed initiation of treatment due to delay in diagnosis or insecurity of the diagnosis. Interestingly, the number of the GCA patients suffering from visual disturbances was the same between the two groups, indicating that rapid diagnosis and initiation of treatment are essential in order to prevent irreversible visual manifestations. The finding of no difference between the two groups in the time from symptoms arising to diagnosis also confirms the above observation.

No differences in main symptoms, signs and laboratory evaluations were observed between the two groups. The low number of biopsies performed in our GCA patients (46%) was due to the fact that after 2013 US replaced biopsy as the main investigational method in the GCA diagnostics within our department. US can depict the whole length of the temporal artery and large supra-aortic vessels, thus giving the performing physician confidence in his diagnosis and subsequent initiation of treatment. This is a major advantage of the ultrasonography method compared with temporal artery biopsies, where skip lesions have been reported to occur in ~8.5% of the biopsies in GCA patients [21]. A further advantage of the ultrasonography method in diagnosing GCA patients compared with temporal artery biopsy is that the method is non-invasive and can be performed as a complementary procedure to the clinical examination without any delay.

It seems that FTC reduced significantly the inpatient days of care in GCA patients. In addition, significantly more patients were examined in the outpatient clinic in FTC than in the conventional group (Table 1). One explanation may be that the FTC was introduced simultaneously with our participation in the Temporal Artery Biopsy vs Ultrasound in diagnosis of GCA study [15]. Another reason could be that the clear ultrasonographic signs combined with the clinical picture make the treating physician more confident in his diagnosis. Thus, it may be

easier to examine the patient in the outpatient clinic and start treatment immediately rather than wait for a biopsy or be hampered by uncertainty about diagnosis. As has previously occurred with inflammatory arthritides, it appears that GCA could also be treated successfully in the outpatient clinic and hospital admissions should be reserved for cases where the clinical suspicion is high but the ultrasonography is negative or for patients with major complications and significant co-morbidities (Fig. 1).

It seems that by 2050, ~500 000 people will be visually impaired worldwide, and in the USA alone the projected cost of visual impairment due to GCA will exceed 76 billion US dollars, while the cost of the inpatient care for the GCA patients will be about 1 billion US dollars [22]. Implementation of the FTC in our department also had economic consequences by reducing the number of inpatient days of care. In our study, we did not calculate the total costs of diagnosing the GCA patients in the FTC and in the conventionally evaluated group. However, by only calculating costs related to inpatient services the costs were reduced by ~1 560 000 NOK, highlighting another potential advantage of the FTC. Future studies should elucidate this important aspect further.

### Limitations

Our study has several limitations. This study is a retrospective quality assessment of the FTC approach that was implemented in our daily clinical practice and was not a prospective cohort study. Furthermore, the small sample of the study could influence the results either way. Another potential bias is that the ultrasonographer was not blinded to laboratory or clinical data, which could have caused over-diagnosis of GCA. However, if this form of bias is present in our study, it is probably equally distributed between the two groups. Selection bias could arise due to increased awareness of the primary care physicians and rheumatologists after the implementation of the FTC and could lead to an increased rate of GCA patients referred to our department. However, our department is the only referral centre for systemic vasculitides in Southern Norway. In addition, another limitation is that we did not use any predefined cut-off limits for GCA in the US examination of the temporal arteries.

## Conclusion

In conclusion, the implementation of the FTC seems to reduce the risk of permanent visual impairment in GCA patients and even reduced costs. However, our data should be interpreted with caution owing to the low number of patients involved. Further observational studies are warranted in order to confirm these encouraging and promising data.

## Acknowledgements

Agder Medforsk, a non-profit scientific organization supplied the US equipment Siemens Acuson S2000.

*Funding:* No specific funding was received from any funding bodies in the public, commercial or not-for-profit sectors to carry out the work described in this manuscript.

*Disclosure statement:* The authors have declared no conflicts of interest.

## Supplementary data

Supplementary data are available at *Rheumatology* Online.

## References

- Weyand CM, Goronzy JJ. Medium- and large-vessel vasculitis. *N Engl J Med* 2003;349:160-9.
- Haugeberg G, Paulsen PQ, Bie RB. Temporal arteritis in Vest Agder County in southern Norway: incidence and clinical findings. *J Rheumatol* 2000;27:2624-7.
- González-Gay MA, García-Porrúa C, Llorca J *et al.* Visual manifestations of giant cell arteritis. Trends and clinical spectrum in 161 patients. *Medicine* 2000;79:283-92.
- Salvarani C, Cimino L, Macchioni P *et al.* Risk factors for visual loss in an Italian population-based cohort of patients with giant cell arteritis. *Arthritis Rheum* 2005;53:293-7.
- Hayreh SS, Zimmerman B, Kardon RH. Visual improvement with corticosteroid therapy in giant cell arteritis. Report of a large study and review of literature. *Acta Ophthalmol Scand* 2002;80:355-67.
- Danesh-Meyer H, Savino PJ, Gamble GG. Poor prognosis of visual outcome after visual loss from giant cell arteritis. *Ophthalmology* 2005;112:1098-103.
- Loddenkemper T, Sharma P, Katzan I, Plant GT. Risk factors for early visual deterioration in temporal arteritis. *J Neurol Neurosurg Psychiatr* 2007;78:1255-9.
- Hayreh SS, Podhajsky PA, Zimmerman B. Occult giant cell arteritis: ocular manifestations. *Am J Ophthalmol* 1998;125:521-6.
- Salvarani C, Cantini F, Boiardi L, Hunder GG. Polymyalgia rheumatica and giant-cell arteritis. *N Engl J Med* 2002;347:261-71.
- Muller S, Zalunardo MP, Hubner M *et al.* A fast-track program reduces complications and length of hospital stay after open colonic surgery. *Gastroenterology* 2009;136:842-7.
- Winther SB, Foss OA, Wik TS *et al.* 1-year follow-up of 920 hip and knee arthroplasty patients after implementing fast-track. *Acta Orthop* 2014;86:1-8.
- Ratanakorn D, Keandoungchun J, Sittichanbuncha Y, Laothamatas J, Tegeler CH. Stroke fast track reduces time delay to neuroimaging and increases use of thrombolysis in an academic medical center in Thailand. *J Neuroimaging* 2012;22:53-7.
- Olesen F, Hansen RP, Vedsted P. Delay in diagnosis: the experience in Denmark. *Br J Cancer* 2009;101 (Suppl 2):S5-8.
- Raza K, Saber TP, Kvien TK, Tak PP, Gerlag DM. Timing the therapeutic window of opportunity in early rheumatoid arthritis: proposal for definitions of disease duration in clinical trials. *Ann Rheum Dis* 2012;71:1921-3.
- Ultrasound Versus Biopsy in Diagnosis of Giant Cell Arteritis (TABUL). 2010. <http://clinicaltrials.gov/ct2/show/NCT00974883?term=gca&rank=1>.
- Norwegian Ministry of Finance. Inpatient days cost in the Norwegian Hospitals. 2013 [cited 2013]. [http://www.regjeringen.no/en/dep/fin/Documents-and-publications/andre/Publications-in-English-or-translated-in/brev\\_stortinget/2013/sporsmal-nr-834-til-skriftlig-besvarelse.html?id=714876](http://www.regjeringen.no/en/dep/fin/Documents-and-publications/andre/Publications-in-English-or-translated-in/brev_stortinget/2013/sporsmal-nr-834-til-skriftlig-besvarelse.html?id=714876) (31 July 2015, date last accessed).
- Diamantopoulos AP, Haugeberg G, Hetland H *et al.* The diagnostic value of color Doppler ultrasonography of temporal arteries and large vessels in giant cell arteritis: a consecutive case series. *Arthritis Care Res* 2014;66:113-9.
- Patil P, Achilleos K, Williams M *et al.* 9. Outcomes and cost effectiveness analysis of fast track pathway in giant cell arteritis. *Rheumatology* 2014;53 (Suppl 2):i5-6.
- Schmidt WA, Krause A, Schicke B, Kuchenbecker J, Gromnica-Ihle E. Do temporal artery duplex ultrasound findings correlate with ophthalmic complications in giant cell arteritis? *Rheumatology* 2009;48:383-5.
- Myklebust G, Gran JT. A prospective study of 287 patients with polymyalgia rheumatica and temporal arteritis: clinical and laboratory manifestations at onset of disease and at the time of diagnosis. *Br J Rheumatol* 1996;35:1161-8.
- Poller DN, van Wyk Q, Jeffrey MJ. The importance of skip lesions in temporal arteritis. *J Clin Pathol* 2000;53:137-9.
- De Smit E, Palmer AJ, Hewitt AW. Projected worldwide disease burden from giant cell arteritis by 2050. *J Rheumatol* 2015;42:119-25.