

The identification and syndromic management of snakebite in South Africa

Blaylock RS, MBChB(UCT), FRCS(Ed), FCS(SA), MMedSc(Natal), MD(Natal)
General Surgeon, Leslie Williams Private Hospital
Goldfields Health, Carletonville

Keywords: snake bite, antivenom

Correspondence: Dr Roger S Blaylock, PO Box 968, Carletonville, 2500,
Tel (018) 788 1000, Fax (018) 788 1151, e-mail: theлма. hibbert@goldfileds.co.za

(SA Fam Pract 2005;47(9): 48-53)

Introduction

The identification of snakebite injury is uncertain, especially in the 40% of patients who do not see the offending snake, unless there are paired fang marks or typical findings of an envenomation syndrome. The differential diagnosis would include a thorn prick, spider bite or scorpion sting. Thorn pricks are not associated with the onset of progressive swelling or systemic illness within minutes. Swelling following dermonecrotic spider bites is slow in onset, whilst significant button (widow) spider bites and scorpion stings are associated with muscle spasticity which is not a feature of snakebites.^{1,2,3}

Where snakes and humans abound, encounters between the two are not uncommon, with bites leading to 30 – 80 hospital admissions per 100,000 persons per year.⁴⁻⁷ Snakebites are most common in the summer months, from late afternoon to early evening, affecting males and females roughly equally, depending on daytime activity. Most occur on the foot or leg during the first three decades of life. Finger and hand bites are far more prone to necrosis than bites elsewhere. Multiple bites on any body part may occur in sleeping patients. The venom to mass ratio is larger in children, resulting in a higher mortality rate than adults.⁴⁻⁷

The syndromic approach to snakebite

Snakebite presents as minor mechanical trauma, allergy to venom (rare) and/or an evenomation syndrome. Simplified, three main clinical envenomation syndromes in snakebite should be identified, namely:

- **Painful progressive swelling (PPS)**
- **Progressive weakness (PW)**
- **Bleeding (B)**

This article follows the syndromic approach which is logical and effective, whether the species of the snake is known or not. (Algorithm 1). For easy reference, the three syndromes have been colour-coded in the text and in the algorithms.

First aid

There is no good first aid measure for all snakebites. These measures attempt to denature venom (topical applications, electrotherapy, cryotherapy), remove venom (incision and suction, excision) or retard its absorption (various types of tourniquet, cryotherapy). These measures in most cases are either ineffective per se or the venom is absorbed too rapidly (mambas) or deposited too deeply (adders) for them to be effective. The vast majority of snakebites lead to PPS and here tourniquet use would aggravate or precipitate necrosis and compartment syndromes. The pressure immobilisation (Sutherland) technique is useful for non-spitting cobra bites where the dominant neurotoxin(s) is lymphatically transported and an arterial tourniquet is effective against the bites of the same snakes and mambas but is extremely uncomfortable and should not be left on for more than 90 minutes. Venom in the mouth should be washed out with water or another bland solution. Venom on the skin should be wiped or washed away. Venom ophthalmia may be complicated by corneal erosions which require repeated slit lamp examinations, specific

treatment and follow-up by the practitioner. (See Algorithm 2)

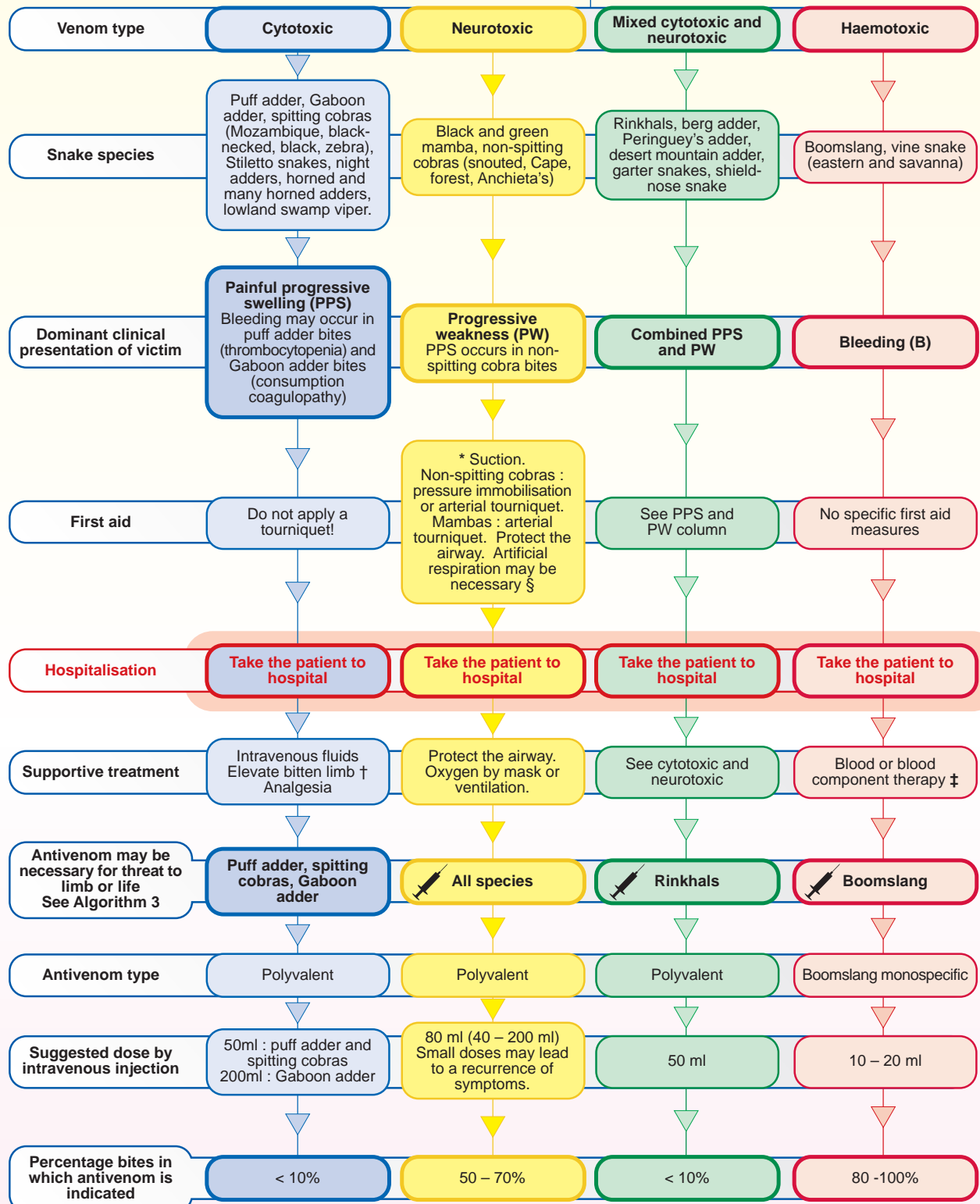
Antivenom

The suggested indications are for threat to limb or life, whether potential or established. (See algorithm 3.) Antivenom is best given in a hospital setting as anaphylaxis may occur, the latter being best prevented or treated with adrenaline.⁸

Take to Practice Messages:

- There is no first aid measure effective against all snake bites.
- Tourniquets are not recommended if the snake species is unknown.
- Syndromic management of snakebite without knowing the species of the snake is logical and effective.
- The majority of poisonous snakebites may be managed without the use of antivenom.
- Antivenom is best administered in a medical setting.
- Antibiotic use is not necessary unless there is bite site necrosis or iatrogenic interference.
- Puff adder bites are responsible for most cases of bleeding.
- Heparin should not be used for a consumption coagulopathy.
- True compartment syndromes are uncommon.

Algorithm 1: Guidelines for the Management of Snakebite



* Mechanical suction device if HIV status is not known (Suction is of minimal benefit but reassuring to the patient.).
 † Some authorities prefer keeping the bitten limb at heart level.
 ‡ Heparin, antifibrinolytics and thrombolytics are of no value and may be dangerous.
 § Polyvalent antivenom for the triad of perioral paraesthesia, excessive salivation and sweating or metallic taste, within a few minutes of the bite (mambas) OR difficulty in breathing.
 Polyvalent antivenom is effective against the bites of the mambas, cobras, rinkhals, puff adder and Gaboon adder only.
 A test dose of antivenom is not indicated.

**Antivenom Unit (SAVP (Pty) Ltd: (011) 386 6000 Fax (011) 386 6016
 For emergencies: Contact Dr Roger Blaylock at 083 652 0105**

South African manufactured antivenom is recommended as venom from South African snakes is used during manufacture, which negates geographic venom variation. Undiluted antivenom administered intravenously over 10 minutes is as safe as diluted antivenom over 30 minutes⁹ and ensures that a medical practitioner is at the bed side should an acute allergic reaction occur. A test dose of antivenom for acute adverse reactions does not predict the response to the main dose and may be omitted. Appropriate administration of antivenom can stop progression of swelling, prevent or reverse an inability to breathe (not the latter in Cape cobra bites) and stop bleeding. Antivenom is efficacious whilst venom is still active as shown by continued deterioration of the patient which in some cases may last several days. Indications for antivenom arise sooner and more frequently in children due to high venom-to-mass ratio which counteracts the increased morbidity and mortality in this age group.

Antivenom is effective and readily available from the SAVP (Pty) Ltd (Antivenom Unit) at Tel 011-386-6000 and Fax 011-386-6016

Antibiotics

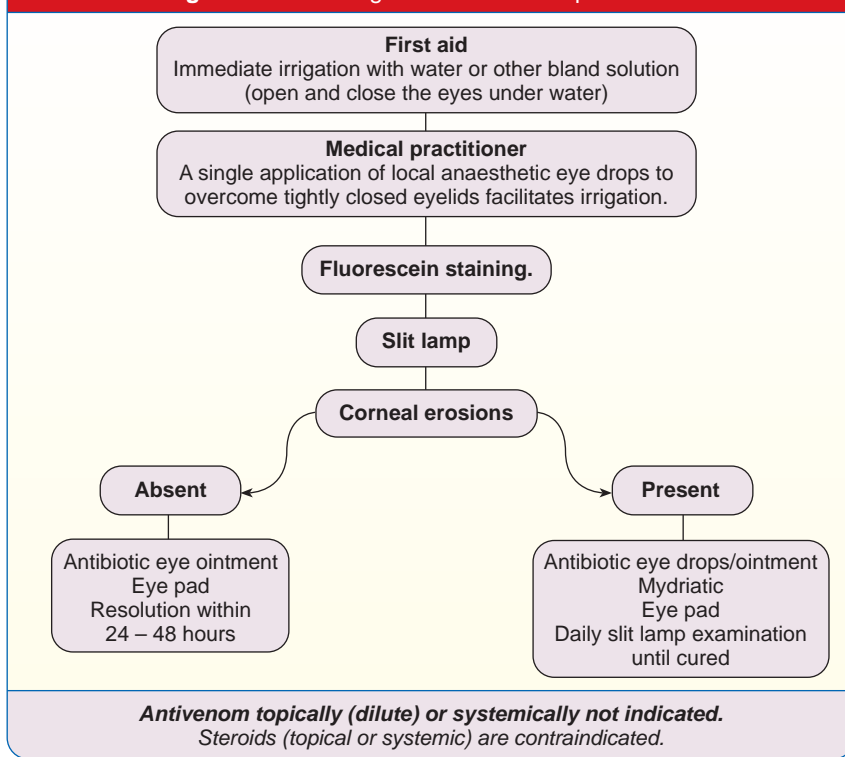
In general, antibiotics are usually unnecessary as bacterial infection is uncommon unless secondary to necrosis or iatrogenic bite site interference.¹⁰ There is a paucity of bacteria in snake mouths which are mainly Gram negative enterobacteriaceae and venom has antibacterial properties.^{11,12} Steroids are of no value and interfere with the venom / antivenom reaction

Painful progressive swelling (PPS)

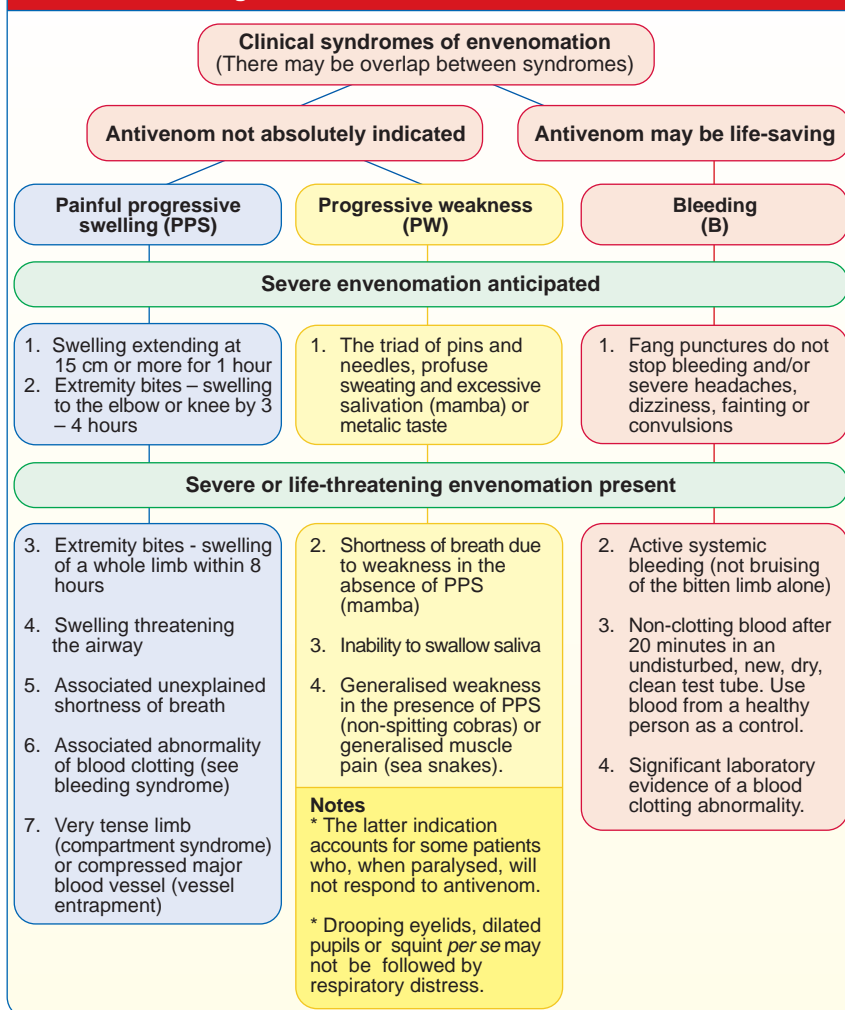
Clinical presentation

This is by far the most common presentation comprising about 90% of all envenomations and is due to cytotoxic venom. Swelling commences around the bite site within a few minutes and spreads mainly in a proximal direction. It is painful, often tender, warm to hot and indurated. The duration and rate at which it spreads is mainly snake species dependent. It is quicker with the adders at 5 – 10 cm or more per hour whilst that due to stiletto snake and spitting cobra bites spreads at about 1 - 2 cm per hour. It spreads faster soon after the bite and slows before stopping. Within 1 – 2 hours of the bite there is usually painful regional lymphadenopathy.

Algorithm 2: Management of venom ophthalmia



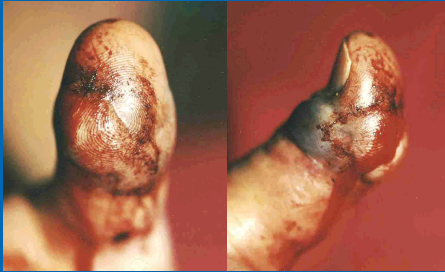Algorithm 3: Indications for antivenom



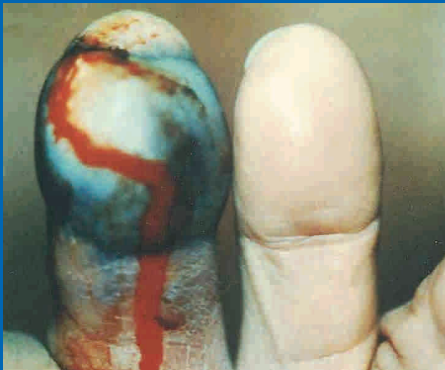Painful progressive swelling (PPS)

Puff adder bite

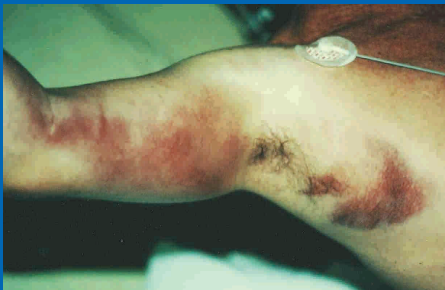Antivenom was not administered. Platelets $28 \times 10^9/l$ at 4 h 10 min. Blistering does not necessarily equate to necrosis, but did in this case.



Day of the bite



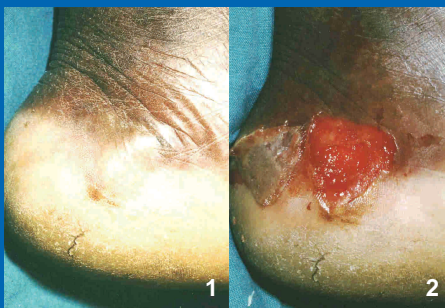
Second day after bite - Note continuous ooze of blood



Second day after bite - Purpura

Common night adder bite

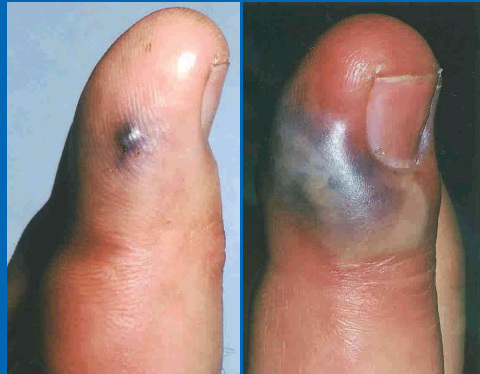Antivenom is ineffective and should not be used. Necrosis has not been recorded following a night adder bite.



1. Seventh day after bite – Blister formation
2. Seventh day after bite – Deroof of blister

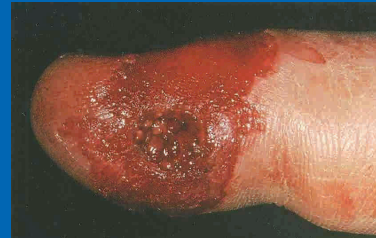Stiletto snake bite

Antivenom is ineffective and should not be used. There is initial blanching at the bite site. A blister equates to necrosis, which occurs in 25% of bites.



17 hours after bite

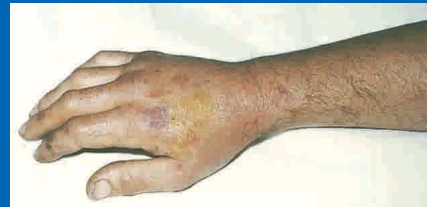5 days after bite



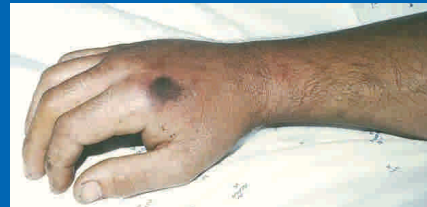Day five following debridement

Mozambique spitting cobra bite

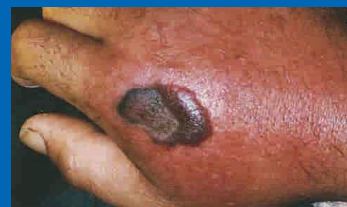Necrosis occurs in the majority of bites and is usually surrounded by a peripheral blister 4 to 6 days after the bite. Antivenom does not prevent necrosis.



Discoloured area 6,5 hours after bite



Second day after bite – discoloured area larger and more obvious



Seventh day after bite – peripheral blistering. Area of underlying necrosis much larger than appears on the surface.

Photographs © RS Blaylock

Complications of PPS may be classified as:

- Local, such as bite site blister, haematoma or necrosis (10%).
- Regional, such as compartment syndrome, nerve and vessel entrapment and deep vein thrombosis (uncommon).
- Systemic, due to loss of fluid and blood components into the swollen area which may lead to hypotension, anaemia, hypoalbuminaemia and hypofibrinogenaemia with prolongation of the PTT and INR. This occurs mostly in those cases where swelling rapidly spreads to the trunk and is most common following puff adder bites. Cardio-toxicity and pulmonary oedema due to circulating venom have only been described following Gaboon adder bites.¹³

Snakes responsible for PPS include:

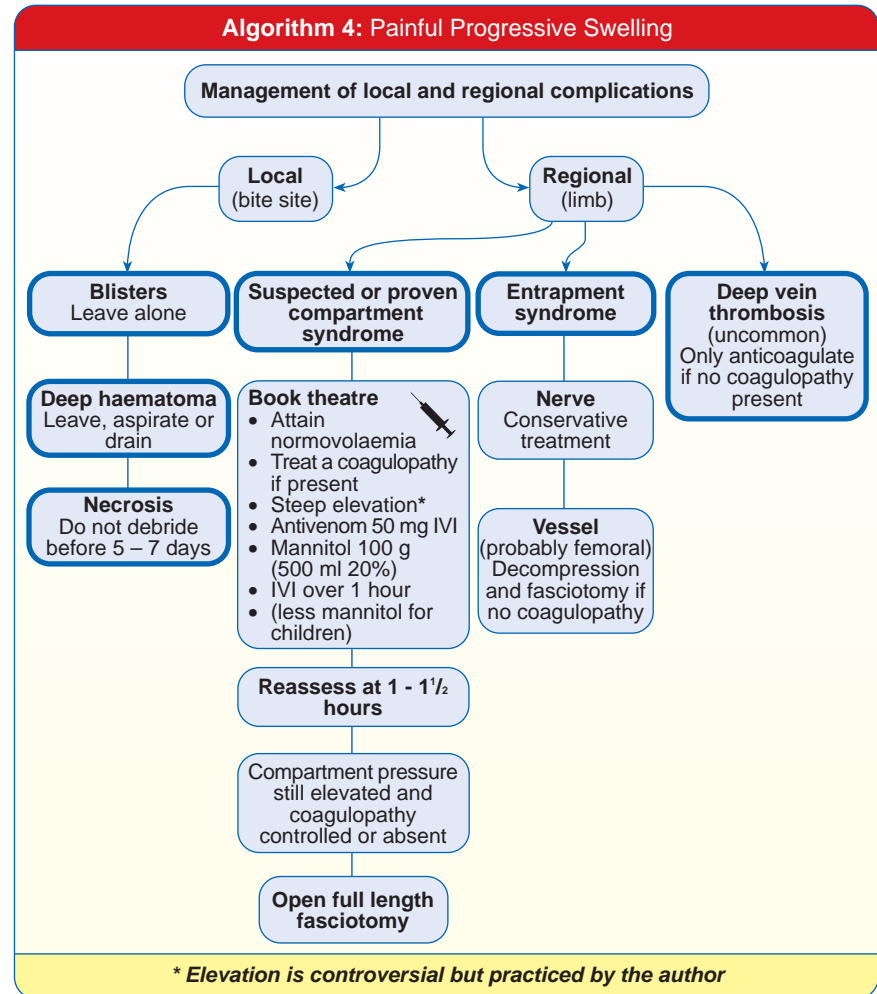
- Puff adder (*Bitis arietans*)
- Spitting cobras (*Naja mossambica*, *N. nigricollis* sp.)
- Stiletto snake (*Atractaspis bibronii*)
- Night adders (*Causus* sp.).

Gaboon adder (*B. gabonica*) and other small adder bites are less common. Although bites by all these snakes lead to PPS there are clinical peculiarities which identifies offending snake species. Bite site necrosis may result.¹⁴⁻¹⁶

Management (Algorithm 1,3,4)

Elevation is analgesic and diminishes swelling. Intravenous fluids replace what has been lost into the swollen area. Analgesia is important. This triad of elevation, intravenous fluid and analgesia is all that is required for the majority of snake bites. Should there be necrosis, surgery is best left for 5 – 7 days, as, prior to this time, the junction between dead and dying tissue may not be well defined. This procrastination does not prejudice the patient in any way.

Compartment syndrome of a limb is uncommon but requires urgent attention. Snake bitten limbs may present like compartment syndrome but, on measuring intra-compartmental pressures, most are not.¹⁷ Compartment syndromes of hands and feet self-decompress via the bite site. Compartment syndromes of limbs may



be successfully managed conservatively for an hour by elevating the limb, administering intravenous mannitol (reduces swelling and helps prevent renal failure) and intravenous antivenom which, in an appropriate dose, stops progression of swelling. Conservative treatment must be aggressively policed or nothing other than elevation and a drip will have been achieved during this time. Should conservative treatment fail, providing there is no significant coagulopathy, open full-length fasciotomy should be performed.

Carpal tunnel syndrome is not uncommon if bitten on a hand or finger. It is self-limiting and responds to elevation.

Vessel entrapment syndrome of the femoral vessels beneath the inguinal ligament and the axillary vessels at the thoracic outlet lead to limb ischaemia. A blister covered pulseless limb suggests the diagnosis.¹⁸

Deep vein thrombosis is not common, is usually diagnosed late when swelling persists for several days and

should not be anticoagulated if a coagulopathy is still present.

Progressive weakness (PW)

Clinical Presentation

Injected neurotoxic venom produces striated muscle dysfunction:

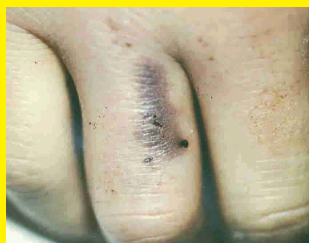- Venom of the non-spitting cobras (Cape (*Naja nivea*), snouted (*N. annulifera*), forest (*N. melanoleuca*) and Anchieta's (*N. anchietae*)) contain curare-like post-synaptic toxins.
- Mamba (*Dendroaspis* spp.) bites lead to excessive circulating levels of acetylcholine
- Some of the small adders, i.e. berg adder (*Bitis atropos*), Peringuey's adder (*B. peringueyi*), desert mountain adder (*B. xeropaga*) contain pre-synaptic toxins.

The different mechanisms of producing paresis lead to different symptomatology. Black mamba (*D. polylepis*) bites may be associated with minor swelling which is neither painful nor tender whilst that caused by non-spitting cobras, the rinkhals

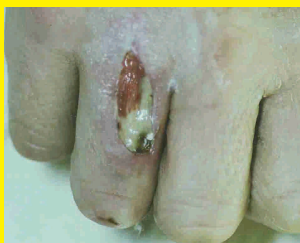Progressive weakness (PW)

Rinkhals bite

Progressive weakness may occur and necrosis is uncommon. The patient was unconscious within one minute due to venom-induced anaphylaxis.

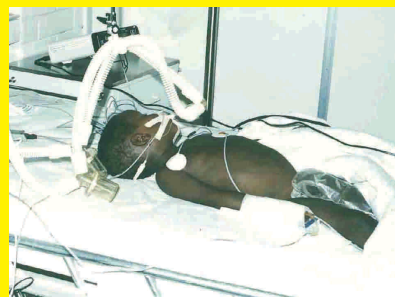

40,5 hours after bite



10 days after bite

Black mamba bite (juvenile snake)



5 hours after the bite. Puncture wounds were not visible. The patient was ventilated from 3 hours 25 min for 2 hours 5 min. 60 ml polyvalent antivenom IVI was administered during ventilation. Patient discharged the following day. If the patient had been bitten by an adult snake, death would have occurred within half an hour due to high venom-to-mass ratio.

Photographs © RS Blaylock

(*Haemachatus haemachatus*) and adders is appreciable in extent, painful, tender and bite site necrosis may result.

Management

A clear airway and adequate oxygenation are all important. Ventilation may be required, in which case sedation is mandatory to prevent the patient overhearing disturbing conversations. There is little place for muscle relaxants except during intubation of a struggling hypoxic patient. The approach to neurotoxic bites is depicted in Algorithm 1 and 3.

Bleeding (B)

Clinical Presentation

Injected haemotoxic venom may lead to a bleeding diathesis. Boomslang (*Dispholidus typus*) and vine snake (*Thelotornis spp.*) venom contains procoagulant toxins which activate factors II and X leading to a consumption coagulopathy with all the possible attendant complications and mortality.^{19,20} These bites are uncommon.

Puff adder bites are far more common and these snakes are responsible for the majority of patients with bleeding due to snake bite. In this case a whole limb may be swollen, which does not occur with boomslang and vine snake bites.

Gaboon adder bites may lead to a severe consumption coagulopathy as well as significant swelling.¹³ These snakes are placid and only found around St Lucia in South Africa making bites decidedly uncommon.

Management

Antivenom has the greatest benefit should a patient have a severe coagulopathy with active bleeding.²¹ There is no place for heparin, fibrin stabilising drugs, fibrinolytics or thrombolytics. Venom-induced 'thrombin' is far less susceptible to heparin than physiological thrombin.²²

(See Algorithm 1 and 3 for further management.)

Referral guidelines

- If the patient's condition is outside of local expertise and resources.
- While awaiting referral, give supportive care (algorithm 1).
- The ability to intubate and ventilate during transfer is essential

Prevention of snakebite

Being sensible is most important. Wearing shoes and using a torch at night are helpful. Do not handle "dead" snakes as some elapid species, particularly the rinkhals, feign death. Sleep in a zip-up tent or tuck a mosquito net under the mattress when on camping trips. 🦋

See CPD Questionnaire, page 41

References

1. Muller GJ. Black and brown widow spider bites in South Africa. *S Afr Med J* 1993; 83: 399 - 405
2. Muller GJ. Scorpionism in South Africa. *S Afr Med J* 1993; 83: 405 - 11
3. Bergman NJ. Scorpion sting in Zimbabwe. *S Afr Med J* 1997; 87: 163 - 7
4. Coetzer PWW, Tilbury CR. The epidemiology of snakebite in Northern Natal. *S Afr Med J* 1982; 62: 206 - 12.
5. McNally SL, Reitz CJ. Victims of snakebite: A 5-year study at Shongwe Hospital, Kangwane, 1978 - 1982. *S Afr Med J* 1987; 72: 855 - 60.

6. Wilkinson D. Retrospective analysis of snakebite at a rural hospital in Zululand. *S Afr Med J* 1994; 84 (12): 844 - 7.
7. Blaylock R. Epidemiology of snakebite in Eshowe, KwaZulu-Natal, South Africa. *Toxicon* 2004 ; 43 (2): 159 - 66.
8. Blaylock RSM. Acute adverse reactions to South African manufactured snakebite antivenom. *Current Allergy & Clinical Immunology* 2002: 15 : 107 - 13.
9. Malasit P, Warrell DA, Chanthavanich P, Viravan C, Mongkolsapaya J, Singthong B, Supich C. Prediction, prevention, and mechanism of early (anaphylactic) antivenom reactions in victims of snake bites. *Br Med J* 1986 292: 17 - 20
10. Blaylock RS. Antibiotic use and infection in snakebite victims. *S Afr Med J* 1999; 89 (8): 874 - 6.
11. Blaylock RSM. Normal oral bacterial flora from some Southern African snakes. *Ondestepoort Journal of Veterinary Research* 2001; 68: 175 - 82
12. Blaylock RSM. Antibacterial properties of KwaZulu Natal snake venoms. *Toxicon* 2000; 68:1529 - 34.
13. Edwards IR, Fleming JBM, James MFM. Management of a Gaboon viper bite : a case report. *Cent Afr J Med* 1979; 25: 217 - 21
14. Scharf GM, du Plessis HJC. Guidelines for the management of puff adder bites. *Trauma Emerg Med* 1993; 948 -52
15. Tilbury, CR. Observations on the bite of the Mozambique spitting cobra (*Naja mossambica mossambica*). *S Afr Med J* 1982; 61: 308 - 13.
16. Tilbury CR, Branch WR. Observations on the bite of the southern burrowing asp (*Atractaspis bibronii*) in Natal. *S Afr Med J* 1989; 75: 327 - 31.
17. Murbarak SJ, Hargens AR. Acute compartment syndromes. *Surg Clin North Am* 1983; 63: 539 - 65
18. Blaylock RSM. Femoral vessel entrapment and compartment syndromes following snakebite. *S Afr J Surg* 2003; 41 (3) : 72 - 3
19. Becker JHR, Jacobson B, Franz RC. Boomslang (*Dispholidus typus*) coagulopathy with special reference to thromboelastography. *Lang Arch Surg* 1982; 220 - 1
20. Atkinson PM, Bradlow BA, White JAM, Grieg ABW, Gaillard MC. Clinical features of Twig snake (*Thelotornis capensis*) envenomation. *S Afr Med J* 1980; 58: 1007 - 11
21. White J. Snake venoms and coagulopathy. *Toxicon* 2005; 951 - 67
22. Warrel DA. Injuries, envenoming, poisoning and allergic reactions caused by animals. In : Weatherall DJ, Ledingham JGG, Warrell DA, editors. Oxford textbook of medicine ; Vol 2, Oxford, Oxford Medical Publications;1996 . p2944 - 721.