

CLINICAL PRACTICE

The Incidentally Discovered Adrenal Mass

William F. Young, Jr., M.D.

This Journal feature begins with a case vignette highlighting a common clinical problem. Evidence supporting various strategies is then presented, followed by a review of formal guidelines, when they exist. The article ends with the author's clinical recommendations.

A 68-year-old woman is incidentally found to have a left adrenal mass, 2.8 cm in diameter, on abdominal computed tomography that was ordered to evaluate right lower abdominal discomfort (which has since resolved). Her medical history is notable only for hypertension that has been well controlled with hydrochlorothiazide, at a dose of 25 mg daily. She reports no sweating, palpitations, headache, weight gain, or proximal muscle weakness. Her physical examination is unremarkable. How should she be evaluated?

THE CLINICAL PROBLEM

An adrenal “incidentaloma” is an adrenal mass, generally 1 cm or more in diameter, that is discovered serendipitously during a radiologic examination performed for indications other than an evaluation for adrenal disease.¹ This definition excludes cases in which a symptomatic adrenal-dependent syndrome is “missed” because of a superficial interview or physical examination.¹ The widespread use of abdominal ultrasonography, computed tomography (CT), and magnetic resonance imaging (MRI) has resulted in the clinical dilemma of the adrenal incidentaloma.

Numerous autopsy studies have examined the frequency of incidental adrenal nodules.² In a report on 25 studies, the overall frequency of adrenal adenomas in 87,065 autopsies was 6% (range, 1 to 32).^{1,2} Abdominal CT yields similar findings; a recent study reported a prevalence of adrenal incidentaloma of 4%.³ The prevalence of adrenal adenomas increases with increasing age^{1,2}: the probability of finding an unsuspected adrenal adenoma on abdominal CT in a patient between 20 and 29 years of age would be approximately 0.2%, as compared with approximately 7% in a patient over 70 years of age.^{1,2}

The majority of adrenal incidentalomas are clinically nonhypersecreting, benign adrenocortical adenomas.⁴ Other frequently reported diagnoses include cortisol-secreting adrenocortical adenoma, pheochromocytoma, adrenocortical carcinoma, and metastatic carcinoma.¹

STRATEGIES AND EVIDENCE

The optimal diagnostic approach to a patient who has an adrenal incidentaloma has not been established.^{1,4-6} However, it is reasonable to start by taking a careful history and performing a physical examination, focusing on the signs and symptoms suggestive of adrenal hyperfunction or malignant disease (Table 1) and hormonal testing^{7,8} (Table 2). Although no specific diagnostic approach has been prospectively validated, an algorithm based on clinical experience and data regarding laboratory and imaging studies is shown in Figure 1.

From the Division of Endocrinology, Diabetes, Metabolism, Nutrition, and Internal Medicine, Mayo Clinic, Rochester, MN. Address reprint requests to Dr. Young at the Division of Endocrinology, Diabetes, Metabolism, Nutrition, and Internal Medicine, Mayo Clinic, 200 First St. SW, Rochester, MN 55905, or at young.william@mayo.edu.

N Engl J Med 2007;356:601-10.

Copyright © 2007 Massachusetts Medical Society.

Table 1. Symptoms and Signs Suggestive of Adrenal Hyperfunction or Malignant Disease.

Disorder	Symptoms	Signs
Cushing's syndrome	Patient may be asymptomatic if disease is subclinical; symptoms may include weight gain with central obesity, facial rounding and plethora, supraclavicular and dorsocervical fat pads, easy bruising, thin skin, poor wound healing, purple striae, proximal muscle weakness, emotional and cognitive changes (e.g., irritability, spontaneous tearfulness, depression, and restlessness), opportunistic and fungal infections, altered reproductive function, acne, and hirsutism	Hypertension, osteopenia, osteoporosis, fasting hyperglycemia, diabetes mellitus, hypokalemia, hyperlipidemia, and leukocytosis with relative lymphopenia
Pheochromocytoma	Patient may be asymptomatic; episodic symptoms may occur in spells (paroxysms) that can be extremely variable in presentation but typically include forceful heartbeat, pallor, tremor, headache, and diaphoresis; spells may be either spontaneous or precipitated by postural change, anxiety, medications (e.g., metoclopramide, anesthetic agents), and maneuvers that increase intraabdominal pressure (e.g., change in position, lifting, defecation, exercise, colonoscopy, pregnancy, and trauma)	Hypertension (paroxysmal or sustained), orthostatic hypotension, pallor, retinopathy grades 1 to 4, tremor, and fever
Primary aldosteronism	If hypokalemia is present, nocturia, polyuria, muscle cramps, and palpitations may be present	Hypertension, mild or severe; possibly hypokalemia and mild hypernatremia
Adrenocortical carcinoma	Symptoms may include mass effect (e.g., abdominal pain) and symptoms related to adrenal hypersecretion of cortisol (Cushing's syndrome), androgens (hirsutism, acne, amenorrhea or oligomenorrhea, oily skin, and increased libido), estrogens (gynecomastia), or aldosterone (hypokalemia-related symptoms)	Hypertension, osteopenia, osteoporosis, fasting hyperglycemia, diabetes mellitus, hypokalemia, hyperlipidemia, and leukocytosis with relative lymphopenia
Metastatic cancer	History of an extraadrenal cancer	Cancer-specific signs

HORMONAL EVALUATION*Subclinical Cushing's Syndrome*

The term "subclinical" Cushing's syndrome is used to refer to autonomous cortisol secretion in patients who do not have the typical signs and symptoms of hypercortisolism. Although the obvious stigmata of Cushing's syndrome are absent, these patients may have the adverse effects of continuous, endogenous cortisol secretion, including hypertension, obesity, diabetes mellitus, and osteoporosis.⁹⁻¹³

In a report summarizing the results of 13 studies including 2005 patients with adrenal incidentalomas, autonomous cortisol secretion (independent of normal hypothalamic-pituitary control) was found in 5.3% of the patients.¹ Since such patients do not have clinical Cushing's syndrome and may have normal 24-hour urinary cortisol excretion, a measure of autonomous adrenocortical secretion is the best strategy for testing. Because there is no reliable way to distinguish between low-normal values and suppressed values with most commercially available corticotropin assays, adrenal autonomy is best assessed by an overnight dexamethasone (1 mg) suppression test (Table 2).^{1,14} Although the optimal cutoff value is debated, the use of a cortisol level greater than 5 μg per deciliter (138 nmol per liter) is

standard to define abnormal values according to this test,^{15,16} because this level is considered to be a reasonable criterion for clinically significant glucocorticoid secretory autonomy.¹⁵ The specificity of the 1-mg overnight dexamethasone suppression test is 91%^{17,18}; if the result is abnormal, confirmatory testing should be performed to rule out a false positive result (Table 2).

Data from randomized trials are lacking to guide the optimal management of subclinical Cushing's syndrome. A reasonable strategy is to consider adrenalectomy for younger patients (below the age of 40 years) and those with disorders that are potentially attributable to autonomous glucocorticoid secretion (e.g., the recent onset or worsening of underlying hypertension, diabetes mellitus, obesity, or osteoporosis). A patient with subclinical Cushing's syndrome should receive glucocorticoid therapy perioperatively because of the risks of adrenal insufficiency, hemodynamic crisis, and death.¹⁹ The need for longer-term replacement and slow tapering of exogenous glucocorticoids should be assessed postoperatively. In limited case series, weight loss, improvement in hypertension or glycemic control or both, and the normalization of markers of bone turnover were reported after unilateral adrenalectomy in patients with subclinical Cushing's syndrome.^{9,11,14}

Table 2. Laboratory Evaluation of the Patient with Adrenal Incidentaloma.

Possible Diagnosis	Screening Test	Causes of False Positive Results	Confirmatory Tests
Subclinical Cushing's syndrome	Overnight dexamethasone (1 mg) suppression test; abnormal result: serum cortisol, >5 µg per deciliter (138 nmol per liter); some clinicians use a higher dose of dexamethasone (e.g., 3 mg instead of the standard 1 mg) to reduce the possibility of a false positive result without a change in sensitivity	Medications that accelerate hepatic metabolism of dexamethasone (e.g., anti-convulsants); noncompliance with dexamethasone regimen	Consider the following tests: serum corticotropin, cortisol in a blood specimen and 24-hr urine specimen, midnight salivary measurement of cortisol, and a formal 2-day high-dose dexamethasone suppression test (the result is considered abnormal when the cortisol level in the 24-hr urine specimen is greater than the lower limit of the normal range for the local laboratory)
Pheochromocytoma	Measurement of fractionated metanephrines and catecholamines in a 24-hr urinary specimen; imaging phenotype may also suggest pheochromocytoma	Any situation (e.g., illness requiring hospitalization) or medication (e.g., tricyclic antidepressant) that increases endogenous production of catecholamines ⁷	Consider iodine-123 metaiodobenzylguanidine scintigraphy, MRI, subspecialty consultation, and surgery
Primary aldosteronism	Morning measurement of the plasma aldosterone concentration and plasma renin activity,* which can be performed while the patient is receiving any antihypertensive drug except spironolactone (Aldactone, Searle), eplerenone (Inspra, Pfizer), or high-dose amiloride (Midamor, Merck); the plasma aldosterone concentration and plasma renin activity ratio of ≥ 20 and a plasma aldosterone concentration of ≥ 15 ng per deciliter are positive results (but the cutoff for a positive result is laboratory-dependent)	Assay and biologic variability	To confirm the diagnosis of primary aldosteronism: aldosterone suppression testing with either a saline infusion test or 24-hour urinary aldosterone excretion test while the patient maintains a high-sodium diet ⁸ To confirm that the adrenal mass (and not bilateral adrenal hyperplasia) is the source of aldosterone excess in patients with documented primary aldosteronism, adrenal venous sampling should be considered ⁸

* In this test, values for the plasma aldosterone concentration are in nanograms per deciliter, and values for plasma renin activity are in nanograms per milliliter per hour.

Long-term prospective studies are needed to provide a better understanding of the natural history of subclinical Cushing's syndrome and better guidance for decisions regarding surgical intervention.

At least two reports have suggested that cortisol secretion may be normal when the adrenal incidentaloma is discovered but may become autonomous during a subsequent period of 4 years or longer.^{20,21} Until data are available from large prospective studies, these observations suggest that it is reasonable to repeat the hormonal screening annually for 4 years, as suggested by the National Institutes of Health (NIH) state-of-the-science statement.⁵

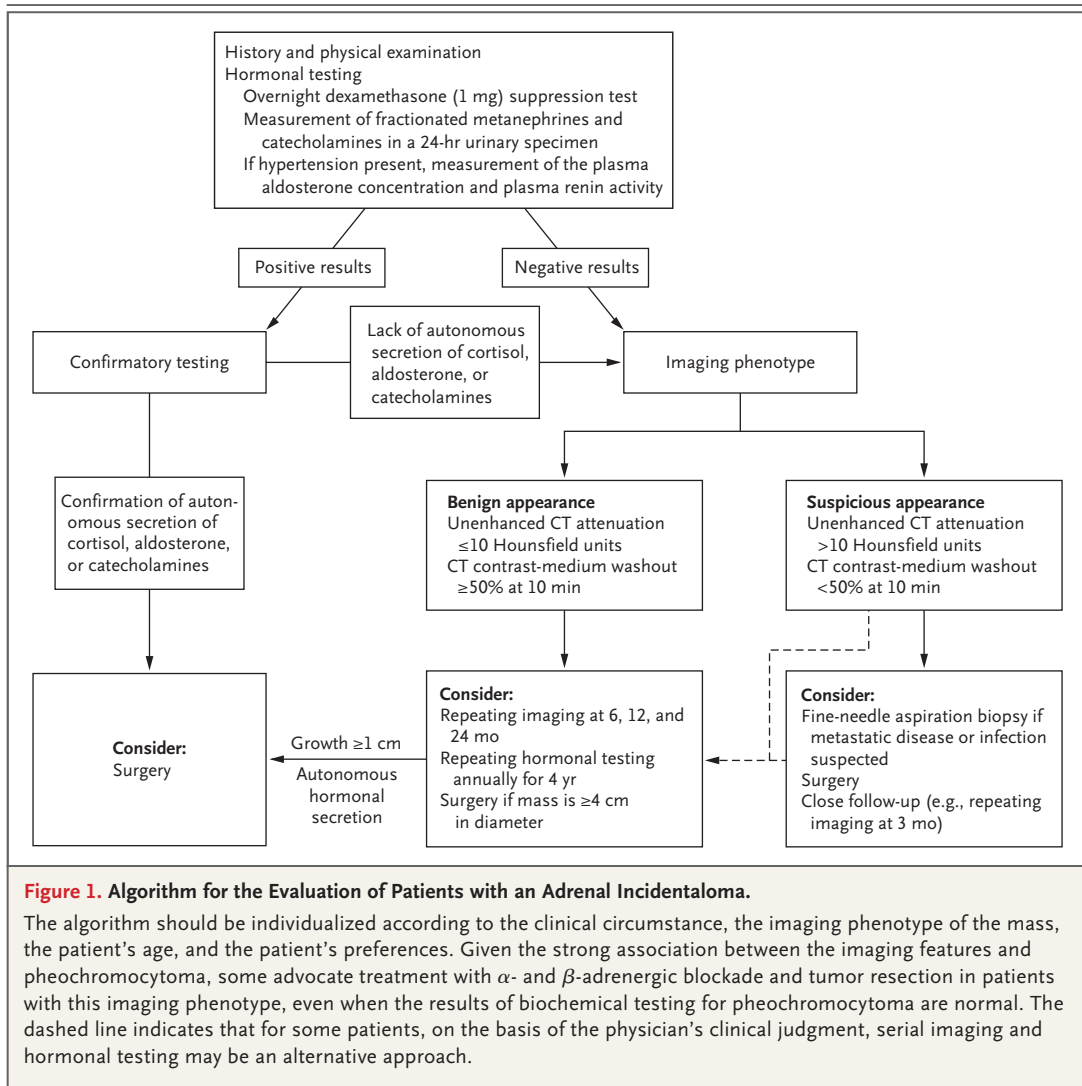
Clinically Silent Pheochromocytoma

Approximately 5% of adrenal incidentalomas have proved to be pheochromocytomas.¹ In one study, 19 of 33 adrenal pheochromocytomas (58%) were detected initially as incidental adrenal masses,

and only 10 of the 19 patients had hypertension.²² However, even clinically silent pheochromocytomas can be lethal.²³

The characteristics of an adrenal mass on imaging — the imaging phenotype — can be helpful in determining whether it is a pheochromocytoma¹ (Table 3). Findings consistent with (although not diagnostic of) pheochromocytoma include increased attenuation on unenhanced CT, prominent vascularity of the mass (Fig. 2A), delayed washout of contrast medium, and high signal intensity on T₂-weighted MRI.²²

Because not all pheochromocytomas have this phenotype and because the expertise of radiologists and clinicians in identifying this rare neoplasm can vary, biochemical assessment is warranted for all patients. Studies reporting the characteristics of biochemical tests for pheochromocytoma are based on data from both symptomatic and asymptomatic patients. The measurement of fractionated metanephrines and



catecholamines in a 24-hour urine specimen is recommended for all patients with adrenal incidentalomas; the detection of elevated levels of fractionated metanephrines, catecholamines, or both has high sensitivity and specificity for pheochromocytoma (91 to 98% in Mayo Clinic series, for both).^{8,26,27} The additional measurement of fractionated catecholamines in the 24-hour urinary specimen increases the sensitivity of this approach by 5%⁸ and is especially helpful in diagnosing patients with dopamine-secreting neoplasms.²⁶ If the suspicion of subclinical pheochromocytoma is high on the basis of the imaging phenotype but the results of 24-hour urinary studies are normal, the measurement of fractionated plasma free metanephrines (available at most ref-

erence laboratories) may be useful.²⁸ Although elevated levels of fractionated plasma metanephrines have high sensitivity for pheochromocytoma (96 to 100%),^{26,28} the test has low specificity (85 to 89% overall^{26,28,29} and 77% in patients older than 60 years).²⁶ Thus, the measurement of fractionated plasma metanephrines is recommended only when suspicion is high, to minimize the risk of false positive results that might lead to unnecessary surgery.

Primary Aldosteronism

Approximately 1% of adrenal incidentalomas have proved to be aldosterone-producing adenomas.¹ Excessive secretion of aldosterone is associated with an increased risk of cardiovascular disease

Table 3. Characteristics of Adrenal Incidentalomas on Imaging (Imaging Phenotype).*

Variable	Adrenocortical Adenoma	Adrenocortical Carcinoma	Pheochromocytoma	Metastasis
Size	Small, usually ≤ 3 cm in diameter	Large, usually > 4 cm in diameter	Large, usually > 3 cm in diameter	Variable, frequently < 3 cm
Shape	Round or oval, with smooth margins	Irregular, with unclear margins	Round or oval, with clear margins	Oval or irregular, with unclear margins
Texture	Homogeneous	Heterogeneous, with mixed densities	Heterogeneous, with cystic areas	Heterogeneous, with mixed densities
Laterality	Usually solitary, unilateral	Usually solitary, unilateral	Usually solitary, unilateral	Often bilateral
Attenuation (density) on unenhanced CT	≤ 10 Hounsfield units	> 10 Hounsfield units (usually > 25)	> 10 Hounsfield units (usually > 25)	> 10 Hounsfield units (usually > 25)
Vascularity on contrast-enhanced CT	Not highly vascular	Usually vascular	Usually vascular	Usually vascular
Rapidity of washout of contrast medium	$\geq 50\%$ at 10 minutes	$< 50\%$ at 10 minutes	$< 50\%$ at 10 minutes	$< 50\%$ at 10 minutes
Appearance on MRI [†]	Isointense in relation to liver on T ₂ -weighted image	Hyperintense in relation to liver on T ₂ -weighted image	Markedly hyperintense in relation to liver on T ₂ -weighted image	Hyperintense in relation to liver on T ₂ -weighted image
Necrosis, hemorrhage, or calcifications	Rare	Common	Hemorrhage and cystic areas common	Occasional hemorrhage and cystic areas
Growth rate	Usually stable over time or very slow (< 1 cm per year)	Usually rapid (> 2 cm per year)	Usually slow (0.5 cm to 1.0 cm per year)	Variable, slow to rapid

* Adrenal hemorrhage and myelolipoma are usually easily characterized because of their distinctive imaging characteristics.^{24,25} Myelolipomas are composed of myeloid, erythroid, and adipose tissue. On imaging, they have low attenuation on unenhanced CT, and they are hyperintense on T₁-weighted in-phase MRI. The presence of pure fat within an adrenal lesion on CT is consistent with the presence of a myelolipoma. Acute adrenal hemorrhage has increased attenuation on unenhanced CT, and on T₁-weighted MRI, there is hyperintensity secondary to methemoglobin. In a chronic adrenal hemorrhage, a dark rim develops along the periphery of the mass on the T₂-weighted image because of the hemosiderin-laden macrophages.

[†] If the imaging characteristics are indeterminate on both unenhanced and enhanced CT, MRI may be considered to clarify the imaging phenotype.

and other disorders,⁷ and the normalization of circulating aldosterone levels or mineralocorticoid receptor blockade is warranted in patients with excessive secretion of aldosterone.⁸ Screening for hyperaldosteronism is routinely recommended for hypertensive patients who have an adrenal incidentaloma. Given that patients with aldosterone-producing adenomas may have normal levels of potassium in the blood,³⁰ the measurement of potassium levels is not reliable in screening. A reasonable screening test is the ratio of the ambulatory morning plasma aldosterone concentration to plasma renin activity (Table 2).^{30,31} If this ratio is high, the diagnosis of primary aldosteronism should be confirmed by an additional measurement of mineralocorticoid secretory autonomy (Table 2).⁸

Other Hormonally Active Processes

Sex hormone-secreting adrenocortical tumors are rare and typically occur in the presence of clinical

manifestations (e.g., hirsutism or virilization).¹ Routine screening for excess androgens or estrogens in patients with adrenal incidentalomas is therefore not warranted.

Nonclassic congenital adrenal hyperplasia is another infrequent cause of adrenal incidentalomas (unilateral or bilateral).¹ Cosyntropin-stimulation testing with the measurement of cortisol precursors (e.g., 17-hydroxyprogesterone) is not routinely recommended but, rather, should be reserved for patients in whom the diagnosis is suspected on the basis of clinical manifestations (e.g., hyperandrogenism) or the presence of bilateral adrenal masses.

ASSESSMENT OF MALIGNANT POTENTIAL

The possibility of malignant disease is the major concern when an incidental adrenal mass is identified. Among 2005 patients in whom adrenal incidentalomas were detected, adrenocortical carcinoma was found in 4.7% of the patients and

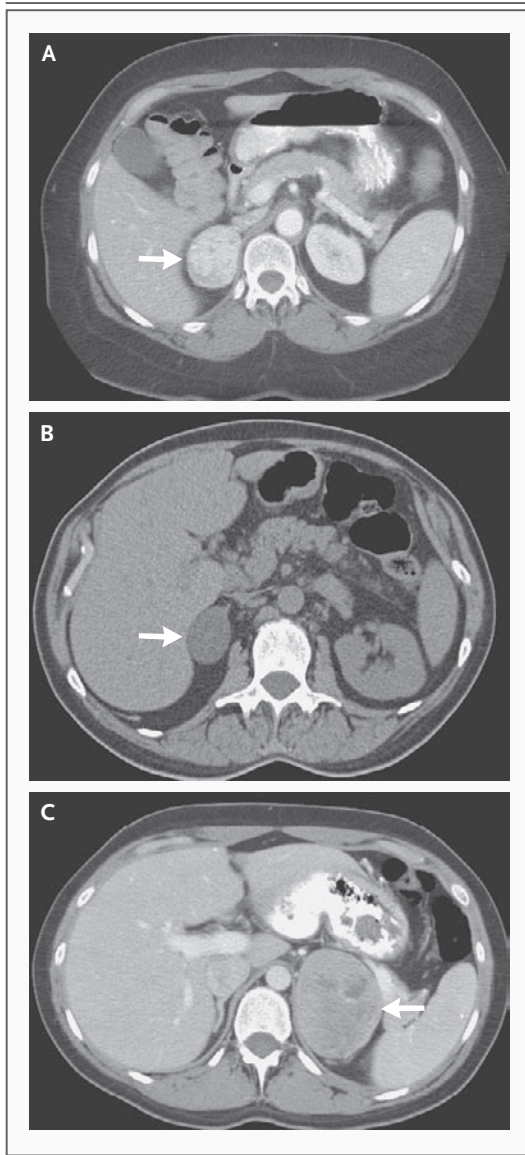


Figure 2. Pheochromocytoma (Panel A), Benign Cortical Adenoma (Panel B), and Adrenocortical Carcinoma (Panel C).

A heterogeneous (vascular), contrast-enhanced, right adrenal mass, 4.5 cm in diameter (Panel A, arrow), was incidentally revealed on abdominal CT in a 48-year-old woman who was being evaluated for possible appendicitis. The unenhanced CT attenuation was 40 Hounsfield units, and the contrast-medium washout was less than 50% at 10 minutes. The patient had no symptoms or signs of pheochromocytoma. Both urine and plasma normetanephrine levels were markedly elevated. She was treated with α - and β -adrenergic blockade, and a pheochromocytoma was removed. A right adrenal mass (Panel B, arrow), 3.6 cm by 2.5 cm, was incidentally discovered on abdominal CT (performed because of diffuse abdominal discomfort) in a 62-year-old woman with normal blood pressure. The unenhanced CT density (-10 Hounsfield units) and the contrast-medium washout of more than 50% at 10 minutes were consistent with the presence of a cortical adenoma. Hormonal testing for subclinical Cushing's syndrome and pheochromocytoma was negative. The patient is being followed with repeated imaging and hormonal testing. A heterogeneous, contrast-enhanced, left adrenal mass (Panel C, arrow), 7.5 cm by 5.5 cm by 6.5 cm, was detected on abdominal CT after measurement of a minimally elevated level of 24-hour urinary 5-hydroxyindoleacetic acid in a 27-year-old woman who had flushing and loose stools. The unenhanced CT attenuation was greater than 10 Hounsfield units, and the contrast-medium washout at 10 minutes was below 50%. Hormonal testing revealed that the mass was nonfunctioning. A laparotomy was performed to remove the mass; the finding on pathological examination was adrenocortical carcinoma.

metastatic cancer in 2.5%.¹ The size of the mass and its appearance on imaging are the two major predictors of malignant disease.

Size of Adrenal Mass

In a report involving 887 patients who had adrenal incidentalomas,³² a diameter greater than 4 cm was shown to have 90% sensitivity for the detection of adrenocortical carcinoma but low specificity; only 24% of lesions greater than 4 cm in diameter were malignant.³² Size is also important because the smaller an adrenocortical carcinoma is at the time of diagnosis, the lower the tumor stage is and the better the overall prognosis will be.³³ Although most experts would recom-

mend resection of adrenal masses larger than 6 cm in diameter,⁵ decisions regarding surgery should also take into account the imaging phenotype of the mass, as well as the patient's age and any co-existing conditions. For example, a nonfunctioning adrenal incidentaloma that is 6.5 cm in diameter and has a benign imaging phenotype may be reasonably followed in an octogenarian. Because the prevalence of benign adrenal cortical adenomas increases with age, the finding of a nonfunctioning adrenal mass that is 3.2 cm in diameter in a younger patient (e.g., below the age of 30 years) should increase the suspicion of an alternative diagnosis. The size of an adrenal incidentaloma does not affect recommendations regarding biochemical testing.

Imaging Phenotype

The CT features used to distinguish adenomas from nonadenomas are the lipid content of the

adrenal mass and rapidity of the washout of contrast medium (Table 3).³⁴ The intracytoplasmic fat in adenomas results in low attenuation on unenhanced CT (Fig. 2B); nonadenomas have higher attenuation on unenhanced CT.³⁴ On chemical-shift MRI (a form of lipid-sensitive imaging that is routinely used), benign adrenocortical adenomas lose signal on out-of-phase images, as compared with in-phase images.³⁵ However, up to 30% of adenomas do not contain large amounts of lipid and may be indistinguishable from nonadenomas on both unenhanced CT and chemical-shift MRI.³⁴

On delayed contrast-enhanced CT, adenomas typically exhibit rapid washout of contrast medium, whereas other adrenal nonadenomas have delayed washout of contrast material (Table 3).³⁶ Ten minutes after the administration of the contrast medium, an absolute washout of more than 50% of the contrast medium was reported to be 100% sensitive and specific for adenoma in a comparison between patients with adenomas and those with carcinomas, pheochromocytomas, or metastatic disease.^{34,36,37} Although the imaging phenotype does not predict hormonal function, it does predict the underlying pathology, and surgical resection should be considered for patients who have adrenal incidentalomas with a suspicious imaging phenotype (Fig. 2C).

Metastatic Disease

Metastases are the cause of the adrenal incidentaloma in approximately half of patients who have a history of malignant disease.³⁸ Tumors that commonly metastasize to the adrenals include carcinomas of the lung, kidney, colon, breast, esophagus, pancreas, liver, and stomach (Fig. 3A and 3B).³⁹ Metastases to the adrenal glands are frequently bilateral. The primary cancer usually has already been recognized when an adrenal incidentaloma is discovered; metastatic cancer to the adrenal without a known primary cancer is extremely rare.⁴⁰

Positron-emission tomography (PET) with ¹⁸F-fluorodeoxyglucose (¹⁸F-FDG) can be helpful in selected patients (those with a history of malignant disease) because of its high sensitivity in detecting malignant diseases.⁴¹ However, 16% of benign adrenal lesions may have greater FDG-PET uptake than the background uptake.⁴¹ The absence of activity on ¹¹C-metomidate (MTO)-PET appears to be specific for tumors of nonadreno-

cortical origin (e.g., pheochromocytomas and metastatic disease),⁴² but this type of imaging is not routinely available. Because of their cost and because there are insufficient data to support their routine use, FDG-PET and MTO-PET are not recommended for the evaluation of a patient with an adrenal incidentaloma who does not have a history of malignant disease.

Fine-Needle Aspiration Biopsy

The primary role of fine-needle aspiration biopsy is to differentiate between adrenal tissue and non-adrenal tissues (e.g., metastases or infection).⁴³⁻⁴⁵ Image-guided fine-needle aspiration biopsy is relatively safe; the complication rate was 2.8% in one series of 277 biopsies.⁴⁵ The risks of this procedure include adrenal hematoma, abdominal pain, hematuria, pancreatitis, pneumothorax, formation of an adrenal abscess, and tumor recurrence along the needle track.^{1,44,45} Also, fine-needle aspiration biopsy of a pheochromocytoma may result in hemorrhage and hypertensive crisis, and the possibility of pheochromocytoma should always be ruled out by biochemical testing before fine-needle aspiration biopsy is undertaken.^{46,47}

BILATERAL ADRENAL MASSES

When adrenal masses occur bilaterally (as they do in up to 15% of patients with adrenal incidentaloma),^{20,32} the most likely diagnoses are metastatic disease, congenital adrenal hyperplasia, bilateral cortical adenomas, and infiltrative disease of the adrenal glands.¹ Adrenocortical hypofunction may occur in patients with bilateral adrenal masses, so screening for adrenocortical hypofunction may be prudent in such patients, although the yield is unknown.

AREAS OF UNCERTAINTY

The optimal frequency and duration of follow-up for patients who have adrenal incidentalomas are uncertain, and prospective data to guide the clinician are scarce. Repeated imaging is commonly recommended at 6, 12, and 24 months; earlier follow-up (at 3 months) has been suggested when the imaging phenotype is suspicious (Fig. 1), with the rationale that many malignant lesions will grow during this 3-month interval (Fig. 3A and 3B), resulting in earlier intervention. However, the yield and cost-effectiveness of repeated imaging at these intervals are uncertain. On the basis of our

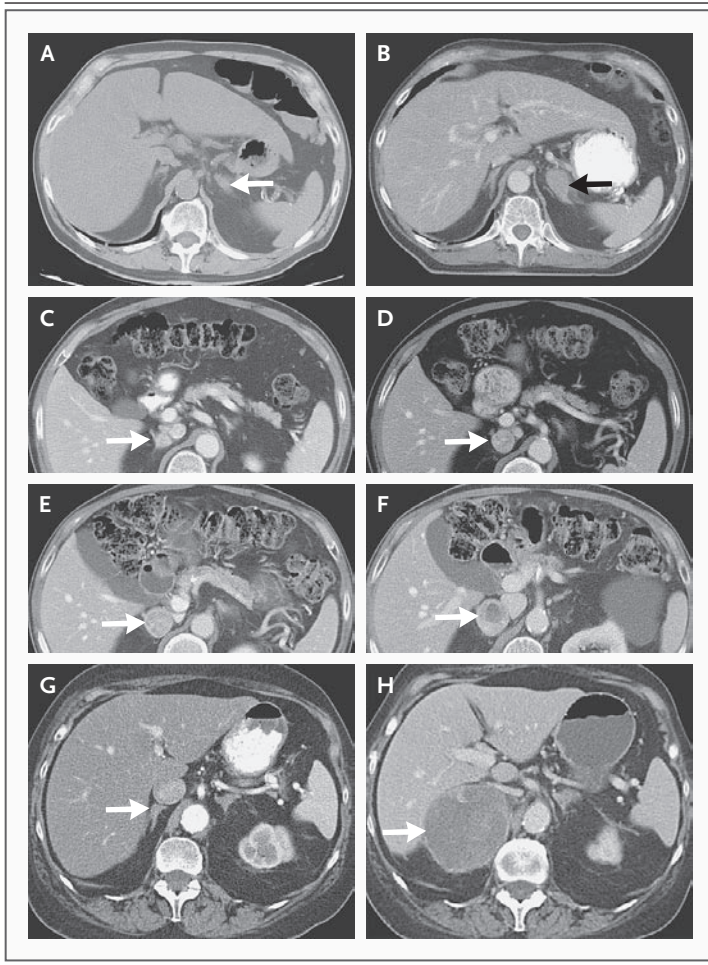


Figure 3. Serial CT Scans Showing Metastatic Disease to the Adrenal Gland (Panels A and B), a Benign Pheochromocytoma (Panels C through F), and Adrenocortical Carcinoma (Panels G and H).

On abdominal CT in a 63-year-old man with a history of colon cancer, a mass, 1.0 cm in diameter, was found in the left adrenal gland (Panel A, arrow); an image obtained 3 months later shows marked growth of the mass (3 cm in diameter) (Panel B, arrow). After biochemical testing had ruled out pheochromocytoma, a diagnosis of metastatic colon cancer was confirmed on CT-guided fine-needle aspiration biopsy. On initial CT performed to evaluate nephrolithiasis in a 66-year-old man, a right adrenal mass, 1.7 cm by 1.3 cm (Panel C, arrow), was incidentally discovered. Two years later (after prostate cancer had been diagnosed), CT revealed that the right adrenal mass had enlarged (2.6 cm by 2.4 cm) (Panel D, arrow). Repeated CT after an additional 2 years of follow-up showed further growth of the mass (3.2 cm by 2.9 cm) (Panel E, arrow); another follow-up scan obtained 1 year later (i.e., 5 years after the mass was initially noted) showed further enlargement of the mass (3.8 cm by 3.3 cm) (Panel F, arrow). The patient did not have symptoms of pheochromocytoma. He had long-standing hypertension that was treated with a single antihypertensive agent until 2001, when poor blood-pressure control required the addition of two more antihypertensive agents. In 2002, diabetes mellitus developed. Although his urine and plasma normetanephrine levels had not been checked previously, on testing in July 2005, they were found to be markedly elevated. The patient was treated with α - and β -adrenergic blockade, followed by laparoscopic adrenalectomy; the pathological examination confirmed the diagnosis of pheochromocytoma. At follow-up 1 year after surgery, the diabetes mellitus had resolved and the hypertension was well controlled with one agent. On abdominal CT in a 69-year-old woman with pulmonary symptoms, a slightly thickened right adrenal gland was found (Panel G, arrow). Two years later, an image obtained to evaluate right upper quadrant abdominal pain showed a right adrenal mass, 8.0 cm by 6.5 cm by 6.0 cm (Panel H, arrow). The results of biochemical testing were normal. The patient underwent an open procedure for resection of a nonfunctional adrenocortical carcinoma.

unpublished experience with nine patients who underwent serial imaging, the typical rate of growth of benign adrenal pheochromocytoma is approximately 0.5 to 1.0 cm in diameter per year (Fig. 3C through 3F), whereas adrenocortical carcinomas typically have a rapid growth rate (>2 cm per year) (Fig. 3G and 3H). However, most adrenal masses that grow are not malignant. In case series of adrenal incidentalomas followed for an average of 4 years, 5 to 20% increased in size, and 1.3 to 5.2% decreased in size.^{1,21,48} In two of these series, only 1 of 9 patients and none of 11 patients with enlarging adrenal masses who underwent surgery were found to have malignant tumors.^{21,48} Less frequent imaging during follow-up is reasonable for patients who have no history of malignant disease and who have small (<2 cm), uniform, hypodense cortical nodules.

The observation that abnormal adrenal function (secretion of glucocorticoids and catecholamines) that is not present at baseline may be de-

tected during follow-up testing^{21,48,49} has led to the recommendation of repeating hormonal evaluation annually for at least 4 years when the initial evaluation is negative.^{5,48,49} However, the yield and cost-effectiveness of such testing are unknown.

GUIDELINES

No comprehensive guidelines have been published by professional societies to guide the evaluation of patients with adrenal incidentalomas. The rec-

ommendations given here are in general agreement with the NIH state-of-the-science statement on adrenal incidentalomas, which was published in 2003.⁵

CONCLUSIONS AND RECOMMENDATIONS

For the patient described in the vignette, a thorough history should be obtained and a physical examination performed to assess the evidence of adrenal hormone excess (Table 1). I would perform a 1-mg overnight dexamethasone suppression test, collect a 24-hour urinary specimen for measurement of fractionated metanephrines and catecholamines, and (because she has hypertension) measure the plasma aldosterone concentration and plasma renin activity. If the results of the initial hormonal testing are consistent with autonomous hormone secretion, and if this finding is confirmed by subsequent studies, unilateral laparoscopic adrenalectomy should be considered.

The adrenal imaging should be reviewed with a radiologist. If the imaging phenotype suggests infection or metastatic disease, CT-guided fine-needle aspiration biopsy should be considered (after biochemical testing to rule out pheochromocytoma). If the results of hormonal testing are normal and the imaging features are consistent with benign disease, I would recommend repeating the imaging studies at 6, 12, and 24 months and repeating the hormonal evaluation yearly for 4 years, even though there are no data from large, long-term studies to support these recommendations. Although the data are also scarce to suggest when surgery is necessary, I would recommend consideration of adrenalectomy if the adrenal mass is 4 cm or greater in diameter, if the mass enlarges by 1 cm or more during the period of observation, or if evidence of autonomous hormonal secretion develops.

No potential conflict of interest relevant to this article was reported.

REFERENCES

- Young WF Jr. Management approaches to adrenal incidentalomas: a view from Rochester, Minnesota. *Endocrinol Metab Clin North Am* 2000;29:159-85.
- Kloos RT, Gross MD, Francis IR, Korobkin M, Shapiro B. Incidentally discovered adrenal masses. *Endocr Rev* 1995;16:460-84.
- Bovio S, Cataldi A, Reimondo G, et al. Prevalence of adrenal incidentaloma in a contemporary computerized tomography series. *J Endocrinol Invest* 2006;29:298-302.
- Mansmann G, Lau J, Balk E, Rothberg M, Miyachi Y, Bornstein SR. The clinically inapparent adrenal mass: update in diagnosis and management. *Endocr Rev* 2004;25:309-40.
- Grumbach MM, Biller BM, Braunstein GD, et al. Management of the clinically inapparent adrenal mass ("incidentaloma"). *Ann Intern Med* 2003;138:424-9.
- Brunaud L, Kebebew E, Sebag F, Zarnegar R, Clark OH, Duh QY. Observation or laparoscopic adrenalectomy for adrenal incidentaloma? A surgical decision analysis. *Med Sci Monit* 2006;12:CR355-CR362.
- Kudva YC, Sawka AM, Young WF Jr. The laboratory diagnosis of adrenal pheochromocytoma: the Mayo Clinic experience. *J Clin Endocrinol Metab* 2003;88:4533-9.
- Young WF Jr. Primary aldosteronism: renaissance of a syndrome. *Clin Endocrinol (Oxf)* (in press).
- Erbil Y, Ademoglu E, Ozbey N, et al. Evaluation of the cardiovascular risk in patients with subclinical Cushing syndrome before and after surgery. *World J Surg* 2006;30:1665-71.
- Chiodini I, Tauchmanova L, Torlontano M, et al. Bone involvement in eugonadal male patients with adrenal incidentaloma and subclinical hypercortisolism. *J Clin Endocrinol Metab* 2002;87:5491-4.
- Rossi R, Tauchmanova L, Luciano A, et al. Subclinical Cushing's syndrome in patients with adrenal incidentaloma: clinical and biochemical features. *J Clin Endocrinol Metab* 2000;85:1440-8.
- Terzolo M, Pia A, Ali A, et al. Adrenal incidentaloma: a new cause of the metabolic syndrome? *J Clin Endocrinol Metab* 2002;87:998-1003.
- Tauchmanova L, Rossi R, Biondi B, et al. Patients with subclinical Cushing's syndrome due to adrenal adenoma have increased cardiovascular risk. *J Clin Endocrinol Metab* 2002;87:4872-8.
- Emral R, Uysal AR, Asik M, et al. Prevalence of subclinical Cushing's syndrome in 70 patients with adrenal incidentaloma: clinical, biochemical and surgical outcomes. *Endocr J* 2003;50:399-408.
- Nugent CA, Nichols T, Tyler FH. Diagnosis of Cushing's syndrome: single dose dexamethasone suppression test. *Arch Intern Med* 1965;116:172-6.
- Tsagarakis S, Vassiliadi D, Thalassinou N. Endogenous subclinical hypercortisolism: diagnostic uncertainties and clinical implications. *J Endocrinol Invest* 2006;29:471-82.
- Tsagarakis S, Roboti C, Kokkoris P, Vasiliou V, Alevizaki C, Thalassinou N. Elevated post-dexamethasone suppression cortisol concentrations correlate with hormonal alterations of the hypothalamopituitary adrenal axis in patients with adrenal incidentalomas. *Clin Endocrinol (Oxf)* 1998;49:165-71.
- Gorges R, Knappe G, Gerl H, Ventz M, Stahl F. Diagnosis of Cushing's syndrome: re-evaluation of midnight plasma cortisol vs urinary free cortisol and low-dose dexamethasone suppression test in a large patient group. *J Endocrinol Invest* 1999;22:241-9.
- McLeod MK, Thompson NW, Gross MD, Bondeson AG, Bondeson L. Sub-clinical Cushing's syndrome in patients with adrenal gland incidentalomas: pitfalls in diagnosis and management. *Am Surg* 1990;56:398-403.
- Barzon L, Fallo F, Sonino N, Boscaro M. Development of overt Cushing's syndrome in patients with adrenal incidentaloma. *Eur J Endocrinol* 2002;146:61-6.
- Libe R, Dall'Asta C, Barbetta L, Baccarelli A, Beck-Peccoz P, Ambrosi B. Long-term follow-up study of patients with adrenal incidentalomas. *Eur J Endocrinol* 2002;147:489-94.
- Motta-Ramirez GA, Remer EM, Herts BR, Gill IS, Hamrahian AH. Comparison of CT findings in symptomatic and incidentally discovered pheochromocytomas. *AJR Am J Roentgenol* 2005;185:684-8.
- Sutton MG, Sheps SG, Lie JT. Prevalence of clinically unsuspected pheochromocytoma: review of a 50-year autopsy series. *Mayo Clin Proc* 1981;56:354-60.

24. Meyer A, Behrend M. Presentation and therapy of myelolipoma. *Int J Urol* 2005;12:239-43.
25. Ikeda O, Urata J, Araki Y, et al. Acute adrenal hemorrhage after blunt trauma. *Abdom Imaging* (in press).
26. Sawka AM, Jaeschke R, Singh RJ, Young WF Jr. A comparison of biochemical tests for pheochromocytoma: measurement of fractionated plasma metanephrines compared with the combination of 24-hour urinary metanephrines and catecholamines. *J Clin Endocrinol Metab* 2003;88:553-8.
27. Perry CG, Sawka AM, Singh R, Thabane L, Bajnarek J, Young WF Jr. The diagnostic efficacy of urinary fractionated metanephrines measured by tandem mass spectrometry in detection of pheochromocytoma. *Clin Endocrinol (Oxf)* (in press).
28. Lenders JW, Pacak K, Walther MM, et al. Biochemical diagnosis of pheochromocytoma: which test is best? *JAMA* 2002;287:1427-34.
29. Sawka AM, Prebtani AP, Thabane L, Gafni A, Levine M, Young WF Jr. A systematic review of the literature examining the diagnostic efficacy of measurement of fractionated plasma free metanephrines in the biochemical diagnosis of pheochromocytoma. *BMC Endocr Disord* 2004;4:2.
30. Mulatero P, Stowasser M, Loh K-C, et al. Increased diagnosis of primary aldosteronism, including surgically correctable forms, in centers from five continents. *J Clin Endocrinol Metab* 2004;89:1045-50.
31. Montori VM, Young WF Jr. Use of plasma aldosterone concentration-to-plasma renin activity ratio as a screening test for primary aldosteronism: a systematic review of the literature. *Endocrinol Clin North Am* 2002;31:619-32.
32. Angeli A, Osella G, Ali A, Terzolo M. Adrenal incidentaloma: an overview of clinical and epidemiological data from the National Italian Study Group. *Horm Res* 1997;47:279-83.
33. Allolio B, Fassnacht M. Adrenocortical carcinoma: clinical update. *J Clin Endocrinol Metab* 2006;91:2027-37.
34. Szolar DH, Korobkin M, Reittner P, et al. Adrenocortical carcinomas and adrenal pheochromocytomas: mass and enhancement loss evaluation at delayed contrast-enhanced CT. *Radiology* 2005;234:479-85.
35. Hussain HK, Korobkin M. MR imaging of the adrenal glands. *Magn Reson Imaging Clin N Am* 2004;12:515-44.
36. Korobkin M, Brodeur FJ, Francis IR, Quint LE, Dunnick NR, Londy F. CT time-attenuation washout curves of adrenal adenomas and nonadenomas. *AJR Am J Roentgenol* 1998;170:747-52.
37. Pena CS, Boland GW, Hahn PF, Lee MJ, Mueller PR. Characterization of indeterminate (lipid-poor) adrenal masses: use of washout characteristics at contrast-enhanced CT. *Radiology* 2000;217:798-802.
38. Lenert JT, Barnett CC Jr, Kudelka AP, et al. Evaluation and surgical resection of adrenal masses in patients with a history of extra-adrenal malignancy. *Surgery* 2001;130:1060-7.
39. Hess KR, Varadhachary GR, Taylor SH, et al. Metastatic patterns in adenocarcinoma. *Cancer* 2006;106:1624-33.
40. Lee JE, Evans DB, Hickey RC, et al. Unknown primary cancer presenting as an adrenal mass: frequency and implications for diagnostic evaluation of adrenal incidentalomas. *Surgery* 1998;124:1115-22.
41. Yun M, Kim W, Alnafisi N, Lacorte L, Jang S, Alavi A. 18F-FDG PET in characterizing adrenal lesions detected on CT or MRI. *J Nucl Med* 2001;42:1795-9.
42. Hennings J, Lindhe O, Bergstrom M, Langstrom B, Sundin A, Hellman P. [11C]metomidate positron emission tomography of adrenocortical tumors in correlation with histopathological findings. *J Clin Endocrinol Metab* 2006;91:1410-4.
43. Harisinghani MG, Maher MM, Hahn PF, et al. Predictive value of benign percutaneous adrenal biopsies in oncology patients. *Clin Radiol* 2002;57:898-901.
44. Arellano RS, Harisinghani MG, Gervais DA, Hahn PF, Mueller PR. Image-guided percutaneous biopsy of the adrenal gland: review of indications, technique, and complications. *Curr Probl Diagn Radiol* 2003;32:3-10.
45. Welch TJ, Sheedy PF II, Stephens DH, Johnson CM, Swensen SJ. Percutaneous adrenal biopsy: review of a 10-year experience. *Radiology* 1994;193:341-4.
46. Casola G, Nicolet V, vanSonnenberg E, et al. Unsuspected pheochromocytoma: risk of blood-pressure alterations during percutaneous adrenal biopsy. *Radiology* 1986;159:733-5.
47. McCorkell SJ, Niles NL. Fine-needle aspiration of catecholamine-producing adrenal masses: a possibly fatal mistake. *AJR Am J Roentgenol* 1985;145:113-4.
48. Bulow B, Jansson S, Juhlin C, et al. Adrenal incidentaloma — follow-up results from a Swedish prospective study. *Eur J Endocrinol* 2006;154:419-23.
49. Barzon L, Scaroni C, Sonino N, Fallo F, Paoletta A, Boscaro M. Risk factors and long-term follow-up of adrenal incidentalomas. *J Clin Endocrinol Metab* 1999;84:520-6.

Copyright © 2007 Massachusetts Medical Society.

COLLECTIONS OF ARTICLES ON THE JOURNAL'S WEB SITE

The Journal's Web site (www.nejm.org) sorts published articles into more than 50 distinct clinical collections, which can be used as convenient entry points to clinical content. In each collection, articles are cited in reverse chronological order, with the most recent first.