

## Regional Anesthesia and Pain

# The infraclavicular brachial plexus block by the coracoid approach is clinically effective: an observational study of 150 patients

*[Le bloc infraclaviculaire du plexus brachial, réalisé par l'approche coracoïde, est efficace sur le plan clinique : une étude prospective de 150 patients]*

Jean Desroches MD FRCPC

**Purpose:** To evaluate the sensory distribution, motor block and the clinical efficacy of the infraclavicular block by the coracoid approach.

**Methods:** In this prospective descriptive study, 150 patients received an infraclavicular block by the coracoid approach performed by a single anesthesiologist. Neurostimulation was used and 40 mL of mepivacaine 1.5% with adrenaline were injected. Block performance time, sensory distribution, motor block and tourniquet tolerance were evaluated.

**Results:** Time to perform the block was  $5 \pm 2$  min (mean  $\pm$  SD). Success rate defined as analgesia in the five nerves distal to the elbow (musculocutaneous, median, ulnar, radial and medial cutaneous nerve of the forearm) was 91% (137 patients). A proximal block of the axillary nerve was present in 98.5% of the patients and of the medial cutaneous nerve of the arm in 60%. An arm tourniquet (250 mmHg of pressure) was applied to 115 of the 137 patients with a successful block and all tolerated the tourniquet for a duration of  $37 \pm 21$  min (mean  $\pm$  SD).

**Conclusion:** Infraclavicular block by the coracoid approach provides an extensive sensory distribution with an excellent tourniquet tolerance. We conclude that this approach provides highly consistent brachial plexus anesthesia for upper extremity surgery.

**Objectif:** Évaluer la distribution du bloc sensitif, le bloc moteur et l'efficacité clinique du bloc infraclaviculaire par l'approche coracoïde.

**Méthode :** Dans cette étude prospective et descriptive, un bloc infraclaviculaire a été réalisé selon l'approche coracoïde par un même anesthésiologiste chez 150 patients. La neurostimulation a été utilisée

et 40 mL de mépivacaine à 1,5 % avec adrénaline ont été injectés. Le temps pour réaliser le bloc, la distribution sensitive, le degré de bloc moteur et la tolérance au garrot ont été évalués.

**Résultats :** Le temps pour réaliser le bloc a été de  $5 \pm 2$  min (moyenne  $\pm$  écart type). L'efficacité définie par l'analgesie dans les cinq nerfs distaux au coude (musculocutané, médian, cubital, radial et le nerf brachial cutané interne) a été de 91 % (137 patients). Une extension proximale du bloc au nerf circonflexe était présente chez 98,5 % des patients et au nerf accessoire du brachial cutané interne chez 60 %. Un garrot (pression de 250 mmHg) a été utilisé chez 115 des 137 patients avec un bloc efficace et tous ont toléré le garrot pour une durée de  $37 \pm 21$  min (moyenne  $\pm$  écart type).

**Conclusion :** Le bloc infraclaviculaire réalisé selon l'approche coracoïde produit un bloc sensitif étendu avec une excellente tolérance du garrot. Cette approche produit donc de façon hautement prévisible une anesthésie du plexus brachial permettant la chirurgie du membre supérieur.

**T**HE infraclavicular approach to a brachial plexus block was first described in the early 20<sup>th</sup> century by Bazy and was even included in Labat's textbook: *Regional Anesthesia* in 1930.<sup>1</sup> It was not until 1973 that a new infraclavicular approach was introduced by Raj.<sup>2</sup> Raj considered that the axillary approach had certain limitations that he expressed as follows: 1) the block can only be performed when the arm is abducted to 90 or

From the Department of Anesthesia, Hôtel-Dieu de Saint-Jérôme, Saint-Jérôme, Québec, Canada.

Address correspondence to: Dr. Jean Desroches, Department of Anesthesia, Hôtel-Dieu de Saint-Jérôme, 290 rue Montigny, Saint-Jérôme, Québec J7Z 5T3, Canada. Phone: 450-431-8200; Fax: 450-431-8208; E-mail: jean.desroches@sympatico.ca

Accepted for publication August 12, 2002.

Revision accepted November 12, 2002.

more; 2) it is difficult to block the musculocutaneous and axillary nerves; 3) whenever a tourniquet is to be used, the intercostobrachial nerve has to be blocked by additional infiltration. The infraclavicular approach was developed in the hope to overcome these limitations, but widespread use of Raj's infraclavicular brachial approach seems not to have materialized.<sup>3</sup> Clinical data on Raj's infraclavicular block are lacking. We can only speculate that it has not gained widespread use because of unreliable results; indeed a recent study has shown, with the aid of magnetic resonance imaging, the lack of precision in needle placement with this approach.<sup>4</sup> There have been, however, numerous descriptions of new infraclavicular approaches varying in their site of needle insertion, success and complication rate.<sup>5-10</sup> Wilson *et al.*<sup>6</sup> described in 1998 an infraclavicular coracoid technique that we have since then adopted in our community hospital. The aim of their study was to use magnetic resonance imaging and cadaveric sections to establish the orientation and depth of needle placement required to reach the brachial plexus by this coracoid approach. Few clinical results with this specific infraclavicular approach have been published, even though it has gained acceptance in some American institutions.<sup>A</sup> This study was undertaken to evaluate the sensory distribution of the infraclavicular brachial plexus block by the coracoid approach and its clinical efficacy.

### Methods

This is a prospective descriptive study where consecutive patients scheduled for elective or urgent hand, wrist, forearm or elbow surgery were recruited after obtaining informed consent for a brachial plexus block. Most of these surgeries were performed on outpatients. Exclusion criteria included: age younger than 14 yr, pregnancy, infection at the site of puncture, coagulopathy and allergy to amide local anesthetics. The brachial plexus block was performed by a single anesthesiologist. Standard monitoring was applied, an *iv* line was secured and sedation (midazolam 1–2 mg *iv*) and analgesia (fentanyl 50–100 µg *iv*) were given, the dose titrated depending on the patient's age, weight and degree of anxiety. The block was performed with the patient lying supine with his head turned in the direction opposite the limb to be anesthetized. The arm to be blocked laid in a neutral position, along the body. We identified by palpation the

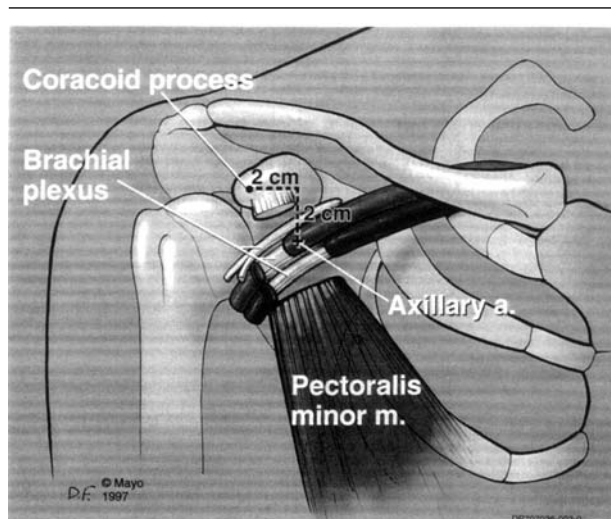


FIGURE Anatomical landmarks for the infraclavicular/coracoid block. Reproduced with permission from: Wilson JL, Brown DL, Wong GY, Ehman RL, Cahill DR. Infraclavicular brachial plexus block: parasagittal anatomy important to the coracoid technique. *Anesth Analg* 1998; 87: 870–3.

coracoid process and marked, with the help of a ruler, the point of entry of the needle 2 cm caudal and 2 cm medial to the coracoid process, as previously described by Wilson *et al.*<sup>6</sup> (Figure). At that point, the operating room stop clock was started to determine the time required to perform the block. Using a sterile technique, a 100 mm 22-gauge insulated short-bevel stimulating needle (Stimplex A, B.Braun Melsungen AG) was inserted perpendicular to the skin and connected to a nerve stimulator (Stimplex-dig, B.Braun Melsungen AG) that was programmed with the following variables: current 2.0 mA and frequency 2 Hz. The needle was advanced with the knowledge that the plexus would be at about 4 cm of depth. In the absence of an upper extremity motor response, the needle was redirected either cephalad or caudal but never medially to avoid the pleura. In the presence of an upper extremity motor response, the intensity of the current was then progressively reduced to 0.5 mA and 40 mL of mepivacaine 1.5% with adrenalin 5 µg·mL<sup>-1</sup> were injected after negative aspiration. At that point the stop clock was stopped.

Initially, in the first 75 patients, proximal (forearm flexion or extension) or distal (finger flexion or extension) motor response was considered an adequate response for performance of the block. Subsequently after obtaining a few inadequate blocks despite a good proximal motor response (most often stimulation of the musculocutaneous nerve), a distal motor response

<sup>A</sup> Enneking FK. How do I do...infraclavicular brachial plexus blocks. *ASRA newsletter*; August 2001: 2.

(finger flexion only) was specifically looked for in the remaining 75 patients. When the patient was ready for surgery, the same anesthesiologist documented the extent of the sensitive and motor blocks. The territories supplied by the following nerves were evaluated for presence or absence of pain sensation (analgesia) with a 25-gauge needle: axillary (lateral side of the upper arm), musculocutaneous (lateral side of the forearm), radial (dorsum of the hand over the second metacarpophalangeal joint), median (thenar eminence), ulnar (little finger), medial cutaneous nerve of the arm (medial side of the arm) and medial cutaneous nerve of the forearm (medial side of the forearm). Motor block of the distal upper extremity was evaluated as either good (limp), fair (weak movements) or poor (no relaxation).

A successful block was defined as analgesia in the five nerves distal to the elbow. When the site of surgery involved an unblocked nerve, general anesthesia or local anesthesia by the surgeon with sedation/analgesia were administered. In the cases where an arm tourniquet was applied, tolerance (need for analgesics) and duration of use were documented.

### Results

In a period of nine months, 150 consecutive patients were recruited to have an infraclavicular plexus block performed. The demographic data are summarized as follow: 98 males/52 females, age (yr)  $49 \pm 19$  and weight (kg)  $75 \pm 18$  (values are mean  $\pm$  SD). A variety of surgical procedures involved the hand in 92 patients, the wrist in 36 patients, the forearm in eight and the elbow in 14 patients.

Mean time to perform the block (start of skin disinfection-end of injection) was  $5 \pm 2$  min. Success rate, defined as analgesia in the five nerves distal to the elbow, was 91% (137 patients). No patient in this group required supplementary analgesics or infiltration during surgery. Initially, in our study, we were accepting either a proximal or distal motor response with neurostimulation and our 13 unsuccessful blocks occurred in our first 75 patients. For our remaining 75 patients, we systematically searched for a distal motor response, flexion of the fingers, and no failed block occurred. In patients with a successful block, a proximal block of the axillary nerve was present in 98.5% of the patients and of the medial cutaneous nerve of the arm in 60%. An arm tourniquet inflated to a pressure of 250 mmHg was applied to 115 of the 137 patients with a successful block for a duration of  $37 \pm 22$  min (mean  $\pm$  SD). All patients tolerated the tourniquet with no need for additional analgesics. Motor block of the upper extremity was good in 132 patients, fair in

five patients and poor in zero patients.

We have not specifically looked at the incidence of accidental venous puncture which occasionally occurred. We are aware of a case of pneumothorax that came to the attention of one of our surgeons. This patient was a 43-yr-old woman weighing 47 kg, who had a technically unremarkable infraclavicular block. She consulted a few hours after discharge. A diagnosis of pneumothorax was made, that did not necessitate chest tube drainage.

### Discussion

In our experience, the infraclavicular block by the coracoid approach provides highly consistent brachial plexus anesthesia for upper extremity surgery. Several favourable characteristics of this approach can be highlighted: 1) contrary to the axillary block, the arm to be anesthetized does not need to be in a 90° abduction and a 90° elbow flexion. Arm positioning is thus less painful for patients with fractures;<sup>7</sup> 2) the technique relies on the identification of the coracoid process, an easily palpable landmark, even in obese patients; 3) this single injection block is time efficient. It takes an average of five minutes to execute, which is shorter than that reported for the axillary multiple injection technique: eight minutes,<sup>11</sup> ten minutes;<sup>12</sup> 4) this block gives excellent results with 91% of the patients having analgesia of the five terminal nerves distal to the elbow. This criterion of block success is more stringent than that used in other studies: block of two terminal nerves<sup>3</sup> or operability (block permitting surgery to proceed).<sup>8</sup> For surgery distal to the elbow, the axillary approach is still the most widely used technique for brachial plexus block. Stimulation of multiple nerves seems to offer the best results,<sup>13</sup> but even with stimulation of four nerves (musculocutaneous, median, radial and ulnar), a block effectiveness of only 80% has been reported.<sup>14</sup> Other authors have obtained better results with multiple nerve stimulation but a number of patients still complained of tourniquet pain despite a successful block;<sup>11</sup> 5) the infraclavicular approach described makes it possible to tolerate the arm tourniquet without the need of additional *sc* infiltration. In our 137 patients with a successful block, 84% had an arm tourniquet applied and none complained of tourniquet pain. Proximal sensory nerve extension involved the axillary nerve in 98.5% and the medial cutaneous nerve of the arm in 60%. As can be seen, proximal extension of the block was partial with a frequent sparing of the medial cutaneous nerve of the arm; even so the tourniquet was well tolerated in all of our patients.

We would like to re-emphasize the need to distinguish the different infraclavicular approach-

TABLE I Infraclavicular brachial plexus block: approaches described

	<i>Needle insertion site</i>
Raj: <sup>2</sup>	2.5 cm below mid-clavicle, needle 45° to skin directed to brachial artery
Borgeat: <sup>10</sup>	mid distance from jugular notch to ventral acromial process, 1 cm caudal, needle 45° directed to axillary artery
Rodriguez: <sup>3</sup>	1.5 cm caudal and 1 cm medial to the coracoid process, needle perpendicular
Whiffler: <sup>5</sup>	needle perpendicular at a point medial and caudal to the coracoid process, on a line from the subclavian artery to the axillary artery
Wilson: <sup>6</sup>	2 cm caudal and medial to the coracoid process, needle perpendicular
Kapral: <sup>7</sup>	2–3 cm caudal to the coracoid process, needle perpendicular
Koscielniak-Nielsen: <sup>15</sup>	2–3 cm caudal to the coracoid process
Mehrkens, <sup>16</sup> Kilka: <sup>8</sup>	just under mid-clavicle, needle perpendicular
Salazar: <sup>9</sup>	junction 1/3 lateral-2/3 medial of the clavicle, 1 finger breadth below this point and medial to the coracoid, needle directed caudal, posterior and medial

TABLE II Infraclavicular brachial plexus block: success rates and adverse events

<i>Approach</i>	<i>Injection</i>		<i># Patients</i>		<i>Success rate</i>			<i>Adverse events (puncture)</i>		
	<i>Unique</i>	<i>multiple</i>			<i>volume</i>	<i>2 nerves</i>	<i>5 nerves</i>	<i>operability</i>	<i>venous</i>	<i>arterial</i>
Raj: <sup>2</sup>	×		20-30 mL	200		95%		—	—	—
Borgeat: <sup>10</sup>	×		40-50 mL	150		97%		—	2%	—
Rodriguez: <sup>3</sup>	×		40 mL	20	100%			—	—	—
Whiffler: <sup>5</sup>		×	40 mL	40		92.5%		—	50%	—
Kapral: <sup>7</sup>	×		40 mL	20		100%		0%	0%	0%
Koscielniak-Nielsen: <sup>15</sup>		×	30 mL	30		53%		—	17%	—
Kilka: <sup>8</sup>	×		50 mL	175			95%	10%	0%	0%
Mehrkens: <sup>16</sup>	×		50 mL	570			91%	10%	—	0.7%
Salazar: <sup>9</sup>	×		40 mL	360			95%	0.6%	—	0%
Desroches	×		40 mL	150			91%	—	—	0.7%

— = no data.

es<sup>2,3,5-10,15,16</sup> that have been described since 1973 (Tables I and II), some also relying on the identification of the coracoid process. They vary in their puncture site, needle direction, single or multiple neurostimulation, volume of local anesthetic injected, type of motor response accepted (proximal or distal), definition of block success (two terminal nerves, five terminal nerves, operability) and incidence of complications. The optimal infraclavicular approach remains unclear. The vertical infraclavicular approach<sup>8,16</sup> seems to have gained in popularity in Central Europe,<sup>7</sup> but its more medial needle insertion site makes it less appealing because, theoretically, it carries a greater risk of pneumothorax. We report one case of pneumothorax (incidence 0.7%) in a thin, short stature 47 kg woman. Thus, it may be prudent, in unusually short patients to have a needle insertion site slightly less medial to the coracoid process. There is no doubt however that, contrary to the axillary approach, this infraclavicular approach carries a risk of pneumotho-

rax, albeit low. In addition, the infraclavicular block technique with the least incidence of vessel puncture is desired because of the inability to compress the source of bleeding after accidental vessel puncture. Unfortunately, our data do not allow us to comment on this specific adverse event.

It is very important to emphasize the need to look specifically for a distal motor response with this infraclavicular approach. Fitzgibbon,<sup>17</sup> in a case report, mentioned that a musculocutaneous nerve motor response (forearm flexion) is not adequate for an infraclavicular plexus block. Borgeat,<sup>10</sup> using a different infraclavicular approach, reported a success rate of 44% when a proximal motor response was accepted for local anesthetic injection, compared to 97% when they looked specifically for a distal motor response. Finger flexion is considered by Borgeat<sup>10</sup> as the motor response giving the best block results because, when this motor response is obtained, the needle is located approximately at the centre of the cords. We, and others,<sup>3,16</sup> are in agreement

with this notion which is not consistently integrated in the literature. Even in a recent review article on neurostimulation, the authors stated (without the support of clinical data) that a musculocutaneous motor response is adequate while using the infraclavicular approach.<sup>18</sup> With the infraclavicular approach, the brachial plexus is at the cord level and we are tempted to consider that when we obtain forearm flexion with neurostimulation, this represents stimulation of the lateral cord and not the individual musculocutaneous nerve. In 1973 when Winnie<sup>1</sup> commented the new Raj's approach, he pointed out to the fact that the coracoid region is where the musculocutaneous nerve leaves the sheath of the plexus. This view that the musculocutaneous nerve leaves the plexus early is supported by others<sup>16</sup> and probably explains why we should not rely on a forearm flexion as an adequate motor response when performing an infraclavicular block.

In conclusion, the infraclavicular coracoid approach described by Wilson *et al.*<sup>6</sup> is a very effective brachial plexus block with distinct advantages. Future studies are needed to define latency time, if a specific distal motor response obtained with neurostimulation is better in predicting block success rate, vascular puncture rate and comparative studies with the axillary multiple nerve stimulation technique, which is the favoured approach at this time.

## References

- 1 Winnie AP. Infraclavicular brachial plexus block—a new approach. Guest discussion. *Anesth Analg* 1973; 52: 903–4.
- 2 Raj PP, Montgomery SJ, Nettles D, Jenkins MT. Infraclavicular brachial plexus block—a new approach. *Anesth Analg* 1973; 52: 897–903.
- 3 Rodriguez J, Barcena M, Rodriguez V, Aneiros F, Alvarez J. Infraclavicular brachial plexus block effects on respiratory function and extent of the block. *Reg Anesth Pain Med* 1998; 23: 564–8.
- 4 Klaastad O, Lilleas FG, Rotnes JS, Breivik H, Fosse E. Magnetic resonance imaging demonstrates lack of precision in needle placement by the infraclavicular brachial plexus block described by Raj et al. *Anesth Analg* 1999; 88: 593–8.
- 5 Whiffler K. Coracoid block – a safe and easy technique. *Br J Anaesth* 1981; 53: 845–8.
- 6 Wilson JL, Brown DL, Wong GY, Ehman RL, Cabill DR. Infraclavicular brachial plexus block: parasagittal anatomy important to the coracoid technique. *Anesth Analg* 1998; 87: 870–3.
- 7 Kapral S, Jandrasits O, Schabernig C, et al. Lateral infraclavicular plexus block vs. axillary block for hand and forearm surgery. *Acta Anaesthesiol Scand* 1999; 43: 1047–52.
- 8 Kilka HG, Geiger P, Mehrkens HH. Infraclavicular vertical brachial plexus blockade. A new technique of regional anaesthesia. *Anaesthesist* 1995; 44: 339–44.
- 9 Salazar CH, Espinosa W. Infraclavicular brachial plexus block: variation in approach and results in 360 cases. *Reg Anesth Pain Med* 1999; 24: 411–6.
- 10 Borgeat A, Ekatrodamis G, Dumont C. An evaluation of the infraclavicular block via a modified approach of the Raj technique. *Anesth Analg* 2001; 93: 436–41.
- 11 Sia S, Bartoli M. Selective ulnar nerve localization is not essential for axillary brachial plexus block using a multiple nerve stimulation technique. *Reg Anesth Pain Med* 2001; 26: 12–6.
- 12 Koscielniak-Nielsen ZJ, Hesselbjerg L, Fejlberg V. Comparison of transarterial and multiple nerve stimulation techniques for an initial axillary block by 45 ml of mepivacaine 1% with adrenaline. *Acta Anaesthesiol Scand* 1998; 42: 570–5.
- 13 Benhamou D. Axillary plexus block using multiple nerve stimulation: a European view (Editorial). *Reg Anesth Pain Med* 2001; 26: 495–8.
- 14 Koscielniak-Nielsen ZJ, Rasmussen H, Jepsen K. Effect of impulse duration on patients' perception of electrical stimulation and block effectiveness during axillary block in unsedated ambulatory patients. *Reg Anesth Pain Med* 2001; 26: 428–33.
- 15 Koscielniak-Nielsen ZJ, Rotboll Nielsen P, Risby Mortensen C. A comparison of coracoid and axillary approaches to the brachial plexus. *Acta Anaesthesiol Scand* 2000; 44: 274–9.
- 16 Mehrkens HH. Peripheral Regional Anaesthesia Tutorial. Ulm Rehabilitation Hospital. 1998: 13–6.
- 17 Fitzgibbon DR, Debs AD, Erjavec MK. Selective musculocutaneous nerve block and infraclavicular brachial plexus anesthesia. Case report. *Reg Anesth* 1995; 20: 239–41.
- 18 De Andres J, Sala-Blanch X. Peripheral nerve stimulation in the practice of brachial plexus anesthesia: a review. *Reg Anesth Pain Med* 2001; 26: 478–83.