

The Interdigestive Motor Complex of Normal Subjects and Patients with Bacterial Overgrowth of the Small Intestine

G. VANTRAPPEN, J. JANSSENS, J. HELLEMANS, and Y. GHOOS

From the Department of Medical Research, University of Leuven, and the Department of Medicine, Akademisch Ziekenhuis St. Rafaël, B-3000 Leuven, Belgium

ABSTRACT Intraluminal pressures were measured in the gastric antrum and at different levels of the upper small intestine in 18 normal subjects to investigate whether or not the interdigestive motor complex, identified in several animal species, occurs in man and, if so, to determine its characteristics. In all normal subjects, the activity front of the interdigestive motor complex was readily identified as an uninterrupted burst of rhythmic contraction waves that progressed down the intestine and that was followed by a period of quiescence. Quantitative analysis of various parameters of the complex and simultaneous radiological and manometrical observations revealed that it resembled closely the canine interdigestive motor complex. To test the hypothesis that disorders of this motor complex may lead to bacterial overgrowth in the small intestine, similar studies were performed in 18 patients with a positive $^{14}\text{CO}_2$ bile acid breath test and in an additional control group of 9 patients with a normal $^{14}\text{CO}_2$ breath test. All but five patients had normal interdigestive motor complexes. The five patients in whom the motor complex was absent or greatly disordered had bacterial overgrowth as evidenced by $^{14}\text{CO}_2$ bile acid breath tests before and after antibiotics. These studies establish the presence and define the characteristics of the normal interdigestive motor complex in man. They also suggest that bacterial overgrowth may be due to a specific motility disorder i.e., complete or almost complete absence of the interdigestive motor complex.

INTRODUCTION

In 1969, Szurszewski (1) identified in the small intestine of fasted dogs an electric complex characterized by a front of intense spiking activity that migrated down the entire small bowel. As the complex reached the ileum, another activity front developed

in the duodenum. Feeding interrupted this cycle and changed the tracing into a pattern of irregular spiking activity. This observation has been confirmed and extended by other investigators who have called the phenomenon the "interdigestive myoelectric complex" (2). An analogous cyclically recurring sequence of regular spiking activity has been observed in several animal species, including sheep (3), calves (4), horses (5), and rats (6). Very little is known about the presence of this complex in man and nothing about its characteristics and function. Kyfareva (7) and Foulk et al. (8) studied the motility of the human upper small intestine. They described periods of activity alternating with periods of quiescence and recognized that sometimes this motility pattern developed into a burst of rhythmic contractions of several minutes duration terminating the active phase. It has been shown that these bursts progress aborally in the duodenum of man (9). This rhythmic sequence probably corresponds to the activity front (2) of the interdigestive myoelectric complex. The cyclic recurrence of the phenomenon and its migration down the intestine were not recognized. On the basis of simultaneous radiological and electromyographical observations, it has been stated that this activity front serves to clean up the remnants of the preceding meal and functions as the "house keeper" of the small intestine (10).

The first purpose of the present study was to investigate whether or not an interdigestive motor complex occurs in humans and, if so, to determine its characteristics. If this interdigestive complex functions as a house keeper, it seems natural to speculate that a deficient clearing mechanism may result in accumulation of food remnants, desquamated cells, and secretions, thus creating a medium favorable to bacterial overgrowth in the small intestine. Therefore, the second purpose of this study was to test the hypothesis that abnormalities of the interdigestive motor complex

may lead to bacterial colonization of the small intestine.

METHODS

Normal subjects and patients. 18 normal subjects, without gastrointestinal symptoms or signs and with a normal $^{14}\text{CO}_2$ bile acid breath test, were studied. Their ages ranged from 18 to 71 yr, with a mean of 33 yr. There were 11 men and 7 women. 18 patients, selected on the basis of an abnormal $^{14}\text{CO}_2$ bile acid breath test, were also investigated. After the motility study, they were treated for 5 days with a daily dose of 2 g of Tetrex (tetracycline phosphate complex) (Bristol Laboratories, Syracuse, N.Y.) by mouth. A second $^{14}\text{CO}_2$ bile acid breath test was then performed to distinguish between ileal malabsorption and small intestinal bacterial overgrowth (11, 12). Nine patients with various diseases of the digestive system but with a negative $^{14}\text{CO}_2$ breath test were studied as an additional control group. Some pertinent data on the patients are summarized in Table I.

Motility recordings. Intraluminal pressures were measured by means of three polyethylene catheters (PE 205, Clay Adams, Div. of Becton, Dickinson and Co., Parsippany, N. J.) with side openings 25 cm apart. The catheters were perfused continuously at a rate of 0.19 ml/min (Harvard pump, Harvard Apparatus Co., Inc., Millis, Mass.). External pressure transducers (EMT 34, Elema Schönander, Stockholm, Sweden) were used and the tracings were recorded on a polygraph (Mingograph 81, Elema Schönander). The catheter assembly included two other tiny polyethylene tubes (PE 60, Clay Adams) which ended in a mercury-filled latex bag 15 cm below the most aboral recording orifice. The mercury-filled bag facilitated the passage of the catheter system through the small intestine whereas the two additional catheters made it possible to aspirate the mercury. In three subjects of the control group, the most proximal recording site was temporarily located in the antrum. In all other normal subjects and in the patients, the proximal recording orifice was positioned in the distal part of the duodenum about 10 cm above the angle of Treitz as shown by fluoroscope control. Nine normal subjects took a continental breakfast of about 450 kcal immediately before the pressure measurements started. These recordings lasted for periods of 527–735 min, with a mean of 619 min. In this way the interval between the meal and the appearance of the first interdigestive motor complex could be determined. In the remaining normals and in the patients, the recordings were started after an overnight fast and were continued for a period of 266–735 min, with a mean of 434 min.

In three normal subjects and two patients (S. V. and S. L.), the effect of this motor complex on small intestinal propulsion was studied radiologically (Videorecording, De Oude Delft, OD-X40, Delft, Netherlands). Onset and end of each period of video recording were marked on the pressure tracing to permit correlation of motility records and radiological pictures. The contrast material was injected during the various phases of the complex through a supplementary catheter which ended 5 cm proximal of the middle recording orifice.

Analysis of pressure records. The first step of the analysis consisted of counting the number of pressure waves per minute throughout the recording period. Only waves of 5 mm Hg or more were taken into account. In a second stage, the interdigestive motor complexes were identified using the following criteria for identification of an activity front: (a) appearance of an uninterrupted burst of pressure waves which were produced at a rhythm of about 12 per min

at the level of the angle of Treitz; (b) aboral progression of the activity front, as indicated by its sequential passage over all three or over the distal two recording orifices; (c) a period of complete quiescence after the activity front. If a burst of rhythmic contractions was observed at the level of the distal recording orifice only, and if this burst was followed by a period of complete quiescence, this pattern could not with certainty be interpreted as an activity front because there was no proof of its aboral progression. As this complex of pressure changes is similar to the pattern produced by an activity front, it is logical to assume that it is produced by an activity front that starts between the two distal recording orifices. Such pressure complexes were called "probable interdigestive motor complexes". The activity fronts were identified independently by two of the authors. The tracings were coded so that no clinical information was available to the analyzers. Up to this phase of the analysis, interobserver variation was limited to only one activity front.

The final step of the analysis consisted of determining the duration of the bursts of rhythmic contractions at different levels (duration of activity fronts), the frequency of the contraction waves during the periods of rhythmic activity, the progression velocity of the activity front, the calculated length of the activity front (duration \times progression velocity), the interval between meal and appearance of the first activity front, and the duration of the complete cycle of the motor complex. As this phase of the analysis is subject to observer bias and requires the drawing of marks on the tracings, it was carried out jointly by three authors. The data were analyzed statistically by means of Student's *t* test (13).

$^{14}\text{CO}_2$ Bile acid breath test. The bile acid breath test was performed according to the method of Fromm et al. (14) with slight modifications. After an overnight fast, subjects and patients took with their breakfast a starch capsule containing 5 μCi choly- ^{14}C glycine (The Radiochemical Centre, Amersham, Buckinghamshire, England). Breath samples were collected before and 1, 2, 3, 4, 5, 6, 8, 10, 12, and 24 h after breakfast. The radioactivity of the 2 mmol CO_2 , trapped in a 4-ml hyamine hydroxide solution, was measured in a liquid scintillation counter (model 2450, Packard Instrument Co., Inc., Downers Grove, Ill.). The counting efficiency was checked by external quench correction. Our normal values, based on tests in 25 normal subjects, are presented in Fig. 1. The test was taken to be abnormal when at least two consecutive values were higher than the mean $+2$ SD.

RESULTS

Normal subjects. The various phases of the interdigestive motor complex could easily be identified in all tracings but the most striking feature was the burst of rhythmic contractions called the activity front (Fig. 2). In the 18 normal subjects, 66 interdigestive complexes were analyzed, covering a total registration period of 150 h 48 min. When only those complexes were taken into account for which all three criteria of an interdigestive motor complex were satisfied, the mean duration of a complete cycle was 112 min $30 \text{ s} \pm 11 \text{ min } 25 \text{ s}$ (mean \pm SEM). However, when the probable interdigestive motor complexes (see Methods, Analysis of records) were also taken into account, the duration of a complete cycle was 84

TABLE I
Clinical and Experimental Data on Patients in Whom the Interdigestive Motility Was Studied

Patient identification	Age	Sex	Diagnosis	¹⁴ CO ₂ Breath test		Interdigestive motor complex
				Before antibiotics	After antibiotics	
	<i>yr</i>					
P. F.	40	M	Yersinia enterocolitis	Normal		Normal
R. A.	61	F	Systemic sclerosis	Normal		Normal
M. A. M.	55	F	Gall stones	Normal		Normal
M. J.	37	F	Sigmoid polyp	Normal		Normal
P. A. S.	58	M	Systemic sclerosis	Normal		Normal
D. A.	52	F	Zollinger-Ellison Syndrome	Normal		Normal
M. A.	43	F	Celiac disease	Normal		Normal
M. N.	28	F	Psychogenic diarrhea	Normal		Normal
T. P.	41	M	Duodenal ulcer	Normal		Normal
V. L. A.	27	M	Crohn's disease	Abnormal	Abnormal	Normal
D. B. E.	25	M	Crohn's disease	Abnormal	Abnormal	Normal
V. K. L.	49	M	Ileal resection	Abnormal	Abnormal	Normal
J. S.	49	F	Psychosomatic	Abnormal	Abnormal	Normal
S. E.	62	F	Crohn's disease	Abnormal	Abnormal	Normal
V. B.	42	F	Ileal resection for Crohn's disease	Abnormal	Abnormal	Normal
M. T.	42	M	Chronic cholangitis	Abnormal	Normal	Normal
M. P.	80	F	Ileocolic fistula	Abnormal	Normal	Normal
V. Y.	40	F	Systemic sclerosis	Abnormal	Normal	Normal
B. R.	32	M	Hypogammaglobulinemia Giardia intestinalis	Abnormal	Normal	Normal
D. R. M.	45	M	Partial obstruction due to adhesions	Abnormal	Normal	Normal
Z. D. C.	57	F	Partial gastrectomy and vagotomy	Abnormal	Normal	Normal
L. J.	50	F	Achlorhydria	Abnormal	Normal	Normal
K. L.	34	M	Total gastrectomy	Abnormal	Normal	Absent
S. V.	45	M	Systemic sclerosis	Abnormal	Normal	Absent
A. R.	33	M	Crohn's disease	Abnormal	Normal	Absent
D. B.	67	M	Unknown	Abnormal	Normal	Abnormal
S. L.	45	M	Unknown	Abnormal	Normal	Absent

min 56 s ± 5 min 40 s (mean ± SEM). Phase one of the interdigestive motor complex was characterized by a nearly complete absence of pressure waves. During phase two, pressure waves occurred in irregular sequences. This phase usually ended abruptly with the appearance of the burst of rhythmic contractions of

phase three. More rarely the activity front was preceded by a short period of quiescence (Fig. 3). The duration of the activity front, its progression velocity, and the frequency of the rhythmic contractions are summarized in Table II. As in dogs (1-2), the progression velocity was slightly faster in the

duodenum than in the upper jejunum, but the differences are just below significance. The calculated length of the activity front was 34.17 ± 4.35 cm (mean \pm SEM). Phase four, which follows the activity front, was characterized by a rapid decrease in both amplitude and regularity of the pressure peaks. This phase was always very short. Furthermore, 24 probable interdigestive motor complexes were observed, which probably correspond to complexes which started very distally.

52 of the 66 complexes (79%) started at or above the proximal recording orifice (in the duodenum or stomach) and 14 (21%) started between the proximal and middle orifice (below the angle of Treitz). Seven complexes were observed in three subjects in whom the proximal recording site was temporarily located in the antrum, but only one of these seven complexes (14%) started in the stomach.

The interval between breakfast and the appearance of the first activity front was 213 ± 48 min (mean \pm SD).

Patients with abnormal $^{14}\text{CO}_2$ bile acid breath test (18 patients). The initially abnormal $^{14}\text{CO}_2$ bile acid breath test normalized after treatment with antibiotics in 12 patients, suggesting the presence of bacterial overgrowth in the small intestine. Five of these patients had gross disorders of their interdigestive motor activity. Although the patients were fasted for at least 12 h before the study and the registration was continued for at least 7 h, no interdigestive complex was observed in patients K.L., S. V., A. R., and S. L., and only one in patient D. B. Patient K. L. had undergone a total gastrectomy for malignancy 3 yr previously and there was no evidence of recurrence. S. V. had systemic sclerosis involving the jejunum, and A. R. had Crohn's disease involving the terminal ileum and complicated by a vesicointestinal fistula. Patient S. L. had a very prolonged small intestinal transit time and severe fecal stasis without visible lesions on barium

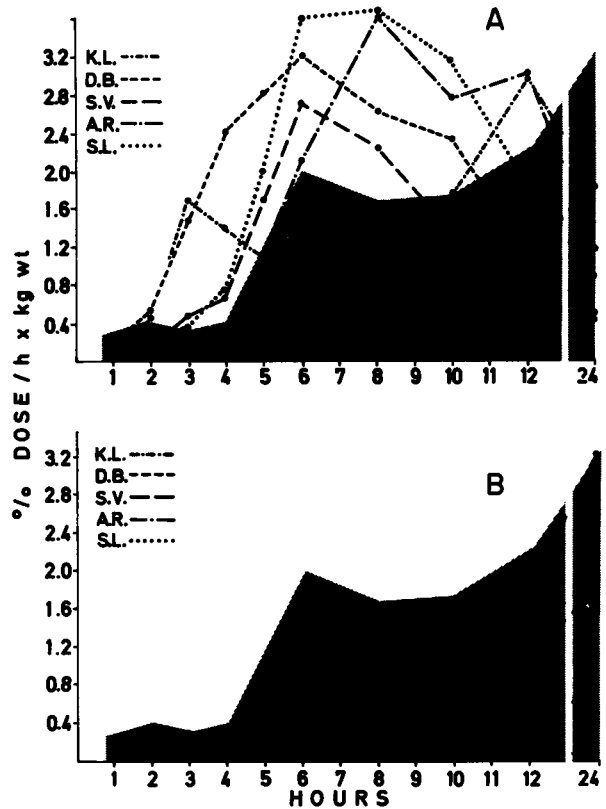


FIGURE 1 $^{14}\text{CO}_2$ bile acid breath tests before (A) and after (B) treatment with antibiotics in patients K. L., D. B., S. V., A. R., and S. L. The uninterrupted line and the shaded area represent the mean \pm 2 SD in a series of 25 normal subjects. The normalization of the breath tests suggests bacterial overgrowth of the small intestine.

studies. In patient D. B., no lesion could be detected in spite of intensive investigation. He complained of diarrhea, exaggerated and audible bowel sounds, and weight loss. The results of the $^{14}\text{CO}_2$ bile acid breath

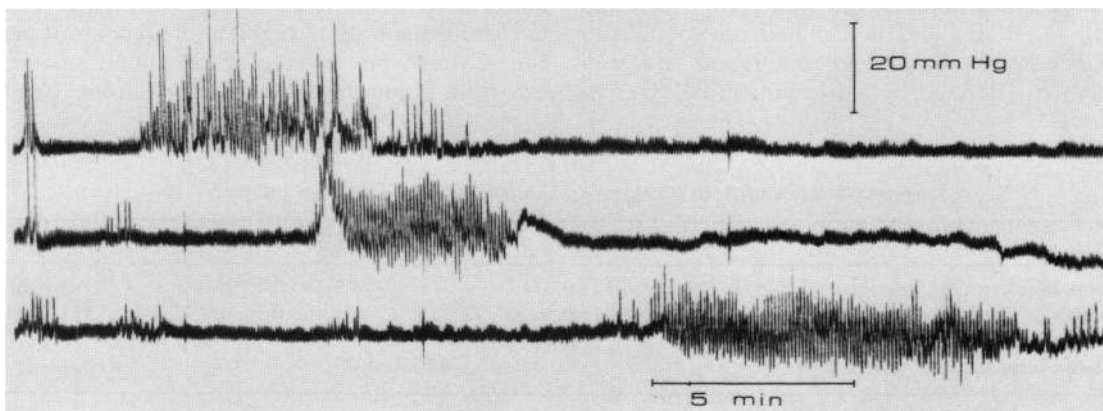


FIGURE 2 The activity front of the interdigestive motor complex is characterized on manometric tracings by a burst of rhythmic contraction waves that progresses down the intestine.

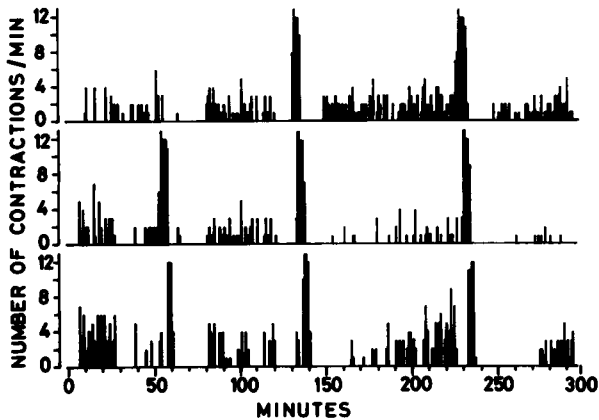


FIGURE 3 Schematic representation of three consecutive interdigestive motor complexes.

tests in the patients who had no or a greatly disordered interdigestive motor complex are presented in Fig. 1. The other seven patients had a normal number of interdigestive motor complexes. The duration of a cycle was $129 \text{ min } 34 \text{ s} \pm 24 \text{ min } 28 \text{ s}$ (mean \pm SEM) or $92 \text{ min } 43 \text{ s} \pm 8 \text{ min } 44 \text{ s}$ when the probable complexes were taken into account. 16 of the 21 complexes (76%) started in the duodenum or above it; 5 complexes (24%) started in the proximal jejunum. Six probable complexes were also observed. The total registration period in these patients amounted to 46 h 18 min. Table III summarizes the characteristics of the activity fronts in this group. Apart from slight differences in frequency of the contraction waves, only the calculated length of the activity front was significantly shorter than in the normal controls ($P < 0.01$). All these patients had pathological conditions which apparently could be responsible for the bacterial colonization (Table I).

In 6 of the 18 patients, the $^{14}\text{CO}_2$ bile acid breath test remained abnormal after treatment with antibiotics, suggesting ileal dysfunction. Three of them (V. L. A., D. B. E., and S. E.) had uncomplicated Crohn's disease; V. K. L. had undergone resection of ileal loops perforated by a gunshot, and J. S. com-

plained of abdominal discomfort which was considered to be of psychosomatic nature. V. B. had undergone resection of the terminal ileum (30 cm) and the right hemicolon for Crohn's disease. These six patients had a normal number of interdigestive motor complexes: the duration of a cycle was $94 \text{ min } 56 \text{ s} \pm 10 \text{ min } 37 \text{ s}$ (mean \pm SEM) or $91 \text{ min } 35 \text{ s} \pm 15 \text{ min } 35 \text{ s}$ when the probable complexes were taken into account. The characteristics of their activity fronts are shown in Table IV. These data are derived from 18 complexes, 12 of which (67%) started in the duodenum or above it, whereas 6 complexes (33%) started in the proximal jejunum. 10 probable complexes were observed. The total registration period in this group was 46 h 42 min.

As an additional control group, nine patients with various diseases of the digestive system but a normal $^{14}\text{CO}_2$ bile acid breath test were examined (Table I). The total registration period in this group was 69 h 40 min. All patients had a normal number of interdigestive motor complexes (duration of a cycle, $119 \text{ min } 1 \text{ s} \pm 22 \text{ min } 56 \text{ s}$ or $135 \text{ min } 44 \text{ s} \pm 32 \text{ min } 25 \text{ s}$ when the probable complexes were also taken into account). Their activity fronts were not different from those of the normal controls (except for some minor differences in frequency of contractions) (Table V). In 18 instances (78%), the complex started in the duodenum or above it; 5 complexes (22%) started in the proximal jejunum; and 7 probable activity fronts were observed at the level of the most distal recording orifice.

Radiological observations. When a small bolus of contrast material was injected into a jejunal segment activated by the rhythmic contractions of an activity front, the barium was seen to be completely removed in an aboral direction by a contraction wave that progressed over a distance of 25–35 cm at an estimated speed of about 2.5 cm/s. When a larger amount of barium was injected during the activity front, the aborally progressing contraction waves were seen to follow each other in close sequence and very quickly to clean the intestinal segment of all contrast material. Fig. 4 shows an example of the aboral movement of a barium bolus during the activity front. Instillation

TABLE II
Characteristics of Activity Front in Control Group of Normal Subjects

	Duodenum	Jejunum I*	Jejunum II†
Duration, min	5.11 ± 0.61 §	5.48 ± 0.40	5.90 ± 0.37
Frequency of contractions, no./min	11.61 ± 0.13	11.48 ± 0.14	11.30 ± 0.14
Progression velocity, cm/min		7.65 ± 1.06	5.91 ± 0.79
Calculated length, cm		34.17 ± 4.35	

* Jejunum I, ± 15 cm below angle of Treitz.

† Jejunum II, ± 40 cm below angle of Treitz.

§ Numbers refer to means \pm SEM.

TABLE III
Characteristics of Activity Front in Patients with Bacterial Overgrowth of the Small Intestine

	Duodenum	Jejunum I*	Jejunum II†
Duration, min	4.41±0.46§	5.25±0.34	6.20±0.47
Frequency of contractions, no./min	11.08±0.14 [‡]	11.38±0.19	11.12±0.18
Progression velocity, cm/min		6.76±1.36	3.79±0.54
Calculated length, cm		19.12±2.53¶	

* Jejunum I, ±15 cm below angle of Treitz.

† Jejunum II, ±40 cm below angle of Treitz.

§ Numbers refer to means±SEM.

[‡] $P < 0.05$ as compared to normal controls.

¶ $P < 0.01$ as compared to normal controls.

of barium during phase one resulted in filling of an intestinal segment which remained immobile and relaxed and in stasis of the contrast material. Most contractions occurring during phase two were segmentary phenomena producing either aboral or oral movement of the barium. Occasionally two or three consecutive contractions were seen to progress aborally over longer segments. The radiological observations in the patients with systemic sclerosis (S. V.) confirmed the presence of dilated, poorly active jejunal loops, but were otherwise not contributory because no interdigestive motor complex was observed. Also, in patient S. L. only segmentary mixing contractions were observed with irregular and very slow aboral progression of the injected barium.

DISCUSSION

Our studies indicate that the small intestine of normal fasted human subjects exhibits a cyclically recurring, migrating motor complex that is the equivalent of the interdigestive myoelectric complex first identified in dogs (1, 2). Feeding stops the complex in man as it does in dogs (2) and changes the motility tracing into a pattern of contraction waves appearing at irregular intervals. The aborally progressing front of rhythmic contractions efficiently clears the involved intestinal segment of all injected barium, suggesting that, in man as well as in dogs, it functions as a house keeper

(10). Our observations in patients with a positive ¹⁴C₂ bile acid breath test due to small intestinal bacterial overgrowth suggest that disorders of the interdigestive motor complex may be an important factor in the pathogenesis of bacterial colonization of the upper small bowel.

Szurszewski identified the interdigestive myoelectric complex in the small intestine of fasted dogs (1). Code and collaborators (2, 10, 15, 16) extended these studies and divided the complex into four different phases: phase one is characterized by the relative absence of action potentials; during phase two there is persistent but irregular action potential activity; phase three, the activity front, is characterized by its sudden onset and end, and by the presence of large action potentials on every pacesetter potential (or slow wave) of that period; during phase four, incidence and intensity of action potentials decline rapidly and disappear completely. Simultaneous measurements in dogs of intraluminal pressure changes and electrical activity have established the motor correlates of the interdigestive myoelectric complex (10). From these investigations, it is evident that pressure measurements may be used to study the interdigestive myoelectric complex and to determine its characteristics in man. Our pressure tracings clearly visualized the different phases of the interdigestive motor complex. The activity front could easily be identified and several fronts were observed in every subject of the control

TABLE IV
Characteristics of Activity Front in Patients with Ileal Dysfunction

	Duodenum	Jejunum I*	Jejunum II†
Duration, min	4.12±0.73§	5.44±0.59	4.52±0.81
Frequency of contractions, no./min	11.24±0.26	11.47±0.19	11.67±0.39
Progression velocity, cm/min		7.97±0.79	6.04±0.9
Calculated length, cm		30.35±5.37	

* Jejunum I, ±15 cm below angle of Treitz.

† Jejunum II, ±40 cm below angle of Treitz.

§ Numbers refer to means±SEM.

TABLE V
Characteristics of Activity Front in Additional Control Group of Patients with Normal ¹⁴CO₂ Breath Test

	Duodenum	Jejunum I*	Jejunum II†
Duration, min	3.92±0.61‡	5.04±0.85	5.85±1.56
Frequency of contractions, no./min	11.45±0.30	10.97±0.16 [¶]	10.60±0.20 [¶]
Progression velocity, cm/min		9.58±2.48	6.47±1.76
Calculated length, cm		25.86±6.67	

* Jejunum I, ±15 cm below angle of Treitz.

† Jejunum II, ±40 cm below angle of Treitz.

‡ Numbers refer to means±SEM.

[¶] *P* < 0.05 as compared to normal controls.

group. As our pressure recordings were limited to the upper 50–60 cm of the small bowel, it has not been demonstrated that the activity front progresses down to the terminal ileum. Various parameters of the motor complex had the same magnitude in man as in the dog: the duration of the activity front at a given level of the intestine, its propagation velocity, and its calculated length; the duration of a complete motor cycle; and the interval between feeding and the appearance of the first activity front (2, 17). The rhythm of the contraction waves during the activity front, however, was similar to the pacesetter (or slow wave) rhythm of the human jejunum (9, 18).

The interdigestive motor complex in humans did not always start in the antrum. In many instances, even after a fast of 24 h, the activity front originated at or below the angle of Treitz. Bursts of rhythmic contraction waves followed by a period of quiescence were often seen at the level of the distal recording orifice only. They probably correspond to activity fronts which originate very distally. The combined manometrical and radiological studies in normal subjects confirm in man the results obtained in dogs by others (10). The activity front efficiently clears the intestinal lumen of all injected contrast material. The function of these cyclically recurring rhythmic contraction waves may thus well be to clean up all remnants of the preceding meal and to remove interdigestive secretions and desquamated cells.

The mechanisms that control bacterial populations in the small bowel are multiple, complex, and poorly understood (19). There is general agreement that motility disorders constitute an important factor in the pathogenesis of bacterial overgrowth in the small intestine. However, apart from stasis of luminal contents due to mechanical obstruction, no specific motor disorder has been identified so far. The 18 normal subjects and all but 5 of the 27 patients had a normal number of interdigestive motor complexes. In contrast, all five patients with a complete or almost complete absence of activity fronts had small intestinal bacterial overgrowth as evidenced by the ¹⁴CO₂ bile

acid breath tests before and after treatment with antibiotics. The observation that absence or gross disorders of the interdigestive motor complex are always associated with evidence of bacterial overgrowth in the small intestine makes it very improbable that the association is merely coincidental. The possibility cannot be excluded that bacterial overgrowth by itself interferes with the small intestinal motor function and results in a disappearance of the activity front. In favor of this hypothesis is the observation that three of the five patients with gross disorders of the interdigestive motor activity also had diseases which may have contributed to the development of bacterial overgrowth. Patient S. V. had systemic sclerosis involving the jejunum. Muscular atrophy and sclerosis of the intestinal wall may have favored intestinal stasis. Patient K. L. had undergone a total gastrectomy 3 yr previously. Anacidity may have contributed to the development of bacterial overgrowth in this patient (20, 21). A. R. had Crohn's disease of the ileum. Although there was no ileocolic fistula, a slight degree of mechanical obstruction, difficult to demonstrate radiologically, cannot be excluded. However, 8 of the 13 patients with evidence of bacterial overgrowth had a normal number of interdigestive motor complexes. Although the calculated length of the activity front was decreased as compared to normals (but not as compared to patients with a negative ¹⁴CO₂ bile acid breath test), this observation indicates that bacterial colonization by itself does not invariably eliminate the activity front of the interdigestive motor complex. Moreover, this activity front is such a highly efficient mechanism of intestinal propulsion and is normally recurring so constantly throughout the interdigestive period that it is logical to assume that the disorders of the interdigestive motor complex may be the cause rather than the result of the bacterial colonization. The final proof may come from experiments in which the activity front of the interdigestive motor complex is pharmacologically inhibited for a long period of time. At this moment, no such agents are available.

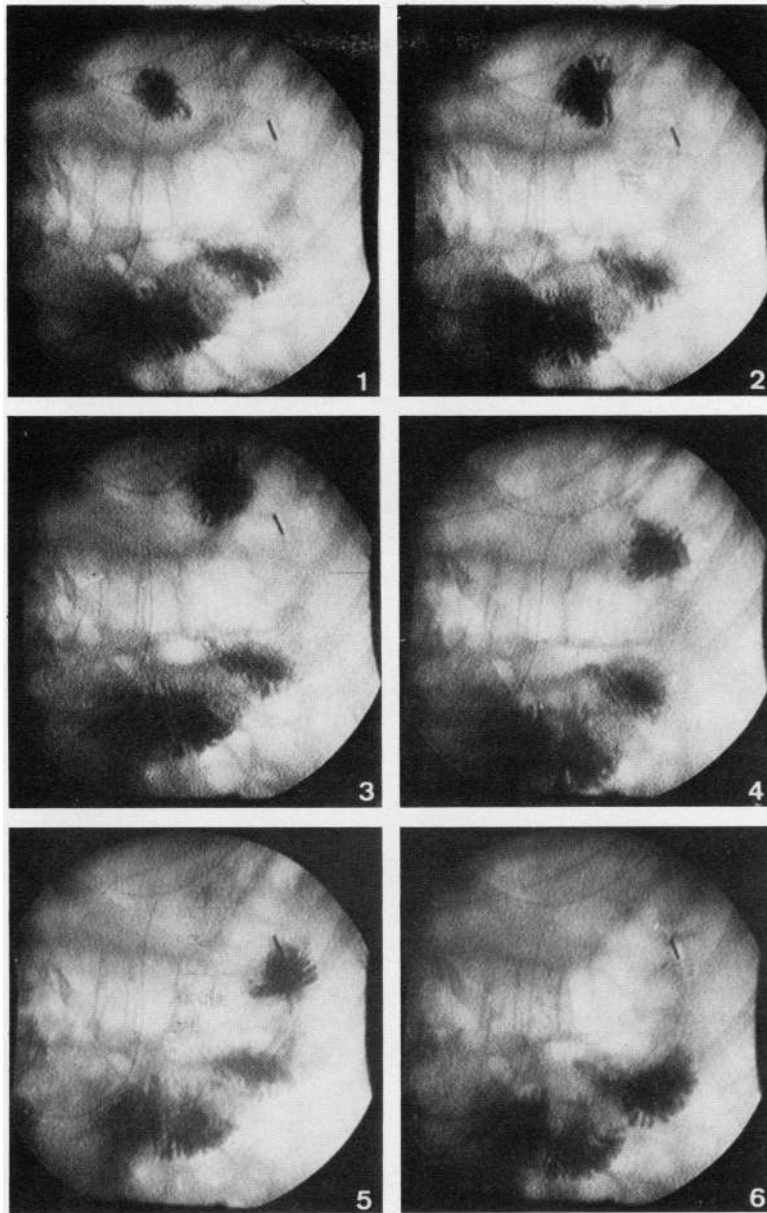


FIGURE 4 Propulsion of a barium bolus during the activity front of the interdigestive motor complex. The radiocinematographic sequence has been copied from the video recording tape. The middle recording orifice is located 3 cm below the angle of Treitz (just proximal to the radio-opaque marker visible in the upper right quadrant). Recording orifices 1 and 3 are located 25 cm proximally and 25 cm distally of the middle orifice but these are not visible on the photograph. The bolus was injected through a supplementary catheter 5 cm proximal to the middle recording orifice at the time the activity front was clearly visible at the level of the second recording orifice but had not yet reached the distal recording orifice 25 cm more distally. The interval between each picture is 1 s. The bolus is seen to progress rapidly over a distance of about 12 cm. The progression velocity is approximately 2.5 cm/s.

It is evident that many more patients must be studied before conclusions can be drawn regarding the incidence of disorders of the interdigestive myoelectric

complex in pathological conditions such as systemic sclerosis, total gastrectomy, or Crohn's disease.

Both hormonal and neural mechanisms are involved

in the control of the interdigestive motor complex. Vagotomy produces disorders of the motor complex (16, 22, 23). High doses of pentagastrin and of insulin interrupt the complex (16, 24), whereas motilin injections induce this type of motor activity (25). It may be interesting to study these hormones, particularly motilin, in patients with bacterial overgrowth and disorders of the interdigestive motor complex.

REFERENCES

1. Szurszewski, J. H. 1969. A migrating electric complex of the canine small intestine. *Am. J. Physiol.* **217**: 1757-1763.
2. Code, C. F., and J. A. Marlett. 1975. The interdigestive myo-electric complex of the stomach and small bowel of dogs. *J. Physiol. (Lond.)* **246**: 289-309.
3. Grivel, M.-L., and Y. Ruckebusch. 1972. The propagation of segmental contractions along the small intestine. *J. Physiol. (Lond.)* **227**: 611-625.
4. Ruckebusch, Y., and L. Bueno. 1973. The effect of weaning on the motility of the small intestine in the calf. *Br. J. Nutr.* **30**: 491-499.
5. Ruckebusch, Y. 1973. Les particularités motrices du jéjuno-iléon chez le cheval. *Cah. Med. Lyon.* **42**: 128-143.
6. Ruckebusch, M., and J. Fioramonti. 1975. Electrical spiking activity and propulsion in small intestine in fed and fasted rats. *Gastroenterology* **68**: 1500-1508.
7. Kyfareva, O. 1948. Duodenal function in man. I. Motor and secretory function of the duodenum and their relation in healthy subjects. *Klin. Med. (Mosc.)* **26**: 45-56.
8. Foulk, W. T., C. F., Code, C. G. Morlock, and J. A. Barga. 1954. A study of the motility patterns and the basic rhythm in the duodenum and upper part of the jejunum of human beings. *Gastroenterology* **26**: 601-611.
9. Texter, E. C., C. C. Chou, H. C. Laureta, and G. R. Vantrappen. 1968. Motility of the small intestine. In *Physiology of the Gastrointestinal Tract*. The C. V. Mosby Company, St. Louis, Mo. 113-123.
10. Code, C. F., and J. F. Schlegel. 1974. The gastrointestinal interdigestive housekeeper: motor correlates of the interdigestive myoelectric complex of the dog. In *Proceedings of the Fourth International Symposium on Gastrointestinal Motility*. E. E. Daniel, J. A. L. Gilbert, B. Schofield, T. K. Schnitka, and G. Scott, editors. Vancouver Mitchell Press Ltd., Banff, Canada. 631-634.
11. Sherr, H. P., Y. Sasaki, A. Newman, J. G. Banwell, H. N. Wagner, Jr., and T. R. Hendrix. 1971. Detection of bacterial deconjugation of bile salts by a convenient breath-analysis technic. *N. Engl. J. Med.* **285**: 656-661.
12. Fromm, H., and A. F. Hofmann. 1971. Breath test for altered bile-acid metabolism. *Lancet* **2**: 621-625.
13. Snedecor, G. W., and W. G. Cochran. 1968. *Statistical Methods*. Iowa State University Press, Ames, Iowa. 6th edition. 593 pp.
14. Fromm, H., P. J. Thomas, and A. F. Hofmann. 1973. Sensitivity and specificity in tests of distal ileal function: prospective comparison of bile acid and vitamin B12 absorption in ileal resection patients. *Gastroenterology* **64**: 1077-1090.
15. Carlson, G. M., B. S. Bedi, and C. F. Code. 1972. Mechanism of propagation of intestinal interdigestive myoelectric complex. *Am. J. Physiol.* **222**: 1027-1030.
16. Marik, F., and C. F. Code. 1975. Control of the interdigestive myoelectric activity in dogs by the vagus nerves and pentagastrin. *Gastroenterology* **69**: 387-395.
17. Summers, R. W., J. Helm, and J. Christensen. 1976. Intestinal propulsion in the dog. Its relation to food intake and the migratory myoelectric complex. *Gastroenterology* **70**: 753-758.
18. Hightower, N. C., Jr. 1968. Motor action of the small bowel. *Handb. Physiol.* **4** (Section 6. Alimentary Canal): 2001-2024.
19. Donaldson, R. M., Jr. 1970. Small bowel bacterial overgrowth. *Adv. Intern. Med.* **16**: 191-212.
20. Gray, J. D. A., and M. Shiner. 1967. Influence of gastric pH on gastric and jejunal flora. *Gut* **8**: 574-581.
21. Drasar, B. S., M. Shiner, and G. M. McLeod. 1969. Studies on the intestinal flora. I. The bacterial flora of the gastrointestinal tract in healthy and achlorhydric persons. *Gastroenterology* **56**: 71-79.
22. Stoddard, C. J., and H. L. Duthie. 1974. Effects of varying degrees of vagotomy on the gastroduodenal response to food. *Gut* **15**: 348.
23. Stoddard, C. J., and H. L. Duthie. 1973. The changes in gastroduodenal myoelectrical activity after varying degrees of vagal denervation. *Gut* **14**: 824.
24. Bueno, L., and Y. Ruckebusch. 1976. Evidence for a role of endogenous insulin on intestinal motility. In *Proceedings of the Fifth International Symposium on Gastrointestinal Motility*. G. Vantrappen, editor. Typoff-Press, Herentals, Belgium. 64-69.
25. Itoh, Z., I. Aizawa, S. Takeuchi, and E. F. Couch. 1976. Hunger contractions and motilin. In *Proceedings of the Fifth International Symposium on Gastrointestinal Motility*. G. Vantrappen, editor. Typoff-Press, Herentals, Belgium. 48-55.