

The neutral zone in complete dentures

Victor E. Beresin, DDS,^a and Frank J. Schiesser, DDS^b
Temple University School of Dentistry, Philadelphia, Pa

The neutral-zone approach to complete denture construction is neither new nor original but, rather, constitutes the bringing together of the concepts and ideas of many men into a viable and practical procedure.

Over the past forty years, numerous articles which have touched upon or related to what we have termed the "neutral-zone concept" have appeared in the literature. Unfortunately, the profession generally has ignored these ideas, and consequently, the principles are frequently bypassed in denture construction.

The two men who probably have contributed the most to these concepts are Wilford Fish¹ and Russell Tench.² Many others,²⁻⁹ including Perry¹⁰ and the Detroit Dental Clinic Club, have helped to advance and develop both the theoretical basis and practical procedures.

Complete dentures are primarily mechanical devices, but since they function in the oral cavity, they must be fashioned so that they are in harmony with normal neuromuscular function. All oral functions, such as speech, mastication, swallowing, smiling, and laughing, involve the synergistic actions of the tongue, lips, cheeks, and floor of the mouth which are very complex and highly individual. Failure to recognize the cardinal importance of tooth position and flange form and contour often results in dentures which are unstable and unsatisfactory, even though they were skillfully designed and expertly constructed. The coordination of complete dentures with neuromuscular function is the foundation of successful, stable dentures.

When all of the natural teeth have been lost, there exists within the oral cavity a void which is the potential denture space (Fig. 1). The neutral zone is that area in the potential denture space where the forces of the tongue pressing outward are neutralized by forces of the cheeks and lips pressing inward. Since these forces are developed through muscular contraction during the various functions of chewing, speaking, and swallowing, they vary in magnitude and direction in different individuals.

NEUTRAL ZONE

The soft tissues that form the internal and external boundaries of the denture space exert forces which greatly influence the stability of the dentures. The central thesis of the neutral-zone approach to complete dentures is to locate that area in the edentulous mouth where the teeth should be positioned so that the forces exerted by muscles will tend to stabilize the denture rather than unseat it.

MUSCLE FORCES IN THE DENTAL ARCH

In the mouth of the child, the teeth erupt under the influence of a muscular environment. This environment, which is created by forces exerted by the tongue, cheeks, and lips, has a definite influence upon the position of the erupted teeth, the resultant arch form, and the occlusion.

The dental arch is formed by the muscle forces exerted on the teeth by the tongue, lips, and cheeks. There is also a genetic factor which cannot be overlooked. This inherent factor along with the muscular forces uniquely combine their influences to determine the final arch form and tooth position.

Generally, muscular activity and habits which develop during childhood continue through life. After the teeth have been lost, muscle function and activity remain highly individual and greatly influence any complete dentures that are placed in the mouth. It is therefore, extremely important that the teeth be placed in the mouth with the arch form located so that it will fall within the area compatible with muscular forces.

MUSCLE FORCES AND DENTURE STABILITY

By thinking of the soft-tissue boundaries of the denture space and of muscle function, the dentist becomes cognizant of those forces which tend to seat or unseat the denture. Our objective, therefore, is to recognize and to utilize those forces resulting from muscle function so that they will have a positive influence on denture stability. This can be accomplished only if we are aware of the neutral zone and if we position the teeth and develop the external surfaces of the denture so that all of

Read before the Academy of Denture Prosthetics, Washington, D. C. Reprinted with permission from *J Prosthet Dent* 1976;36:357-67.

^aAssociate Clinical Professor, Department of Prosthetic Dentistry.

^bAssistant Clinical Professor, Department of Prosthetic Dentistry. *J Prosthet Dent* 2006;95:93-101.

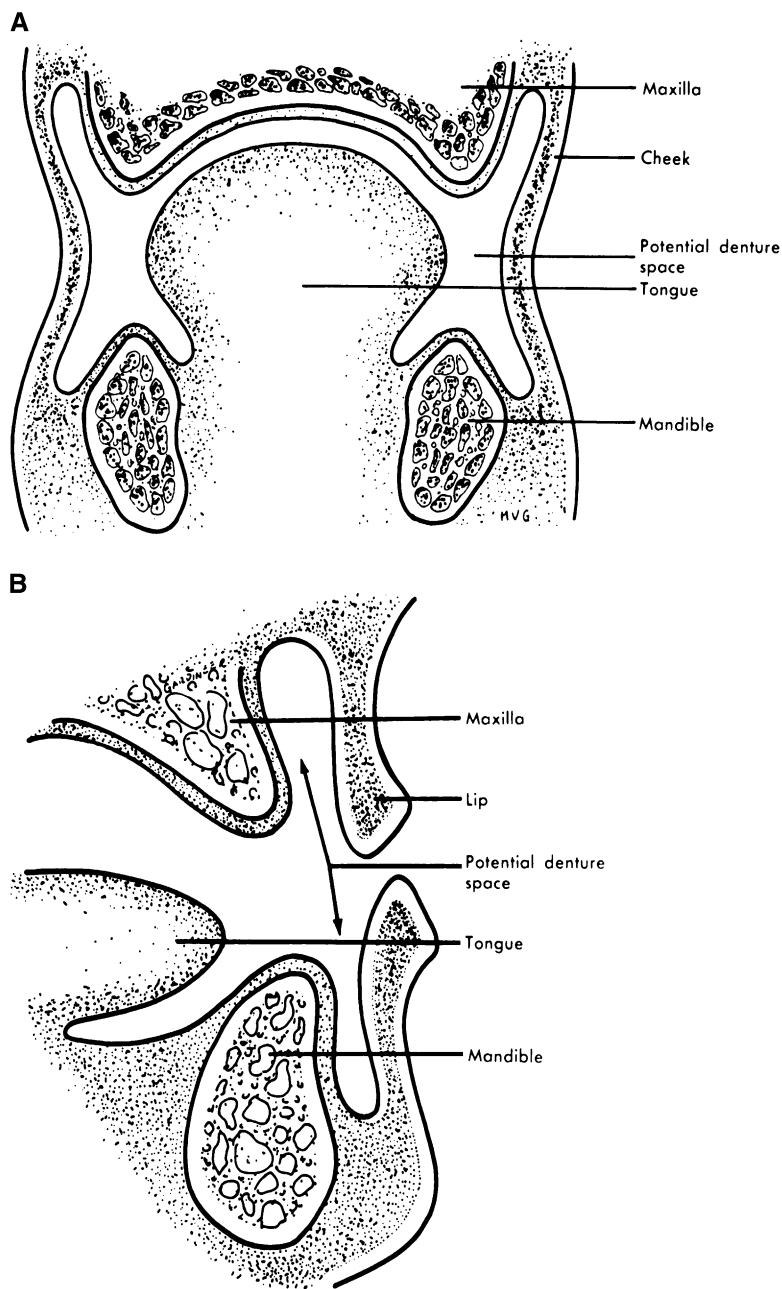


Fig. 1. Denture space: **A**, cross section of molar area; **B**, lateral view of incisor area. (From Beresin VE, Schiesser FJ. The neutral zone in complete dentures. St. Louis: C. V. Mosby Co; 1973.)

the forces exerted are neutralized and the denture maintains a state of equilibrium.

DENTURE SURFACES

The dental profession has always been concerned with equalizing the vertical forces that are delivered by the occlusal surfaces of the teeth and counteracted by the vault and the ridges. It has generally ignored the importance of the horizontal forces exerted on the external

surfaces of the dentures. Thus, the dental profession has been concerned, in the main, with two surfaces—the occlusal surface and the impression surface.

Sir Wilford Fish¹ of England has described a denture as having three surfaces, with each surface playing an independent and important role in the over-all fit, stability, and comfort of the denture.

We are very familiar with the impression and the occlusal surfaces of the denture. The third surface—as termed by Fish, “the polished surface”—is the rest of

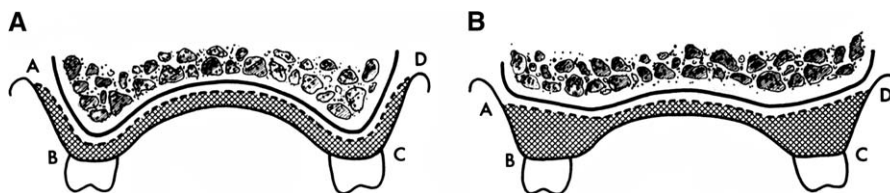


Fig 2. **A**, Cross section of a favorable upper ridge. The over-all size of surface *AD* (impression surface) is approximately equal to the over-all size of surface *ABCD* (external surface). **B**, Cross section of an unfavorable upper ridge caused by excessive resorption. The over-all area of surface *AD* (impression surface) is considerably less than the over-all area of surface *ABCD* (external surface). Therefore, forces exerted on the external surface have greater influence on denture stability and retention than do those in part **A**. (From Beresin VE, Schiesser FJ. *The neutral zone in complete dentures*. St. Louis: C. V. Mosby Co; 1973.)

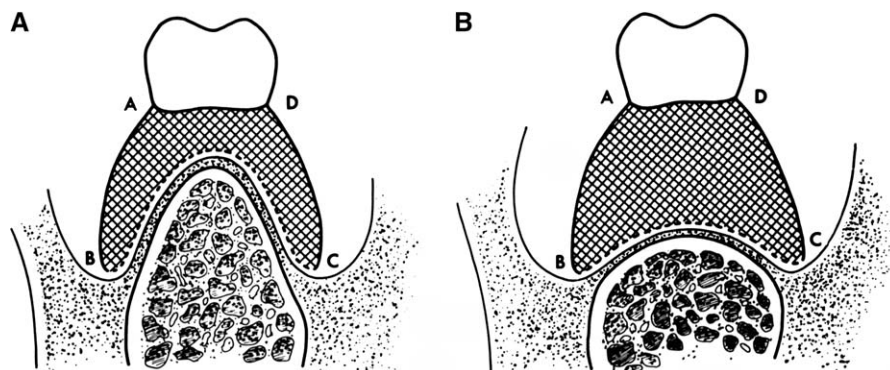


Fig 3. **A**, Cross section of favorable lower ridge. The over-all area of surface *BC* (impression surface) is approximately equal to the combined area *ABCD* (external surface). **B**, Cross section of unfavorable lower ridge caused by excessive resorption. The over-all area of surface *BC* (impression surface) is considerably less than the area of combined surface *ABCD* (external surface). Therefore, forces exerted on external surface will have greater influence on denture stability and retention as compared to part **A**. (From Beresin VE, Schiesser FJ. *The neutral zone in complete dentures*. St. Louis: C. V. Mosby Co; 1973.)

the denture that is not part of the other two surfaces. It is mostly denture base material, but it also consists of those surfaces of the teeth that are not contacting or articulating surfaces. The external or polished surface of the denture is in contact with the cheeks, lips, and tongue. One can visualize that, per square unit of area, the polished surface can be as large as or larger than impression and occlusal surfaces combined, depending on anatomic structure.

INFLUENCE OF FORCES ON DENTURE SURFACES

The greater the ridge loss, the smaller the denture base area and the less influence the impression surface area will have on the stability and retention of the denture. As the area of the impression surface decreases and the polished surface area increases, tooth position and contour of the polished surface become more critical (Figs. 2 and 3). In other words, where more of the alveolar ridge has been lost, denture stability and retention are more dependent on correct position of

the teeth and contour of the external surfaces of the dentures.

The forces exerted on the external surfaces of the teeth and the polished surfaces are essentially horizontal. When the occlusal surfaces of the teeth are not in contact, the stability of the denture is determined by the fit of the impression surface and the direction and magnitude of forces transmitted through the polished surfaces.

If the teeth were in contact all of the time, the polished surfaces would have relatively little effect on denture stability. Conversely, if the teeth were never brought into contact, the occlusal surfaces would be relatively unimportant. In order to construct dentures which function properly in chewing, swallowing, speaking, etc., we must develop not only proper tooth position but also the fit and contour of the polished surfaces just as accurately and meticulously as the fit and contour of impression and occlusal surfaces.

For example, let us examine a critical area of the lower denture such as the anterior segment. The force of the lower lip against the anterior surface of the denture

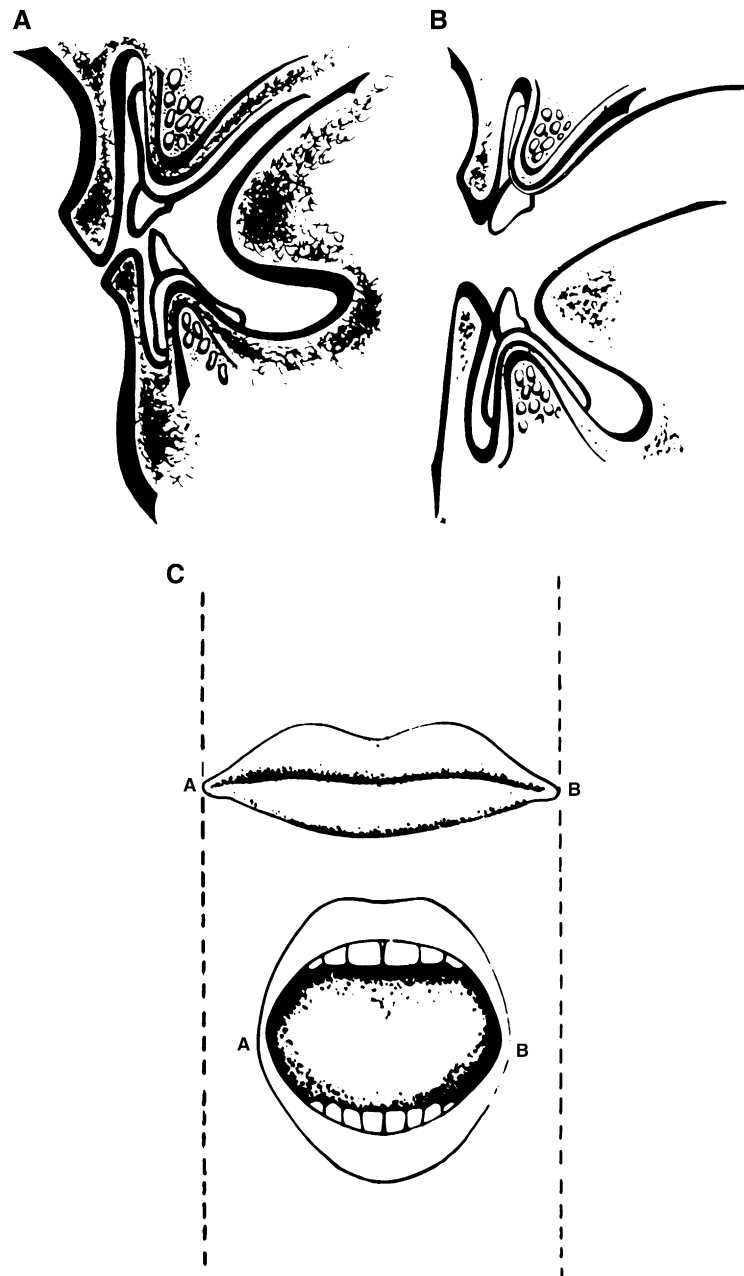


Fig 4. **A**, Cross section of mouth in repose. No unfavorable forces are external surfaces by the lips and cheeks. **B**, As the mouth opens, the denture comes under the influence of horizontal forces from the lips. **C**, With the mouth wide open, maximum horizontal forces are exerted on the labial and buccal external surfaces of the teeth and flanges. The distance *AB* when the mouth is open (*below*) is less than the distance *AB* when the mouth is at rest (*above*). (From Beresin VE, Schiesser FJ. *The neutral zone in complete dentures*. St. Louis: C. V. Mosby Co; 1973.)

and the anterior teeth will cause the denture to rise unless the teeth and flange are properly positioned and contoured. When the mouth is closed, the denture may remain stable. However, as soon as the mouth opens, the lower lip is like an elastic band pressing against the anterior flange and teeth. The wider the mouth is opened, the tighter the band (Fig. 4).

The influence of the lip on stability of the lower denture becomes more critical as resorption of the ridge

increases or as the patient ages (Fig. 5). Lammie⁵ has shown that as the alveolar ridge resorbs, the ridge crest falls below the origin of the mentalis muscle. As a result, the muscle attachment folds over the alveolar ridge and comes to rest on the superior surface of the ridge crest. The result is a posterior positioning of the neutral zone and, with it, the need to place the lower anterior teeth further lingually than had been the position of the natural teeth (Fig. 6).

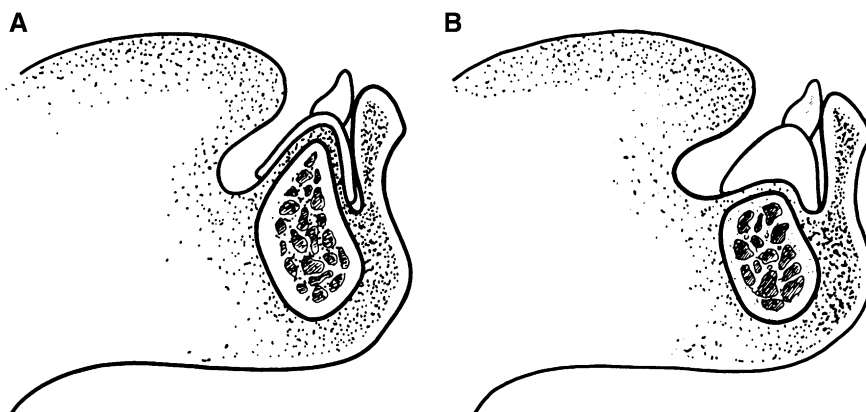


Fig 5. **A**, Cross section of a favorable lower anterior ridge. The dislodging forces exerted on the denture by the lower lip are resisted by the ridge. **B**, Cross section of unfavorable lower anterior ridge. The dislodging forces exerted on the denture by the lower lip cannot be counter-acted by the unfavorable ridge. Therefore, tooth position becomes much more critical. (From Beresin VE, Schiesser FJ. *The neutral zone in complete dentures*. St. Louis: C. V. Mosby Co; 1973.)

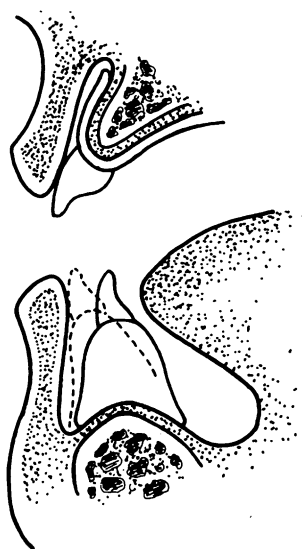


Fig 6. Broken line indicates original position of natural lower anterior teeth. Solid outline indicates proper position of anterior denture teeth to avoid dislodging forces of the lip. (From Beresin VE, Schiesser FJ. *The neutral zone in complete dentures*. St. Louis: C. V. Mosby Co; 1973.)

It seems obvious that if we do not determine the neutral zone and, as a result, the teeth and flanges are not properly positioned and contoured, the force of pressure from the lower lip may constantly unseat the lower denture.

REVERSED SEQUENCE IN DENTURE CONSTRUCTION

The usual sequence for complete dentures is to make primary impressions, construct individual trays, make final impressions, and then fabricate stabilized bases.

Occlusion rims or other devices are used to establish the occlusal vertical dimension and centric relation. With the neutral-zone approach to complete dentures, the procedure is reversed. Individual trays are constructed first. These trays are very carefully adjusted in the mouth to be sure that they are not overextended and remain stable during opening, swallowing, and speaking. Next, modeling compound is used to fabricate occlusion rims. These rims, which are molded by muscle function, locate the patient's neutral zone (Fig. 7). After a tentative vertical dimension and centric relation have been established, the final impressions are made with a closed-mouth procedure. Only when the final impressions are completed are the occlusal vertical dimension and centric relation finally determined.

BASE AND BODY OF THE DENTURE

It is important to understand the rationale behind the reversal of the usual steps in complete denture construction. The premise is that we should separate the denture base from the body of the denture.

With the neutral-zone concept, the impression surface is called the "base" and the polished surface is called the "body" of the denture. In the past, we did not orient our thinking in this direction, and as a result, we were less aware of the problems and their solutions.

Once the dentist begins to think of first creating a stable base and then placing teeth and flange contours that will not unseat it, the problems become apparent and are comparatively simple to solve.

The following example illustrates this important point. We all have had the experience of inserting a lower denture which moves upward as soon as the patient opens his mouth or starts to speak. The first assumption is usually that the denture is overextended so that the

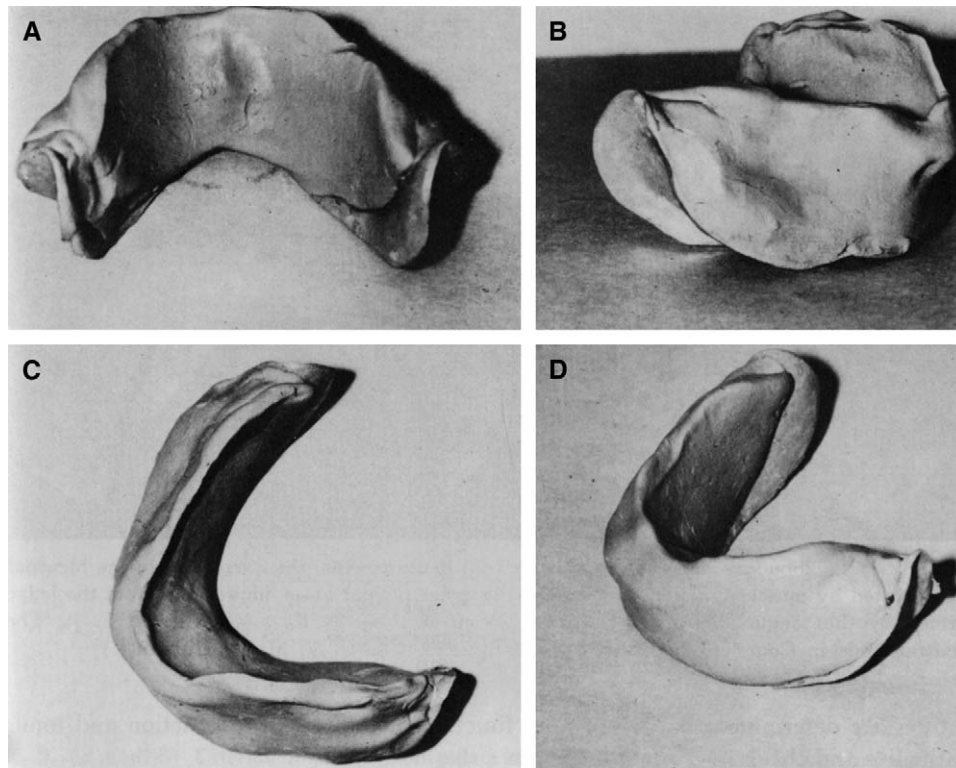


Fig 7. The molded compound rim: **A**, lingual view; **B**, buccal view (note depression formed by suctorial pad of cheek and concavity formed by action of lip); **C**, occlusal view; **D**, lateral view. (From Beresin VE, Schiesser FJ. *The neutral zone in complete dentures*. St. Louis: C. V. Mosby Co; 1973.)

denture periphery may be reduced. However, no matter how much the base is reduced, it still pops up.

It is not unusual to end up with a denture base that is considerably smaller than the original size but that still lacks stability and moves during the slightest function.

It is not the denture base that is the cause for denture instability but, rather, the body of the denture—that is, the tooth position and the flange form which was erected on top of the denture base. For this reason, theoretically and clinically, we differentiate between the base and the body of the denture. By separating these two entities, the dentist can more readily determine and correct the cause of instability of the denture.

EXTERNAL IMPRESSIONS

Usually, the contours of the external surfaces are arbitrarily determined by the dentist or technician. With the neutral-zone procedure, the external contours are molded by muscle function.

The moldable material used to locate the neutral zone also determines the shape of the arch and the angles and contours of the body of the denture. These three entities are determined by the size and function of the tongue and action and tonus of the lips and cheeks.

Just as a primary impression is the first step in developing the impression surface of the denture, the compound rims which located the neutral zone can be considered the primary impression or the first procedure in developing the polished surface of the denture.

External impressions, similar to secondary impressions of the ridge, capture in greater detail the action of the lips, cheeks, and tongue and determine the thickness, contours, and shape of the polished surface of the denture. By means of these external impressions, a physiologic molding is done so that the external surfaces are functionally compatible with muscle action (Figs. 8 and 9).

SUMMARY

The neutral-zone philosophy is based upon the concept that for each individual patient, there exists within the denture space a specific area where the function of the musculature will not unseat the denture and where forces generated by the tongue are neutralized by the forces generated by the lips and cheeks.

The influence of tooth position and flange contour on denture stability is equal to or greater than that of

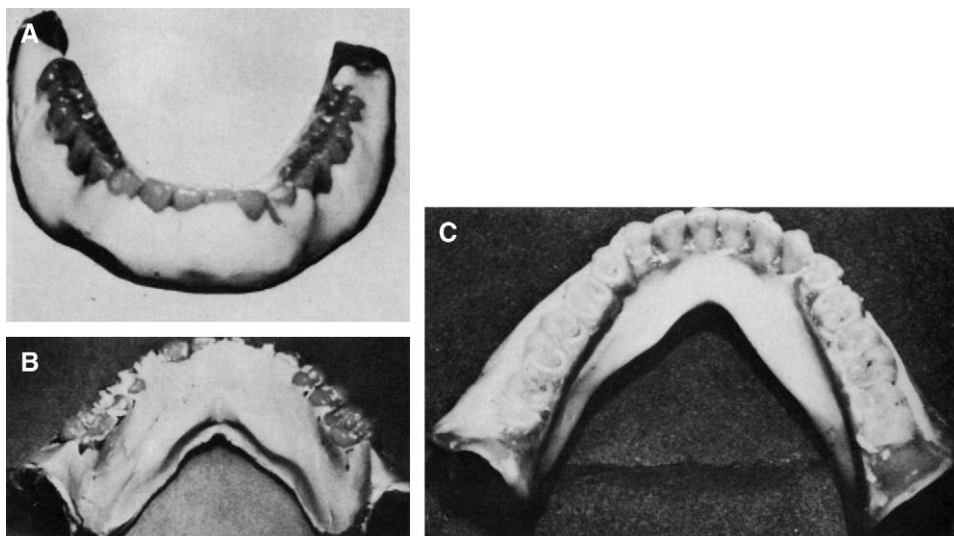


Fig 8. (A) Labiobuccal impression on lower trial denture. Note the narrowing in the bicuspid area created by muscle function. (B) and (C) External lingual lower impression. Note the ledge formed by the tongue during swallowing. (From Beresin VE, Schiesser FJ. *The neutral zone in complete dentures*. St. Louis: C. V. Mosby Co; 1973.)

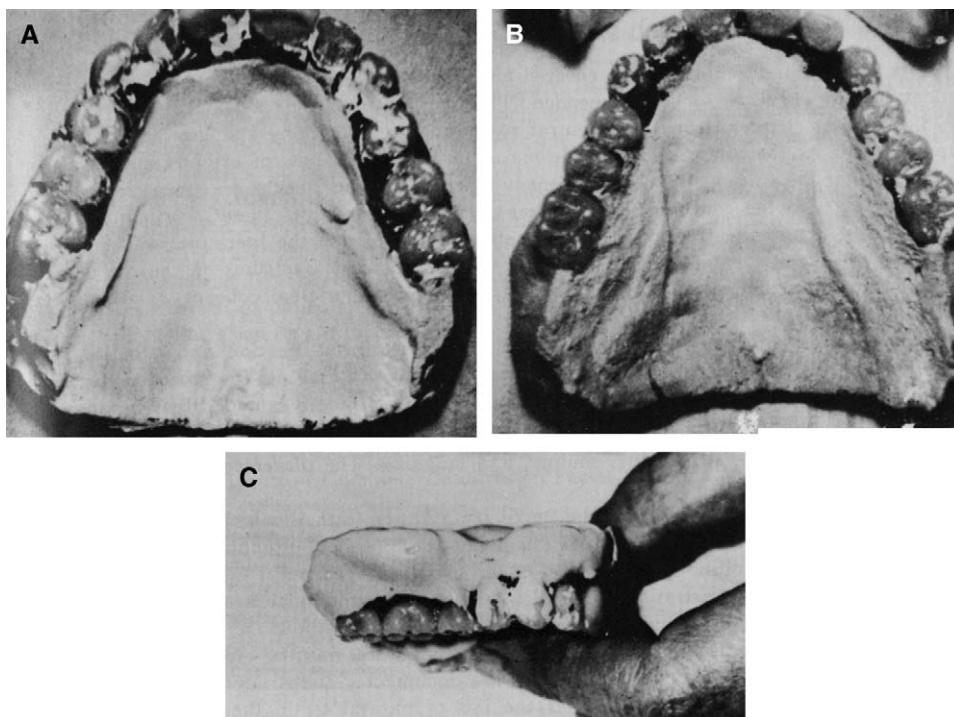


Fig 9. A and B, External impression on palate of trial denture. Note bulges or eminentiae lingual to molars. C, External impression on the labial and buccal parts of upper trial denture. Note that there is a prominence over the first molar area. (From Beresin VE, Schiesser FJ. *The neutral zone in complete dentures*. St. Louis: C. V. Mosby Co; 1973.)

any other factor. We should not be dogmatic and insist that teeth be placed over the crest of the ridge, buccal or lingual to the ridge. Teeth should be placed as dictated by the musculature, and this will vary for different

patients. Positioning artificial teeth in the neutral zone achieves two objectives.

First, the teeth will not interfere with the normal muscle function, and second, the forces exerted by the

musculature against the dentures are more favorable for stability and retention.

REFERENCES

1. Fish EW. Principles of full denture prosthesis. 7th ed. London: Staples Press, Ltd; 1948.
2. Tench RW. Personal communication, 1952.
3. Brill N, Tryde G, Cantor R. The dynamic nature of the lower denture space. *J Prosthet Dent* 1965;15:401-18.
4. Cavalcanti AA. Personal communication, 1962.
5. Lammie GA. Aging changes in the complete lower denture. *J Prosthet Dent* 1956;6:450-64.
6. Lott F, Levin B. Flange technique, an anatomic and physiologic approach to increased retention, function, comfort, and appearance of denture. *J Prosthet Dent* 1996;16:394-413.

7. Raybin NH. The polished surface of complete dentures. *J Prosthet Dent* 1963;13:236-41.
8. Russell AF. The reciprocal lower denture. *J Prosthet Dent* 1959;9:180-90.
9. Wright CR, Swartz WH, Godwin WC. Mandibular stability. Ann Arbor (MI): Overbeck Co; 1961.
10. Perry C. Personal communication, 1972.

0022-3913/\$32.00

Copyright © 2006 by The Editorial Council of *The Journal of Prosthetic Dentistry*.

doi:10.1016/j.prosdent.2005.10.005

Discussion*

Perry W. Bascom, BS, DDS**

Drs. Beresin and Schiesser have covered an important area of prosthodontics in a very excellent paper. They are to be commended. The authors published a book on this subject in 1973. The first chapter defines the neutral zone and its philosophy and lists 33 references in support of it. As they state, the neutral-zone approach is not new or original but an attempt to tie together the concepts and ideas of many men. Fish¹ and Tench² are given credit for contributing much to the concept. Several other dentists also refer to these investigators in their writings. My first real introduction to this concept, aside from the literature, was a presentation by the Detroit Dental Clinic Club. The Club published a syllabus on the use of neuromuscular function in denture construction, based upon the original concept, as a cooperative effort with Tench, Perry, and others.

The ultimate objective of prosthodontics is to restore form, function, and esthetics. As the authors state, the profession has been concerned with the occlusal and impression surfaces. Fish pointed out that there are three surfaces and the third surface is bounded by the tongue and cheeks or the polished surface. The tongue, lips, cheeks, and floor of the mouth are involved in speech, mastication, swallowing, smiling, and laughing. The placement of teeth must be in harmony with these functions.

It is the opinion of many that the maxillary anterior teeth should be placed close to the position of the natural anterior teeth. If this is not accomplished, esthetics and phonetics might be compromised. In addition, the position of the maxillary teeth must satisfy the desires of the patient. Neutral-zone registrations may

dictate that the mandibular anterior teeth be placed lingually by the lower lip. This usually can be accomplished without sacrificing esthetics.

In replacing form in addition to the teeth, consideration must be given to the loss of alveolar process in the posterior areas. Martone³ has documented the structural losses and changes that take place during resorption. After the loss of natural teeth, the maxillae resorb in a lingual direction. Pound⁴ pointed out that in advanced resorption the maxillary ridge moves lingually and the mandibular ridge moves buccally. Werner demonstrated this phenomenon with the use of wooden models. Atwood⁵ divides the factors related to the rate of resorption into the categories of anatomic, metabolic, functional, and prosthetic. Our knowledge of these factors is imperfect, and we know that resorption may take place despite our best efforts at prevention. Many others have studied the changes that take place with resorption of the maxillae and mandible. The neutral-zone approach registers the neutral zone to determine the proper placement of teeth after resorption has taken place.

Recording of tongue positions and movement receives close attention in the neutral-zone approach. Wright and associates⁶ pointed out that the border-seal area for the mandibular denture extends downward to the floor of the mouth and posteriorly into the lateral throat form. Rinaldi and Sharry⁷ refer to a study that indicated that the tongues of aged persons showed no atrophic tendencies, which is not true of other tissues. It is advantageous to record the positions of the tongue during sucking, swallowing, and movement.

Opposing the maxillary and mandibular teeth on the buccal surface is the buccinator muscle. This muscle helps to place food over the occlusal surfaces of the teeth

*Read before the Academy of Denture Prosthetics, Washington, D.C.

**Dental Service, Veterans Administration Hospital, Hines, Ill.