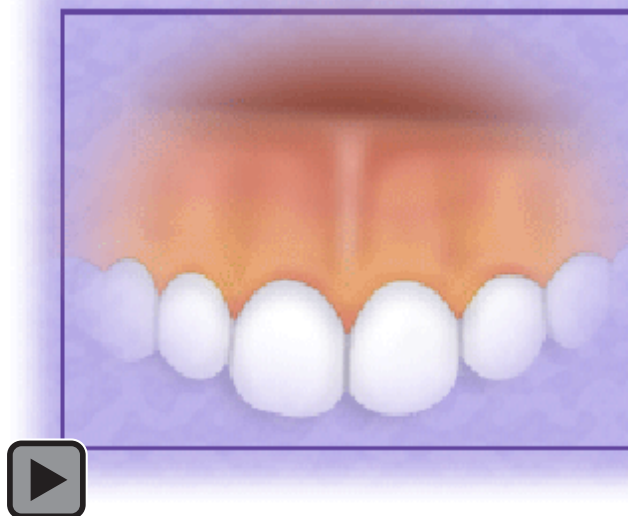


## The Normal and Pathological Pigmentation of Oral Mucous Membrane: A Review

Yasin ÇIÇEK DDS, Phd; Ümit ERTAŞ DDS Phd



### Abstract

Pigmentation is both the normal and abnormal discoloration of oral mucous membrane. Pigmentation has multifactorial etiology. Most of the pigmentation is physiologic but sometimes it can be a precursor of severe diseases. Melanin pigment irregularities and color changes of the oral tissues could provide significant diagnostic evidence of both local and systemic disease.

The differential diagnosis, clinical, etiology, and histopathological features of pigmentation are discussed and the current literature is reviewed.

**Keywords:** Pigmentation, gingiva, oral lesions, oral mucosa, Peutz-Jeghers syndrome, Burtonian line.

**Citation:** Çiçek Y. The Normal and Pathological Pigmentation of Oral Mucous Membrane: A Review. J Contemp Dent Pract 2003 August;(4)3:076-086.

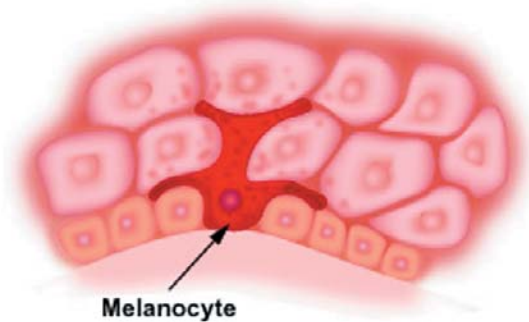
© Seer Publishing

## Introduction

Pigmentation is a discoloration of the oral mucosa or gingiva due to the wide variety of lesions and conditions. Oral pigmentation has been associated with a variety of endogenous and exogenous etiologic factors.<sup>1,2</sup> Most pigmentation is caused by five primary pigments. These include: melanin, melanoid, oxyhemoglobin, reduced haemoglobin, and carotene.<sup>3</sup> Others are caused by bilirubin and iron.

## Melanin

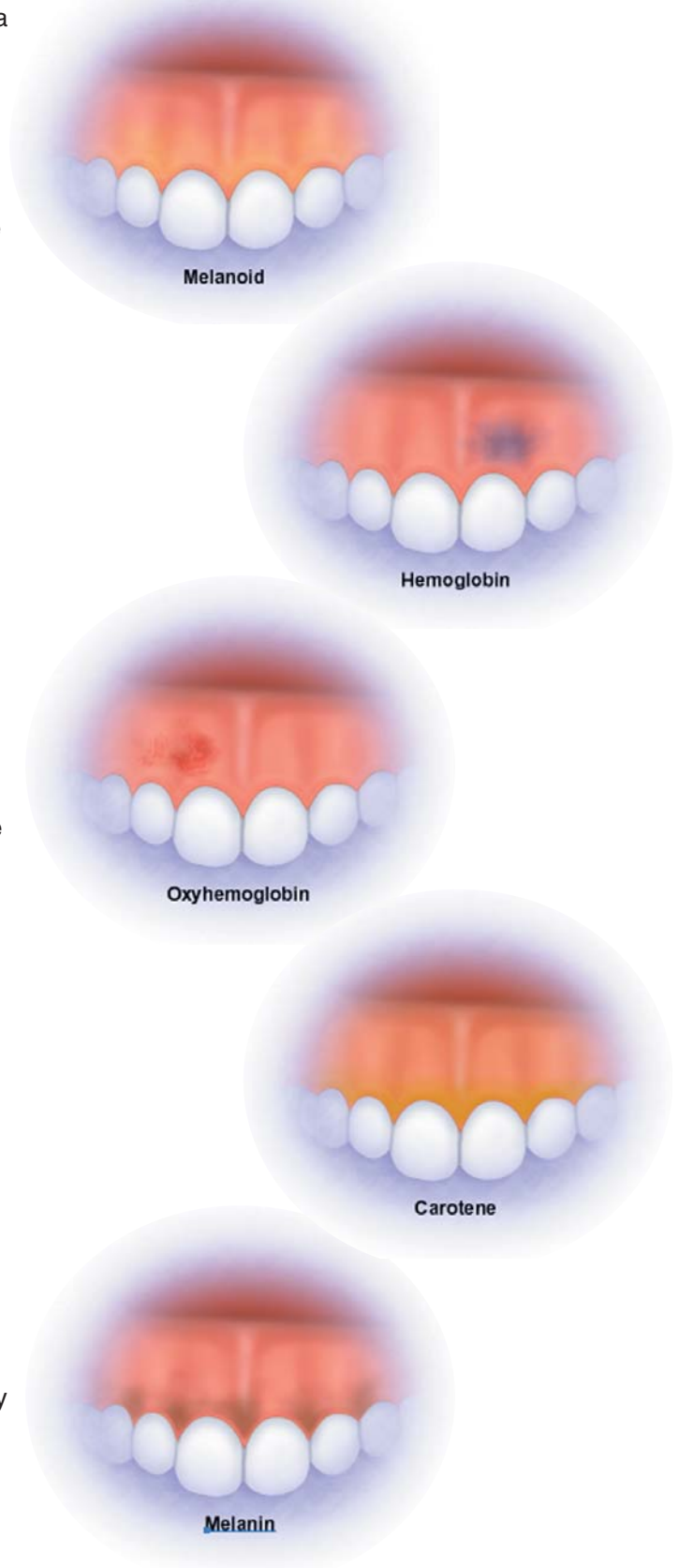
Melanin, a nonhemoglobin derived brown pigment, is the most common of the endogenous pigments and is produced by melanocytes present in the basal layer of the epithelium.<sup>4,5</sup> Melanocytes have a round nucleus with a double nucleus membrane and clear cytoplasm lacking desmosomes or attachment plates.<sup>6</sup> Melanin accumulates in the cytoplasm, and the melanosome is transformed into a structureless particle no longer capable of melanogenesis.<sup>6</sup> The number of melanocytes in the mucosa corresponds numerically to that of skin; however, in the mucosa their activity is reduced. Various stimuli can result in an increased production of melanin at the level of mucosa including trauma, hormones, radiation, and medications.<sup>2</sup> Tyrosinase activity is present in premelanosome and melanosomes but absent in melanin granules.<sup>6</sup>



## Melanoid

Granules of melanoid pigment are scattered in the stratum lucidum and stratum corneum of the skin. Initially it was assumed melanoid was a degradation product of melanin, but more recently it has been shown that such a relationship is highly improbable. Melanoid imparts a clear yellow shade to the skin.<sup>3</sup>

## 5 Primary Pigmentations



### Oxyhemoglobin and Reduced Hemoglobin

Oxyhemoglobin and reduced hemoglobin are pigments resulting from hemosiderin deposits. The skin color is affected by the capillary and venom plexuses shining through the skin.<sup>3</sup>

### Carotene

Carotene is distributed in the lipids of the stratum corneum and stratum lucidum and gives a deep yellow color to the skin. It is found in higher concentrations in more women than in men.

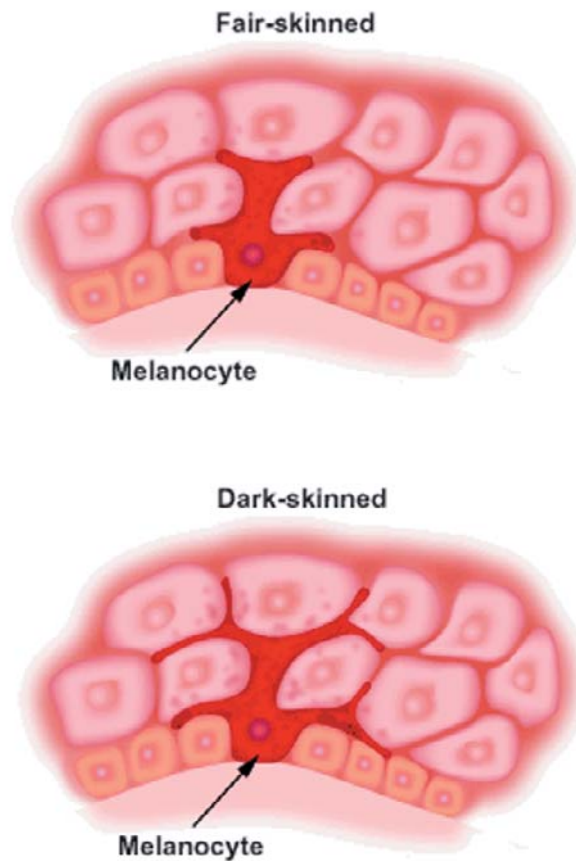
Pigmented lesions of the oral cavity are of multiple origin. Different classifications are used at this time. Some researchers divide the lesions into two main groups as either endogenous or exogenous lesions.<sup>1,7</sup> Brocheriou et al.<sup>8</sup> subdivides pigmented lesions as follows:

- Non tumoral pigmentations
- Non melanin pigmented tumors or tumor like lesions
- Benign melanin pigmented tumors
- Malignant melanomas

In several articles on oral pigmentation, Dummett and others implicate many systemic and local factors as causes of changes in oral pigmentation.<sup>9</sup>

### Epidemiology

Oral pigmentation occurs in all races of man.<sup>10,11</sup> There were no significant differences in oral pigmentation between males and females.<sup>3</sup> The intensity and distribution of racial pigmentation of the oral mucosa is variable, not only between races, but also between different individuals of the same race and within different areas of the same mouth.<sup>4</sup> Physiologic pigmentation is probably genetically determined, but as Dummett suggested<sup>12</sup>, the degree of pigmentation is partially related to mechanical, chemical, and physical stimulation. In darker skinned people oral pigmentation increases, but there is no difference in the number of melanocytes between fair-skinned and dark-skinned individuals. The variation is related to differences in the activity of melanocytes.<sup>4</sup> There is some controversy about the relationship between age and oral pigmentation. Steigmann and Amir et al.<sup>2</sup> stated all kinds of oral pigmentation appear in young children. Prinz<sup>13</sup>, on the other hand, claimed



physiologic pigmentation did not appear in children and was clinically visible only after puberty.

### Clinical Characteristics

The gingivae are the most frequently pigmented intraoral tissues.<sup>4,10,14</sup> Microscopically, melanoblasts are normally present in the basal layers of the lamina propria.<sup>15,16</sup> The most common location was the attached gingiva (27.5%) followed in decreasing order by the papillary gingiva, the marginal gingiva, and the alveolar mucosa.<sup>3,17,18</sup>

The total number of melanophores in the attached gingival was approximately 16 times greater than in the free gingival.<sup>19</sup> The prevalence of gingival pigmentation was higher on the labial part of the gingiva than on the buccal and palatal/lingual parts of the arches.<sup>17</sup> The shade of pigment was classified as very dark brown to black, brown, light brown-yellow.<sup>3</sup> Melanin pigmentation of the oral tissues usually does not present a medical problem, but patients complain of black gums.

## Classification and Differential Diagnosis

Oral pigmentation has been associated with a variety of lesions and conditions.<sup>20-32</sup>

Differential diagnosis of oral mucous membrane pigmentations are made according to the following situations:

- A. **Localized Pigmentations:** Amalgam tattoo, graphite or other tattoos, nevus, melanotic macules, melanoacanthoma, malignant melanoma, Kaposi's sarcoma, epithelioid oligomatosis, verruciform xanthoma
- B. **Multiple or Generalized Pigmentations**
  1. **Genetics:** Idiopathic melanin pigmentation (racial or physiologic pigmentation), Peutz-Jegher's syndrome, Laugier-Hunziker syndrome, complex of myxozomas, spotty pigmentation, endocrine overactivity, Carney syndrome, Leopard syndrome, and lentiginosis profuse
  2. **Drugs:** Smoking, betel, anti-malarials, antimicrobials, minocycline, amiodarone, clorpromazine, ACTH, zidovudine, ketoconazole, methyl dopa, busulphan, menthol, contraceptive pills, and heavy metals exposure (gold, bismuth, mercury, silver, lead, copper)
  3. **Endocrine:** Addison's disease, Albright's syndrome, Acanthosis nigricans, pregnancy, hyperthyroidism
  4. **Postinflammatory:** Periodontal disease, postsurgical gingival repigmentation
  5. **Others:** Haemochromatosis, generalized neurofibromatosis, incontinenti pigmenti, Whipple's disease, Wilson's disease, Gaucher's disease, HIV disease, thalassemia, pigmented gingival cyst, and nutritional deficiencies

## Systemic and Local Causes of Pigmentation

Many systemic and local factors are caused by changes in oral pigmentation. Some of the important factors are discussed below.

### Amalgam Tattoo

The pigmentation of the oral mucous membrane by tooth restoration material (amalgam) is a common finding in dental practice.<sup>33</sup> Amalgam pigmentation is generally called amalgam tattoo.<sup>34</sup> The lesion represents embedded amalgam

particles and usually manifests itself as an isolated bluish or black macule in various areas of the mucosa.<sup>34</sup> The color is usually described as black, blue, grey, or a combination of these. Almost half were located on the gingiva and alveolar mucosa, the mandibular region being affected more than the maxillary region.<sup>34</sup> Almost half of the lesions were asymptomatic and were discovered during routine dental examination. The amalgam granules and fragments were found mainly in the lamina propria but were sometimes seen in the submucosa.<sup>34</sup>

### Pigmented Nevi

Pigmented nevi of the oral cavity are uncommon.<sup>35</sup> The pigmented nevi are classified as intramucosal, junctional, compound, or blue according to their histological features.<sup>35</sup> Nevi are seen particularly on the vermilion border of the lips and the gingivae. They are usually grey, brown, or bluish macules and are typically asymptomatic.<sup>36</sup> Melanocytes are pigment producing cells characterized by the ability to synthesize via the enzyme dihydroxyphenylalanine (DOPA). A group of melanocytes (generally four or more) are in contact with the basal layer of the epithelium.<sup>36</sup>

### Oral Melanotic Macules

Oral melanotic macules are relatively rare oral mucosal lesions, analogous to skin freckles, due to the focal increase of melanin production.<sup>37</sup> These melanotic macules have been variously termed ephelis, melonosis, lentigo, solitary labial lentigo, labial melanotic macule, and oral melanotic macule.<sup>36,37-40</sup> The vermilion border of the lower lip is most commonly involved.<sup>23</sup> The buccal mucosa, palate, and gingiva are less commonly affected. The color is usually described as grey, brown, blue, black, or a combination of these.<sup>34</sup> Histologically, ephelis shows increased melanin pigmentation in the basal cell layer without an increase in the number of melanocytes; otherwise, the epidermis is normal.<sup>34</sup>

### Melanoma

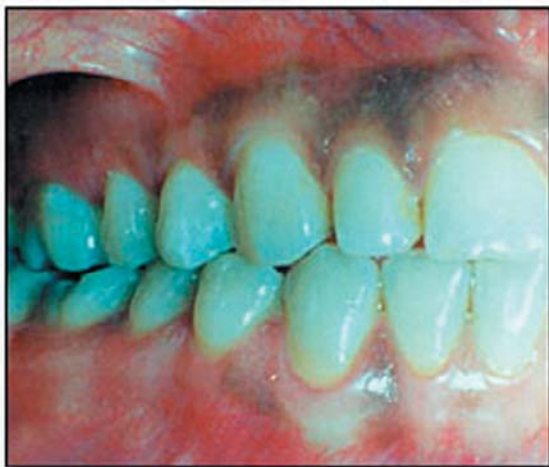Melanoma is a cancerous condition of the melanocyte. Special corpuscles in this cell, known as melanosomes, contain the necessary enzyme (tyrosinase) to transform amino acids into melanin.<sup>41</sup> Melanocytes are found among the

basal cells of the epidermis. Histopathologically, the mucosal epithelium is abnormal with large atypical melanocytes and excessive melanin.<sup>36</sup> Malignant melanoma of the oral mucosa affects both sexes equally usually after 40 years of age. The great majority of the lesions (about 70-80%) occur on the palate, upper gingival, and alveolar mucosa.<sup>37</sup> Initially there usually is a solitary small asymptomatic brown or black macule.

### Physiologic Pigmentation

Physiologic pigmentation of the oral mucosa is clinically manifested as multifocal or diffuse melanin pigmentation with variable prevalence in different ethnic groups.<sup>2</sup> Melanin is normally found in the skin of all people.<sup>11</sup> (Figure 1)

In dark skinned persons the gingiva may contain melanin pigment to a greater extent than the adjacent alveolar mucosa. The melanin pigment is synthesized in specialized cells, the melanocytes, located in the basal layer of the epithelium. The melanin is produced as granules. The melanosomes are stored within the cytoplasm of the melanocytes, as well as in the cytoplasm of adjacent keratinocytes. Melanocytes are embryologically derived from neural crest cells that eventually migrate into the epithelium. If pigmented gingiva is surgically resected, it will often heal with little or no pigmentation; therefore, surgical procedures should be designed so as to preserve the pigmented tissues.



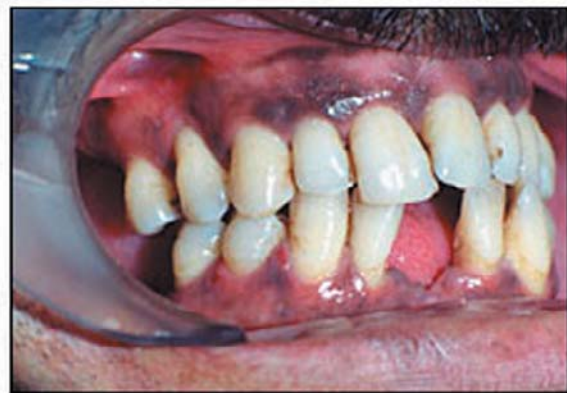**Figure 1.** Physiologic pigmentation.

### Peutz-Jeghers Syndrome

Peutz-Jeghers syndrome (intestinal polyposis) is a genetic disorder characterized by mucocutaneous pigmentation and hamartomas of the intestine.<sup>37</sup> It manifests itself as freckle-like macules about the hands, perioral skin, and intraorally to include the gingiva, buccal, and labial mucosa.<sup>42</sup> Pigmented spots are 1 to 10 mm in diameter. Pigmented spots are particularly found on the lower lip and buccal mucosa but rarely on the upper lip, tongue, palate, and gingiva.

### Smoker's Melanosis

Smoker's melanosis is a benign focal pigmentation of the oral mucosa.<sup>15</sup> It tends to increase significantly with tobacco consumption.<sup>43</sup> Tobacco smokers have significantly more oral surfaces pigmented than non-tobacco users.<sup>44</sup> Clinically, the lesion usually presents as multiple brown pigmented macules less than 1 cm in diameter, localized mainly at the attached labial anterior gingival and the interdental papillae of the mandible. Smoker's melanosis is more common in females usually after the third decade of life.<sup>37</sup>



**Figure 2.** Smoker's melanosis.

### Antimalaria Drug Use

Several antimalarial drugs are known to be capable of inducing intraoral melanin pigmentation. These drugs include: quinacrine, chloroquine, and hydroxychloroquine.<sup>45,46</sup> Long-term use may cause pigmentation of the oral mucosa. The pigmentation of the oral mucosa is described as slate-grey in color, bearing some resemblance to pigmentation caused by silver arsphenamine.<sup>47</sup>

### Minocycline Use

Minocycline is a synthetic tetracycline that is commonly used in the treatment of acne vulgaris.<sup>1,48</sup> Although tetracycline causes pigmentation of bones and teeth, minocycline alone is also responsible for soft tissue pigmentation.<sup>49</sup> It is usually seen as brown melanin deposits on the hard palate, gingiva, mucous membranes, and the tongue.<sup>1,49</sup>

### Heavy Metals

Heavy metals absorbed systemically from therapeutic use or occupational environments may discolor the gingiva and other areas of the oral mucosa.<sup>5</sup> Bismuth, arsenic, and mercury produce a black line in the gingiva which follows the contour of the margin. Lead results in a bluish red or deep blue linear pigmentation of the gingival margin (Burtonian line). Exposure to silver causes a violet marginal line, often accompanied by a diffuse bluish-grey discoloration throughout the oral mucosa.

### Addison's Disease

Addison's disease or primary adrenocortical hypofunction is due to adrenocortical damage and hypofunction.<sup>36,50</sup> Bronzing of the skin and increased pigmentation of the lips, gingivae, buccal mucosa, and tongue may be seen. Oral pigmentation may be the first sign of the disease.<sup>50</sup> A biopsy of the oral lesions shows acanthosis with silver-positive granules in the cells of the stratum germinativum. Melanin is seen in the basal layer.<sup>50</sup>

### Periodontal Diseases

Periodontal diseases often produce discolorations of the oral mucosa.<sup>15</sup> The pigmentation is worsened by gingivitis, which increases vascular permeability and allows the heavy metals access to the soft tissues.<sup>51</sup> Melanin re-pigmentation is related to after surgical injury.<sup>52</sup>

### Hemachromatosis

Hemachromatosis (bronze diabetes) is a chronic disease characterized by the deposition of excess iron (ferritin and hemosiderin) in the body tissues, resulting in fibrosis and functional insufficiency of the involved organs.<sup>53</sup> Hyperpigmentation may appear both in skin and mucous membranes (oral and conjunctiva).<sup>37</sup> Gingival or mucosal pigmentation is reported to occur in

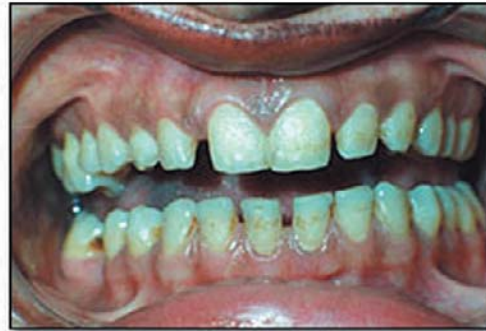

Figure 3a. Pigmentation of the gingival.

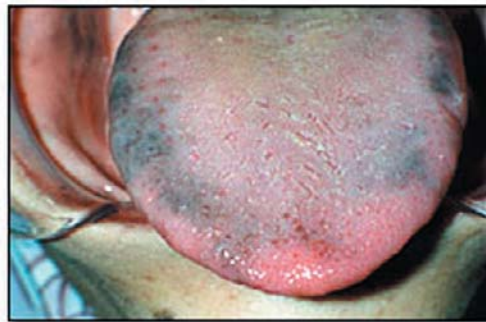

Figure 3b. Pigmentation of the tongue (dorsal view).

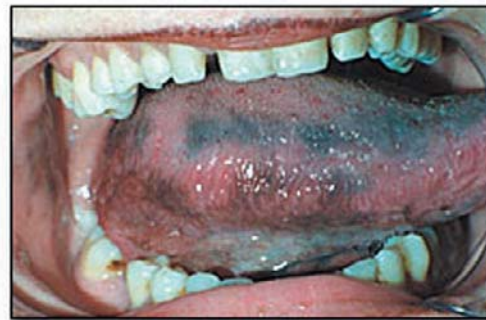

Figure 3c. Pigmentation of the tongue (lateral view).

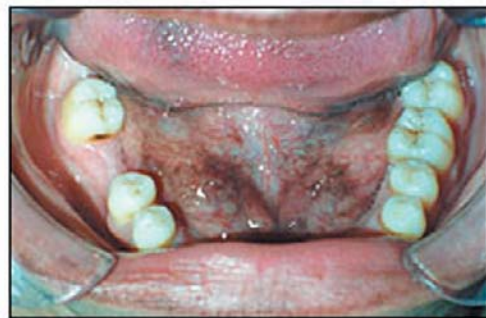

Figure 3d. Pigmentation of the floor of the mouth.

15 to 25% of patients with hemochromatosis.<sup>53</sup> The oral mucosa shows diffuse homogeneous pigmentation of gray-brown or deep brown in about 20% of the cases.<sup>37</sup> The buccal mucosa and the attached gingiva are the most frequently involved sites.<sup>37</sup>

### HIV Infection

In patients infected with human immunodeficiency virus (HIV), progressive hyperpigmentation of the skin, oral mucosa, fingernails, and toenails have been reported being related to primary adrenocortical deficiency and to zidovudine (azidothymidine) therapy in some cases.<sup>54</sup> Clinically, oral pigmentation appears as irregular macules with brown or dark brown color. The tongue, buccal mucosa, and palate are the most commonly affected sites.<sup>37</sup>

### Conclusion

The integrity of the oral mucous membrane is maintained by a wide range of complex factors including those dependent on adequate nutrition.<sup>37,55</sup> A wide range of conditions has

been described in the past which depend on the absence or reduction of certain specific nutritional factors, particularly vitamins.

The recognition, identification, and clinical assessment of pigmentation is of great importance because of the possible risk of serious systemic disease, such as melanoma, various syndromes, and the side effects of drugs.



### References

1. Meyerson MA, Cohen PR, Hymes SR. Lingual hyperpigmentation associated with minocycline therapy. *Oral Surg Oral Med Oral Pathol Oral Radiol Endod.* 1995 Feb;79(2):180-4.
2. Amir E, Gorsky M, Buchner A, et. al. Physiologic pigmentation of the oral mucosa in Israeli children. *Oral Surg Oral Med Oral Pathol.* 1991 Mar;71(3):396-8.
3. Steigmann S. Treatment of melanin-pigmented gingiva and oral mucosa by CO2 laser. *Oral Surg Oral Med Oral Pathol Oral Radiol Endod.* 2000 Jul;90(1):14-5. No abstract available.
4. Özbayrak S, Dumlu A, Ercalik-Yalcinkaya S. Treatment of melanin-pigmented gingiva and oral mucosa by CO2 laser. *Oral Surg Oral Med Oral Pathol Oral Radiol Endod* 2000; 90: 14-15.
5. Carranza AC, Saglie FR. Clinical features of gingivitis In: Carranza FA. *Clikman's clinical periodontology.* Philadelphia:WB Saunders company 1990:109-125.
6. Dummett CO, Barens G. Oromucosal pigmentation: an updated literary review. *J Periodontol.* 1971 Nov;42(11):726-36. Review. No abstract available.
7. Gazi MI. Unusual pigmentation of the gingiva. Report of two different types. *Oral Surg Oral Med Oral Pathol.* 1986 Dec;62(6):646-9.
8. Brocheriou C, Kuffer R, Verola O. [Pigmented lesions of the oral cavity] *Ann Pathol.* 1985;5(4-5): 221-9. French.
9. Merchant HW, Hayes LE, Ellison LT. Soft-palate pigmentation in lung disease, including cancer. *Oral Surg Oral Med Oral Pathol.* 1976 Jun;41(6):726-33.
10. Perlmutter S, Tal H. Repigmentation of the gingiva following surgical injury. *J Periodontol.* 1986 Jan;57(1):48-50.
11. Tamizi M, Taheri M. Treatment of severe physiologic gingival pigmentation with free gingival autograft. *Quintessence Int.* 1996 Aug;27(8):555-8.
12. Dummett CO. Clinical observation on pigment variations in healthy oral tissues in the Negro. *J Dent Res.* 1945;24:7-13.
13. Prinz H. Pigmentation of the oral mucous membrane. *Dental Cosmos.* 1932;72:554-561.
14. Yeh CJ. Cryosurgical treatment of melanin-pigmented gingiva. *Oral Surg Oral Med Oral Pathol Oral Radiol Endod.* 1998 Dec;86(6):660-3.

15. Dummett CO. Oral tissue color changes (I). *Quintessence Int.* 1979 Nov;10(11):39-45. No abstract available.
16. Brown FH, Houston GD. Smoker's melanosis. A case report. *J Periodontol.* 1991 Aug;62(8):524-7. Review.
17. Gorsky M, Buchner A, Fundoianu-Dayana D, et. al. Physiologic pigmentation of the gingiva in Israeli Jews of different ethnic origin. *Oral Surg Oral Med Oral Pathol.* 1984 Oct;58(4):506-9.
18. Dummett CO, Barends G. Pigmentation of the oral tissues: a review of the literature. *J Periodontol.* 1967;38:360-78.
19. Patsakas A, Demetriou N, Angelopoulos A. Melanin pigmentation and inflammation in human gingiva. *J Periodontol.* 1981 Nov;52(11):701-4.
20. Porter SR, Flint SR, Scully C. *Oral Diseases.* Martin Dunitz, second edition, London 1996, 1-371.
21. Laskaris G. *Color atlas of oral diseases in children and adolescents.* Thieme Stuttgart, New York 1999, 1-337.
22. Demas PN, Bridenstine JB, Braun TW. Pharmacology of agents used in the management of patients having skin resurfacing. *J Oral Maxillofac Surg.* 1997 Nov;55(11):1255-8. Review.
23. Mercado-Ortiz G, Wilson D, Jiang DJ. Reverse smoking and palatal mucosal changes in Filipino women. Epidemiological features. *Aust Dent J.* 1996 Oct;41(5):300-3.
24. Ashri N, Gazi M. More unusual pigmentations of the gingiva. *Oral Surg Oral Med Oral Pathol.* 1990 Oct;70(4):445-9.
25. Weathers DR, Corio RL, Crawford BE, et. al. The labial melanotic macule. *Oral Surg Oral Med Oral Pathol.* 1976 Aug;42(2):196-205.
26. Stern D. The influence of systemic cancer on the oral tissues. *Oral Surg Oral Med Oral Pathol.* 1970 Feb;29(2):229-36. No abstract available.
27. Koplon BS, Hurley HJ. Prominent pigmented papillae of the tongue. *Arch Derm.* 1967; 95: 394-396.
28. Greenberg MS. Clinical and histologic changes of the oral mucosa in pernicious anemia. *Oral Surg Oral Med Oral Pathol.* 1981 Jul;52(1):38-42. No abstract available.
29. Buchner A, Calderon S, Ramon Y. Localized hyperplastic lesions of the gingiva: a clinicopathological study of 302 lesions. *J Periodontol.* 1977 Feb;48(2):101-4.
30. Cale AE, Freedman PD, Lumermant H. Pigmentation of the jawbones and teeth secondary to minocycline hydrochloride therapy. *J Periodontol.* 1988 Feb;59(2):112-4.
31. Lockhart PB. Gingival pigmentation as the sole presenting sign of chronic lead poisoning in a mentally retarded adult. *Oral Surg Oral Med Oral Pathol.* 1981 Aug;52(2):143-9.
32. Kleinegger CL, Hammond HL, Finkelslein MW. Oral mucosal hyperpigmentation secondary to anti-malarial drug therapy. *Oral Surg Oral Med Oral Pathol Oral Radiol Endod.* 2000 Aug;90(2):189-94.
33. Simon E, Buchner A, Bubis JJ. Asteroid bodies in foreign-body reaction to amalgam. *Oral Surg Oral Med Oral Pathol.* 1972 May;33(5):772-4. No abstract available.
34. Buchner A, Hansen LS. Amalgam pigmentation (amalgam tattoo) of the oral mucosa. A clinicopathologic study of 268 cases. *Oral Surg Oral Med Oral Pathol.* 1980 Feb;49(2):139-47.
35. Dyer PV, Eveson JW. Recurrent compound naevus of gingiva. *J Periodontol.* 1993 Aug;64(8): 739-41.
36. Scully C. *Handbook of oral disease diagnosis and management.* Martin Dunitz, London, 1999, 1-420.
37. Laskaris G. *Color atlas of oral diseases.* Thieme Med Pub Stuttgart, second edition, New York 1994, 1-372.
38. Buchner A, Hansen LS. Melanotic macule of the oral mucosa. A clinicopathologic study of 105 cases. *Oral Surg Oral Med Oral Pathol.* 1979 Sep;48(3):244-9.
39. Page LR, Corio RL, Crawford BE, et. al. The oral melanotic macule. *Oral Surg Oral Med Oral Pathol.* 1977 Aug;44(2):219-26.
40. Teles JC, Cardoso AS, Goncalves AR. Blue nevus of the oral mucosa. Review of the literature and report of two cases. *Oral Surg Oral Med Oral Pathol.* 1974 Dec;38(6):905-10. No abstract available.
41. Grinspan D, Abulafia J, Diaz J, et. al. Melanoma of the oral mucosa. A case of infiltrating melanoma originating in Hutchinson's malignant lentigo or precancerous melanosis of Dubreuilh. *Oral Surg Oral Med Oral Pathol.* 1969 Jul;28(1):1-16. No abstract available.



42. Gorlin RJ, Cohen MN, Levin LS. Syndromes of the head and neck. 3rd ed. New York:Oxford University Press,1990.
43. Araki S, Murata K, Ushio K, et. al. Dose-response relationship between tobacco consumption and melanin pigmentation in the attached gingiva. Arch Environ Health. 1983 Nov-Dec;38(6):375-8.
44. Ramer M, Burakoff RP. Smoker's melanosis. Report of a case. N Y State Dent J. 1997 Oct;63(8):20-1.
45. Birek C, Main JH. Two cases of oral pigmentation associated with quinidine therapy. Oral Surg Oral Med Oral Pathol. 1988 Jul;66(1):59-61.
46. Veraldi S, Schianchi-Veraldi R, Scarabelli G. Pigmentation of the gums following hydroxychloroquine therapy. Cutis. 1992 Apr;49(4):281-2.
47. Giansanti JS, Tillery DE, Olansky S. Oral mucosal pigmentation resulting from antimalarial therapy. Oral Surg Oral Med Oral Pathol. 1971 Jan;31(1):66-9. No abstract available.
48. Odell EV, Hodgson RP, Haskell R. Oral presentation of minocycline-induced black bone disease. Oral Surg Oral Med Oral Pathol Oral Radiol Endod. 1995 Apr;79(4):459-61.
49. Cockings JM, Savage NW. Minocycline and oral pigmentation. Aust Dent J. 1998 Feb;43(1):14-6. Review.
50. Chuong R, Goldberg MH. Case 47, part II: Oral hyperpigmentation associated with Addison's disease. J Oral Maxillofac Surg. 1983 Oct;41(10):680-2.
51. Wrigt JM. Oral manifestations of drug reactions. Dent Clin North Am. 1984 Jul;28(3):529-43.
52. Bergamaschi O, Kon S, Doine AI, et. al. Melanin repigmentation after gingivectomy: a 5-year clinical and transmission electron microscopic study in humans. Int J Periodontics Restorative Dent. 1993;13(1):85-92.
53. Frantzis TG, Sheridan PJ, Reeve CM, et. al. Oral manifestations of hemochromatosis. Report of a case. Oral Surg Oral Med Oral Pathol. 1972 Feb;33(2):186-90. No abstract available.
54. Langford A, Pohle HD, Gelderblom H, et. al. Oral hyperpigmentation in HIV-infected patients. Oral Surg Oral Med Oral Pathol. 1989 Mar;67(3):301-7.
55. Thildesley WR. Oral medicine. Oxford: Oxford University Press, 1989: 182-200.

### About the Author

**Yasin Çiçek DDS, PhD**



Dr. Çiçek is an associate professor in the department of periodontology in the faculty of dentistry at atatürk university in erzurum-turkey. He received his dental degree and his certificate in periodontics from the university of atatürk school of dentistry. His research interests include recurrent aphthous stomatitis(ras) and oral malodor. Dr. Çiçek is a member of the turkish and europe societies of periodontology.

e-mail: [ycicek@atauni.edu.tr](mailto:ycicek@atauni.edu.tr)

**Ümit Ertaş, DDS, PhD**



Dr. Ertaş is an Assistant Professor in the Department of Oral and Maxillofacial Surgery in the Faculty of Dentistry at Atatürk University in Erzurum, Turkey.