

The pathophysiology of tremor

DEUSCHL, Gunther, *et al.*

Reference

DEUSCHL, Gunther, *et al.* The pathophysiology of tremor. *Muscle & nerve*, 2001, vol. 24, no. 6, p. 716-735

PMID : 11360255

Available at:

<http://archive-ouverte.unige.ch/unige:95862>

Disclaimer: layout of this document may differ from the published version.

ABSTRACT: Tremor is defined as rhythmic oscillatory activity of body parts. Four physiological basic mechanisms for such oscillatory activity have been described: mechanical oscillations; oscillations based on reflexes; oscillations due to central neuronal pacemakers; and oscillations because of disturbed feedforward or feedback loops. New methodological approaches with animal models, positron emission tomography, and mathematical analysis of electromyographic and electroencephalographic signals have provided new insights into the mechanisms underlying specific forms of tremor. Physiological tremor is due to mechanical and central components. Psychogenic tremor is considered to depend on a clonus mechanism and is thus believed to be mediated by reflex mechanisms. Symptomatic palatal tremor is most likely due to rhythmic activity of the inferior olive, and there is much evidence that essential tremor is also generated within the olivocerebellar circuits. Orthostatic tremor is likely to originate in hitherto unidentified brainstem nuclei. Rest tremor of Parkinson's disease is probably generated in the basal ganglia loop, and dystonic tremor may also originate within the basal ganglia. Cerebellar tremor is at least in part caused by a disturbance of the cerebellar feedforward control of voluntary movements, and Holmes' tremor is due to the combination of the mechanisms producing parkinsonian and cerebellar tremor. Neuropathic tremor is believed to be caused by abnormally functioning reflex pathways and a wide variety of causes underlies toxic and drug-induced tremors. The understanding of the pathophysiology of tremor has made significant progress but many hypotheses are not yet based on sufficient data. Modern neurology needs to develop and test such hypotheses, because this is the only way to develop rational medical and surgical therapies.

© 2001 John Wiley & Sons, Inc. *Muscle Nerve* 24: 716–735, 2001

THE PATHOPHYSIOLOGY OF TREMOR

GÜNTHER DEUSCHL, MD, JAN RAETHJEN, MD, MICHAEL LINDEMANN, MSc,
and PAUL KRACK, MD

Department of Neurology, Christian-Albrechts-Universität, Niemannsweg 147,
D-24105 Kiel, Germany

Accepted 5 December 2000

One of the first state-of-the-art reviews covering the pathophysiology of tremor was that of C. David Marsden in 1984.¹⁵³ Since then, three important books^{68,77,78} and one supplement⁴⁴ on tremor have summarized many aspects of the pathophysiology of tremor.

Tremor research has developed rapidly in the past few years because clinicians and basic neuroscientists have become more interested in the oscilla-

tory phenomena occurring under normal and abnormal conditions. The pathophysiology, however, cannot be discussed without the clinical context and thus we will briefly mention the current clinical classification.

CLINICAL CLASSIFICATION OF TREMORS

A new classification of tremors has been published recently, based on clinical criteria alone.⁴⁴ This classification must suffice the clinical needs and, therefore, it combines etiologically defined tremors (like parkinsonian tremor or dystonic tremor) and tremor syndromes that are phenomenologically defined, such as cerebellar tremor or Holmes' tremor, but can arise from various etiologies. The key features that help clinicians to separate the different tremor entities are: (1) the tremor frequency; (2) the conditions under which the tremor is activated;

Abbreviations: CNS, central nervous system; EEG, electroencephalography; EMG, electromyography; EPT, essential palatal tremor; ET, essential tremor; FDG, ¹⁸fluoro-2-deoxyglucose; GPe, globus pallidus externus; GPi, globus pallidus internus; IO, inferior olive; MEG, magnetoencephalography; PD, Parkinson's disease; PET, positron emission tomography; PTN, pyramidal tract neuron; Put, putamen; SPT, symptomatic palatal tremor; STN, subthalamic nucleus

Key words: basal ganglia; cerebellum; essential tremor; orthostatic tremor; oscillations; physiology; Parkinson's disease; tremor

Correspondence to: G. Deuschl; e-mail: g.deuschl@neurologie.uni-kiel.de

© 2001 John Wiley & Sons, Inc.

and (3) additional information from the medical and family history (e.g., hereditary tremor, factors influencing the tremor) and additional findings on the neurologic examination (e.g., akinesia, rigidity, peripheral neuropathies). Figure 1 lists the different tremors according to this current view.

PHYSIOLOGY OF OSCILLATORY ACTIVITY IN HUMANS

Four Principles of Tremor Genesis. In technical terms, systems able to produce rhythmic activity are called oscillators. This nomenclature has been adopted for human tremor research. An oscillator in

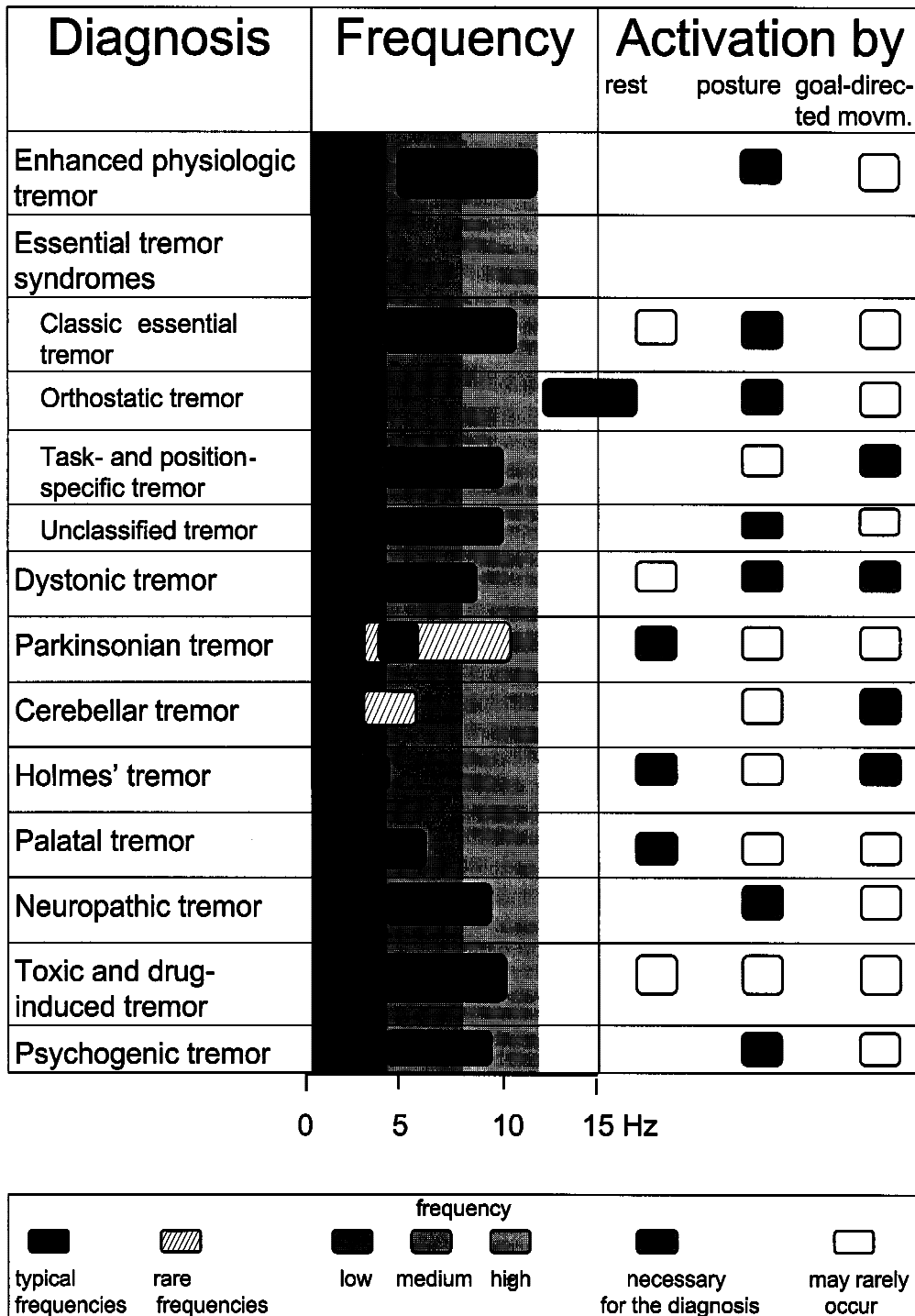


FIGURE 1. Frequency and activation characteristics of tremors.⁴⁴

this biological sense does not necessarily mean a single anatomical structure, but rather a system consisting of body parts and functional connections, including neuronal assemblies that can cause rhythmic activity under certain conditions.

The causes of tremor in humans can be reduced to a limited number of basic factors. The first is mechanical tremor of the extremity, the second is reflex activation leading to oscillatory activity, the third is central oscillators, and the fourth is oscillatory activity that may occur when feedforward or feedback systems become unstable.

The most simple cause of tremor is so-called *mechanical tremor* of the extremity. Consider a stretched-out hand with the extensor muscles tonically activated to counterbalance gravity. Assuming a completely flat spectrum of muscle activity (see Fig. 2), some of the muscle fibers will be activated at the resonance frequency of the hand. Thereby, the hand will oscillate at this resonance frequency, which is determined by the equation:

$$\text{Frequency} \approx \sqrt{\frac{K}{\text{Inertia}}}$$

with K being a constant determined mainly by the stiffness of the muscle and the inertia of the oscillating limb. This resonance frequency is different for different body parts; for instance, 25 Hz for the fingers, 6–8 Hz for the hand, 3–4 Hz for the elbow, and 0.5–2 Hz for the shoulder joint.¹⁵³

The resonance frequency can be decreased by adding mass or increased by adding stiffness. For practical reasons it is easier to add inertia (e.g., by attaching rigidly a weight of 1 kg to the dorsum of the hand). Any mechanical tremor component can be identified this way provided that there is only a small reflex contribution.

The second mechanism is mediated through *reflexes of the central nervous system*. Any movement in one direction (e.g., a flexion movement) will stretch the extensors and cause an afferent volley eliciting reflexes in the antagonistic extensors. While the extensor is activated, the flexor will be stretched, causing an afferent volley from the flexors. When the reflex gains and the conduction time for the afferent and efferent conduction are appropriate, an oscillation will result.^{205,206} Theoretically, it is expected that the frequency of the tremor will be lower when

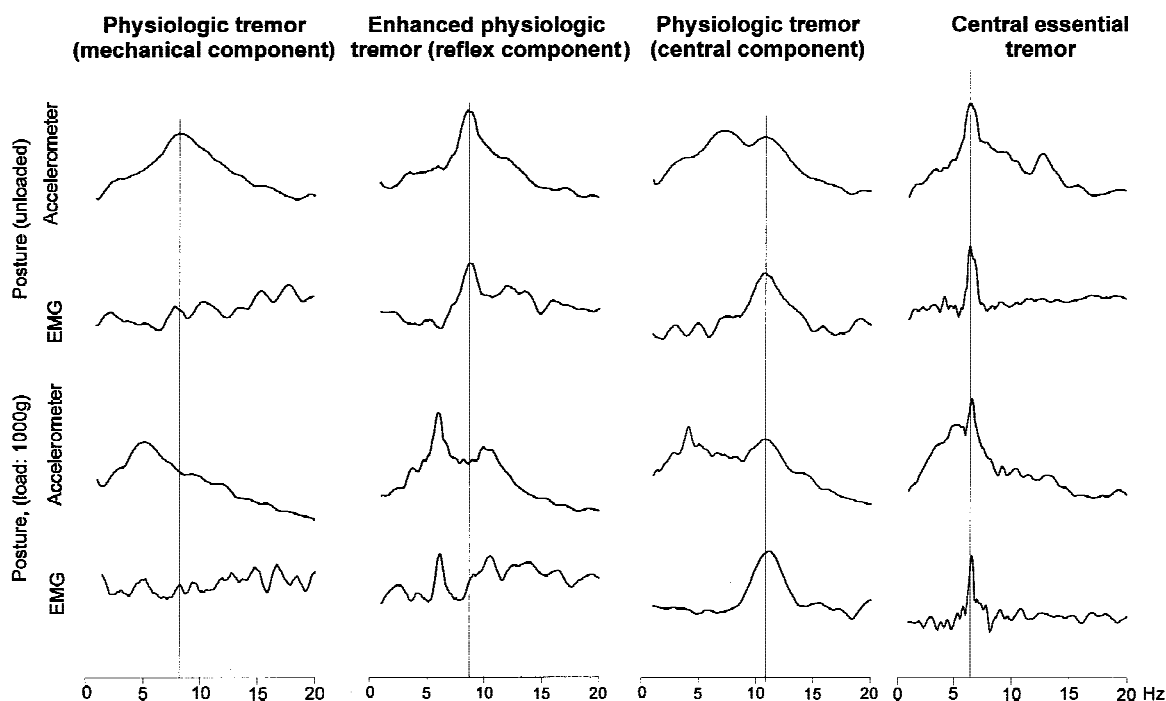


FIGURE 2. Spectral analysis of four different postural hand tremors with the accelerometer spectrum and the electromyographic spectrum of the wrist extensors (EMG) unloaded and with a load of 1000 g mounted on the back of the hand. The first example is a physiological tremor with a flat EMG spectrum and a load-dependent mechanical resonance peak. The second column is from a patient with thyrotoxic tremor who had a reflex-activated tremor because the EMG frequency peak decreased with the accelerometer peak during loading. The third example is from a normal subject having a central, frequency-invariant component in addition to the load-dependent mechanical component. The last is from a patient with a mild essential tremor displaying a frequency-invariant central component. This test can also be applied for diagnostic purposes.

the conduction distance is longer. However, mathematical calculations have shown that this could be compensated by the existence of different latencies and gains of reflexes.¹⁷⁴

Such reflex contributions can be identified in individual patients (Fig. 2). For this purpose, the oscillation of the extremity (typically the hand, for practical reasons) and the electromyogram (EMG) of the wrist flexors and extensors is recorded with the hand held in an outstretched position. The mechanical oscillations and the EMG is analyzed with spectral analysis and, for example, shows synchronized frequency peaks at the resonance frequency of the hand. When the hand is loaded with 1 kg, this mechanical frequency will drop by about 2 Hz. Whenever the EMG frequency is also decreasing, reflex loops must be mediating the decreased resonance frequency to the central nervous system (CNS) centers responsible for EMG synchronization. Other more subtle mathematical tools to detect an influence of reflexes on tremor have been described.²¹⁴

The third mechanism is *central oscillation*. Two hypotheses have been proposed about the possible principles underlying such central oscillations. The first is the rhythmic activity of a group of neurons within a nucleus. Animal experiments have shown such mechanisms for cells within the inferior olive and the thalamus.^{113,145,147,208} These neurons can adopt one of two ways of firing. The first is summation of excitatory action potentials at the membrane and firing of a regular action potential when the firing threshold is reached. The second is the so-called oscillatory mode. In this condition the firing is followed by a prolonged action potential and a subsequent prolonged hyperpolarization, which is terminated by a rebound spike leading to the next spike. The changes in ionic conductance at the membrane have been studied in detail.^{113,145} Synchronization of single oscillating cells is necessary to produce rhythmic activity strong enough to rhythmically activate spinal motor nuclei. One way to synchronize a given set of oscillating neurons is through electrotonic coupling at gap junctions. Such a mechanism has been convincingly demonstrated for cells of the inferior olive. These neurons have gap junctions,²⁰³ and electrotonic coupling of oscillatory activity has been demonstrated in the guinea-pig.^{146,203} Such mechanisms are also likely for thalamic neurons.¹¹³

A possible second mechanism is that oscillations are generated within loops consisting of neuronal populations or different nuclei and their axonal connections.⁹⁹ The conduction time and time for excit-

atory summation or inhibition in the different nuclei involved in such a loop are assumed to determine the frequency of the oscillation. Recently, physiological evidence for the existence of such a mechanism has been provided by a study demonstrating that, in cortex-striatum-subthalamic nucleus (STN)-globus pallidus externus (GPe) cultures, a synchronized bursting at 0.4–1.8 Hz develops, caused by excitatory drive from the STN and inhibitory action from the GPe.¹⁸¹ For practical purposes, such a central oscillator can be identified in patients with spectral analysis by demonstrating a load-invariant peak in the electromyogram (Fig. 2).

The fourth mechanism is *malfunction of feedforward loops* within the CNS, especially the cerebellum. The tremor type occurring in this condition is most often an intention tremor or tremor during goal-directed movements. To better understand the mechanism of these feedforward abnormalities, the pattern of activity in ballistic movements must be considered. This consists of agonist-antagonist-agonist activation⁹⁷ with the agonist initiating the movement, the antagonist breaking the movement, and the second agonist contraction performing the fine tuning of the movement. These ballistic movements are preprogrammed, but the corticospinal system alone is not sufficient to control this motor sequence. The cerebellum plays a critical role in these ballistic movements because cooling of the cerebellum in monkeys^{39,166} or lesioning of the cerebellum^{65,80,108} leads to a delay in onset of the antagonist and second agonist contractions. The delay of the antagonist leads to insufficient breaking of the ballistic movement and movement overshoot. The further delay of the second agonist contraction causes a delayed and thereby enhanced correction movement, leading to hypermetria in the other direction. By this mechanism any voluntary movement will end up as an oscillating movement, especially during goal-directed activity. There is much evidence that, in humans, very similar mechanisms are active, because in cerebellar disease the same disturbance of ballistic movements is found for the upper^{57,109} and lower¹⁵⁹ extremity.

It is assumed that the cerebellum is the critical system for tuning the strength and duration of the first agonist, and the timing and shape of antagonist activation. This cannot be a feedback mechanism between peripheral receptors and the CNS because of the conduction times involved. Therefore, it is assumed that the cerebellum is working through a feedforward control system that receives a copy of the movement signal from the cortex and adapts the specific parameters of the movement according to

the present status of the motor system. The more this feedforward control system is defective, the more the motor performance depends on feedback information from the periphery which is, however, delayed, and subsequently the aforementioned deficits of timing and shape of the voluntary muscle activations develop.

Recently, a tremor resembling that of cerebellar disease has been induced in normal subjects when the motor cortex was continuously stimulated.²¹⁷ This may reflect a disturbance of the same cerebellocortical loop, but at a cortical level.

New Developments in Tremor Research. *Animal Models of Tremor.* Animal models are of importance for uncovering the basic mechanisms of tremor (for review, see Wilms et al.²³⁴). Three different approaches have been used to produce tremor in animals: tremorogenic drugs (harmaline, MPTP); experimental CNS lesions (midbrain lesions in primates); and genetic mutants (different mouse mutants). Whereas harmaline induces a postural/kinetic tremor in animals that shares some features with human essential tremor or enhanced physiological tremor, MPTP tremor is the best model available for human rest tremor. The tremor following experimental lesions of the ventromedial tegmentum in primates closely resembles human Holmes' tremor, whereas cerebellar intention tremor is mimicked by cooling of the lateral cerebellar nuclei. The "campus syndrome" discovered in a breed of Pietrain pigs may be a useful model of human orthostatic tremor. It is clear that none of these models can replicate all of the features of the human analog. Problems encountered when comparing tremor in animals and humans include uncertainty as to whether specific transmitter abnormalities or CNS lesions in animal tremor models are characteristic of their human counterparts, and whether the clinical characteristics are actually comparable.

Positron Emission Tomography. In recent years, new insights into the physiology of tremor have been gained by using positron emission tomography (PET) with H₂¹⁵O as a marker of blood flow, ¹⁸fluoro-2-deoxyglucose (FDG) as a marker of metabolic activity, or ¹⁸F-fluorodopa (F-dopa) as a marker of density of dopaminergic terminals in the striatum.²¹

F-dopa PET imaging has demonstrated normal dopaminergic terminals in essential tremor but reduced labeling of these terminals in parkinsonian rest tremor^{12,30} and Holmes' tremor.¹⁸⁹ This is further evidence supporting the assumption that rest

tremor only occurs when the nigrostriatal projection is lesioned.

In parkinsonian tremor, the cerebellum and contralateral thalamus are abnormally activated.²¹ In Parkinson's disease (PD) patients with an implanted stimulator in the Vim nucleus of the thalamus, effective stimulation leads to suppression of this abnormal cerebellar activation.⁴³ However, it is not yet clear whether reduced cerebellar activity leads to reduction of tremor, or reduced tremor causes less cerebellar activation. All types of tremor are associated with abnormal cerebellar activation. In essential tremor, cerebellar overactivity has been found by blood-flow^{38,119} and metabolic studies.⁹⁶ The red nucleus, but not the inferior olive, is overactive.²³² In patients with essential tremor responsive to alcohol, cerebellar overactivity is decreased following alcohol ingestion.²² Writer's tremor,²³¹ orthostatic tremor,²³³ and even tremor associated with neuropathies¹⁴ all show increased cerebellar blood flow.

The most likely interpretation of these findings is that tremor of an extremity or muscle activates strong afferent signals to the cerebellum (e.g., through the spinocerebellar tracts).²⁷ One argument against this interpretation is that such hypermetabolism is also found at rest, but complete relaxation of subjects is hard to achieve. If this hypothesis is correct, a specific role of the cerebellum in the genesis of such tremors will be difficult to demonstrate by such PET studies.

Time-Series Analysis of Rhythmic Muscle and Brain Activity. Coherence analysis was not used in the analysis of the relations between rhythmic muscle and brain activity until recently. The mathematical aspects of coherence analysis have been covered elsewhere.²³⁵ In brief, coherence is a statistical measure of linear predictability between two time-series. It equals one whenever one time-series is obtained from the other by linear transformation. The estimation procedure is based on the auto- and cross-spectra. At those frequencies with significant coherence, phase spectra can be estimated, revealing more details about the nature of any interaction. Specifically the existence and an estimate of the amount of time delay between the two processes can be detected.

The method was applied first hand to better understand the concept of a central generator of tremor. Assuming one central generator, all affected muscles in different extremities would be expected to show coherent activity. Indeed, this has been demonstrated for orthostatic tremor,^{49,129} but not for physiological tremor, enhanced physiological tremor, essential tremor, or parkinsonian tremor.^{139,186}

However, the tremor in different muscles of the same extremity did show coherence.¹⁸⁶ We conclude from these observations that multiple oscillators must be responsible for the tremors investigated, except for orthostatic tremor. It is conceivable that different neuronal assemblies within the brain are responsible for pathological tremors in different extremities. However, it cannot be excluded that spinal reflex pathways play a significant role in the distribution of rhythmic activity within an extremity.

Oscillations of cortical areas have been assessed, and activity above 40 Hz has been related to specific sensory aspects. Singer and colleagues, in particular, have elaborated upon the concept of “binding” of those cortical areas working together for specific sensory tasks.^{198,199} Applications of this approach to the motor system are more limited. The first attempts in this field examined the relation between brain activity measured with electroencephalography (EEG) or magnetoencephalography (MEG) and muscle activity. Spectral peaks in the EEG were found at 15–30 Hz and at 30–50 Hz.^{9,15,16,31,32,40,72,98,122} The coherence between cortical and muscle activity has also been calculated. The 15–30 Hz coherence between activity of the first dorsal interosseous muscle and the EEG was found during holding tasks involving a constant force between thumb and index finger.¹²² Recordings in monkeys from two cortical pyramidal tract cells (PTNs) showed coherence with each other and synchrony with the 15–30 Hz cortical rhythm.¹⁵ The synchronous activation of motoneurons by these PTNs may explain the 15–30 Hz rhythm. Thus, this oscillation may reflect processes in the motor cortex. The investigators suggested that this 15–30 Hz oscillation reflects efficient simplification of the motor command,¹⁵ because a holding task needs less complex steering than a movement task, which is associated with desynchronization.

In 1907, Piper demonstrated that muscle activity synchronizes at around 40 Hz when the muscle is strongly contracted.¹⁸⁰ This has been confirmed repeatedly in various studies.¹⁶⁰ The cortical correlates for this Piper rhythm have been investigated using MEG.³² The muscle rhythm showed coherence at 35–60 Hz with an area of the motor cortex corresponding to the extremity under investigation. The phase lag between cortex and arm or leg, respectively, differed by about 15 ms, which corresponds to the time lag between corticospinal conduction between arm and leg. Thus, the investigators have suggested that the Piper rhythm originates in the motor cortex and codes the amount of force exerted in tonic and phasic contractions. For weak contractions

they found coherence at lower frequencies (20–30 Hz), similar to other groups.^{40,122}

Vallbo and colleagues showed that the EMG underlying fine manipulatory movements consists of bursts with a frequency of 8–10 Hz.^{219,228} They showed that such discontinuities are found in almost all movements and do not depend on the stretch reflex or on afferent activity.²²⁹ Thus, they speculated as to whether this is the mechanism by which the corticospinal system grades muscle force and speed.

In Parkinson's disease, the mu rhythm of the MEG is suppressed by tremor, but in one study a cortical correlate for parkinsonian tremor was not found.¹⁵¹ In contrast, Volkmann et al.²²³ found a sequence of magnetic fields in the thalamus, premotor cortex, and sensorimotor cortex that may partly reflect motor commands to the muscles and, partly, sensory feedback due to tremulous activity. These findings have been confirmed with new mathematical tools, demonstrating that muscle activity and cortical activity show a 1:2 phase relationship²¹⁰ that might be explained by the relation of reciprocal alternating activity in two antagonists, of which only one is recorded. Coherence of muscle and brain activity has also been demonstrated with EEG techniques¹⁰² for parkinsonian tremor.

At present, it is premature to draw final conclusions about the impact of these studies on the understanding of tremor. However, it is tempting to speculate that muscle and cortical oscillations in the low-frequency range (6–12 Hz) are the equivalent of physiological tremor. Pathological tremors may use similar pathways within the cortex.

PATHOPHYSIOLOGY OF DISTINCT TREMORS

Conditions with abnormal tremor, but obviously normal and intact CNS functions, include enhanced physiological and psychogenic tremor. These are considered first.

Tremors in Normal Subjects. *Physiological and Enhanced Physiological Tremor: Mechanical and Cortical Tremor.*

The distinction between physiological and enhanced physiological tremor is purely clinical and they share common mechanisms. Physiological tremor is probably the best known form of tremor. It consists of three main components. The first is the *mechanical component* of tremor, which is responsible for the main frequency component in most normal subjects.^{5,58,187} This mechanical component consists of the damped oscillation, which is driven by several factors: (1) resonance at the eigenfrequency^{213,214}; (2) cardiobalistic effects (e.g., during the systolic

phase a small impulse is given to the extremities,^{153,157,225} and this is followed by a damped oscillation); and (3) the discontinuities of innervation, which occur normally.⁸³ The resonance frequency can be identified by spectral analysis of the position or accelerometer signal from the affected extremity and the EMG from the antigravity muscle (Fig. 2). For identification of the mechanical tremor component, the extremity is loaded with a weight, and thus the resonance frequency of the extremity decreases.

Besides this component, there is, in rare cases, an *enhancement* of the mechanical component by *reflexes*. This has been studied in adrenaline-induced tremor.¹⁵⁶ Adrenaline (epinephrine) upregulates the sensitivity of the muscle spindles, and thus enhances rhythmic afferent activity leading to greater synchronization of the afferent volley and enhanced reflex activity. Such a mechanism is also influenced by thyroid hormones.^{100,107} This mechanism can also be identified by spectral analysis when the tremor is measured with and without added load. In the unloaded condition, a significant peak of the EMG will appear at the frequency of the accelerometer peak. In the loaded condition, the accelerometer peak shows a shift to a lower frequency, but the same shift will be observed in the EMG peak. This can only be achieved if the peripheral frequency is mediated to the CNS by reflexes (Fig. 2).

The final mechanism underlying physiological tremor is the so-called *8–12-Hz central component*. This can be identified with spectral analysis when a peak of the EMG remains stable but the mechanical peak shows a decreased frequency under load (Fig. 2). This component has been attributed to different mechanisms.⁶⁸ A reflex mechanism has been proposed,¹⁴⁴ but not confirmed.⁶⁷ Visual feedback does not have a significant influence.²⁰⁷ Hence, neither somatosensory nor visual feedback seems to play a significant role. It has also been proposed that this component is caused by motoneurons that are recruited at 8–12 Hz, but do not produce a fused contraction at this frequency.^{5,83} Their firing causes unfused muscle contractions that are subsequently synchronized by reflex mechanisms. However, it was later demonstrated that the single motor units fire at much higher frequencies and expose a second peak at the 8–12 Hz frequency,⁶⁹ which demonstrates that the underlying cause for the 8–12 Hz peak must be a central facilitation at this frequency. This was attributed to either Renshaw inhibition in the spinal cord or central oscillators located in the inferior olive or thalamus.⁶⁸ This view has been extended by recent reports. First, it was demonstrated that, in subjects with congenital mirror movements, the 8–12

Hz component is coherent in both arms,¹³⁰ in contrast to normal subjects.^{139,186} These subjects are known to have bilateral projections of the corticospinal tract, making it likely that this tremor component is transmitted through this tract. This implies that the oscillator is located either within or upstream to the motor cortex.

Additional information comes from recent experiments on the steering of voluntary movements. It has been demonstrated that movements of the digits and forearm are regulated through an 8–12 Hz pattern of bursts,²¹⁹ which is independent of the stretch reflex²²⁹ and that this rhythm is transmitted to both agonists and antagonists.²²⁷ This was interpreted to reflect a common central input. Combining all these data, the hypothesis might be put forward that the central component of physiological tremor is due to synchronization at the cortical level by a mechanism inherent in the organization of the motor system.

The extent to which the 8–12 Hz central component contribute to the clinical expression of physiological tremor has been estimated in one of our recent studies, and a significant contribution to tremor amplitude was found in only 30% of normal subjects.¹⁸⁷ This percentage is believed to be much higher for enhanced physiological tremor. Reflex-driven tremor was found in only 2% of normal subjects.

Psychogenic Tremor: Rhythmic Activity Mediated by a Clonus Mechanism? The pathophysiology of psychogenic tremor is still unclear. Diagnosis has been made on clinical grounds alone^{48,123,127} (Fig. 1). Psychogenic tremor may cover a wide range of frequencies (Fig. 1). Some patients simply mimic tremor indistinguishable from voluntary tremor and others present with low-frequency voluntary rhythmic body movements during stance and gait. They represent neither a clinical nor a pathophysiological problem, as they are simply performing voluntary movements. Other patients have an almost continuous tremor of one or more limbs, which can often be influenced by distracting maneuvers,¹⁶¹ but sometimes persists despite such maneuvers. We have consistently observed that these patients produce cocontraction of antagonists in the affected limb.⁴⁸ This can be assessed by testing movement at the oscillating joint with passive movements. Tremor is only present when cocontraction occurs; when the cocontraction is reduced, the tremor stops. We concluded that cocontraction is a necessary condition for this type of tremor. Cocontraction is known to be a factor facilitating clonus.²⁰⁵ We propose that psychogenic tremor is due to a clonus mechanism. Such clonus can indeed be pro-

duced by a normal subject and, once initiated by a conscious cocontraction, can persist without requiring much attention. This accords with earlier descriptions of soldiers who had epidemic psychogenic tremor during World War I. They vividly described that they simply had to initiate cocontraction and tremor developed automatically.^{7,10} During that time, neurologists interpreted the tremor as manifesting a voluntary change in reflex threshold, and thereby were close to what may be explained nowadays as clonus.^{6,134,178,224} Indirect evidence supports such a view. The amplitude of hand tremor usually decreases when the mass of the hand is increased by adding a load, whereas in patients with psychogenic tremor the amplitude often increases.⁴⁸ This may be explained by the additional cocontraction necessary to maintain the reflex activity. It is difficult to confirm this hypothesis, but studies in normal subjects have shown that such a mechanism might indeed exist. Prochazka and colleagues^{112,185} have shown that vibration or electrical stimulation of the elbow flexors or extensors at some frequencies can produce tremors in the range between 3 and 8 Hz. This phenomenon depends on cocontraction by the subjects. They argued that these mechanisms may be active in pathological tremors, but because of the preinnervation modus it seems more likely that this is the mechanism of psychogenic tremor. For clinical purposes, this cocontraction sign is a necessary finding for the diagnosis of psychogenic tremor, and in our experience (Table 1) it is the best means to confirm this diagnosis.

Pathological Tremors. Palatal Tremor: An Olivary Tremor? Palatal tremor is a rare condition, but one of its variants is especially relevant for the understanding of tremor mechanisms in general. Palatal tremor (also called palatal myoclonus, palatal nystagmus) is characterized by rhythmic movements of the soft palate and sometimes of other muscles. It is divided into symptomatic (SPT) and essential palatal tremor (EPT).^{51,54} SPT is characterized by: (1) preceding brainstem/cerebellum lesion with subsequent olivary hypertrophy (which can be demonstrated by magnetic resonance imaging); and (2) rhythmic movements of the soft palate (levator veli palatini) and often of other brainstem-innervated or extremity muscles.

EPT is characterized by: (1) absence of preceding lesion and absent olivary pseudohypertrophy; and (2) presentation with an earclick. The rhythmic movements of the soft palate involve mostly the tensor veli palatini. Extremity or eye muscles are not involved.

Table 1. Diagnostic criteria of psychogenic tremors.

1. Sudden onset of the condition and/or remissions
2. Somatization in the past history
3. Appearance of additional and unrelated neurological signs
4. Unusual clinical combinations of rest and postural/intention tremors
5. Decrease of tremor amplitude during distraction
6. Variation of tremor frequency during distraction or during voluntary movements of the contralateral hand
7. "Coactivation sign" of psychogenic tremor (see text)

Much work has been done on SPT. It has been known for many years that SPT is associated with an abnormal morphology of the inferior olive (IO),¹²⁵ which is labeled as "pseudohypertrophy" and is characterized by cells with inclusion bodies and tortuous dendrites.^{2,3,126,135-138} This condition develops secondary to a lesion within the pathways from the cerebellum through the superior peduncle and contralaterally through the brainstem to the inferior olive. The cause of rhythmic activity is probably the inherent activity of the cells within the IO. It has been proposed that the gap junctions between the IO cells mediate the synchronization of the oscillation.²⁰³ They mediate electrotonic coupling¹⁴⁶ and this electrotonic coupling is regulated through a GABAergic pathway from the deep cerebellar nuclei to the contralateral IO.²⁰² Thus, the present hypothesis for genesis of this tremor includes several steps.⁵⁴ The first is a lesion of the GABAergic pathway to the IO by an ischemic insult or other brainstem disorder. Subsequently, the gap junctions are no longer inhibited, and continuous electrotonic coupling takes place between the majority of the IO cells, leading to synchronized excitation. This is transmitted to the contralateral cerebellum, which is able to influence the motoneurons synchronously through bulbospinal pathways and can thereby cause tremor. Olivary pseudohypertrophy develops over several months^{92,93} and palatal tremor is not clinically visible before a certain level of olivary hypertrophy.²⁴¹ Many observations in patients with SPT support this view. Thus, SPT always develops contralateral to the hypertrophied inferior olive,^{36,54,240} which is compatible with the anatomical projection of the IO to the contralateral cerebellar hemisphere. Palatal tremor is associated with subclinical rhythmic activation time-locked to the tremor of all the muscles of the contralateral side,⁵⁴ indicating the strongly unilateral projection of the rhythm of the palate. This may be the reason that extremity muscles sometimes exhibit tremor at the same rate as the palatal myoclonus.^{136,194,238} Finally, patients with unilateral IO pseudohypertrophy may show contralateral clinical signs of a cerebellar

disturbance⁴⁷ and abnormal motor learning in tests requiring normal cerebellar function.^{17,53,121} Almost nothing is known about the pathophysiology of EPT.

Essential Tremor: A Possible Olivocerebellar Tremor.

Essential tremor (ET) is commonly hereditary and linkage has been found for several genes.^{73,94,104} Pathoanatomical investigations have not identified any morphological changes,¹⁸⁸ supporting the belief that ET is due mainly to a functional abnormality within the CNS. Clinically, it is a slowly progressive, monosymptomatic disorder with postural and kinetic tremor; in advanced stages, intention tremor can cause severe handicap. The diagnostic criteria are shown in Table 2. It has been suggested that ET is caused by a functional disturbance of the olivocerebellar circuit. Among the most convincing clinical evidence is the observation that ET disappears after lesions of the cerebellum,⁶³ pons,^{172,218} or thalamus,⁶² which are all part of a cerebello-cortical loop. The aforementioned PET studies have shown that there is cerebellar hyperactivity in ET, although it is not yet clear whether this is the cause or the result of ET. Harmine, a β -carboline related to harmaline, has been shown to induce tremor in normal humans, and shares some features with ET.^{142,179,234} Therefore, animal studies with the harmaline model of tremor are of specific interest with regard to the pathophysiology of ET. It has been shown for different species that cells of the inferior olive are synchronized²³⁴ and that rhythmic activity is transferred through the cerebellum and the reticulospinal projections to the motoneurons.²³⁴ The hypothesis has been put forward that ET is generated in a similar way. The study of cerebellar functions in ET has shown slight cerebellar disturbances: the triphasic pattern underlying ballistic movements shows distinct abnormalities, resembling the situation in cerebellar disease.^{18,25} The onset of antagonist activity, which normally breaks the agonist movement, and the second activity of the agonist are delayed. Voluntary movements have shown an intention tremor

in almost half of the patients with ET, which is indistinguishable from cerebellar tremor.⁵⁵ In addition, there is a slowness of voluntary movements and hypermetria, which provide clinical support for cerebellar dysfunction in ET.⁵⁵ We have interpreted these findings to reflect a progressive cerebellar disturbance in ET, depending on the severity of the condition. If intention tremor develops in the setting of ET, we assume a disturbance of cerebellar feed-forward control (discussed earlier).

It is generally accepted that ET is a central tremor. For individual patients this can be demonstrated by spectral analysis of the accelerometer and EMG. As in all central tremors, the peak frequency of the EMG does not shift when the extremity is loaded (Fig. 2). Unfortunately, this cannot always be demonstrated in early ET,⁶⁶ and the distinction between ET and enhanced physiological tremor may then be difficult.

Orthostatic Tremor: A Brainstem Tremor. Orthostatic tremor is a unique tremor syndrome^{26,49,87,88,101,129,143,152,163,175,182,183,193,226,230} characterized by: (1) a subjective feeling of unsteadiness during stance but only in severe cases during gait, without any disturbance during sitting or lying; (2) sparse clinical findings that are mostly limited to a visible and sometimes only palpable fine-amplitude rippling of the leg (quadriceps or gastrocnemius) muscles when standing; and (3) electromyographic recordings (e.g., from the quadriceps muscle) that show a typical 13–18 Hz pattern.⁴⁴ This unique, high-frequency pattern of EMG activity has certain features of pathophysiological interest. The pattern occurs in all the patients during standing or during weight-bearing in an erect position.^{24,26,50,193} Some also experience this condition during physical activity in a sitting position or when lying and performing active tonic contraction of the legs.^{23,24} If the body weight is reduced by unloading through a parachute belt in a standing position, the high-frequency pattern usually remains stable. The most surprising observation is, however, that many patients have a completely normal interference pattern in a lying position. Thus, the condition under which this tremor occurs in all patients is the standing position. A hitherto unknown descending system related to postural and sometimes also to nonpostural tasks seems to malfunction.

The 16-Hz tremor occurs not only in the anti-gravity muscles but also in the flexor muscles of the leg, the trunk, and arm muscles.^{23,24,26,49,50,212} In addition to the muscles innervated by the spinal cord, the cranial nerve muscles are also involved,¹²⁹ indicating that all motor nuclei have this unique pattern

Table 2. The core and secondary criteria for the diagnosis of classic essential tremor.¹³

Core criteria

1. Bilateral action tremor of the hands and forearms (but not rest tremor)
2. Absence of other neurological signs with the exception of the cogwheel phenomenon
3. May have isolated head tremor with no signs of dystonia

Secondary criteria

1. Long duration (>3 years)
2. Positive family history
3. Beneficial response to propranolol

with the possible exception of the extraocular muscles, which have not yet been tested. The activity of the muscles in orthostatic tremor is highly coherent in all muscles tested.^{23,24,49,50,212} Muscles from both sides of the body and from the upper and lower legs or cranial nerve muscles are all coherent (Fig. 3). This is a unique finding among all the tremors that have been assessed with coherence analysis¹³⁹ and it confirms a unique oscillator underlying this tremor.

This oscillator must be strong enough to dominate normal corticospinal and bulbospinal activity, because single-unit recordings have shown (Fig. 4) that individual units are activated only at 16 Hz or at lower harmonics (e.g., 8 Hz, 4 Hz, 2 Hz, etc.) of the 16-Hz pattern.⁵⁰ Thus, the motoneurons receive such a strong excitatory potential at the time of each tremor burst that additional excitatory potentials in the pauses between the tremor bursts are not able to increase the membrane potential to firing threshold. This firing pattern excludes a purely spinal mechanism of orthostatic tremor.

A recent PET study has demonstrated increased bilateral cerebellar and contralateral lentiform and thalamic blood flow during activity, and increased cerebellar blood flow at rest.²³³ Further information

may come from a porcine animal model. Similar to the human condition, these pigs show a coarse tremor while standing and walking and they show an EMG pattern of 14–15 Hz during walking and standing.^{190,236}

The location of the oscillator in orthostatic tremor remains unknown. However, as bilateral brainstem and spinal motor nuclei are involved and the tremor activity is coherent in different muscles, it is not possible that one of the lateralized motor systems of the brain or spinal cord is responsible for these oscillations. A reasonable location for an oscillating system is the bilaterally projecting brainstem centers regulating stance or tone. Thus, we hypothesize that orthostatic tremor is an example of a brainstem tremor.

Parkinsonian Tremor: Classic Basal Ganglionic Tremor. In PD, several different forms of tremor occur.⁴⁴ Most typical is the rest tremor, which only occurs in PD and Holmes' tremor if rigid criteria for the definition of rest tremor are applied. We consider here only so-called classic parkinsonian tremor characterized by tremor at rest, which is activated by mental stress and is at least temporarily suppressed when the extremity is voluntarily activated. The usual frequency is 4–6 Hz, but higher frequencies

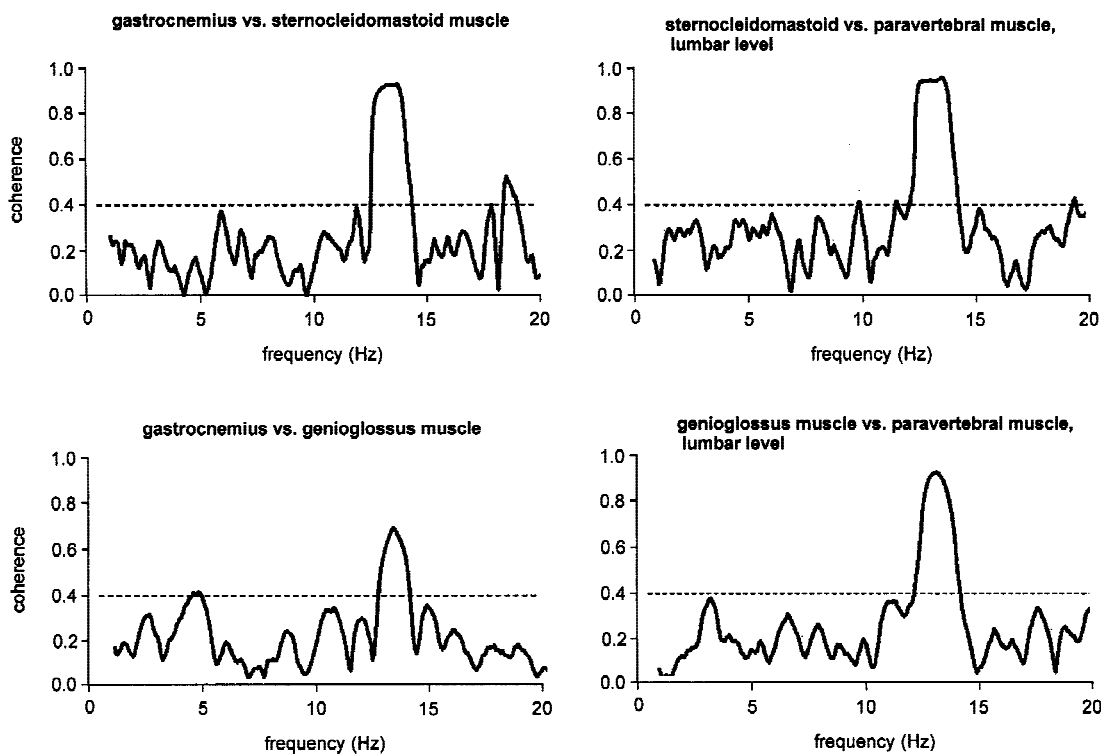


FIGURE 3. Coherence spectra between different brainstem-innervated and leg or paravertebral muscles demonstrating highly significant coherence even in muscles located far apart. This is a unique finding in orthostatic tremor and is not found in any other organic tremor. Significant coherence can be assumed when a coherence value of 0.4 Hz is exceeded (from Koster et al.¹²⁹).

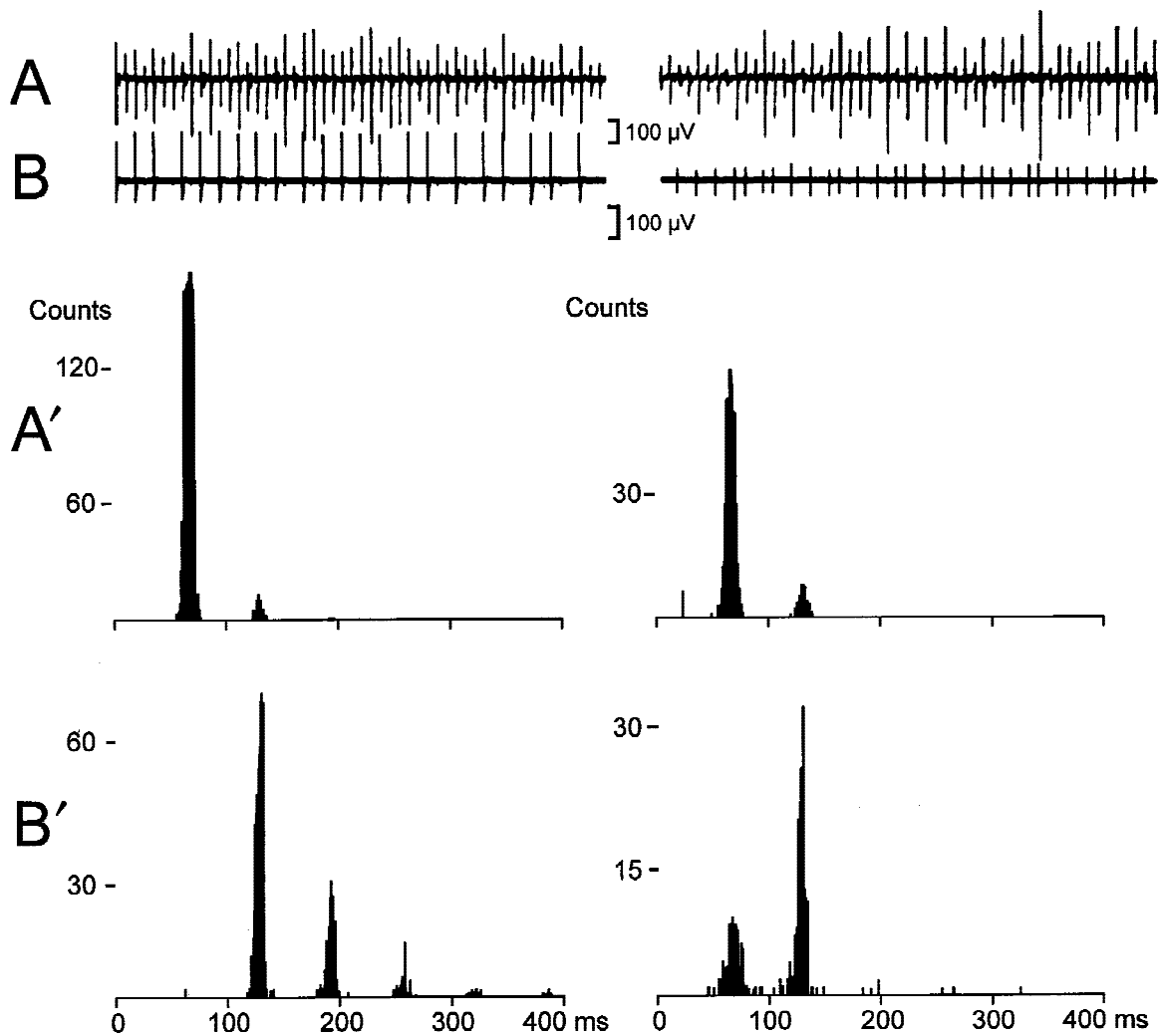


FIGURE 4. Single-unit firing intervals in a patient with orthostatic tremor. **(A)** A recording of the 16-Hz pattern with a surface electrode overlying the quadriceps muscle. **(B)** Single motor units recorded with a needle electrode. **(A')** Interspike intervals of the surface potential and **(B')** the interspike intervals of the single units. The units are firing at discrete intervals only at multiples of the interspike interval given by the 16-Hz pattern. The smaller unit on the right side is recruited only at 16 and 8 Hz (corresponding to 62-ms or 124-ms interspike intervals), whereas the larger unit on the left side is recruited at two, three, four, five, or even six times the 62-ms interspike interval. This indicates strong synchronization by the oscillator for the orthostatic tremor, which leaves no possibility for the single motor units to fire outside the 16-Hz pattern (modified from Deuschl et al.⁵⁰).

rarely occur. Numerous studies have investigated the physiological and anatomical aspects of this common type of tremor (reviewed elsewhere⁵²).

The pathological hallmark of PD is degeneration of dopaminergic cells within the substantia nigra and subsequent dopamine depletion of the striatum. Tremor-dominant patients have predominant degeneration of the medial substantia nigra, the retro-rubral A 8-field, whereas the akinetic-rigid variant shows more severe damage of the lateral substantia nigra (A 9),^{105,118,177} indicating that the tremor may have a specific pathology. PET studies have shown that patients with rest tremor have a dopaminergic deficit even when other signs of PD are absent.^{30,189}

However, the severity of tremor does not correlate with the loss of dopamine within the striatum or with severity of the disease in general. In contrast, severity of akinesia and rigidity correlate excellently with overall disease progression^{115,149,173} and with loss of putaminal dopamine measured with F-dopa PET.^{12,28,29,64,216} This robust finding remains unexplained.

Reflexes play only a minor role in the generation and maintenance of parkinsonian tremor. Afferent denervation does not stop the tremor, although its frequency and amplitude may be affected.¹⁸⁴ If the rhythm of a tremor can be reset, it was assumed that this indicates a dominant role for reflex factors.

However, studies with various stimuli have not shown a dominant role for reflexes.⁶⁸

It is generally agreed that rest tremor is a central tremor, but the location and physiology of the related central oscillators are still a matter of debate. The most common belief is that parkinsonian tremor is generated within the basal ganglia loop. However, it has recently been proposed^{150,204} that it is produced in the cerebellothalamic loop, because the cerebellum shows prominent hyperactivity in tremor,⁴³ and parkinsonian tremor can be successfully treated by placement of a lesion in the nucleus ventralis intermedius of the thalamus, which is the target of cerebellothalamic fibers.¹³² However, this hypothesis implies that rest tremor should cease when the cerebellum is removed in a patient with parkinsonian tremor. Such a patient has recently been described and continuous rest tremor was found,⁵⁶ conflicting with the cerebellar hypothesis for such tremor.

A new hypothesis is that several oscillators account for parkinsonian tremor. This hypothesis is based on coherence analyses in patients with PD and in the MPTP monkey model of PD. It has been found that the tremor within one extremity is highly correlated, but not that between different extremities,^{111,139,186} even when the tremor frequencies are identical in different extremities.¹⁸⁶ Nonlinear relations between a single central oscillator within the brain and multiple spinal networks could account for this finding,¹²⁰ but it is more likely that specific features within the basal ganglia loop are responsible for such a topography of oscillators. It has been shown both anatomically^{4,176} and with single-unit recordings^{19,20,74} that information within the pathways from the striatum to the internal pallidum and the thalamus along the indirect pathway through the basal ganglia⁴ is focused on fewer cells from one nucleus to the next, but the firing patterns of different neurons are not correlated along the whole pathway.¹⁹ In monkeys with MPTP-induced parkinsonism these cells show a strong coherence. Based on this finding, Bergman et al.¹⁹ developed their hypothesis that PD tremor is produced by the loss of segregation within these information channels and subsequent synchronization of neighboring single cells. The segregation of information is believed to be stronger for different extremities and may even be preserved in severe tremors. This could at least explain why different extremities exhibit the same frequency of tremor, but the tremor activity remains uncorrelated.

Single-unit recordings in patients during stereotactic surgery⁵² have revealed that the number of

cells having a clear relation to the peripheral tremor varies in the different nuclei, with the majority being found in the thalamus, followed by the globus pallidus internus (GPi) and the subthalamic nucleus (STN), whereas tremor-related cells are only rarely recorded in the external pallidum (GPe) and putamen (Put). This suggests that the STN is an important neuronal group for the generation of tremor. Recently, an animal model of a pacemaker formed by the STN and the GPe has been described¹⁸¹ but other possibilities, such as a corticosubthalamic–internal pallidum–thalamocortical loop, may be equally likely to form such an oscillating loop. Another hypothesis, that the thalamus is the pacemaker due to specific membrane properties,^{33,113,145} is less likely, according to recent single-unit recordings in thalamic cells of parkinsonian patients.²⁴²

The oscillating activity is reflected in the cortex as MEG^{210,223} and EEG studies¹⁰² have shown cortical coherence with the peripheral EMG. However, it is not yet clear whether this cortical activity leads or lags behind muscle activity, and further studies are necessary.

In summary, parkinsonian tremor is most likely generated within the basal ganglia. The oscillators are topographically organized and different hypotheses exist on the detailed mechanisms producing this rhythmicity within the basal ganglia. Studies on the cortical activity related to this tremor will further define the pathways of tremor-related brain activity.

Dystonic Tremor: Another Type of Basal Ganglia Tremor? Despite many studies on dystonic tremor,^{8,11,41,45,59,60,90,110,114,116,117,148,154,162,167,191,192,195,197,201}

it still remains a poorly classified entity. It has recently been defined clinically⁴⁴ as mainly a postural/kinetic tremor in an extremity or body part that is affected by dystonia and which is usually not seen during complete rest. These are mostly focal tremors with irregular amplitudes and variable frequency (usually below 7 Hz).

A typical example of dystonic tremor is tremulous spasmodic torticollis (or dystonic head tremor). In many patients with dystonic tremor, “trick maneuvers” have been shown to lead to a reduction of tremor amplitude. This can be used to separate dystonic head tremor⁴⁶ from essential head tremor. Such tricks are less common in dystonic tremors of the extremities, and it is not clear whether they are related to the tremor or the dystonia. Hallett has proposed that these tricks relate to the basic mechanisms underlying dystonia⁹⁵ rather than being a specific feature of dystonic tremor. It is not clear how this tremor is generated, but it may be related to the mechanism of dystonia. There is ample evidence

that dystonia is a disorder of the basal ganglia, and dystonic tremor may therefore be another form of basal ganglia tremor.

Cerebellar Tremor: A Defect of Feedforward Control? Cerebellar (intention) tremor is diagnosed according to the following clinical signs: (1) pure or dominant intention tremor, uni- or bilateral; (2) tremor frequency generally below 5 Hz; and (3) postural tremor, but not rest tremor, may be present.

Cerebellar tremor is often used synonymously with intention tremor, although various clinical expressions of tremor have been described in cerebellar disorders.⁷¹ The mechanisms underlying cerebellar tremors have been studied extensively in animals. The cerebellum has either been removed or its function temporarily blocked by cooling or chemical agents.^{39,70,79–81,108,166,222} Selective muscimol injections into deep cerebellar nuclei have revealed that the critical structure seems to be the globose-emboliform nucleus.²¹¹ Tremor-related activity in monkeys was found in the motor and somatosensory cortex and the globose-emboliform nucleus, but not the dentate nucleus.⁷⁰ Therefore, transcerebellar and transcortical loops seem to be involved. As intention tremor persists following deafferentation in monkeys,⁹¹ somatosensory loops cannot be the only source of intention tremor and it is likely that a transcerebellar loop is involved. Analysis of voluntary movements in animal experiments and patients with cerebellar lesions suggests that the major cause is disturbed timing and grading of the activity of antagonistic muscles. Indeed, several studies have suggested that long-latency reflexes are enhanced in cerebellar disease.^{37,84,159} Although this mechanism is very likely to underlie cerebellar tremor, an additional tremor-generating mechanism is also possible.

Holmes' Tremor: Combination of Basal Ganglia and Cerebellar Tremor. The name of this tremor syndrome has long been controversial. The traditional terms "rubral tremor" and "midbrain tremor" are misleading, because cases with lesions outside these locations have been described.^{75,86,90,133,140,169,171} Holmes' description¹⁰⁶ was among the first, and hence this designation was proposed recently by a committee of the Movement Disorder Society.⁴⁴ The following criteria apply to this tremor: (1) rest and intention tremor and sometimes also a postural tremor (the tremor is often not as rhythmic as other tremors); (2) low frequency, mostly below 4.5 Hz; and (3) a variable delay (usually 4 weeks to 2 years) between lesion onset and first occurrence of the tremor is typical.

It is unclear whether thalamic tremor^{169,221} is a separate entity or only a variant location of the un-

derlying pathology. Most patients with so-called "thalamic tremors" have additional dystonia and classic signs of a thalamic lesion.

It is generally accepted that Holmes' tremor is a symptomatic tremor that follows different lesions of the brainstem/cerebellum and thalamus. Two systems, the dopaminergic nigrostriatal system and the cerebellothalamic system, must be lesioned according to pathoanatomical¹⁵⁸ and PET data.¹⁸⁹ As these systems can also be lesioned along their fiber tracts, this tremor may also follow lesions in other locations (and even at multiple cortical sites). A few patients have had preexisting cerebellar lesions and a stable cerebellar deficit but subsequently developed a nigrostriatal deficit^{76,85,131} and presented later with a Holmes' tremor. This finding provides strong clinical evidence that both cerebellar and nigrostriatal deficits are required to produce this form of tremor.

The functional deficits of these two systems are thus reflected by the clinical symptoms, and some insights into the interplay of the cerebellum and the basal ganglia are provided by this form of tremor. Rest tremor is known to cease when voluntary movements are performed, but this is no longer true when the ipsilateral cerebellum is affected; rest tremor then seems to spill into voluntary movements, giving rise to an intention tremor of the same frequency. Thus, the cerebellar influence on motor performance may partially compensate for the deficits induced by basal ganglia pathology, at least during voluntary activity. Moreover, the rest tremor frequency seems to be influenced by the cerebellum as it is usually below 4 Hz in Holmes' tremor but between 4 and 6 Hz in parkinsonian rest tremor. It may be hypothesized that the cerebellar system can compensate the basal ganglia circuits during voluntary movements as far as tremor production is concerned.

Neuropathic Tremor: A Peripheral Tremor? A peripheral basis is assumed if a patient develops tremor in association with a peripheral neuropathy and no other neurological diseases associated with tremor. Some forms of peripheral neuropathies tend to cause tremors more often than others. Demyelinating neuropathies in particular are frequent causes of such tremors.^{42,196,200,209,239} The tremors are mostly postural and kinetic tremors with a frequency between 3 and 6 Hz in arm and hand muscles. The frequency in hand muscles can be lower than in proximal arm muscles in patients with gammopathies,¹⁴ and can be used as an electrophysiological tool for diagnosis of the condition. This can also be taken as an argument that tremor frequency depends on the length of the reflex pathway and,

therefore, suggests that the tremor relates to an abnormal reflex mechanism.

Some animal models present with the combination of tremor and peripheral neuropathy, but often with an additional pathology of the central nervous system such as with the “gracile axonal dystrophy” mouse mutant,²³⁷ the “gray tremor mutant mouse,”^{103,124} or the “twitcher” mouse.⁶¹ Because the pathology is then not limited to the peripheral nervous system, the role that the neuropathy plays in development of these conditions is unknown. Physiological analysis of these animal tremors is completely lacking.

In patients with dysgammaglobulinemic neuropathy, wrist tremor can be modulated by mechanical perturbations or median-nerve electrical shocks. A peripheral contribution by reflexes thus seems to be present.¹⁴ Finally, the cerebellum shows abnormal activation in this condition.¹⁴ It seems likely that distorted and mistimed peripheral inputs are among the important reasons for this tremor. The finding of abnormal cerebellar activation may indicate that the central processing of the afferent information is defective or may suggest peripheral tremor. However, as only a minority of patients with severe peripheral neuropathies develop tremors a further—but unrecognized—factor must presumably be present to produce this tremor.

Drug-Induced and Toxic Tremors: Different Causes for Different Entities. A tremor is considered to be *drug-induced* if it occurs in a reasonable timeframe following drug intake. *Toxic tremors* occur following intoxications.

Drug-induced tremors differ in their clinical presentation and cover the whole range of clinical symptoms seen in the other tremors mentioned earlier. Toxic tremors are generally accompanied by additional clinical signs of CNS intoxication.

The most common form is an enhanced physiological tremor syndrome following sympathomimetics or antidepressants. The mechanism underlying tremor from sympathomimetics is most likely the sensitization of muscle spindles and γ -fibers^{82,155,156} and subsequent synchronization of the afferent volley. Another frequent form is rest tremor following dopamine receptor blocking drugs, usually mimicking classic parkinsonian tremor.^{34,170,215} The blockade of striatal dopamine receptors is the most likely cause. Cerebellar tremor syndromes may occur following intoxication with lithium and certain other substances. As these tremors show only minor improvement even when the intoxication is corrected, a definite toxic effect on cerebellar structures may be responsible.^{35,89,220}

The tremor caused by withdrawal from alcohol or other drugs has been characterized as enhanced physiological tremor, with tremor frequencies generally above 6 Hz.^{1,164,165,168} As the tremor frequency is higher than in ET, it has been concluded that the underlying mechanisms are different.¹²⁸ Neurophysiological tests have shown that the frequency is mostly between 8 and 12 Hz,¹⁶⁸ but others have also found a low-frequency component¹ of between 4 and 7 Hz. The low-frequency but not the high-frequency component decreased following loading, and thus the investigators concluded that alcohol-withdrawal tremor might be a form of enhanced physiological tremor. However, withdrawal tremor has to be separated from the intention tremor of chronic alcoholism, which is likely to be related to cerebellar damage following alcohol ingestion.¹⁴¹ This is often associated with a 3-Hz stance tremor, which has been ascribed to anterior lobe damage caused by chronic alcoholism.^{57,159}

CONCLUSIONS

The study of tremor is one of the rapidly growing research fields of neurology, and new neurophysiological techniques and methods promise further insights into its mechanisms. Presently, hypotheses exist for almost every tremor encountered clinically and they need to be further substantiated by animal models. This is a necessary condition for the promotion of rational treatment for each tremor type. At present, almost all antitremor medications and surgical procedures for tremor have been recognized by chance. Not only molecular but also integrative, system-oriented basic and clinical research will be required.

This work was supported by the Deutsche Forschungsgemeinschaft (DFG, De-438/4-1) and the German Bundesministerium für Bildung und Forschung (Medizinisches Kompetenznetzwerk Parkinson).

REFERENCES

1. Aisen ML, Adelstein BD, Romero J, Morris A, Rosen M. Peripheral mechanical loading and the mechanism of the tremor of chronic alcoholism. *Arch Neurol* 1992;49:740–742.
2. Alajouanine T, Thurel R, Hornet T. Un cas de myoclonies vélo-pharyngées et oculaires: hypertrophie de l'olive bulbair avec état fenêtré. *Rev Neurol* 1935;64:853–872.
3. Alajouanine T, Thurel R, Ullmann M. Un cas de myoclonie-épilepsie: association d'épilepsie généralisée et d'un syndrome myoclonique facio-linguo-vélo-palatin. *Rev Neurol* 1938;69:59–61.
4. Alexander GE, Crutcher MD, DeLong MR. Basal ganglia-thalamocortical circuits: parallel substrates for motor, oculomotor, “prefrontal” and “limbic” functions. *Prog Brain Res* 1990;85:119–146.
5. Allum JH, Dietz V, Freund HJ. Neuronal mechanisms un-

- derlying physiological tremor. *J Neurophysiol* 1978;41:557-571.
6. Altenburger H. Zur Pathophysiologie psychogener Bewegungsstörungen. *Zsch Neurol Psychiatry* 1937;158:133-135.
 7. Ambold A. Eine Kriegsneurose in ärztlicher Selbstbeobachtung. *Münch Med Wochenschr* 1922;9:311.
 8. Aminoff MJ, Dedo HH, Izdebski K. Clinical aspects of spasmodic dysphonia. *J Neurol Neurosurg Psychiatry* 1978;41:361-365.
 9. Amjad AM, Halliday DM, Rosenberg JR, Conway BA. An extended difference of coherence test for comparing and combining several independent coherence estimates: theory and application to the study of motor units and physiological tremor. *J Neurosci Methods* 1997;73:69-79.
 10. Anonymous. Bekenntnisse eines Zitterkünstlers. *Hannoverscher Anzeiger* 1920;24 August:12.
 11. Anonymous. Writing tremor and writing dystonia. *Mov Disord* 1990;5:354-355.
 12. Antonini A, Moeller JR, Nakamura T, Spetsieris P, Dhawan V, Eidelberg D. The metabolic anatomy of tremor in Parkinson's disease. *Neurology* 1998;51:803-810.
 13. Bain P, Brin M, Deuschl G, Elble R, Jankovic J, Findley L, Koller B, Pahwa R. Criteria for the diagnosis of essential tremor. *Neurology* 2000;54(Suppl. 4):57.
 14. Bain PG, Britton TC, Jenkins IH, Thompson PD, Rothwell JC, Thomas PK, Brooks DJ, Marsden CD. Tremor associated with benign IgM paraproteinaemic neuropathy. *Brain* 1996;119:789-799.
 15. Baker SN, Kilner JM, Pinches EM, Lemon RN. The role of synchrony and oscillations in the motor output. *Exp Brain Res* 1999;128:109-117.
 16. Baker SN, Olivier E, Lemon RN. Coherent oscillations in monkey motor cortex and hand muscle EMG show task-dependent modulation. *J Physiol (Lond)* 1997;501:225-241.
 17. Bastian AJ, Thach WT. Cerebellar outflow lesions: a comparison of movement deficits resulting from lesions at the levels of the cerebellum and thalamus. *Ann Neurol* 1995;38:881-892.
 18. Berardelli A, Hallett M, Rothwell JC, Agostino R, Manfredi M, Thompson PD, Marsden CD. Single-joint rapid arm movements in normal subjects and in patients with motor disorders. *Brain* 1996;119:661-674.
 19. Bergman H, Feingold A, Nini A, Raz A, Slovlin H, Abeles M, Vaadia E. Physiological aspects of information processing in the basal ganglia of normal and parkinsonian primates. *Trends Neurosci* 1998;21:32-38.
 20. Bergman H, Raz A, Feingold A, Nini A, Nelken I, Hansel D, Ben-Pazi H, Reches A. Physiology of MPTP tremor. *Mov Disord* 1998;13:29-34.
 21. Boecker H, Brooks DJ. Functional imaging of tremor. *Mov Disord* 1998;13:64-72.
 22. Boecker H, Wills AJ, Ceballos BA, Samuel M, Thompson PD, Findley LJ, Brooks DJ. The effect of ethanol on alcohol-responsive essential tremor: a positron emission tomography study. *Ann Neurol* 1996;39:650-658.
 23. Borojerdi B, Ferbert A, Foltys H, Kosinski CM, Noth J, Schwarz M. Evidence for a non-orthostatic origin of orthostatic tremor. *J Neurol Neurosurg Psychiatry* 1999;66:284-288.
 24. Britton TC, Thompson PD. Primary orthostatic tremor. *BMJ* 1995;310:143-144.
 25. Britton TC, Thompson PD, Day BL, Rothwell JC, Findley LJ, Marsden CD. Rapid wrist movements in patients with essential tremor. The critical role of the second agonist burst. *Brain* 1994;117:39-47.
 26. Britton TC, Thompson PD, van der Kamp W, Rothwell JC, Day BL, Findley LJ, Marsden CD. Primary orthostatic tremor: further observations in six cases. *J Neurol* 1992;239:209-217.
 27. Brodal A. Neurological anatomy in relation to clinical medicine. New York: Oxford University Press; 1981.
 28. Brooks DJ. PET and SPECT studies in Parkinson's disease. *Baillieres Clin Neurol* 1997;6:69-87.
 29. Brooks DJ. PET studies on the early and differential diagnosis of Parkinson's disease. *Neurology* 1993;43(suppl):S6-S16.
 30. Brooks DJ, Playford ED, Ibanez V, Sawle GV, Thompson PD, Findley LJ, Marsden CD. Isolated tremor and disruption of the nigrostriatal dopaminergic system: an 18F-dopa PET study. *Neurology* 1992;42:1554-1560.
 31. Brown P, Farmer SF, Halliday DM, Marsden J, Rosenberg JR. Coherent cortical and muscle discharge in cortical myoclonus. *Brain* 1999;122:461-472.
 32. Brown P, Salenius S, Rothwell JC, Hari R. Cortical correlate of the Piper rhythm in humans. *J Neurophysiol* 1998;80:2911-2917.
 33. Buzsaki G, Smith A, Berger S, Fisher LJ, Gage FH. Petit mal epilepsy and parkinsonian tremor: hypothesis of a common pacemaker. *Neuroscience* 1990;36:1-14.
 34. Caligiuri MP, Lacro JP, Jeste DV. Incidence and predictors of drug-induced parkinsonism in older psychiatric patients treated with very low doses of neuroleptics. *J Clin Psychopharmacol* 1999;19:322-328.
 35. Chacko RC, Marsh BJ, Marmion J, Dworkin RJ, Telschow R. Lithium side effects in elderly bipolar outpatients. *Hillside J Clin Psychiatry* 1987;9:79-88.
 36. Chang YY, Tsai TC, Shih PY, Liu JS. Unilateral symptomatic palatal myoclonus: MRI evidence of contralateral inferior olivary lesion. *Kao Hsiung I Hsueh Ko Hsueh Tsa Chih* 1993;9:371-376.
 37. Claus D, Schocklmann HO, Dietrich HJ. Long latency muscle responses in cerebellar diseases. *Eur Arch Psychiatry Neurol Sci* 1986;235:355-360.
 38. Colebatch JG, Findley LJ, Frackowiak RS, Marsden CD, Brooks DJ. Preliminary report: activation of the cerebellum in essential tremor. *Lancet* 1990;336:1028-1030.
 39. Conrad B, Brooks VB. Cerebellare Bewegungsstörung im Tierversuch. *J Neurol* 1975;209:165-179.
 40. Conway BA, Halliday DM, Farmer SF, Shahani U, Maas P, Weir AI, Rosenberg JR. Synchronization between motor cortex and spinal motoneuronal pool during the performance of a maintained motor task in man. *J Physiol (Lond)* 1995;489:917-924.
 41. Couch JR. Dystonia and tremor in spasmodic torticollis. *Adv Neurol* 1976;14:245-258.
 42. Dalakas MC, Teravainen H, Engel WK. Tremor as a feature of chronic relapsing and dysgammaglobulinemic polyneuropathies. Incidence and management. *Arch Neurol* 1984;41:711-714.
 43. Deiber MP, Pollak P, Passingham R, Landais P, Gervason C, Cinotti L, Friston K, Frackowiak R, Mauguiere F, Benabid AL. Thalamic stimulation and suppression of parkinsonian tremor. Evidence of a cerebellar deactivation using positron emission tomography. *Brain* 1993;116:267-279.
 44. Deuschl G, Bain P, Brin M. Scientific committee. Consensus statement of the Movement Disorder Society on Tremor. *Mov Disord* 1998;13:2-23.
 45. Deuschl G, Heinen F, Guschlbauer B, Schneider S, Glocker FX, Lücking CH. Hand tremor in patients with spasmodic torticollis. *Mov Disord* 1997;12:547-552.
 46. Deuschl G, Heinen F, Kleedorfer B, Wagner M, Lücking CH, Poewe W. Clinical and polymyographic investigation of spasmodic torticollis. *J Neurol* 1992;239:9-15.
 47. Deuschl G, Jost S, Schumacher M. Symptomatic palatal tremor is associated with signs of cerebellar dysfunction. *J Neurol* 1996;243:553-556.
 48. Deuschl G, Koster B, Lücking CH, Scheidt C. Diagnostic and pathophysiological aspects of psychogenic tremors. *Mov Disord* 1998;13:294-302.
 49. Deuschl G, Krack P, Lauk M, Timmer J. Clinical neurophysiology of tremor. *J Clin Neurophysiol* 1996;13:110-121.
 50. Deuschl G, Lücking CH, Quintern J. Orthostatischer Tremor:

- Klinik, Pathophysiologie und Therapie. *Z EEG-EMG* 1987; 18:13–19.
51. Deuschl G, Mischke G, Schenck E, Schulte-Mönting J, Lücking CH. Symptomatic and essential rhythmic palatal myoclonus. *Brain* 1990;113:1645–1672.
 52. Deuschl G, Raethjen J, Baron R, Lindemann M, Wilms H, Krack P. The pathophysiology of Parkinsonian tremor: a review. *J Neurol* 2000;247(Suppl. 5):V33–V48.
 53. Deuschl G, Toro C, Valls SJ, Hallett M. Symptomatic and essential palatal tremor. 3. Abnormal motor learning. *J Neurol Neurosurg Psychiatry* 1996;60:520–525.
 54. Deuschl G, Toro C, Valls-Sole J, Zeffiro T, Zee DS, Hallett M. Symptomatic and essential palatal tremor. 1. Clinical, physiological and MRI analysis. *Brain* 1994;117:775–788.
 55. Deuschl G, Wenzelburger R, Löffler K, Raethjen J, Stolze H. Essential tremor and cerebellar dysfunction: clinical and kinematic analysis of intention tremor. *Brain* 2000;123:1568–1580.
 56. Deuschl G, Wilms H, Krack P, Wurker M, Heiss WD. Function of the cerebellum in Parkinsonian rest tremor and Holmes' tremor. *Ann Neurol* 1999;46:126–128.
 57. Diener HC, Dichgans J. Pathophysiology of cerebellar ataxia. *Mov Disord* 1992;7:95–109.
 58. Dietz V. Tremor. Mechanical effect of the discharge behavior of motor neurons. *Fortschr Med* 1978;96:215–219.
 59. Duane DD. Familial cervical dystonia, head tremor, and scoliosis: a case report. *Adv Neurol* 1998;78:117–120.
 60. Dubinsky RM, Gray CS, Koller WC. Essential tremor and dystonia. *Neurology* 1993;43:2382–2384.
 61. Duchen LW, Eicher EM, Jacobs JM, Scaravilli F, Teixeira F. Hereditary leucodystrophy in the mouse: the new mutant twitcher. *Brain* 1980;103:695–710.
 62. Duncan R, Bone I, Melville ID. Essential tremor cured by infarction adjacent to the thalamus. *J Neurol Neurosurg Psychiatry* 1988;51:591–592.
 63. Dupuis MJ, Delwaide PJ, Boucquoy D, Gonsette RE. Homolateral disappearance of essential tremor after cerebellar stroke. *Mov Disord* 1989;4:183–187.
 64. Eidelberg D, Moeller JR, Ishikawa T, Dhawan V, Spetsieris P, Chaly T, Robeson W, Dahl JR, Margouff D. Assessment of disease severity in parkinsonism with fluorine-18-fluorodeoxyglucose and PET. *J Nucl Med* 1995;36:378–383.
 65. Elble RJ. Animal models of action tremor. *Mov Disord* 1998; 13:35–39.
 66. Elble RJ. Tremor in ostensibly normal elderly people. *Mov Disord* 1998;13:457–464.
 67. Elble RJ, Higgins C, Moody CJ. Stretch reflex oscillations and essential tremor. *J Neurol Neurosurg Psychiatry* 1987; 50:691–698.
 68. Elble RJ, Koller WC. Tremor. Baltimore: Johns Hopkins University Press; 1990.
 69. Elble RJ, Randall JE. Motor-unit activity responsible for 8- to 12-Hz component of human physiological finger tremor. *J Neurophysiol* 1976;39:370–383.
 70. Elble RJ, Schieber MH, Thach WT Jr. Activity of muscle spindles, motor cortex and cerebellar nuclei during action tremor. *Brain Res* 1984;323:330–334.
 71. Fahn S. Cerebellar tremor: clinical aspects. In: Findley LJ, Capildeo R, editors. *Movement disorders: tremor*. London: Macmillan; 1984.
 72. Farmer SF, Sheean GL, Mayston MJ, Rothwell JC, Marsden CD, Conway BA, Halliday DM, Rosenberg JR, Stephens JA. Abnormal motor unit synchronization of antagonist muscles underlies pathological co-contraction in upper limb dystonia. *Brain* 1998;121:801–814.
 73. Farrer M, Gwinn-Hardy K, Muenter M, DeVrieze FW, Crook R, Perez-Tur J, Lincoln S, Maraganore D, Adler C, Newman S, MacElwee K, McCarthy P, Miller C, Waters C, Hardy J. A chromosome 4p haplotype segregating with Parkinson's disease and postural tremor. *Hum Mol Genet* 1999;8:81–85.
 74. Feingold A, Nini A, Raz A, Zelenskaya V, Bergman H. Functional connectivity and information processing in the basal ganglia of normal and parkinsonian monkeys. In: Ohye C, editor. *The basal ganglia V*. New York: Plenum Press; 1996.
 75. Ferbert A, Gerwig M. Tremor due to stroke. *Mov Disord* 1993;8:179–182.
 76. Fernandez HH, Friedman JH, Centofanti JV. Benedikt's syndrome with delayed-onset rubral tremor and hemidystonia: a complication of tic douloureux surgery. *Mov Disord* 1999; 14:695–697.
 77. Findley JL, Koller WC. *Handbook of tremor disorders*. New York: Marcel Dekker; 1995.
 78. Findley LJ, Capildeo R, editors. *Movement disorders: tremor*. London: Macmillan; 1984.
 79. Flament D, Hore J. Comparison of cerebellar intention tremor under isometric and isometric conditions. *Brain Res* 1988;439:179–186.
 80. Flament D, Hore J. Movement and electromyographic disorders associated with cerebellar dysmetria. *J Neurophysiol* 1986;55:1221–1233.
 81. Flament D, Vilis T, Hore J. Dependence of cerebellar tremor on proprioceptive but not visual feedback. *Exp Neurol* 1984; 84:314–325.
 82. Foley TH, Marsden CD, Owen DA. Evidence for a direct peripheral effect of adrenaline on physiological tremor in man. *J Physiol (Lond)* 1967;189:65P–66P.
 83. Freund HJ. Motor unit and muscle activity in voluntary motor control. *Physiol Rev* 1983;63:387–436.
 84. Friedemann HH, Noth J, Diener HC, Bacher M. Long latency EMG responses in hand and leg muscles: cerebellar disorders. *J Neurol Neurosurg Psychiatry* 1987;50:71–77.
 85. Friedman JH. "Rubral" tremor induced by a neuroleptic drug. *Mov Disord* 1992;7:281–282.
 86. Fukuhara T, Gotoh M, Asari S, Ohmoto T. Magnetic resonance imaging of patients with intention tremor. *Comput Med Imag Graph* 1994;18:45–51.
 87. Gabellini AS, Martinelli P, Gulli MR, Ambrosetto G, Ciucci G, Lugaresi E. Orthostatic tremor: essential and symptomatic cases. *Acta Neurol Scand* 1990;81:113–117.
 88. Gates PC. Orthostatic tremor (shaky legs syndrome). *Clin Exp Neurol* 1993;30:66–71.
 89. Gelenberg AJ, Jefferson JW. Lithium tremor. *J Clin Psychiatry* 1995;56:283–287.
 90. Ghika J, Bogousslavsky J, Henderson J, Maeder P, Regli F. The "jerky dystonic unsteady hand": a delayed motor syndrome in posterior thalamic infarctions. *J Neurol* 1994;241: 537–542.
 91. Gilman S, Carr D, Hollenberg J. Limb trajectories after cerebellar ablation and deafferentation in the monkey. *Trans Am Neurol Assoc* 1976;101:168–170.
 92. Goto N, Kakimi S, Kaneko M. Olivary enlargement: stage of initial astrocytic changes. *Clin Neuropathol* 1988;7:39–43.
 93. Goto N, Kaneko M. Olivary enlargement: chronological and morphometric analyses. *Acta Neuropathol (Berl)* 1981;54: 275–282.
 94. Gulcher JR, Jonsson P, Kong A, Kristjansson K, Frigge ML, Karason A, Einarsdottir IE, Stefansson H, Einarsdottir AS, Sigurthorardottir S, Baldursson S, Bjornsdottir S, Hrafinkelsdottir SM, Jakobsson F, Benedickz J, Stefansson K. Mapping of a familial essential tremor gene, FET1, to chromosome 3q13. *Nat Genet* 1997;17:84–87.
 95. Hallett M. Is dystonia a sensory disorder? *Ann Neurol* 1995; 38:139–140.
 96. Hallett M, Dubinsky RM. Glucose metabolism in the brain of patients with essential tremor. *J Neurol Sci* 1993;114:45–48.
 97. Hallett M, Shahani BT, Young RR. EMG-analysis of stereotyped voluntary movements in man. *J Neurol Neurosurg Psychiatry* 1975;38:1154–1162.
 98. Halliday DM, Conway BA, Farmer SF, Rosenberg JR. Using electroencephalography to study functional coupling between cortical activity and electromyograms during voluntary contractions in humans. *Neurosci Lett* 1998;241:5–8.

99. Hassler R, Mundinger F, Riechert T. Pathophysiology of tremor at rest derived from the correlation of anatomical and clinical data. *Conf Neurol* 1970;32:79–87.
100. Hefter H, Homberg V, Reiners K, Freund HJ. Stability of frequency during long-term recordings of hand tremor. *Electroencephalogr Clin Neurophysiol* 1987;67:439–446.
101. Heilman KM. Orthostatic tremor. *Arch Neurol* 1984;41:880–881.
102. Hellwig B, Hausler S, Lauk M, Guschlbauer B, Koster B, Kristeva-Feige R, Timmer J, Lucking CH. Tremor-correlated cortical activity detected by electroencephalography. *Clin Neurophysiol* 2000;111:806–809.
103. Henry EW, Cowen JS, Sidman RL. Comparison of Trembler and Trembler-J mouse phenotypes: varying severity of peripheral hypomyelination. *J Neuropathol Exp Neurol* 1983;42:688–706.
104. Higgins JJ, Pho LT, Nee LE. A gene (ETM) for essential tremor maps to chromosome 2p22-p25. *Mov Disord* 1997;12:859–864.
105. Hirsch EC, Mouatt A, Fauchoux B, Bonnet AM, Javoy AF, Graybiel AM, Agid Y. Dopamine, tremor, and Parkinson's disease. *Lancet* 1992;340:125–126.
106. Holmes G. On certain tremors in organic cerebral lesions. *Brain* 1904;27:327–375.
107. Hömberg V, Hefter H, Reiners K, Freund HJ. Differential effects of changes in mechanical limb properties on physiological and pathological tremor. *J Neurol Neurosurg Psychiatry* 1987;50:568–579.
108. Hore J, Flament D. Evidence that a disordered servo-like mechanism contributes to tremor in movements during cerebellar dysfunction. *J Neurophysiol* 1986;56:123–136.
109. Hore J, Wild B, Diener HC. Cerebellar dysmetria at the elbow, wrist, and fingers. *J Neurophysiol* 1991;65:563–571.
110. Hughes AJ, Lees AJ, Marsden CD. Paroxysmal dystonic head tremor. *Mov Disord* 1991;6:85–86.
111. Hurtado JM, Gray CM, Tamas LB, Sigvardt KA. Dynamics of tremor-related oscillations in the human globus pallidus: a single case study. *Proc Natl Acad Sci USA* 1999;96:1674–1679.
112. Jacks A, Prochazka A, Trend PS. Instability in human forearm movements studied with feed-back-controlled electrical stimulation of muscles. *J Physiol (Lond)* 1988;402:443–461.
113. Jahnsen H, Llinas R. Ionic basis for the electro-responsiveness and oscillatory properties of guinea-pig thalamic neurones in vitro. *J Physiol (Lond)* 1984;349:227–247.
114. Jankovic J, Leder S, Warner D, Schwartz K. Cervical dystonia: clinical findings and associated movement disorders. *Neurology* 1991;41:1088–1091.
115. Jankovic J, McDermott M, Carter J, Gauthier S, Goetz C, Golbe L, Huber S, Koller W, Olanow C, Shoulson I, et al. Variable expression of Parkinson's disease: a base-line analysis of the DATATOP cohort. The Parkinson Study Group. *Neurology* 1990;40:1529–1534.
116. Jankovic J, Van der Linden C. Dystonia and tremor induced by peripheral trauma: predisposing factors. *J Neurol Neurosurg Psychiatry* 1988;51:1512–1519.
117. Jedynak CP, Bonnet AM, Agid Y. Tremor and idiopathic dystonia. *Mov Disord* 1991;6:230–236.
118. Jellinger KA. Post mortem studies in Parkinson's disease — is it possible to detect brain areas for specific symptoms? *J Neural Transm* 1999;56(suppl):1–29.
119. Jenkins IH, Bain PG, Colebatch JG, Thompson PD, Findley LJ, Frackowiak RS, Marsden CD, Brooks DJ. A positron emission tomography study of essential tremor: evidence for overactivity of cerebellar connections. *Ann Neurol* 1993;34:82–90.
120. Jung R. Physiologische Untersuchungen über den Parkinsontremor und andere Zitterformen beim Menschen. *Zsch Neurol Psychiatry* 1941;173:263–332.
121. Kane S, Thach W. Palatal myoclonus and function of the inferior olive: are they related? In: Strata P, editor. *The olivocerebellar system in motor control*. Berlin: Springer; 1989.
122. Kilner JM, Baker SN, Salenius S, Jousmaki V, Hari R, Lemon RN. Task-dependent modulation of 15–30 Hz coherence between rectified EMGs from human hand and forearm muscles. *J Physiol (Lond)* 1999;516:559–570.
123. Kim YJ, Pakiam AS, Lang AE. Historical and clinical features of psychogenic tremor: a review of 70 cases. *Can J Neurol Sci* 1999;26:190–195.
124. Kinney HC, Sidman RL. Pathology of the spongiform encephalopathy in the Gray tremor mutant mouse. *J Neuro-pathol Exp Neurol* 1986;45:108–126.
125. Klien H. Zur Pathologie der kontinuierlichen rhythmischen Krämpfe der Schlingmuskulatur (2 Fälle von Erweichungsherden im Kleinhirn). *Neurol Centralbl* 1907;26:245–246.
126. Koeppen AH, Barron KD, Dentinger MP. Olivary hypertrophy: histochemical demonstration of hydrolytic enzymes. *Neurology* 1980;30:471–480.
127. Koller W, Lang A, Vetere OB, Findley L, Cleaves L, Factor S, Singer C, Weiner W. Psychogenic tremors. *Neurology* 1989;39:1094–1099.
128. Koller W, O'Hara R, Dorus W, Bauer J. Tremor in chronic alcoholism. *Neurology* 1985;35:1660–1662.
129. Köster B, Lauk M, Timmer J, Poersch M, Guschlbauer B, Deuschl G, Lucking CH. Involvement of cranial muscles and high intermuscular coherence in orthostatic tremor. *Ann Neurol* 1999;45:384–388.
130. Köster B, Lauk M, Timmer J, Winter T, Guschlbauer B, Glocker FX, Danek A, Deuschl G, Lucking CH. Central mechanisms in human enhanced physiological tremor. *Neurosci Lett* 1998;241:135–138.
131. Krack P, Deuschl G, Kaps M, Warnke P, Schneider S, Traupe H. Delayed onset of "rubral tremor" 23 years after brainstem trauma. *Mov Disord* 1994;9:240–242.
132. Krack P, Hamel W, Mehdorn HM, Deuschl G. Surgical treatment of Parkinson's disease. *Curr Opin Neurol* 1999;12:417–425.
133. Krauss JK, Wakhloo AK, Nobbe F, Trankle R, Mundinger F, Seeger W. Lesion of dentatothalamic pathways in severe post-traumatic tremor. *Neurol Res* 1995;17:409–416.
134. Kretschmer E. Die Gesetze der willkürlichen Reflexverstärkung in ihrer Bedeutung für das Hysterie- und Simulationsproblem. *Zsch Neurol Psychiatry* 1918;41:354–385.
135. Lapresle J. Palatal myoclonus. *Adv Neurol* 1986;43:265–273.
136. Lapresle J. Rhythmic palatal myoclonus and the dentato-olivary pathway. *J Neurol* 1979;220:223–230.
137. Lapresle J, Ben Hamida M. A contribution to the knowledge of the dento-olivary pathway. Anatomical study of 2 cases of hypertrophic degeneration of the olivary nucleus following limited softening of the tegmentum mesencephali. *Presse Med* 1968;76:1226–1230.
138. Lapresle J, Hamida MB. The dentato-olivary pathway. Somatotopic relationship between the dentate nucleus and the contralateral inferior olive. *Arch Neurol* 1970;22:135–143.
139. Lauk M, Koster B, Timmer J, Guschlbauer B, Deuschl G, Lucking CH. Side-to-side correlation of muscle activity in physiological and pathological human tremors. *Clin Neurophysiol* 1999;110:1774–1783.
140. Lee MS, Marsden CD. Movement disorders following lesions of the thalamus or subthalamic region. *Mov Disord* 1994;9:493–507.
141. Lefebvre-D'Amour M, Shahani BT, Young RR. Tremor in alcoholic patients. *Prog Clin Neurophysiol* 1978;5:160–164.
142. Lewin L. Untersuchungen über *Banisteria caapi* Sp. (Ein südamerikanisches Rauschmittel). *Arch Exp Pathol Pharmacol* 1928;129:133–149.
143. LeWitt PA. Orthostatic tremor: the phenomenon of 'paradoxical clonus.' *Arch Neurol* 1990;47:501–502.
144. Lippold OC. Oscillation in the stretch reflex arc and the origin of the rhythmical, 8–12 c/s component of physiological tremor. *J Physiol (Lond)* 1970;206:359–382.

145. Llinas R. Rebound excitation as the physiological basis for tremor: a biophysical study of the oscillatory properties of mammalian central neurons in vitro. In: Findley LJ, Capildeo R, editors. *Movement disorders: tremor*. London: Macmillan; 1984.
146. Llinas R, Baker R, Sotelo C. Electrotonic coupling between neurons in cat inferior olive. *J Neurophysiol* 1974;37:560–571.
147. Llinas R, Yarom Y. Electrophysiology of mammalian inferior olivary neurones in vitro. Different types of voltage-dependent ionic conductances. *J Physiol (Lond)* 1981;315:549–567.
148. Lou JS, Jankovic J. Essential tremor: clinical correlates in 350 patients. *Neurology* 1991;41:234–238.
149. Louis ED, Tang MX, Cote L, Alfaro B, Mejia H, Marder K. Progression of parkinsonian signs in Parkinson disease. *Arch Neurol* 1999;56:334–337.
150. Lucking CH, Koster B, Guschlbauer B, Lauk M, Timmer J. Parkinsonian and essential tremors: different entities or different manifestations of the same disorder? *Adv Neurol* 1999;80:335–339.
151. Makela JP, Hari P, Karhu J, Salmelin R, Teravainen H. Suppression of magnetic mu rhythm during parkinsonian tremor. *Brain Res* 1993;617:189–193.
152. Manto MU, Setta F, Legros B, Jacquy J, Godaux E. Resetting of orthostatic tremor associated with cerebellar cortical atrophy by transcranial magnetic stimulation. *Arch Neurol* 1999;56:1497–1500.
153. Marsden CD. Origins of normal and pathologic tremor. In: Findley LJ, Capildeo R, editors. *Movement disorders: tremor*. London: Macmillan; 1984.
154. Marsden CD. The pathophysiology of movement disorders. *Neurol Clin* 1984;2:435–459.
155. Marsden CD, Gimlette TM, McAllister RG, Owen DA, Miller TN. Effect of beta-adrenergic blockade on finger tremor and Achilles reflex time in anxious and thyrotoxic patients. *Acta Endocrinol (Copenh)* 1968;57:353–362.
156. Marsden CD, Meadows JC. The effect of adrenaline on the contraction of human muscle—one mechanism whereby adrenaline increases the amplitude of physiological tremor. *J Physiol (Lond)* 1968;194:70P–71P.
157. Marsden CD, Meadows JC, Lange GW, Watson RS. The role of the ballistocardiac impulse in the genesis of physiological tremor. *Brain* 1969;92:647–662.
158. Masucci EF, Kurtzke JF, Saini N. Myorhythmia: a widespread movement disorder. *Clinicopathological correlations*. *Brain* 1984;107:53–79.
159. Mauritz KH, Schmitt C, Dichgans J. Delayed and enhanced long latency reflexes as the possible cause of postural tremor in late cerebellar atrophy. *Brain* 1981;104:97–116.
160. McAuley JH, Rothwell JC, Marsden CD. Frequency peaks of tremor, muscle vibration and electromyographic activity at 10 Hz, 20 Hz and 40 Hz during human finger muscle contraction may reflect rhythmicities of central neural firing. *Exp Brain Res* 1997;114:525–541.
161. McAuley JH, Rothwell JC, Marsden CD, Findley LJ. Electrophysiological aids in distinguishing organic from psychogenic tremor. *Neurology* 1998;50:1882–1884.
162. McDaniel KD, Cummings JL, Shain S. The “yips”: a focal dystonia of golfers. *Neurology* 1989;39:192–195.
163. McManis PG, Sharbrough FW. Orthostatic tremor: clinical and electrophysiologic characteristics. *Muscle Nerve* 1993;16:1254–1260.
164. Meert TF. Pharmacological evaluation of alcohol withdrawal-induced inhibition of exploratory behaviour and supersensitivity to harmine-induced tremor. *Alcohol Alcohol* 1994;29:91–102.
165. Meert TF, Rassnick S, Huysmans H, Peeters J, et al. Quantification of tremor sensitivity and inhibition of exploratory behaviour during alcohol withdrawal in rats. *Behav Pharmacol* 1992;3:601–607.
166. Meyer-Lohmann J, Conrad B, Matsunami K, Brooks VB. Effects of dentate cooling on precentral unit activity following torque pulse injections into elbow movements. *Brain Res* 1975;94:237–251.
167. Milanov I, Georgiev D. Writer’s cramp and tremor due to brain tumor. *Can J Neurol Sci* 1995;22:59–61.
168. Milanov I, Toteva S, Georgiev D. Alcohol withdrawal tremor. *Electromyogr Clin Neurophysiol* 1996;36:15–20.
169. Miwa H, Hatori K, Kondo T, Imai H, Mizuno Y. Thalamic tremor: case reports and implications of the tremor-generating mechanism. *Neurology* 1996;46:75–79.
170. Montastruc JL, Llau ME, Rascol O, Senard JM. Drug-induced parkinsonism: a review. *Fundam Clin Pharmacol* 1994;8:293–306.
171. Mossuto AL, Puccetti G, Castellano AE. “Rubral” tremor after thalamic haemorrhage. *J Neurol* 1993;241:27–30.
172. Nagaratnam N, Kalasabail G. Contralateral abolition of essential tremor following a pontine stroke. *J Neurol Sci* 1997;149:195–196.
173. Nieuwboer A, De Weerd W, Dom R, Lesaffre E. A frequency and correlation analysis of motor deficits in Parkinson patients. *Disabil Rehabil* 1998;20:142–150.
174. Oguztoreli MN, Stein RB. Interactions between centrally and peripherally generated neuromuscular oscillations. *J Math Biol* 1979;7:1–30.
175. Papa SM, Gershanik OS. Orthostatic tremor: an essential tremor variant? *Mov Disord* 1988;3:97–108.
176. Parent A, Hazrati L-N. Functional anatomy of the basal ganglia. I. The cortico-basal ganglia-thalamo-cortical loop. *Brain Res Rev* 1995;20:91–127.
177. Paulus W, Jellinger K. The neuropathologic basis of different clinical subgroups of Parkinson’s disease. *J Neuropathol Exp Neurol* 1991;50:743–755.
178. Pelán J. Das Zittern. Seine Erscheinungsformen, seine Pathogenese und klinische Bedeutung. Berlin: Springer; 1913.
179. Pennes HH, Hoch PH. Psychotomimetics, clinical and theoretical considerations: Harmine, Win-2299 and Nalline. *Am J Psychiatry* 1957;113:885–892.
180. Piper H. Über den willkürlichen Muskeltetanus. *Pflügers Arch* 1907;119:301–338.
181. Plenz D, Kital ST. A basal ganglia pacemaker formed by the subthalamic nucleus and external globus pallidus. *Nature* 1999;400:677–682.
182. Poersch M. Orthostatic tremor: combined treatment with primidone and clonazepam. *Mov Disord* 1994;9:467.
183. Poersch M, Koster B. Tremor frequency shift in orthostatic tremor from low to high frequencies due to forceful muscle contractions. *Muscle Nerve* 1996;19:795–796.
184. Pollock LJ, Davis L. Muscle tone in Parkinsonian states. *Arch Neurol Psychiatry* 1930;23:303–309.
185. Prochazka A, Trend PS. Instability in human forearm movements studied with feed-back-controlled muscle vibration. *J Physiol (Lond)* 1988;402:421–442.
186. Raethjen J, Lindemann M, Schmaljohann H, Wenzelburger R, Pfister G, Deuschl G. Multiple oscillators are causing parkinsonian and essential tremor. *Mov Disord* 2000;15:84–94.
187. Raethjen J, Pawlas F, Lindemann M, Wenzelburger R, Deuschl G. Determinants of physiologic tremor in a large normal population. *Clin Neurophysiol* 2000;111:1825–1837.
188. Rajput AH, Rozdilsky B, Ang L, Rajput A. Clinicopathologic observations in essential tremor: report of six cases. *Neurology* 1991;41:1422–1424.
189. Remy P, de Recondo A, Defer G, Loc’h C, Amarenco P, Plante-Bordeneuve V, Dao-Castellana MH, Bendriem B, Crouzel C, Clanet M, et al. Peduncular “rubral” tremor and dopaminergic denervation: a PET study. *Neurology* 1995;45:472–477.
190. Richter A, Wissel J, Harlizius B, Simon D, Schelosky L, Scholz U, Poewe W, Loscher W. The “campus syndrome” in pigs: neurological, neurophysiological, and neuropharmacologi-

- cal characterization of a new genetic animal model of high-frequency tremor. *Exp Neurol* 1995;134:205–213.
191. Rivest J, Marsden CD. Trunk and head tremor as isolated manifestations of dystonia. *Mov Disord* 1990;5:60–65.
 192. Rosenbaum F, Jankovic J. Focal task-specific tremor and dystonia: categorization of occupational movement disorders. *Neurology* 1988;38:522–527.
 193. Sander HW, Masdeu JC, Tavoulares G, Walters A, Zimmerman T, Chokroverty S. Orthostatic tremor: an electrophysiological analysis. *Mov Disord* 1998;13:735–738.
 194. Sasaki H, Sudoh K, Hamada K, Hamada T, Tashiro K. Skeletal myoclonus in olivopontocerebellar atrophy: treatment with trihexyphenidyl. *Neurology* 1987;37:1258–1262.
 195. Schwartzman RJ, Kerrigan J. The movement disorder of reflex sympathetic dystrophy. *Neurology* 1990;40:57–61.
 196. Senderek J, Hermans B, Bergmann C, Borojerdi B, Bajbouj M, Hungs M, Ramaekers VT, Quasthoff S, Karch D, Schroder JM. X-linked dominant Charcot-Marie-Tooth neuropathy: clinical, electrophysiological, and morphological phenotype in four families with different connexin32 mutations. *J Neurol Sci* 1999;167:90–101.
 197. Sheehy MP, Rothwell JC, Marsden CD. Writer's cramp. *Adv Neurol* 1988;50:457–472.
 198. Singer W. Coherence as an organizing principle of cortical functions. *Int Rev Neurobiol* 1994;37:153–183.
 199. Singer W. Neurobiology. Striving for coherence. *Nature* 1999;397:391.
 200. Smith IS. The natural history of chronic demyelinating neuropathy associated with benign IgM paraproteinaemia. A clinical and neurophysiological study. *Brain* 1994;117:949–957.
 201. Soland VL, Bhatia KP, Volonte MA, Marsden CD. Focal task-specific tremors. *Mov Disord* 1996;11:665–670.
 202. Sotelo C, Gotow T, Wassef M. Localization of glutamic-acid-decarboxylase-immunoreactive axon terminals in the inferior olive of the rat, with special emphasis on anatomical relations between GABAergic synapses and dendrodendritic gap junctions. *J Comp Neurol* 1986;252:32–50.
 203. Sotelo C, Llinas R, Baker R. Structural study of inferior olivary nucleus of the cat: morphological correlates of electrotonic coupling. *J Neurophysiol* 1974;37:541–559.
 204. Stein JF, Aziz TZ. Does imbalance between basal ganglia and cerebellar outputs cause movement disorders? *Curr Opin Neurol* 1999;12:667–669.
 205. Stein RB, Lee RG. Tremor and clonus. *Handbook of physiology*. Bethesda, MD: American Physiological Society; 1981.
 206. Stein RB, Lee RG, Nichols TR. Modifications of ongoing tremors and locomotion by sensory feedback. *Electroencephalogr Clin Neurophysiol* 1978;34:512–519.
 207. Stephens JA, Taylor A. The effect of visual feedback on physiological muscle tremor. *Electroencephalogr Clin Neurophysiol* 1974;36:457–464.
 208. Steriade M, Deschenes M. The thalamus as a neuronal oscillator. *Brain Res* 1984;320:1–63.
 209. Streib EW. Distal ulnar neuropathy as a cause of finger tremor: a case report. *Neurology* 1990;40:153–154.
 210. Tass P, Rosenblum MG, Weule J, Kurths J, Pikovsky A, Volkman J, Schnitzler A, Freund H-J. Detection of n:m phase locking from noisy data: application to magnetoencephalography. *Phys Rev Lett* 1998;81:3291–3294.
 211. Thach WT, Goodkin HP, Keating JG. The cerebellum and the adaptive coordination of movement. *Annu Rev Neurosci* 1992;15:403–442.
 212. Thompson PD, Rothwell JC, Day BL, Berardelli A, Dick JP, Kachi T, Marsden CD. The physiology of orthostatic tremor. *Arch Neurol* 1986;43:584–587.
 213. Timmer J, Lauk M, Pflieger W, Deuschl G. Cross-spectral analysis of physiological tremor and muscle activity. I. Theory and application to unsynchronized electromyogram. *Biol Cybernet* 1998;78:349–357.
 214. Timmer J, Lauk M, Pflieger W, Deuschl G. Cross-spectral analysis of physiological tremor and muscle activity. II. Application to synchronized electromyogram. *Biol Cybernet* 1998;78:359–368.
 215. Tison F, Lecaroz J, Letenneur L, Dartigues JF. Parkinsonism and exposure to neuroleptic drugs in elderly people living in institutions. *Clin Neuropharmacol* 1999;22:5–10.
 216. Tissingh G, Bergmans P, Booij J, Winogrodzka A, van Royen EA, Stoof JC, Wolters EC. Drug-naïve patients with Parkinson's disease in Hoehn and Yahr stages I and II show a bilateral decrease in striatal dopamine transporters as revealed by [¹²³I]beta-CIT SPECT. *J Neurol* 1998;245:14–20.
 217. Topka H, Mescheriakov S, Boose A, Kuntz R, Hertrich I, Seydel L, Dichgans J, Rothwell J. A cerebellar-like terminal and postural tremor induced in normal man by transcranial magnetic stimulation. *Brain* 1999;122:1551–1562.
 218. Urushitani M, Inoue H, Kawamura K, Kageyama T, Fujisawa M, Nishinaka K, Udaka F, Kameyama M. Disappearance of essential neck tremor after pontine base infarction. *No To Shinkei* 1996;48:753–756.
 219. Vallbo AB, Wessberg J. Organization of motor output in slow finger movements in man. *J Physiol (Lond)* 1993;469:673–691.
 220. Vestergaard P, Amdisen A, Schou M. Clinically significant side effects of lithium treatment. A survey of 237 patients in long-term treatment. *Acta Psychiatr Scand* 1980;62:193–200.
 221. Vidailhet M, Jedynak CP, Pollak P, Agid Y. Pathology of symptomatic tremors. *Mov Disord* 1998;13:49–54.
 222. Vilis T, Hore J. Effects of changes in mechanical state of limb on cerebellar intention tremor. *J Neurophysiol* 1977;40:1214–1224.
 223. Volkman J, Joliot M, Mogilner A, Ioannides AA, Lado F, Fazzini E, Ribary U, Llinas R. Central motor loop oscillations in parkinsonian resting tremor revealed by magnetoencephalography. *Neurology* 1996;46:1359–1370.
 224. Wachholder K, Haas J. Untersuchungen über organischen und nichtorganischen Tremor. Berlin: Springer; 1929.
 225. Wade P, Gresty MA, Findley LJ. A normative study of postural tremor of the hand. *Arch Neurol* 1982;39:358–362.
 226. Walker FO, McCormick G. Orthostatic tremor. *Mov Disord* 1991;6:266–267.
 227. Wessberg J, Kakuda N. Single motor unit activity in relation to pulsatile motor output in human finger movements. *J Physiol (Lond)* 1999;517:273–285.
 228. Wessberg J, Vallbo AB. Coding of pulsatile motor output by human muscle afferents during slow finger movements. *J Physiol (Lond)* 1995;485:271–282.
 229. Wessberg J, Vallbo AB. Pulsatile motor output in human finger movements is not dependent on the stretch reflex. *J Physiol (Lond)* 1996;493:895–908.
 230. Wills AJ, Brusa L, Wang HC, Brown P, Marsden CD. Levodopa may improve orthostatic tremor: case report and trial of treatment. *J Neurol Neurosurg Psychiatry* 1999;66:681–684.
 231. Wills AJ, Jenkins IH, Thompson PD, Findley LJ, Brooks DJ. A positron emission tomography study of cerebral activation associated with essential and writing tremor. *Arch Neurol* 1995;52:299–305.
 232. Wills AJ, Jenkins IH, Thompson PD, Findley LJ, Brooks DJ. Red nuclear and cerebellar but no olivary activation associated with essential tremor: a positron emission tomographic study. *Ann Neurol* 1994;36:636–642.
 233. Wills AJ, Thompson PD, Findley LJ, Brooks DJ. A positron emission tomography study of primary orthostatic tremor. *Neurology* 1996;46:747–752.
 234. Wilms H, Sievers J, Deuschl G. Animal models of tremor. *Mov Disord* 1999;14:557–571.
 235. Winfree AT. *The geometry of biological time*. New York: Springer; 1980.
 236. Wissel J, Harlizuis B, Richter A, Loscher W, Schelosky L, Scholz U, Poewe W. A new tremor mutant in the Pietrain pig: an animal model of orthostatic tremor? *Clinical and*

- neurophysiological observations. *Mov Disord* 1997;12:743-746.
237. Yamazaki K, Wakasugi N, Tomita T, Kikuchi T, Mukoyama M, Ando K. Gracile axonal dystrophy (GAD), a new neurological mutant in the mouse. *Proc Soc Exp Biol Med* 1988;187:209-215.
238. Yanagisawa T, Sugihara H, Shibahara K, Kamo T, Fujisawa K, Murayama M. Natural course of combined limb and palatal tremor caused by cerebellar-brain stem infarction. *Mov Disord* 1999;14:851-854.
239. Yeung KB, Thomas PK, King RH, Waddy H, Will RG, Hughes RA, Gregson NA, Leibowitz S. The clinical spectrum of peripheral neuropathies associated with benign monoclonal IgM, IgG and IgA paraproteinaemia. Comparative clinical, immunological and nerve biopsy findings. *J Neurol* 1991;238:383-391.
240. Yokota T, Hirashima F, Furukawa T, Tsukagoshi H, Yoshikawa H. MRI findings of inferior olives in palatal myoclonus. *J Neurol* 1989;236:115-116.
241. Yokota T, Tsukagoshi H. Olivary hypertrophy precedes the appearance of palatal myoclonus. *J Neurol* 1991;238:408.
242. Zirh TA, Lenz FA, Reich SG, Dougherty PM. Patterns of bursting occurring in thalamic cells during parkinsonian tremor. *Neuroscience* 1998;83:107-121.