

The place of magnetic resonance and ultrasonographic examinations of the parotid gland in the diagnosis and follow-up of primary Sjögren's syndrome

É. Makula, G. Pokorny¹, M. Kiss, E. Vörös, L. Kovács¹,
A. Kovács¹, L. Csernay and A. Palkó

Department of Radiology and ¹1st Department of Medicine,
Albert Szent-Györgyi Medical University, Szeged, Hungary

Abstract

Objective. The aim was to determine the place of magnetic resonance imaging (MRI) and ultrasonographic (US) examination in the diagnosis and follow-up of Sjögren's syndrome (SS).

Methods. Parotid MRI and US examinations were carried out on 44 primary SS patients and 52 controls of similar age.

Results. The most important structural changes in SS were different degrees of parenchymal inhomogeneity, which could be detected by both methods, and were found more frequently in the SS patients than in the controls (MRI: 95.4 vs 17.3%; US: 88.6 vs 7.7%; $P < 0.001$). There was good agreement between the MRI and US findings both in the SS cases (93.2%) and in the controls (86.5%). In one SS patient who developed parotid lymphoma, the US examination showed a hypoechoic 'cobblestones'-like inhomogeneous internal pattern which was coupled with an almost homogeneous MRI pattern.

Conclusions. MRI appears unnecessary as a routine method in the diagnosis of SS; US examination is suitable both for the diagnosis and follow-up of SS. The above combination of the seemingly contradictory US and MRI findings is highly characteristic of lymphoma which has developed in the course of the disease.

KEY WORDS: Primary Sjögren's syndrome, Ultrasonographic examination, Magnetic resonance imaging, Lymphoma.

Primary Sjögren's syndrome (SS) is a chronic inflammatory autoimmune disease affecting mainly the exocrine glands. The involvement of the salivary and lacrimal glands is an obligatory component of the disease, resulting in xerostomia and xerophthalmia. Histologically, SS is characterized by lymphoplasmacytic infiltration, parenchymal destruction and later atrophy of the affected glands. Besides the salivary and lacrimal glands, other organs (respiratory tract, gastrointestinal tract, vascular system, kidneys and joints) are often involved, accompanied by either clinically manifest symptoms or only latent functional disturbances [1, 2].

While the ocular component of the disease, keratoconjunctivitis sicca, can be diagnosed accurately by objective tests, the assessment of the salivary gland manifestation is more difficult. Of the various tests that have been applied to date, histological examination of the minor

salivary glands and sialography are considered to be the most reliable methods for diagnosis of the oral component [3]. Nevertheless, the necessity of the simultaneous performance of other tests is emphasized by most authors [4–6], as both histology and sialography can give a negative result in SS and they cannot be performed in all cases. Understandably, great efforts have been made to find methods with appropriate sensitivity and specificity, and imaging modalities such as salivary gland scintigraphy, ultrasonography (US), computed tomography (CT) and magnetic resonance imaging (MRI) have been introduced to diagnose the salivary manifestation of the disease [5, 7–10]. MRI is generally regarded as an important modality which allows a non-invasive evaluation of the complex anatomy of the parotid gland [11]. Parotid gland US has likewise proved to be a useful method for the diagnosis of SS [7, 8].

Here, we present our findings on the clinical value of parotid MRI as compared with that of US in the detection of the oral component of SS. The aim was to determine the place of MRI and US in the diagnosis and follow-up of SS.

Submitted 25 February 1999; revised version accepted 8 September 1999.

Correspondence to: G. Pokorny.

Patients and methods

In 1997 and 1999, parotid gland MRI and US examinations were performed on 44 (41 females and three males) primary SS patients with systemic symptoms and on 52 controls (46 females and six males). All the patients met the European Community criteria for SS [12]. The mean age of the SS patients was 53.6 yr (range 32–74), and the mean duration of xerostomia and/or parotid enlargement was 11.6 yr (range 3–23).

Three groups of subjects of similar age (mean 49.2 yr, range 22–72) served as controls for the imaging examinations. The first group (C_1 : 'healthy' controls; $n = 14$) consisted of four healthy volunteers and 10 patients with diseases generally not involving the salivary glands (e.g. reflux oesophagitis, osteoporosis, renal stone, etc.). The second control group (C_2 ; $n = 27$) comprised patients with diseases which can affect the glands (16 patients with diabetes mellitus, five with hyperlipidaemia and six with chronic liver disease). The third control group (C_3) consisted of 11 female patients with sicca symptoms not fulfilling the criteria for definite SS. Recurring subjective xerostomia occurred in all diabetic and hyperlipidaemic patients, in two of the six patients with chronic liver disease and in three of group C_1 .

US examinations

All the SS patients and the controls were examined with a real-time high-resolution US system (Acuson 128 XP, Acuson Corp., CA, USA) equipped with a 7 MHz linear transducer. As described previously, both parotids were examined in transversal (in the cranial to caudal direction) and longitudinal (in the anterior to posterior direction) planes. The parenchymal homogeneity, echogenicity and size of the gland were evaluated. In normal cases, the parenchyma is homogeneous. In the cases of parenchymal inhomogeneity (PIH), which is the most important structural change in SS, three grades of PIH were distinguished [7, 8]. In mild PIH (grade 1), a diffuse microareolar structure can be seen, the borders of the hypoechogenic areolae are blurred, and the areolae are < 2 mm in diameter. In evident (moderately severe) PIH (grade 2), the hypoechogenic areas are larger (2–6 mm in diameter), with a sharper border. In gross (severe) PIH (grade 3), large (> 6 mm in diameter) circumscribed hypoechogenic areas are also present (Fig. 1). The parenchymal echogenicity was determined in comparison with that of the thyroid gland. The size of the parotid was considered to be normal if its width was 27 ± 7 mm. The US pictures were judged independently by two observers who were not aware of the clinical diagnosis or the opinion of the other examiner.

MRI

MRI of the parotid glands was carried out with a 0.5 T MR imager (Gyrex V Dlx Elscint, Elscint Ltd; Haifa, Israel) with a 256×256 matrix. A head coil was used on all subjects examined. The MR images were obtained with spin-echo sequences (T1-weighted: TR/TE = 480 ms/20 ms; T2-weighted: TR/TE = 4000 ms/100 ms).

Both axial and coronal scans were obtained on all subjects, with a slice thickness of 5 mm (T1) and 6 mm (T2) without a gap. Following intravenous injection of the contrast medium gadolinium-diethylene-triamine-pentaacetic acid (DTPA) (Magnevist, Schering, Berlin; 0.1 ml/kg body mass), axial and coronal images were taken again. During the examination, the structure and size of the parotid gland, and its relationship to the surrounding tissues (masseter, parapharyngeal space) was evaluated. In the evaluation of the parotid structure, the stage categories described by Späth and colleagues [10] were distinguished, with a slight modification [grade 0, normal, homogeneous parenchyma; grade 1, fine reticular or small nodular structure (diameter of nodules < 2 mm); grade 2, medium nodular (2–5 mm in diameter); and grade 3, coarsely nodular (> 5 mm in diameter)] (Fig. 1). This modification seems to be justified, as in this way the MRI categories become comparable with the US ones. The MRI scans were evaluated by two independent examiners, who were unaware of the clinical diagnosis and of the opinion of the other examiner.

Histology

A lower lip biopsy was performed for histological examination of the minor salivary glands in 38 SS patients. The histology was considered positive if at least one focus of ≥ 50 mononuclear inflammatory cells per 4 mm^2 was found [3, 12]. A US-guided percutaneous parotid gland biopsy was performed in two SS patients in whom palpation and imaging suggested the possibility of a malignant lymphoma.

Laboratory investigations

Routine laboratory and immunoserological examinations were carried out on all patients: antinuclear antibodies (ANA; indirect immunofluorescence on rat liver substrate), IgM rheumatoid factor (latex test, positive if titre $\geq 1:40$), anti-native DNA (radioimmunoassay), anti-SSA, anti-SSB, anti-RNP and anti-Sm antibodies (enzyme-linked immunosorbent assay; ImmunoDOT), and concentrations of complement C3 (rocket immunoelectrophoresis) and serum immunoglobulins (Mancini technique).

Statistical analysis

The Fisher exact test was applied for pairwise comparison of the age of the patients, the duration of the salivary gland involvement and the clinical variables in the groups of SS patients exhibiting different structural patterns of parotids in the imaging examinations.

Results

As concerns the clinical picture of the SS patients, the articular involvement was the most frequent systemic manifestation (97.7%). As indicated in Table 1, this was followed, in the sequence of decreasing frequency, by involvement of the upper airways (from the nose inclusive of the two main bronchi; 81.8%), vascular changes

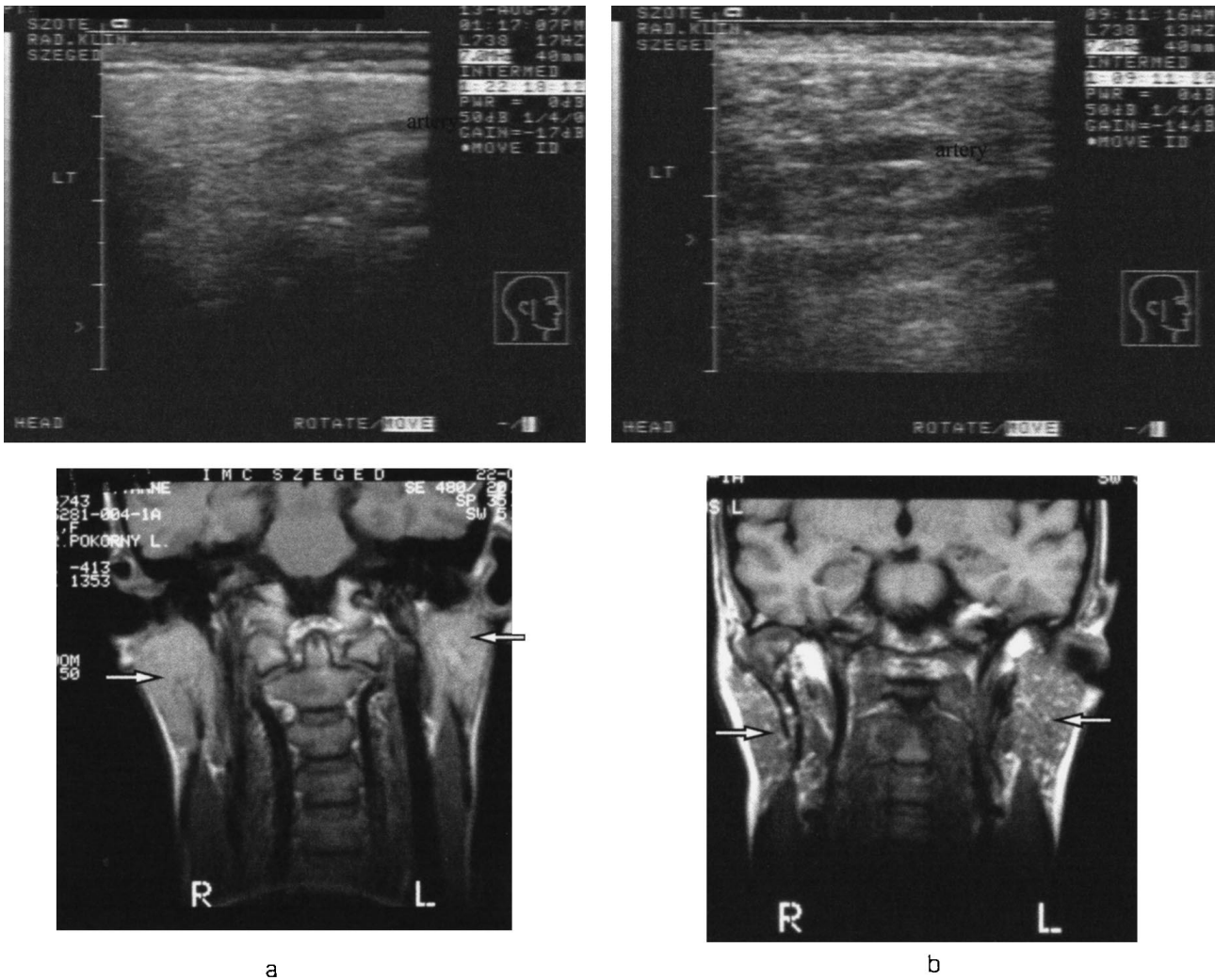


FIG. 1. Parenchymal patterns of the parotid glands on US and MRI examinations in patients with SS. (a) Homogeneous parotid in a 47-yr-old SS patient on US (upper) and MRI (lower) examinations. (b) Gross PIH in the parotids on US, and a coarsely nodular pattern on MRI examination in a 46-yr-old SS patient.

(54.5%) and lower airway disease (from the segmental bronchi to the small airways; 31.8%). In five of the 14 patients with lower airway involvement, high-resolution CT also showed lung fibrosis (mild in three and clinically significant in two), and one of the 14 had interstitial pneumonitis many years ago. As regards the laboratory findings, the IgM rheumatoid factor and anti-SSA and/or SSB antibody positivities were the most frequent serological changes, with occurrences of 81.8 and 81.7%, respectively.

Parotid enlargement was observed in half of the SS patients. In one SS patient with enlarged parotids, a B-cell lymphoma developed in both parotids in 1997, 6 yr after the onset of the disease (Fig. 2). In another patient with enlarged nodular parotids, histological examination of the US-guided fine-needle biopsy specimen raised the possibility of a non-Hodgkin lymphoma, but the histology on the surgically removed parotids did not confirm a malignant transformation. In a third patient, subtotal parotidectomy was likewise performed

because of nodular parotids 13 yr ago (1986). As in the former patient, the histological examination demonstrated a benign lymphoepithelial lesion without signs of malignancy. However, in this patient, a pulmonary B-cell lymphoma developed in 1998, 18 yr after the first symptom of the disease.

In the SS patients, characteristically of the disease, both MRI and US examinations revealed the structural changes in the parotids to be bilateral. A positive result (inhomogeneous parenchyma) was obtained significantly more frequently by both imaging methods in the SS patients than in the control groups ($P < 0.001$). MRI positivity was found in 42 (95.4%) and US positivity in 39 (88.6%) of the 44 SS patients. In the C_1 and C_2 groups, a positive result was rare (US: 1/41; 2.4%, and MRI: 5/41; 12.2%), and the structural changes were mild in all positive cases. In group C_3 , the structural changes were also mild, but the frequency of both US (3/11; 27.3%) and MRI (4/11; 36.4%) positivity was slightly higher; US positivity proved to be significantly

TABLE 1. Main clinical manifestations and laboratory findings in patients with primary SS ($n = 44$) during the course of the disease

| Manifestations and laboratory findings | Frequency of occurrence | |
|--------------------------------------------------------|-------------------------|------|
| | <i>n</i> | % |
| Parotid enlargement | 23 | 52.3 |
| Articular | 43 | 97.7 |
| Vascular | 24 | 54.5 |
| Vasculitis | 2 | 4.5 |
| Purpura | 8 | 18.2 |
| Raynaud's phenomenon | 19 | 43.2 |
| Renal ^a | 12 | 27.3 |
| Upper airway | 36 | 81.8 |
| Lower airway ^b | 14 | 31.8 |
| B-cell lymphoma (6 and 18 yr after the first symptoms) | 2 | 4.5 |
| Anaemia | 14 | 31.8 |
| Leucopenia | 22 | 50.0 |
| Antibody positivity | | |
| Only anti-SSA | 17 | 38.6 |
| Only anti-SSB | 2 | 4.5 |
| Anti-SSA + SSB | 17 | 38.6 |
| IgM rheumatoid factor | 36 | 81.8 |
| ANA | 27 | 61.4 |
| Hypergammaglobulinaemia | 28 | 63.6 |

^aRenal tubular acidosis, and histologically proven chronic tubulointerstitial nephritis in two of the 12 patients.

^bLung fibrosis was also diagnosed in five of the 14 patients and lymphocytic interstitial pneumonitis in one.

higher in this group than in group C₂ ($P < 0.05$). There was good agreement between the MRI and US findings both in the SS cases (41/44; 93.2%) and in the control groups (C₁: 13/14; 92.9%, C₂: 24/27; 88.9%, and C₃: 8/11; 72.7%) (Table 2). The agreement was taken as complete if the US and MRI grade categories were the same, and as incomplete if the MRI and US grades of change were different. In all three control groups, MRI and US results were always in complete agreement. In 26 of the 44 SS patients, the agreement between the MRI and US results was complete [both positive in 24

(54.6%) and both negative in two (4.5%)], and incomplete in 15 (34.1%) (Fig. 3). In 14 of the latter 15 patients, there was only a difference of one grade between the results of the two imaging methods (a more severe US change in 13, a more severe MRI change in one). In the remaining case, the inhomogeneity of the glands was found to be marked on US examination (grade 3), with the suspicion of a lymphoma. In this patient, the enlarged parotids exhibited a very fine reticular (grade 1), almost homogeneous signal pattern, with low intensity in the T1-weighted sequence and high intensity in the T2-weighted sequence, supporting the possibility of a lymphoma. This was confirmed by histological examination of the US-guided fine-needle biopsy specimen and the surgically removed parotids.

Two groups of SS patients were differentiated on the basis of the US findings: patients with a homogeneous parotid gland parenchyma and mild PIH (grade 1), and patients with more advanced abnormalities (grade 2 or 3) which are of true diagnostic value [8]. There were no significant differences between the patients in these two groups as regards age, duration of salivary gland involvement, articular, vascular, renal or airway manifestations, presence of anaemia and/or leucocytopenia, ANA and anti-SSA antibody positivity. In contrast, parotid enlargement, anti-SSB and anti-SSA + SSB antibody positivities, hypergammaglobulinaemia ($P < 0.01$) and IgM rheumatoid factor positivity ($P < 0.001$) were significantly more frequent in the latter group. Similarly, of the immunological variables, hypergammaglobulinaemia ($P < 0.01$), rheumatoid factor ($P < 0.05$) and anti-SSB ($P < 0.05$) antibody positivities were more frequent in the 32 SS patients with more severe MRI changes (grade 2 or 3) than in the 10 patients with MRI abnormalities of grade 1. Because of the small number of patients, the two MRI-negative cases were omitted from this evaluation. The other laboratory parameters and the clinical manifestations, including the parotid enlargement, did not differ significantly between the two patient groups.

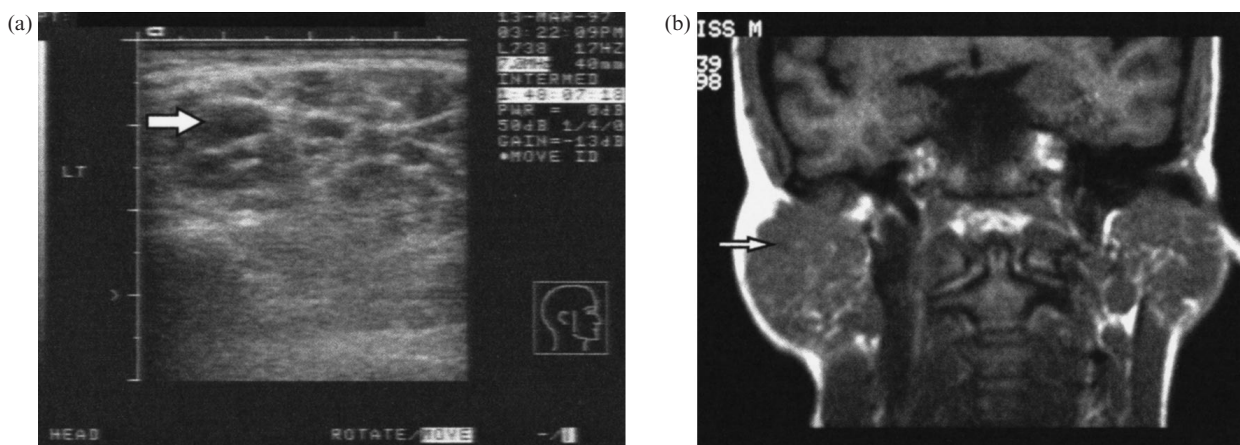


FIG. 2. Parenchymal patterns of the parotid gland on US (a) and MRI (b) examinations in a 54-yr-old SS patient with B-cell lymphoma. (a) US: unusually large, ill-defined hypoechoic area with a 'cobblestones'-like internal pattern (\Rightarrow) in the parotid corresponding to the lymphoma. (b) MRI: almost homogeneous fine reticular pattern of the lymphoma involving the whole parotid gland (\Rightarrow).

TABLE 2. Relationship between MRI and US findings as concerns the parenchymal structure of the parotid glands in SS patients ($n = 44$) and in the control groups (C_1 : $n = 14$ 'healthy' controls; C_2 : $n = 27$ patients with diabetes mellitus or hyperlipidaemia or chronic liver disease; and C_3 : $n = 11$ patients with sicca symptoms not fulfilling criteria for definite SS)

| US findings | MRI findings | | | | | | | | | |
|-------------|--------------|--------------------|----------|----------|-------|--------------------|-------|--------------------|-------|--------------------|
| | SS | | | | C_1 | | C_2 | | C_3 | |
| | H | Fine R/ small N | Medium N | Coarse N | H | Fine R/ small N | H | Fine R/ small N | H | Fine R/ small N |
| H | 2 | 3 | – | – | 12 | 1 | 24 | 3 | 6 | 2 |
| Mild PIH | – | 3 | 1 | – | – | 1 | – | – | 1 | 2 |
| Evident PIH | – | 3 | 11 | – | | | | | | |
| Gross PIH | – | 1 | 10 | 10 | | | | | | |

H, homogeneous parenchyma; PIH, parenchymal inhomogeneity; R, reticular pattern; N, nodular pattern.

Histology of the minor salivary glands of the lower lip biopsy was chosen for the determination of the sensitivity and specificity of the MRI and US examinations. When all abnormal MRI changes (grades 1–3) were taken as positive findings, the sensitivity of MRI was high (100%), but its specificity was low (40%). However, when only the advanced MRI stage categories (grades 2 and 3) were taken as MRI-positive findings, the MRI sensitivity remained good (81.8%), while its specificity increased to 100%. With only the evident and gross PIH (which are of true diagnostic value [7, 8]) taken as positive findings, the sensitivity and specificity of the US examinations were 90.9 and 100%, respectively.

Discussion

Subjective xerostomia is a troublesome complaint in most primary SS patients. From a clinical point of view, it is important to define whether the feeling of a dry mouth is caused by SS or other diseases (e.g. diabetes) or conditions (e.g. drugs, smoking, etc.). Of the various imaging methods, to date only sialography and/or salivary gland scintigraphy are accepted reliable methods for the diagnosis of salivary gland involvement. However, modalities such as US, CT and MRI are also useful techniques in this respect [7–10]. As the risk of developing a lymphoma in the SS salivary gland is increased, not only the diagnosis of the oral component of the disease, but also the early detection of any malignant complication is of great importance. Lymphomas may appear several years after the onset of SS [1, 13]. In the choice of the diagnostic modalities, besides the costs, it is important to decide which methods must be used and which need not in the different stages of the disease. If a certain method cannot be performed for some reason, it is also essential to decide which method can replace it with information of similar value. In general, techniques with less discomfort to and burden on the patient should be preferred, if this does not jeopardize the correct diagnosis. In our practice, similar to that of others [7], US proved to be a useful and reliable method for the diagnosis of the salivary involvement of SS. The presence of bilateral PIH, the most important US change

in SS, displayed a good correlation ($\sim 85\%$) with the results of sialography, scintigraphy and histology of the minor salivary glands [8]. However, only evident and gross PIH can be regarded as being of true diagnostic value for the disease, since mild PIH can also be present in other disorders with subjective xerostomia [7, 8].

MRI, another modern imaging modality, is considered useful in the diagnosis of both tumorous and non-tumorous parotid diseases [10, 13–17], including SS. In parotid tumours, MRI is held to be superior to all other imaging techniques [10, 13, 14]. The normal parotid is usually homogeneous, with an intermediate signal intensity (higher than that of the masseter, and lower than that of the fat tissue) on T1-weighted sequences. On T2-weighted images, the salivary glands also have a higher signal intensity than that of the muscle, but equal to or lower than that of the fat [14–16, 18]. On axial scans, the facial nerve can often be seen as a hypointense, linear structure within the parotids. For typical SS parotids, similar to the US picture, MRI gives an inhomogeneous internal pattern in both T1- and T2-weighted sequences, often described as having a 'salt-and-pepper' or 'honeycomb-like' appearance. This nodular picture consists of multiple mixed hypo- and hyperintense foci varying in size and scattered throughout the parotids [10, 11, 18]. Späth *et al.* [10] described a staging system with four severity categories, and considered all of them (from the fine reticular to the coarsely nodular patterns) to be highly suggestive of SS. However, other authors [18] have emphasized that a slightly inhomogeneous appearance may also be seen in the parotids of normal individuals. In SS, the diagnostic value of MRI has been assessed in comparison with that of sialography [18] and histology of the salivary glands [11]. Takashima *et al.* [18] found MRI to be a clinically beneficial, but not the optimal imaging method for the evaluation of the salivary involvement in SS, because its sensitivity was lower than that of sialography. In the study by Valesini *et al.* [11], the sensitivity of MRI was 70.5% and its specificity was 100% on the basis of the salivary gland histology. In more than half of their 17 SS patients, the histological grade was essentially higher than that of MRI. This discrepancy may be ascribed to the fact that the microscopic changes

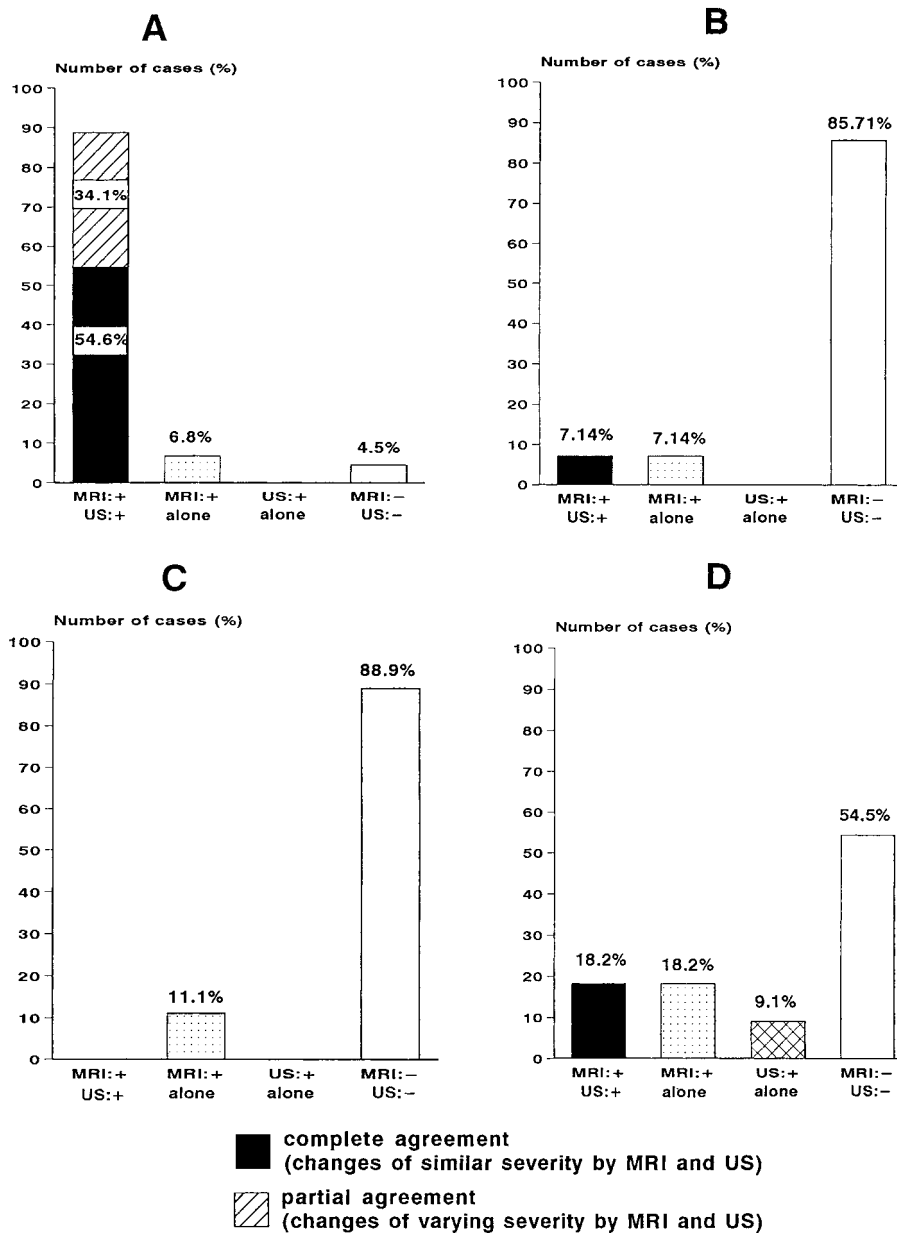


FIG. 3. Comparison of MRI and US results concerning the parenchymal pattern of the parotid glands in SS patients ($n = 44$; A) and in the control groups [C_1 : $n = 14$ healthy controls (B); C_2 : $n = 27$ patients with diabetes mellitus or hyperlipidaemia or chronic liver disease (C); and C_3 : $n = 11$ patients with sicca symptoms not fulfilling criteria for definite SS (D)].

must achieve a certain degree before they can be detected as macroscopic abnormalities by the imaging methods.

In our present prospective study, parotid gland changes were detected by both US and MRI in a high proportion of the SS patients, significantly more frequently than in the control groups. The diagnostic value of both imaging modalities proved to be good for SS patients *vs* healthy individuals (group C_1) and patients in group C_2 . However, the differential diagnostic value of these methods was slightly worse at distinguishing between SS patients and patients with sicca symptoms

not fulfilling the criteria for definite SS (group C_3). In the latter group, structural changes were more common than in the other control groups. This may be due to the possibility that some of these patients will later develop true SS. The results of the two imaging modalities were concordant in the majority of the subjects examined. As regards the MRI findings, we share the opinion of Takashima *et al.* [18] that diagnostic cautiousness is the appropriate radiological standpoint in the detection of a fine reticular pattern in the salivary glands, as such mild changes also occurred in our control

groups. In other words, a mild MRI abnormality (similar to a mild US abnormality) suggests only the possibility of SS.

Because of the increased risk of developing a lymphoma, primary SS patients need regular follow-ups. This must include careful examination of the salivary glands by palpation and a sensitive imaging method which can reveal any newly developed parenchymal change differing from the usual PIH. US, which can be performed repeatedly without any discomfort to the patients, is suited to imaging follow-up for most SS patients. In one of De Vita *et al.*'s [7] primary SS patients, a B cell lymphoma was revealed in the submandibular gland by the US pattern and the subsequent histological examination. On US, intraparotid lymphomatous nodes are large, usually very hypoechoic masses and occasionally so hypoechoic that they appear cystic. This appearance can be explained by the monotonous arrangement of the lymphoma cells, which provides very few acoustical interfaces to generate internal echoes [19]. While US examination can accurately visualize the parenchymal changes, including the solid masses in the superficial parotid lobe (80% of the gland), scanning of the deep lobe is difficult or impossible. CT or MRI may be needed if palpation suggests a deep circumscribed lesion, but US does not offer decisive information [15, 17, 19]. MRI is regarded as the best imaging technique for the detection of intraparotid tumours [10]. The lymphomas have a homogeneous signal pattern with low intensity in the T1-weighted and high intensity in the T2-weighted sequences. Although this MRI pattern is highly suggestive of lymphoma, there is no absolute correlation between the imaging morphology and the histology of the lesion. Grevers *et al.* [13] reported on four SS patients with MRI patterns consistent with a lymphoma, but lymphoma was confirmed histologically in only three of the four patients. In the fourth patient, a benign extensive lymphocytic infiltration and parenchymal atrophy were found. This shows that an early lymphoma and a localized benign lymphoid infiltration with severe glandular atrophy can give a very similar MRI pattern. It is likely that, with increasing (benign or malignant) lymphocytic infiltration of the glands, the typical nodular MRI picture seen in SS will change into a homogeneous pattern which can involve the parenchyma partially or entirely. In one of our SS patients with enlarged nodular parotids, the US examination showed an unusually large, ill-defined, solid, hypoechoic area with a 'cobblestones'-like non-homogeneous internal pattern in the parotid which raised the possibility of a lymphoma. This US picture was coupled with an almost homogeneous, fine reticular MRI pattern. Both US and MRI changes were caused by a monotonous arrangement of the lymphoid cells, which proved to be lymphoma cells histologically. Although this was the only parotid lymphoma case in our study, we think that such a combination of US and MRI findings is highly characteristic of lymphoma. In spite of this, our experience and the literature data suggest that none of the imaging methods is able to give

a histological diagnosis with absolute certainty if the possibility of a malignant transformation arises.

To summarize, some conclusions may be drawn. US and MRI are equally sensitive tools for the diagnosis of salivary involvement in SS patients. As there was good agreement between the MRI and US findings, in US-positive cases MRI seems unnecessary as a routinely applied diagnostic method. Of the MRI stage categories, the medium and coarsely nodular patterns are highly supportive findings for the diagnosis of SS, but the milder MRI changes can also occur in diseases other than SS and even in healthy persons. During the regular follow-up of SS patients, we must rely primarily on careful physical and US examination of the salivary glands. However, if both or even one of these examinations suggests the possibility of a malignant transformation, MRI must be performed.

References

1. Moutsopoulos HM. Sjögren's syndrome. In: Schumacher HR, ed. Primer on the rheumatic diseases, 10th edn. Atlanta, GA: Arthritis Foundation, 1993:131-5.
2. Fox RI. Sjögren's syndrome. In: Kelley WN, Harris ED, Ruddy S, Sledge CB, eds. Textbook of rheumatology, 5th edn. Philadelphia: WB Saunders Co., 1997:955-68.
3. Vitali C, Moutsopoulos HM, Bombardieri S, European Community Study Group on Diagnostic Criteria for Sjögren's Syndrome. The European Community Study Group on Diagnostic Criteria for Sjögren's Syndrome. Sensitivity and specificity of tests for ocular and oral involvement in Sjögren's syndrome. *Ann Rheum Dis* 1994;53:637-47.
4. Vitali C, Monti P, Giuggioli C *et al.* Parotid sialography and lip biopsy in the evaluation of oral component in Sjögren's syndrome. *Clin Exp Rheumatol* 1989;7:131-5.
5. Scully C. Oral parameters in the diagnosis of Sjögren's Syndrome. *Clin Exp Rheumatol* 1989;7:113-7.
6. Schiødt M, Thorn J. Criteria for the salivary component of Sjögren's syndrome. *Clin Exp Rheumatol* 1989;7:119-22.
7. De Vita S, Lorenzon G, Rossi G, Sabella M, Fossaluzza V. Salivary gland echography in primary and secondary Sjögren's syndrome. *Clin Exp Rheumatol* 1992;10:351-6.
8. Makula É, Pokorny G, Rajtár M *et al.* Parotid gland ultrasonography as a diagnostic tool in primary Sjögren's syndrome. *Br J Rheumatol* 1996;35:972-7.
9. Szolar DH, Groell R, Braun H *et al.* Ultrafast computed tomography and three-dimensional image processing of CT sialography in patients with parotid masses poorly defined by magnetic resonance imaging. *Acta Otolaryngol (Stockh)* 1996;116:112-8.
10. Späth M, Krüger K, Dresel S, Grevers G, Vogl T, Schattenkirchner M. Magnetic resonance imaging of the parotid gland in patients with Sjögren's syndrome. *J Rheumatol* 1991;18:1372-8.
11. Valesini G, Gualdi GF, Priori R *et al.* Magnetic resonance imaging of the parotid glands and lip biopsy in the evaluation of xerostomia in Sjögren's syndrome. *Scand J Rheumatol* 1994;23:103-6.
12. Vitali C, Bombardieri S, Moutsopoulos HM *et al.* Preliminary criteria for the classification of Sjögren's syndrome. Result of a prospective concerted action sup-

- ported by the European Community. *Arthritis Rheum* 1993;36:340–7.
13. Grevers G, Ihrler S, Vogl TJ, Weiss M. A comparison of clinical, pathological and radiological findings with magnetic resonance imaging studies of lymphomas in patients with Sjögren's syndrome. *Eur Arch Otorhinolaryngol* 1994;251:214–7.
 14. Mandelblatt SM, Braun IF, Davis PC, Fry SM, Jacobs LH, Hoffman JC. Parotid masses: MR imaging. *Radiology* 1987;163:411–4.
 15. Traxler M, Hajek P, Solar P, Ulm C. Magnetic resonance in lesions of the parotid gland. *Int J Oral Maxillofac Surg* 1991;20:170–4.
 16. Izumi M, Eguchi K, Ohki M *et al.* MR imaging of the parotid gland in Sjögren's syndrome: a proposal for new diagnostic criteria. *Am J Roentgenol* 1996;166:1483–7.
 17. Ariyoshi Y, Shimahara M. Determining whether a parotid tumor is in the superficial or deep lobe using magnetic resonance imaging. *J Oral Maxillofac Surg* 1998;56:23–6.
 18. Takashima S, Takeuchi N, Morimoto S *et al.* MR imaging of Sjögren syndrome: correlation with sialography and pathology. *J Comput Assist Tomogr* 1991;15:393–400.
 19. Alexander AA. The thyroid, the parathyroid, the salivary glands and the cervical lymph nodes In: Goldberg B, Pettersson H, eds. *The NICER Year Book 1996: Ultrasonography, Series on diagnostic imaging from the NICER Institute, Oslo, Norway*, 1996:399–449.