

# The Protective Role of Vitamin C Against Cerebral and Pulmonary Damage Induced by Cadmium Chloride in Male Adult Albino Rat

Gamal H. El-Sokkary\*<sup>1</sup> and Eatemad A. Awadalla<sup>2</sup>

<sup>1</sup>Department of Zoology, Faculty of Science, Assiut University, 71516 Assiut-Egypt; <sup>2</sup>Department of Zoology, Aswan Faculty of Science, South Valley University, Aswan-Egypt

**Abstract:** This study was designed to examine the protective role of vitamin C (VC) against oxidative stress and morphological changes induced by chronic exposure to cadmium chloride (CdCl<sub>2</sub>) in the lungs and brain. Male adult rats received CdCl<sub>2</sub> (5 mg/kg body weight) daily for forty days. Vitamin C (VC) at a dose of 100 mg/kg body weight was given concomitantly with CdCl<sub>2</sub> to the rats. Three animal groups were used in this experiment (control, CdCl<sub>2</sub> and CdCl<sub>2</sub>+VC). The concentration of malondialdehyde (MDA), activity of superoxide dismutase (SOD) enzyme and concentration of glutathione (GSH) were measured in the lung and brain homogenates. Also, histopathological investigations were carried out in lung and brain tissues. CdCl<sub>2</sub> administration significantly increased the levels of MDA and decreased the activity of SOD and GSH concentration in the lungs and brain versus those of control rats. Administration of vitamin C counteract the changes of all measured parameters and appear nearly like those of controls. Light microscopy revealed marked changes in the structure of the studied tissues of CdCl<sub>2</sub> administered animals. Again, vitamin C restored the damage of tissues associated with CdCl<sub>2</sub> administration. The present results suggest that vitamin C administration attenuated the oxidative damage and morphological changes induced by CdCl<sub>2</sub> in the lungs and brain of rats.

**Keywords:** Cadmium, vitamin C, brain, lungs, lipid peroxidation, superoxide dismutase, glutathione.

## 1. INTRODUCTION

Cadmium (Cd) is a highly toxic element that is naturally present in all parts of the environment, including food, water, and soil [1]. It is extracted during the production of other metals, such as zinc, lead and copper and it is used in industrial and household products, mainly in batteries, pigments, metal coatings, plastics and some metal alloys [2,3]. The main source of toxic exposure of cadmium is by the inhalation route of cadmium particles or fumes during industrial operations [4,5]. It is also present in cigarette smoke, representing a significant source of exposure [6].

Cadmium accumulates and proves to cause severe damage to a variety of organs such as lung, brain, testis, kidney, liver, blood system and bone [7-9]. Pneumonitis, pulmonary emphysema, interstitial fibrosis together with cancer are a frequent response to cadmium exposure [10,11]. Because of its characteristics as a lung carcinogen, cadmium has been classified as a category 1 carcinogen (human carcinogen) by the International Agency for Research on Cancer and the National Toxicology Program of the USA [12].

Acute inhalation of sufficient exposure of cadmium can cause both a chemical pneumonitis and pulmonary edema from the toxic effect to the alveolar epithelium and endothelium [13]. Within 24 h of exposure, workers develop

shortness of breath, fever, and fatigue, which can progress to pulmonary edema and death [14]. Chronic exposure to cadmium dusts and fumes has been suspected as a cause of emphysema, obstructive lung disease, pulmonary fibrosis, and lung cancer.

Exposure of adult rats to low or moderate doses of Cd induced lipid peroxidation (LPO) in all tissues, mainly lung and brain [7]. Monroe and Halvorsen [15] provided evidence that CdCl<sub>2</sub> increases oxidative stress in nervous cells. The brain is particularly sensitive to oxidative damage because of its high rate of oxidative metabolism [16]. Cd also enhances the production of free radicals in the brain of adult rats and interferes with the antioxidant defense system that in turn leads to a Cd-induced alteration of the structural integrity of lipids [17]. In adult rats co-exposed to Cd, there was an increase of LPO in the corpus striatum and cerebral cortex [18]. Cd also induces a significant increase of free radicals production and LPO in brain of developing rats [19].

Cd(II) accumulates and is toxic in many organs, including kidneys, lungs and testis [20,21]. Nishimura *et al.* [22] reported that Cd(II) can enter into the brain parenchyma and neurons and causes neurological alterations in humans [23] and animal models [24], leading to lower attention, hypernociception, olfactory dysfunction and memory deficits. Moreover, Cd induced cerebral hemorrhage and cerebral edema in neonatal rats [25]. In experimental studies with animals, cadmium is able to induce neurotoxicity with a wide spectrum of clinical entities including neurological disturbance [26], changes in the normal neurochemistry of the brain [27].

\*Address correspondence to this author at the Department of Zoology, Faculty, of Science, Assiut University, 71516 Assiut-Egypt; Tel: ++ 088-2401724; Fax: ++ 088-2342708; E-mail: Elsokkary2000@yahoo.com

Several authors have shown that antioxidants should be one of the important components of an effective treatment of cadmium poisoning [28-30]. Accordingly, to prevent undesired oxidative damage induced by reactive species, organisms are equipped with several lines of antioxidant defense. Vitamin C is an aqueous phase antioxidant has been established for many decades and has several important roles. It modulates intracellular redox status through maintaining sulphhydryl compounds, including glutathione, in their reduced state. It has been suggested to repair protein hydroperoxides, through regeneration of parent amino acids by reduction. Also, it serves to maintain membrane alpha tocopherol and enzyme activities including hepatic mixed function oxidase activity [31]. Ascorbic acid, after being converted to dehydroascorbic acid by free radical reactions, is regenerated via the glutathione enzyme complex [32]. Gupta and Kar [33] reported that vitamin C can prevent increased lipid peroxidation levels resulting from cadmium toxicity. Vitamin C could serve as an effective antioxidant against restraint stress induced pro-oxidant status and increase the antioxidant enzyme activity in rat brain [34] and liver [35].

The present study has implicated the importance of antioxidants such as vitamin C in protecting living organism against the toxic effect of cadmium exposure.

## 2. MATERIALS AND METHODS

### 2.1. Experimental Animals

Thirty adult male Sprague-Dawley rats weighting 100-120 g were used in the present work. The animals were purchased from Aboroash Joint Animal Breeding Unit. The animals were kept in a controlled light room with a photoperiod of 12 hours dark and 12 hours light (dark light cycle 12:12) at a temperature of  $28 \pm 2$  °C. All animals were given free access to standard laboratory chow and tap water.

### 2.2. Chemicals

Cadmium chloride ( $\text{CdCl}_2$ , 99% pure) was purchased from Aldrich Chemical Co. Cadmium chloride was dissolved in saline solution (0.9% NaCl). Ascorbic acid, dimethyl sulfoxide, Sodium dodecyl sulphate (SDS), Thiobarbituric acid (TBA) and epinephrine were purchased from Sigma Chemical Co. (St. Louis, MO, USA). Ascorbic acid (Vitamin C) was dissolved in distilled water. All other chemicals were of the highest purity commercially available.

### 2.3. Experimental Design:

The rats were randomly divided into three groups, 10 rats each:

- **The first group:** designated Cd, was injected subcutaneously with cadmium chloride at a dose of 5 mg/kg body weight.
- **The second group:** designated Cd + VC, was injected subcutaneously with vitamin C at a dose of 100 mg/kg body weight. The administration of vitamin C was 30 min. before Cd injection and was given at 8 a.m.
- **The third group:** served as controls and the rats were injected with vehicles only.
- All the above injections were repeated daily for 40 days.

### 2.4. Tissue Preparations

The specimens from the selected organs (lungs and brain) were rapidly excised, and cut conveniently into small pieces, which were used for histology and histopathology. Another portions of the studied organs were frozen at  $-40$  °C for measurement of lipid peroxidation (LPO) which is an oxidative stress indicator.

### 2.5. Measurement of Lipid Peroxidation

The method of measurement of oxidized lipids was based on that of Ohkawa *et al.* [36] using 1,1,3,3-tetramethoxypropane as standard. A 10 (w/v) tissue homogenate from brain and lungs required for this assay (this homogenate contained 1% v/v dimethyl sulfoxide to prevent further oxidation). To 0.2 ml aliquots of tissue homogenate was added 0.2 ml 8.1 % w/v sodium dodecyl sulfate solution, 1.5 ml 20% v/v acetic acid solution (PH 3.5) and 1.5 ml 0.8% w/v thiobarbituric acid solution. The mixture was made up to 4.0 ml with distilled water and heated to 95 °C for 1 h. The samples were cooled and centrifuged at 2000 xg for 10 min and absorbance measured at 532 nm. Results were expressed as n mol malondialdehyde formation per g tissue.

### 2.6. Superoxide Dismutase (SOD) Activity

SOD activity was determined at room temperature according to the method of Misra and Fridovich [37]. Ten microlitres of tissue extract was added to 970 ml (0.05 M, pH 10.2, 0.1 mM EDTA) sodium carbonate buffer. Twenty microlitres of 30 mM epinephrine (dissolved in 0.05% acetic acid) was added to the mixture to start the reaction. SOD was measured at 480 nm for 4 min. Activity was expressed as the amount of enzyme that inhibits the oxidation of epinephrine by 50%, which is equal to 1 unit, per mg protein.

### 2.7. Measurement of Glutathione (GSH) Concentration

GSH content was measured by a modification of the method of Beutler *et al.* [38]. Briefly, 500  $\mu\text{l}$  of tissue extract was added to 2.0 ml of 0.2 M phosphate buffer and 0.25 ml 0.04% 5,5'-dithio-bis 2-nitrobenzoic acid. Absorbance was read at 410 nm. GSH content was expressed as nanomoles of GSH per mg of protein. Protein concentrations were measured by the method of Bradford [39] using bovine albumin as standard..

### 2.8. Histological and Histopathological Examinations

For the histological and histopathological examinations, pieces of the organs were fixed in 10% of neutral buffered formalin (pH 7.2), dehydrated in ascending series of ethanol, cleared in methyl benzoate and embedded in paraffin wax. Paraffin sections of 5 microns in thickness were prepared and stained with Harris's haematoxylin and eosin [40].

### 2.9. Statistical Analysis

Results of LPO were expressed as means  $\pm$  S.E.M Differences between means were tested by the ANOVA followed by the Student-Newman-Keuls t-test. The percent of stimulation (S%) or inhibition (I%) in the mean values of LPO was calculated.

### 3. RESULTS

Quantitative results of cadmium oxidative stress induction in the lungs and brain of control and different treated animal groups were presented in Tables 1 and 2. As shown, administration of cadmium significantly increased ( $P<0.01$ ) LPO levels (as indicated by the increase in malondialdehyde [MDA] levels) in the homogenates of the lungs and brain versus those of control rats by 53.6% and 68.8%, respectively. When vitamin C was given (30 minutes before cadmium) to cadmium-administered rats, it significantly inhibited ( $P<0.01$ ) the increase of MDA by 47.4% and 45.8% in the lungs and brain, respectively.

The activity of SOD was severely inhibited ( $P<0.01$ ) in the lungs and brain homogenates of cadmium-administered animals versus those of controls. The cadmium-induced inhibition of SOD activity was 38.6% and 48.2% in the lungs and brain, respectively. The administration of vitamin C to rats which given cadmium markedly stimulated ( $P<0.01$ ) the activity of SOD by 33.6% and 32.9% in both the lungs and brain.

Cadmium administration to the rats reduced total GSH concentrations ( $P<0.01$ ) in the lungs and brain compared to those of controls by 51.5% and 49.4%, respectively. In contrast, vitamin C administration to cadmium-administered rats markedly restored (34.8% and 31.6%) the concentrations of GSH ( $P<0.01$ ) in the lungs and brain, respectively.

Histopathological examination revealed marked

destruction of both lungs and brain tissues. In the lungs, administration of Cd induced severe changes (Fig. 1B) versus those of controls (Fig. 1A). The changes include thickened-walled alveoli and alveolar septa, infiltration of a huge number of inflammatory cells and exudation in many places as shown in Fig. (1B). When vitamin C was given to Cd-administered rats, it restored these changes and the lung tissue appear nearly like those of control rats as shown in Fig. (1C). In the brain, Cd induced massive damage in the hippocampus and cerebral cortex (Figs. 2B and 3B) versus those of control animals (Figs. 2A and 3A) respectively. The most obvious changes are cellular atrophy, shrinkage, cellular necrosis, pyknosis, deeply stained and dark nuclei as shown in Figs. (2B) and (3B). Again, vitamin C administered-rats exhibited more or less normal neurons in both hippocampus and cerebral cortex compared with those of Cd-group (Figs. 2C and 3C).

### 4. DISCUSSION

Cadmium (Cd) is known to produce a variety of health hazards in humans and experimental animals due to its ability to induce severe alterations in various organs and tissues including the nervous system, following either acute or chronic exposure [7]. Inhalation of Cd can cause pulmonary emphysema, fibrosis, and lung carcinomas in human and experimental models [41]. It promotes an early oxidative stress and afterward contributes to the development of serious pathological conditions [42]. The mechanism by which cadmium causes toxicity is far from

**Table 1. Mean Values ± S.E.M of Lipid Peroxidation Product (MDA), Superoxide Dismutase (SOD), Glutathione (GSH) and Inhibition (I) and/or Stimulation (S) % in the Lungs Homogenates of Control and Different Treated Groups of Rats**

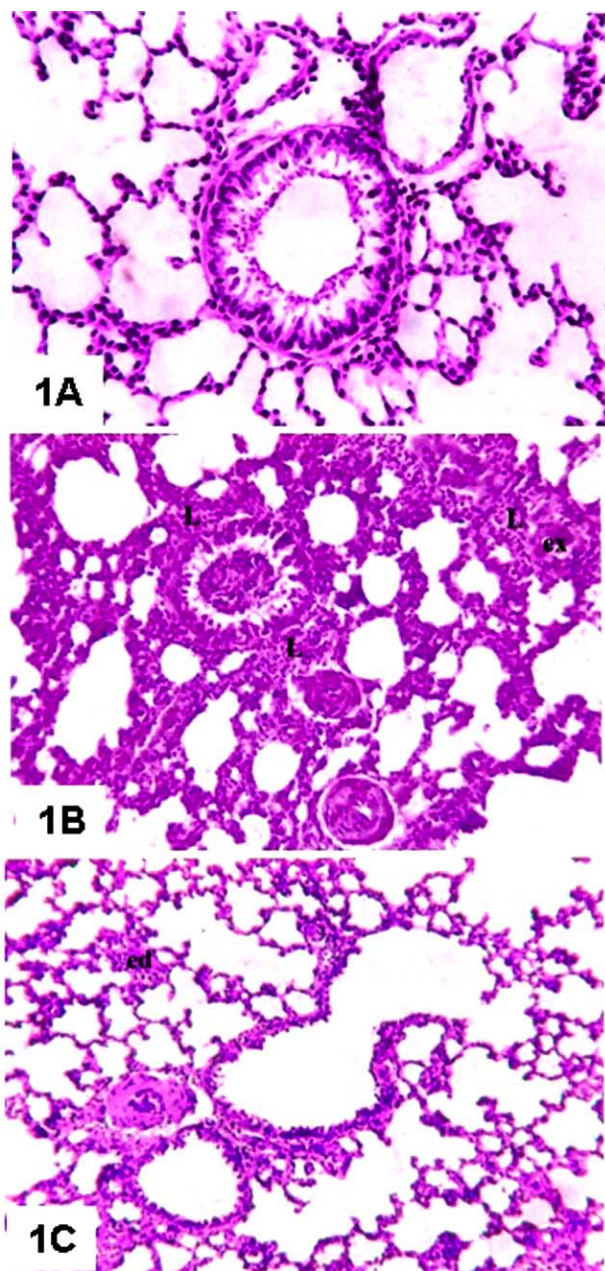
<i>Measurements</i> Groups	MDA (nmol/g Tissue)	SOD (Units/mg Protein)	GSH µgm/mg Protein
Control (n=10)	3.747 ± 0.172 <sup>a</sup>	1.162 ± 0.067 <sup>a</sup>	0.0181 ± 0.0007 <sup>a</sup>
Cadmium (n=10)	8.079 ± 0.475 <sup>b</sup>	0.714 ± 0.034 <sup>b</sup>	0.0088 ± 0.0004 <sup>b</sup>
I or S% vs control	S= 53.6	I= 38.6	I= 51.5
Cd+Vitamin C (n=10)	4.247 ± 0.323 <sup>ac</sup>	1.075 ± 0.053 <sup>c</sup>	0.0135 ± 0.0004 <sup>c</sup>
I or S% vs Cd	I= 47.4	S= 33.6	S= 34.8

S.E.M: standard error of the mean. Values in the same columns with unlike superscript letters significantly differ.

**Table 2. Mean Values ± S.E.M of Lipid Peroxidation Product (MDA), Superoxide Dismutase (SOD), Glutathione (GSH) and Inhibition (I) and/or Stimulation (S) % in the Brain Homogenates of Control and Different Treated Groups of Rats**

<i>Measurements</i> Groups	MDA (nmol/g Tissue)	SOD (Units/mg Protein)	GSH µgm/mg Protein
Control (n=10)	1.984 ± 0.161 <sup>a</sup>	1.995 ± 0.057 <sup>a</sup>	0.0214 ± 0.0001 <sup>a</sup>
Cadmium (n=10)	6.233 ± 0.534 <sup>b</sup>	1.033 ± 0.046 <sup>b</sup>	0.0108 ± 0.0005 <sup>b</sup>
I or S% vs control	S= 68.8	I= 48.2	I= 49.4
Cd+Vitamin C (n=10)	3.377 ± 0.488 <sup>ac</sup>	1.539 ± 0.062 <sup>c</sup>	0.0158 ± 0.0014 <sup>c</sup>
I or S% vs Cd	I= 45.8	S= 32.9	S= 31.6

S.E.M: standard error of the mean. Values in the same columns with unlike superscript letters significantly differ.



**Fig. (1).** (A) Lung section of a control rat showing sponge-like appearance of the bronchial tree and normal respiratory tissue. (H&E X 400). (B) Lung section of Cd-administered rat displaying marked thickness of the alveolar septa, infiltration of inflammatory cells (L) and some exudation (ex). (H&E X 400). (C) Lung section of VC+Cd-treated rat showing nearly normal architecture of the respiratory tissue with edema (ed) in some regions. (H&E X 400).

being completely understood, although lipid peroxidation (LPO) has long been considered to be the primary mechanism for cadmium toxicity [7]. Among the various effects induced by Cd in biological systems, the oxidative destruction of membrane polyunsaturated fatty acids, a phenomenon termed LPO, has been observed in numerous tissues both *in vitro* and *in vivo* [43]. The oxidative stress which contributes to the pathogenesis of cadmium toxicity is the consequence of either enhanced ROS production or

attenuated ROS scavenging capacity resulting in tissue damage that is most easily assessed by measuring lipid peroxide levels [44,45].

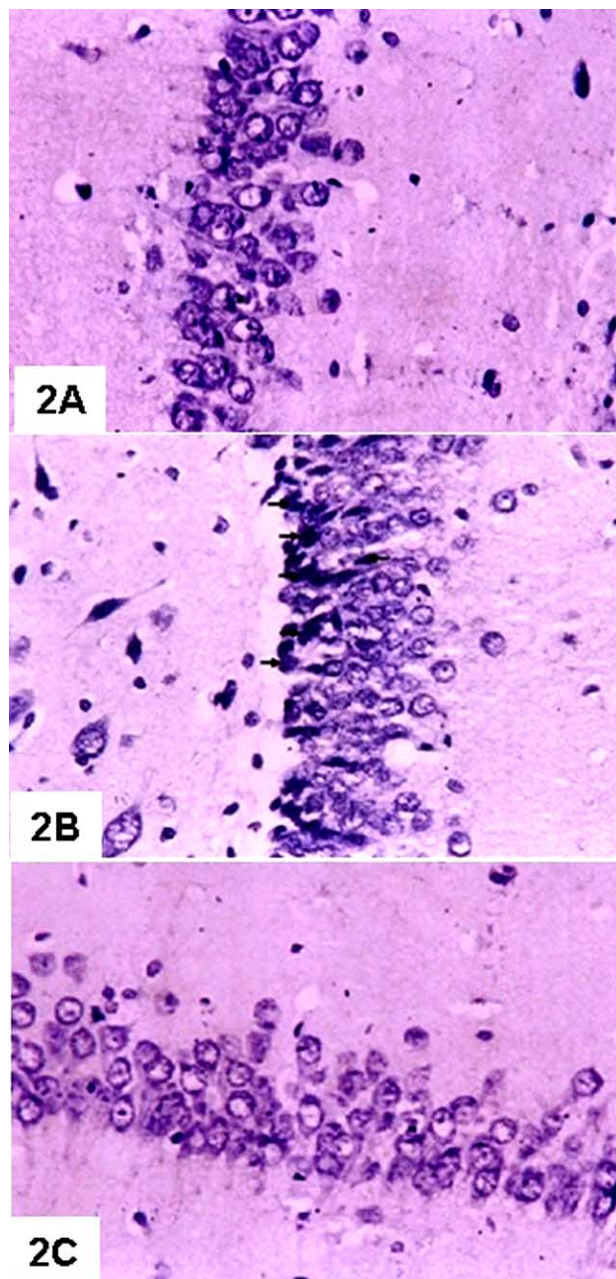
In the present study, we found a significant increase in the levels of LPO and a significant decrease in both SOD activity and GSH concentration in the lungs and brain of cadmium-exposed rats compared to those of controls. Our results are in harmony with those of Luchese *et al.* [10] and El-Sokkary *et al.* [29,30] who found that cadmium induced oxidative damage which had been demonstrated by the previous parameters. Furthermore, several studies demonstrated that, LPO may be one of the important events responsible for pulmonary and cerebral toxicity of Cd [7,8]. The lung, because of its interface with the environment, is a major target organ for injury by exogenous oxidants such as environmental pollutants, cigarette smoke, drugs, chemotherapeutic agents and hyperoxia, as well as by endogenous ROS generated by inflammatory cells. Yang *et al.* [46] reported that Cd is able to cause oxidative cellular damage in lung fibroblasts, manifested by lipid peroxidation, elevated level of ROS formation, and mitochondrial membrane damage, which eventually leads to irreversible cell injury.

Stohs and Bagchi [47] demonstrated that cadmium is a potent cell poison and its toxicity was mediated by the oxidative damage of essential cellular macromolecules. Other reports demonstrate that Cd induces oxidative stress in blood and tissues by increasing lipid peroxidation and by altering the antioxidant status [48,49]. The brain, off all the organs, is thought to be vulnerable to oxidative damage due to its high oxygen consumption, presence of high concentrations of polyunsaturated fatty acids and nondegenerative nature of neurons, which may lead to various neurodegenerative diseases [50,51].

It has been proposed that Cd may initiate oxidative stress through the following two pathways: 1) depletion antioxidant enzymes [28,52] and 2) enhancing production of reactive oxygen species, both *in vitro* and *in vivo* [53,54].

The morphological investigations of the current study revealed different changes in the lungs and brain. Lung lesions are consisting of vascular severe inflammation in both alveoli and bronchioles with edema and congestion. These pathological changes are in agreement with the findings of Shin *et al.* [55] who reported that the lung is a primary target organ of systemic exposure to cadmium. Because cadmium is mainly absorbed through the inhalation of industrial pollution and tobacco smoke, the result is the accumulation of this metal in the lung. Also, Yamada *et al.* [56] noticed a dramatic increase in the number of alveolar neutrophilic leukocytes 6-48 h after intra-bronchial instillation of 1 mg cadmium chloride into lungs of dogs. Bell *et al.* [57] reported that Cd exposure was deleterious to the lung tissue causing mild to severe inflammation in the lung. However, inhalation of Cd has been implicated in the development of emphysema and pulmonary fibrosis [58]. Mckenna *et al.* [5] reported that Cd-exposed lungs showed acute and more chronic pulmonary inflammation in both rats and mice with bronchiolar and alveolar lesions.

Administration of Cd induced morphopathological changes in the brain involved different types of neurons in



**Fig. (2).** (A) T. S of brain of a control rat showing granular layer of the hippocampus with normal neurons. The nuclei are vesicular. (H&E X 400). (B) T. S of brain of Cd-treated rat showing granular layer of the hippocampus with predominantly shrinkage, pyknotic and deeply-stained neurons (arrows). (H&E X 400). (C) T. S of brain of VC+Cd-treated rat showing granular layer of the hippocampus with normal appearance of the majority of neurons. (H&E X 400).

the examined regions (hippocampus and cerebral cortex). The neurons undergo either degenerative or apoptotic changes. The degenerative changes manifested by shrinkage and deeply stained neurons in both studied regions. These observations in harmony with experimental studies in the CNS of newborn rats and rabbits exposed to high doses of Cd, which showed extensive hemorrhage in the cerebral and

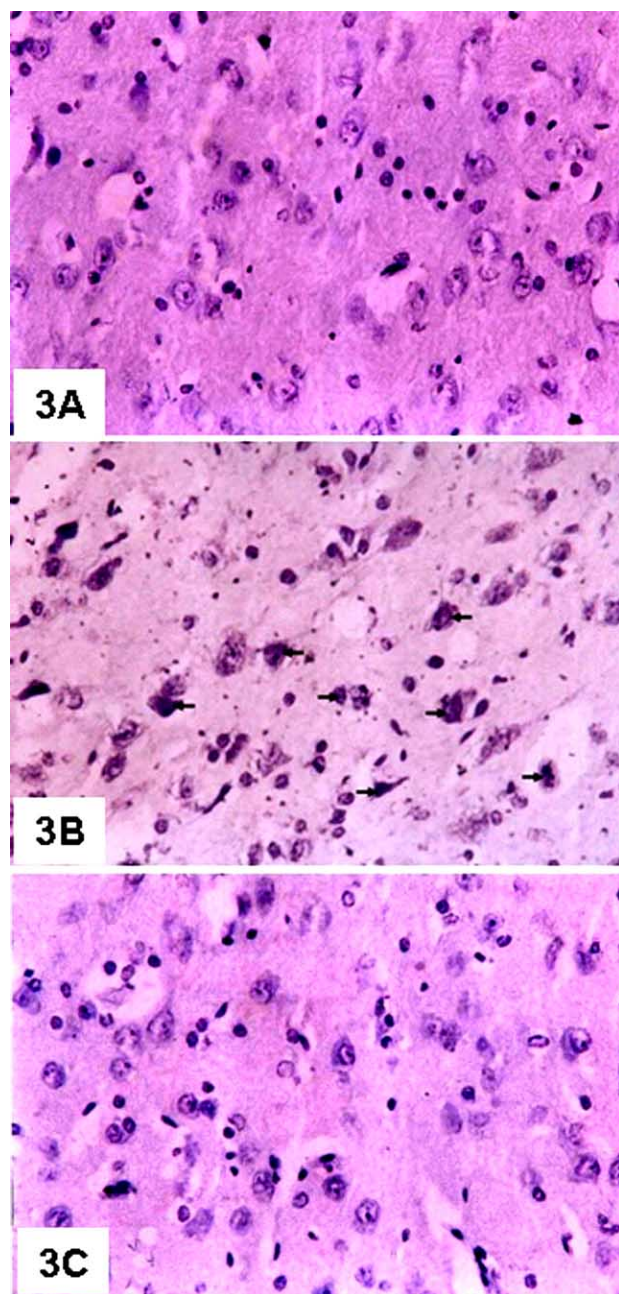
cerebellar cortices, several pyramidal cells with pyknotic nuclei, neuroglial cells with cytolysis and altered purkinje cells [59,60]. It was reported that Cd has distinct neurotoxic effects in adults and newborn animals. In adult rats, high doses of Cd produce damage to the Gasserian and sensory spinal ganglia, but in newborn rats, high doses of Cd produce severe hemorrhagic lesions in cerebrum and cerebellum [59]. Also, Cd is a highly toxic metal; in particular, it was reported to produce neuropathological and neurochemical alterations in the central nervous system resulting in irritability and hyperactivity [61].

The necrotic and degenerative changes of brain may be attributed to the high susceptibility of rats to Cd toxicity and it was considered an important indication for neuro-toxic effect of Cd due to oxidative stress induction. This interpretation is confirmed by Williams [62] who reported that oxidative stress is one of the mechanisms that contribute to structural changes and it plays an important role in neuro-degeneration.

Recent experiments have implicated the importance of antioxidant such as vitamins in protecting living organism against the toxic effects of environmental chemicals [63]. Free radical scavengers and antioxidants, such as glutathione, vitamin E, vitamin C are capable of protecting against Cd toxicity [64]. Vitamin C is an important dietary antioxidant and in the general absence of metal ion-catalyzed reactions, it is qualitatively the single most important plasma antioxidant. Thus vitamin C has been used as a choice of antioxidants *in vitro* [65]. It has been known to protect all classes of lipids from oxidation under a number of relevant types of oxidant stress while other non- enzymatic antioxidants such as vitamin A, Vitamin E, glutathione, bilirubin, and urate merely lower the rate of oxidation or act in a more restricted [66]. Vitamin C is an important dietary antioxidant and significantly decreases the adverse effect of reactive species such as reactive oxygen that can cause oxidative damage to macromolecules such as lipids, DNA and proteins which are implicated in several diseases [67].

In the present investigation, vitamin C maintained the levels of LPO, SOD activity and GSH concentration produced in the lungs and brain nearly at control values. Accordingly, vitamin C inhibited the increase of LPO levels (by 47.4 % and 45.8%) in both lungs and brain at respectively and this inhibition was significant ( $p < 0.05$ ). The inhibiting effect of vitamin C on lipid peroxidation resulting from cadmium toxicity corresponds well to the finding of Gupta and Kar [33] and Gupta *et al.* [68] who proposed that Vitamin C supplementation helped to reduce MDA levels and at the same time increased the activity of antioxidant enzymes such as superoxide dismutase and glutathione peroxide in Cd-exposed rats. Also, Halliwell *et al.* [32] reported that vitamin C scavenges the aqueous ROS by very rapid electron transfer that inhibit LPO. In addition, studies of Rodriguez-Martinez *et al.* [69] and Muthuvel *et al.* [50] revealed that vitamin C acts against oxidative stress in central nervous system

In the current study, vitamin C markedly reduced the histopathological changes induced by cadmium chloride in both lungs and brain (hippocampus and cerebral cortex) which had normal appearance on examination. These observations are in agreement with Oski [70] who recorded



**Fig. (3).** (A) T. S of brain of a control rat showing the cerebral cortex with normal neurons. (H&E X 400). (B) T. S of brain of Cd-treated rat showing the cerebral cortex with predominantly shrinkage, pyknotic, necrosed and deeply-stained neurons (arrows). (H&E X 400). (C) T. S of brain of VC+Cd-treated rat showing the cerebral cortex with normal appearance of the majority of neurons. (H&E X 400).

that highly unstable free radicals attack the polyunsaturated fatty acids of membrane phospholipids, and can damage both the structure and function of cell membranes in a chain reaction unless they are quenched by an antioxidant. Administration of a moderately large dose of vitamin C almost completely prevents protein damage, apoptosis and the lung injury [71]. Moreover, population surveys have linked a low dietary intake of vitamin C with worse lung function [72]. In addition, antioxidants have therapeutic

importance in neurological disorders where oxidative stress is involved [73]. The antioxidant potential of ascorbic acid is not only attributed to its ability to quench reactive oxygen species, but also to its ability to generate other small molecule antioxidants, such as  $\alpha$  tocopherol, glutathione and B-carotene [74].

In conclusion, the results of the current study suggest that vitamin C is useful and effective antioxidant against the toxicity induced by CdCl<sub>2</sub> in lungs and brain of rats. Thus vitamin C can be used in co-treatment of cadmium poisoning, since it has the capability to alleviate many of the harmful effects of cadmium.

#### REFERENCES:

- [1] Sherlock JC. Cadmium in foods and the diet. *Experientia* 1984; 40: 152-56.
- [2] Page AL, Al-Amamy, MM, Chang AC. Cadmium: Cadmium in the environment and its entry into terrestrial food chain crops. Springer-Verlag, Berlin: Heideberg, New York; 1986; pp. 33-74.
- [3] Hart BA. Response of the respiratory tract to cadmium. In: Zalpus. RK, Koropatnick J, Eds. *Molecular Biology and toxicology of metals*. London. UK: Taylor and Francis 2000; pp 208-33.
- [4] Office of Environmental Health Hazard Assessment (OEHA). Public health goal for cadmium in drinking water, February 1999.
- [5] Mckenna IM, Waalkes MP, Chen LC, Grdn T. Comparison of inflammatory lung responses in Wister rats and C57 and DBA mice following acute exposure to cadmium oxide fumes. *Toxicol Appl Pharmacol* 1997; 146: 196-206.
- [6] Stohs SJ, Bagchi D, Bagchi M. Toxicity of trace element in tobacco smoke. *Inhal Toxicol* 1997; 9: 867-90.
- [7] Manca D, Ricard AC, Trottier B, Chevalier G. Studies on lipid peroxidation in rat tissues following administration of low and moderate doses of cadmium chloride. *Toxicology* 1991; 67: 303-23.
- [8] Manca D, Ricard AC, Tra HV, Chevalier G. Relation between lipid peroxidation and inflammation in the pulmonary toxicity of cadmium. *Arch Toxicol* 1994; 68: 364-69.
- [9] Ercal N, Gurer-Orhan H, Aykin-Burns N. Toxic metals and oxidative stress. Part 1. Mechanisms involved in metal-induced oxidative damage. *Curr Top Med Chem* 2001; 1: 529-39.
- [10] Luchese C, Brandao R, de Oliveira R, Nogueira WC, Santos WC. Efficacy of diphenyl diselenide against cerebral and pulmonary damage induced by cadmium in mice. *Toxicol Lett* 2007; 173: 181-90.
- [11] Luchese C, Pinton S, Nogueira WC. Brain and lungs of rats are differently affected by cigarette smoke exposure: antioxidant effect of an organoselenium compound. *Pharmacol Res* 2009; 59: 194-201.
- [12] Waisberg M, Joseph P, Hale B, Beyersmann D. Molecular and cellular mechanisms of cadmium carcinogenesis. *Toxicology* 2003; 192: 95-117.
- [13] Newman L, Metals. Occupational and Environmental Respiratory Disease, 1st ed. In: Harber P, Schenker MB, Balmes J, Eds. MO: Mosby St. Louis 1996; pp. 469-513.
- [14] Fernandez MA, Sanz P, Palomar M, Serra J, Gadea E. Fatal chemical pneumonitis due to cadmium fumes. *Occup Med* 1996; 46: 372-74.
- [15] Monroe KR, Halvorsen WS. Cadmium blocks receptor-mediated Jak/STAT signaling in neurons by oxidative stress. *Free Radic Biol Med* 2006; 41: 493-502.
- [16] Pajovic SB, Saicic ZS, Sasic MB, Petrovic MB. The effect of ovarian hormones on antioxidant enzyme activities in the brain of male rats. *Physiol Rev* 2003; 52: 189-94.
- [17] Shukla A, Shukla SG, Srimal RC. Cadmium induced alterations in blood-brain barrier permeability and its possible correlation with decreased microvessel antioxidant potential in rat. *Hum Exp Toxicol* 1996; 15: 400-5.
- [18] Pal R, Nath R, Gill DK. Influence of ethanol on cadmium accumulation and its impact on lipid peroxidation and membrane bound functional enzymes (Na<sup>+</sup>, K<sup>+</sup>, ATPase and acetylcholinesterase) in various regions of adult rat brain. *Neurochem Int* 1993; 23: 451-58.

- [19] Méndez-Armenta M, Villeda-Hernandez J, Barroso-Moguel R, Nava-Ruiz C, Jimenez-Cadeville ME, Rios C. Brain regional lipid peroxidation and metallothionein levels of developing rats exposed to cadmium and dexamethasone. *Toxicol Lett* 2003; 144: 151-57.
- [20] López E, Arce C, Oset-Gasque MJ, Canadas S, Gonzalez MP. Cadmium induces reactive oxygen species generation and lipid peroxidation in cortical neurons in culture. *Free Radic Biol Med* 2006; 40: 940-51.
- [21] Takiguchi M, Yoshihara S. New aspects of cadmium as endocrine disruptor. *Environ Sci* 2006; 13: 107-16.
- [22] Nishimura Y, Yamaguchi JY, Kanada A, *et al.* Increase in intracellular Cd (2+) concentration of rat cerebellar granule neurons incubated with cadmium chloride: cadmium cytotoxicity under external Ca (2+) - free condition. *Toxicol In vitro* 2006; 20: 211-16.
- [23] Rose CS, Heywood PG, Costanzo RM1992. Olfactory impairment after chronic occupational cadmium exposure. *J Occup Med* 1992; 34: 600-5.
- [24] Lukawski K, Nieradko B, Sieklucka-Dziuba M. Effects of cadmium on memory processes in mice exposed to transient cerebral oligemia. *Neurotoxicol Teratol* 2005; 27: 575-84.
- [25] Méndez-Armenta M, Rios C. Cadmium toxicity. *Environ Toxicol Pharmacol* 2007; 23: 350-58.
- [26] Viaene MK, Masschelein R, Leenders J, Groof M, De Swerts LJV, Rels HA. Neurobehavioural effects of occupational exposure to cadmium: a cross sectional epidemiological study. *Occup Environ Med* 2000; 57: 19-27.
- [27] Gutierrez-Reyes E, Albores A, Rios C. Increase of striatal dopamine release by cadmium in nursing rats and its prevention by dexamethasone-induced metallothionein. *Toxicology* 1998; 131: 145-54.
- [28] Valko M, Rhodes CJ, Moncol J, Izakovic M, Mazur M. Free radicals, metals and antioxidants in oxidative stress-induced cancer. *Chem Biol Interact* 2006; 160: 1-40.
- [29] El-Sokkary GH, Nafady AA, Shabash EH. Melatonin ameliorates cadmium-induced oxidative damage and morphological changes in the kidney of rat. *Open Neuroendocrinol J* 2009; 2: 1-9.
- [30] El-Sokkary GH, Nafady AA, Shabash EH. Melatonin administration ameliorates cadmium-induced oxidative stress and morphological changes in the liver of rat. *Ecotoxicol Environ Saf* 2010; 73: 456-63.
- [31] Suberlich HA. Pharmacology of vitamin C. *Annu Rev Nutr* 1994; 14: 371-91.
- [32] Halliwell B, Wasil M, Grootveld M. Biologically significant scavenging of the myeloperoxidase-derived oxidant hypochlorous acid by ascorbic acid. *FEBS Lett* 1987; 213: 15-17.
- [33] Gupta P, Kar A. Role of ascorbic acid in cadmium-induced thyroid dysfunction and lipid peroxidation. *J Appl Toxicol* 1998; 18: 317-20.
- [34] Zaidi SMK, Banu N. Antioxidant potentials of vitamins A, E and C in modulating oxidative stress in rat brain. *Clin Chem Acta* 2004; 340: 22-33.
- [35] El-Sokkary GH. Melatonin and vitamin C administration ameliorate diazepam-induced oxidative stress and cell proliferation in the liver of rats. *Cell Prolif* 2008; 41: 168-76.
- [36] Ohkawa H, Ohishi N, Nagi K. Assay for lipid peroxides in animal tissues by thiobarbituric acid reaction. *Anal. Biochem.* 1979; 95: 351-58.
- [37] Misra HP, Fridovich I. The role of superoxide anion in the autoxidation of epinephrine and a simple assay for superoxide dismutase. *J Biol Chem* 1992; 247: 3170-75.
- [38] Beutler E, Duron O, Kelly BM. Improved method for the determination of blood glutathione. *J Lab Clin Med* 1963; 61: 882-88.
- [39] Bradford M. Rapid and sensitive method for quantitation of protein utilizing the principle of protein-day binding. *Analytical Biochem* 1976; 72: 248-54.
- [40] Gabe M. *Histological Techniques*. Paris: Masson / New York, Heidelberg and Berlin: Springer-Verlag 1976.
- [41] Kwon KY, Jang JH, Kwon SY, Cho CH., Oh HK, Kim SP. Cadmium induced acute lung injury and TUNEL expression of apoptosis in respiratory cells. *J Korean Med Sci* 2003; 18: 655-62.
- [42] Bagchi D, Josh, SS, Bagchi M, *et al.* Cadmium and chromium-induced oxidative stress, DNA damage, and apoptotic cell death in cultured human chronic myelogenous leukemic K562 cells, promyelocytic leukemic HL-60 cells, and normal human peripheral blood mononuclear cells. *J Biochem Mol Toxicol* 2000; 14: 33-41.
- [43] Jamal IS, Smith JC. Effects of cadmium on glutathione peroxidase, superoxide dismutase and lipid peroxidation in the rat heart: A possible mechanism of cadmium cardiotoxicity. *Toxicol Appl Pharmacol* 1985; 80: 33-42.
- [44] Szuster-Ciesielska A, Stachura A, Slotwinska M, *et al.* The inhibitory effect of zinc on cadmium-induced cell apoptosis and reactive oxygen species (ROS) production in cell cultures. *Toxicology* 2000; 145: 159-71.
- [45] Dickinson PJ, Carrington AL, Fros, GS, Boulton AJM. Neurovascular disease, antioxidants and glycation in diabetes. *Diabetes Metab Res Rev* 2002; 18: 260-72.
- [46] Yang CF, Shen HM, Shen Y, Zhuang ZX, Ong CN. Cadmium-induced cellular damage in human fetal lung fibroblasts (MRC-5 cells). *Environ Health Perspect* 1997; 105: 712-16.
- [47] Stohs SJ, Bagchi D. Oxidative mechanisms in the toxicity of metal ions. *Free Radic Biol Med* 1995; 18: 321-36.
- [48] El-Demerdash FM, Yousef MI, Kedwany FS, Baghdadi HH. Cadmium-induced changes in lipid peroxidation, blood hematology, biochemical parameters and semen quality of male rats: protective role of vitamin E and B-carotene. *Food Chem Toxicol* 2004; 42: 1563-71.
- [49] Uchida M, Teranishi H, Aoshima K, Katoh T, Kasuya M, Inadera H. Reduction of erythrocyte catalase and superoxide dismutase activities in male inhabitants of a cadmium-polluted area in Jinzu river basin. *J Toxicol Lett* 2004; 151: 451-57.
- [50] Muthuvel R, Venkataraman P, Krishnamoorthy G, *et al.* 2006. Anti-oxidant effect of ascorbic acid on PCB (Aroclor 1254) induced oxidative stress in hypothalamus of albino rats. *Clin Chim Acta* 2006; 365: 297-303.
- [51] Halliwell B, Gutteridge JMC. *Free radicals in biology and medicine*. 4th ed. Oxford/UK: Clarendon Press/Oxford Science 2007.
- [52] Stohs SJ, Bagchi D, Hassoun E, Bagchi M. Oxidative mechanisms in the toxicity of chromium and cadmium ions. *J Environ Pathol Toxicol Oncol* 2001; 20: 77-88.
- [53] Filipic M, Hei TK. Mutagenicity of cadmium in mammalian cells: implication of oxidative DNA damage. *Mutat Res* 2004; 546: 81-91.
- [54] Watjen W, Beyersmann D. Cadmium-induced apoptosis in C6 glioma cells: influence of oxidative stress. *Biometals* 2004; 17: 65-78.
- [55] Shin H, Lee B, Yeo MG, *et al.* Induction of orphan nuclear receptor Nur77 gene expression and its role in cadmium-induced apoptosis in lung. *Carcinogenesis* 2004; 25: 1467-75.
- [56] Yamada H, Damiano VV, Meranze DR, Glasgow J, Abrams WR, Weinbaum G. Neutrophil degranulation in cadmium chloride induced acute lung inflammation. *Am J Pathol* 1992; 109: 145-56.
- [57] Bell RR, Nonavinakere VK, Soliman MR. Intratracheal exposure of the guinea pig lung to cadmium and/or selenium: a histological evaluation. *Toxicol Lett* 2000; 114: 101-9.
- [58] Driscoll KE, Maurer JK, Poynter J, Higgins J, Asquith T, Miller NS. Stimulation of rat alveolar macrophage fibronectin release in a cadmium chloride model of lung injury and fibrosis. *Toxicol Appl Pharmacol* 1992; 116: 30-37.
- [59] Wong KL, Cachia R, Klaassen CD. Comparison of the toxicity and tissue distribution of cadmium in newborn and adult rats after repeated administration. *Toxicol Appl Pharmacol* 1980; 56: 317-25.
- [60] Méndez-Armenta M, Barroso-Moguel R, Villeda-Hernandez J, Nava-Ruiz C, Rios C. Histopathological alterations in the brain regions of rats after perinatal combined treatment with cadmium and dexamethasone. *Toxicology* 2001; 161: 189-199.
- [61] Antonio M, Corpas I, Laret ML. Neurochemical changes in newborn rat's brain after gestational cadmium and lead exposure. *Toxicol Lett* 1999; 104: 1-9.
- [62] Williams LR. Oxidative stress, age-related neurodegeneration, and the potential for neurotrophic treatment. *Cerebrovasc. Brain Metab Rev* 1995; 7: 55-73.
- [63] Na N, Delanghe JR, Taes YEC, Torck M, Baeyens WRG, Ouyang J. Serum vitamin C concentration is influenced by hepatoglobin polymorphism and iron status in Chinese. *Clin Chim Acta* 2006; 365: 31-324.
- [64] Peters JM, Duncan JR, Wiley LM, Keen CL. Influence of antioxidants on cadmium toxicity of mouse preimplantation embryos *in vitro*. *Toxicology* 1995; 99: 11-18.

- [65] Kang SA, Jang YJ, Park H. *In vivo* dual effects of vitamin C on paraquat-induced lung damage: dependence on released metals from the damaged tissue. *Free Radic Res* 1998; 28: 93-107.
- [66] Coa G, Booth SL, Sadowski JA, Prior RL. Increases in human plasma antioxidant capacity after consumption of controlled diets high in fruit and vegetables. *Am J Clin Nutr* 1998; 68: 1081-87.
- [67] You WC, Zhang L, Gail MA, *et al.* Gastric cancer: Helicobacter pylori, serum vitamin C, and other risk factors. *J Natl Cancer Inst* 2000; 2: 1607-12.
- [68] Gupta RS, Gupta ES, Dhakal BK, Thakur AR, Ahnn J. Vitamin C and vitamin E protect the rat testes from cadmium-induced reactive oxygen species. *Mol Cell* 2003; 17: 132-39.
- [69] Rodriguez-Martinez E, Rugerio-Vargas C, Rodriguez AL, Borgonio-Perez G, Rivas-Arancibia S. Antioxidant effects of taurine, vitamin C and vitamin E on oxidative damage in hippocampus caused by the administration of 3-nitropropionic acid in rats. *Int J Neurosci* 2004; 114: 1133-45.
- [70] Oski FA. Vitamin E-A radical defense. *N Engl J Med* 1980; 303: 454-55.
- [71] Banerjee S, Chattopadhyay R, Ghosh A, *et al.* Cellular and molecular mechanisms of cigarette smoke-induced lung damage and prevention by vitamin C. *J Inflamm* 2008; 11: 5-21.
- [72] Schunemann HJ, Freudenheim JL, Grant BJ. Epidemiologic evidence linking antioxidant vitamins to pulmonary function and airway obstruction. *Epidemiol Rev* 2001; 23: 248-67.
- [73] Law A, Gauthier S, Quirion R. Neuroprotective and neurorescuing effects of isoform-specific nitric oxide synthase inhibitors, nitric oxide scavenger, and antioxidant against betaamyloid toxicity. *Br J Pharmacol* 2001; 133: 1114-24.
- [74] Evans P, Halliwell B. Micronutrients: oxidant/ antioxidant status. *Br J Nutr* 2001; 85: 567-74.

---

Received: July 25, 2010

Revised: November 01, 2010

Accepted: November 02, 2010

© El-Sokkary and Awadalla; Licensee *Bentham Open*.

This is an open access article licensed under the terms of the Creative Commons Attribution Non-Commercial License (<http://creativecommons.org/licenses/by-nc/3.0/>) which permits unrestricted, non-commercial use, distribution and reproduction in any medium, provided the work is properly cited.