

University of Groningen

The relation between electromyography and growth velocity of the spine in the evaluation of curve progression in idiopathic scoliosis

Cheung, J.; Veldhuizen, A.G.; Halbertsma, J.P.; Maurits, N.M.; Sluiter, W.J.; Cool, J.C.; van Horn, J.R.

Published in:
SPINE

IMPORTANT NOTE: You are advised to consult the publisher's version (publisher's PDF) if you wish to cite from it. Please check the document version below.

Document Version
Publisher's PDF, also known as Version of record

Publication date:
2004

[Link to publication in University of Groningen/UMCG research database](#)

Citation for published version (APA):

Cheung, J., Veldhuizen, A. G., Halbertsma, J. P., Maurits, N. M., Sluiter, W. J., Cool, J. C., & van Horn, J. R. (2004). The relation between electromyography and growth velocity of the spine in the evaluation of curve progression in idiopathic scoliosis. *SPINE*, 29(9), 1011-1016.

Copyright

Other than for strictly personal use, it is not permitted to download or to forward/distribute the text or part of it without the consent of the author(s) and/or copyright holder(s), unless the work is under an open content license (like Creative Commons).

The publication may also be distributed here under the terms of Article 25fa of the Dutch Copyright Act, indicated by the "Taverne" license. More information can be found on the University of Groningen website: <https://www.rug.nl/library/open-access/self-archiving-pure/taverne-amendment>.

Take-down policy

If you believe that this document breaches copyright please contact us providing details, and we will remove access to the work immediately and investigate your claim.

Downloaded from the University of Groningen/UMCG research database (Pure): <http://www.rug.nl/research/portal>. For technical reasons the number of authors shown on this cover page is limited to 10 maximum.

The Relation Between Electromyography and Growth Velocity of the Spine in the Evaluation of Curve Progression in Idiopathic Scoliosis

John Cheung, MD,* Albert G. Veldhuizen, MD, PhD,* Jan P. K. Halbertsma, PhD,†
Natasha M. Maurits, PhD,‡ Wim J. Sluiter, PhD,* Jan C. Cool, MSc,§ and
Jim R. Van Horn, MD, PhD*

Study Design. A prospective study in which patients with idiopathic scoliosis were examined longitudinally by radiographic and electromyographic measurements according to a protocol.

Objectives. To measure the growth velocity of the spine and the electromyographic ratio of the paraspinal muscles to determine their relation to progression of the scoliotic curve.

Summary of Background Data. Several factors have been reported to be involved in the progression of idiopathic scoliosis. Possible factors may be growth disturbances and muscular abnormality.

Methods. Thirty patients with idiopathic scoliosis were examined over periods of 4 to 5 months. The periods were scored for progression, defined as an increase in Cobb angle of $>10^\circ$. Spinal growth velocity was measured as the length difference of the scoliotic spine between two consecutive radiographs. The electromyographic activity on both sides of the spine expressed as an electromyographic ratio was measured during relaxed upright standing using bipolar surface electrodes. Predictability of progression was evaluated with regression analysis and receiver operating characteristic analysis.

Results. There was an independent association between both spinal growth velocity and electromyographic ratio and progression of the scoliotic curve. An equal sensitivity and specificity of spinal growth velocity for progression of 79.1% was observed at a growth velocity cutoff point of 11 mm/year. Similarly, a cutoff point of 1.25 for the electromyographic ratio could be determined with a predictive value for progression of 68.9%. In the presented nomogram, a spinal growth velocity >15 mm/year combined with an electromyographic ratio >2 gave an 89% probability of progression of the scoliotic deformity. Growth velocities <8 mm/year never resulted in progression.

Conclusions. The combined measurement of spinal growth velocity and electromyographic ratio has significant predictive potential and may be valuable in the evaluation and treatment of idiopathic scoliosis. [Key words: [idiopathic scoliosis, spinal growth velocity, electromyographic ratio] **Spine 2004;29:1011-1016**

The management of idiopathic spinal deformity in young adolescents constitutes challenging and complex clinical problems for an orthopedic surgeon. Treatment is largely aimed toward preventing curve progression. Many factors have been reported in the curve progression of idiopathic scoliosis (IS), but conclusive answers are scanty.^{3,12,13,15,22,24-28,30,34,35,42} It is now commonly assumed that no single cause can explain the development and progression of IS, and a multifactorial genesis is generally accepted. Possible factors may be the remaining growth potential and imbalance of the paraspinal muscles, both resulting in biomechanical instability leading to progression of the scoliotic curve.^{1,6,12,15,19,33,36,37,39,40,41,44,45,46} If so, the spinal growth velocity and the variations of electromyographic (EMG) activity of the spine may be relevant.

These studies have concentrated on the skeletal spinal growth and the paraspinal activity separately in relation to progression of the scoliotic curve. Detailed studies of the relation between spinal growth and paraspinal activity in the context of curve progression do not seem to exist. Moreover, no study to our knowledge has evaluated the correlation between spinal growth velocity and EMG activity of the paraspinal muscles.

Some of our own preliminary results suggest that spinal growth velocity and paraspinal EMG activity may have predictive value for progression of the scoliotic curve.^{8,43} The combined effect of EMG activity and growth velocity of the spine on progression of the scoliotic curve has hitherto not been reported, to our knowledge.

We therefore compared the spinal growth velocity and the paraspinal EMG activity in children with IS. Spinal growth velocity was measured as the difference in length of the scoliotic spine on two consecutive digital radiographs. The paraspinal EMG activity was expressed as the ratio of activity on the convex and concave sides of the scoliotic curve. The children were examined on determined periods wherein these periods were qualified as nonprogressive or progressive.

The objectives of this study were to evaluate whether a correlation could be found between spinal growth velocity and EMG activity of paraspinal muscles, and to investigate their possible relation to progression of the scoliotic deformity. Our hypothesis was that children with IS would show enhanced asymmetric paraspinal EMG activity in association with a more pronounced

From the Departments of *Orthopaedic Surgery, †Rehabilitation, and ‡Neurology, University Hospital Groningen, and the §Institute for Biomedical Technology, University Twente, The Netherlands.

Acknowledgment date: May 2, 2003. Acceptance date: July 14, 2003. Financial support for this study was obtained from STW (Netherlands Technology Foundation).

XThe manuscript submitted does not contain information about medical device(s)/drug(s).

Federal funds were received to support this work. No benefits in any form have been or will be received from a commercial party related directly or indirectly to the subject of this manuscript.

Address correspondence to Dr. A. G. Veldhuizen, Department of Orthopaedic Surgery, University Hospital Groningen, PO Box 30.001, 9700 RB Groningen, The Netherlands; E-mail: a.g.veldhuizen@orth.azg.nl

spinal growth velocity during periods with progression, compared with periods without progression of the scoliotic curve. To establish more detailed insight, we further evaluated this relation for its predictive value for progression of the scoliotic deformity.

Materials and Methods

Patient Groups. All patients with adolescent idiopathic scoliosis (AIS) attending the Department of Orthopedic Surgery of the University Hospital of Groningen were identified. Patients with a diagnosis of scoliosis with right-sided thoracic spinal curves on the initial digital radiographic examination were included between January 2000 and January 2002. Thirty patients (26 girls and 4 boys) fulfilled the inclusion criteria. The severity of the scoliosis (according to Cobb⁹) on the first radiographs varied between 10° and 60°. The ages of the patients at inclusion varied from 10 to 16 years. Each patient was examined clinically and then monitored by digital radiographic and EMG examination in periods of 4 to 5 months. The examinations were evaluated using standardized methods and tests, of which details and methods of measurement have been published previously.⁷ A period between two consecutive visits was scored as progressive or nonprogressive. Progression of the scoliosis was defined as a Cobb angle difference of >10° increase of curvature.

Twenty-seven patients were monitored during four successive periods, two patients were seen twice, and one patient was monitored during three periods. All subjects were examined and measured by the same investigator, using the same measuring equipment, and in the same testing conditions. Informed consent was obtained from each patient and her or his parents before data collection.

Digital Radiographic Measurements. All children had a radiographic examination in standing position, which included a posterior-anterior and lateral view of the spine. For the measurements, anatomic landmarks were positioned at the corners of the vertebral bodies from T1 to L4 on digital images with a mouse (Figure 1) at the Easy Vision workstation (Release 5.1, Philips Medical Systems, Best, The Netherlands). The curvature was measured according to the Cobb method.⁹ The digital radiographic measurement technique using a computer algorithm has been described in detail earlier.⁷

Electromyographic Measurements. Six pairs of bipolar surface EMG electrodes (NEOTRODE 10 mm diameter, Utica, NY, USA) were placed symmetrically along the superficial erector spinae muscles at three levels, 30 mm from the midline and parallel to the spinous processes (Figure 2). The electrode levels corresponded to the apex vertebra and both end vertebrae of the curve. The ECG was measured from two electrodes at the ictus cordis. The electrodes were connected to a multichannel recording device (Porti system, TMS International, Enschede, The Netherlands). Raw EMG signals were amplified, AD-converted, and stored at a sampling rate of 800 Hz in a computer for analysis. The EMG signals were full-wave rectified and low-pass filtered. The ECG artifact correction was performed by zero offsetting for 125 milliseconds around the QRS complex. The EMG activity was expressed as the area under the curve of the EMG recording during the measure. The

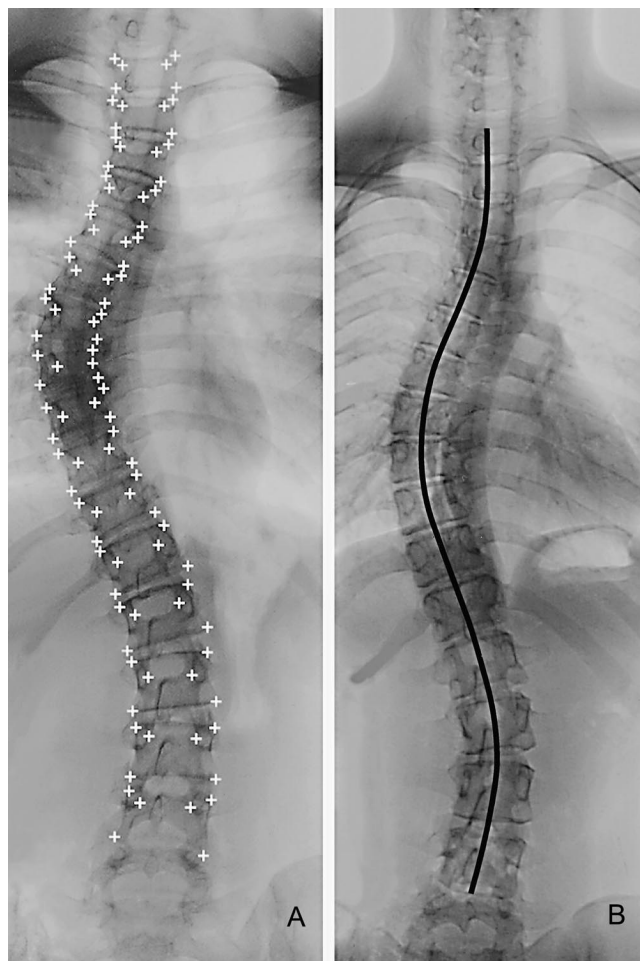


Figure 1. After placement of anatomic landmarks from T1 to L4 (A), calculation of the length of the scoliotic spine through the mid-points of all vertebra and discs between the upper endplate of T1 and the lower endplate of L4 (B) by a computer algorithm

method of EMG measurements has been described in detail in a submitted paper.⁸ The EMG signals were recorded with the patients in a relaxed upright standing posture with arms along the body and feet together.

Data Analysis. The variables used in this study were defined as follows: the Cobb⁹ method was used to determine the severity and progression of the scoliotic deformity.

The length of the scoliotic spine was measured on the digital posterior-anterior radiograph from the distance through the upper endplate of T1 to the lower endplate of L4 (Figure 1). The spinal lengths, computed from two consecutive digital radiographs, were used to calculate the spinal growth velocity in millimeters per year.

Paraspinal activity (EMG) ratio was defined as the EMG activity of a convex electrode pair divided by the EMG activity of a contralateral concave electrode pair of the erector spinae muscles. The EMG recordings of the apex vertebra and the two end vertebrae were considered.

Statistical Analysis. The SPSS10 package was used for statistical analysis. Table 1 shows the means and 95% confidence intervals (CI) of the independent variables, spinal growth velocity and EMG ratio, at the start of the periods. Both variables

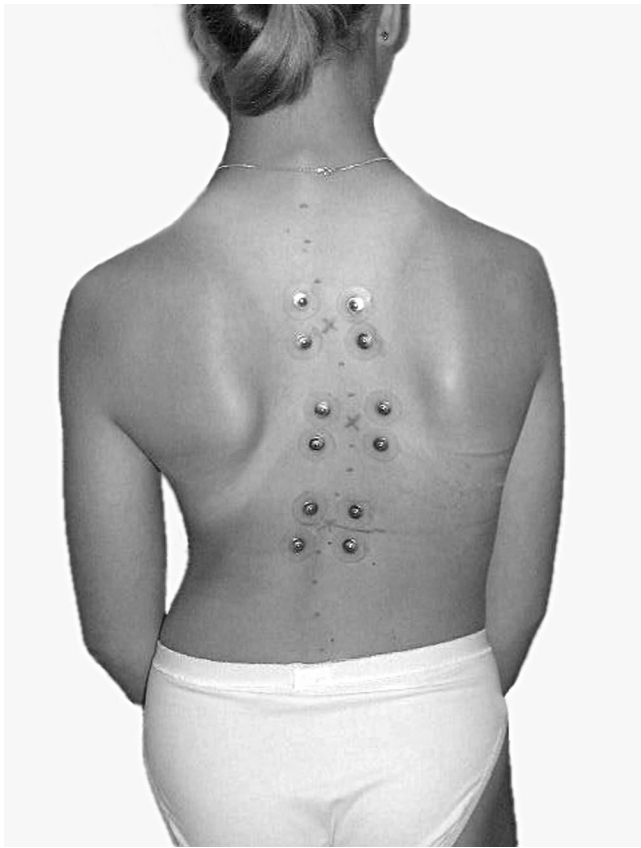


Figure 2. Placement of six pairs of surface electromyographic electrodes on both sides of the spine to measure paraspinal activity.

were log-transformed to obtain a normal distribution. Linear regression analysis was performed to determine whether the independent variables had predictive value for progression of the scoliotic deformity. Statistical significance of differences between (non-) progressive periods was assessed by *t* tests.

To determine the predictive value of the spinal growth velocity and EMG ratio on progression, the receiver operating characteristic (ROC) procedure was used. In this report the cutoff points with equal sensitivity and specificity with 95% CI are given.

■ Results

A total of 85 periods was studied, of which 17 were progressive. The periods of progression of the scoliotic curve occurred in 9 female and 2 male patients with a mean age of 13.2 ± 1.5 years. The remaining group of 17 female and 2 male patients, with a mean age of 14.6 ± 2.4 years, did not experience any progressive period.

The mean with 95% CI of the spinal growth velocity and EMG ratio at the upper end, apex, and lower end vertebrae of the scoliotic curve at the start of the progressive and nonprogressive periods are shown in Table 1. The mean spinal growth velocity was 20.5 mm/year at the start of progressive periods. In the nonprogressive periods, the mean spinal growth velocity was 3.8 mm/year at the start period. The spinal growth velocity at the start of a period was significantly different between progressive and nonprogressive periods ($P < 0.05$).

Enhanced EMG ratios were observed at all three levels of the scoliotic curve at the start of progressive periods. At the start of nonprogressive periods, such an enhanced EMG ratio was observed only at the apex. The EMG ratios at the upper and lower end vertebrae did not differ from 1. Comparison between the two groups of periods showed significant differences at all three levels at the start.

To determine whether there exists an association between spinal growth velocity or EMG ratio and progression, correlation coefficients were calculated. Spinal growth velocity did show a highly significant association with progression at the start of the period ($r = 0.405$, $P = 0.000$). The EMG ratio at the lower end vertebra was significantly associated with progression at the start of the period ($r = 0.371$, $P = 0.000$).

To determine whether spinal growth velocity and EMG ratio at the lower end vertebra were independently associated with progression, multiple variable regression was performed, using the values at the start of a period. Both variables showed independent contributions, re-

Table 1. Mean Spinal Growth Velocity (mm/yr) and EMG Ratio and their 95% CI at Three Levels of the Curve at Start of the Period

| | | Period | | Difference <i>P</i> value |
|-------|--------------------|---------------------------------|------------------------------------|------------------------------|
| | | Progressive (<i>n</i> = 17) | Nonprogressive (<i>n</i> = 68) | |
| | | Growth velocity | Growth velocity | |
| Start | | 20.5 (14.6–28.6) | 3.8 (2.6–5.6) | 0.000 |
| | Electrode level | EMG ratio | EMG ratio | Difference <i>P</i> value |
| Start | Upper end vertebra | 1.47 (1.08–2.00)* | 0.96 (0.81–1.15) | 0.033 |
| | Apex | 1.94 (1.46–2.57)* | 1.30 (1.10–1.54)* | 0.033 |
| | Lower end vertebra | 2.23 (1.60–3.11)* | 1.09 (0.93–1.26) | 0.000 |

CI, confidence interval. * *P* value < 0.05, which means that the ratio difference of the convex and concave side is significant from 1.

Table 2. Nomogram using the Variables Spinal Growth Velocity (SGV) in mm/year and EMG Ratio for predicting the Probability of Progression

| SGV | <8 | 8–15 | >15 | Total |
|-----------|-----------|------------|-------------|-------------|
| EMG Ratio | | | | |
| <0.8 | 0/8 (0%) | 0/6 (0%) | 0/4 (0%) | 0/18 (0%) |
| 0.8–2.0 | 0/22 (0%) | 3/15 (20%) | 3/7 (43%) | 6/44 (14%) |
| >2.0 | 0/9 (0%) | 3/5 (60%) | 8/9 (89%) | 11/23 (48%) |
| Total | 0/39 (0%) | 6/26 (23%) | 11/20 (55%) | 17/85 (20%) |

sulting in the following model ($r = 0.522$, $P = 0.0000$ (spinal growth velocity) and $P = 0.001$ (EMG ratio):

Change in Cobb angle degrees = $-0.882 + 1.177^*$

\ln (spinal growth velocity) + $2.403^* \ln$ (EMG ratio)

Although statistically significant, the associations were too weak to be used for the individual prediction of changes in Cobb angle. Using this formula, the standard error of the differences between predicted changes and the observed ones is 4.40° .

To determine the predictive value of the spinal growth velocity at the start of a period on progression, ROC analysis revealed the cutoff point for growth velocity of 11.0 mm/year with an equal sensitivity and specificity of 79.1%. Thus, concordance was 79.1%. A sensitivity of 95% could be achieved at a cutoff point for spinal growth velocity of 8.1 mm/year with a concordance of 62.8%. A specificity of 95% could be achieved at a cutoff point for spinal growth velocity of 27.8 mm/year with a concordance of 81.6%. Although a clear relation could be found between growth velocity and progression, no definitive cutoff point could be established as having predictive value.

The predictive value of the EMG ratio at the lower end vertebra at the start of a period on progression showed, at a cutoff point for EMG ratio of 1.25, an equal sensitivity and specificity of 68.9%. A cutoff point for the EMG ratio of 0.79 showed a sensitivity of 95%. The concordance for this cutoff point was 28.0%. A specificity of 95% could be achieved at a cutoff point for an EMG ratio of 2.91 with a concordance of 82.1%. So, no absolute predictive value was obtainable.

Using the obtained data, we constructed a nomogram (Table 2). In this nomogram the probability of progression, expressed as percentage, can be determined by using the different categories of the variables growth velocity and EMG ratio. It can be seen that a spinal growth velocity of >15 mm/year and an EMG ratio of >2 gives an 89% probability that a scoliotic curve will show progression in the next period of 4 to 5 months.

■ Discussion

In the present study, the association of both the spinal growth velocity and the EMG ratio of the paraspinal muscles with progression of the scoliotic deformity was evaluated. Our hypothesis was that children with IS

would show enhanced paraspinal EMG activity, in combination with a higher spinal growth velocity, during periods with progression of the scoliotic curve, compared with periods without progression of the scoliotic curve.

Our findings support the fact that the scoliotic curve tends to progress in a period of rapid growth. There was an obvious relation between spinal growth velocity and progression of the scoliotic curve. An equal sensitivity and specificity of 79.1% of spinal growth velocity for progression was found at a cutoff point of 11 mm/year. Nevertheless, an absolute cutoff point in growth velocity could not be determined to predict whether or not the curve would progress. This finding is in good agreement with a previously reported study that children with low spinal growth tend to show no progression of the scoliotic curve.⁴³ The authors found a greater progression rate in periods with growth >10 mm/year than in periods with <10 mm/year.

It is generally accepted that structural scoliosis can develop only in the growing spine.^{5,10,16,20,21,24,47} This has been demonstrated by an increased frequency of diagnosis and the progression of the condition in periods of rapid growth and by the fact that structural scoliosis usually becomes stationary after the end of the period of growth. Bunnell⁴ has shown that growth potential is a predictive factor for the risk of progression of scoliosis. Duval-Beaupère¹¹ found that the progress of scoliosis occurred rapidly after the age of 10 years. Ylikoski,⁴⁷ in a study of girls with AIS, also reported that scoliosis progresses most rapidly in early puberty.

Several reference points in judging relative maturity and spinal growth have been proposed, such as calendar and skeletal age of the hand and wrist, the Risser sign, and date of menarche, but none have proved to be detailed enough to predict the progression of IS. The Risser sign is the most frequently used evaluation in assessing the growth of the spine in relation to clinical problems. However, according to Bunnell et al,⁴ one of the most reliable predictive factors for progression is future growth potential. The estimation of growth potential in children with IS has also been recommended by several other authors for predicting the likelihood of significant curve progression.³⁴ Buckler² showed that $>90\%$ of both male and female persons with IS are within 2.5 cm of their final adult height 3 years after the growth peak. The investigation of Little et al²¹ has confirmed similar results. In a longitudinal study, Lonèar-Dušek et al²³ demonstrated a significantly higher peak velocity for scoliotic children. The study of Song et al³⁴ also showed that the use of peak height velocity more accurately predicts remaining growth for boys with IS than the Risser sign and chronological age.

In the present study, the method used for measuring the spinal growth took into account the shortening of the spine caused by lateral curves but did not take into consideration the effect of sagittal curves, *ie*, thoracic kyphosis and lumbar lordosis. Despite this limitation, the rela-

tive short period of consecutive measurements made it easy to identify when changes in spinal growth velocities and curve progression occur.

Our results showed that enhanced EMG activity ratios occurred at the apex vertebra in the progressive and nonprogressive periods. These results are consistent with the findings in other studies, but the meaning of the increased muscle activity on the convex side of the deformed spine was interpreted differently.^{17,29,32,48,49} Some authors explained the increased muscle activity as being an effect of stretching of the erector spinae muscles on the convex side or as a fatigue mechanism.^{1,32,49} Zetterberg *et al*⁴² described asymmetric EMG changes in a quantitative way. They found increased paraspinal EMG activities on the convex side in curves $>30^\circ$. In the study of Reuber *et al*,³¹ the authors observed significant EMG differences between control participants and IS patients with curves exceeding 25° . In contrast to our study, they observed no EMG activity differences between patients with progressive and nonprogressive curves. By contrast, Guth *et al*¹⁴ and Hopf *et al*¹⁸ observed a distinct asymmetric activity in nonprogressive scoliosis. Several investigators have suggested that EMG findings on the convex side are a biomechanical necessity to balance the deviated spine.^{18,31} Other authors see the asymmetry as a sign of possible progression.^{14,29,38,40} Satisfactory explanations for these observations were not offered, but a muscle imbalance was postulated. Whether the muscle dysfunction is secondary to the development of the scoliotic curve, or is a primary myogenic or neurogenic factor, also remains to be established with certainty. It is not the intent of this paper to evaluate the etiologic possibilities of AIS.

In our study, the paraspinal muscles surrounding the primary curve were evaluated using surface electrodes at the apex and the two end vertebrae of the deformity. It is interesting to notice that in the progressive periods the EMG ratios were significantly higher also at the end vertebrae of the curve, compared with the nonprogressive periods. These neuromuscular findings likely demonstrate that increased EMG paraspinal activity at all three levels of the scoliotic curve may disturb the delicate balance of forces in the spinal column to produce progression. We could find no other study (except our own previous reports⁸) to compare these results.

Furthermore, our results showed a significant association between the EMG ratio at the lower end vertebra and progression. Progression was also associated with a high growth velocity. An explanation could be that after a period of rapid growth, the extent of vertical imbalance is so large that asymmetric EMG activity only at the apex is not sufficient to counteract this imbalance. To keep the center of gravity of the upper part of the body in the midline plane, the spinal column has to be pulled to the convex side of the curve by asymmetric muscle activity at the lower end of the curve. This adaptation will lead to progression of the curve if growth velocity remains high. Oddly enough, the progression of the curve

thus counteracts the vertical imbalance, resulting in a declining association with EMG asymmetry at the lower end of the curve.

This part of the study has two main limitations related to the interpretation of the influence of a manipulation on EMG activity. First, the clinical significance of the magnitude of changes in EMG activity is unknown, given the lack of correlates between these EMG functional changes and other clinical outcome measures. Furthermore, this study was limited to the use of surface EMG, which gives a global picture of paraspinal muscle activity. It is possible that manipulation may influence deeper muscles, which remain hidden from detection by surface electrodes.

We could find no other study that examined the relation between spinal growth (measured as spinal growth velocity) and paraspinal muscular imbalance (expressed as EMG ratio) as prognostic parameters for curve progression in IS. The relation between the growth velocity and muscular imbalance demonstrated here is a novel observation. When children finish their growth spurt, presumably maturation or compensation is reached. There may be a limit to the growth velocity, above which the body is unable to compensate the changes by asymmetric muscle action at the apex.

Another important finding of the current study is that spinal growth velocity and EMG ratio have independent contributions to progression prediction. However, the predictive value in an individual scoliotic patient is moderate, because of the great variability in muscle tension, body posture, and electrode position in our patients. Furthermore, it must be stressed that the growth of a given individual is genetically, geographically, and nutritionally governed.

With the available data, it was not possible for us to predict with 100% accuracy which curve would progress and which would not. We were able to establish the probability of progression in a very general manner, as shown in the nomogram in Table 2. Using the nomogram with the variables spinal growth velocity and EMG ratio, the probability of progression can be determined. In the present study, the risk of curve progression was 89% in patients with a spinal growth velocity >15 mm/year and an EMG ratio >2 . Based on the nomogram, decision making in the management of scoliosis could be facilitated for the orthopedic surgeon. If there is a high probability of progression, the decision can be made to observe the patient more often with radiographs over short time periods. If there is a low probability of progression, the observation might be over a longer time period.

■ Conclusion

The present study has established a clear association between both the spinal growth velocity and EMG ratio of the paraspinal muscles and progression of the scoliotic deformity. We observed enhanced EMG ratios in association with a more pronounced spinal growth velocity in patients with progressive scoliotic curves. We consider

that these findings could be a valuable predictive factor for early identification of individuals with AIS who are at greater risk for progression.

■ Key Points

- Thirty patients with idiopathic scoliosis were longitudinally monitored by measurements of growth velocities of the spinal column and electromyographic ratios of the paraspinal muscles according to a protocol.
- Periods with progression of the curve were associated with both enhanced electromyographic ratios and a high spinal growth velocity, compared with periods without progression.
- The combination of spinal growth velocity and electromyographic ratio may be valuable for prediction of progression in idiopathic scoliosis.
- A nomogram is presented that can be used in decision making for the management of scoliosis.

Acknowledgment

The authors thank Dr. Tom W. van Weerden for discussions and communications, the children who volunteered for this study, and Ronald Davidsz and Occo van der Laan for their assistance in this work.

References

1. Alexander MA, Season EH. Idiopathic scoliosis: an electromyographic study. *Arch Phys Med Rehabil*. 1978;59:314–5.
2. Buckler JMH. *A Longitudinal Study of Adolescent Growth*. New York: Springer-Verlag, 1990.
3. Bunnell WP. An objective criterion for scoliosis screening. *J Bone Joint Surg Am*. 1984;66:1381–7.
4. Bunnell WP. The natural history of idiopathic scoliosis before skeletal maturity. *Clin Orthop*. 1988;229:20–5.
5. Burwell RG. The relationship between scoliosis and growth. In Zorab PA, ed. *Scoliosis and Growth*. Edinburgh, London: Churchill Livingstone, 1971:131–50.
6. Butterworth TR, James C. Electromyographic studies in idiopathic scoliosis. *South Med J*. 1969;1008–10.
7. Cheung J, Wever DJ, Veldhuizen AG, et al. The reliability of quantitative analysis on digital images of the scoliotic spine. *Eur Spine*. 2002;11:535–42.
8. Cheung J, Halbertsma JPK, Veldhuizen AG, et al. A preliminary study on electromyographic analysis of the paraspinal musculature in idiopathic scoliosis. Submitted for publication.
9. Cobb JR. Outline for the study of scoliosis. Instructional Course Lectures. *Am Acad Orthop*. 1948;5:261–75.
10. Drummond DS, Rogala EJ. Growth and maturation of adolescent with idiopathic scoliosis. *Spine*. 1980;5:507–11.
11. Duval-Beaupère G. Growth and its relation to bone deformities. In Zorab PA, ed. *Scoliosis and Growth*. Edinburgh, London: Churchill Livingstone, 1971:58–64.
12. Goldberg CJ, Dowling FE, Fogarty EE. Adolescent idiopathic scoliosis: early menarche, normal growth. *Spine*. 1993;18:529–35.
13. Gross C, Graham J, Neuwirth M, et al. Scoliosis and growth. *Clin Orthop*. 1983;175:243–50.
14. Güth V, Abbink F, Götze HG, et al. Kinesiologische und elektromyographische untersuchungen über die wirkung des Milwaukee-korsetts. *Z Orthop Ihre Grenzgeb*. 1976;114:480–4.
15. Hägglund G, Karlberg J, Willner S. Growth in girls with adolescent idiopathic scoliosis. *Spine*. 1992;17:108–11.
16. Heine J, Reher H. Progression of untreated idiopathic scoliosis up to the end of growth. *Zeitschr Orthop bre Grenzgebiete*. 1975;113:87–96.
17. Hoogmartens MJ, Basmajian JV. Asymmetrical postural tone as a possible cause of idiopathic scoliosis: a preliminary communication. *Electromyogr Clin Neurophysiol*. 1973;13:365–6.
18. Hopf Ch, Scheidecker M, Steffan K, et al. Gait analysis in idiopathic scoliosis before and after surgery: a comparison of the pre- and postoperative muscle activation pattern. *Eur Spine*. 1998;7:6–11.
19. Hoppenfeld S. Histochemical findings in paraspinal muscles of patients with idiopathic scoliosis. In: Zorab PA, ed. *Scoliosis and Muscle*. London: Heine-mann 1974;113–4.
20. Howell FR, Mahood, Dickson RA. Growth beyond skeletal maturity. *Spine*. 1992;17:437–40.
21. Little DG, Song KM, Katz D, et al. Relationship of peak height velocity to other maturity indicators in idiopathic scoliosis in girls. *J Bone Joint Surg Am*. 2000;82:685–93.
22. Lloyd-Roberts GC, Pincott JR, McMeniman P, et al. Progression in idiopathic scoliosis. *J Bone Joint Surg Am*. 1978;60:451–60.
23. Lonèar-Dušek M, Pecina M, Prebeg Z. A longitudinal study of growth velocity and development of secondary gender characteristics versus onset of idiopathic scoliosis. *Clin Orthop*. 1991;270:278–89.
24. Lonstein JE, Carlson JM. The prediction of curve progression in untreated idiopathic scoliosis during growth. *J Bone Joint Surg Am*. 1984;66:1061–71.
25. Lonstein JE. Adolescent idiopathic scoliosis. *Lancet*. 1994;344:1407–12.
26. Mannion AF, Meier M, Grob D, et al. Paraspinal muscle fibre type alterations associated with scoliosis: an old problem revisited with new evidence. *Eurospine*. 1998;7:289–93.
27. Nachemson AL, Sahlstrand T. Etiologic factors in adolescent idiopathic scoliosis. *Spine*. 1977;2:176–84.
28. Reamy BV, Slakey JB. Adolescent idiopathic scoliosis: review and current concepts. *Am Fam Physician*. 2001;64:111–6.
29. Redford JB, Butterworth TR, Clements EI. Use of electromyography as a prognostic aid in the management of idiopathic scoliosis. *Arch Phys Med Rehabil*. 1969;50:434–8.
30. Renshaw TS. Idiopathic scoliosis in children. *Curr Opin Pediatr*. 1993;5:407–12.
31. Reuber M, Schultz A, McNeill T, et al. Trunk muscle myoelectric activities in idiopathic scoliosis. *Spine*. 1983;8:447–56.
32. Riddle HFV, Roaf R. Muscle imbalance in scoliosis. *Lancet*. 1955;1:1245–7.
33. Skogland LB, Millner JAA. The length and proportions of the thoracolumbar spine in children with idiopathic scoliosis. *Acta Orthop Scand*. 1981;52:177–85.
34. Song KM, Little DG. Peak height velocity as a maturity indicator for males with idiopathic scoliosis. *J Pediatr Orthop*. 2000;20:286–8.
35. Soucacos PN, Zachareis, Gelalis J, et al. Assessment of curve progression in idiopathic scoliosis. *Eurospine*. 1998;7:270–7.
36. Spencer GSG, Zorab PA. Spinal muscle in scoliosis: Part I. Histology and histochemistry. *J Neurol Sci*. 1976;30:137–42.
37. Spencer GSG, Zorab PA. Spinal muscle in scoliosis: Part II. The proportion size of type I and type II skeletal muscle fibers measured using a computer controlled microscope. *J Neurol Sci*. 1976;30:143–54.
38. Tanchev PI, Dzherov AD, Parushev AD, et al. Scoliosis in rhythmic gymnasts. *Spine*. 2000;11:1367–72.
39. Terver S, Kleinman R, Bleck EE. Growth landmarks and the evolution of scoliosis: a review of pertinent studies on their usefulness. *Dev Med Child Neurol*. 1980;22:675–84.
40. Valentino B, Maccauro L, Mango G, et al. Electromyography for the investigation and early diagnosis of scoliosis. *Anat Clin*. 1985;7:55–9.
41. Veldhuizen AG, Baas P, Webb PJ. Observations on the growth of the adolescent spine. *J Bone Joint Surg Br*. 1986;68:724–8.
42. Weinstein SL, Ponseti IV. Curve progression in idiopathic scoliosis. *J Bone Joint Surg Am*. 1983;65:447–55.
43. Wever DJ, Tønseth KA, Veldhuizen AG, et al. Curve progression and spinal growth in brace treated idiopathic scoliosis. *Clin Orthop*. 2000;377:169–79.
44. Willner S. Development of trunk asymmetries and structural scoliosis in prepubertal school children in Malmö: follow-up study of children 10–14 years of age. *J Pediatr Orthop*. 1984;4:452–5.
45. Yarom R, Gordon CB. Muscle pathology in idiopathic scoliosis. *Israel J Med Sci*. 1979;15:917–24.
46. Yarom R, Gordon CB. Studies on spinal and peripheral muscles from patients with scoliosis. *Spine*. 1979;4:12–21.
47. Ylikoski M. Spinal growth and progression of adolescent idiopathic scoliosis. *Eur Spine*. 1993;1:236–9.
48. Zetterberg C, Björk R, Örtengren R, et al. Electromyography of the paravertebral muscles in idiopathic scoliosis: measurements of amplitude and spectral changes under load. *Acta Orthop Scand*. 1984;55:304–9.
49. Zuk T. The role of spinal and abdominal muscles in the pathogenesis of scoliosis. *J Bone Joint Surg Br*. 1962;44:102–5.