

TITLE

The relationship between protoporphyrin IX photobleaching during real-time dermatological methyl-aminolevulinate photodynamic therapy (MAL-PDT) and subsequent clinical outcome.

AUTHORS

Tyrrell, Jessica S.; Campbell, Sandra M.; Curnow, Alison

JOURNAL

Lasers in Surgery and Medicine

DEPOSITED IN ORE

11 January 2016

This version available at

<http://hdl.handle.net/10871/19194>

COPYRIGHT AND REUSE

Open Research Exeter makes this work available in accordance with publisher policies.

A NOTE ON VERSIONS

The version presented here may differ from the published version. If citing, you are advised to consult the published version for pagination, volume/issue and date of publication

The relationship between protoporphyrin IX photobleaching during real-time dermatological methyl-aminolevulinate photodynamic therapy (MAL-PDT) and subsequent clinical outcome

Jessica S. Tyrrell, MBiochem, Sandra M. Campbell, MD and Alison Curnow, PhD

Clinical Photobiology, Peninsula Medical School, University of Exeter, Knowledge Spa, Royal Cornwall Hospital, Treliske, Truro, Cornwall, TR1 3HD, UK

Email: jessica.tyrrell@pms.ac.uk

Telephone: 00 44 (0)1872 256432

Facsimile: 00 44 (0)1872 256497

Acknowledgements: This work is kindly supported by the Duchy Health Charity Ltd

Keywords: Actinic keratosis (AK); Bowen's disease (BD); Basal cell carcinoma (BCC); Dyaderm; Fluorescence diagnosis (FD); Non-invasive fluorescence imaging; Metvix®

Abstract

Background and Objective: The relationship between protoporphyrin IX (PpIX) photobleaching and cellular damage during aminolevulinic (ALA) photodynamic therapy (PDT) has been studied at the cellular level. This study assessed the capability of a non-invasive fluorescence imaging system (Dyaderm, Biocam, Germany), to monitor changes in PpIX during real time methyl-aminolevulinate (MAL) PDT in dermatological lesions, and thus to act as a predictive tool in terms of observed clinical outcome post treatment.

Materials and Methods: Patients attending Royal Cornwall Hospital (Truro, UK) for MAL-PDT to licensed lesions (actinic keratosis, Bowen's disease and basal cell carcinoma) were monitored using the pre-validated non-invasive fluorescence imaging system. Patients were imaged at three distinct time points: prior to the application of MAL, after the three hours of MAL application and immediately following light irradiation. The fluorescence intensity of the images were analysed with image analysis software and the percentage change in fluorescence during light irradiation was related to the clinical outcome observed three months following treatment. In total 100 patients underwent at least one session of MAL-PDT.

Results: Significantly higher levels of change in PpIX fluorescence during light irradiation ($P < 0.005$) were observed in lesions undergoing complete clearance at three months when compared to those patients who underwent partial or no clearance. In contrast no significant difference ($P > 0.500$) was observed in the total levels of PpIX recorded after MAL application in patients undergoing partial and complete clearance at three months.

Conclusions: PpIX photobleaching is indicative of the level of cellular damage PDT treatment will induce and therefore the clinical outcome expected within patients.

This study indicated the potential of the commercially available fluorescence imaging system investigated to predict treatment success at the time of light irradiation and in the future it may be possible to employ it to individualise treatment parameters to improve dermatological PDT efficacy/outcome.

Introduction

Non-melanoma skin cancers (NMSC) and associated precancerous lesions originate from non-melanocytic cell types within the epidermis and they are the most common malignancy in the Caucasian population (1). They comprise more than one-third of all adult cancers within the U.S. (approximately 900,000 to 1,200,000 cases per year) (2) and the incidence is steadily increasing worldwide at a rate of 3 % – 8 % each year (3). Although these cancers rarely metastasise, when left untreated they can cause extensive local damage to the skin and often disfigure the patient (due to their frequently prominent localisation in sun exposed areas). The treatment of NMSC and the associated precancerous lesions therefore places a huge burden on health organisations.

Photodynamic therapy (PDT) is a highly selective technique for the ablation of tumor tissue via the production of singlet oxygen and other reactive oxygen species (ROS) (4). The photodynamic reactions generate the ROS providing that three critical components are present; a photosensitiser, light of the appropriate wavelength and oxygen (5) . Topical PDT with the application of a prodrug (aminolevulinic acid, ALA or its methyl ester MAL) has found a niche in the treatment of dermatological conditions, especially in treating NMSC and other precancerous skin lesions (e.g. basal cell carcinoma (BCC), Bowen's disease (BD) and actinic keratosis (AK)) which are all licensed indications in the UK (6). High complete response rates are observed when treating these lesions with topical PDT and these are comparable to the standard treatment modalities of cryosurgery and surgical excision (7-10). PDT has several advantages over standard treatment for NMSC and precancerous

lesions, particularly in terms of improved cosmetic outcome and the ability to easily treat large or multiple lesions (7-10).

Endogenous protoporphyrin IX (PpIX) accumulates within cells following the topical application of ALA/MAL, which are converted enzymatically via the heme biosynthesis pathway (11,12). PpIX accumulation occurs preferentially within tumor cells probably as a result of disruption of the stratum corneum and differences in enzyme activity within neoplastic and normal tissues (13). The accumulated PpIX is activated via the application of red light (635 nm). The majority of this energy dissipates as heat or fluorescence but occasionally a high energy triplet state is formed (12). Interaction of the triplet state PpIX with molecular oxygen results in the production of singlet oxygen and other reactive oxygen species (ROS) which cause localised oxidative damage to the cells resulting in cell death via apoptosis or necrosis (14). The characteristic optical properties of PpIX enable fluorescence diagnosis (FD) a technique that identifies and demarcates tumors and pre-cancers due to their preferential accumulation of PpIX in comparison with normal skin, thereby aiding diagnosis and surgical excision (15-18). In addition FD equipment with appropriate validation/modification has the potential to follow the accumulation and destruction of the photosensitizer during real-time PDT.

This study employed a commercially available imaging system (Dyaderm, Biocam, Germany) to monitor the changes in PpIX during real-time clinical dermatological MAL-PDT. We have previously validated this system to ensure that changes in PpIX levels can be reproducibly followed during dermatological PDT (19). Previous *in vivo* studies have indicated the positive correlation between PpIX photobleaching and cellular damage, indicating that greater photobleaching enhances the efficacy of the treatment (20-22). This investigation considered the levels of PpIX photobleaching

and total PpIX fluorescence observed at the time of treatment with the clinical outcome at three months to determine whether this system had the potential to act as a predictor of treatment efficacy at the time of PDT treatment.

Materials and Methods

Fluorescence imaging

PpIX fluorescence was determined using a pre validated non-invasive imaging system (Dyaderm, Biocam, Germany) (19). The system consisted of a Xenon flash light source that had a custom bandpass filter (370–440 nm) enabling alternation between white and blue light. The light source had a low irradiance (3–5 mWcm⁻²) and a short exposure time to minimise ROS production during light irradiation. Previous investigations within our group have shown no significant alterations in PpIX fluorescence when sequential measurements were acquired (data not shown). Seven light pulses per second were delivered to the area of interest, and the returning light was collected by a 12-bit Sony charge coupled device (CCD) camera (exposure time 100 µs) which utilised a special Schott GG 455 longpass filter to exclude the excitation light. The light source and CCD were combined in one adjustable arm coupled to a Pentium IV computer equipped with custom-made image capturing software (Dyaderm Pro v2, Biocam, Germany). The red pixels of the CCD camera (spectral sensitivity of which at 630 nm was between 85% and 90%) were used to generate a fluorescence image from the red spectrum fluorescence emitted from the excited PpIX. In this way, a normal coloured image (from the white light) and a fluorescence image (from the blue light 370–440 nm) was simultaneously collected and processed by the system in real time.

In addition to PpIX other fluorophores within the skin (e.g. lipopigments and flavins) were activated with the blue light and emitted light in the green spectrum. This autofluorescence was also recorded by the camera. The software computed a “PpIX filtered” image which corrected for the heterogeneity due to imperfections in the

excitation light and the natural curvature of the object imaged by combining the red and green fluorescence images.

PDT treatment

Patients attending the photodynamic therapy clinic in the Dermatology Department, Royal Cornwall Hospital, for routine dermatological PDT were provided with verbal and written information about the study prior to giving written consent before participating in this ethically approved (Cornwall and Plymouth Research Ethics Committee) fluorescence imaging study. This study was therefore a non-interventional, non-randomised, observational study. All the lesions included were dermatological indications (AK, BD and BCC) for which MAL-PDT has been approved in the UK (6,23). The majority of BCC and BD lesions were biopsied prior to referral for MAL-PDT treatment; in contrast AK lesions were referred at the Consultant Dermatologist's discretion. The BCC lesions monitored were all histologically considered to be superficial (less than 0.5 mm thick) in nature following clinical observation and biopsy. Patients' lesion(s) were imaged at both their first and second clinic visits if they received more than one PDT treatment. One hundred patients were recruited and one lesion was monitored in each patient to limit statistical error. There was an approximately equal split in terms of the three licensed lesions (37 AK, 29 BD and 34 BCC) and patient gender (56 Males and 44 Females), with the age of the patient ranging from 45 – 96 years, with an average of 77 years. Our previous studies (data not shown) have indicated that the histologically distinct lesions behaved in a similar manner to MAL-PDT and therefore the data was analysed as a whole. Patient gender and age have also been previously considered and these were not considered to contribute significantly to the changes in PpIX levels observed (data not shown). The majority of patients (84

patients) received two treatments, nine days apart, to the individual lesions as per the NICE clinical guidelines (24) with the exception being superficial AK (16 patients) which only received (as recommended) a single PDT treatment. The lesions were treated as per the standard clinical protocol, with overlying crust removed from the lesion prior to the application of a thin layer (1 mm thick with a border of 5 mm around the visible lesion) of the topical MAL cream (160 mg/g MAL, commercially known as Metvix®, Galderma, UK). The lesion was then occluded from the light for a period of three hours. After the allotted time the lesion was irradiated with a red light (Aktelite, Galderma, UK; 635 nm +/- 5 nm; 37 Jcm⁻²; 90 mWcm⁻²) which was positioned by a specialist nurse practitioner to be between 5 and 8 centimetres away from the lesion (in accordance with the NICE treatment guidelines (24)).

The lesions were imaged at multiple time points during standard PDT treatment, specifically prior to the application of MAL, after the three hour MAL application period and immediately following light irradiation. All images were taken in accordance with our previously derived standardised operating procedure which enabled reproducible images to be acquired by limiting the other factors potentially altering image acquisition (19). To enable the identical region to be imaged the position of the camera was marked on the patients' skin to enable replacement of the camera in the same place. The fluorescence intensity within images (arbitrary units (AU)) were then analyzed at a consistent pixel position using ImageJ software to follow the changes in PpIX fluorescence within the lesion at the different points in the treatment. When patients attended the clinic for a second treatment nine days later the images were acquired and analyzed in exactly the same manner.

Outcome at three months

All patients attended an outpatient clinic three months after their last PDT treatment and the lesions were visually assessed by a Consultant Dermatologist who was blinded to the fluorescence imaging results. The outcome reported was based on the initial assessment of the lesion entered in the notes, which included details of the lesion size and an image of the lesion prior to treatment. If no clinical evidence of the tumour remained at three months then the lesions were considered to have undergone complete clinical clearance. Lesions that were observed to have decreased in size but where (pre)cancerous cells clearly remained were reported to have undergone a partial clearance. Lesions which remained unaltered following the one or two PDT treatments they had received were reported as no clearance.

Data analysis

The clinical outcomes recorded were related to the image analysis data in particular the total PpIX fluorescence recorded after the three hour MAL application and the percentage change in fluorescence intensity observed during light irradiation. For each patient the total fluorescence after the three hour application of MAL was noted and the percentage change in fluorescence during light irradiation was calculated. The values were then allotted to the appropriate group (i.e. complete, partial or no clearance) and the median values of the outcome group calculated. The analysis looked initially at the first and second MAL-PDT treatments separately and then the data were combined.

These non-parametric data were analysed using the Mann Whitney U test to compare the percentage changes in fluorescence during light irradiation or total PpIX fluorescence after the three hour MAL application observed in lesions undergoing complete, partial and no clearance. Due to the low number of patients undergoing no clearance statistical analysis was only conducted between the complete and partial clearance groups.

The z-test for two proportions was utilized to compare the percentage of patients within the complete and partial clearance groups that underwent a greater than 40%, 50% and 60% fluorescence change in PpIX.

It should be noted that this non-interventional, non-randomised, observational study of routine dermatological MAL-PDT practice was not powered in advance as no idea of the size of change in fluorescence intensity that might be observed during clinical light irradiation was previously known or indeed how this may be related (if at all) to the clinical outcome observed at three months.

Results

Total PpIX fluorescence

The median total PpIX fluorescence observed after the three hour MAL application were similar in all patients independent of the clinical outcome observed at three months (1st treatment: complete 132.94 au, partial 126.36 au and no response 108.57 au; 2nd treatment: complete 104.91 au, partial 100.48 au and no response 150 au) (Figure 1). When the grayscale fluorescence intensities after MAL application for complete responders (n = 72) were compared to the grayscale intensities for partial responders (n = 27) no significant differences were observed in lesions undergoing the first PDT treatment alone ($P=0.529$), nor the second PDT treatment alone ($P=0.641$), nor when the combination of the first and second treatments were analysed together ($P=0.598$) (Figure 1).

Percentage change in fluorescence intensity during light irradiation

Light irradiation resulted in a statistically significant decrease in the fluorescence intensity within the lesions which corresponded to the photobleaching of the lesion. Patients observed to undergo complete clinical clearance (n = 72) had statistically higher levels of change in PpIX fluorescence intensity during the first and second PDT treatments ($P<0.005$) in comparison to those patients who only underwent partial clearance (n = 27) (Figure 2).

Determination of an optimal percentage change in fluorescence

The percentage of lesions undergoing a change in fluorescence intensity of greater than 40% during light irradiation was not noted to differ significantly between complete and partial responders. In contrast fluorescence changes of 50% and 60% were significantly more likely within the complete responders group when compared with the partial responders group ($P<0.01$ and $P<0.001$ respectively, 90% power; Figure 3). When a 70% change was analysed, the number of patients undergoing such a considerable change was considered too low for this to be a useful threshold.

Discussion

MAL-PDT has become a successful treatment modality for the treatment of NMSC and skin pre-cancers (6,7,25). The endogenous photosensitizer, PpIX, produced from the topical precursor MAL accumulates specifically within these lesions (12,13,26) and results in the production of singlet oxygen and other ROS when activated with red light. Previous studies have shown a positive correlation between PpIX photobleaching and the induced cellular damage, indicating that greater PpIX photobleaching results in more efficacious PDT (20-22,27). Therefore the potential exists to follow PpIX photobleaching and utilize it as a predictive tool in determining clinical outcome within the clinical setting.

The characteristic fluorescent properties of PpIX enables fluorescence imaging which is normally employed to identify and demarcate lesions to aid their removal, but it also has the potential to follow PpIX accumulation and destruction during PDT (16). Fluorescence spectroscopy is commonly used to follow changes in PpIX *in vitro* (28,29) and in animal models (22,30,31), however to date limited clinical data is available due to the poor reproducibility of results (32). This study utilised a system which we had previously validated to follow PpIX changes during MAL-PDT (19) and related these to the observed clinical outcome after three months.

Our findings indicated that the percentage change in fluorescence during light irradiation (which relates to PpIX photobleaching) (Figure 2) and not the total level of PpIX fluorescence prior to light irradiation (Figure 1) was associated with improved clinical outcome (observed at three months after treatment). No significant difference was observed between complete, partial and non responders in terms of the total PpIX fluorescence detected prior to light irradiation ($P>0.500$). In contrast

the percentage change in fluorescence in complete responders was statistically greater than in partial responders ($P<0.005$) for both the first and second PDT treatments. Comparisons were only made between complete and partial responders in this study due to the lack of non-responders (only one patient showed no response to PDT treatment using our standard PDT treatment protocol). The clearance rates (complete clearance 72% and partial clearance 27%) obtained are consistent with the literature which indicates that this standard MAL-PDT treatment regime is able to produce effective clearance in these approved dermatological indications (23,33).

Figure 3 indicated that a significantly higher percentage of lesions undergoing complete clearance were observed to undergo changes in fluorescence of greater than 50% and 60% when compared with lesions undergoing a partial response ($P<0.01$ and $P<0.001$ respectively). The purpose here was to try and predict treatment effectiveness at the time of PDT treatment in order to be able to alter treatment as appropriate (e.g. conduct another PDT treatment if not enough photobleaching was observed rather than waiting three months before retreating) and it appears that in this respect this may be possible with further investigation.

The National Institute of Clinical Excellence (NICE) guidelines (24) recommend two PDT treatments seven days apart for licensed lesions treated with MAL-PDT (with the exception of superficial AK where one treatment is deemed sufficient). The data in figure 3 suggests that a threshold percentage change of either 50% or 60% could be applied to determine whether a third and/or fourth treatment may be beneficial. Following this analysis, the authors would suggest a threshold of 60% should be considered for further investigation as this percentage demonstrated the greatest level of significance between the number of complete and partial responders

undergoing a change of this magnitude. This highlights the potential of this system to individualise patient treatments with the aim of retreating lesions which did not undergo a 'satisfactory' change in fluorescence during the first one or two treatments conducted routinely. This has the potential to reduce clinical time constraints (particularly for the Consultant) and reduce the economic burden of PDT treatment as patients may only need/require one subsequent PDT treatment rather than being referred for a further course of two PDT treatments. Further research would be required to determine whether implementing a PpIX photobleaching threshold level such as this could have this desired positive effect on dermatological PDT practice.

It is important to note that within this study clinical outcome was determined at three months, as this is our standard clinical follow up period. However the results may vary if outcome was determined at different time periods following treatment especially when considering long term follow ups (e.g. several years). The literature commonly states that recurrence of the lesion can occur in regions previously considered clear several years following treatment (34). This is most common in the initial years following treatment.

The clinical outcome after treatment was determined by clinical evaluation only, not by histological analysis. This was done to avoid another biopsy, preserve the good cosmesis achieved with PDT and is the normal method for determining outcome following PDT within our Department. However, the reviewing Consultant compared the treated area with the previous explanations within the notes, particularly comparing size and visual appearance of the area. The lesion was considered completely clear if no clinical signs were visible.

Monitoring PpIX photobleaching *in vivo* is known to be technically feasible (22,30,31,35) and has been demonstrated in this present work for the first time in patients undergoing dermatological MAL-PDT. Despite this, the mechanistic relationships between photobleaching and the resulting photo-damage are not trivial (36). The rate of photobleaching is thought to be dependent on the light fluence, photosensitiser concentration and the partial pressure of oxygen (pO_2) within the tissues under investigation (36). In terms of this study the light fluence was constant and therefore fluence and fluence rate were not a variable. In contrast the pO_2 will be of critical importance to the efficacy of PDT as it is related to the level of singlet oxygen produced within the localised area (37). The oxygenation of the tissue is known to determine the photobleaching rate (36) and therefore the initial value of pO_2 within the tissue needs to be considered. During light delivery the oxygen level will be reduced due to photochemical consumption, and due to the variability in initial tissue pO_2 , in some instances photobleaching may switch from oxygen-dependent to oxygen-independent mechanisms (38). A link between oxygen-independent photobleaching and photochemical damage is yet to be determined however. This indicates that photobleaching alone may not be suitable to determine clinical outcome in patients undergoing MAL-PDT as the fluorescence measurements alone do not consider oxygen independent photobleaching, which due to the heterogeneity of microvasculature in skin is certainly plausible. Although in the skin a proportion of the oxygenation comes from the atmosphere rather than the vasculature (39).

Previous literature has indicated that PpIX photobleaching differs at various PpIX concentrations *in vitro*, with higher PpIX concentrations relating to lower PpIX photobleaching (20,40). This is proposed to occur due to the localisation of PpIX at secondary sites (which protect PpIX from singlet oxygen or make it less photoactive)

following the saturation of the primary binding sites. The clinical relevance of this is currently not known, and in this study with the sample size investigated no significant difference was observed in the total PpIX fluorescence observed prior to light irradiation in the complete and partial responders ($P>0.500$).

The clinical data presented here are consistent with the literature in terms of the positive correlation previously observed between PpIX photobleaching and cellular damage (20-22,41). Importantly this study looks at percentage change in fluorescence rather than the raw data generated from the non-invasive imaging system utilized which would be device specific and therefore the thresholds postulated here with investigation could be utilized by other clinical investigators with other fluorescence monitoring devices.

This study has indicated the potential of a commercially available fluorescence imaging system to follow changes in PpIX fluorescence non-invasively in real time during routine dermatological practice and also indicates that it may be possible to use PpIX photobleaching during light irradiation to give an indication of likely treatment outcome at three month follow-up whilst PDT is still in progress.

Disclosure: "I certify that I have no affiliation with or financial involvement in any organization or entity with a direct financial interest in the subject matter or materials discussed in the manuscript (e.g., employment, consultancies, stock ownership, honoraria) except as discussed in an attachment."

References

1. Neville JA, Welch E, Leffell DJ. Management of nonmelanoma skin cancer in 2007. *Nat Clin Pract Oncol* 2007; 4(8):462-469.
2. Braathen LR, Szeimies RM, Basset-Seguín N, Bissonnette R, Foley P, Pariser D, Roelandts R, Wennberg AM, Morton CA. Guidelines on the use of photodynamic therapy for nonmelanoma skin cancer: an international consensus. *International Society for Photodynamic Therapy in Dermatology*, 2005. *J Am Acad Dermatol* 2007; 56(1):125-143.
3. Green A. Changing patterns in incidence of non-melanoma skin cancer. *Epithelial Cell Biol* 1992; 1(1):47-51.
4. Luna MC, Ferrario A, Wong S, Fisher AM, Gomer CJ. Photodynamic therapy-mediated oxidative stress as a molecular switch for the temporal expression of genes ligated to the human heat shock promoter. *Cancer Res* 2000; 60(6):1637-1644.
5. Henderson BW, Dougherty TJ. How does photodynamic therapy work? *Photochem Photobiol* 1992; 55(1):145-157.
6. Morton CA, McKenna KE, Rhodes LE. Guidelines for topical photodynamic therapy: update. *Br J Dermatol* 2008; 159(6):1245-1266.
7. Annemans L, Caekelbergh K, Roelandts R, Boonen H, Leys C, Nikkels AF, van Den Haute V, van Quickenborne L, Verhaeghe E, Leroy B. Real-life practice study of the clinical outcome and cost-effectiveness of photodynamic therapy using methyl aminolevulinate (MAL-PDT) in the management of actinic keratosis and basal cell carcinoma. *Eur J Dermatol* 2008; 18(5):539-546.

8. Basset-Seguín N, Ibbotson SH, Emtestam L, Tarstedt M, Morton C, Maroti M, Calzavara-Pinton P, Varma S, Roelandts R, Wolf P. Topical methyl aminolaevulinate photodynamic therapy versus cryotherapy for superficial basal cell carcinoma: a 5 year randomized trial. *Eur J Dermatol* 2008; 18(5):547-553.
9. Kaufmann R, Spelman L, Weightman W, Reifenberger J, Szeimies RM, Verhaeghe E, Kerrouche N, Sorba V, Villemagne H, Rhodes LE. Multicentre intraindividual randomized trial of topical methyl aminolaevulinate-photodynamic therapy vs. cryotherapy for multiple actinic keratoses on the extremities. *Br J Dermatol* 2008; 158(5):994-999.
10. Morton CA, Horn M, Leman J, Tack B, Bedane C, Tijoe M. A randomized, placebo-controlled, European study comparing MAL-PDT with cryotherapy and 5-fluoracil in subjects with Bowen's disease. *J Eur Acad Dermatol Venereol* 2004; 18(Suppl 2):415.
11. Malik Z, Lugaci H. Destruction of erythroleukaemic cells by photoactivation of endogenous porphyrins. *Br J Cancer* 1987; 56(5):589-595.
12. Peng Q, Berg K, Moan J, Kongshaug M, Nesland JM. 5-Aminolevulinic acid-based photodynamic therapy: principles and experimental research. *Photochem Photobiol* 1997; 65(2):235-251.
13. Peng Q, Warloe T, Berg K, Moan J, Kongshaug M, Giercksky KE, Nesland JM. 5-Aminolevulinic acid-based photodynamic therapy. Clinical research and future challenges. *Cancer* 1997; 79(12):2282-2308.
14. Noodt BB, Berg K, Stokke T, Peng Q, Nesland JM. Apoptosis and necrosis induced with light and 5-aminolaevulinic acid-derived protoporphyrin IX. *Br J Cancer* 1996; 74(1):22-29.

15. Ackermann G, Abels C, Karrer S, Baumler W, Landthaler M, Szeimies RM. [Fluorescence-assisted biopsy of basal cell carcinomas]. *Hautarzt* 2000; 51(12):920-924.
16. Allison RR, Sibata CH. Photodiagnosis for cutaneous malignancy: a brief clinical and technical review. *Photodiagnosis Photodyn Ther* 2008; 5(4):247-250.
17. Baumler W, Abels C, Szeimies R. Fluorescence diagnosis and photodynamic therapy. *Medical Laser Application* 2003; 18:47-56.
18. Siewecke C, Szeimies RM. PDT and fluorescence diagnosis in dermatology. *Hospital Pharmacy Europe* 2004; May/June:49-52.
19. Tyrrell J, Campbell S, Curnow A. The validation of a non-invasive fluorescence imaging system to monitor clinical dermatological photodynamic therapy. *Photodiagnosis and Photodynamic Therapy* 2010; In Press.
20. Ascencio M, Collinet P, Farine MO, Mordon S. Protoporphyrin IX fluorescence photobleaching is a useful tool to predict the response of rat ovarian cancer following hexaminolevulinate photodynamic therapy. *Lasers Surg Med* 2008; 40(5):332-341.
21. Boere IA, Robinson DJ, de Bruijn HS, van den Boogert J, Tilanus HW, Sterenberg HJ, de Bruin RW. Monitoring in situ dosimetry and protoporphyrin IX fluorescence photobleaching in the normal rat esophagus during 5-aminolevulinic acid photodynamic therapy. *Photochem Photobiol* 2003; 78(3):271-277.
22. Robinson DJ, de Bruijn HS, van der Veen N, Stringer MR, Brown SB, Star WM. Fluorescence photobleaching of ALA-induced protoporphyrin IX during photodynamic therapy of normal hairless mouse skin: the effect of light dose

- and irradiance and the resulting biological effect. *Photochem Photobiol* 1998; 67(1):140-149.
23. Morton CA, Brown SB, Collins S, Ibbotson S, Jenkinson H, Kurwa H, Langmack K, McKenna K, Moseley H, Pearse AD, Stringer M, Taylor DK, Wong G, Rhodes LE. Guidelines for topical photodynamic therapy: report of a workshop of the British Photodermatology Group. *Br J Dermatol* 2002; 146(4):552-567.
 24. National Institute of Clinical Excellence (NICE). Photodynamic therapy for non-melanoma skin tumours (including pre malignant and non metastatic tumours). Interventional procedure guidance. Volume 155; 2006.
 25. Calzavara-Pinton PG, Venturini M, Sala R, Capezzer R, Parrinello G, Specchia C, Zane C. Methylaminolaevulinate-based photodynamic therapy of Bowen's disease and squamous cell carcinoma. *Br J Dermatol* 2008; 159(1):137-144.
 26. Peng Q, Soler AM, Warloe T, Nesland JM, Giercksky KE. Selective distribution of porphyrins in skin thick basal cell carcinoma after topical application of methyl 5-aminolevulinate. *J Photochem Photobiol B* 2001; 62(3):140-145.
 27. Ericson MB, Sandberg C, Stenquist B, Gudmundson F, Karlsson M, Ros AM, Rosen A, Larko O, Wennberg AM, Rosdahl I. Photodynamic therapy of actinic keratosis at varying fluence rates: assessment of photobleaching, pain and primary clinical outcome. *Br J Dermatol* 2004; 151(6):1204-1212.
 28. Curnow A, Pye A. Biochemical manipulation via iron chelation to enhance porphyrin production from porphyrin precursors. *J Environ Pathol Toxicol Oncol* 2007; 26(2):89-103.

29. Lee JB, Choi JY, Chun JS, Yun SJ, Lee SC, Oh J, Park HR. Relationship of protoporphyrin IX synthesis to photodynamic effects by 5-aminolaevulinic acid and its esters on various cell lines derived from the skin. *Br J Dermatol* 2008; 159(1):61-67.
30. Kruijt B, de Bruijn HS, van der Ploeg-van den Heuvel A, de Bruin RW, Sterenberg HJ, Amelink A, Robinson DJ. Monitoring ALA-induced PpIX Photodynamic Therapy in the Rat Esophagus Using Fluorescence and Reflectance Spectroscopy. *Photochem Photobiol* 2008; 84(6):1515-1527.
31. Iinuma S, Schomacker KT, Wagnieres G, Rajadhyaksha M, Bamberg M, Momma T, Hasan T. In vivo fluence rate and fractionation effects on tumor response and photobleaching: photodynamic therapy with two photosensitizers in an orthotopic rat tumor model. *Cancer Res* 1999; 59(24):6164-6170.
32. Smits T, Kleinpenning MM, Blokx WA, van de Kerkhof PC, van Erp PE, Gerritsen MJ. Fluorescence diagnosis in keratinocytic intraepidermal neoplasias. *J Am Acad Dermatol* 2007; 57(5):824-831.
33. Morton CA. Methyl aminolevulinate (Metvix) photodynamic therapy - practical pearls. *J Dermatolog Treat* 2003; 14 Suppl 3:23-26.
34. Calzavara-Pinton PG, Venturini M, Sala R. Photodynamic therapy: update 2006. Part 2: Clinical results. *J Eur Acad Dermatol Venereol* 2007; 21(4):439-451.
35. Nadeau V, O'Dwyer M, Hamdan K, Tait I, Padgett M. In vivo measurement of 5-aminolaevulinic acid-induced protoporphyrin IX photobleaching: a comparison of red and blue light of various intensities. *Photodermatol Photoimmunol Photomed* 2004; 20(4):170-174.

36. McIlroy BW, Mann TS, Dysart JS, Wilson BC. The effects of oxygenation and photosensitizer substrate binding on the use of fluorescence photobleaching as a dose metric for photodynamic therapy. *Vibrational Spectroscopy* 2002; 28(1):25-35.
37. Fuchs J, Thiele J. The role of oxygen in cutaneous photodynamic therapy. *Free Radic Biol Med* 1998; 24(5):835-847.
38. Dysart JS, Patterson MS. Photobleaching kinetics, photoproduct formation, and dose estimation during ALA induced PpIX PDT of MLL cells under well oxygenated and hypoxic conditions. *Photochem Photobiol Sci* 2006; 5(1):73-81.
39. Stucker M, Struk A, Altmeyer P, Herde M, Baumgartl H, Lubbers DW. The cutaneous uptake of atmospheric oxygen contributes significantly to the oxygen supply of human dermis and epidermis. *J Physiol* 2002; 538(Pt 3):985-994.
40. Brancaleon L, Moseley H. Effects of photoproducts on the binding properties of protoporphyrin IX to proteins. *Biophys Chem* 2002; 96(1):77-87.
41. Pogue BW, Sheng C, Benevides J, Forcione D, Puricelli B, Nishioka N, Hasan T. Protoporphyrin IX fluorescence photobleaching increases with the use of fractionated irradiation in the esophagus. *J Biomed Opt* 2008; 13(3):034009.

Figures

Figure 1 – Box and whisker plot illustrating the spread of the total PpIX fluorescence observed after three hours of MAL application for patients undergoing complete or partial clearance after the first and second MAL-PDT treatments. The central line of the box represents the median value of the group, the edges are the corresponding inter-quartile values, the whiskers represent the 10th and 90th percentiles of the data and the dots represent outliers.

Figure 2 – Box and whisker plot indicating the percentage change in PpIX fluorescence during light irradiation for complete and partial responders to MAL-PDT. * represents statistical significance at $P < 0.005$ between the complete responders and corresponding partially responding group. The central line of the box represents the median value of the group, the edges are the corresponding inter-quartile values, the whiskers represent the 10th and 90th percentiles of the data and the dots represent outliers.

Figure 3 – Bar chart indicating the percentage of complete, partial and non-responders that underwent a greater than 40, 50 or 60% change in fluorescence during light irradiation in at least one of the MAL-PDT treatments.

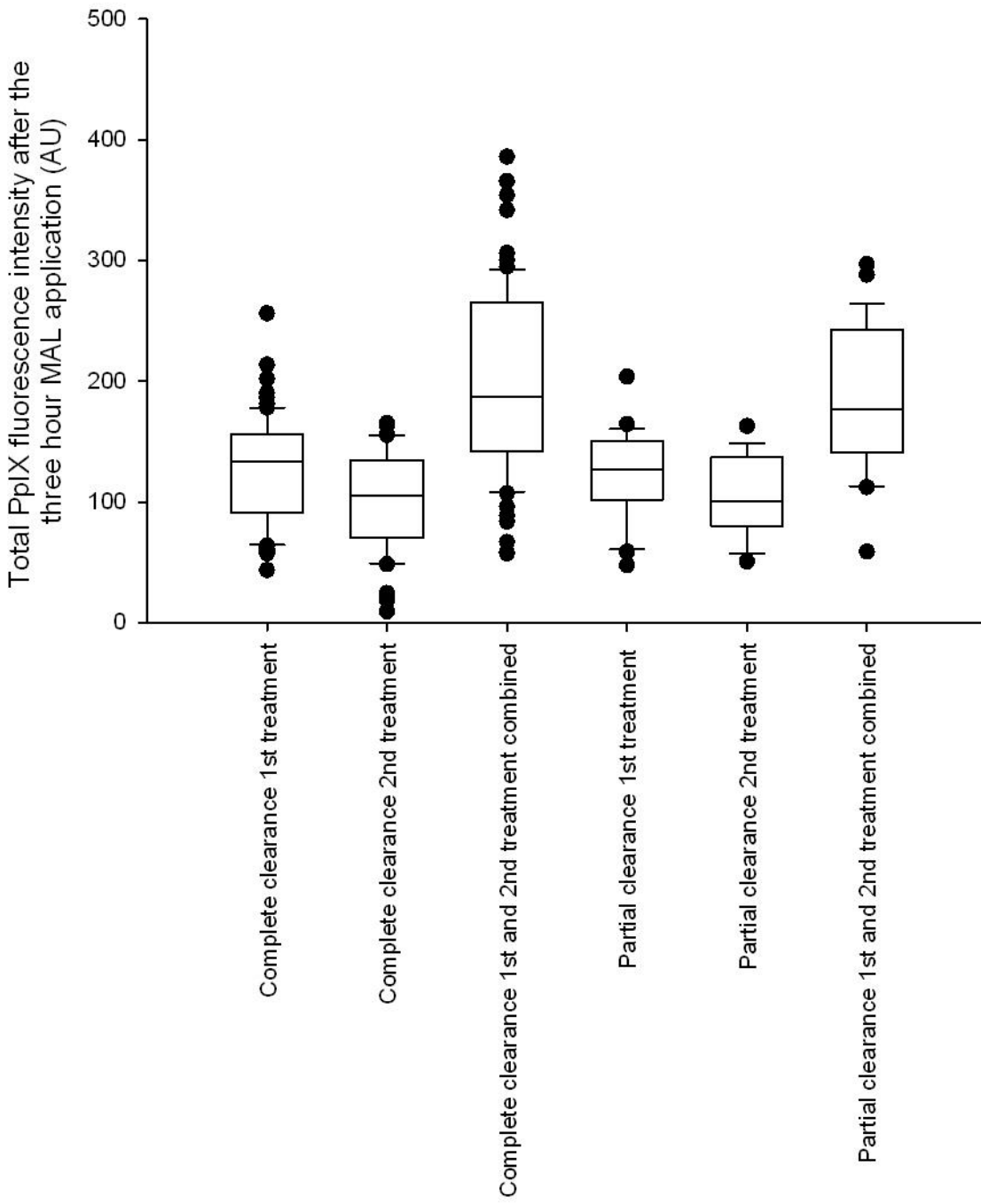


Figure 1

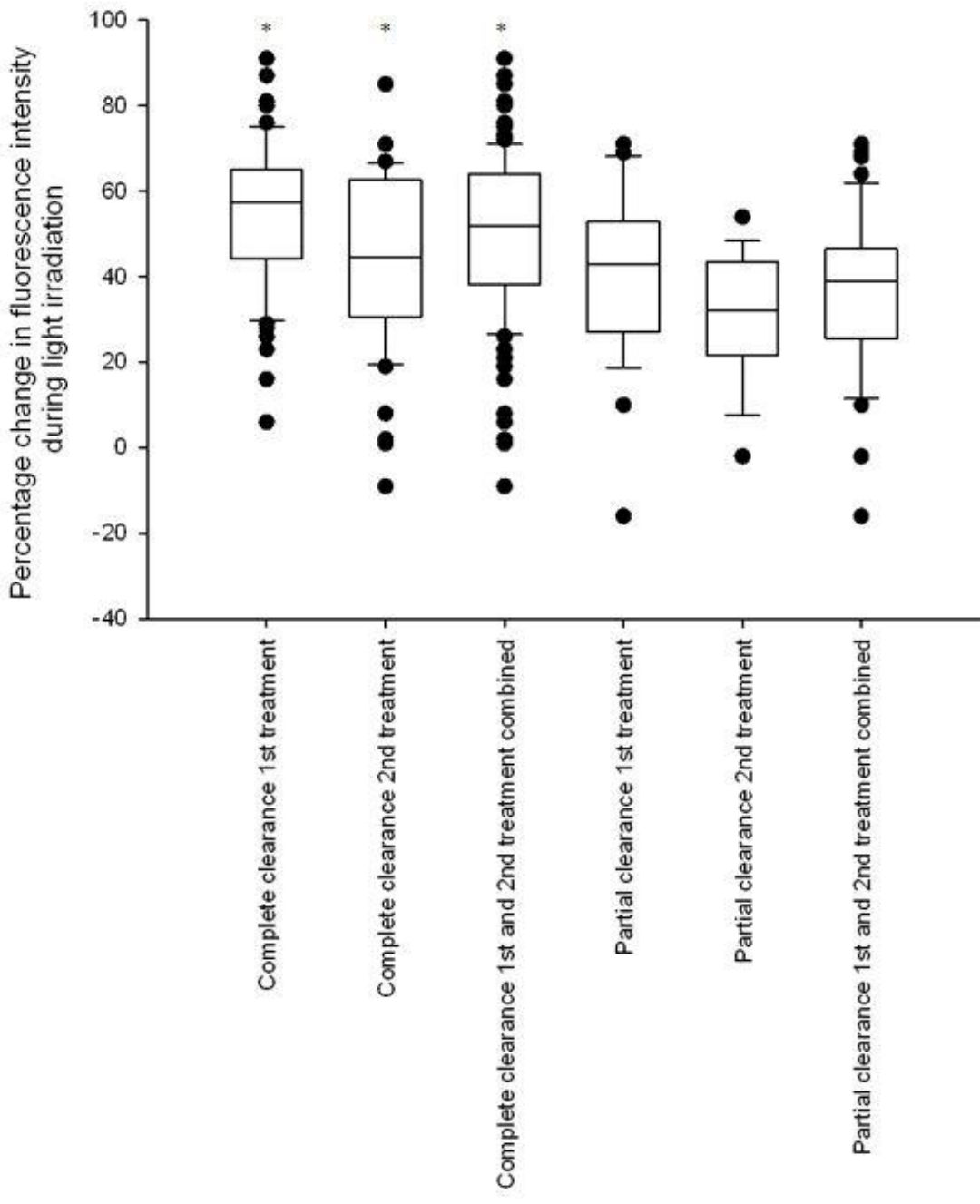


Figure 2

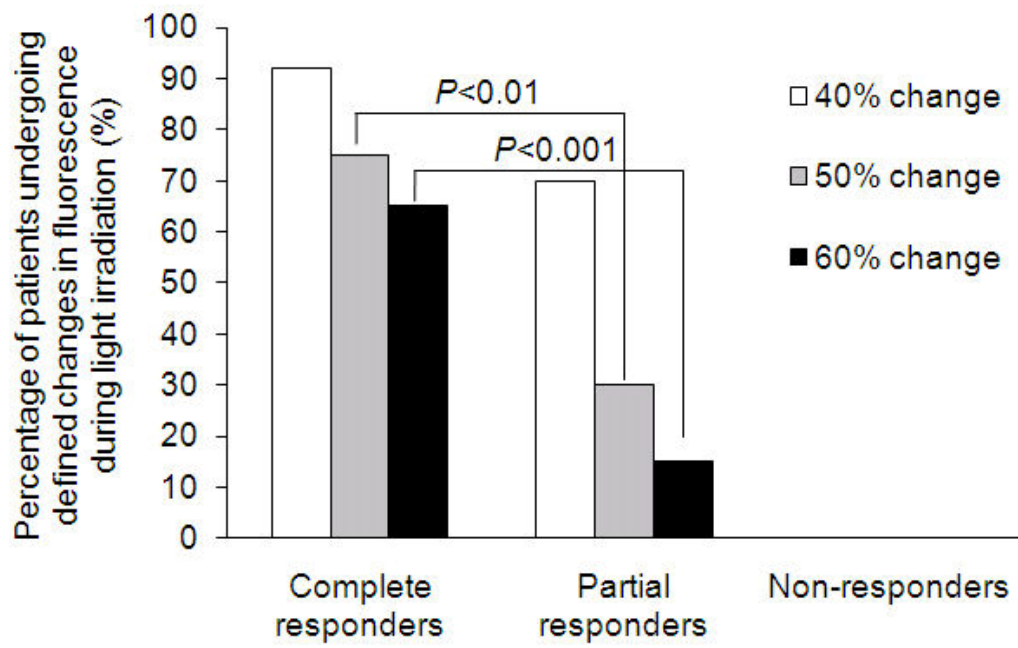


Figure 3