

THE ROLE OF ANTI-GLOMERULAR BASEMENT MEMBRANE  
ANTIBODY IN THE PATHOGENESIS OF  
HUMAN GLOMERULONEPHRITIS\*

BY R. A. LERNER, M.D., R. J. GLASSOCK, † M.D., AND FRANK J. DIXON, M.D.

(From the Department of Experimental Pathology, Scripps Clinic and Research Foundation, La Jolla, California 92037, § and the Cardiorenal Section, Peter Bent Brigham Hospital, Harvard Medical School, Boston, Massachusetts 02115 ||) ¶

PLATES 72-76

(Received for publication 5 July 1967)

The concept that anti-glomerular antibodies might cause glomerulonephritis dates back to the beginning of this century, when Lindemann demonstrated the nephritogenic properties of heterologous anti-kidney antibodies (1). Subsequent work on nephrotoxic serum nephritis has provided precise information concerning the nature and potency of these heterologous nephritogenic antibodies, the location and immunochemical characteristics of the glomerular antigen, and some of the mediators of inflammation activated by the antibody-antigen interaction (reviewed in reference 2). A further step toward implicating this pathogenetic mechanism in nephritis was achieved when it was shown that animals immunized with homologous or heterologous glomerular basement membranes (GBM) could develop glomerulonephritis (3, 4). The demonstration of anti-GBM antibody in the serum and kidneys of such animals and the passive serum transfer of this form of nephritis in sheep (5) and rabbits (6) to normal homologous recipients provided definitive evidence that an animal could, upon appropriate immunization, form nephritogenic anti-GBM antibodies apparently capable of producing an autoimmune glomerulonephritis.

A question still unanswered, however, was whether anti-GBM antibodies were ever formed, particularly in man, in the absence of intentional immunization. While there

\* This is publication number 235 from the Department of Experimental Pathology, Scripps Clinic and Research Foundation, La Jolla, Calif. 92037. Reprint requests should be sent to this address.

† Present address: Department of Medicine, Harbor General Hospital, Torrance, Calif.

§ Supported by U.S.P.H.S. Grant A1-07007, Training Grant 5T1 GM683, and AEC Contract AT(04-3)-410.

|| Supported in part by grants from the John A. Hartford Foundation and U.S.P.H.S. Training Grant T1-A1-00301-02.

¶ With the clinical collaboration of Pediatric Research Laboratories of Variety Club Hospital, University of Minnesota School of Medicine; Clinical Study Center, University of Arkansas Medical Center; Department of Medicine, U.S. Public Health Service Hospital, San Francisco; Department of Surgery, University of California Medical Center, San Francisco; Department of Surgery, Stanford University, Palo Alto; Department of Surgery, University of Utah College of Medicine; and Department of Surgery, Medical College of Virginia.

have been disputed reports of circulating anti-kidney antibodies in some patients with nephritis and certain other diseases, the nature of the renal antigen(s) involved has not been established nor has any relationship of such antibodies to the pathogenesis of nephritis been established. Similarly, during the past decade, there have been many immunofluorescent demonstrations of gamma globulin, presumably antibody, in the glomeruli of human nephritic kidneys. In none of these, however, has the gamma globulin in the glomeruli been identified as antibody to GBM or to any other specific glomerular antigen.

The present studies were designed to look for anti-GBM antibodies in human nephritis both in the circulation and in the kidneys and, if found, to determine their nephritogenic properties. Anti-GBM antibodies were found in the serum and/or kidneys of six nephritic patients. These antibodies would react with GBM antigens *in vitro* and *in vivo*. On passive transfer, they induced an immediate glomerulonephritis in recipient monkeys.

In view of the reasonably well-established role of circulating antibody-nonglomerular antigen complexes in the pathogenesis of serum sickness nephritis (7, 8, 9), experimental allergic glomerulonephritis induced with tubular antigens (EAG-TA) (10), the nephritis of NZB mice (11),<sup>1</sup> systemic lupus erythematosus (12, 13), and possibly acute poststreptococcal nephritis (14, 15), there would appear to be at least two quite distinct and independent immunopathogenic mechanisms which may operate in different forms of experimental and human glomerulonephritis. The relative frequency of these two mechanisms in the various forms of human glomerulonephritis remains to be determined.

### *Materials and Methods*

#### *Analysis of Sera from Nephritic Patients*

250 sera from 50 intact and 25 bilaterally nephrectomized patients were obtained from several centers. In most cases, these sera were kept at  $-20^{\circ}\text{C}$  until used. The diagnoses and clinical courses of the patients were obtained from the physicians in charge. 47 of the intact patients were diagnosed as having glomerulonephritis (acute poststreptococcal 3, subacute 4, chronic 36, unclassified 4). 23 of the bilaterally nephrectomized patients had glomerulonephritis (chronic 15, subacute 4, Goodpasture's syndrome 2, unclassified 2). Of the remaining 5 patients, 3 had chronic pyelonephritis and 2 had polycystic renal disease.

*Gel Diffusion.*—Preparation and characterization of the antigen used in these studies is the subject of separate reports<sup>2</sup> (16). In brief, glomerular basement membrane (GBM) was isolated by the method of Krakower and Greenspon (17) from no less than 30 presumably normal human kidneys obtained at autopsy. The membranes were pooled and extracted with collagenase which solubilized approximately 30% of the membranes. Soluble material thus obtained was desalted by dialysis, lyophilized, and used in gel diffusion studies.

The sera described above were tested for their ability to precipitate soluble GBM antigen in 1% agarose using both the micro-Ouchterlony technique and Holm's modification of the

<sup>1</sup> Lambert, P. H., and F. J. Dixon. Unpublished observations.

<sup>2</sup> Lerner, R. A., F. J. Dixon, and F. E. Young. Isolation and characterization of soluble human glomerular basement membrane antigens. To be published.

template method described by Hanson (18). Each analysis was done in triplicate using respective antigen concentrations of 1000, 500, and 100  $\mu\text{g}/\text{ml}$ . In the case of the micro-Ouchterlony analysis, if no precipitation was observed after 48 hr at 22°C, the antigen and antiserum wells were refilled several times.

*Indirect Immunofluorescence.*—The levels of circulating anti-GBM antibody when present have, in our experience, been so low that small amounts of nonspecific uptake of gamma globulin by the test kidney sections make indirect immunofluorescent interpretation difficult. Presumably normal human kidneys obtained at autopsy, or normal renal tissues obtained at surgery and stored frozen for several weeks, may give such nonspecific reactions. Therefore, in these studies, in the absence of satisfactory human kidney tissue, the target tissues were obtained from a healthy chimpanzee and from healthy Lewis rats sacrificed for this purpose shortly before the studies were performed.

Sera from all 75 patients mentioned above, plus 60 normal males and females, were diluted 1:1 with phosphate-buffered saline, pH 7.2, and then laid over kidney sections for 30 min. The sections were washed twice in saline at room temperature and then stained with fluorescent rabbit anti-human IGG.

*Detailed Studies on Patient G.L. Who Had Precipitating Antibodies Against GBM*

*Clinical Course.*—G.L., in whom detectable amounts of circulating anti-glomerular antibody were found during his anephric period, received a renal allotransplant from his brother. Serial samples of serum were obtained prior to and after bilateral nephrectomy and after transplantation. The course of the renal transplant was judged by 24 hr protein excretion and serum creatinine concentration. For comparison, concurrent studies of proteinuria and renal function were carried out in five patients with nonglomerular disease (i.e., polycystic renal disease and chronic pyelonephritis) who underwent renal transplantation and had clinical courses and treatment protocols similar to G.L.

*Immunopathological Studies.*—

1. *Quantitation of the amount of in vivo kidney-fixing antibody (KFAb) in sera from G.L.:* Several sera from G.L. which precipitated GBM antigens in vitro were pooled and precipitated with ammonium sulfate at 50% saturation. Some of this ammonium sulfate-precipitable globulin was eluted from a diethylaminoethyl cellulose (DEAE) column with 0.0175 M phosphate buffer at pH 8.0. The single protein peak thus obtained was shown to be IGG by immunoelectrophoresis against rabbit anti-human whole serum. This IGG was labeled with  $^{131}\text{I}$  and control human IGG was labeled with  $^{125}\text{I}$  according to the method of McConehey and Dixon (19). Tracer amounts of these two globulins (one labeled with  $^{131}\text{I}$  and the other with  $^{125}\text{I}$ ) were simultaneously injected intravenously into two 500 g squirrel monkeys. These animals were sacrificed 24 hr after injection and the blood, kidneys, liver, spleen, muscle, testicles, and heart were obtained. The ratio of the two isotopes present, as well as the absolute amounts fixed, were determined. The amount of  $^{125}\text{I}$ - and  $^{131}\text{I}$ -labeled proteins which were bound to the particulate kidney fraction were determined by counting the sedimentable portion of a homogenate of the kidney which was first repeatedly washed in phosphate-buffered saline (PBS) and centrifuged at 2000 g for 15 min. The absolute amount of KFAb was calculated according to a previously published formula (5).

2. *Studies on the allotransplanted kidney received by G.L.:* Biopsies of the allotransplanted kidney were performed just prior to and 75 min after restoration of its blood supply in G.L. and 29 days after transplantation. The tissue obtained was processed for light and immunofluorescent microscopy. Immunofluorescent reagents included fluoresceinated rabbit anti-human IGG,  $\beta_{1\text{G}}$ , albumin, and fibrin. Controls for specificity of reagents were similar to those previously reported (20).

*Transfer of Nephritis with Serum From G.L.*—500 mg of ammonium sulfate-precipitable globulin prepared as described above from a pool of sera containing precipitating anti-GBM antibody was injected into each of two unilaterally nephrectomized 500 g squirrel monkeys. On the basis of the previous studies, this represented a total of somewhat less than 1 mg particulate-bound KFAb or approximately 350  $\mu\text{g/g}$  of recipient kidney. Urinary protein excretion was determined by the sulfosalicylic acid method for 3 days prior to and 7 days after injection. A unilaterally nephrectomized control monkey received 500 mg of ammonium sulfate-precipitable globulin obtained by pooling sera from patients with glomerulonephritis who did not have detectable levels of precipitating anti-GBM antibody. Renal tissue obtained by biopsy and at sacrifice 1 and 8 days, respectively, after injection was saved for light and fluorescent microscopy. The kidney obtained at the time of pretreatment unilateral nephrectomy served to control all morphological observations.

*Studies of Eluates of Glomerulonephritic Kidneys*

*Elution.*—Kidneys obtained at nephrectomy from 13 patients with a variety of renal diseases were available for this study. Prior to elution, a frozen piece of each kidney was sectioned and stained with fluoresceinated rabbit anti-human IGG,  $\beta_{1C}$ , and fibrin. After these studies, the cortical portion of each kidney was isolated by dissection, mixed with PBS (pH 7.0–7.2), and homogenized in a Waring Blendor at high speed for 3 min. This homogenate was spun at 2000 g in a refrigerated centrifuge for 30 min at 4°C. The sediment thus obtained was washed in PBS and spun as above, repeatedly, until the supernatant was clear. At this point, the sediment, which consisted of particulate renal cortical material essentially freed from unbound serum proteins and soluble tissue proteins, was mixed with 0.02 M citrate buffer, pH 3.2 (10 parts buffer: 1 part sediment v/v), and incubated at 37°C with constant stirring for 2 hr. After incubation, the mixture was spun at 2000 g for 30 min. The resulting supernatant fraction was immediately brought to pH 7.0 with 0.1 N NaOH, and then dialyzed against several changes of PBS. During this dialysis, a precipitate formed. In early experiments, this precipitate was shown not to contain antibody and in subsequent experiments was discarded. Next, the eluted material was brought to a protein concentration of 10 mg/ml by pressure dialysis and either used at this concentration for indirect fluorescent studies or directly conjugated to fluorescein isothiocyanate (FITC) according to the method of Clark and Shepard (21).

Each eluate was studied by immunoelectrophoresis using rabbit anti-human whole serum, albumin,  $\beta_{1C}$ , and IGG. Some eluates were also studied for the presence of IGA with specific rabbit anti-human IGA.

*In Vitro Studies with Eluates.*—The concentrations of anti-GBM antibody in the positive eluates have been so great and the staining in indirect immunofluorescent procedures so intense that the small amount of nonspecific uptake of gamma globulin by human kidneys, which was a problem in the search for anti-GBM antibodies in sera, presented no difficulty here.

Normal human kidneys were obtained from two patients immediately after death from traumatic injury. The tissue was frozen in liquid nitrogen and used within 1 wk. Tissue sections were fixed in ether alcohol (50:50 v/v) for 10 min, followed by 95% alcohol for 20 min, and then washed in PBS. Sections thus prepared were first overlaid for 45 min with the eluates described above and then washed twice with PBS for 8 min. After this, the sections were incubated for 30 min with fluorescent rabbit anti-human IGG and then washed in two changes of PBS. To rule out the chance that either of the two presumably normal human kidneys used had preexisting localization of IGG in the glomeruli, control sections were stained directly with fluorescent rabbit anti-human IGG. Some studies were done to test the ability of eluates directly conjugated with FITC to stain normal human kidney. In addition, those eluates

shown to stain human kidney were tested for their ability to stain mouse, rat, guinea pig, rabbit, sheep, and monkey kidney.

*Demonstration of Pathogenicity of Eluates.*—Eluate from patient R.G. with Goodpasture's disease was precipitated at 50% ammonium sulfate saturation, and 12 mg of the redissolved precipitate was injected into a 500 g unilaterally nephrectomized monkey. 6 mg of similarly prepared material from patient V.U. with subacute glomerulonephritis was injected into another 500 g unilaterally nephrectomized monkey. In spite of the fact that these eluates had been previously shown not to agglutinate the recipient monkey's RBC's, they were absorbed with a one-third volume of the recipient monkey's packed RBC's prior to injection. These monkeys were studied for proteinuria for 3 days prior to and for 5 days after injection. Renal tissue was obtained by biopsy 24 hr after injection. A complete autopsy was done at sacrifice or at death 6 days after injections. Tissues thus obtained were studied by light and fluorescent microscopy as described above. The kidneys obtained at the time of unilateral nephrectomy were used to control the histologic observations.

## RESULTS

### *Analysis of Sera from Nephritic Patients*

Precipitating antibodies against soluble collagenase extracts of human GBM were found in the sera of only 2 (G.L. and R.E.) of the 23 bilateral nephrectomized nephritics and none of the intact patients. The clinical and morphological diagnosis for the two positive cases was chronic active glomerulonephritis. Sufficient serum for further studies was available only on G.L. Anti-GBM antibody could not be demonstrated in the sera of G.L. prior to nephrectomy, but it was present 5 days after bilateral nephrectomy and persisted in the serum for 55 days during the anephric state and disappeared 24 hr after renal transplantation. During the subsequent 5 months after transplantation, detectable levels of precipitating antibody against GBM have not reappeared in the sera of this patient.

*Indirect Immunofluorescence.*—Of the 47 intact nephritic patients, 2 had sera which fixed to chimpanzee but not to rat kidney basement membranes, while of the 23 nephrectomized nephritics 7 had sera which fixed to chimpanzee but not to rat kidney basement membranes. These reactions could not, however, be considered conclusive evidence of specific anti-GBM antibodies since 6 of 60 sera from presumed normal humans also fixed, to some extent, to the chimpanzee but not to the rat kidney basement membranes. All six of these normal reactors were males. The basis of these reactions and their significance are not clear at this time.

However, of the 70 nephritic patients, 14 had readily demonstrable anti-nuclear antibodies reactive with both chimpanzee and rat nuclei, while only 1 of the 60 controls showed anti-nuclear antibodies. All of these 15 reactors were females, while for the entire series the sex incidence was approximately equal. None of the sera with antinuclear antibodies reacted to GBM. Whether the anti-nuclear antibodies are causative or contributory to the nephritic process or merely incidental by-products of the disease cannot be said. It is clear,

though, that the incidence of anti-nuclear antibodies in unselected adult patients with severe nephritis is high.

*Detailed Studies on Patient G.L. Who Had Precipitating Antibodies Against GBM*

*Clinical Course.*—The details of this patient's clinical course before and after transplantation are given in a separate report.<sup>3</sup> In brief, he was a 29 yr old male with chronic active glomerulonephritis with rapidly progressive renal failure. After institution of intermittent hemodialysis, a bilateral nephrectomy was performed in anticipation of renal allotransplantation. The nephrectomy specimens revealed severe chronic active glomerulonephritis. 55 days after bilateral nephrectomy, a renal allotransplant was performed using his healthy brother as the donor. Immunosuppressive therapy was begun 1 day prior to transplantation. In addition, extra corporeal irradiation of blood and thoracic duct fistula were carried out prior to transplantation. After transplantation, proteinuria was noted but renal function was excellent. The posttransplantation level of proteinuria in G.L. averaged 3 g per day for the first 2 wk and then remained 1 g per day for the next 5 months. In the five nonglomerulonephritic control transplanted patients, proteinuria averaged 3 g per day during the first posttransplantation week, 1 g per day during the 2nd wk, after which the proteinuria declined to less than 0.5 g per day.

*Immunopathological Studies.*—

1. *Quantitation of the amount of in vivo KFAb present in sera from G.L.:* In two separate experiments, 0.15 and 0.18% of the IGG obtained from the anephric patient was specifically bound to the particulate fraction of kidney 24 hr after intravenous injection into a normal squirrel monkey. That these percentages represent specific antibody is further suggested by the fact that, in each experiment, the ratio of experimental globulin to control globulin was higher in the kidney than in any other organ or the blood. The kidney-fixing globulin present in the serum of this patient was similar in amount to that found in nephrectomized sheep with experimentally induced allergic glomerulonephritis (5).

2. *Studies on the allotransplanted kidney received by G.L.:* Biopsies of the allotransplanted kidney taken 30 min after removal from the donor, (after perfusion with bicarbonate-buffered cold Ringer's solution) and 75 min after restoration of blood flow to the graft in the recipient, revealed no significant histologic glomerular alterations. However, IGG and  $\beta_{1C}$ -globulins were already found deposited in a linear fashion along the glomerular capillary walls in the 75 min biopsy. 29 days after transplantation, another renal biopsy was taken which revealed, by routine light microscopy, significant glomerular alterations consisting of focal glomerular basement membrane thickening and epithelial cell

<sup>3</sup> Glasscock, R. J., R. A. Lerner, and J. P. Merrill. Report of a case of recurrent glomerulonephritis in a human renal allotransplant. To be published.

proliferation. Lesions of the interstitium and vessels usually associated with allograft rejection were notably absent. Immunohistologic study of this latter biopsy revealed uniform linear deposits of IGG and  $\beta_{1C}$ -globulins along the glomerular capillary walls and focal, weak, irregular deposits of fibrin. Fig. 1 is a section of the biopsy obtained at 29 days showing part of a glomerulus incubated with rabbit anti-human IGG. Control sections of this biopsy incubated with fluorescent anti-human albumin and anti-human IGG, which had been absorbed with immunochemically pure IGG, showed no staining.

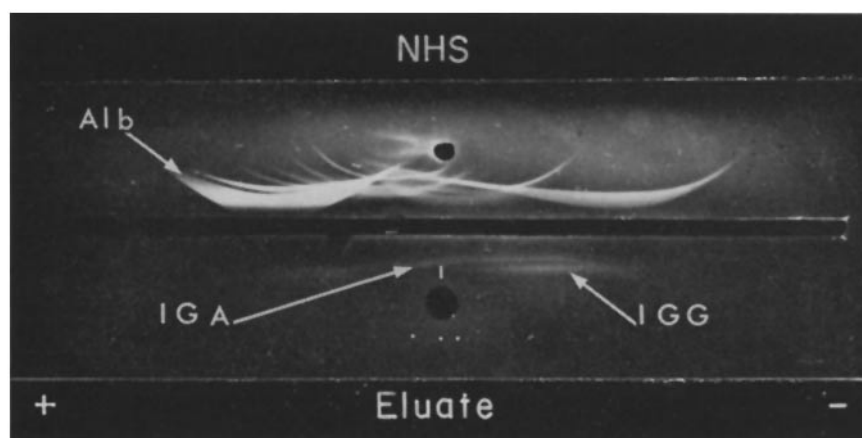
*Transfer of Nephritis with Serum From G.L.*—The injection of 500 mg of globulin obtained from G.L. (containing slightly less than 1 mg KFAb) into each of two unilaterally nephrectomized squirrel monkeys resulted in proteinuria within 6 hr after injection. The amount of proteinuria went as high as 200 mg/100 ml and lasted for 1 wk. Control unilaterally nephrectomized monkeys receiving 500 mg of globulin from other nephrectomized patients who did not have detectable levels of precipitating antibody against GBM had only trace proteinuria, 5–10 mg/100 ml, lasting only 1–2 days. Renal tissue obtained from the monkeys 24 hr after injection of globulin from G.L. showed between 5 and 7 polymorphonuclear leukocytes (PMN) per glomerular cross section, in contrast to an average of <1 PMN per glomerulus from control animals. When this tissue was stained with fluorescent rabbit anti-human IGG and  $\beta_{1C}$ , a linear deposition of IGG and  $\beta_{1C}$  could be found along the glomerular capillary walls. The kidneys obtained at the time of sacrifice (7 days after injection) appeared normal when examined by the light microscope; however, IGG and  $\beta_{1C}$  could still be demonstrated along the glomerular capillary walls. There were no histologic alterations or deposition of IGG or  $\beta_{1C}$  at any time in the glomeruli of monkeys injected with control globulin preparations.

#### *Studies of Eluates of Glomerulonephritic Kidneys*

*Elution.*—A total of 13 kidneys were eluted. Seven of these kidneys were from patients with chronic glomerulonephritis, two from patients with Goodpasture's disease, one from a patient with subacute glomerulonephritis, two from patients with chronic pyelonephritis, and one from a presumably normal patient who died after trauma. In nine cases, IGG and  $\beta_{1C}$  were demonstrated in the glomeruli prior to elution. The deposition of IGG and  $\beta_{1C}$  along the glomerular capillary walls could be shown with certainty to be uniformly linear in four of these nine cases. Two of these four patients had Goodpasture's disease, one had chronic glomerulonephritis, and one had subacute glomerulonephritis. Fig. 2 is a photomicrograph taken of a glomerulus from patient R.G. with Goodpasture's disease which was stained with rabbit anti-human IGG. Our findings, that in this disease IGG and  $\beta_{1C}$  are localized along the glomerular capillaries in a linear fashion, confirm the work of others (22, 23). Fig. 3 shows an entire glomerulus (a) and a portion of a glomerulus (b) similarly stained

from a section of the kidney of patient V.U. with subacute glomerulonephritis. Again, the linear deposition of IGG along the glomerular capillary loops should be noted. Because of the severe glomerular injury and scarring in the remaining five cases of chronic glomerulonephritis where IGG was seen, the exact pattern of distribution could not be determined. Of the four kidneys showing no localization of IGG or  $\beta_{1C}$  in the glomeruli prior to elution, two were from patients with pyelonephritis, one from a normal patient who died after traumatic injury, and one from a patient with chronic sclerosing glomerulonephritis.

The eluates from the nine kidneys known to have glomerular localization of



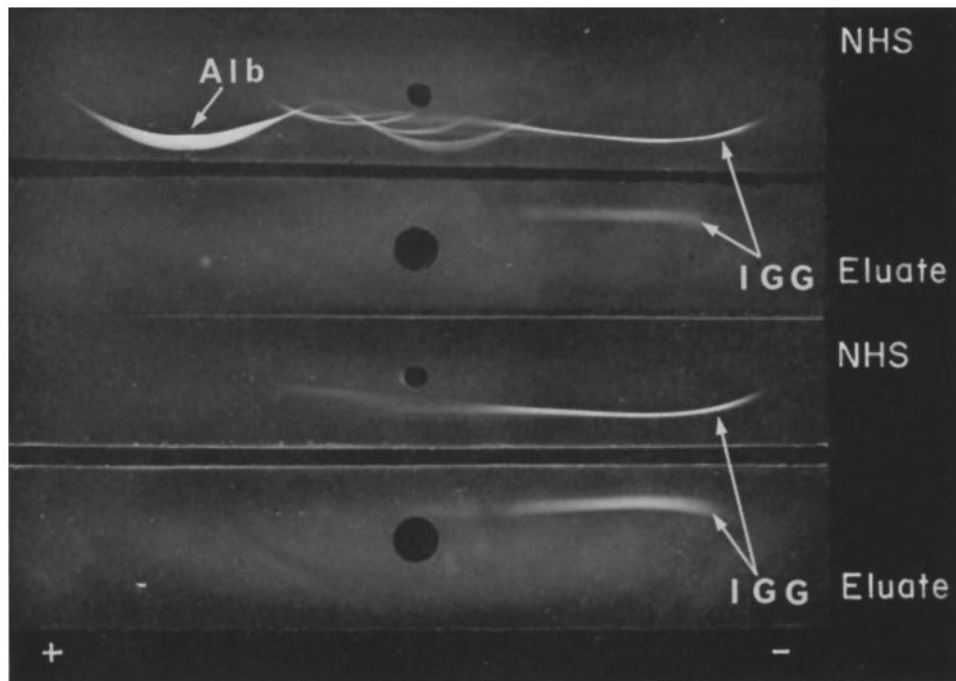
TEXT-FIG. 1. IEP comparing the protein content of the unpurified eluate from the kidney of patient R.G. with Goodpasture's disease to normal human serum. It should be noted that eluate contains predominantly globulins of  $\gamma$  mobility. The reason for the relative "fastness" of the IGG in the eluate is not known. The trough is filled with rabbit anti-human whole serum. Normal human sera (NHS).

IGG by immunofluorescence invariably contained this globulin in higher concentration than any other serum protein. In one case of Goodpasture's disease (R.G.) and in the case of subacute glomerulonephritis (V.U.), where sufficient renal tissue was available for quantitation, approximately  $100 \mu\text{g}$  of IGG per gram of kidney could be eluted with acid citrate. Text-fig. 1 is an IEP which compares the nature of the proteins contained in the unpurified eluate from patient R.G. with Goodpasture's disease to those contained in normal human serum. It should be noted that the eluate primarily contains IGG and IGA and that the IGG is relatively "fast." The identity of IGA was confirmed by using a specific rabbit anti-human IGA antisera which was kindly supplied by Dr. Howard Grey. Text-fig. 2 compares the proteins eluted from the kidney of pa-



tient V.U. with subacute glomerulonephritis to normal human serum. In this case, the eluate contained only IGG. It should be noted that the mobility of the IGG in this eluate was similar to that of untreated IGG from normal human serum.

*In Vitro Studies with Eluted Antibody.*—The eluates from 4 of the 13 kidneys fixed strongly to sections of normal human kidney in vitro. These were from the



TEXT-FIG. 2. IEP comparing unpurified eluate from patient V.U. with subacute glomerulonephritis to normal human serum (NHS). The trough on the top is filled with rabbit anti-whole human serum and the bottom trough is filled with rabbit anti-human IGG. It should be noted that only IGG can be detected in the eluate and that, in this case, the mobility of eluted IGG is similar to the IGG contained in NHS.

four kidneys showing linear deposition of IGG by immunofluorescence. Two of these kidneys were from the patients with Goodpasture's disease, one from a patient with chronic glomerulonephritis, and the fourth from the patient with subacute glomerulonephritis. There was a discrete linear localization of the eluted globulin along GBM's, Bowman's capsule, and tubular basement membranes (TBM). Furthermore, each of these eluates stained GBM, Bowman's capsule, and TBM of sections of mouse, rat, guinea pig, rabbit, pig, lamb, and

monkey kidneys. They did not, however, stain sections of human heart, liver, or lung. Fig. 4 shows a glomerulus from a normal human kidney which was first overlaid with the eluate obtained from the kidney shown in Fig. 2, then stained with rabbit anti-human IGG. There is deposition of IGG along GBM and Bowman's capsule, as well as the TBM. A staining pattern similar to that seen in Fig. 4 was seen when the eluate from the kidney shown in Fig. 3 was reacted with normal human kidney in vitro. The positive staining of rat basement membranes was abolished by absorption of these eluates with purified rat GBM.

*Demonstration of Pathogenicity of Eluted Globulins.*—The monkeys which were injected, one with 6 mg of globulin eluted from the kidney of patient V.U. and one with 12 mg of globulin eluted from the kidney of patient R.G., developed respective proteinurias of 75 and 200 mg/100 ml during the first 24 hr after injection. Control monkeys which received approximately 40 times more human acid-treated globulin than these monkeys developed only mild proteinuria which never exceeded 20 mg/100 ml. The kidney biopsies obtained 24 hr after injection showed PMN accumulation in the glomeruli and moderate swelling and proliferation of fixed glomerular cells. There were no abnormalities in the glomeruli of these monkeys obtained at the time of unilateral nephrectomy before injection of globulin.

Fig. 5 is a glomerulus from the biopsy obtained 24 hr after injection of the eluate from patient V.U. showing proliferation of fixed glomerular cells. Immunofluorescent studies performed on the biopsies obtained 24 hr after injection using anti-human IGG and  $\beta_{1C}$  showed, in both cases, a linear deposition of injected IGG and what was presumed to be host  $\beta_{1C}$  along the glomerular capillary walls. Previous observations showed a significant cross-reaction between anti-human  $\beta_{1C}$  and monkey  $\beta_{1C}$ . Fig. 6 shows the linear deposition of IGG along the glomerular capillary walls in the biopsy of the monkey obtained at 24 hr after injection of the eluate obtained from patient R.G. Fig. 7 is a low power photograph of the same section shown in Fig. 6 which emphasizes the exclusive in vivo localization of IGG to the glomeruli in contrast to the in vitro reaction with tissue sections where basement membranes of tubules, etc., were also stained. This difference is presumed to be the result of differences in the anatomical availability of the various basement membrane antigens to the antibody in vivo and in vitro. There was no staining when the kidney removed prior to injection was incubated with the same fluorescent reagents used above.

On the 4th day after injection of the eluate from patient R.G., the monkey was virtually anuric, and by the 6th day, the blood urea nitrogen (BUN) was 100 mg/100 ml when the animal died. Renal tissue obtained at postmortem (6 days after injection) from this monkey showed proliferation of fixed glomerular cells as well as some casts in the renal tubules. The monkey injected with the eluate from patient V.U. showed a similar course in that by the 6th day after

injection, the BUN was 80 mg/100 ml. In this case, the kidney obtained at sacrifice (6 days after injection) showed severe proliferative glomerulonephritis (Figs. 8 and 9). IGG and  $\beta_{1C}$  were still present along the glomerular capillary walls in the tissue obtained from both monkeys 6 days after injection. No significant histologic alterations were found in any organ other than the kidney at postmortem examination. Furthermore, when the lung, liver, and heart were studied by fluorescent microscopy, no *in vivo* localization of IGG or  $\beta_{1C}$  could be demonstrated in either monkey.

#### DISCUSSION

The present experiments establish the presence of anti-GBM antibodies in some cases of human glomerulonephritis and offer considerable evidence for their participation in the pathogenesis of this disease. The finding of circulating precipitating anti-GBM antibodies in two anephric patients, but in no intact patients, is in keeping with the observations made on sheep with experimentally induced anti-GBM antibodies, in which levels of these circulating antibodies rose after nephrectomy. Apparently the kidneys, with their GBM exposed to the circulation via endothelial pores, are extremely efficient in removing antibody from the blood. The elution of anti-GBM antibodies from the kidneys of four nephritic patients demonstrates not only the presence of these antibodies in nephritics but also their localization in the organ suffering injury. The pattern of fixation of host IGG, presumably the anti-GBM antibody, in a smooth linear fashion along the glomerular capillary walls corresponds precisely to the distribution of heterologous anti-GBM antibodies localized *in vivo* in nephrotoxic serum nephritis and of autologous anti-GBM antibodies in the autoimmune version of this experimental disease. The *in vitro* reactions of the serum and renal eluate antibodies with soluble extracts of homologous and heterologous GBM in gel, plus their reaction with a linear structure in the glomerular capillary walls in frozen sections of kidney, further support their reactivity with antigens of the GBM. The lack of species specificity in the reaction of these eluted antibodies supports the well-recognized fact that there is considerable antigenic cross-reactivity among mammalian GBM's. Finally, the fixation of these antibodies in a linear fashion along the glomerular capillary walls of the kidneys of monkeys to which they had been transferred and of the allotransplanted kidney in a patient with such antibodies demonstrates not only their immunologic reactivity but also their *in vivo* effectiveness in reaching their target antigen.

The demonstration of *in vivo* reaction of these human anti-GBM antibodies with antigens of the glomerular capillary wall, plus the associated initiation of immediate severe glomerulonephritis in monkeys receiving such antibodies, would appear to establish the pathogenicity of these antibodies. As little as 6 mg of IGG eluted from a nephritic kidney produced severe glomerulonephritis

in a unilaterally nephrectomized monkey. Equally convincing evidence of pathogenicity of these antibodies is provided by the events observed in a patient during renal transplantation. Detectable circulating anti-GBM antibody appeared first after bilateral nephrectomy of the patient prior to transplantation and persisted in the circulation throughout the anephric period. With the implantation of a renal allograft, the antibody promptly disappeared from the circulation and host IGG, presumably the antibody, and  $\beta_{1C}$  accumulated in a linear pattern along the glomerular capillary walls of the transplanted kidney. Simultaneously with this deposition of IGG, the kidney developed glomerulonephritis.

The *in vitro* behavior of antibodies, presumably anti-GBM, eluted from kidneys with a linear deposition of IGG along their glomerular capillary walls, should be contrasted to antibodies eluted from kidneys where IGG is localized in a discontinuous, granular fashion, presumably as a result of deposition of circulating antibody nonglomerular antigen complexes. The latter has been most clearly studied in EAG-TA in the rat (24), the NZB mouse (11),<sup>1</sup> and in human systemic lupus erythematosus (SLE) (12, 13). In EAG-TA, where the origin of the antigen has been shown to be the proximal convoluted tubule, acid eluates of IGG from nephritic kidneys stained only tubular cells and not normal glomeruli. Similarly, both in patients with SLE and in NZB mice, where the globulin deposited in the kidney is at least in large part antinuclear antibody, eluates would only stain nuclei or the nuclear material deposited in diseased glomeruli and not normal GBM.

The most important unanswered questions remaining concerning the nephritides associated with anti-GBM antibodies concern the source of the immunizing antigen(s) and the particular events leading to immunization. Both endogenous GBM antigens and exogenous materials cross-reactive with GBM are possible immunogens. The recent findings of GBM antigen(s) in normal animal and human urines and the nephritogenicity of this antigen when it is injected into the animals from which it was obtained suggest that such urinary antigens might be the immunogens in human nephritis (25).<sup>4, 5</sup> If normal urine and, therefore, presumably normal glomerular filtrate contain GBM antigens potentially nephritogenic to their host, any abnormal handling of the filtrate which might expose lymphoid cells to the antigen would be potentially nephritogenic. In such instances, the presence of infectious agents or other exogenous materials might have an adjuvant effect on the response. The additional finding that during active glomerulonephritis the amount and variety of these GBM antigens in the urine increase (25) provides a possible self-accelerating

<sup>4</sup> Lerner, R. A., and F. J. Dixon. The induction of acute glomerulonephritis in rabbits by injection with soluble autologous and homologous glomerular basement membrane (GBM) antigens isolated from normal urine. To be published.

<sup>5</sup> Hawkins, D., and R. A. Lerner. Unpublished observations.

nephritogenic stimulus. The second means of immunizing to GBM, contact with environmental antigens cross-reactive with GBM, has as yet little experimental or clinical support. Claims of cross-reactions between some streptococcal strains and GBM have been made (26, 27), but these cross-reactions have not been readily reproduced nor do they always correlate well with the nephritogenicity of the streptococcal strains employed. Further, morphological and immunohistochemical observations suggest strongly that poststreptococcal glomerulonephritis is caused by the deposition of circulating antibody-antigen complexes and not by anti-GBM antibodies.

While the presence and pathogenetic role of anti-GBM antibodies in some cases of glomerulonephritis seems established, their incidence in adult human glomerulonephritis is still not clear. The present method of testing sera for anti-GBM antibodies is bound to underestimate their frequency in nephritics for several reasons: First, sera obtained from patients with their kidneys would have low levels of antibody at best, since the kidneys would remove much of it from the circulation as was observed in sheep with experimental nephritis; second, sera from the nephrectomized end stage chronic glomerulonephritics might well have much lower levels of antibody than would have been present earlier in the disease because of loss of glomerular antigenic stimulation and any immunosuppressive effects of uremia and debilitation; and third, our test system is not the most sensitive nor is it certain that the antigens employed contained all the GBM determinants. Thus our observed incidence of two patients with circulating anti-GBM antibodies of the 23 nephrectomized glomerulonephritics is doubtless too low. Significantly, the two nephrectomized patients who did have circulating anti-GBM antibodies had rapidly progressing disease and did not have a prolonged period of terminal renal failure prior to nephrectomy. It is possible that more extensive immunofluorescent studies might positively identify additional anti-GBM containing sera. The incidence of four of nine glomerulonephritic kidney eluates containing anti-GBM antibodies is probably more realistic, although the series is too small to allow definitive conclusions. Perhaps the best idea of the frequency of anti-GBM antibodies can be obtained from immunofluorescent staining of renal biopsies taken during early or active disease for host IGG or  $\beta_{1C}$ . Such observations in our experience agree approximately with the kidney eluate data. If host IGG and  $\beta_{1C}$  are present in a distinct, sharp, linear pattern along the GBM, this is presumptive evidence of anti-GBM antibodies. Using this criterion, it appears that anti-GBM antibodies are present in: (a) all cases of Goodpasture's disease now studied, (b) somewhat less than half of the cases of subacute chronic glomerulonephritis of adults, (c) a smaller proportion of the membranous glomerulonephritides of children, and (d) few if any, of the acute poststreptococcal glomerulonephritides and lupus nephritides. That this pathogenetic mechanism may also affect human renal transplants is suggested by our finding of linear deposits of IGG and  $\beta_{1C}$  along

the glomerular capillary walls in several allotransplants in which glomerular lesions and persistent proteinuria developed soon after transplantation.<sup>6</sup> Such glomerular localization of IGG and  $\beta_{1C}$  has not been a feature of allograft injection alone<sup>6</sup> (28).

The data presented above suggest that, if anti-GBM antibody can be demonstrated either in the circulation or fixed to the kidneys of patients with glomerulonephritis, such patients are relatively poor prospects for immediate renal transplantation. Although these data are preliminary, it would seem that patients producing anti-GBM antibodies may well develop early glomerulonephritis in a transplanted kidney. Such recurrent glomerulonephritis in the transplant, if severe, may be mistaken for homograft rejection as happened in two of the six cases reported here. Whether immunosuppressive therapy, especially during the anephric period prior to transplantation, will suffice to terminate anti-GBM antibody production is not certain, but the successful allografting of one of the Goodpasture's disease patients in this series would suggest that this may be the case.

#### SUMMARY

These observations established the presence of anti-GBM antibodies in the sera and/or kidneys of six humans with glomerulonephritis. Further, it seems clear that these antibodies do combine with the host's glomeruli *in vivo* and with GBM antigen of several species *in vitro*.

Transfer of acute glomerulonephritis to normal recipient monkeys was possible with serum or renal eluate IGG from the three patients with anti-GBM antibodies in whom sufficient material was available. Based on this transfer of nephritis and on the presence of these antibodies at the site of injury in the nephritic kidneys of both the patients and the recipient monkeys, it seems likely that they are at least a contributing, if not primary, cause of the glomerular injury.

The frequency of anti-GBM antibodies in human nephritis is not certain, but on the basis of preliminary observations it would appear that they are present in all cases of Goodpasture's nephritis and somewhat less than half of the cases of subacute and chronic glomerulonephritis of adults.

The nature and source of immunogen stimulating the production of anti-GBM antibodies is not known, but the presence of potentially nephritogenic GBM antigens in normal urine raises the question of possible autoimmunization.

From a practical point of view, it appears that patients forming anti-GBM antibodies may not be good candidates for renal transplantation since they are likely to produce in the transplants the nephritic changes already suffered by their own kidneys.

*Note Added in Proof.*—Since this manuscript was submitted, kidneys from 15 patients with glomerulonephritis have been eluted. Anti-GMB antibody was demon-

<sup>6</sup> Glasscock, R. J. Unpublished observations.

strated in the eluates from 3 of the 15. Of the positive eluates, one was from a patient with Goodpasture's disease and two were from patients with chronic glomerulonephritis.

The authors would like to thank the many investigators who sent serum and kidney samples to us. We are indebted to Doctors J. P. Merrill, J. E. Murray, G. J. Dammin, and C. L. Hammers for providing material for study from G.L. and other cases. We are also grateful for the contributions of Doctors Ted Knicker, W. J. Flanigan, A. Fish, R. Good, G. M. Williams, R. Vernier, J. Najarian, J. Mannick, S. Kountz, A. Michael, and L. Burrows. The authors would also like to thank Dr. Sun Lee who performed all surgical procedures on the monkeys.

#### BIBLIOGRAPHY

1. Lindemann, W. 1900. Sur le mode d'action de certains poisons rénaux. *Ann. Inst. Pasteur.* **14**:49.
2. Unanue, E. R., and F. J. Dixon. 1967. *Advances in Immunology*. Academic Press Inc., New York. **6**:1.
3. Steblay, R. W. 1962. Glomerulonephritis induced in sheep by injection of heterologous glomerular basement membrane and Freund's complete adjuvant. *J. Exptl. Med.* **116**:253.
4. Steblay, R. W. 1962. Some aspects of glomerulonephritis induced in sheep and monkeys by injections of heterologous glomerular basement membrane and Freund's adjuvant. *Ann. Conf. Kidney 1961.* **13**:105.
5. Lerner, R. A., and F. J. Dixon. 1966. Transfer of ovine experimental allergic glomerulonephritis (EAG) with serum. *J. Exptl. Med.* **124**:431.
6. Unanue, E. R., and F. J. Dixon. 1967. Experimental allergic glomerulonephritis induced in the rabbit with heterologous renal antigens. *J. Exptl. Med.* **125**:149.
7. Dixon, F. J., J. D. Feldman, and J. J. Vazquez. 1961. Experimental glomerulonephritis; the pathogenesis of a laboratory model resembling the spectrum of human glomerulonephritis. *J. Exptl. Med.* **113**:889.
8. Germuth, F. G. 1953. A comparative histologic and immunologic study in rabbits induced hypersensitivity of the serum sickness type. *J. Exptl. Med.* **97**:257.
9. Dixon, F. J., J. J. Vazquez, W. O. Weigle, and C. G. Cochrane. 1958. Pathogenesis of serum sickness. *Arch. Pathol.* **65**:18.
10. Edgington, T. S., R. J. Glassock, and F. J. Dixon. 1967. Autologous immune-complex pathogenesis of experimental allergic glomerulonephritis. *Science.* **155**:1432.
11. Mellors, R. C. 1967. Autoimmune disease in NZB/BL mice. *J. Exptl. Med.* **122**:25.
12. Krishnan, C., and M. H. Kaplan. 1967. Immunopathologic studies of systemic lupus erythematosus. *J. Clin. Invest.* **46**:569.
13. Koffler, D., P. Schur, and H. Kunkel. Immunological studies concerning the nephritis of systemic lupus erythematosus. *J. Exptl. Med.* **126**:607.
14. Michael, A. F., Jr., K. N. Drummond, R. A. Good, and R. L. Vernier. 1966. Acute poststreptococcal glomerulonephritis: immune deposit disease. *J. Clin. Invest.* **45**:237.
15. Andres, G. A., L. Accinni, K. C. Hsu, J. B. Zabriskie, and B. C. Seegal. 1966. Electron microscopic studies of human glomerulonephritis with ferritin-conjugated antibody. *J. Exptl. Med.* **123**:399.

16. Lerner, R. A., F. J. Dixon, F. E. Young, and R. J. Glassock. 1967. Isolation and characterization of soluble human glomerular basement membrane (HuGBM) antigens and the demonstration of pathogenic antiglomerular antibody in man. *Federation Proc.* **26**:2718.
17. Krakower, C. A., and S. A. Greenspon. 1951. Localization of the nephrotoxic antigen within the isolated renal glomerulus. *Arch. Pathol.* **51**:629.
18. Hanson, L. A. 1959. Immunological analysis of streptococcal antigens and human sera by means of diffusion-gel methods. *Int. Arch. Allergy Appl. Immunol.* **14**:279.
19. McConahey, P. J. and F. J. Dixon. 1966. A method of trace iodination of proteins for immunologic studies. *Int. Arch. Allergy Appl. Immunol.* **29**:185.
20. Lerner, R. A. and F. J. Dixon. 1967. Spontaneous glomerulonephritis in sheep. *Lab. Invest.* **15**:1279.
21. Clarke, H. F., and C. C. Shepard. 1963. Dialysis technique for preparing fluorescent antibody. *Virology.* **20**:642.
22. Duncan, D. A., K. N. Drummond, A. F. Michael, and A. F. Vernier. 1965. Pulmonary hemorrhage and glomerulonephritis. *Ann. Internal Med.* **62**:920.
23. Sturgill, B. C., and F. B. Westervelt. 1965. Immunofluorescent studies in a case of Goodpasture's syndrome. *J. Am. Med. Assoc.* **194**:914.
24. Grupe, W. E., and M. H. Kaplan. 1967. A proximal tubular antigen in the pathogenesis of autoimmune nephrosis. *Federation Proc.* **26**:1779.
25. Hawkins, D. 1967. Basement membrane material excreted during acute immunologic renal injury. *Federation Proc.* **26**:2724.
26. Holm, S. E. Precipitinogens in beta-hemolytic streptococci and some related human kidney antigens. *Acta Pathol. Microbiol. Scand.* In press.
27. Markowitz, A. S., and C. F. Lange. 1964. Streptococcal related glomerulonephritis. I. Isolation, immunochemistry and comparative chemistry of soluble fractions from type 12 nephritogenic streptococci and human glomeruli. *J. Immunol.* **92**:565.
28. Feldman, J. D. and S. Lee. 1967. Renal homotransplantation in rats. I. Allogeneic recipients. *J. Exptl. Med.* **126**:783.

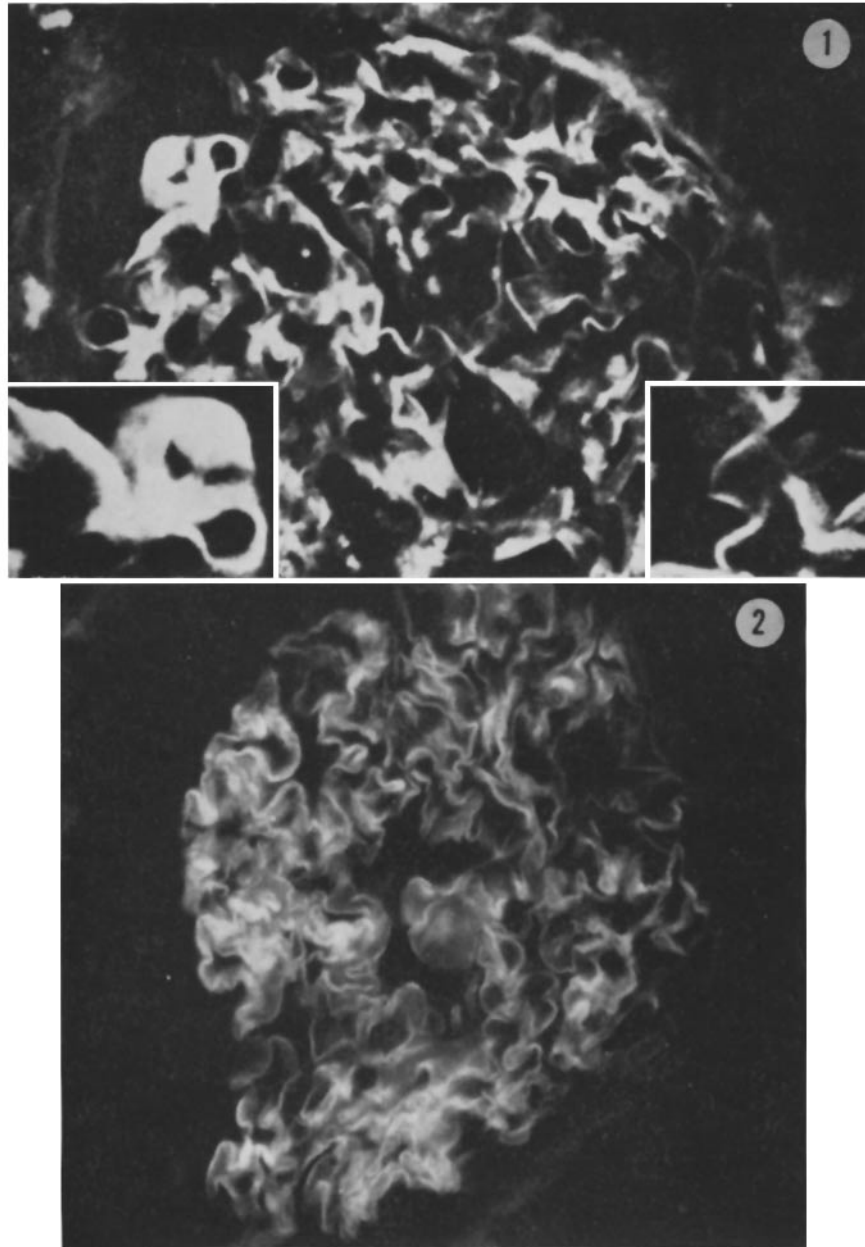
#### EXPLANATION OF PLATES

##### PLATE 72

FIG. 1. Section of the biopsy obtained from G.L. 29 days after renal transplantation. This section was incubated with rabbit anti-human IGG. Note the linear deposition of IGG along the glomerular capillary walls. The inserts emphasize the *linear* deposition of IGG at higher magnification.  $\times 450$ .

FIG. 2. A glomerulus from the kidney of patient R.G. with Goodpasture's disease incubated with rabbit anti-human IGG. Note the linear deposition of IGG along the glomerular capillary walls.  $\times 350$ .

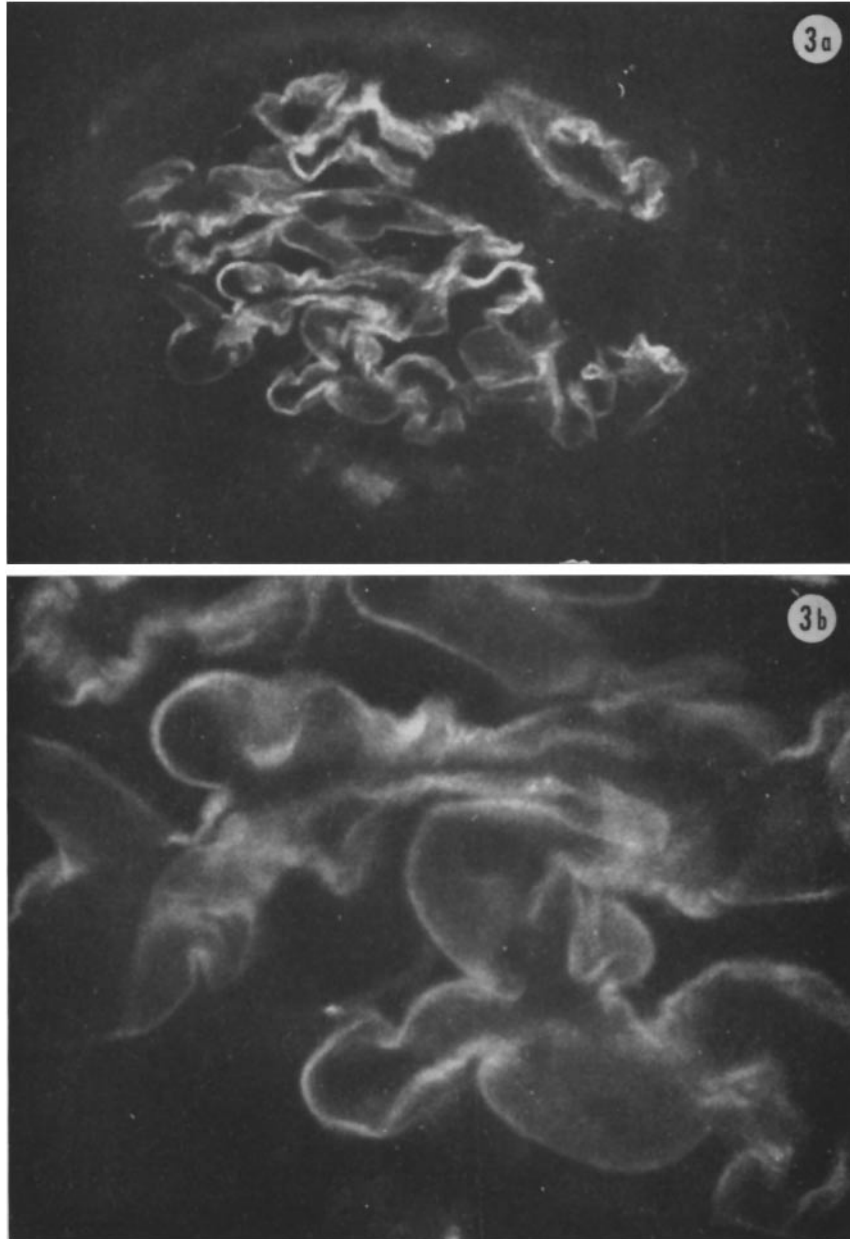




(Lerner et al.: Anti-glomerular antibody in human nephritis)

PLATE 73

FIG. 3. A low power (*a*) and a high power (*b*) photograph of a glomerulus from patient V.U. with subacute glomerulonephritis. The section was incubated with rabbit anti-human IGG. The linear distribution along GBM should be noted.  $\times 325;600$ .

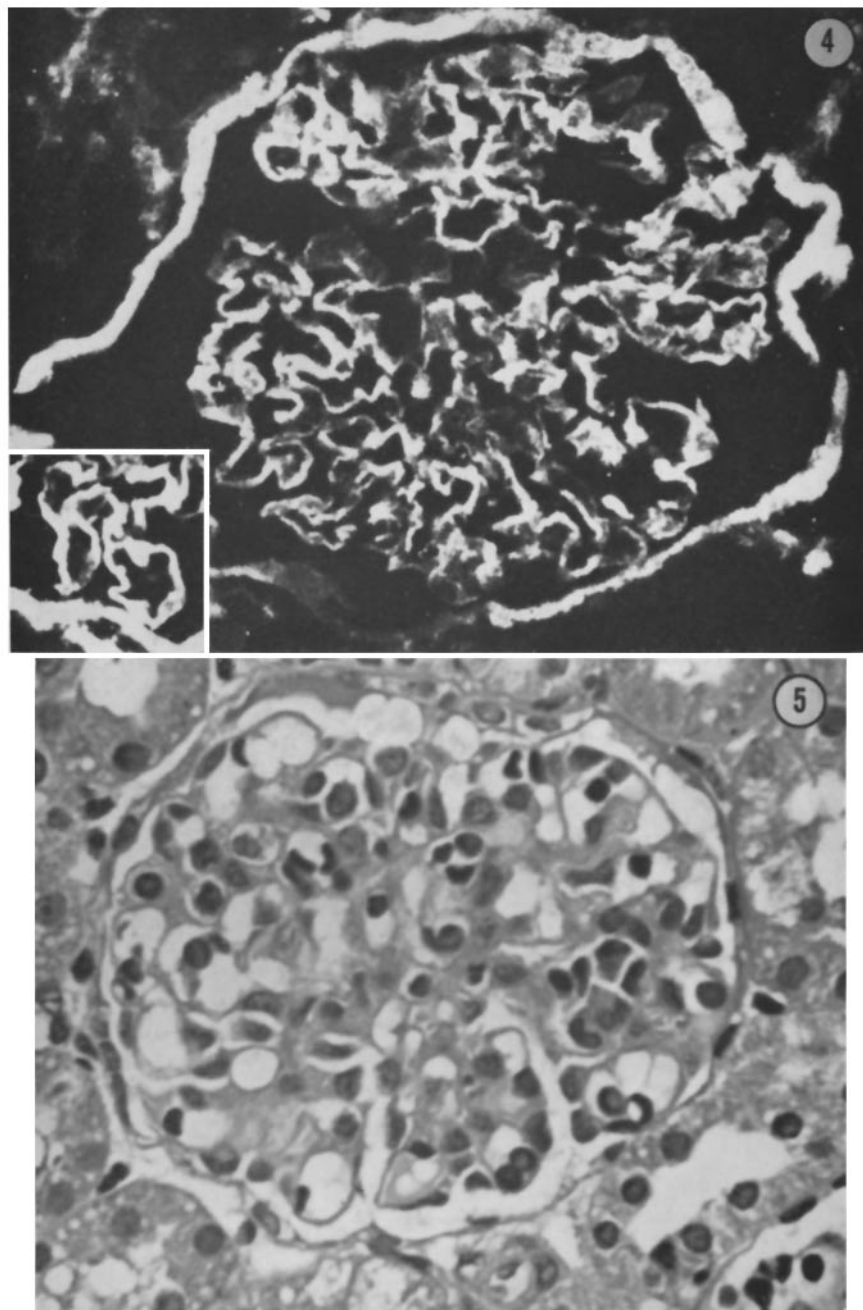


(Lerner et al.: Anti-glomerular antibody in human nephritis)

PLATE 74

FIG. 4. A glomerulus from a normal kidney which was first incubated with the eluate from the kidney shown in Fig. 2 and then stained with rabbit anti-human IGG. The insert is a portion of another glomerulus from the same section. Note the linear deposition of IGG along the glomerular capillary wall, as well as Bowman's capsule.  $\times 450$ .

FIG. 5. A glomerulus from a monkey 24 hr after the injection of globulin eluted from the kidney of patient V.U. with subacute glomerulonephritis. Note the proliferation of fixed glomerular cells.  $\times 350$ .

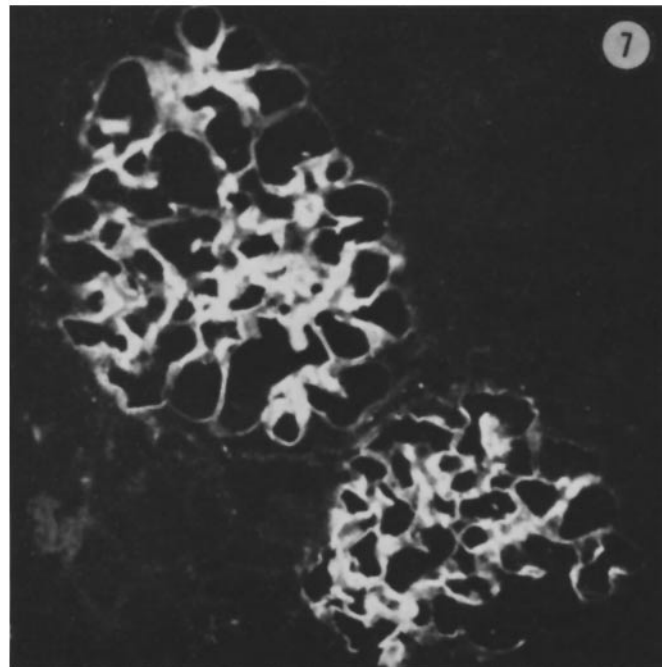
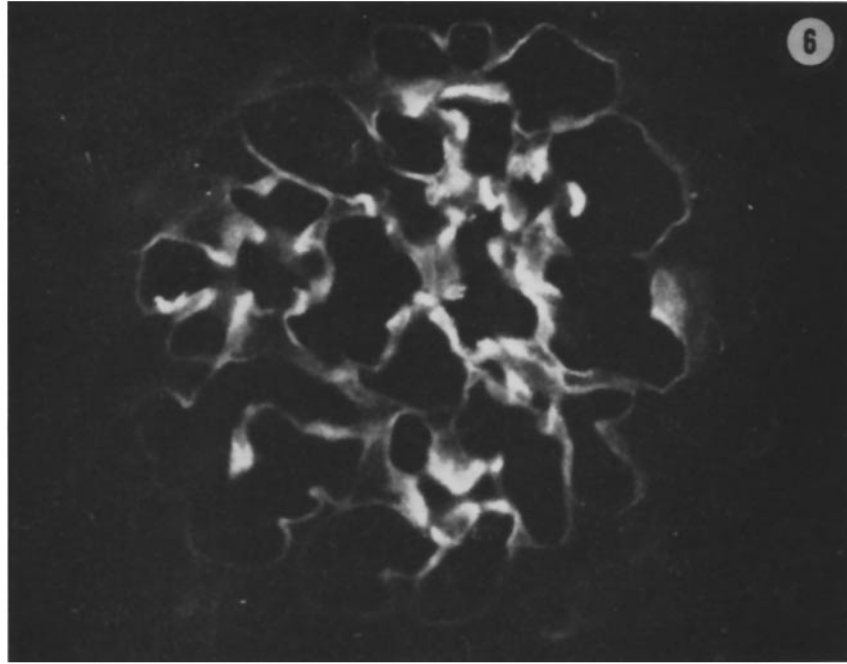


(Lerner et al.: Anti-glomerular antibody in human nephritis)

PLATE 75

FIG. 6. A glomerulus from the monkey kidney biopsied 24 hr after injection of globulin eluted from a kidney of patient R.G. with Goodpasture's disease. This section had been incubated with rabbit anti-human IGG and demonstrates the localization of the injected globulin in a linear fashion along GBM.  $\times$  350.

FIG. 7. A lower power view of the same section shown in Fig. 6 showing the specific localization of the injected globulin to the glomeruli.  $\times$  250.



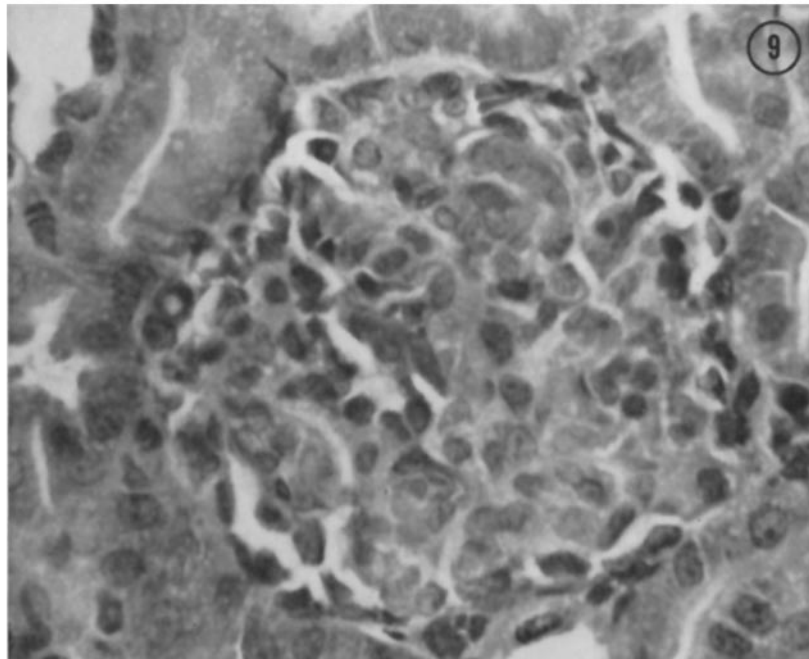
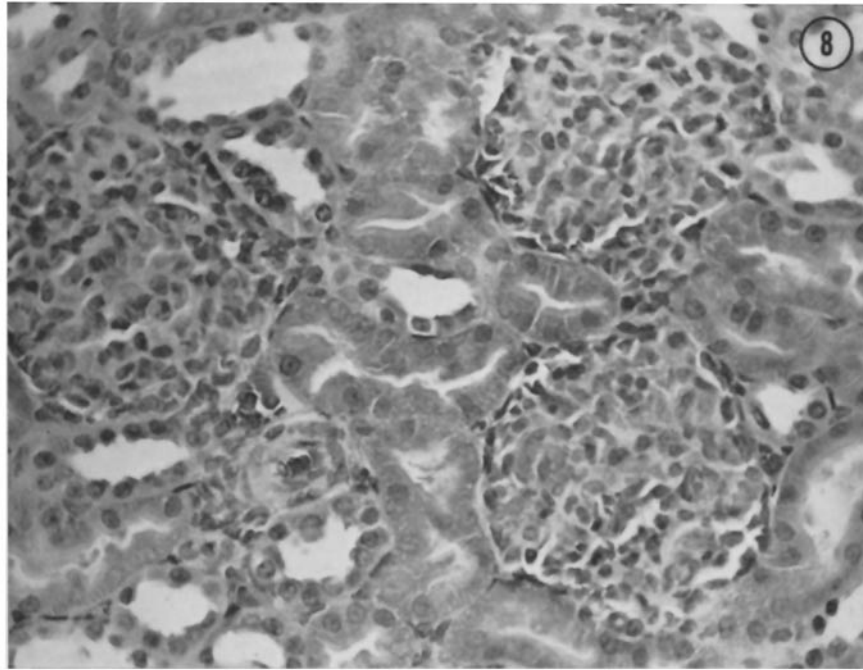
(Lerner et al.: Anti-glomerular antibody in human nephritis)

PLATE 76

FIG. 8. A low power view of three glomeruli showing proliferation of fixed glomerular cells from a monkey 6 days after the injection of globulin eluted from the kidney shown in Fig. 3.  $\times 200$ .

FIG. 9. A high power view of a single glomerulus from the same section shown in Fig. 8 illustrating more clearly the marked proliferation of fixed glomerular cells.  $\times 350$ .





(Lerner et al.: Anti-glomerular antibody in human nephritis)