

# The role of REBOA in the control of exsanguinating torso hemorrhage

Walter L. Biffl, MD, Charles J. Fox, MD, and Ernest E. Moore, MD, Denver, Colorado

Management of patients with exsanguinating torso hemorrhage—that is, noncompressible hemorrhage in the chest, abdomen, or pelvis—is challenging. The fate of the patient with potentially survivable injuries depends on the surgeon's timely and effective action and the availability of necessary resources (e.g., an operating room [OR] and staff, blood products, equipment, and supplies). The current approach is to perform emergency surgery with the occasional use of resuscitative thoracotomy (RT) in the emergency department (ED) with descending aortic clamping for patients in extremis. Recent clinical reports of resuscitative endovascular balloon occlusion of the aorta (REBOA) have led to discussions about changing paradigms in the management of patients with exsanguinating torso hemorrhage.<sup>1,2</sup> In fact, some have suggested there is a role in patients with massive hemorrhage from solid organ injuries<sup>3</sup> or even in the prehospital arena.<sup>4</sup> Although it is clear that REBOA will and should play a more prominent role in trauma care, a rational and evidence-based approach is in order.

## HISTORICAL PERSPECTIVE

The history of intra-aortic balloon occlusion (IABO) dates back to the Korean Conflict.<sup>5</sup> In 1954, Lt. Col. Carl W. Hughes gave a presentation on hemorrhage control in the Course on Recent Advances in Medicine and Surgery at Walter Reed Army Medical Center.<sup>6</sup> In it, he described the use of IABO catheters in two moribund patients—both of whom died—and speculated that earlier use might prove beneficial to more patients. Whether due to lack of familiarity with the technique, the potential for mesenteric and spinal ischemia, concerns for technical complications, or the unfortunate outcomes of the patients, the use of such catheters was not widely adopted in either the military or the civilian world. In the 1970s and 1980s, the groups from Detroit Receiving Hospital<sup>7</sup> and Denver General Hospital<sup>8</sup> described the performance of RT with descending aortic clamping in the setting of massive hemoperitoneum. It was suggested that limiting subdiaphragmatic hemorrhage, and redistributing blood flow to the myocardium and the brain, might avoid cardiovascular collapse and improve survival. This was arguably a more straightforward technical exercise than IABO catheter

placement and gained widespread acceptance. A subsequent report from Brooklyn advocated IABO over RT as an “effective, comparatively easy, and versatile method for proximal control.”<sup>9</sup> But perhaps because of the high complication rate (35%) reported by Gupta et al.<sup>9</sup>—one case of paraplegia, four cases of the catheter exiting from an aortic injury, and three cases of femoral arterial thrombosis among 23 patients—this technique never supplanted RT with aortic clamping as a salvage maneuver for patients in extremis after abdominal trauma. Recent preclinical and clinical reports by the military have reinvigorated discussion of the use of REBOA in a variety of scenarios as an alternative to RT.<sup>1,10–12</sup> A small series described six successful cases of REBOA deployment in a variety of clinical situations in Houston and Baltimore.<sup>2</sup> This trial garnered a great deal of attention and has led to enthusiasm for learning and applying the technique in civilian centers. Indeed, the current authors (W.L.B., C.J.F., E.E.M.) have all attended training courses. However, it seems that REBOA is prematurely being promoted for broad use. A Joint Theater Trauma System Clinical Practice Guideline was created in June 2014 for use by the U.S. military; it indicated that REBOA be considered as an alternative to RT in the setting of extrathoracic blunt or penetrating injury and severe shock, including prehospital cardiac arrest.<sup>13</sup> Another group has suggested that REBOA might be used in the civilian prehospital arena.<sup>4</sup> And recently, a group from Japan reported a protocol in which they placed REBOA, performed angioembolization of solid organ injuries, and transfused an average of 3.7 L of blood in the course of “successful nonoperative management.”<sup>3</sup>

It is important that this new technique be evaluated rigorously and transparently before widespread adoption.<sup>14</sup> A current multicenter study of the American Association for the Surgery of Trauma is collecting data on patients who undergo aortic occlusion by means of thoracotomy, REBOA, or laparotomy (LAP) with aortic cross-clamping to compare outcomes. This study is likely to provide valuable information on the performance and outcomes in various scenarios, but it will be some time before we see published data from the trial. Furthermore, as designed, the study is unlikely to provide definitive guidance on the optimal means of torso hemorrhage control. As a prospective observational study, there will be inherent patient selection and procedure selection biases and potentially poorly matched subgroups. We submit that the primary maneuvers (RT, REBOA, and LAP) are complementary and doubt that any one approach will prove to be a panacea. It is our opinion that the most appropriate means of torso hemorrhage control must be tailored to the clinical situation.

From the Department of Surgery (W.L.B., C.J.F., E.E.M.), Denver Health Medical Center, Denver, Colorado.

Address for reprints: Walter L. Biffl, MD, Denver Health Medical Center, 777 Bannock St., MC 0206, Denver, CO 80204; email: walter.biffl@dhha.org.

DOI: 10.1097/TA.0000000000000609

## PROPOSED MANAGEMENT ALGORITHM FOR CONTROL OF EXSANGUINATING TORSO HEMORRHAGE

Based on the available evidence, we propose an algorithm for torso hemorrhage control (Fig. 1). The primary maneuver is determined based on the patient's condition and the likely primary source of hemorrhage, as determined by clinical assessment, focused abdominal sonographic examination for trauma (FAST), chest x-ray (CXR), and pelvic x-ray. In the following discussion, the reader is directed to the grid created by hemodynamic conditions (A, B, C, D) and area of primary hemorrhage (1, 2, 3).

### Prehospital Cardiopulmonary Resuscitation

Patients who arrive at the ED with cardiopulmonary resuscitation (CPR) in progress (Fig. 1, column A) should undergo RT in the ED, as long as the duration of CPR does not exceed 15 minutes for penetrating thoracic trauma, 10 minutes for blunt trauma, or 5 minutes for nontorso penetrating trauma.<sup>15</sup> Failure to attain a systolic blood pressure (SBP) more than 70 mm Hg after aortic clamping is a marker of futility.

### Thoracic Hemorrhage

Patients in hemorrhagic shock after penetrating thoracic trauma (Fig. 1, row 1) will generally require emergent thoracotomy. A discussion of optimal incisions is beyond the scope of this article; the reader is referred to a recent "Critical Decisions" algorithm promulgated by the Western Trauma Association.<sup>16</sup> One exception is the patient with thoracoabdominal trajectory. In this case, rapid determination of the cavity with predominant blood loss (abdominal vs. thoracic) and exclusion of pericardial blood using CXR and FAST guide one to the correct body cavity in the correct order.<sup>17</sup>

The patient in extremis, that is, SBP less than 60 mm Hg (Fig. 1, 1B), should have prompt RT in the ED because

cardiovascular collapse is imminent. In this scenario, intra-thoracic hemorrhage can be directly controlled and the descending thoracic aorta can be occluded above the diaphragm to redistribute blood flow to the myocardium and the brain. The deployment of REBOA in the setting of thoracic hemorrhage is not appropriate and potentially dangerous because it could exacerbate hemorrhage from thoracic great vessels. The patient with SBP between 60 and 80 mm Hg needs emergency thoracotomy (Fig. 1, 1C). The decision to perform this in the ED versus the OR is a matter of debate and partly driven by institutional capabilities. A Western Trauma Association multicenter trial found that patients undergoing emergent thoracotomy for penetrating chest trauma had significantly better survival if the thoracotomy was performed in the OR compared with the ED.<sup>18</sup> Despite the selection bias in that trial, it seems reasonable to proceed immediately to the OR if it is available. If the SBP is more than 80 mm Hg, the patient should be taken to the OR immediately for thoracotomy without attempts to further increase the blood pressure (Fig. 1, 1D).

### Abdominal Hemorrhage

Abdominal trauma with hemorrhagic shock (Fig. 1, row 2) is a clear indication for emergent LAP. In the patient in extremis, RT with descending thoracic aortic occlusion limits subdiaphragmatic hemorrhage before LAP and direct hemorrhage control (Fig. 1, 2B). An unanswered question is whether REBOA can be deployed as safely and as rapidly as RT. The 35% complication rate reported by Gupta et al.<sup>9</sup> is germane, as RT—despite the unfavorable conditions under which it is typically performed—has a remarkably low procedure-related morbidity.<sup>8,19,20</sup> At this time, it is our opinion that RT in the ED is preferred; however, local expertise and experience with the procedures may favor REBOA deployed in Zone I of the aorta (Fig. 2). This should be studied in a controlled trial.

Patients with SBP 60 to 80 mm Hg may be best served by immediate transfer to the OR for LAP and direct hemorrhage

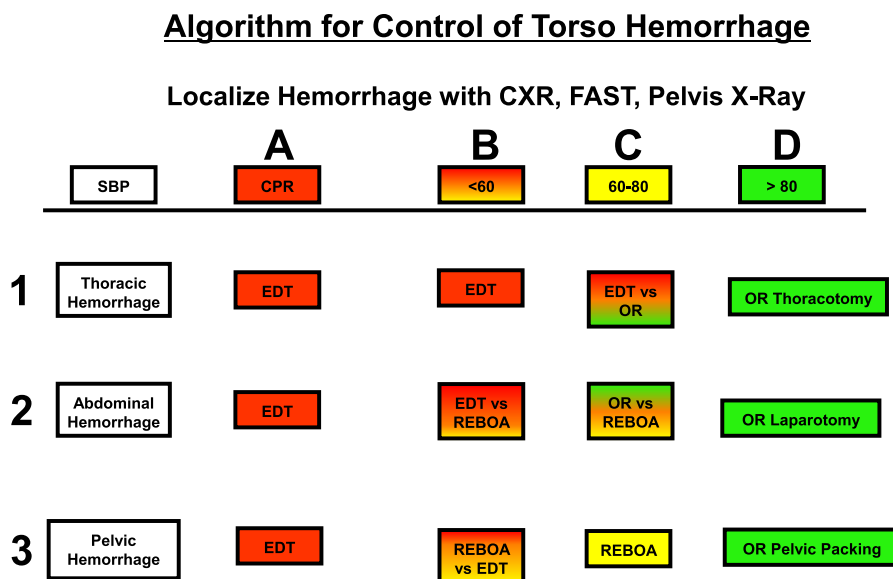
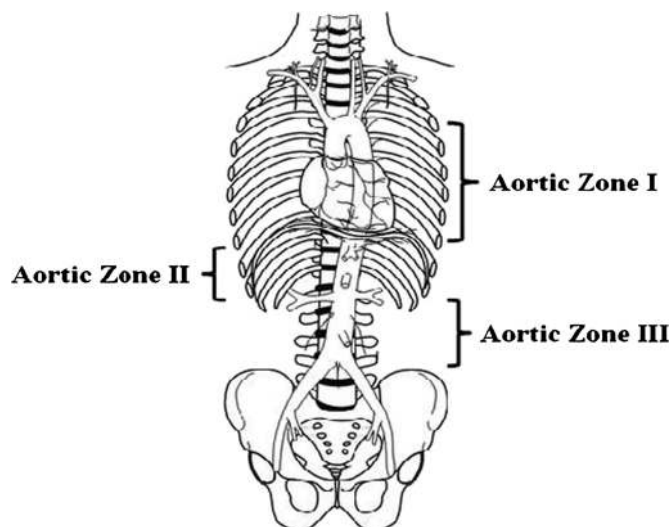


Figure 1. Algorithm for torso hemorrhage control. EDT, emergency department resuscitative thoracotomy.



**Figure 2.** Aortic zones related to REBOA. Zone I extends from the origin of the left subclavian artery to the celiac artery and is a potential zone of occlusion. Zone II extends from the celiac artery to the lowest renal artery and is a no-occlusion zone. Zone III exists from the lowest renal artery to the aortic bifurcation. REBOA in this zone may provide particular utility for instances of pelvic and junctional femoral (contralateral) hemorrhage. Reproduced with permission from Lippincott, Williams & Wilkins. Source: Stannard A, Eliason JL, Rasmussen TE. Resuscitative endovascular balloon occlusion of the aorta (REBOA) as an adjunct for hemorrhagic shock. *J Trauma* 2011;71:1869–1872.

control (Fig. 1, 2C). This avoids delays and procedure-related complications. In a level I or II trauma center with immediate OR availability, this should take only the time it takes for the surgeon to make a decision. Of note, however, Paul et al.<sup>21</sup> found that, in their level I trauma center, mortality from intra-abdominal vascular injury did not improve between the periods 1970 to 1981 and 1996 to 2007 despite in-house trauma surgeons. The authors did not report time to LAP, so it is unclear whether more rapid transfer to OR for LAP, or the use of RT or REBOA, could have improved outcomes (of note, the authors had no patients who underwent RT either in the ED or OR before LAP). It is likely that, to make any progress in improving outcomes, hemorrhage control must happen as quickly as possible. Indeed, Remick et al.<sup>22</sup> analyzed all deaths occurring within the first 4 hours in the Pennsylvania Trauma Outcomes Study. They found that 5% of the cohort died within 23 minutes and 50% had died by 59 minutes. The intervals were even shorter in the setting of penetrating trauma or hypotension. The authors suggest that more rapid transfer to OR is imperative to salvage patients, but it also raises the question whether RT or REBOA in the ED would be beneficial.

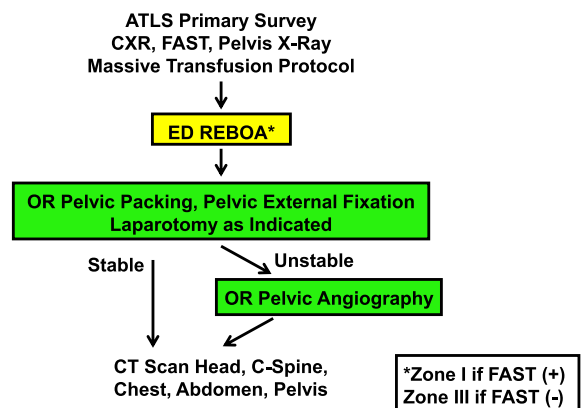
In a setting that includes inherent delay to LAP (e.g., a lower-level trauma center), aortic control in the ED could prove lifesaving. This may prove to be an ideal situation for REBOA, which could temporize life-threatening bleeding while preparing for definitive care. This should be studied in a controlled trial. Patients with an SBP more than 80 mm Hg should proceed to OR without attempts to further increase the blood pressure until direct control of hemorrhage is achieved (Fig. 1, 2D).

**Pelvic Hemorrhage**

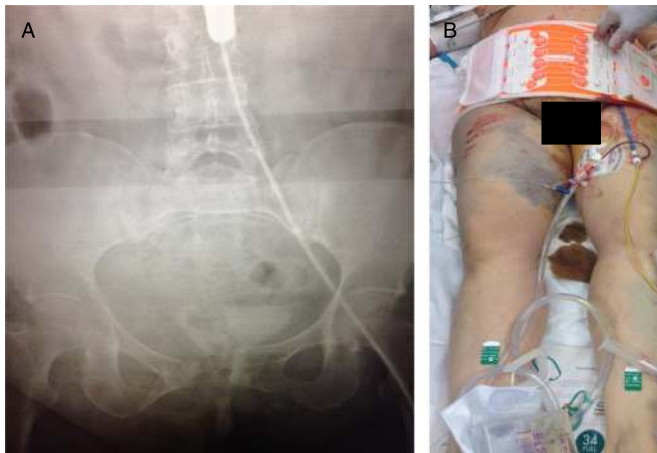Patients with exsanguinating hemorrhage from pelvic fractures (Fig. 1, row 3) have continued to present complex challenges to trauma surgeons. Despite unified algorithms streamlining

multidisciplinary care, mortality has remained high.<sup>23</sup> Pelvic packing can be successful in limiting transfusion requirements and the need for angioembolization.<sup>24</sup> Transfer of patients to the interventional radiology suite for angioembolization is only appropriate when other sources of major hemorrhage have been excluded, as ongoing hemorrhage in an uncontrolled environment can be disastrous. It seems that REBOA deployed in Zone III (Fig. 2) may prove to be the optimal means of immediate hemorrhage control in the patient with pelvic fractures in hemorrhagic shock (Fig. 1, 3B and 3C).<sup>25</sup> Moreover, the arterial catheter allows performance of arteriography in the OR, obviating the need for transport to interventional radiology.

**DHMC Algorithm: Management of Patient with Unstable Pelvic Fractures and Severe Hemorrhagic Shock**



**Figure 3.** Revised Denver Health Medical Center (DHMC) algorithm for the management of hemodynamically unstable patients with mechanically unstable pelvic fractures. ATLS, advanced trauma life support.



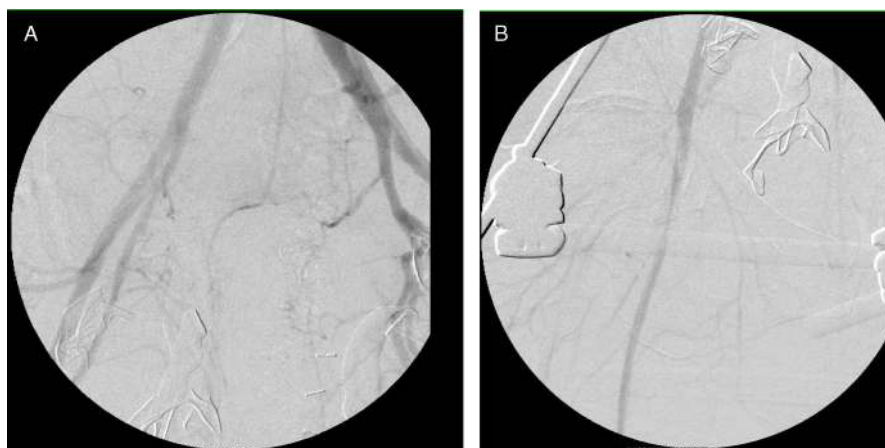**Figure 4.** (A) Plain x-ray in ED demonstrating REBOA balloon inflated in REBOA Zone III. (B) Patient with pelvic binding device secured and REBOA catheter in place in left common femoral artery.

At our institution, we have revised our algorithm for the management of hemodynamically unstable patients with mechanically unstable pelvic fractures (Fig. 3). A recent case illustrates some advantages of this approach. A 60-year-old woman was critically injured in a motor vehicle crash. She was initially taken to a rural level IV trauma center, where she was diagnosed with an unstable pelvic fracture. A computed tomography scan at that facility demonstrated traumatic lumbar hernia and first lumbar vertebral body fracture but no intra-abdominal hemorrhage. Of note, computed tomography also revealed a right common femoral artery injury—a finding that altered the approach and warrants consideration in cases of blind insertion of REBOA. She was transferred by helicopter to our institution, requiring blood transfusion *en route* to maintain perfusing blood pressure. On arrival, her SBP dropped to 50 mm Hg. A REBOA was rapidly inserted via the left common femoral artery, and blood pressure immediately normalized (Fig. 4, A and B). The patient was quickly transferred to the OR where she underwent pelvic packing and external fixation.<sup>26</sup> The REBOA balloon was

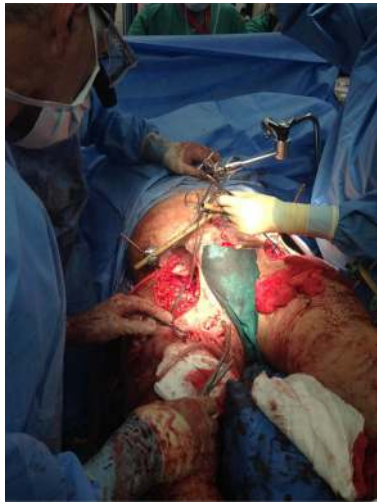deflated, and the patient underwent pelvic arteriography in the OR using fluoroscopy (Fig. 5A). There was no pelvic arterial bleeding, but the right common femoral arterial injury was visualized (Fig. 5B). The femoral artery was repaired (Fig. 6), along with other necessary extremity procedures.

Our recommended algorithm for aortic occlusion (Fig. 1) represents a “straw man” approach for level I trauma centers. Approaches should be tailored to the resources and expertise available at individual centers. In the expert hands of Brenner et al.,<sup>2</sup> REBOA can be placed in 6 minutes. However, a surgeon who is less facile with the technique must honestly appraise his or her skills and available resources before deciding to undertake REBOA versus RT versus LAP in the patient in shock caused by abdominal or pelvic hemorrhage. The use of smaller-diameter catheters and fluoroscopy-free insertion techniques may well facilitate the rapid and safe placement of the catheter.<sup>27</sup> At this time, we recommend against broad application of REBOA in the absence of data demonstrating a favorable benefit-risk profile. To that end, we propose the following future research questions:

1. Is there a role for REBOA in the setting of thoracic trauma?
2. If thoracic injury can be excluded with reasonable certainty, should REBOA replace RT in the setting of blunt trauma arrest?
3. How does REBOA compare with RT for the patient in extremis with abdominal trauma?
4. How does REBOA compare with RT for the patient in extremis with pelvic trauma?
5. Does REBOA offer benefit in a patient with severe shock (SBP, 60–80 mm Hg) after abdominal trauma or should LAP be undertaken without delay?
6. Does REBOA offer benefit in a patient with severe shock (SBP, 60–80 mm Hg) after pelvic trauma or should pelvic packing/external fixation/angioembolization be undertaken without delay?
7. Do new low-profile devices offer significant advantages in terms of improving the risk-benefit profile of REBOA, allowing more rapid deployment and potentially fewer vascular complications?



**Figure 5.** (A) Pelvic arteriogram did not reveal any pelvic arterial contrast extravasation. (B) Right common femoral arteriogram confirmed arterial dissection.



**Figure 6.** Repair of right common femoral artery. Anterior external fixation device is in place, REBOA has been removed, and the left common femoral artery has been repaired.

8. Who should be performing REBOA? What should be the standards for training, credentialing, and competency?

#### DISCLOSURE

The authors declare no conflicts of interest.

#### REFERENCES

- Stannard A, Eliason JL, Rasmussen TE. Resuscitative endovascular balloon occlusion of the aorta (REBOA) as an adjunct for hemorrhagic shock. *J Trauma*. 2011;71:1869–1872.
- Brenner ML, Moore LJ, DuBose JJ, Tyson GH, McNutt MK, Albarado RP, Holcomb JB, Scalea TM, Rasmussen TE. A clinical series of resuscitative endovascular balloon occlusion of the aorta for hemorrhage control and resuscitation. *J Trauma Acute Care Surg*. 2013;75:506–511.
- Ogura T, Lefor AT, Nakano M, Izawa Y, Morita H. Nonoperative management of hemodynamically unstable abdominal trauma patients with angioembolization and resuscitative endovascular balloon occlusion of the aorta. *J Trauma Acute Care Surg*. 2015;78:132–135.
- Chaudery M, Clark J, Wilson MH, Bew D, Yang GZ, Darzi A. Traumatic intra-abdominal hemorrhage control: has current technology tipped the balance toward a role for prehospital intervention? *J Trauma Acute Care Surg*. 2015;78:153–163.
- Hughes CW. Use of an intra-aortic balloon catheter tamponade for controlling intra-abdominal hemorrhage in man. *Surgery*. 1954;36:65–68.
- Hughes CW. Hemorrhage. In: *Recent Advances in Medicine and Surgery (19–30 April 1954)*. Medical Science Publication No. 4, Vol. I. Washington, DC: US Army Medical Service Graduate School, Walter Reed Army Medical Center; 1954:243–249. Available at: <http://history.amedd.army.mil/booksdocs/korea/recad1/ch5-1.html>. Accessed January 17, 2015.
- Ledgerwood AM, Kazmers M, Lucas CE. The role of thoracic aortic occlusion for massive hemoperitoneum. *J Trauma*. 1976;16:610–615.
- Millikan JS, Moore EE. Outcome of resuscitative thoracotomy and descending aortic occlusion performed in the operating room. *J Trauma*. 1984;24:387–392.
- Gupta BK, Khaneja SC, Flores L, Eastlick L, Longmore W, Shaftan GW. The role of intra-aortic balloon occlusion in penetrating abdominal trauma. *J Trauma*. 1989;29:861–865.
- White JM, Cannon JW, Stannard A, Spencer JR, Hancock H, Williams K, Oh JS, Rasmussen TE. A porcine model for evaluating the management of noncompressible torso hemorrhage. *J Trauma*. 2011;71:S131–S138.
- White JM, Cannon JW, Stannard A, Markov NP, Spencer JR, Rasmussen TE. Endovascular balloon occlusion of the aorta is superior to resuscitative thoracotomy with aortic clamping in a porcine model of hemorrhagic shock. *Surgery*. 2011;150:400–409.
- Morrison JJ, Percival TJ, Markov NP, Villamaria C, Scott DJ, Saches KA, Spencer JR, Rasmussen TE. Aortic balloon occlusion is effective in controlling pelvic hemorrhage. *J Surg Res*. 2012;177:341–347.
- U.S. Department of Defense. CENTCOM Joint Theater Trauma System (JTTS) Clinical Practice Guidelines. Resuscitative endovascular balloon occlusion of the aorta (REBOA) for hemorrhagic shock. Available at: [http://www.usaisr.amedd.army.mil/clinical\\_practice\\_guidelines.html](http://www.usaisr.amedd.army.mil/clinical_practice_guidelines.html). Accessed February 2, 2015.
- Biffi WL, Spain DA, Reitsma AM, Minter RM, Upperman J, Wilson M, Adams R, Goldman EB, Angelos P, Krummel T, et al., The Society of University Surgeons Surgical Innovations Project Team. Responsible development and application of surgical innovations: a position statement of the Society of University Surgeons. *J Am Coll Surg*. 2008;206:1204–1209.
- Burlew CC, Moore EE, Moore FA, Coimbra R, McIntyre RC Jr, Davis JW, Sperry J, Biffi WL. Western Trauma Association critical decisions in trauma: resuscitative thoracotomy. *J Trauma Acute Care Surg*. 2012;73:1359–1363.
- Karmy-Jones R, Namias N, Coimbra R, Moore EE, Schreiber M, McIntyre R Jr, Croce M, Livingston DH, Sperry JL, Malhotra AK, Biffi WL. Western Trauma Association critical decisions in trauma: penetrating chest trauma. *J Trauma Acute Care Surg*. 2014;77:994–1002.
- Berg RJ, Inaba K, Okoye O, Karamanos E, Strumwasser A, Chouliaras K, Teixeira PG, Demetriades D. The peril of thoracoabdominal firearm trauma: 984 civilian injuries reviewed. *J Trauma Acute Care Surg*. 2014;77:684–691.
- Karmy-Jones R, Nathens A, Jurkovich GJ, Shatz DV, Brundage S, Wall MJ Jr, Engelhardt S, Hoyt DB, Holcroft J, Knudson MM, et al. Urgent and emergent thoracotomy for penetrating chest trauma. *J Trauma*. 2004;56:664–668.
- Harnar TJ, Oreskovich MR, Copass MK, Heimbach DM, Herman CM, Carrico CJ. Role of emergency thoracotomy in the resuscitation of moribund trauma victims: 100 consecutive cases. *Am J Surg*. 1981;142:96–99.
- Sheppard FR, Cothren CC, Moore EE, Orfanakis A, Ciesla DJ, Johnson JL, Burch JM. Emergency department resuscitative thoracotomy for non-torso injuries. *Surgery*. 2006;139:574–576.
- Paul JS, Webb TP, Aprahamian C, Weigelt JA. Intraabdominal vascular injury: are we getting any better? *J Trauma*. 2010;69:1393–1397.
- Remick KN, Schwab CW, Smith BP, Monshizadeh A, Kim PK, Reilly PM. Defining the optimal time to the operating room may salvage early trauma deaths. *J Trauma Acute Care Surg*. 2014;76:1251–1258.
- Biffi WL, Smith WR, Moore EE, Gonzalez RJ, Morgan SJ, Hennessey T, Offner PJ, Ray CE Jr, Franciose RJ, Burch JM. Evolution of a multidisciplinary clinical pathway for the management of unstable pelvis fractures. *Ann Surg*. 2001;233:843–850.
- Burlew CC, Moore EE, Smith WR, Johnson JL, Biffi WL, Barnett CC, Stahel PF. Preperitoneal pelvic packing/external fixation with secondary angioembolization: optimal care for life-threatening hemorrhage from unstable pelvic fractures. *J Am Coll Surg*. 2011;212:628–635.
- Martinelli T, Thony F, Decléty P, Sengel C, Broux C, Tonetti J, Payen JF, Ferretti G. Intra-aortic balloon occlusion to salvage patients with life-threatening hemorrhagic shocks from pelvic fractures. *J Trauma*. 2010;68:942–948.
- Stahel PF, Mauffrey C, Smith WR, McKean J, Hao J, Burlew CC, Moore EE. External fixation for acute pelvic ring injuries: decision making and technical options. *J Trauma Acute Care Surg*. 2013;75:882–887.
- Scott DJ, Eliason JL, Villamaria C, Morrison JJ, Houston R 4th, Spencer JR, Rasmussen TE. A novel fluoroscopy-free, resuscitative endovascular aortic balloon occlusion system in a model of hemorrhagic shock. *J Trauma Acute Care Surg*. 2013;75:122–128.