

# The Role of Ultrasonically Guided Fine Needle Cytology in the Diagnosis of Focal Liver Lesions in Sulaimani-Kurdistan Region, Iraq

Taha A. Alkarboly<sup>1</sup>, Mohammed Omer Mohammed<sup>1</sup>, Kawa Abdullah Mahmood<sup>1</sup>,  
Muhsin Abubakir<sup>2</sup>

<sup>1</sup>School of Medicine, Faculty of Medical Sciences, University of Sulaimani, Sulaymaniyah, Iraq

<sup>2</sup>Kurdistan Center for Gastroenterology and Hepatology (KCGH), Asulaimanayah, Iraq

Email: alkarbolytaha@gmail.com, dr\_m\_omer@yahoo.com, kawaaya06@yahoo.com, muhsin1247@yahoo.com

**How to cite this paper:** Alkarboly, T.A., Mohammed, M.O., Mahmood, K.A. and Abubakir, M. (2017) The Role of Ultrasonically Guided Fine Needle Cytology in the Diagnosis of Focal Liver Lesions in Sulaimani-Kurdistan Region, Iraq. *Open Journal of Gastroenterology*, 7, 18-27.  
<http://dx.doi.org/10.4236/ojgas.2017.71003>

**Received:** April 9, 2016

**Accepted:** January 19, 2017

**Published:** January 22, 2017

Copyright © 2017 by authors and Scientific Research Publishing Inc.

This work is licensed under the Creative Commons Attribution International License (CC BY 4.0).

<http://creativecommons.org/licenses/by/4.0/>



Open Access

## Abstract

**Background:** Fine Needle Aspiration Cytology (FNAC) under image guidance has gained increasing acceptance as the diagnostic procedure of choice for patients with focal hepatic lesions. It can be performed percutaneously or endoscopically. FNA may also be performed at laparoscopy or laparotomy under direct vision when image guided FNA fails to provide diagnostic tissue. In experienced hands, FNA is safe, minimally invasive, accurate, and cost-effective. However, the main aim of this study is to assess the role of FNAC in the evaluation of focal liver lesions. **Patients and method:** This prospective study was conducted over one year, on 100 patients in Kurdistan Center for Gastroenterology and Hepatology (KCGH) and in Sulaimani General Teaching Hospital. All patients were properly assessed by history analyses and thorough clinical examination. Laboratory investigations including hematological, biochemical, viral markers, and tumor markers were requested. Thus, ultrasonically guided FNA was performed after obtaining a written informed consent from the patients. **Results:** FNAC showed that eighty patients (80%) had secondary liver metastasis. Ten patients (10%) had HCC; three patients had hemangioma; one patient had abscess; and 6 patients had inconclusive result; two patients had simple cyst. Apart from mild post procedure pain, no complication or mortality had been recorded. **Conclusion:** FNAC is simple, easy, rapid and a minimally invasive procedure that has an acceptable diagnostic yield for focal liver lesions.

## Keywords

FNAC, Ultrasound, Focal Liver Lesion, KCGH, Sulaimani

## 1. Introduction

Fine Needle Aspiration (FNA) under image guidance has gained increasing ac-

ceptance as the diagnostic procedure of choice for patients with focal hepatic lesions. It can be performed percutaneously or endoscopically. However, the latter approach is technically difficult for lesions located far away from the tip of the echoendoscope and lesion near the 2nd or 3rd portion of the duodenum due to poor visualization [1].

FNA may also be performed at laparoscopy or laparotomy under direct vision when imaged guided FNA fails to provide diagnostic tissue [2].

The specificity of FNA cytology of the liver approaches 100% and the sensitivity ranges from 67% - 100%, averaging about 85% [3]-[9].

FNA alone is superior to core biopsy alone because the needle is longer and can be guided, and the procedure can be easily repeated. FNA is often preferred in sampling deeply placed lesions, sites adjacent to major vessels, or in situations in which needles are to be passed through the bowel wall. However, both methods are complimentary to each other [10] [11] [12] [13].

The occurrence of complications after hepatic FNA is rare with about 0.5% minor complications, 0.05% major complications requiring surgery, and less than 0.01% mortality [14] [15] [16] [17]. They are limited largely to hemorrhage. The frequency of complications is often related to the vascularity and the location of the lesions as well as the needle size [18]. Another concern is the subcutaneous seeding of tumor along the needle tract during percutaneous liver FNA. It is still an extremely rare complication when using a needle of 23 gauges or less [18] [19] [20].

Absolute contraindications for FNA of liver include uncorrectable bleeding diathesis, lack of a safe access route, e.g. vascular structure in the biopsy path, hydatid cyst and uncooperative patients.

Several studies have shown that the assistance of cytopathologists during the procedure increases overall accuracy [21] [22] [23]. The latter is attributed to the ability to assess specimen adequacy at the time of procedure and to determine if additional tissue is required for diagnosis and/or ancillary studies such as flow cytometry [24].

A markedly elevated serum AFP level, >1000 ng/ml, is highly suggestive of HCC or in children, hepatoblastoma. A moderate increase in serum AFP, however, is non-specific and can be seen in a wide variety of benign and malignant conditions [24] [25].

Aspirates of normal liver consist predominantly of hepatocytes and scattered bile duct epithelial cells. Other cell types such as endothelial cells and Kupffer's cells are infrequently noted [24] [25] [26].

Hepatocellular carcinoma (HCC) is the most common primary hepatic malignancy [26]. Cirrhosis may be sampled by FNA when a dominant nodule mimics a HCC radiologically. The cytology of cirrhotic liver is similar to that of normal liver [27] [28]. AFP level and the finding of a single lesion with or without satellite lesions on imaging, favor a primary tumor over metastatic disease [27].

Up to the knowledge of the researcher, no previous scientific study has been conducted about ultrasonically guided FNA in Sulaimani city or Kurdistan re-

gion. Therefore, the purpose of this study is to examine the diagnostic value of ultrasonically guided percutaneous FNA cytology in the diagnosis of focal liver lesions.

## 2. Patients and Methods

This is a prospective study conducted in Kurdistan center for Gastroenterology and Hepatology and the Sulaimani General Teaching Hospital over one year. After the agreement by the ethical committee of the School of Medicine, University of Sulaimani, one hundred patients with Focal liver lesions were studied.

### Inclusion Criteria

Adult patients with Focal liver lesion(s) that were identified by imaging studies (ultrasound, Computerized Tomography, Magnetic Resonant Imaging) were included.

### Exclusion Criteria

1. All cystic lesions proved by imaging studies.
2. Any lesion less than 1 cm in diameter (difficult to target).
3. Any inaccessible lesion deeper than the length of 22 G  $\times$  3<sub>1/2</sub> spinal needle
4. Gross Ascites.
5. Un-cooperative patients.
6. Uncorrectable coagulopathy (INR > 2.5), by fresh frozen plasma and/or Vitamin K
7. Patient's refusal.

We obtained informed consent from the patients, and after taking proper history and performing a thorough examination, ten ml venous blood were aspirated for the following laboratory tests; (complete blood Count, ESR, TSB, AST, ALT, PT, INR, Serum Albumin, Blood Urea, Blood glucose, Serum Alkaline Phosphatase, Alfa feto protein, Carcinoembryonic Antigen, CA<sub>19-9</sub>, CA 125, HBs Ag, HCV Ab).

Using sterile technique, the skin was cleansed with povidone Iodine USP 10% (1% available Iodine). The ultrasound guidance was done by an experienced ultrasonographer using SONAC 8000 Live (prime) MEDISON device with a probe of 3.5 MHz, convex free hand technique. After the localization of the lesion (s), the needle (spinal needle 22 G  $\times$  3<sub>1/2</sub>) was advanced under continuous ultrasound guide through the skin and soft tissue and into the target mass. After ensuring the correct position of the needle tip, the trocar was removed and a 10 ml syringe was attached; then a 2 - 3 ml negative pressure was applied while performing 2 - 4 punctures of the wall and central part of the lesion, then the needle was withdrawn and the specimen was distributed over slides which were immediately placed into a 95% alcohol solution for 20 minutes, and then, it was left to dry and later sent for cytological examination.

All slides were studied by two expert pathologists. Follow up was done for all patients after the procedure for 6 hours to observe any complications. Statistical analysis was done using SPSS Software version 17.

### 3. Results

One hundred patients with focal liver lesion (s) were enrolled in this study, 54 patients were male (54%), and 46 were female (46%). Age of the patients ranged between 23 to 88 years with (a mean age + SD) of  $55 \pm 5.36$  year. The majority (64%) of patients were above 60 years (**Figure 1**).

The most common presenting symptoms among the patients were fatigue and weight loss (90% and 78% respectively), while the most common sign was hepatomegaly (38%). Therefore, the rest of the symptoms and signs are illustrated in **Table 1**.

Anemia and high ESR was found in (54% and 90% respectively) and low serum albumin in (64%), **Table 2**.

Viral markers had been performed for all the patients, and only 8 patients (8%) had positive results of HBs Ag. Four HBs Ag positive cases had secondaries and four cases had hepatocellular carcinoma by FNAC. None were positive for HCV.

**Table 3** revealed levels of tumor markers. Ultrasonic findings and distribution of liver masses are shown in **Table 4**.

**Table 5** demonstrates the sites of primary tumors.

**Table 6** compares the trans-abdominal ultrasound of the studied patients with the results of ultrasonic guided FNAC.

**Table 1.** Clinical characteristics of the studied patients (N = 100).

Clinical features	Patients No.	Percentage
<b>HISTORY</b>		
Fatigue	90	90
Weight loss	78	78
Anorexia	76	76
Rt. Hypochondrial and epigastric Pain	60	60
Constipation	40	40
Pallor	31	31
Jaundice	28	28
Itching	12	12
<b>EXAMINATION</b>		
Hepatomegaly	38	38
Leg edema	15	15
Palmer erythema	14	14
Ascites	10	10
Clubbing	8	8
Duputyrens' contracture	4	4
Flapping tremor	4	4
Gynaecomastia	2	2
Splenomegaly	2	2

**Table 2.** Hematological, biochemical investigations of the study population (N = 100).

Hematologic Parameters	Low No. (%)	Normal No. (%)	High No. (%)
PCV%	54 (54)	46 (46)	0 (0)
WBC	14 (14)	74 (74)	12 (12)
ESR	0 (0)	10 (10)	90 (90)
Platelet	4 (4)	93 (93)	2 (2)
TSB	0 (0)	78 (78)	22 (22)
AST	0 (0)	74 (74)	26 (26)
ALT	0 (0)	86 (86)	14 (14)
S. Albumin	64 (64)	36 (36)	0 (0)
Bl. Urea	0 (0)	75 (74)	25 (25)
PT/INR	0 (0)	58 (58)	42 (42)

**Table 3.** Tumor markers of the studied patients.

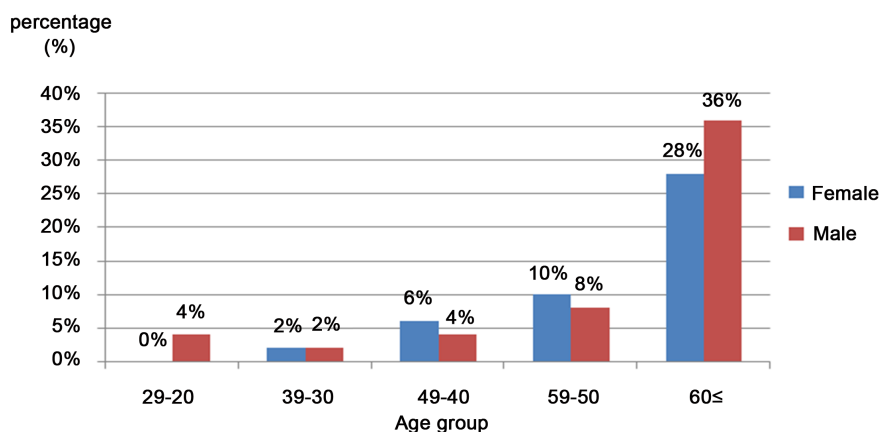
High level Tumor markers	HCC	Second- ary	Abscess	Hemangioma	Inconclusive	Total
AFP	6	14				20
CEA		32			2	34
CA 19-9	2	34			2	38
CA 125	4	40			2	46
<b>Total</b>	<b>10</b>	<b>80</b>	<b>1</b>	<b>3</b>	<b>6</b>	<b>100</b>

**Table 4.** U/S distribution of liver lesions (N = 100).

Ultrasonic findings	No.	Percent
Multiple	80	80
Single	20	20
Rt. Lobe	38	39
Rt. and Left	58	57
Lt lobe	4	4

**Table 5.** The primary sites of liver secondaries.

Primary sites	No (%)	Histology	Diagnostic techniques
Breast	13 (13)	Invasive ductal carcinoma	Previous Mastectomy
Stomach	12 (12)	Adenocarcinoma	OGD-Histopathology
Pancreas	8 (8)	Adenocarcinoma	Ultrasonography-FNAC
Colon	7 (7)	Adenocarcinoma	OGD- Histopathology
Esophagus	4 (4)	Adenocarcinoma	OGD- Histopathology
Bronchus	2 (2)	Squamous cell carcinoma	Bronchoscopy-Histopathology
Prostate	2 (2)	Adenocarcinoma	Previous prostatectomy
Retro peritoneal	2 (2)	Sarcoma	Ultrasonography-FNA
Unidentified	30 (30)		
<b>Total</b>	<b>80 (80)</b>		



**Figure 1.** Age and gender distribution of cases (N = 100),  $P$ -value = 0.64 (there is no significant difference between age groups and no significant difference between  $\geq 60$  years and  $<60$  years;  $P = 0.89$ ).

**Table 6.** Ultrasonography findings vs. FNAC results.

Age group (year)	Ultrasound Finding					FNAC				Total	
	Abscess	Heman	HCC	2nd	Total	Abscess	Heman	HCC	2nd Inco		
20 - 29				4	4				4	4	
30 - 39				4	4				4	4	
40 - 49				10	10				5	3	8
50 - 59		2	2	14	18		3	4	14	1	22
60 and More	1	1	4	58	64	1		6	53	2	62
<b>Total</b>	1	3	6	90	100	1	3	10	80	6	100

Sixty two (62%) patients (38% males and 24% females) were found to be free from pain during and after the procedure, while 38 (38%) patients (16% males and 22% females) had developed mild and transient right hypochondrial pain.

#### 4. Discussion

Focal liver lesions (FLL) have been a common reason for the consultation faced by gastroenterologists and hepatologists. It is important to consider not only malignant liver lesions, but also benign solid and cystic liver lesions such as hemangioma, focal nodular hyperplasia, hepatocellular adenoma, and hepatic cysts in the differential diagnosis [28]. Fine Needle Aspiration cytology is a safe and effective method of establishing a definitive diagnosis of either metastatic or primary malignancy [29] [30]. FNA cytology is usually guided by ultrasound or CT [31] [32].

The use of Fine Needle technique has been shown to shorten the length of hospitalization, obviate the need for more invasive procedures including laparoscopy and considerably lower the cost of hospitalization in many situations [33].

The Sonographic FNA technique requires no more time than a routine abdo-

minal scan which is usually less considerable. This technique also may be performed portably or outside the ultrasound laboratory when necessary [30].

This study was performed on 100 patients. However, most of them were adult and elderly age groups, 18 patients (18%) between 50 to 59 years and 64 patients (64%) were beyond 60 years of age, which indicates that the liver masses are most common in the elderly age group as it is a usual age for malignancy.

The most common presenting symptoms among the patients were fatigue and weight loss (90% and 78% respectively), while the most common signs were hepatomegaly, which is comparable to other study [34].

Anemia and high ESR found in (54% and 90% respectively) and low serum albumin in 64% is expected in people with malignancy [35].

Most of the patients in our study proved by FNAC as cases of secondaries (80%) were close to that found by ultrasound (90%) which means that the (p) value of FNAC is (0.001), which indicated the significance of FNA in comparison to radiological findings. Furthermore, we did not compare our procedure to histopathological examination which is definitive diagnosis of benign or malignant lesions, because it is unwise to do laparotomy for suspicion of multiple secondaries in elderly and end stage patients.

The finding of high percent (80%) of secondary lesions in the liver in our study was similar to another study which found the overall accuracy to be 92% and 94% respectively. The specificity of the procedure was 100%. Ultrasonically guided fine-needle aspiration cytology followed by cytological examination appears indispensable in the diagnosis and differentiation between benign and malignant hepatic and pancreatic focal lesions [36].

FNA is superior in the diagnosis of HCC because 6 cases of HCC were diagnosed by Ultrasound. Therefore, 10 cases proved HCC by FNA, accompanied by high tumor markers (AFP) which is more supportive for HCC.

In this study, the FNA results of 7 patients (7%) were inconclusive or contained blood elements. In two of them, ultrasound had suggested secondary lesion, but CT scan showed simple cyst. Later on, FNA was done and the result was just blood. Thus, the clinical course of the patient and the tumor marker were in favor of non malignant lesion.

This was comparable to the study done by Wei Ding *et al* in Hangzhou, China which was performed on 46 patients. Thus, 6 patients had Red Blood Cells on aspirations which are in agreement with other study [37] [38].

One patient had history of breast carcinoma with mastectomy, but on follow up, focal liver lesion found. The Radiologist and Oncologist suspected secondary for which FNA was done, and fortunately, the results was sheets of pus cells. The sample sent for culture and it revealed the growth of *Staphylococcus aureus*, and also, tumor markers and clinical course of the disease suggest non malignant lesions *i.e.* ultrasonic examination alone cannot differentiate benign from malignant lesion definitely and thus, it is better to decide on radiological examination, FNAC and tumor markers.

The outcome of the procedure in our study was very favorable. Therefore, on-

ly mild non persistent right hypochondrial pain was seen in 38% of the patients. Our outcome has been comparable to that reported in other studies [39]. At the same time, this very accepted outcome indicates that post procedure ultrasonography is unnecessary and should only be reserved when a major complication is suspected [39].

## 5. Conclusion

Fine Needle Aspiration Cytology is minimally invasive and a rapid method for pathologic evaluation of focal hepatic masses. Early evaluation and workup is important for early management. Thus, the most common focal liver lesions are hepatic secondaries which are more common in elderly patients. Radiological examination, whether by ultrasound or CT scan alone cannot differentiate between benign or malignant lesions definitely and should be followed and confirmed by FNA under imaging scan.

## References

- [1] Ten Berge, J., Hoffman, B.J., Hawes, R.H., *et al.* (2002) EUS-Guided Fine Needle Aspiration of the Liver: Indications Yield, and Safety Based on an International Survey of 167 Cases. *Gastrointestinal Endoscopy*, **55**, 859-862. <https://doi.org/10.1067/mge.2002.124557>
- [2] Babb, R.R. and Jackman, R.J. (1989) Needle Biopsy of the Liver. A Critique of Four Currently Available Methods. *Western Journal of Medicine*, **150**, 39-42.
- [3] Bret, P.M., Sente, J.M., Bretagnolle, M., *et al.* (1986) Ultrasonically Guided Fine-Needle Biopsy in Focal Intrahepatic Lesions: Six Years' Experience. *Canadian Association of Radiologists Journal*, **37**, 5-8.
- [4] Edoute, Y., Tibon-Fisher, O., Ben-Haim, S.A., *et al.* (1991) Imaging Guided and Non Imaging-Guided Fine Needle Aspiration of Liver Lesions: Experience with 406 Patients. *Journal of Surgical Oncology*, **48**, 246-251. <https://doi.org/10.1002/jso.2930480407>
- [5] Guo, Z., Kurtycz, D.F., Salem, R., *et al.* (2002) Radiologically Guided Percutaneous Fine-Needle Aspiration Biopsy of the Liver: Retrospective Study of 119 Cases Evaluating Diagnostic Effectiveness and Clinical Complications. *Diagnostic Cytopathology*, **26**, 283-289. <https://doi.org/10.1002/dc.10097>
- [6] Pitman, M.B. (1998) Fine Needle Aspiration Biopsy of the Liver. Principal Diagnostic Challenges. *Clinics in Laboratory Medicine*, **18**, 483-506.
- [7] Michielsen, P.P., Duysburgh, I.K., Francque, S.M., *et al.* (1998) Ultrasonically Guided Fine Needle Puncture of Focal Liver Lesions. Review and Personal Experience. *Acta Gastro-Enterologica Belgica*, **61**, 158-163.
- [8] Pilotti, S., Rilke, F., Claren, R., *et al.* (1988) Conclusive Diagnosis of Hepatic and Pancreatic Malignancies by Fine Needle Aspiration. *Acta Cytologica*, **32**, 27-38.
- [9] Samaratunga, H. and Wright, G. (1992) Value of Fine Needle Aspiration Biopsy Cytology in the Diagnosis of Discrete Hepatic Lesions Suspicious for Malignancy. *Australian and New Zealand Journal of Surgery*, **62**, 540-544. <https://doi.org/10.1111/j.1445-2197.1992.tb07047.x>
- [10] Bell, D.A., Carr, C.P. and Szyfelbein, W.M. (1986) Fine Needle Aspiration Cytology of Focal Liver Lesions. Results Obtained with Examination of Both Cytologic and Histologic Preparations. *Acta Cytologica*, **30**, 397-402.



- [11] Whitlatch, S., Nunez, C. and Pitlik, D.A. (1984) Fine Needle Aspiration Biopsy of the Liver. A Study of 102 Consecutive Cases. *Acta Cytologica*, **28**, 719-725.
- [12] Jacobsen, G.K., Gammelgaard, J. and Fuglo, M. (1983) Coarse Needle Biopsy versus Fine Needle Aspiration Biopsy in the Diagnosis of Focal Lesions of the Liver. Ultrasonically Guided Needle Biopsy in Suspected Hepatic Malignancy. *Acta Cytologica*, **27**, 152-156.
- [13] Cochand-Priollet, B., Chagnon, S., Ferrand, J., *et al.* (1987) Comparison of Cytologic Examination of Smears and Histologic Examination of Tissue Cores Obtained by Fine Needle Aspiration Biopsy of the Liver. *Acta Cytologica*, **31**, 476-480.
- [14] Buscarini, L., Fornari, F., Bolondi, L., *et al.* (1990) Ultrasound-Guided Fine-Needle Biopsy of Focal Liver Lesions: Techniques, Diagnostic Accuracy and Complications. A Retrospective Study on 2091 Biopsies. *Journal of Hepatology*, **11**, 344-348. [https://doi.org/10.1016/0168-8278\(90\)90219-H](https://doi.org/10.1016/0168-8278(90)90219-H)
- [15] Chawla, Y.K., Ramesh, G.N., Kaur, U., Bambery, P. and Dilawar, J.B. (1990) Percutaneous Liver Biopsy: A Safe Outpatient Procedure. *Journal of Gastroenterology and Hepatology*, **5**, 94-95. <https://doi.org/10.1111/j.1440-1746.1990.tb01770.x>
- [16] Fornari, F., Civardi, G., Cavanna, L., *et al.* (1989) Complications of Ultrasonically Guided Fine-Needle Abdominal Biopsy. Results of a Multicenter Italian Study and Review of the Literature. The Cooperative Italian Study Group. *Scandinavian Journal of Gastroenterology*, **24**, 949-955. <https://doi.org/10.3109/00365528909089239>
- [17] Smith, E.H. (1991) Complications of Percutaneous Abdominal Fine Needle Biopsy. Review. *Radiology*, **178**, 253-258. <https://doi.org/10.1148/radiology.178.1.1984314>
- [18] Pitman, M.B. (1998) Fine Needle Aspiration Biopsy of the Liver. Principal Diagnostic Challenges. *Clinics in Laboratory Medicine*, **18**, 483-506.
- [19] Vergara, V., Garripoli, A., Marucci, M.M., Bonino, F. and Capussotti, L. (1993) Colon Cancer Seeding after Percutaneous Fine Needle Aspiration of Liver Metastasis. *Journal of Hepatology*, **18**, 276-278. [https://doi.org/10.1016/S0168-8278\(05\)80269-7](https://doi.org/10.1016/S0168-8278(05)80269-7)
- [20] Yamada, N., Shinzawa, H., Ukai, K., *et al.* (1993) Subcutaneous Seeding of Small Hepatocellular Carcinoma after Fine Needle Aspiration Biopsy. *Journal of Gastroenterology and Hepatology*, **8**, 195-198. <https://doi.org/10.1111/j.1440-1746.1993.tb01513.x>
- [21] Hamazaki, K., Matsubara, N., Mori, M., *et al.* (1995) Needle Tract Implantation of Hepatocellular Carcinoma after Ultrasonically Guided Needle Liver Biopsy: A Case Report. *Hepato-Gastroenterology*, **42**, 601-606.
- [22] Austin, J.H. and Cohen, M.B. (1993) Value of Having a Cytopathologist Present during Percutaneous Fine-Needle Aspiration Biopsy of Liver: Report of 55 Cancer Patients and Metaanalysis of the Literature. *American Journal of Roentgenology*, **160**, 175-177. <https://doi.org/10.2214/ajr.160.1.8416620>
- [23] Miller, D.A., Carrasco, C.H., Katz, R.L., *et al.* (1986) Fine Needle Aspiration Biopsy: The Role of Immediate Cytologic Assessment. *American Journal of Roentgenology*, **147**, 155-158. <https://doi.org/10.2214/ajr.147.1.155>
- [24] Pak, H.Y., Yokota, S., Teplitz, R.L., *et al.* (1981) Rapid Staining Techniques Employed in Fine Needle Aspirations of the Lung. *Acta Cytologica*, **25**, 178-184.
- [25] Weinberg, A.G. and Finegold, M.J. (1983) Primary Hepatic Tumors of Childhood. *Human Pathology*, **14**, 512-537. [https://doi.org/10.1016/S0046-8177\(83\)80005-7](https://doi.org/10.1016/S0046-8177(83)80005-7)
- [26] Craig, J.R., Peters, R.L. and Edmonson, H.A. (1989) Tumors of the Liver and Intrahepatic Bile Ducts. 2nd Edition, AFIP, Washington DC.
- [27] Imoto, M., Nishimura, D., Fukuda, Y., *et al.* (1985) Immunohistochemical Detection of Alpha-Fetoprotein, Carcinoembryonic Antigen, and Ferritin in Forma-

- lin-Paraffin Sections from Hepatocellular Carcinoma. *American Journal of Gastroenterology*, **80**, 902-906.
- [28] Marrero, J.A., Ahn, J. and Rajender Reddy, K. (2014) ACG Clinical Guideline: The Diagnosis and Management of Focal Liver Lesions. *The American Journal of Gastroenterology*, **109**, 1328-1347. <https://doi.org/10.1038/ajg.2014.213>
- [29] Ferrucci, J.T., Wittenberg, J. and Mueller, P.R. (1980) Diagnosis of Abdominal Malignancy by Radiologic Fine Needle Aspiration Biopsy. *American Journal of Roentgenology*, **134**, 323-330. <https://doi.org/10.2214/ajr.134.2.323>
- [30] Holm, H.H., Als, O. and Gammelgaard, J. (1979) Percutaneous Aspiration and Biopsy Procedure Under Ultrasound Visualization. In: Taylor, K.J.W., Ed., *Diagnostic Ultrasound in Gastrointestinal Disease*, Churchill Livingstone, New York, 137-149.
- [31] Jegou, J., Peruzzi, P., Arav, E., et al. (2004) Métastases mixtes cutanéο-osseuses révélatrices d'un carcinome hépatocellulaire. *Gastroentérologie Clinique et Biologique*, **28**, 804-806. [https://doi.org/10.1016/S0399-8320\(04\)95132-9](https://doi.org/10.1016/S0399-8320(04)95132-9)
- [32] Torzilli, G., Minagawa, M., Takayama, T., et al. (1999) Accurate Preoperative Evaluation of Liver Mass Lesions without Fine Needle Biopsy. *Hepatology*, **30**, 889-893. <https://doi.org/10.1002/hep.510300411>
- [33] Mitty, H.A., Efremides, S.C. and Yeh, H. (1981) Impact of Fine Needle Biopsy on the Management of Patients with Carcinoma of the Pancreas. *American Journal of Roentgenology*, **137**, 1119-1121. <https://doi.org/10.2214/ajr.137.6.1119>
- [34] Carr, B.I. (2012) Tumors of the Liver and Biliary Tree. In: Longo, D.L., Fauci, A.S., Kasper, D.L., et al., Eds., *Harrison's Principles of Internal Medicine*, 18th Edition, McGraw Hill, New York, 777-785.
- [35] Collier, J.D. and Webster, G. (2010) Liver and Biliary Tract Disease. In: Nicki, R., Brian, R., Stuart, H., et al., Eds., *Davidson's Textbook of Medicine*, 18th Edition, Churchill Livingstone, New York, 927-929.
- [36] Ljubicic, N., Bilic, A., Lang, N. and Bakula, B. (1992) Ultrasonically Guided Percutaneous Fine Needle Aspiration Biopsy of the Hepatic and Pancreatic Focal Lesions: Accuracy of Cytology in the Diagnosis of Malignancy. *Journal of the Royal Society of Medicine*, **85**, 139-141.
- [37] Ding, W. and He, X.J. (2004) Fine Needle Aspiration Cytology in the Diagnosis of Liver Lesions. *Hepatobiliary & Pancreatic Diseases International*, **3**, 90-92.
- [38] Hall-Craggs, M.A. and Lees, W.R. (1987) Fine Needle Biopsy: Cytology, Histology or Both. *Gut*, **28**, 233-236. <https://doi.org/10.1136/gut.28.3.233>
- [39] Carrera Alonso, E., Garcia Gonzalez, M., Valer lopez-Fando, P., et al. (2007) Department of Gastroenterology. Ramon y Cajal Hospital, Madrid.

**Submit or recommend next manuscript to SCIRP and we will provide best service for you:**

Accepting pre-submission inquiries through Email, Facebook, LinkedIn, Twitter, etc.

A wide selection of journals (inclusive of 9 subjects, more than 200 journals)

Providing 24-hour high-quality service

User-friendly online submission system

Fair and swift peer-review system

Efficient typesetting and proofreading procedure

Display of the result of downloads and visits, as well as the number of cited articles

Maximum dissemination of your research work

Submit your manuscript at: <http://papersubmission.scirp.org/>

Or contact [ojgas@scirp.org](mailto:ojgas@scirp.org)