

The Sforzesco brace and SPoRT concept: A brace to replace cast in worst curves

SALVATORE ATANASIO, FABIO ZAINA & STEFANO NEGRINI

ISICO (Italian Scientific Spine Institute), Milan, Italy

Abstract

Purpose. Bracing still remains the most important conservative treatment for scoliosis; approaches to bracing are really many and diverse. The aim of this paper of this paper, is the presentation of the brace we recently developed (the Sforzesco brace and SPoRT concept) to face worst scoliosis, in the past treated through casting.

Methods. The SPoRT concept was born while we were looking for a new brace; it means Symmetric, Patient oriented, Rigid, Three-dimensional and Active. Details of construction and the biomechanical principle of its corrective action are reported. This brace has been used widely in the last 3 years.

Results. The Sforzesco brace showed to be more effective than the Lyon brace and as effective as the Risser cast on different clinical and radiological outcome measures in 2 different prospective study of best clinical practice.

Conclusion. When compared to the other braces, the Sforzesco can find its place in the most important curves, in which there are no alternatives to try avoiding surgery. The SPoRT Concept appear a useful tool to interpret what happens with this brace, even if in the future could be overcome by new theories according to new (and awaited) results in the literature.

Keywords: *Bracing, plaster brace, cast, adolescent idiopathic scoliosis, rehabilitation*

Introduction

According to Italian and Sosort guidelines [1,2] for conservative treatment, reliable and effective approaches to scoliosis consist of exercises, bracing plus exercises, cast plus exercises. Bracing has been questioned by some authors [3,4], but still remains the most important conservative treatment for scoliosis. Approaches to bracing, as testified by this same issue of *Disability and Rehabilitation: Assistive Technology*, are really many and diverse. Moreover, individual physicians apply the same braces in different ways, with an important personalization of treatment that can for sure explain part of the variability of results [5]. In our Institute in these years we developed our own bracing approach that nevertheless was born partly by knowledge and experience, and partly because of a patient-centred approach that is characteristic of ISICO [6]. Behind this approach there are some premises that we will rapidly review in this introduction, before coming to

the core of this paper, that is the presentation of the Sforzesco brace and the SPoRT concept consequently developed through careful observation of this new corrective instrument.

Brace treatment

Brace treatment must almost always achieve a very good aesthetic body shaping (Figure 1) [6–8] and it is intended to achieve radiographic results that are compatible with good functioning of the spine in adulthood, while the quality-of-life impact and psychological disturbance due to the brace must be minimized [5,9,10]. With respect to scoliotic disease, the goal of brace treatment varies according to the degree of curvature considered, and forces (in terms of strength of brace and hours of usage) are consequently administered. The extreme cases to be considered are: In mild progressive adolescent scoliosis (up to 30° Cobb) that cannot be controlled through exercises, the first aim is to avoid

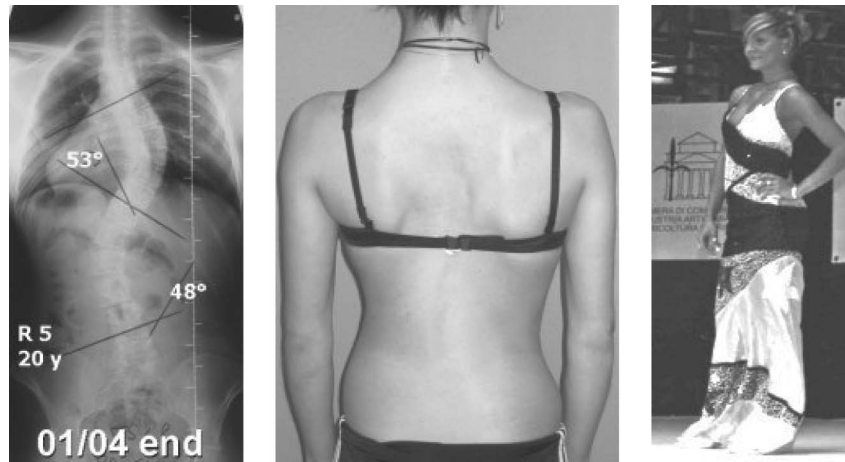


Figure 1. Brace treatment must almost always achieve a very good aesthetic body shaping. Elisa started her treatment pre-menarchial at Risser 1, with 58° and 59° curves and refusing to be operated on. At the end of treatment she reached a very good aesthetic while reducing the curves a little. She has already had some experiences in the fashion world. (With permission of [6]).

progression while allowing the maximum possible freedom in activities of daily life and reducing the discomfort caused by the brace; in severe adolescent scoliosis (up to 45–50°, and over if the patient does not want to be operated on or if surgery is not possible) the aim is at least to avoid progression (and surgery) and possibly also to reduce the amount of curvature.

We developed with time two main braces (Sibilla and Sforzesco) to be applied in different cases, and now the only difference between the two relies on the strength of the material, while the corrective theory behind them is the same. Consequently, the therapeutic choice in the extreme cases painted above are: In mild progressive adolescent scoliosis the chosen brace will be less rigid (Sibilla brace) and will have to be worn at start for 18–23 hours each day until the end of the progressive period; in severe adolescent scoliosis a brace is worn all day long for at least one year, and the most rigid one is chosen (Sforzesco brace). Afterwards, brace wearing is gradually reduced by one or two hours every six months, while maintaining the results, even if the hours are maintained up to 18 per day until Risser stage 3. Treatment is tailored according to these extremes and the individual preferences, anthropometric characteristics and other risk factors such as ATR (angle of trunk rotation), prominence, lumbar curve take-off, unbalance, etc.

Material and methods

The SPoRT concept [9,11,12] was born while we were looking for a new brace, not for a new method of correcting scoliosis. We were searching for a way to avoid casting for our worst patients, because of the significant costs involved both at an individual

(side-effects including cast syndrome, skin problems, great psychological impact, not being able to shower for months, etc.) and a social (inpatient repeated treatment) level. For that reason, we developed the new Sforzesco brace and, while applying and developing it, we ended up with a new, highly effective concept of bracing called SPoRT, whose meaning is:

- *Symmetric*: On the outside the brace is almost perfectly symmetrical. This was a good beginning, but it was gradually overcome as we furthered our understanding of the brace action. Nowadays, the external construction is not so symmetrical, even if it is grossly maintained to reduce visibility and preserve as much as possible a theoretically perfect body shape.
- *Patient-oriented*: This brace is almost invisible under common clothes, according to the acceptability principle. What patients care most about is having a brace that will be seen as little as possible, not to have less material on. This is why they would almost always choose a TLSO instead of a Milwaukee brace [13], even if the first one causes the patient to feel hot during the summer. The Sforzesco brace has its own design, which makes it somewhat fashionable, and this is how patients feel their braces. This is the most important achievement that allows us to increase acceptability, followed by compliance and efficacy;
- *Rigid*: The chosen material and the fact that the brace is made in two large pieces strongly connected with aluminium allow us to achieve a high rigidity that gives rise to higher pushes than in other braces;

- *Three-dimensional*: The brace has a three-dimensional action on the spine, and all its features have been developed with this purpose in mind, starting from its symmetrical and sagittal physiological external appearance. This is discussed extensively in the section on practical application.
- *Active*: This is also a property of the brace, since the Sforzesco allows total freedom of movement for all four limbs, as well as the complete possibility of normal behaviour in activities of daily life, obviously with the exclusion of trunk flexion, bending and rotation (at least from the external point of view: inside the trunk moves only towards correction, while movements towards the progression of pathology are completely blocked).

The SPoRT concept always requires a customized construction of the brace according to the patient's individual requirements. In the opinion of Sibilla [7,8], bracing is a meal served according to a 'menu à la carte' in which one chooses all the elements needed to achieve the best individual result. It is possible to apply CAD-CAM technologies, which usually allow us to obtain the best results in this case, but without using pre-built forms stored in databases, as is usually done. Orthotists must directly shape the scanned trunk according to the patient's requirements, and the physician can check this first draft before final carving. Once done, a final test must be made on the patient in order to change the first theoretical project and adapt it in the best possible way, depending on the real interaction between the body and the brace. This check is made using eyes and hands because one single change is usually not enough, and because it isn't possible to perform repeated radiographs to verify what has been done.

The brace is developed in consideration of the following key points:

- *Foundation*. Like a building, at the base of the brace we need a fix point, which is the pelvis. On one hand, this is a theoretical concept because the pelvis is not a fixed point. On the other hand, proximally applied pushes will always produce counter-pushes on the pelvis, and provided that the brace does not rotate in any 3-D direction on the pelvis, pushes will be correctly applied. If the brace decompensates (i.e., it rotates or it flexes in an antero-posterior or lateral direction), this can be corrected by pushing on the pelvis or by changing pushes on the spine so as to regain a balanced action;
- *Construction*. The brace must be carefully constructed on the sagittal plane, because once built it will not be possible to truly and effectively change this configuration;
- *Pushes*. The brace is a somewhat rough instrument. We try to refine it as much as possible, but current research does not allow us to be as precise as we would like. Usually, we develop a project of correction and then check and change it on the patient. These thoughts and our experience have led us to believe that pushes are not points as conceived by others but areas developed according to curvature characteristics;
- *Escapes*. These are crucial, and are conceived according to curvature characteristics and desired correction. Therefore, they must be considered three-dimensionally. Braces built according to the SPoRT concept seemingly lack escapes because they finish with drivers so as to allow the most important one – vertical escape;
- *Drivers*. These are the areas that control and drive pushes and escapes to obtain the real 3-D action so as to avoid wrong deviations with respect to the desired correction, as well as over-pushes or over-escapes;
- *Stops*. These are commonly referred to as counter-pushes.

The construction (sagittal shaping) of the brace almost always changes according to the curve, even if there are individual variations:

- *Lumbar scoliosis*. The construction must be in lordosis, and with this objective we need an antiversion of the pelvis with a retro-positioning of the upper trunk over the apex of lordosis, while the abdomen must also be allowed to escape anteriorly;
- *Thoraco-lumbar scoliosis*. This must usually be in lordosis, which is due to the tendency of this curve to evolve in junctional kyphosis. In this case, the apex of lordosis must coincide with T12-L1;
- *Thoracic scoliosis*. This must be almost always in kyphosis, which is achieved through the previously described good construction in lordosis and through an important retro-positioning of the higher trunk so as to use the force of gravity to induce the spine to posteriorly 'sit' in the given space while superiorly shaping the brace in an anterior direction.

Because general brace action according to the SPoRT concept is too complex to be adequately described in these few pages, we will now give a complete example of the means to correct a thoracic scoliosis. The Figures have been obtained from an actual case, so they do not always totally coincide

with the theoretical description. However, as already stated, theory is always and continuously changed according to individual needs and reactions to the brace. Terminology is defined according to a posterior-anterior radiograph. Accordingly, convexity and concavity refer to the considered scoliosis curve, not to trunk protuberances. This means that the convex side posteriorly coincides with posterior rib hump and anteriorly with rib depression, while the concave side coincides with anterior rib hump and posterior depression.

Action of deflection

The mechanisms needed to achieve deflection (Figures 2 and 3) action are:

- *Lateral distal convex push (a)*: This is obtained through brace modelling and a direct pad; to reach the spine using the ribs it is necessary to have posterior (1) and anterior (2) convex drivers, while the counter-push is given by the lumbar lateral stop (3). This push drives the spine to the anterior-superior escape (A) through the concave lateral driver (4), which does not allow a direct lateral shift;
- *Lateral proximal concave push (b)*: This is obtained by maintaining the brace high under the axilla through brace modelling and a direct pad. Again, to avoid rib flexion and apply the push to the spine we need the posterior (5) and anterior (6) superior concave drivers as well as the counter-push of the thoracic lateral stop (7). The spine is driven to the anterior-superior escape (A) and also to the convex-superior escape (B);
- *Posterior convex push (c)*: The main action of this push is derotation, but it also becomes deflection due to the thoracic lateral stop (7), which allows a straightening (flattening) of the ribs with no lateral space but only medial space; and the anterior superior (6) and inferior (8) concave drivers, which avoid an anterior escape. Again, in terms of deflection the spine is driven to the anterior-superior escape (A) through the concave lateral driver (4), which does not allow a direct lateral shift.

Action of derotation

The mechanisms needed to achieve derotation action are:

- *Posterior convex push (a)*: This works through the thoracic lateral stop (1) and the posterior (5) and anterior (6) superior concave drivers, which really represent stops so as to avoid an

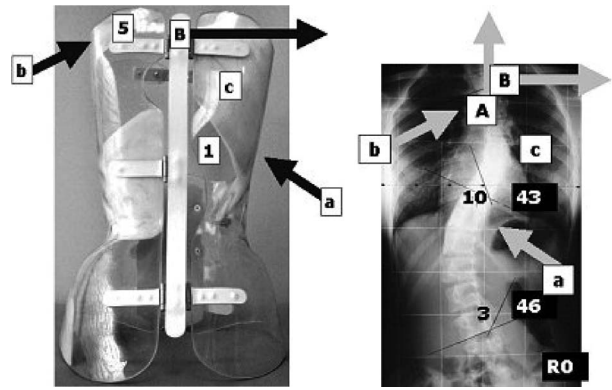


Figure 2. Action of deflection according to SPoRT concept for thoracic scoliosis in the posterior-anterior and radiographic views. Pushes (lower-case letters), escapes (upper-case letters), drivers (numbers) and stops (numbers) are explained in the text. Black letters refer to pushes, drivers and stops on the surface considered, while white letters to controlateral surfaces: e.g., in the lateral view of the brace of Figure 3 the push ‘a’ and the stop ‘7’ are on the right side of the brace (controlateral surface), while all the others are on the left side of it (surface represented). (With permission of [6]).

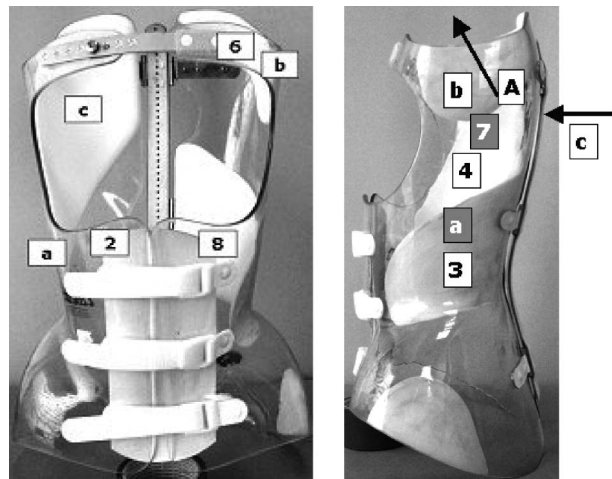


Figure 3. Action of deflection according to SPoRT concept for thoracic scoliosis in the anterior-posterior and lateral views. (With permission of [6]).

anterior uncontrolled buckling of the spine (Figure 4);

- *Anterior-inferior concave push (b)*: It joins the posterior convex push in a couple of forces posteriorly transmitted through the concave lateral driver (4). The lumbar posterior stop (5) avoids a posterior buckle of the spine;
- *Posterior concave escape (A)*: This is the only escape for this correction, even if it does not allow over-derotation due to the posterior concave driver (4) that, once reached, transforms the forces towards the anterior-superior escape considered in the deflection action (Figure 5);

- *Superior concave push (c)*: The combined actions of previously reported forces almost always cause a contra-rotation of the upper girdle towards concavity, which must be controlled through this push (whose action is mainly towards kyphotization) whenever necessary.

Action of kyphotization

This is mainly realized through brace construction, but it is also achieved through other mechanisms as follows:

- *Anterior-inferior bilateral pushes (a)*: They posteriorly decompensate the upper trunk, creating a lordosis through the lumbar posterior bilateral stops (1) but also facilitating the formation of kyphosis (Figure 6);
- *Superior bilateral push (c)*: Once posteriorly unbalanced, the spine must be superiorly

flexed to create kyphosis. The combined actions of previously reported forces almost always cause a contra-rotation of the upper girdle towards concavity, which must be controlled through this push (whose action is anyway mainly towards kyphotization) whenever necessary (Figure 7);

- *Posterior convex push (c)*: Again, the main action of this push is derotation, but it also becomes kyphotization when it is allowed an adequate paravertebral escape to the medial side of the hump, together with the thoracic lateral drivers (2) that allow a straightening (flattening) of the ribs with no lateral space but only medial space; and the anterior superior (6) and inferior (8) concave drivers, which avoid an anterior escape. Again, in terms of deflection the spine is driven to the anterior-superior escape (A) through the concave lateral driver (4), which does not allow a direct lateral shift.

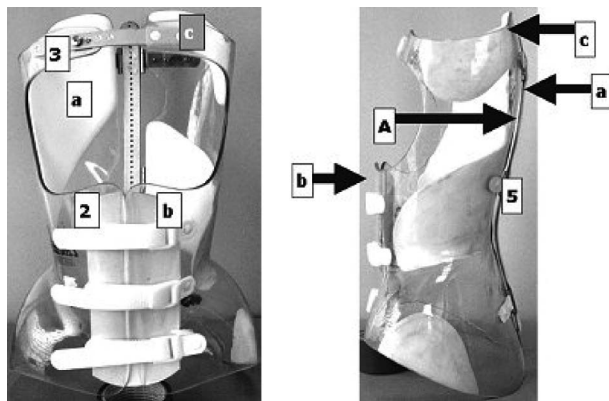


Figure 4. Action of derotation according to SPoRT concept for thoracic scoliosis in the anterior-posterior and lateral views. (With permission of [6]).

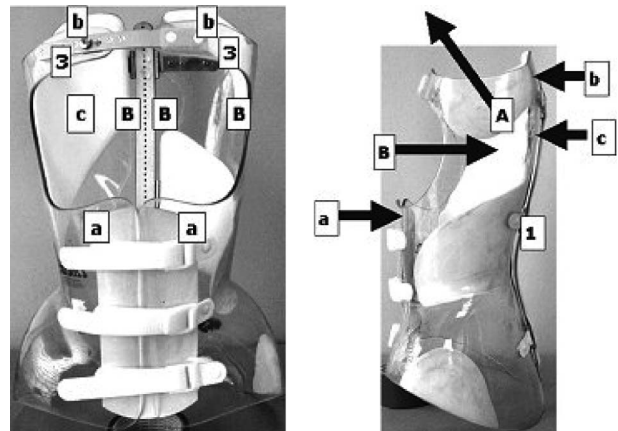


Figure 6. Action of kyphotization according to SPoRT concept for thoracic scoliosis in the anterior-posterior and lateral views. (With permission of [6]).

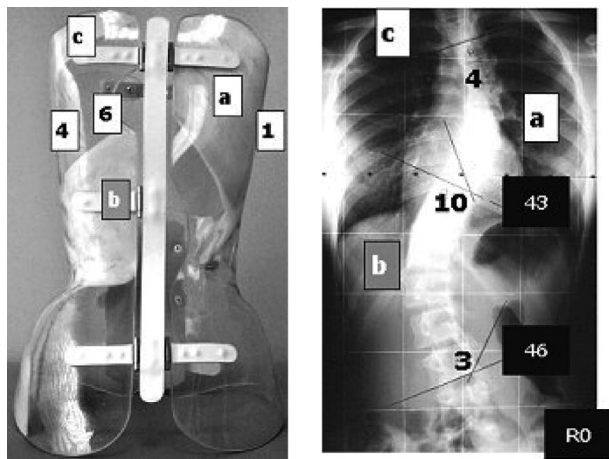


Figure 5. Action of derotation according to SPoRT concept for thoracic scoliosis in the posterior-anterior and radiographic views (Figure 4). (With permission of [6]).

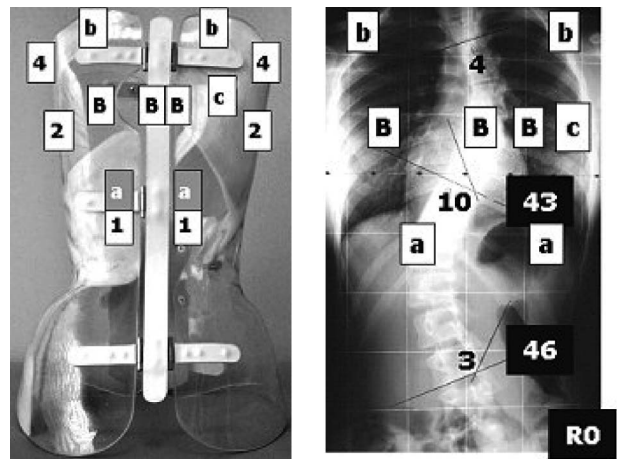


Figure 7. Action of kyphotization according to SPoRT concept for thoracic scoliosis in the posterior-anterior and radiographic views (Figure 5). (With permission of [6]).

Results

The results that are today available on the SPoRT concept relate to the Sforzesco brace and necessarily are short term, because the first treated patients are now reaching the third-year follow-up examination and have not yet completed their treatments. At an anecdotal level (not confirmed by formal studies), we can already state that results are at least maintained over time, according to what is reported below on the basis of preliminary results.

We conducted a prospective cohort study [11,12] (Sforzesco brace, SPoRT correction concept) with a matched retrospective control group (Lyon brace, three-point correction concept) on 30 patients aged 13 years and with curves of 38° Cobb. It was a study on the ‘best available practice’, because the proposed brace was considered the best at the moment of treatment execution. The Sforzesco brace obtained higher mean radiographic improvements in out-of-brace x-rays (−10° Cobb vs. −5°), as well as a better cosmetic appearance of the flanks and shoulders, without the negative impact on kyphosis determined by the Lyon brace. In terms of Cobb degrees, in the Sforzesco group 80% of patients improved and none worsened, while the Lyon group had respective results of 53% and 13%. We did not notice a difference in regard to prominence (Figure 8).

Currently, the Risser plaster brace is also proposed by the Scoliosis Research Society (SRS) as the most effective tool for the conservative treatment of adolescent idiopathic scoliosis. We conducted a prospective cohort study [14] with a retrospective control group on forty-one patients aged four years and with curves of 40° Cobb. Eighteen were treated with the Risser plaster brace and 33 with the Sforzesco brace. It was a study on the ‘best available practice’, because until 2002 plaster had been our standard treatment for the largest curves, while since the midpoint of 2004 we have systematically used the Sforzesco brace. The verification was scheduled at 18 months, when the corrective phase of the treatment has finished (12 months) and the first follow-up examination is available with complete clinical and radiographic out-of-brace data. The Sforzesco was shown to be more effective at reducing the thoracic curve, and its results were super-imposable for the other regions. The Risser plaster brace was shown to be more effective on the thoracic prominence and in regard to the cosmetic appearance of the flanks, but it also caused a serious kyphosis reduction. Considering the decrease of personal (quality of life) and social costs (outpatient treatment for brace, while plasters always require some kind of hospitalization, at least in day-hospital), today we have a plastic brace that can take the place of the Risser plaster brace (Figure 9).

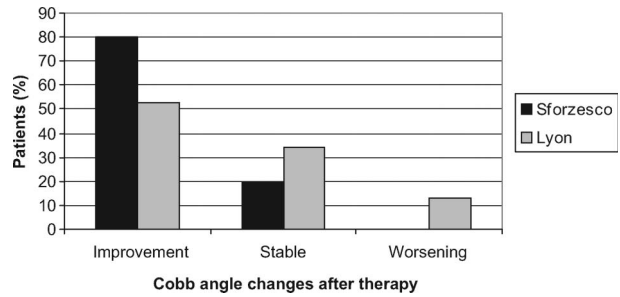


Figure 8. The number of improved patient in terms of Cobb angle is significantly higher in the Sforzesco group than in the Lyon one.

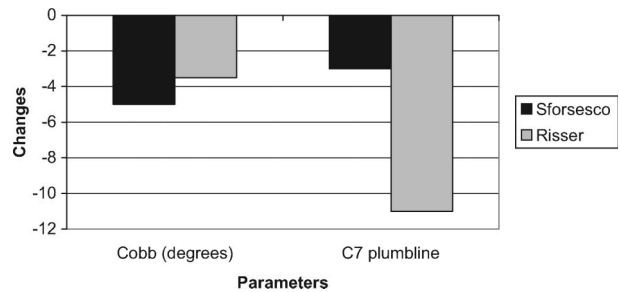


Figure 9. The mean reduction of Cobb angle in out-of-brace x-rays is higher in the Sforzesco group than in the Risser plaster brace one, even if not statistically significant, while the opposite happens for sagittal plane curves.

Conclusion

This brace has recently been developed and results are still in their first phase, but already really promising. It appears to be a brace that could substitute casts, because of the big forces that can be applied to the trunk. In reality, it is not only forces that are important, but how they are applied to the patient [15]; and on the same lines, and even more so, what matters are final results. In this respect the results we collected in the past are a very good starting point [16], but we look for better ones with less effort for the patients.

When compared to the other braces, the Sforzesco can find its place in the most important curves, in which there are no alternatives than pushing as much as possible. When lower degree curves are faced, reduced forces with less discomfort for the patient should be used. The SPoRT Concept appears a useful tool to interpret what happens with this brace, but in the future will presumably be overcome by new theories according to new (and awaited) results in the literature.

References

1. Negrini S, Aulisa L, Ferraro C, Fraschini P, Masiero S, Simonazzi P, Tedeschi C, Venturin A. Italian guidelines on rehabilitation treatment of adolescents with scoliosis or other spinal deformities. *Eura Medicophys* 2005;41:183–201.

Downloaded By: [Negrini, Stefano] At: 10:33 13 June 2008

2. Weiss HR, Negrini S, Rigo M, Kotwicki T, Hawes MC, Grivas TB, Maruyama T, Landaver F, (SOSORT Guideline Committee). Indications for conservative management of scoliosis (guidelines). *Scoliosis* 2006; May 8, 1:5.
3. Dolan LA, Donnelly MJ, Spratt KF, Weinstein SL. Professional opinion concerning the effectiveness of bracing relative to observation in adolescent idiopathic scoliosis. *J Pediatr Orthop* 2007;27:270–276.
4. Dolan LA, Weinstein SL. Surgical rates after observation and bracing for adolescent idiopathic scoliosis: An evidence-based review. *Spine* 2007;32:S91–100.
5. Rigo M, Negrini S, Weiss HR, Grivas TB, Maruyama T, Kotwicki T, SOSORT. SOSORT consensus paper on brace action: TLSO biomechanics of correction (investigating the rationale for force vector selection). *Scoliosis* 2006;1:11.
6. Negrini S. The Evidence-based ISICO approach to spinal deformities. 1st ed. Milan, Boston: ISICO; 2007.
7. Sibilla P. Trent'anni di scoliosi. Lezione 'non' magistrale. In: Negrini S, Rainero G, editors. *Rachide & Riabilitazione 2002*, Vigevano: Gruppo di Studio Scoliosi e patologie vertebrali; 2002. pp 73–92.
8. Sibilla P. Il trattamento conservativo attivo della scoliosi idiopatica in Italia. In: Negrini S, Sibilla P, editors. *Le deformità vertebrali: stato dell'arte*, Vigevano: Gruppo di Studio Scoliosi e patologie vertebrali; 2001. pp 20–41.
9. Negrini S, Marchini G, Tomaello L. Efficacy of the Symmetric, Patient-oriented, Rigid, Three-Dimensional (SPoRT) concept of bracing for scoliosis: A pair-controlled retrospective short-term study on the Sforzesco Brace. In: *SOSORT rICoCMosDaSMot* editor. Poznan, Poland; 2006.
10. Negrini S, Grivas TB, Kotwicki T, Maruyama T, Rigo M, Weiss HR, SOSORT. Why do we treat adolescent idiopathic scoliosis? What we want to obtain and to avoid for our patients. *SOSORT 2005 Consensus paper*. *Scoliosis* 2006;1:4.
11. Negrini S, Marchini G, Tomaello L. The Sforzesco brace and SPoRT concept (Symmetric, Patient-oriented, Rigid, Three-dimensional) versus the Lyon brace and 3-point systems for bracing idiopathic scoliosis. *Stud Health Technol Inform* 2006;123:245–249.
12. Negrini S, Marchini G. Efficacy of the Symmetric, Patient-oriented, Rigid, Three-dimensional, active (SPoRT) concept of bracing for scoliosis: A prospective study of the Sforzesco versus Lyon brace. *Eura Medicophys* 2007;43:171–181.
13. Climent JM, Sanchez J. Impact of the type of brace on the quality of life of adolescents with Spine Deformities. *Spine* 1999;24:1903–1908.
14. Negrini S, Zaina F, Negrini F, Atanasio S, Marchini G. Sforzesco brace (SPoRT Concept) versus Risser cast in adolescent idiopathic scoliosis treatment: Similar efficacy, with reduced spinal side effects for the brace. In: O'Brien JP, Hawes MC, editors. *4th International Conference on Conservative Management of Spinal Deformities*. Boston: SOSORT (Society on Scoliosis Orthopaedic and Rehabilitation Treatment); 2007.
15. Weiss HR, Hawes MC. Adolescent idiopathic scoliosis, bracing and the Hueter-Volkman principle. *Spine J* 2004; 4:484–485; author reply 5–6.
16. Negrini S, Romano M, Negrini A, Parzini S. End-growth final results of an effective conservative treatment: A retrospective case series. In: O'Brien JP, Hawes MC, editors. *4th International Conference on Conservative Management of Spinal Deformities*. Boston: SOSORT (Society on Scoliosis Orthopaedic and Rehabilitation Treatment); 2007.